

## CASE REPORT

# Sporadic porphyria cutanea tarda due to haemochromatosis

H.R.H. de Geus<sup>1\*</sup>, A. Dees<sup>2</sup>

<sup>1</sup>Department of Intensive Care, Erasmus Medical Centre, Rotterdam, the Netherlands (present address),

<sup>2</sup>Department of Internal Medicine, Ikazia Hospital, Rotterdam, the Netherlands,

\*corresponding author: e-mail: [geushrhde@yahoo.com](mailto:geushrhde@yahoo.com)

## ABSTRACT

Haemochromatosis is a hereditary iron-overload syndrome caused by increased intestinal iron absorption and characterised by accumulation of potentially toxic iron in the tissues. Sometimes this disease presents as a cutanea porphyria. We describe a patient with joint complaints and blistering skin lesions on sun-exposed skin. After identifying the porphyria cutanea tarda by urine analysis we found that the serum activity of uroporphyrinogen decarboxylase (UROD) was normal, meaning a partial inactivation of UROD in liver tissue due to external factors. Further investigation showed the homozygous Cys282Tyr missense mutation and high levels of serum ferritin. It is important to recognise the symptoms of iron overloading at an early stage because hereditary haemochromatosis needs to be treated immediately. We therefore advocate routine sampling of ferritin levels in patients with unexplained joint complaints.

## KEYWORDS

Arthralgias, blistering skin lesions, ferritin, haemochromatosis, porphyria cutanea tarda

## INTRODUCTION

Haemochromatosis is an iron-overload syndrome caused by increased intestinal absorption and characterised by accumulation of potentially toxic iron in the tissues. There are primary genetic forms expressed in adults (the Cys282Tyr and H63D mutations) and hereditary juvenile and neonatal forms. Secondary haemochromatosis can be a result of excessive intake of iron, augmented by the use of alcohol and vitamin C, and of multiple blood transfusions, usually seen in patients with persistent anaemias. In its

early stages systemic iron deposition leads to mild symptoms such as fatigue, arthralgias and arthrosis. Untreated though, it can result in major organ damage such as congestive heart failure, cardiac arrhythmias, bronze diabetes, hepatic cirrhosis, impotence and infertility.<sup>1</sup> Early recognition of the symptoms is of crucial importance to prevent further tissue destruction of the various organ systems. The direct or indirect effect of prolonged iron overloading on the skin is the first sign of haemochromatosis. We present a patient referred because of untreatable arthralgias of the hands and blistering lesions on sun-exposed skin.

## CASE REPORT

A 56-year-old male presented with arthralgias, blistering skin lesions on sun-exposed skin and slightly raised liver enzymes: bilirubin 18  $\mu\text{mol/l}$  (0-17), aspartate aminotransferase 75 U/l (<31), alanine aminotransferase 122 U/l (<31), and  $\gamma$ -glutamyltransferase 75 U/l (<35). He consumed two glasses of wine a day. The patient did not have any close relatives such as children, brothers or sisters. Physical examination did not reveal any signs of arthritis or an enlarged liver. However, remarkable blistering skin lesions on his hands and lower legs were seen. Ultrasound of the liver suggested steatosis hepatis without focal lesions. Hepatitis B/C virus, Epstein-Barr virus and cytomegalovirus serology were normal, as were serum levels of the rheumatoid factors. The differential diagnosis consisted of porphyria cutanea tarda (PCT) or paraporphyrin. Subsequent 24-urine analysis revealed elevated levels of uroporphyrinogen III at 116 nmol/mmol creatinine (<2.0), hepta-carboxyl porphyrin 72 nmol/mmol creatinine (<1.6), hexa-carboxyl porphyrin 8.0 nmol/mmol creatinine (<2.4) and penta-carboxyl porphyrin 20 nmol/mmol creatinine (<0.5), indicating partial blockage of the

decarboxylation of uroporphyrinogen III. The activity of uroporphyrinogen decarboxylase (UROD) in erythrocytes, which was normal, differentiated between an acquired and inherited subtype of PCT. To confirm the diagnosis of sporadic type I PCT due to iron overload in case of haemochromatosis, we tested ferritin levels in plasma (>1450 µg/l), iron saturation (105.5%) and HFE gene analysis. This gene turned out to be homozygously changed with the Cys282Tyr missense mutation. A liver biopsy was not performed, considering the highly invasive nature of this test without any clinical consequences, because there were no radiological and biochemical signs of fibrosis.

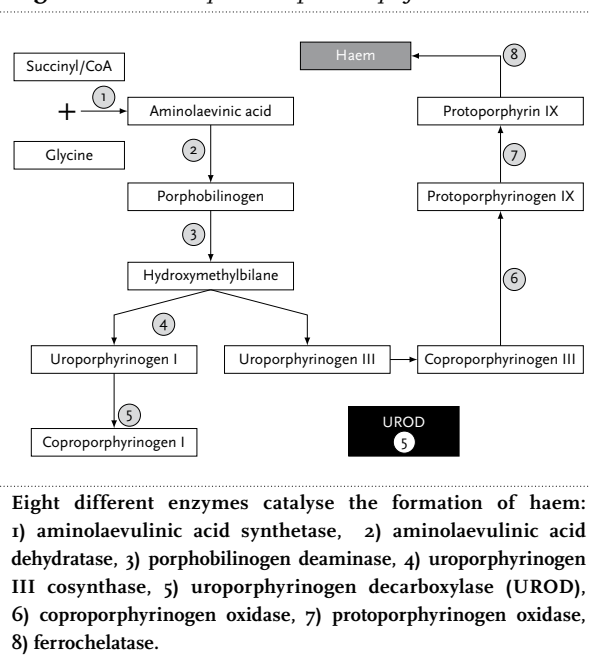
Our patient was strongly advised to stop the use of alcohol-containing products and repeatedly underwent phlebotomy, resulting in a decrease in the ferritin levels of up to 150 µg/l with acceptable haemoglobin levels. The skin abnormalities disappeared rapidly and his joint complaints were controllable with non-steroidal anti-inflammatory drugs. Outpatient visits were continued to control the ferritin levels and six-monthly serum tests of α-fetoprotein levels (AFP) will be performed because of the increased risk of hepatocellular carcinoma in this patient.

## DISCUSSION

In the patient described above, hereditary haemochromatosis was found with a mutation in the HFE gene. Why were iron overload and skin blistering related here? The key to this question is incomplete haem synthesis, producing toxic precursors. In our patient, the blockage in the haem pathway was found at the level of UROD which decarboxylates uroporphyrinogen III to coproporphyrinogen III in four steps producing hepta-, hexa- and penta-carboxyl porphyrin as by-products (*figure 1*; decarboxylation by-products are not shown). The effects of iron on the formation of haem precursors are thought to consist of three cornerstones. First, iron catalyses the formation of reactive oxygen molecules enhancing uroporphyrin formation, secondly iron enhances the production of nonporphyrin products directly inhibiting UROD and thirdly iron induces δ-aminolaevulinic acid synthetase and thus the production of δ-aminolaevulinic acid, the precursor of uroporphyrinogen.<sup>2</sup>

Deficiency or inactivation of UROD causes accumulation and skin deposition of the haem precursor uroporphyrinogen. This molecule is potentially toxic to our skin because of its photosensibility for ultraviolet light (400 nm). The excited energy state leads to complement activation and release of histamine resulting in blistering skin lesions. Expression of this sporadic subtype of PCT (s-PCT) is usually observed in the third or fourth decade,

**Figure 1.** The biosynthetic pathway of haem



since substantial accumulation of iron is required to successfully block the pathway. Hepatitis C infection, alcohol use and usage of oestrogens contribute to the expression of s-PCT.<sup>3,4</sup> Combining these risk factors with hereditary or secondary derived haemochromatosis predisposes even more to the expression of s-PCT.<sup>5,6</sup> Buljai *et al.* performed a study to investigate the correlation of hereditary haemochromatosis (HH) and sporadic porphyria cutanea tarda in an American patient population; they found a significantly higher incidence of s-PCT in homozygous HH patients compared with heterozygous patients and nonaffected controls.<sup>7</sup> The performance of liver biopsies used to be considered the gold standard in diagnosing haemochromatosis. With modern gene analysis, diagnosing HH is much easier and liver biopsies are only performed for prognostic reasons because of potential cirrhosis and hepatocellular carcinoma (HCC). Furthermore, several authors have shown that with simple clinical and biochemical variables (ferritin, platelet counts and aspartate aminotransferase values, absence of hepatomegaly) an accuracy of 77 to 90% can be reached for correctly diagnosing the absence of fibrosis, thus reducing the need for liver biopsy.<sup>8,9</sup> Organ-specific imaging techniques such as magnetic resonance imaging (MRI) will be used in the evaluation of the HH patient in near future. Monitoring is of growing importance, since there is a 20-fold increased risk of developing HCC, especially in men. The highest risk of developing HCC is found in patients with established cirrhosis, thus screening should be focused in that direction.

As in our patient, the recognition of the skin lesions led to the final diagnosis of hereditary haemochromatosis. In retrospect, he had a history of nonspecific joint complaints for two years without any significant skin lesions. Rheumatologists in our country usually perform routine blood tests containing ferritin sampling on patients with arthralgias. Whether or not this is cost-effective in screening for HH in patients with joint complaints is unknown, especially because of the low sensitivity and specificity of the test. The issue remains that we probably would have diagnosed our patient with HH in an earlier stage if we had performed a ferritin sample because of his joint complaints on his first visit to the outpatient clinic.

## REFERENCES

1. Matthews AL, Grimes SJ, Wiesner GL, Acheson LS. Clinical consult: iron overload--hereditary hemochromatosis. *Prim Care* 2004;31(3):767-xiii.
2. Lambrecht RW, Bonkovsky HL. Hemochromatosis and porphyria. *Semin Gastrointest Dis* 2002;13(2):109-19.
3. Roenigk HH Jr, Gottlob ME. Estrogen-induced porphyria cutanea tarda. Report of three cases. *Arch Dermatol* 1970;102(3):260-6.
4. Bonkovsky HL, Poh-Fitzpatrick M, Pimstone N, et al. Porphyria cutanea tarda, hepatitis C, and HFE gene mutations in North America. *Hepatology* 1998;27(6):1661-9.
5. Cruz-Rojo J, Fontanellas A, Moran-Jimenez MJ, et al. Precipitating/aggravating factors of porphyria cutanea tarda in Spanish patients. *Cell Mol Biol (Noisy-le-grand)* 2002;48(8):845-52.
6. Tannapfel A, Stolzel U, Kostler E, et al. C282Y and H63D mutation of the hemochromatosis gene in German porphyria cutanea tarda patients. *Virchows Arch* 2001;439(1):1-5.
7. Bulaj ZJ, Phillips JD, Ajioka RS, et al. Hemochromatosis genes and other factors contributing to the pathogenesis of porphyria cutanea tarda. *Blood* 2000;95(5):1565-71.
8. Beaton M, Guyader D, Deugnier Y, Moirand R, Chakrabarti S, Adams P. Noninvasive prediction of cirrhosis in C282Y-linked hemochromatosis. *Hepatology* 2002;36(3):673-8.
9. Guyader D, Jacquelinet C, Moirand R, et al. Noninvasive prediction of fibrosis in C282Y homozygous hemochromatosis. *Gastroenterology* 1998;115(4):929-36.