

Mastectomy by Inverted Drip Incision and Immediate Reconstruction: Data From 510 Cases

Albert N. van Geel, MD, PhD, Caroline M. E. Contant, MD, Rudi Tjong Joe Wai, MD, Paul I. M. Schmitz, MSc, Alexander M. M. Eggermont, MD, PhD, and Marian M. E. Menke-Pluijmers, MD, PhD

Background: Immediate reconstruction of the breast can be performed in selected cases after mastectomy for breast cancer or after prophylactic mastectomy in patients with a high risk of developing breast cancer. Despite the frequency with which these procedures are performed, data from large series of subpectoral implantation of silicone prostheses in combination with a skin-saving approach are lacking.

Methods: In this retrospective study, data on complications and late surgical interventions in 356 patients who underwent 510 mastectomies with an inverted drip incision and immediate reconstruction (MIDIIR) were analyzed to determine potential prognostic factors of early complications.

Results: In 82% of the MIDIIRs, the postoperative course was uneventful. In 18%, the complications were infection (32 cases), necrosis of the skin flap (29 cases), bleeding (31 cases), and protrusion of the prosthesis (20 cases), resulting in surgery in 9, 12, 15, and 20 cases, respectively. At the end of the follow-up period, 30 (6%) prostheses were definitively removed. Age, size of the prostheses, radiotherapy, previous lumpectomy, and indication for mastectomy were not significant factors for the prognosis of early complications.

Conclusions: With the right technique and indications, MIDIIR is a very safe procedure and should be one of the surgical treatments that can be offered in the overall management of patients with, or at high risk for, breast cancer.

Key Words: Breast cancer—Mastectomy—Reconstruction—Silicone prosthesis—Skin-sparing incision—Complications.

In the 19th century, mastectomy was performed only in patients with bulky or ulcerating breast cancers, and the local control rate was very low. For instance, between 1867 and 1876, Billroth¹ performed 170 mastectomies, and the local recurrence rate was 82%. When Halsted² introduced the principle of radical surgery for breast cancer by combining a simple mastectomy with

resection of both pectoral muscles and an en-bloc axillary node dissection (also for less-advanced stages), the local control rate improved considerably. Between 1889 and 1894 in 50 patients, the rate was 6% but later increased to 32% when the same group was studied again in 1931.³ This radical mastectomy principle was subsequently modified, first by saving the minor pectoral muscle and later by saving both pectoral muscles, without loss of local control being more than 90%.^{4–7}

In selected patients, radiotherapy of the chest wall is indicated, e.g., in case of irradiated resection or extensive axillary of the chest wall and extensive axillary lymph node metastases.⁸ In recent decades, attention has focused on improving other important issues for breast cancer patients, e.g., from a surgical viewpoint, by improving cosmesis. Nowadays it is generally accepted that conservative surgery and radiotherapy is an excellent alternative for modified radical mastectomy, also leading

Received July 3, 2002; accepted December 27, 2002.

From the Departments of Surgical Oncology (ANVG, CMEC, AMME, MMEM-P) and Statistics (PIMS), Erasmus Medical Center/Daniel den Hoed Cancer Clinic; and Department of Plastic Surgery (RTJW), Zuiderziekenhuis, Rotterdam, The Netherlands.

Address correspondence and reprint requests to: Albert N. van Geel, MD, PhD, Department of Surgical Oncology, Erasmus Medical Center/Daniel den Hoed Cancer Clinic, Groene Hilledijk 301, 3075 EA Rotterdam, The Netherlands; Fax: 31-10-4391011; E-mail: anvangeel@erasmusmc.nl.

Published by Lippincott Williams & Wilkins © 2003 The Society of Surgical Oncology, Inc.

to better patient acceptance and psychosocial effects.^{9,10} Subsequent analyses of trials with breast-conserving therapy resulted in better selection criteria for patients with a relatively high local recurrence rate and thus not recommended for breast-conserving therapy (e.g., related to irradiated lumpectomy, age, or extensive ductal carcinoma-in-situ).^{11,12}

Patients that are recommended to undergo a mastectomy can be offered a delayed or immediate breast reconstruction (Fig. 1). The main disadvantage of delayed reconstruction is the period of unnecessary mutilation and the relative loss of skin that also has to be reconstructed.

Immediate reconstruction of the breast must be a safe oncological procedure that does not lead to an increased number of local recurrences compared with mastectomy alone. After a MEDLINE search, Malata et al.¹³ concluded that there is no evidence that immediate reconstruction is associated with higher recurrence rates or interferes with the physical examination during follow-up. Of all available methods for immediate reconstruction, the reconstruction with a subpectoral prosthesis allows the same properties in chest wall palpation as without a prosthesis. The recurrence rate seems to correlate with the tumor stage and biological properties of the breast cancer.¹⁴ Outcome was very similar for pre- and postmenopausal patients and seemed independent of lymph node status.¹⁵ Moreover, an immediate breast reconstruction was shown not to influence subsequent therapy, because adjuvant chemotherapy does not increase the complication rate.¹⁶

Whether the skin-sparing incision is safe has not yet been investigated in a randomized phase III study; published data are mainly based on personal experience. Carlson et al.¹⁷ compared their series of 188 patients undergoing skin-sparing mastectomy with a historical control group of 327 patients with mastectomy alone and concluded that the local recurrence rate was similar in both groups (4.8% vs. 9.5%, respectively, after a median follow-up of 41 months). This conclusion was confirmed

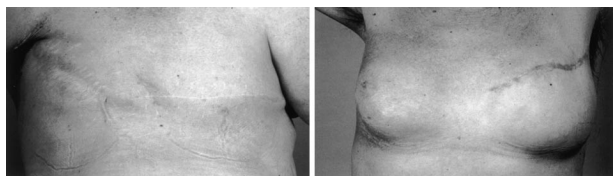

FIG. 1. Photographs of two patients illustrating the surgical history of mastectomy for breast cancer. *Left:* the right side shows the Halsted incision, and the left side shows a modified mastectomy. *Right:* the right side shows a lumpectomy and radiotherapy for breast-saving therapy, and the left side shows an immediate reconstruction with a subpectoral prosthesis after mastectomy.

by others: Slavin et al.¹⁸ investigated 114 native skin flaps and found no evidence for the presence of ducts in the resection margins, whereas Gabka et al.¹⁹ stressed the need for experience in performing this procedure to achieve these results.

Developments in the clinical genetics of breast cancer and the discovery of the *BRCA* genes give women at high risk a choice between intensive surveillance or prophylactic mastectomy. In our clinic, women who choose prophylactic mastectomy are offered an immediate breast reconstruction.

Whereas Halsted used a vertical scar, this was later changed to a horizontal scar for modified radical mastectomy because this horizontal approach enables the surgeon to amputate the breast with wide exposure of the lateral region and the axilla. The wound is usually tailored by reducing the lateral and medial dog ears and produces a “nice flat appearance.” Nevertheless, this scar is ugly and creates some important problems in delayed reconstructive surgery.

In 1990, when our department started immediate breast reconstruction by placement of a subpectoral silicone prosthesis after mastectomy, the matter of the scar was also extensively discussed. Because we were troubled by the transverse scar, we changed our approach. In 1992, for cosmetic reasons, we decided to use Halsted’s original vertical scar but with some modifications: the so-called skin-sparing inverted drip incision. The aim of this study was to investigate the surgical results (complications, corrections, or both) of mastectomy by an inverted drip incision and immediate reconstruction (MIDIIR) and compare these results with other data from the literature.

PATIENTS AND METHODS

Surgical Technique

The operation is performed by a surgeon and a plastic surgeon with the patient in semisitting position, the elbow in flexion, and the hand positioned low on the back. The previous aspiration tract or the incisional/excisional biopsy should have been performed in the future vertical region, which includes the nipple.⁸ The incision extends from just above the nipple down to 1 to 2 cm above the inframammary line (Fig. 2). If the previous scar of a lumpectomy is too far away to include the vertical incision, a separate incision is made to remove the scar in continuity with the breast tissue. Although somewhat less accessible, a mastectomy is then performed with a fiberoptic headlight and dissection by diathermia in the avascular plane. Dissection of the axillary nodes for staging purposes can usually be performed through this

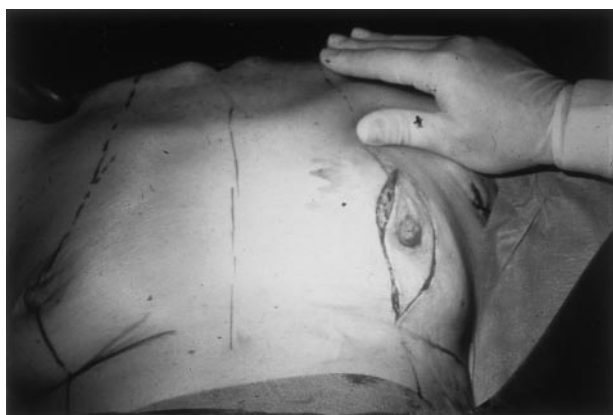

FIG. 2. The inverted drip incision, starting with a round edge just above the nipple down to 1 to 2 cm above the inframammary fold, with a sharp edge.

incision, but a separate incision may be needed if there is inadequate access to the axillary vein. After mastectomy, a subpectoral silicone implant (Cristalline Paragel;TM Laboratoire Eurosilicone, Apt, France) ranging from 150 to 600 mL is inserted through the greater pectoral muscle. Great care is taken to dissect sufficiently far down under the origin of the rectus abdominis muscle and laterally under the serratus muscles, and sometimes even part of the pectoralis minor. Two suction drains are placed: one beneath the pectoral muscle and the other under the skin layer. The skin is closed in layers, without correcting the dog ears. Patients are scheduled for a 5-day stay. The suction drains are removed after production of ≤ 20 mL of drain fluid on two consecutive days. The operation is performed under prophylactic antibiotic and subcutaneous anticoagulant administration. Nipple reconstruction is offered after 6 months.

Study Population

All women who underwent an MIDIIR at the Erasmus Medical Center/Daniel den Hoed Cancer Clinic between January 1992 and August 2001 were included in this study. All medical records of these patients were reviewed (mean follow-up, 63 months; range, 3–116 months). For logistical reasons, the postoperative course was divided into two periods: an early period (<6 weeks) to identify postoperative complications and their related surgical interventions and a late period (>6 weeks) to identify subsequent surgical interventions for cosmetic reasons. Study parameters were age at the time of surgery, indication for MIDIIR, unilateral or (staged) bilateral mastectomy, previous lumpectomy, radiotherapy, size of the implant, early postoperative complications (within 6 weeks), and surgical interventions for cosmetic corrections (after 6 weeks).

Statistical Analysis

Data were analyzed with the statistical program StataTM version 7.0 (Stata Corp., College Station, TX). Comparisons of percentages were made by using the χ^2 test. Continuous data were compared by using the Mann-Whitney *U*-test. A *P* value of <.05 was considered significant. The prognostic factors investigated in relation to complications occurring <6 weeks after surgery were age at MIDIIR (<45 vs. ≥ 45 years), indication for MIDIIR (breast cancer vs. prophylactic), previous lumpectomy (before mastectomy), size of the prosthesis, and radiotherapy (only for recurrence after breast-saving therapy).

RESULTS

Patient Characteristics

From January 1992 to August 2001, 356 patients underwent 510 MIDIIRs. Bilateral MIDIIR was performed in 77 patients (154 MIDIIRs: 140 MIDIIRs were performed synchronously, and 14 MIDIIRs were performed metachronously). The median age at MIDIIR was 43 years (range, 26–66 years; Table 1).

The indications for MIDIIR are listed in Table 1. Most patients (*n* = 239) were treated for breast cancer and had either modified radical mastectomy (*n* = 207) or recurrent breast cancer after breast-saving therapy (*n* = 32).

Prophylactic mastectomy followed by immediate reconstruction was performed in 241 asymptomatic women at high risk of breast cancer (159 with *BRCA1*, 23 with *BRCA2*, and 59 with hereditary breast ovarian cancer). In 104 women, there was no history of breast cancer, whereas 30 women were previously treated for (non)invasive breast cancer. Thirty MIDIIRs were performed for miscellaneous reasons, including severe fibrocystic disease (*n* = 3; bilateral) and anxiety about contralateral breast cancer (especially in patients with lobular carcinoma or dense mammography; *n* = 24).

TABLE 1. Indications for MIDIIR from January 1992 to August 2001 in 356 patients undergoing 510 mastectomies

Indication	Total	Unilateral	Contralateral
<i>BRCA1</i>	159	87	72
<i>BRCA2</i>	23	12	11
HBOC	59	38	21
Recurrence after BST	32	15	17
Carcinoma	207	177	30
Miscellaneous	30	27	3
Total	510	356	154

BST, breast-saving therapy; HBOC, hereditary breast ovarian cancer; MIDIIR, mastectomy with inverted drip incision and immediate reconstruction.

Of the 239 patients who underwent MIDIIR for breast cancer, 178 (74%) had a diagnostic lumpectomy before mastectomy. Of the 510 MIDIIRs, a prosthesis of 150 to 200 mL was used in 16 cases, 220 to 300 mL in 64 cases, 350 to 400 mL in 222 cases, 420 to 500 mL in 203 cases, and 600 mL in 5 cases.

Of the total of 356 women, 39 received radiotherapy before or after MIDIIR: 32 patients were treated previously for breast cancer by breast-saving therapy involving radiation of the breast, and 7 patients received radiotherapy on the chest wall after mastectomy according to the guidelines in our institute after definitive pathologic staging. In five cases, the patient urgently requested mastectomy without removal of the nipple (three unilateral and one bilateral).

Complications Within 6 Weeks

In the 356 women, 510 breast reconstructions were monitored for complications over a median follow-up period of 63 months (range, 3–116 months) after MIDIIR (Table 2). In 419 reconstructions (82%), no complications were observed, whereas the remainder had one or more of the following complications: infection (32 cases), necrosis of the skin flap (29 cases), bleeding (31 cases), and protrusion of the prosthesis (20 cases), resulting in surgery in 9, 12, 15, and 20 cases, respectively. Thus, within 6 weeks after surgery, 56 patients who had MIDIIRs (11%) underwent another surgical intervention. In 7 of the 20 MIDIIR patients with prosthesis-related surgery, the prosthesis was immediately replaced. This means an early loss of prosthesis of 13 of 510 patients, i.e., 2.5%.

TABLE 2. Early complications (<6 wk) and late surgical interventions (>6 wk) after 510 MIDIIRs

	Variable		
	Total	Conservative	Surgical
Early			
Infection	32	23	9
Necrosis	29	17	12
Bleeding	31	16	15
Prosthesis	20	–	13 removed 7 replaced
Late			
Scar/dog ear	45	–	45
Nipple	238	–	238
Prosthesis	83	–	20 removed 53 replaced 10 new

MIDIIR, mastectomy with inverted drip incision and immediate reconstruction.

Late Surgical Interventions After 6 Weeks

Surgical interventions occurring more than 6 weeks after surgery were needed in 366 MIDIIRs (Table 2). These were mainly related to cosmetic appearance, such as nipple reconstruction (238 of the 366 cases), change of prosthesis due to poor symmetry, and correction of scar or dog ear. Of the 83 MIDIIRs for which the indication was related to the prosthesis, in 20 cases the prosthesis was removed. The indications for this were infection, necrosis, or both (six cases) or severe capsular formation (nine cases), whereas the request from three patients (two bilateral) for definitive removal of the prosthesis (personal inconvenience) was not considered related to surgery. In 53 cases, the prosthesis was replaced because of poor cosmetic appearance, capsular formation, or both, and in 10 cases, a new prosthesis was placed after early removal.

During the entire follow-up period (3–116 months), complications related to surgery resulted in a loss of prosthesis in 30 cases (6%). Secondary breast reconstruction was performed in 15 cases: 5 by a new subpectoral, 5 by a subcutaneous prosthesis, and 5 by a pedicled latissimus dorsi flap in combination with a prosthesis. At the end of the follow-up period, the overall loss of prosthesis was 18 (3.5%) of 510. Eighteen (5%) patients with a unilateral MIDIIR requested reduction mammoplasty on the opposite side.

Prognostic Factors Related to Early Complications

The prognostic factors investigated in relation to complications occurring <6 weeks after surgery were age at MIDIIR (<45 vs. ≥45 years), indication of MIDIIR (breast cancer vs. prophylactic), previous lumpectomy (before mastectomy), size of the prosthesis, and radiotherapy (only for recurrence after breast-saving therapy; Table 3). None of these prognostic factors was significant ($P > .05$ in all cases).

DISCUSSION

In most cases, mastectomy is performed with a transverse incision. However, when breast reconstruction is attempted, the transverse scar gives considerable prob-

TABLE 3. Prognostic factors for early complications (<6 wk)

Variable	Prognostic factor	P value
Age	<45 vs. ≥45 y	.53
Indication	Cancer vs. prophylaxis	.64
Previous lumpectomy	Yes vs. no	.39
Size of the prosthesis	<350 vs. ≥350 ml	.10
Previous radiotherapy	Yes/no	.50

lems. First, the scar itself contracts and may have to be lengthened by (lateral) Z-plasty. Second, usually there is an extension up to the median line that can never be corrected. Last but not least, there is a three-dimensional deficit caused by (overly) ample resection and secondary contraction, which requires placement of a tissue expander or use of myocutaneous flaps. Ideally, the center of the scar should give the most projection but unfortunately is contracted, sometimes showing dilated scar tissue. Finally, the transverse scar emphasizes the patch-like appearance of the abdominal skin, contrasting with the thoracic skin.

In reduction mammoplasty, some prefer the vertical scar,^{20–22} whereas others have tried to develop techniques with a short inframammary scar or a periareolar incision.^{23–25} The advantages of the MIDIIR technique are the following:

1. The upper dog ear gives a surplus in the region of the future nipple, providing more projection.²⁶

2. The lower dog ear is inverted after the suction drain is connected, thus creating a natural inframammary fold.

3. Excising the nipple causes some skin loss in the lower pole of the breast. This part is stretched by the correctly positioned prosthesis. In a few months, a nicely rounded form appears. This confirms the investigation of van Egmond et al.,²⁷ who compared the inframammary scars of different types of mammary reductions and concluded that it is the content that determines the final length of the inframammary scar.

4. Because the inner scar (pectoral muscle) and the outer scar (skin) cross each other, this is known as the envelope technique. Apart from providing more stability to pressure (Fig. 3), there are also advantages in perspective: cranially the woman can barely see the full length of

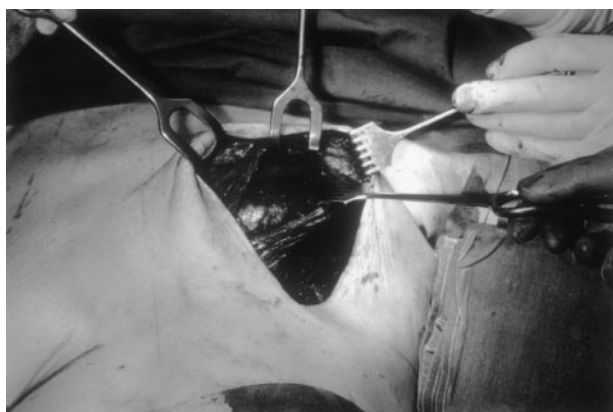


FIG. 3. The envelope technique shows crossing of the skin incision and the pectoralis incision. Subpectoral prosthesis is shown with extension under the rectus abdominis muscle and serratus muscles.

the vertical scar. Frontally the scar appears much smaller because it follows the direction of the inframammary fold and lies on the shadow side of the breast. The actual length of the scar can be reduced by gathering the skin with a continuous intradermal suture.

5. Although the appearance is usually very pleasing, all options remain open: e.g., the nipple can be reconstructed on the elevation of the upper dog ear, the silicone implant can be used as a spacer and can be replaced by (de-epithelized) flaps, and a contralateral reduction can be performed with an identical vertical inframammary scar, thus achieving more symmetry. Even if (for whatever reason) the implant has to be removed, the remaining vertical scar is less conspicuous and smaller than the usual horizontal one.

Since the introduction of DNA testing for the detection of *BRCA1/2* mutation carriers, many women now consider a prophylactic mastectomy.^{27,28} In an attempt to help these women in their free choice, our group decided to offer them an immediate reconstruction after mastectomy.²⁹ By 1992, we considered that we had accumulated sufficient experience with the surgical procedure described previously, and the MIDIIR became a standard surgical tool in our hospital.

The aim of this study was to investigate whether MIDIIR is acceptable with regard to complications and loss of prostheses. It is established that general factors, such as obesity, previous radiotherapy, and smoking, can contribute to complications in reconstructive surgery,^{30–33} whereas other factors, such as the type and size of the prosthesis, age, whether or not the indication is cancer, complete muscle coverage of the prosthesis, and inverted T type of incision, are still disputed.^{30,34,35} Therefore, the prognostic factors studied in our series were age, implant size, previous lumpectomy in primary breast cancer, radiotherapy, and type of indication. Although none of these factors proved to be significant, a comment is required concerning radiotherapy. An earlier study by our group reported radiotherapy to be a negative factor.³⁶ Reasons for this disparity compared with our present series may be improved patient selection, more experience in performing the surgical procedure, and the longer follow-up period in this study.

The complication rate in this series was 18%, which compares well with the 8% to 24% reported by others.^{34,37–41} At the end of the follow-up period, the prosthesis was definitively removed in 30 (6%) of the 510 cases, compared with 1% to 16% reported in the literature.^{30,33,35–39,42} In 15 of our cases, a secondary reconstruction was performed.

For various reasons, 18 (5%) patients with a unilateral MIDIIR requested mammoplasty of the opposite site.

This percentage is very low compared with others, who reported that 50% of their patients underwent reduction of the contralateral breast.^{33,43} We have no explanation for this large difference.

In this study, no information was obtained about subjective factors, such as cosmetic results and psychosocial satisfaction (Fig. 4). These will be investigated prospectively in our hospital; meanwhile, the results of our pilot study on patient satisfaction have been published.⁴⁴

Although we did not evaluate the costs of MIDIIR, it has been estimated that immediate reconstruction is less costly than delayed reconstruction because the latter requires additional hospitalization and more complex reconstructive procedures. It has been reported that the delayed reconstruction can cost \$5,100 to \$10,600 more than immediate reconstruction, irrespective of the type of reconstruction.^{45,46}

In summary, our experience is that MIDIIR is a safe and quick procedure. MIDIIR in our hands had an acceptable complication rate and an acceptable rate of definitive loss of prostheses. The envelope technique allows placement of prostheses of up to 600 mL without the use of a tissue expander. With this technique, another reconstruction can be made after removal of the silicone prosthesis. Regarding limitations, the MIDIIR is not the method of choice for obese patients and those with large breasts; to avoid a bad cosmetic result in these cases, another reconstructive technique (such as transverse rectus abdominis myocutaneous or latissimus dorsi flaps) is recommended. Additional studies are required to determine the long-term cosmetic results of MIDIIR, especially in women with increasing weight and patients with previous radiotherapy.

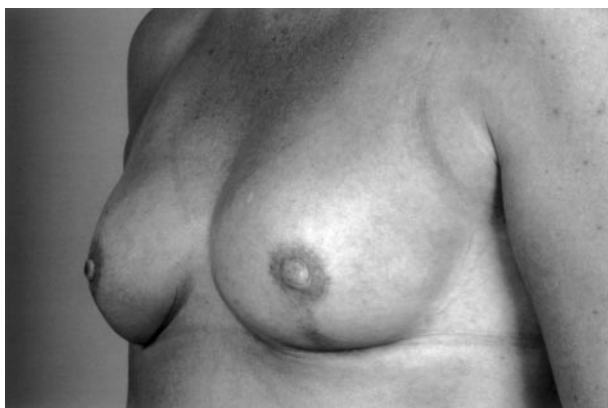

FIG. 4. Bilateral prophylactic mastectomy with inverted drip incision and immediate reconstruction and delayed nipple reconstruction, as performed in our clinic.

ACKNOWLEDGMENTS

The acknowledgments are available online at www.annalssurgicaloncology.org.

REFERENCES

1. Billroth TH. *Die Krankheiten der Brustdruse*. Stuttgart: F. Enke, 1880:116–7.
2. Halsted WS. The results of radical operations for the cure of carcinoma of the breast. *Ann Surg* 1907;46:1–19.
3. Lewis D, Rienhof WF Jr. A study of the results of operation for cure of cancer performed at the John Hopkins Hospital from 1889–1931. *Ann Surg* 1932;95:336–43.
4. Patey DH, Dyson WH. The prognosis of carcinoma of the breast in relation to the type of operation performed. *Br J Cancer* 1948;2:7–13.
5. Madden JL. Modified radical mastectomy. *Surg Gynecol Obstet* 1965;121:1220–30.
6. Auchincloss H. Significance of location and number of axillary metastases in carcinoma of the breast. A justification for a conservative operation. *Ann Surg* 1963;58:37–46.
7. Maddox WA, Carpenter JT Jr, Laws HL, et al. A randomized prospective trial of radical (Halsted) mastectomy versus modified radical mastectomy in 311 breast cancer patients. *Ann Surg* 1983;198:207–12.
8. Wong JS, Harris JR. Importance of local tumour control in breast cancer. *Lancet Oncol* 2001;2:11–7.
9. Effects of radiotherapy and surgery in early breast cancer. An overview of the randomized trials. Early Breast Cancer Trialists' Collaborative Group. *N Engl J Med* 1995;333:1444–55.
10. Paulsen B, Graversen HP, Beckmann J, Blichert-Toft M. A comparative study of post-operative psychosocial function in women with primary operable breast cancer randomized to breast conservation therapy or mastectomy. *Eur J Surg Oncol* 1997;23:327–34.
11. Voogd AC, Nielsen M, Blichert-Toft M, et al. Differences in risk factors for local and distant recurrence after breast-conserving therapy or mastectomy for stage I and II breast cancer: pooled results of two large European randomized trials. *J Clin Oncol* 2001;19:1688–97.
12. Elkhuzen PH, Voogd AC, van den Broek LC, et al. Risk factors for local recurrence after breast conserving therapy for invasive carcinomas: a case-control study of histological factors and alterations in oncogene expression. *Int J Radiat Oncol Biol Phys* 1999;45:73–83.
13. Malata CM, McIntosh SA, Purushotham AD. Immediate breast reconstruction after mastectomy for cancer. *Br J Surg* 2000;87:1455–72.
14. Singletary SE. Skin-sparing mastectomy with immediate breast reconstruction: the MD Anderson Cancer Center experience. *Ann Surg Oncol* 1996;3:411–41.
15. Noguchi M, Fukushima W, Ohta N, et al. Oncological aspects of immediate reconstruction in mastectomy patients. *J Surg Oncol* 1992;50:241–6.
16. Furey PC, Macgillivray DC, Castiglione CL, Allen L. Wound complications in patients receiving adjuvant chemotherapy after mastectomy and immediate reconstruction for breast cancer. *J Surg Oncol* 1994;55:94–197.
17. Carlson GW, Bostwick J III, Stylblo TM, et al. Skin-sparing mastectomy. Oncologic and reconstructive considerations. *Ann Surg* 1997;225:570–5.
18. Slavin SA, Schnitt SJ, Duda RB, et al. Skin-sparing mastectomy and immediate reconstruction: oncologic risks and aesthetic results in patients with early stage breast cancer. *Plast Reconstr Surg* 1998;102:49–62.
19. Gabka CJ, Maiwald G, Bohmert H. Immediate breast reconstruction for breast carcinoma using the periareolar approach. *Plast Reconstr Surg* 1998;101:1228–34.

20. Marchac D, DeOlarde G. Reduction mammoplasty and correction of ptosis with a short inframammary scar. *Plast Reconstr Surg* 1982;69:45–55.
21. Lassus C. Breast reduction: evolution of a technique—a single scar. *Aesthetic Plast Surg* 1987;11:107–112.
22. Lejour M. Vertical mammoplasty and liposuction of the breast. *Plast Reconstr Surg* 1994;94:100–14.
23. Peixoto G. Reduction mammoplasty: a personal technique. *Plast Reconstr Surg* 1980;65:217–26.
24. Bensimon RH, Bergmeyer JM. Improved aesthetics in breast reconstruction: modified mastectomy incision and immediate autologous tissue reconstruction. *Ann Plast Surg* 1995;34:229–33.
25. Suffi PA, Gittos M, Collier DS. Circum-areolar mastectomy with immediate reconstruction (CAMIR). *Eur J Surg Oncol* 2000;26:461–3.
26. Achauer BM. The dog-ear in areolar reconstruction. *Plast Reconstr Surg* 1990;85:647–8.
27. van Egmond DB, IJsselstein K, Ramselaar JM. A comparison between two methods of reduction mammoplasty. *Eur J Plast Surg* 1992;15:75–83.
28. Meijers-Hijboer EJ, Verhoog LC, Brekelmans CTM, et al. Presymptomatic DNA testing and prophylactic surgery in families with a BRCA1 or BRCA2 mutation. *Lancet* 2000;355:2015–20.
29. Contant CME, Menke-Pluijmers M, Seynaeve C, et al. Clinical experience of prophylactic mastectomy followed by immediate reconstruction in women at hereditary risk of breast cancer or with a proven BRCA1 and BRCA2 germ-line mutation. Management, morbidity and oncological aspects in 116 consecutive patients. *Eur J Surg Oncol* 2002;28:627–32.
30. Bailey MH, Smith JW, Casas L, et al. Immediate breast reconstruction: reducing the risks. *Plast Reconstr Surg* 1989;83:845–51.
31. Lin KY, Johns FR, Gibson J, Long M, Drake DB, Moore MM. An outcome of breast reconstruction: presurgical identification of risk factors for complications. *Ann Surg Oncol* 2001;8:586–92.
32. Holley DT, Toursarkissian B, Vasconez HC, et al. The ramifications of immediate reconstruction in the management of breast cancer. *Am Surg* 1995;61:60–5.
33. Ringberg A, Tengrup I, Aspegren K, Palmer B. Immediate breast reconstruction after mastectomy for cancer. *Eur J Surg Oncol* 1999;25:470–6.
34. Dowden RV. Selection criteria for successful immediate breast reconstruction. *Plast Reconstr Surg* 1991;88:628–34.
35. Barreau-Pouhaer L, Lê MG, Rietjens M, et al. Risk factors for failure of immediate breast reconstruction with prosthesis after total mastectomy for breast cancer. *Cancer* 1992;70:1145–51.
36. Contant CME, van Geel AN, van der Holt B, Griep C, Tjong Joe Wai R, Wiggers T. Morbidity of immediate breast reconstruction (IBR) after mastectomy by a subpectorally placed silicone prosthesis: the adverse effect of radiotherapy. *Eur J Surg Oncol* 2000;26:344–50.
37. Sandelin K, Billgren AM, Wichman M. Management, morbidity and oncological aspects in 100 consecutive patients with immediate breast reconstruction. *Ann Surg Oncol* 1998;5:159–65.
38. O'Brian W, Hasselgren PO, Hummel RP, et al. Comparison of postoperative wound complications and early cancer recurrence between patients undergoing mastectomy with and without reconstruction. *Am J Surg* 1993;166:1–5.
39. Francel TJ, Ryan JJ, Manson PN. Breast reconstruction utilizing implants: a local experience and comparison of three techniques. *Plast Reconstr Surg* 1993;92:786–94.
40. Yeh KA, Lyle G, Wei JP, Sherry R. Immediate breast reconstruction in breast cancer: morbidity and outcome. *Am Surg* 1998;64:1195–9.
41. Vinton AL, Traverso LW, Zehring RD. Immediate breast reconstruction following mastectomy is as safe as mastectomy alone. *Arch Surg* 1985;125:1303–8.
42. Clough KB, Bourgeois D, Falcou M-C, Renolleau C, Durand JC. Immediate breast reconstruction by prostheses: a safe technique for extensive intraductal and microinvasive carcinomas. *Ann Surg Oncol* 1996;3:212–8.
43. Wickman M, Jurell G, Sandelin K. Immediate breast reconstruction: short-term experience in 75 consecutive patients. *Scand J Plast Reconstr Surg Hand Surg* 1995;29:153–9.
44. Contant CME, van Wersch AMEA, Wiggers T, Tjong Joe Wai R, van Geel AN. Motivations, satisfaction and information of immediate breast reconstruction following mastectomy. *Pat Educ Couns* 2000;40:201–8.
45. Elkowitz A, Cohen S, Slavin S, Seibert J, Weinstein M, Shaw W. Various methods of breast reconstruction after mastectomy: an economic comparison. *Plast Reconstr Surg* 1993;92:77–83.
46. Khoo A, Kroll SS, Reece GP, et al. A comparison of resource costs of immediate and delayed breast reconstruction. *Plast Reconstr Surg* 1998;104:964–8.