

Circulation

JOURNAL OF THE AMERICAN HEART ASSOCIATION



Late Coronary Occlusion After Intracoronary Brachytherapy

Marco A. Costa, Manel Sabaté, Wim J. van der Giessen, I. Patrick Kay, Pavel Cervinka, Jurgen M. R. Ligthart, Pedro Serrano, Veronique L. M. A. Coen, Peter C. Levendag and Patrick W. Serruys

Circulation 1999;100;789-792

Circulation is published by the American Heart Association, 7272 Greenville Avenue, Dallas, TX 72514

Copyright © 1999 American Heart Association. All rights reserved. Print ISSN: 0009-7322. Online ISSN: 1524-4539

The online version of this article, along with updated information and services, is located on the World Wide Web at:

<http://circ.ahajournals.org/cgi/content/full/100/8/789>

Subscriptions: Information about subscribing to *Circulation* is online at
<http://circ.ahajournals.org/subscriptions/>

Permissions: Permissions & Rights Desk, Lippincott Williams & Wilkins, 351 West Camden Street, Baltimore, MD 21202-2436. Phone 410-5280-4050. Fax: 410-528-8550. Email:
journalpermissions@lww.com

Reprints: Information about reprints can be found online at
<http://www.lww.com/static/html/reprints.html>

Late Coronary Occlusion After Intracoronary Brachytherapy

Marco A. Costa, MD; Manel Sabaté, MD; Wim J. van der Giessen, MD, PhD; I. Patrick Kay, MBChB; Pavel Cervinka, MD; Jurgen M.R. Ligthart, BSc; Pedro Serrano, MD; Veronique L.M.A. Coen, MD; Peter C. Levendag, MD, PhD; Patrick W. Serruys, MD, PhD

Background—Intracoronary brachytherapy appears to be a promising technology to prevent restenosis. Presently, limited data are available regarding the late safety of this therapeutic modality. The aim of the study was to determine the incidence of late (>1 month) thrombosis after PTCA and radiotherapy.

Methods and Results—From April 1997 to March 1999, we successfully treated 108 patients with PTCA followed by intracoronary β -radiation. Ninety-one patients have completed at least 2 months of clinical follow-up. Of these patients, 6.6% (6 patients) presented with sudden thrombotic events confirmed by angiography 2 to 15 months after intervention (2 balloon angioplasty and 4 stent). Some factors (overlapping stents, unhealed dissection) may have triggered the thrombosis process, but the timing of the event is extremely unusual. Therefore, the effect of radiation on delaying the healing process and maintaining a thrombogenic coronary surface is proposed as the most plausible mechanism to explain such late events.

Conclusions—Late and sudden thrombosis after PTCA followed by intracoronary radiotherapy is a new phenomenon in interventional cardiology. (*Circulation*. 1999;100:789-792.)

Key Words: thrombosis ■ angioplasty ■ radioisotopes

Thrombotic occlusion after PTCA is associated with increased morbidity and mortality rates.¹ Current techniques of stenting followed by antiplatelet therapy have dramatically reduced the incidence of this event to <1.5%.^{2,3}

See p 780

Intracoronary radiation is a promising new therapy to prevent restenosis. Recent randomized trials demonstrated a reduction in the restenosis rate and maintenance of benefits up to 2-year follow-up.⁴⁻⁶ Presently, limited data are available regarding long-term safety after intracoronary brachytherapy.^{5,7} Although subacute thrombosis has been reported after radiotherapy,^{4,8-9} the incidence of late thrombotic events has not been determined.

The aim of this study was to document the incidence of late (>1 month) thrombotic events after elective PTCA followed by intravascular radiotherapy.

Methods and Results

From April 1997 to March 1999, 108 consecutive patients were successfully treated with catheter-based intracoronary β -radiation at the Thoraxcenter (Rotterdam, The Netherlands). The Medical Ethical Committee approved the use of radiation therapy and informed consent was obtained from

every patient. All patients presented with stable angina pectoris and single vessel disease. Brachytherapy was performed using the Beta-Cath system (Novoste Corporation)¹⁰ (n=76 patients, 32 stents and 44 balloon angioplasty [BA]), or the Guidant intravascular brachytherapy system (Guidant Corporation Vascular Intervention)¹¹ (n=32 patients, 13 Stents and 19 BA). BA and stenting were performed according to standard techniques. Intravascular ultrasound (IVUS) was performed after radiation with a mechanical ultrasound catheter (CVIS, Boston Scientific). Off-line quantitative coronary angiography was performed using CAAS system (Pie Medical Imaging BV). Six-month angiographic and IVUS follow-up was scheduled in all patients.

All patients were discharged without complications. Ninety-one patients completed at least 2-month clinical follow-up. We observed 1 case of subacute thrombosis occurring 15 days after stenting. This patient received an 18-mm long stent (postdilated at 10 atm) with optimal IVUS result. Ticlopidine withdrawal (12 days after stenting) was the plausible explanation of thrombosis in this case.

Six patients (6.6%) presented with sudden late thrombotic coronary occlusion. Two of them were treated with BA and the remaining 4 received an additional stent after radiation. Their clinical characteristics are summarized in

Received May 10, 1999; revision received June 12, 1999; accepted June 24, 1999.

From Thoraxcenter (M.A.C., M.S., W.J.v.d.G., I.P.K., P.C., J.M.R.L., P.S., P.W.S.), Dijkzigt University Hospital, and Daniel den Hoek Cancer Center (V.L.M.A.C., P.C.L.), Rotterdam, The Netherlands.

Correspondence to Prof Patrick W. Serruys, Head of the Department of Interventional Cardiology, University Hospital Dijkzigt-Thoraxcenter Bd418, Dr. Molewaterplein, 40-3015GD Rotterdam, The Netherlands. E-mail serruys@card.azr.nl

© 1999 American Heart Association, Inc.

Circulation is available at <http://www.circulationaha.org>

Clinical and Angiographic Variables

Variables	1	2	3	4	5	6
Age, y	57	58	49	73	52	62
Sex	Male	Female	Male	Female	Female	Female
Pre-procedure						
Target vessel	LCX	RCA	LCX	LAD	RCA	RCA
Type of lesion	B	B	B	A	A	B
RD, mm	2.5	2.8	2.67	2.66	2.84	2.6
MLD, mm	0.9	1.12	0.64	1.09	0.65	0.55
DS, %	66	60	76	60	77	78
Lesion length, mm	13	15	18	11.2	9.6	9.7
Procedure						
Brachytherapy system	Beta-Cath	Guidant	Beta-Cath	Beta-Cath	Beta-Cath	Beta-Cath
Source length, mm	30	27	30	30	30	30
Prescribed dose, Gy	12*	35†	12*	14*	18*	14*
Stent/angioplasty	Stent	Balloon	Balloon	Stent	Stent	Stent
Total stent length, mm	41			25	25	16
Postprocedure						
Dissection/type	No	Yes/B	Yes/B	No	No	No
MLD, mm	2.47	2.07	2.15	2.4	2.34	2.4
DS, %	-1	26	21	9.5	17	7
Clinical success	Yes	Yes	Yes	Yes	Yes	Yes
Follow-up						
Event	VF	Inferior MI	Posterolateral MI	Anterior MI	Inferior MI	Inferior MI
Time, mo	2	3	15	10	3	2.5
Antiplatelet medication	Yes	Yes	Yes	No	Yes	Yes
Associated factors	Long stent	Dissection	Dissection at 6-mo	Aspirin withdrawal	No	No

LCX indicates left circumflex artery; RCA, right coronary artery; LAD, left anterior descending artery; RD, reference diameter; MLD, minimal lumen diameter; DS, diameter stenosis; VF, ventricular fibrillation; and MI, myocardial infarction.

*At 2 mm from the source; †at 0.5 mm into the vessel wall.

the Table. No clinical or anatomic characteristic appeared to be related to these events.

In patient 1, overlapping 9- and 32-mm NIR stents (Medinol Ltd) were optimally implanted as assessed by IVUS. Patients 2 and 3 (BA) showed type B dissections without compromising flow postprocedure. Patients 4 and 5 both received a Multilink 25-mm stent (Advanced Cardiovascular Systems/Guidant), and patient 6 received a NIR 16-mm stent with optimal angiographic results. Stent patients were discharged on aspirin (250 mg/d) and ticlopidine (250 mg BID for 15 days in patients 3 and 4, and for 30 days in cases 5 and 6). BA patients received aspirin alone.

Patient 1 was readmitted with ventricular fibrillation 2 months after the procedure, whereas, patients 2, 5, and 6 sustained inferior myocardial infarctions (MI) between 2.5 and 3 months after the treatment. The irradiated segment was occluded at 6-month angiogram in patients 1 and 2 (Figure 1). Thrombotic occlusion was successfully treated by primary angioplasty in patients 5 and 6.

In patient 3, the 6-month IVUS control revealed a persistent (unhealed) submedial dissection (Figure 2) with no signs of restenosis. Nine months later, this patient

sustained a posterolateral MI which was treated with thrombolytics. Two weeks after this treatment, an angiogram performed because of recurrent angina showed the occlusion in the irradiated area. Similarly, the 6-month IVUS control of patient 4 showed no neointimal hyperplasia. Four months after control, she had a stroke and aspirin was replaced by acenocoumarol. Ten days later, she sustained an anterior MI. The thrombotic occlusion in the treated site was confirmed by angiography.

Discussion

Progression to total occlusion after BA is a stable process in the general nonirradiated population which occurs in approximately 4% of patients, leading to a MI in <0.5%.¹² In contrast, our study shows a high incidence (6.6%) of thrombotic clinical events 2 to 15 months after PTCA and brachytherapy.

Coronary dissection after BA is associated with abrupt closure; however, type B dissections (NHLBI classification), as observed after BA in our patients, have not been related to thrombotic events.¹³ The normal healing process, present after dissections, may be impaired after intracoro-

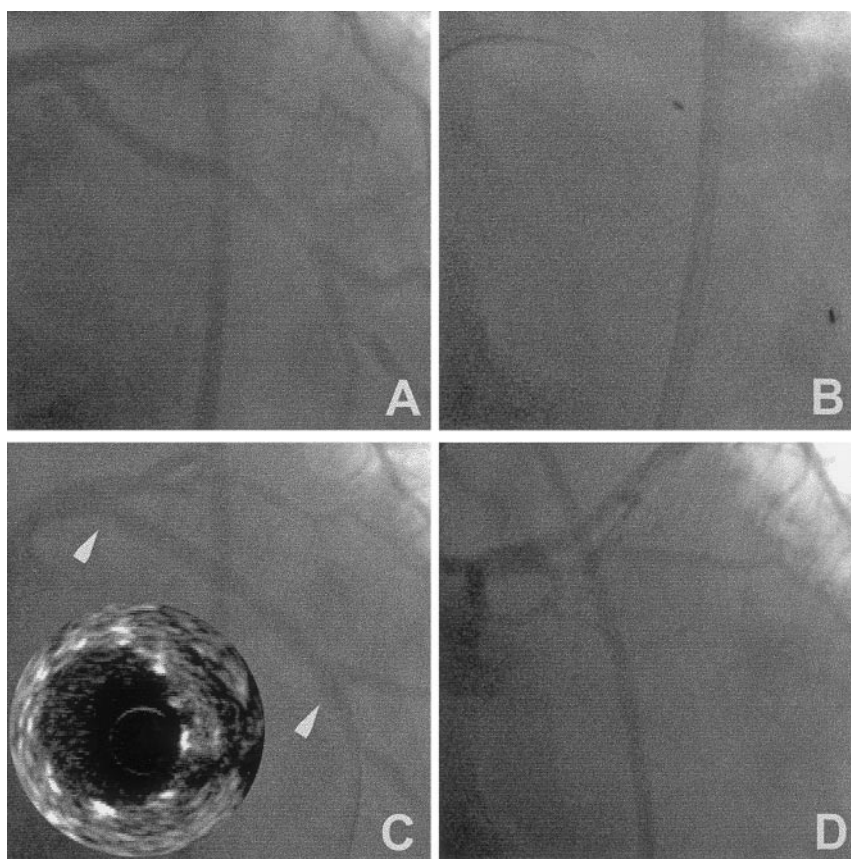


Figure 1. Patient 1. A, Preprocedure angiography shows a significant lesion in the mid-third of left circumflex artery. B, Radioactive source placed in treated site. C, Postprocedure angiography and IVUS images show an optimal result (arrowheads). D, At 2 months, the proximal part of stent appeared occluded.

nary radiation.¹⁴ Whether unhealed dissections, as demonstrated in patient 3, is related to late thrombosis remains to be elucidated in a larger population. Further, the necessity of stenting mild dissections without compromising flow after radiotherapy should be investigated.

The mean time of subacute thrombosis after stenting is approximately 5 to 6 days.^{2,3} In a recent study, subacute thrombosis occurred within the first 24 hours in 86% of patients treated with aspirin and ticlopidine for 14 days, with no case of thrombotic events occurring after 15 days.¹⁵ Colombo et al reported only 2 cases (0.6%) of thrombosis occurring 2 to 6 months after stenting.² In contrast, in our study, 4 patients receiving a stent (8.8%) experienced thrombosis late after radiation.

Experimentally, reendothelialization after injury takes >4 weeks to be completed.¹⁶ However, the clinical presentation of subacute thrombosis infrequently occurs later than 15 days after stenting,¹⁵ when the reendothelialization process may still be incomplete. Delayed reendothelialization as a trigger mechanism of late stent thrombosis after antineoplastic therapy has been hypothesized previously.¹⁷ Farb et al reported incomplete endothelialization 3 months after placement of β -radioactive stent.¹⁸ Nevertheless, the same group showed no differences regarding endothelial cell growth between radioactive and control stents in another experimental model.¹⁹ Further studies should address the timing of stent reendothelialization after brachytherapy to determine its role on the pathogenesis of late thrombosis.

Although multiple stents have been related to subacute thrombosis,²⁰ the significance of multiple stent implantation (patient 1) on late thrombotic phenomena has not been demonstrated.

The use of intracoronary β -radiation is a common feature in our patients. However, the judgment of whether radiation is the key factor in the pathogenesis of late thrombosis should await the analysis of ongoing trials. Concomitantly, the benefit of prolonged antiplatelet therapy with the combination of aspirin, clopidogrel, or ticlopidine should be considered.

Limitations

Our patients were included in well-controlled β -radiation studies with similar baseline characteristics and inclusion criteria (lesion length <15 mm, treatment of single vessel). However, 2 different systems to deliver β -radiation were used.

In addition, it is not possible to rule out the natural history of coronary disease as a cause of late thrombosis. However, the incidence of total occlusion in the general nonirradiated population is much lower than that observed in our study. In fact, the incidence of late thrombotic events would be even higher if, in the interest of completeness, we waited for 1-year follow-up in the total patient population.

Finally, whether late thrombosis is a generic complication of intracoronary radiotherapy or is restricted to the use of β -sources cannot be extrapolated from our findings.

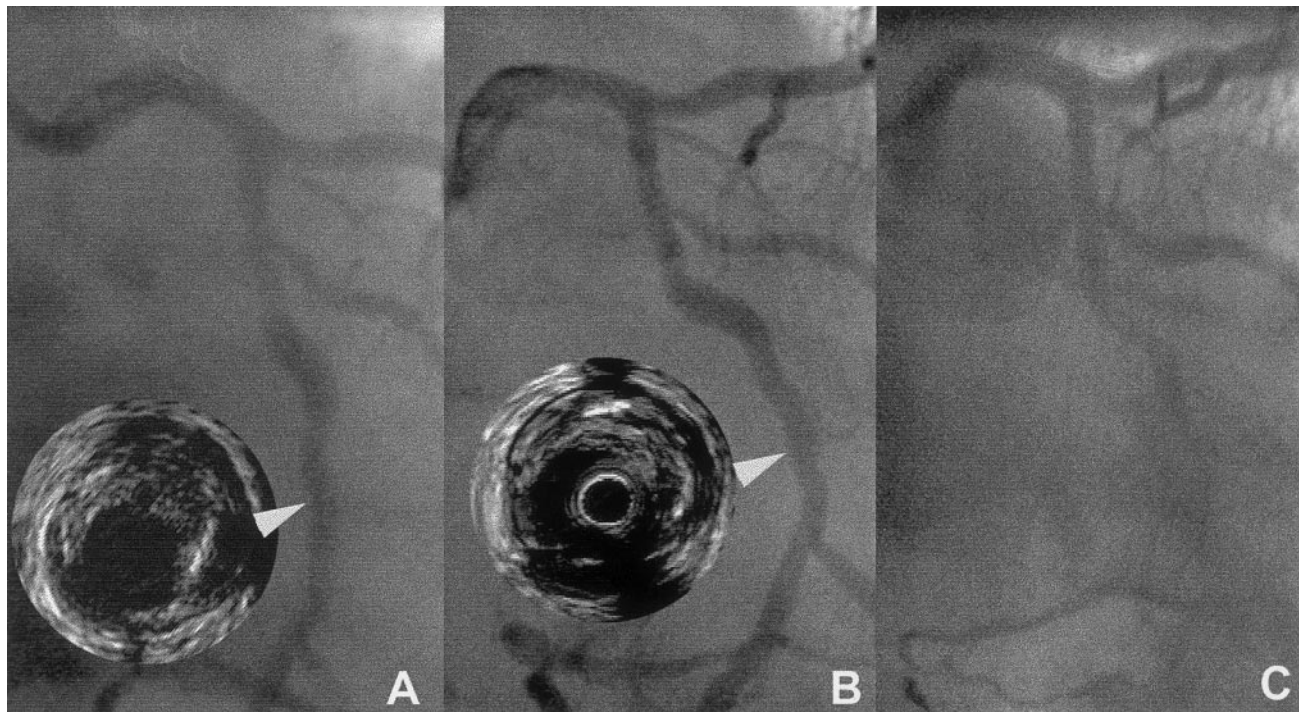


Figure 2. Patient 3. A, Postprocedure coronary dissection, demonstrated both on angiography and IVUS, did not compromise flow in treated area (arrowhead). B, This dissection persisted unhealed at 6-month control (arrowhead). C, At 15 months, irradiated segment appeared occluded.

References

- De Feyter PJ, de Jaegere PP, Serruys PW. Incidence, predictors, and management of acute coronary occlusion after coronary angioplasty. *Am Heart J*. 1994;127:643–651.
- Colombo A, Hall P, Nakamura S, Almagor Y, Maiello L, Martini G, Gaglione A, Goldberg SL, Tobis JM. Intracoronary stenting without anticoagulation accomplished with intravascular ultrasound guidance. *Circulation*. 1995;91:1676–1688.
- Wilson SH, Rihal CS, Bell MR, Velianou JL, Holmes DR Jr, Berger PB. Timing of coronary stent thrombosis in patients treated with ticlopidine and aspirin. *Am J Cardiol*. 1999;83:1006–1011.
- Teirstein PS, Massullo V, Shirish J, Popma JJ, Mintz GS, Russo RJ, Schatz RA, Guarnieri EM, Steuterman S, Morris NB, Leon MB, Tripuranemi P. Catheter-based radiotherapy to inhibit restenosis after coronary stenting. *N Engl J Med*. 1997;336:1697–1703.
- Teirstein PS, Massullo V, Shirish J, Russo RJ, Cloutier DA, Schatz RA, Guarnieri EM, Steuterman S, Sirkin K, Norman S, Tripuranemi P. Two-year follow-up after catheter-based radiotherapy to inhibit coronary restenosis. *Circulation*. 1999;99:243–247.
- Waksman R, White LR, Chan RC, Porrazo MS, Bass BG, Satler LF, Kent KM, Geirlach LM, Mehran R, Murphy MRM, Mintz GS, Leon MB. Intracoronary radiation therapy for patients with in-stent restenosis: 6-month follow-up of a randomized clinical study. *Circulation*. 1998;98(suppl I):I-651. Abstract.
- Condado JA, Saucedo JF, Caldera C, Proctor B, Fadoul M, Waksman R. Two years angiographic evaluation after intracoronary 192 iridium in humans. *Circulation*. 1997;96(suppl I):I-220. Abstract.
- Condado JA, Waksman R, Gurdziel O, Espinosa R, Gonzalez J, Burger B, Villoria G, Acquatella H, Crocker IR, Serung KB, Liprie SF. Long-term angiographic and clinical outcome after percutaneous transluminal coronary angioplasty and intracoronary radiation therapy in humans. *Circulation*. 1997;96:727–732.
- King SB III, Williams DO, Chougule P, Klein L, Waksman R, Hillstead R, Macdonald J, Anderberg K, Crocker IR. Endovascular β -radiation to reduce restenosis after coronary balloon angioplasty: results of the beta energy restenosis trial (BERT). *Circulation*. 1998;97:2025–2030.
- Hillstead RA, Johnson CR, Weldom TD. The Beta Cath® system. In: Waksman R, Serruys PW, eds. *Handbook of Vascular Brachytherapy*. London, UK: Martin Dunitz Ltd.; 1998:41–51.
- Raizner AE, Calfee RV. The Guidant intravascular brachytherapy system. In: Waksman R, Serruys PW, eds. *Handbook of Vascular Brachytherapy*. London, UK: Martin Dunitz Ltd.; 1998:53–58.
- Rozenman Y, Gilon D, Welber S, Sapoznikov D, Wexler D, Lotan C, Mosseri M, Weiss AT, Hasin Y, Gotsman MS. Total coronary artery occlusion late after successful coronary angioplasty of moderately severe lesions: incidence and clinical implications. *Cardiology*. 1994;85:222–228.
- Huber SM, Mooney JF, Madison J, Mooney MR. Use of morphologic classification to predict clinical outcome after dissection from coronary angioplasty. *Am J Cardiol*. 1991;68:467–471.
- Meerkin D, Bonan R, Joyal M, Tardif JC. Intracoronary beta radiation effects on dissection resolution. *J Am Coll Cardiol*. 1999;33(suppl A):48A. Abstract.
- Berger PB, Bell MR, Hasdai D, Grill DE, Melby S, Holmes DR Jr. Safety and efficacy of ticlopidine for only 2 weeks after successful intracoronary stent placement. *Circulation*. 1999;99:248–253.
- van der Giessen WJ, Serruys PW, Beusekom HMM, van Woerkens LJ, van Loon H, Soei LK, Strauss BH, Beatt KJ, Verdouw PD. Coronary stenting with a new, radiopaque, balloon-expandable endoprosthesis in pigs. *Circulation*. 1991;83:1788–1798.
- Smith SC, Winters KJ, Lasala JM. Stent thrombosis in a patient receiving chemotherapy. *Cathet Cardiovasc Diagn*. 1997;40:383–386.
- Farb A, Tang A, Virmani R. The neointima is reduced but endothelialization is incomplete 3 months after 32P B-emitting stent placement. *Circulation*. 1998;98(suppl I):I-779. Abstract.
- Laird JR, Carter AJ, Hufs WM, Hoopes TG, Farb A, Nott SH, Fischell RE, Fischell DR, Virmani R, Fischell TA. Inhibition of neointimal proliferation with low-dose irradiation from a β -particle-emitting stent. *Circulation*. 1996;93:529–536.
- Marco J, Fajadet J, Doucet S, Bar O, Jordan C, Carvalho H, Robert G, Cassagneau B. Palmaz-Schatz coronary stenting: predictors of subacute thrombosis and restenosis in a single center series. *Interv Cardiol Monitor*. 1994;1:5–13.