

## **Reinsertion of an inverted osteochondral lesion of the talus; a case report**

T. Schepers MD PhD, P.P. De Rooij MD, E.M.M. Van Lieshout PhD, P. Patka MD PhD

Erasmus MC, University Medical Center Rotterdam, Rotterdam, the Netherlands

Department of Surgery-Traumatology

### Corresponding author:

T. Schepers, MD PhD

Erasmus MC, University Medical Center Rotterdam

Department of Surgery-Traumatology

Room H-822k

P.O. Box 2040

3000 CA Rotterdam

The Netherlands

Tel: +31-10-7031050

Fax: +31-10-7032396

E-mail: [t.schepers@erasmusmc.nl](mailto:t.schepers@erasmusmc.nl)

## **Abstract**

Osteochondral lesions of the talus (OLT's) occur infrequently and are missed at initial presentation in up to 67% of cases. Probably over 1500 cases of OLT's are described in the literature, of which thus far only five cases of an inverted anterolateral OLT. An anterolateral OLT results from a hyper-supination trauma, in which the talar dome is caught behind the fibula. Apparently, if the forces are large enough a 'flip of the coin' phenomenon occurs, causing the fragment to invert 180 degrees upside down. We present a case of a young female patient with an inverted OLT, treated with open reduction and internal fixation using bio-absorbable pins. Control radiographs and computed tomography showed a congruent joint and complete healing of the osteochondral fragment. At the short-term follow-up the functional outcome has been promising.

## **Keywords**

Osteochondral lesion; talus;surgical; reinsertion

## **Introduction**

Osteochondral lesions of the talus (OLT's) occur infrequently and are missed at initial presentation in up to 67% of cases (1). One of the earliest descriptions of an osteochondral lesion was by Monro in 1737; he described removal of a loose body from the ankle, which was believed to be of traumatic origin (2-3). The term osteochondritis dissecans was first introduced by Franz Konig in 1888, who hypothesized a vascular origin of avascular bone fragments that he found in the knee joint (2-3). Since then, several authors published on osteochondral lesions of the talus, of which Kappis (1922) described a loose fragment that originated from the talus and Rendu (1932) was the first to report a traumatic articular lesion of the talar dome (2-3). The etiology of chronic osteochondral lesions is still debated,

because a significant percentage of patients with osteochondral lesions (OCL's) report no initial trauma (3-7). However, in a review by Flick and Gould on more than 500 patients with OLT's, 98 percent of lateral dome lesions and 70 percent of medial dome lesions were associated with a history of acute trauma (8). The incidence of traumatic osteochondral lesions of the talus has been reported in up to 50% of patients sustaining ankle distortions or fractures (3,9-11)

The controversy on the treatment of OLT's is reflected in the numerous treatment modalities (3-6) and is especially true for the Berndt-Harty grade I to III injuries. For the displaced grade IV injuries surgical management is generally preferred. A special presentation of a grade Berndt-Harty grade IV osteochondral lesion of the talus is the 'inverted osteochondral fragment'. This type of lesion typically occurs on the anterolateral part of the talus and is of traumatic origin. Probably over 1500 cases of OLT's are described in the literature, of which thus far only 5 cases of an inverted anterolateral OLTs. We present a case of a patient with an inverted OLT, treated by open reduction and internal fixation with bio-absorbable pins.

## Case report

A Caucasian female aged 20 years sustained a supination injury of the right ankle during a soccer match. She instantly lost the ability to bear weight on the affected foot. At the Emergency Department a swollen ankle was seen, with pain at the distal fibula. Conventional radiographs were obtained in two orthogonal directions (Figure 1). In these radiographs a loose fragment was visible, which was initially thought to originate from the distal tibia or plafond. The following day she was seen at the outpatient department at which time a CT-scan was obtained for a suspected osteochondral lesion of the talus.

The CT-scan with reconstruction in three planes showed a large osteochondral fragment of 7 by 10 mm, which was 180 degrees inverted (Figure 2). Nine days after the initial trauma the patient was operated on using an anterolateral approach (Figure 3). The anterior talofibular ligament (ATFL) appeared torn. The inverted fragment was located and debrided. The original location at the talar dome was prepared with small drill holes. Hereafter the fragment was reinserted and fixated using two divergent 1.3 mm PDS Orthosorp<sup>®</sup> pins. Upon reconstruction of the ATFL and closure of the wound a non-weight bearing lower leg cast was applied for six weeks, followed by six weeks of non-weight bearing full range of motion exercises. Fifteen weeks after surgery a control CT-scan was performed for assessing consolidation (Figure 4). A fully congruent talar dome was seen, with adequate bony healing at the previous fracture-site. At this time the patient was fully weight bearing without complaints of pain, no loss of flexion and extension at the ankle, and minimal swelling. The patient had returned to work fully and was eager to resume playing soccer.

## Discussion

In the case presented, an inverted osteochondral lesion was successfully reinserted using absorbable pins. The anterolateral OLT results from a hyper-supination trauma, in which the talar dome is caught behind the fibula. Apparently, if the forces are large enough a 'flip of the coin' phenomenon occurs, causing the fragment to invert 180 degrees upside down.

The oldest description of an inverted osteochondral lesion of the talus can be found in the study by Canale et al. from 1980 (12). In a series of 31 OLT's one patient, who was suspect for having a Berndt-Harty -3 injury, appeared to have an inverted OLT. Unfortunately the type of OLT and the treatment provided were not described (12).

One year later, Kenny reported a case of a sixteen year old white female, with an anterolateral two-part OLT, of which one was inverted (13). This injury occurred during an inversion trauma at a soccer match. The fragment was treated by removal and curettage.

Verzin et al. presented a seventeen year old female with an anterolateral inverted OLT and ruptured anterior talo-fibular and calcaneo-fibular ligaments, after slipping in the snow (14). The fragment and base were debrided and the fragment was put back in place without fixation.

In 2007, Chandran et al. presented the case of a 26 year old male patient who injured his ankle after a fall from height, with an anterolateral OLT which appeared to be inverted during arthrotomy of the ankle (15). The fragment was placed back and fixated with three absorbable pins. An excellent result was obtained at one year follow-up.

The fifth case in the literature is described by Wade et al. A twenty-two year old male patient suffered from an inversion trauma during ice hockey eight weeks prior to presentation (16). An anterolateral OLT was identified at the conventional radiographs, however, notion of the fragment being inverted were made during ankle arthroscopy. The fragment was removed and the base debrided.

In the two cases in which the OLT fragment was put back in place, the fragment healed without signs of avascular necrosis (14-15). The duration of follow-up in these cases was 12 (15) and 24 (14) months, without signs of secondary collapse, which has been reported even after bony union upon reinsertion in chronic cases (17). The case presented in the current study has a similar age (*i.e.*, 26 years) as the previously reported cases. Moreover, the trauma mechanism (*i.e.*, supination injury) was identical; the OLT was situated on the anterolateral portion of the talar dome in all cases (12-16).

Numerous modalities have been described for the treatment osteochondral lesions of the talus. This includes non-operative treatment (*e.g.*, non-weight-bearing with cast immobilization, protected weight-bearing, bracing, physiotherapy, and non-steroidal anti-inflammatory drugs) and open or arthroscopic surgical management (*e.g.*, excision and debridement, several forms of marrow stimulation, osteochondral autografts and allografts, and chondrocyte implantation) (3,18). The CT scan in this case showed the classic triad as described by Kenny: inversion of the subchondral plate, reversal of subchondral-cancellous bone layers, and the presence of a radiolucent gap beneath the fragment, making this type of lesion unfit for conservative management (13). Reinsertion of osteochondral lesions, as performed in the current case, has mainly been performed in the femoral condyle (19). Considering reinsertion of osteochondral lesions in the talus only a few small series are available. Alexander et al reinserted four out of twenty-five surgically treated OLT's without further fixation, which were successful in all four cases (20). Pettine et al. reattached five of the thirty operatively treated OLT's (fixation with K-wires in three and with bone pegs in two) obtaining success in two, however the type of lesion and delay in surgery were not clear from this study (21).

In a larger series of 27 patients with mainly Berndt-Harty type 2 and 3 OLT's, fragments were reinserted and fixated using bone pegs and fibrin glue (17), following the technique of Johnson et al (22). Successful reinsertion was achieved in fragments of at least 3mm

thickness and outcome was good in almost 90 percent. Early operation (within 1 year) showed better results than delayed operative treatment (20-21).

In conclusion, the reinsertion of the acute traumatic osteochondral lesion of the talus with PDS bio-absorbable pins is a valuable asset in the treatment of OLT's, especially in the inverted anterolateral lesions, and good to excellent result can be obtained at short term follow-up.

## References

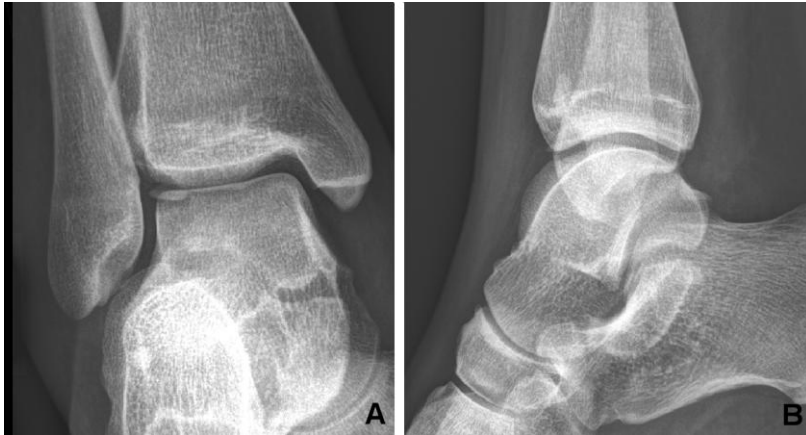1. Schepers T, van Schie-van der Weert EM, de Vries MR, van der Elst M. Foot and ankle fractures at the supination line. *Foot (Edinb)*, 2010.
2. O'Farrell TA, Costello BG. Osteochondritis dissecans of the talus. The late results of surgical treatment. *J Bone Joint Surg Br* 64:494-497, 1982.
3. O'Loughlin PF, Heyworth BE, Kennedy JG. Current concepts in the diagnosis and treatment of osteochondral lesions of the ankle. *Am J Sports Med* 38:392-404, 2010.
4. Chew KT, Tay E, Wong YS. Osteochondral lesions of the talus. *Ann Acad Med Singapore* 37:63-68, 2008.
5. McGahan PJ, Pinney SJ. Current concept review: osteochondral lesions of the talus. *Foot Ankle Int* 31:90-101, 2010.
6. Zengerink M, Szerb I, Hangody L, Dopirak RM, Ferkel RD, van Dijk CN. Current concepts: treatment of osteochondral ankle defects. *Foot Ankle Clin* 11:331-359, vi, 2006.
7. Roden S, Tillegard P, Unanderscharin L. Osteochondritis dissecans and similar lesions of the talus: report of fifty-five cases with special reference to etiology and treatment. *Acta Orthop Scand* 23:51-66, 1953.
8. Flick AB, Gould N. Osteochondritis dissecans of the talus (transchondral fractures of the talus): review of the literature and new surgical approach for medial dome lesions. *Foot Ankle* 5:165-185, 1985.
9. Boraiah S, Paul O, Parker RJ, Miller AN, Hentel KD, Lorich DG. Osteochondral lesions of talus associated with ankle fractures. *Foot Ankle Int* 30:481-485, 2009.
10. Aktas S, Kocaoglu B, Gereli A, Nalbantodlu U, Guven O. Incidence of chondral lesions of talar dome in ankle fracture types. *Foot Ankle Int* 29:287-292, 2008.
11. Sorrento DL, Mlodzienski A. Incidence of lateral talar dome lesions in SER IV ankle fractures. *J Foot Ankle Surg* 39:354-358, 2000.
12. Canale ST, Belding RH. Osteochondral lesions of the talus. *J Bone Joint Surg Am* 62:97-102, 1980.



13. Kenny CH. Inverted osteochondral fracture of the talus diagnosed by tomography. A case report. *J Bone Joint Surg Am* 63:1020-1022, 1981.
14. Verzin EJ, Henderson SA. Inverted osteochondral fracture of the talus with rupture of the lateral ankle ligaments. *Foot Ankle Surg* 10:207-211, 2004.
15. Chandran P, Kamath RP, Nihal A. Osteochondral fracture of talus treated with bio absorbable pins. *The Foot* 18:56-58, 2008.
16. Wade AM, Bustillo J. Unusual orientation of talar osteochondral fragment: a case report. *Foot Ankle Surg* 16:e96-99, 2010.
17. Kumai T, Takakura Y, Kitada C, Tanaka Y, Hayashi K. Fixation of osteochondral lesions of the talus using cortical bone pegs. *J Bone Joint Surg Br* 84:369-374, 2002.
18. Zengerink M, Struijs PA, Tol JL, van Dijk CN. Treatment of osteochondral lesions of the talus: a systematic review. *Knee Surg Sports Traumatol Arthrosc* 18:238-246, 2010.
19. Wouters DB, Burgerhof JG, de Hosson JT, Bos RR. Fixation of osteochondral fragments in the human knee using Meniscus Arrows. *Knee Surg Sports Traumatol Arthrosc* 19:183-188, 2011.
20. Alexander AH, Lichtman DM. Surgical treatment of transchondral talar-dome fractures (osteochondritis dissecans). Long-term follow-up. *J Bone Joint Surg Am* 62:646-652, 1980.
21. Pettine KA, Morrey BF. Osteochondral fractures of the talus. A long-term follow-up. *J Bone Joint Surg Br* 69:89-92, 1987.
22. Johnson EW, Jr., McLeod TL. Osteochondral fragments of the distal end of the femur fixed with bone pegs: report of two cases. *J Bone Joint Surg Am* 59:677-679, 1977.

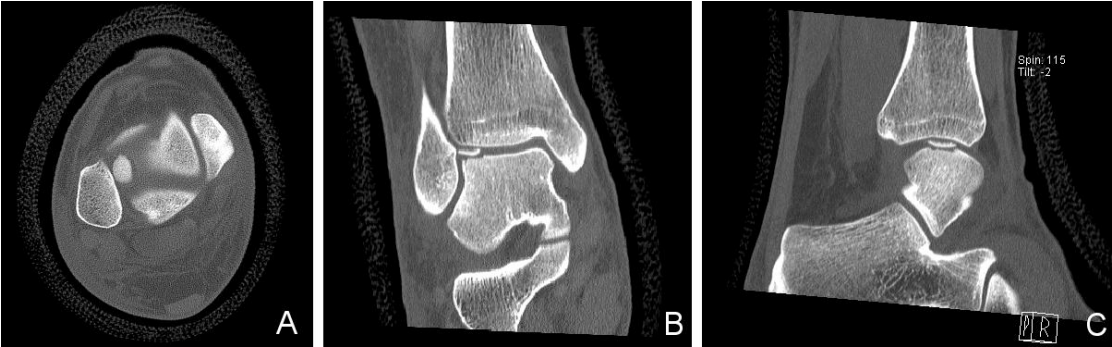## Figures

**Figure 1.** Initial conventional radiographs showing a wafer shaped osteochondral lesion at the anterolateral portion of the talar dome



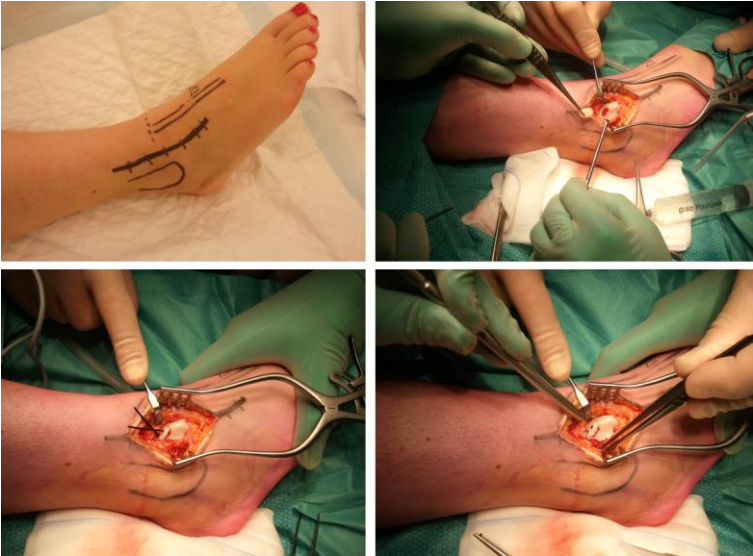
Anteroposterior (A) and lateral (B) radiographic views of the ankle showing a loose fragment anterolaterally.

**Figure 2.** CT-scan of inverted osteochondral lesion of the talus



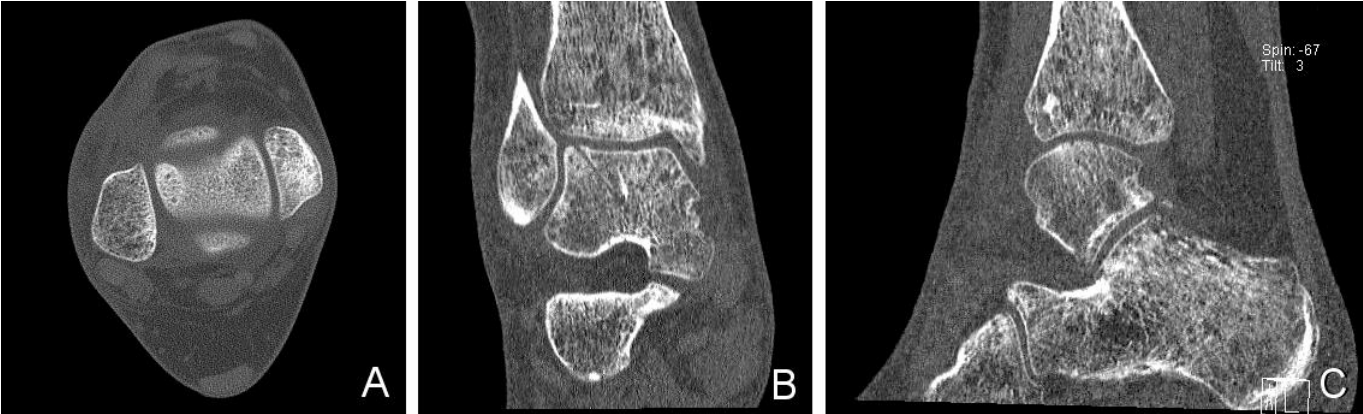
Axial (A), coronal (B) and sagittal (C) reconstructions of the computed tomography scan clearly showing the inverted fragment.

**Figure 3.** Peroperative images of reinsertion of osteochondral lesion



Peroperative images of anterolateral approach (A) identification of fragment and debridement of base (B), fixation with two absorbable rods (C), and end situation prior to closure (D).

**Figure 4.** Control CT-scan at follow-up



Axial (A), coronal (B) and sagittal (C) reconstructions of the computed tomography scan showing complete healing of the OLT and residual holes of absorbable rods.