

# Circulation

JOURNAL OF THE AMERICAN HEART ASSOCIATION



## Long-Term Follow-Up of Incomplete Stent Apposition in Patients Who Received Sirolimus-Eluting Stent for De Novo Coronary Lesions: An Intravascular Ultrasound Analysis

Muzaffer Degertekin, Patrick W. Serruys, Kengo Tanabe, Chi Hang Lee, J. Edouardo Sousa, Antonio Colombo, Marie-Claude Morice, Jurgen M.R. Ligthart and Pim J. de Feyter

*Circulation* 2003;108:2747-2750; originally published online Nov 24, 2003;

DOI: 10.1161/01.CIR.0000103666.25660.77

Circulation is published by the American Heart Association, 7272 Greenville Avenue, Dallas, TX 75214

Copyright © 2003 American Heart Association. All rights reserved. Print ISSN: 0009-7322. Online ISSN: 1524-4539

The online version of this article, along with updated information and services, is located on the World Wide Web at:

<http://circ.ahajournals.org/cgi/content/full/108/22/2747>

Subscriptions: Information about subscribing to *Circulation* is online at <http://circ.ahajournals.org/subscriptions/>

Permissions: Permissions & Rights Desk, Lippincott Williams & Wilkins, 351 West Camden Street, Baltimore, MD 21202-2436. Phone 410-5280-4050. Fax: 410-528-8550. Email: [journalpermissions@lww.com](mailto:journalpermissions@lww.com)

Reprints: Information about reprints can be found online at <http://www.lww.com/static/html/reprints.html>

# Long-Term Follow-Up of Incomplete Stent Apposition in Patients Who Received Sirolimus-Eluting Stent for De Novo Coronary Lesions

## An Intravascular Ultrasound Analysis

Muzaffer Degertekin, MD; Patrick W. Serruys, MD, PhD; Kengo Tanabe, MD; Chi Hang Lee, MBBS; J. Edouardo Sousa, MD, PhD; Antonio Colombo, MD; Marie-Claude Morice, MD; Jurgen M.R. Ligthart, BSc; Pim J. de Feyter, MD, PhD

**Background**—Incomplete stent apposition (ISA) has been previously documented after sirolimus-eluting stent (SES) implantation. The aim of this study was to investigate the long-term intravascular ultrasound (IVUS) findings of ISA in patients who received SES.

**Methods and Results**—A total of 13 patients who received SES and showed ISA at follow-up IVUS (follow-up I) were investigated. IVUS was performed on all of these patients 12 months later (follow-up II). Quantitative ISA area measurement was also performed at follow-up I and II. No vascular remodeling was observed in the vessel segment with ISA; external elastic membrane area was  $19.4 \pm 6.6$  versus  $19.5 \pm 6.4$  mm<sup>2</sup> at follow-up I and II, respectively. There was also no significant change in external elastic membrane area between vessel segment with ISA and without ISA (+1.5% versus -3.0%, respectively;  $P=0.27$ ) at late follow-up. The ISA area, either including ( $2.5 \pm 1.7$  versus  $3.8 \pm 6.3$  mm<sup>2</sup>;  $P=NS$ ) or excluding ( $2.5 \pm 1.8$  versus  $2.4 \pm 1.7$  mm<sup>2</sup>;  $P=NS$ ) a single patient with aneurysm formation, was not significantly different between follow-up I and II. One patient manifested a coronary aneurysm in the stented segment at late follow-up that was probably present at the initial follow-up but masked by thrombus. It was successfully treated with a covered stent. All patients were asymptomatic, and no patient experienced late thrombotic occlusion.

**Conclusions**—Vessel dimensions and area of ISA did not change over time, except for 1 coronary aneurysm that became apparent. ISA after implantation of a SES was not associated with adverse events at late follow-up. (*Circulation*. 2003; 108:2747-2750.)

**Key Words:** stents ■ vessels ■ coronary disease

The RAVEL (RAnimized study with the sirolimus-eluting Bx-VELOCITY stent) trial recently demonstrated that sirolimus-eluting stent (SES) effectively inhibits neointimal hyperplasia (NIH) without showing edge narrowing, thrombotic occlusion, or persistence of dissection.<sup>1,2</sup> However, incomplete stent apposition (ISA) was observed during follow-up intravascular ultrasound (IVUS) in patients who received SES.<sup>2</sup>

ISA has been shown to occur after brachytherapy as well as in patients who receive bare metal stents (BS).<sup>3,4</sup> Clinical outcomes of patients who developed ISA remain controversial. Furthermore, there are no data on serial IVUS evaluation of ISA in the long-term follow-up. Because drug-eluting stents (DES) may potentially become a routine therapy in interventional cardiology, information on the long-term effects of ISA with DES are eagerly awaited. The aim of our

study was to investigate the long-term quantitative IVUS findings of ISA in patients who received SES.

## Methods

### Patient Population

In the RAVEL<sup>1</sup> and First-in-Man<sup>5</sup> trials, 168 patients received SES for single de novo coronary lesions and a subset of 91 patients underwent IVUS investigation at follow-up. In this report, a total of 13 patients who showed ISA at 6 or 12 months follow-up (follow-up I) were included, and quantitative IVUS was performed on all of these patients 12 months later (follow-up II).

### Evaluation of ISA, Quantitative IVUS, and Coronary Angiography Analysis

IVUS was performed with automated pullback at 0.5 mm/s. All IVUS procedures were recorded on VHS videotapes. ISA was defined as 1 or more stent struts clearly separated from the vessel wall with evidence of blood speckles behind the strut without

Received January 10, 2003; de novo received September 21, 2003; accepted October 9, 2003.

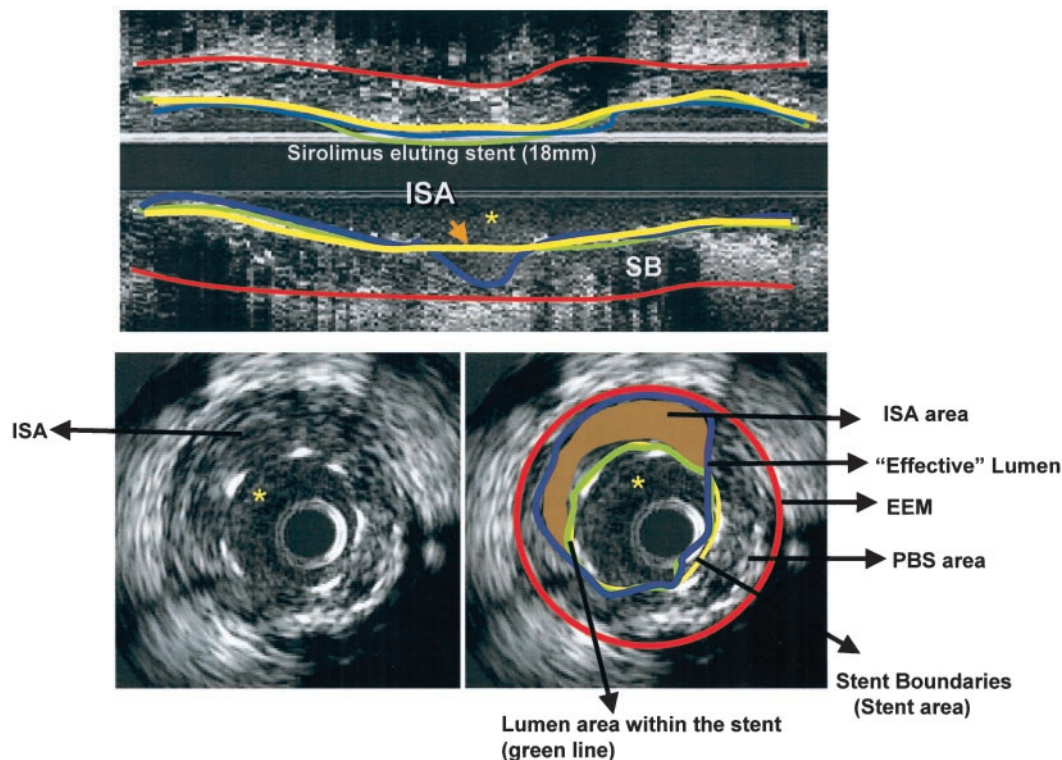
From Erasmus MC, Thoraxcenter, Rotterdam, the Netherlands; Institute Dante Pazzanese Cardiology (J.E.S.), Sao Paulo, Brazil; Centro Cuore Columbus (A.C.), Milan, Italy; and Institut Cardiovasculaire Paris Sud (M.-C.M.), Massy, France.

Correspondence to Professor P.W. Serruys, MD, PhD, Erasmus MC, Thoraxcenter, Bd. 408 Dr. Molewaterplein 40, 3015 GD Rotterdam, The Netherlands. E-mail p.w.j.c.serruys@erasmusmc.nl

© 2003 American Heart Association, Inc.

*Circulation* is available at <http://www.circulationaha.org>

DOI: 10.1161/01.CIR.0000103666.25660.77



**Figure 1.** Longitudinal IVUS image of a patient who has a segment with ISA. Cross-sectional views correspond to the section (\*) of the longitudinal view showing the red, yellow, blue, and green lines that indicate the of external elastic membrane contour, the stent contour, effective lumen area contour, and intrastent lumen area contour, respectively. PBS indicates plaque behind the stent.

overlapping side branches.<sup>2</sup> As previously reported, the maximum number of struts separated from the vessel wall, maximal depth, and angle of the ISA were documented.<sup>2</sup> The length of ISA site was measured from single or multiple longitudinal views. When the patient had >1 ISA sites separated from each other by completely well-apposed stented segment, the total length of ISA was defined as the sum of the lengths of each ISA segment.

In the segment with ISA, the lumen contours were delineated within and outside the stent strut boundaries (stent area [SA]) (Figure 1). The quantitative coronary ultrasound analysis software (Curad BV, Wijk Bij) was modified to calculate the fraction of the lumen area that lies outside of the stent, eg, ISA area.<sup>6</sup> ISA is thus conceptually considered part of an effective lumen. Therefore, 2 types of lumen area are reported: the intrastent lumen area (SA minus intrastent neointimal hyperplasia area) and the effective lumen area (sum of ISA area and intrastent lumen area). In addition, in the segment with ISA, external elastic membrane area (EEMA) and plaque behind stent area (EEMA minus SA minus ISA area) were measured (Figure 1).

Coronary artery aneurysm (CAA) was defined as a maximum lumen area >50% larger than the proximal reference lumen area, which is a cross section of normal appearance within 5 mm proximal to the stent.<sup>7</sup> Quantitative coronary angiography was performed by independent core laboratory, as previously described.<sup>1,5</sup>

### Statistical Analysis

Quantitative data are presented as mean $\pm$ 1 SD and compared using paired Student's *t* test. Treatment group differences were tested by ANOVA of Wilcoxon rank-sums scores. Consecutive quantitative coronary angiography measurements were analyzed by general linear modeling with repeated measures, considering various times as factors. A value of  $P<0.05$  was considered statistically significant.

### Results

Of 13 patients, 8 were men (age, 58.4 $\pm$ 11.6 years). Cardiac risk factor included hypercholesterolemia in 4 and hyperten-

sion in 5. No patient had diabetes. All patients were asymptomatic, and none experienced late thrombotic occlusion or in-stent restenosis 1 year after the diagnosis of ISA. Coronary angiography demonstrated persistent minimal late loss at late follow-up (Table 1).

Table 2 shows serial IVUS measurements of stented segments with ISA. There was no significant difference in either EEMA or plaque behind stent area between follow-up I and II. NIH remained minimal at late follow-up. There was also no significant change in EEMA between vessel segment with ISA and without ISA (+1.5% versus -3.0%, respectively;  $P=0.27$ ) at late follow-up.

Figure 2A illustrates individual data on ISA volume at the 2 time points. At follow-up I, 22 ISA sites were found; 1 of 13 patients (4.5%) had 3 and 7 of 13 patients (31.8%) had 2 separate ISA sites. At follow-up II, the patient who had 3 ISA sites had developed an aneurysm covering the previous 2 ISA sites; apart from this patient, no new ISA sites were observed. Indeed, 4 ISA sites had resolved at follow-up II.

**TABLE 1. Serial Quantitative Coronary Angiography**

Parameters (n=13)	Post	Follow-Up I	Follow-Up II
Reference diameter, mm	2.98 $\pm$ 0.48	3.00 $\pm$ 0.46	2.93 $\pm$ 0.49
Minimum lumen diameter, mm	2.72 $\pm$ 0.46	2.64 $\pm$ 0.53	2.46 $\pm$ 0.61
Diameter stenosis, %	8.9 $\pm$ 6.7	11.9 $\pm$ 10.5	16.0 $\pm$ 14.6
In-stent late lumen loss, mm	...	0.07 $\pm$ 0.29	0.26 $\pm$ 0.46*

Data are presented as No. relative percentages or mean $\pm$ SD.

\* $P=0.04$ , follow-up I vs follow-up II.

**TABLE 2. Serial Quantitative Intravascular Ultrasound Analysis of Vessel Segment Showing Incomplete Stent Apposition (n=12)\***

	Follow-Up I	Follow-Up II	P
Length of the ISA segment, mm	5.1±3.5	4.8±2.6	0.36
External elastic membrane area, mm <sup>2</sup>	19.4±6.6	19.5±6.4	0.86
Maximal depth of the ISA segment, mm	0.8±0.3	0.9±0.4	0.63
Maximal circumferential extent of the ISA, arc	138±66	144±66	0.83
Maximal No. of struts separated from vessel wall on 1 single cross section	3.3±0.8	3.25±1.4	0.79
Mean ISA area, mm <sup>2</sup>	2.5±1.8	2.4±1.7	0.60
Plaque behind stent area, mm <sup>2</sup>	9.02±4.2	9.2±3.9	0.95
Stent area (strut boundaries), mm <sup>2</sup>	7.95±2.40	8.15±2.31	0.57
Intrastent (NIHA), mm <sup>2</sup>	0.02±0.01	0.05±0.04	0.047
Intrastent lumen area (stent area minus NIHA), mm <sup>2</sup>	7.92±2.39	8.09±2.33	0.42
Effective lumen area, mm <sup>2</sup> (Lumen area within the stent plus ISA area)	10.4±3.6	10.3±3.4	0.88

Values are mean±SD. NIHA indicates neointimal hyperplasia area.

\*Patient who showed coronary aneurysm is not included because of lack of external elastic membrane measurement.

The ISA area, either including (2.5±1.7 versus 3.8±6.3 mm<sup>2</sup>; P=NS) or excluding (2.5±1. versus 2.4±1.7 mm<sup>2</sup>; P=NS) a single patient with aneurysm formation, was not significantly different between follow-up I and II. In this patient with aneurysm, the border of external elastic membrane could not be delineated on 6-month IVUS. However, serial IVUS examinations suggesting dissolution of thrombotic material in a pre-existing aneurysm (Figure 2B). This aneurysmal sac with a depth of 5.9 mm was successfully treated by implanting a covered stent.

**Discussion**

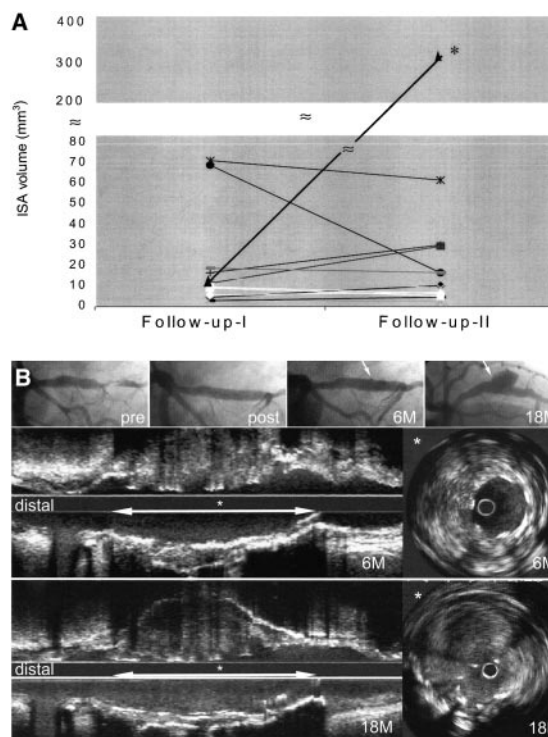
The main findings of our analysis are as follows: (1) ISA after implantation of a SES is not associated with adverse clinical events 1 year after the diagnosis; (2) the vessel segment surrounding the incompletely apposed stent does not show positive vascular remodeling over time; (3) ISA area does not significantly change at late follow-up; and (4) inhibition of in-stent NIH persists during long-term follow-up.

ISA after implantation of SES has been a major concern since it was first described.<sup>2</sup> The present study demonstrated that clinical course of ISA observed after SES implantation was benign; none of the patients with ISA experienced stent thrombosis or myocardial infarction. The absence of events, even in the presence of ISA, is also consistent with the observation that endothelialization after implantation of SES and BS is similar and that SES is less thrombogenic than BS.<sup>8</sup>

The underlying mechanism for ISA remains largely unknown. Several hypotheses have been postulated, including plaque regression, regional positive vascular remodeling, late dissolution of thrombotic material trapped behind the stent, cell necrosis, apoptosis, and allergic reaction to sirolimus.<sup>4,9-11</sup>

Any dilatation of the vessel lumen raises concern about progressive dilatation over time, aneurysm formation, and ultimately the potential of rupture, as is seen with aortic aneurysms. We observed 1 case of CAA in the SES-stented

segment 1 year after the diagnosis of ISA. Although there was no IVUS image from the index procedure, the angiograms after the index procedure and at 6-month follow-up were similar (Figure 2). Therefore, we suspected that there was a



**Figure 2.** A, Volume changes of incomplete stent apposition (per patient) between 2 time intervals. \*Patient who showed coronary aneurysm. B, Serial coronary angiography shows small pouching (arrow) at 6-month follow-up (6M). At 18-month follow-up (18M), coronary aneurysm exists at the same locality of pouching. In the IVUS (bottom), at 6M, homogeneous, low-echogenic solid mass suggests thrombus behind the stent struts. At 18M IVUS, this mass is dissolved with blood flow at the same (\*) area, consistent with aneurysm formation, suggesting dissolution of thrombotic material.



preexisting CAA filled with thrombus at the time of the index procedure and that this thrombotic material had been resolved at 18 months. Based on the fact that elution of sirolimus from the stent struts continues for only 6 weeks, with a half-life of sirolimus in the tissue of 60 hours (R. Falotico, personal communication, 2002), sirolimus itself is unlikely to induce structural vessel wall changes in the longer term. Nevertheless, it remains difficult to rule out formation of CAA after SES implantation. It is worth noting that CAA is well known after BS implantation, balloon angioplasty, and coronary atherectomy.<sup>12,13</sup>

Excluding the aneurysm case, the vessel segment related to the incompletely apposed stent did not significantly alter in size (+1.5% change in EEMA) at late follow-up, and mean ISA area also did not significantly change. Moreover, negligible amount of NIH at late follow-up showed that the efficacy of SES in inhibiting neointimal tissue migration and proliferation was not affected by the presence of ISA. Therefore, because ISA per se was not associated with any additional adverse events, we suggest that there is no need for late mechanical correction of these cases of ISA.

### Conclusions

ISA after implantation of a SES was not associated with adverse events 1 year after the diagnosis. ISA area and vessel dimensions in the segments including ISA did not change over time.

### References

1. Morice MC, Serruys PW, Sousa JE, et al. A randomized comparison of a sirolimus-eluting stent with a standard stent for coronary revascularization. *N Engl J Med*. 2002;346:1773–1780.
2. Serruys PW, Degertekin M, Tanabe K, et al. Intravascular ultrasound findings in the multicenter, randomized, double-blind RAVEL (Randomized study with the sirolimus-eluting VELOCITY balloon-expandable stent in the treatment of patients with de novo native coronary artery Lesions) trial. *Circulation*. 2002;106:798–803.
3. Kozuma K, Costa MA, Sabate M, et al. Late stent malapposition occurring after intracoronary beta-irradiation detected by intravascular ultrasound. *J Invasive Cardiol*. 1999;11:651–655.
4. Shah VM, Mintz GS, Apple S, et al. Background incidence of late malapposition after bare-metal stent implantation. *Circulation*. 2002;106:1753–1755.
5. Sousa JE, Costa MA, Abizaid AC, et al. Sustained suppression of neointimal proliferation by sirolimus-eluting stents: one-year angiographic and intravascular ultrasound follow-up. *Circulation*. 2001;104:2007–2011.
6. Hamers R, Bruining N, Knook M, et al. A novel approach to quantitative analysis of intravascular ultrasound images. *Comput Cardiol*. 2001;28:589–592.
7. Maehara A, Mintz GS, Ahmed JM, et al. An intravascular ultrasound classification of angiographic coronary artery aneurysms. *Am J Cardiol*. 2001;88:365–370.
8. Suzuki T, Kopia G, Hayashi S, et al. Stent-based delivery of sirolimus reduces neointimal formation in a porcine coronary model. *Circulation*. 2001;104:1188–1193.
9. Hardinger KL, Cornelius LA, Trulock EP 3rd, et al. Sirolimus-induced leukocytoclastic vasculitis. *Transplantation*. 2002;74:739–743.
10. Roque M, Cordon-Cardo C, Fuster V, et al. Modulation of apoptosis, proliferation, and p27 expression in a porcine coronary angioplasty model. *Atherosclerosis*. 2000;153:315–322.
11. Mintz GS, Shah VM, Weissman NJ. Regional remodeling as the cause of late stent malapposition. *Circulation*. 2003;107:2660–2663.
12. Slota PA, Fischman DL, Savage MP, et al. Frequency and outcome of development of coronary artery aneurysm after intracoronary stent placement and angioplasty: STRESS Trial Investigators. *Am J Cardiol*. 1997;79:1104–1106.
13. Bell MGK, Bresnahan JF, Edwards WD, et al. Relation of deep arterial resection and coronary artery aneurysms after directional coronary atherectomy. *J Am Coll Cardiol*. 1992;20:1474–1481.