

# Angiographic Predictors of Recurrence of Restenosis After Wiktor Stent Implantation in Native Coronary Arteries

Peter De Jaegere, MD, Patrick W. Serruys, MD, Michel Bertrand, MD, Volker Wiegand, MD, Jean François Marquis, MD, Matthias Vrolicx, MD, Jan Piessens, MD, Bernard Valeix, MD, Gisbert Kober, MD, Hans Bonnier, MD, Wolfgang Rutsch, MD, and Rainer Uebis, MD

**Intracoronary stenting has been proposed as an adjunct to balloon angioplasty to improve the immediate and long-term results. However, late luminal narrowing has been reported following the implantation of a variety of stents. One of the studies conducted with the Wiktor stent is a prospective registry designed to evaluate the feasibility, safety and efficacy of elective stent implantation in patients with documented restenosis of a native coronary artery. To identify angiographic variables predicting recurrence of restenosis, the angiograms of the first 91 patients with successful stent implantation and without clinical evidence of (sub)acute thrombotic stent occlusion were analyzed with the Computer Assisted Angiographic Analysis System using automated edge detection. The incidence of restenosis was 44% by patient and 45% by stent according to the 0.72 mm criterion, and 30% by patient and 29% by stent according to the 50% diameter stenosis criterion. The risk for restenosis for several angiographic variables was determined using an univariate analysis and is expressed as odds ratio with corresponding confidence interval. The only statistically significant predictor of restenosis was the relative gain when it exceeded 0.48 using the 0.72 mm criterion (odds ratio 2.7, 95% confidence interval 1.1–6.4). Furthermore, the relation between the relative gain (increase in minimal luminal diameter normalized to vessel size) as angiographic index of vessel wall injury and relative loss (decrease in minimal luminal diameter normalized to vessel size) as index of neointimal**

**thickening was analyzed using a linear regression analysis. A Pearson product-moment correlation coefficient of 0.38 ( $p < 0.001$ ) was found. When using the categorical approach to address restenosis, there is an increased risk for recurrent restenosis when the relative gain exceeds 0.48. The continuous approach underscores this concept by indicating a weak but positive relation between the relative gain and relative loss.**

(*Am J Cardiol* 1993;72:165–170)

**P**ercutaneous transluminal coronary balloon angioplasty is now widely accepted as a safe and effective treatment in selected patients with obstructive coronary artery disease.<sup>1</sup> However, acute vessel closure and late restenosis are inherent to balloon angioplasty and continue to compromise its efficacy.<sup>2,3</sup> Although the exact pathophysiologic mechanism(s) and factors responsible for restenosis are largely unknown, some clinical and angiographic variables have been identified as potential risk factors.<sup>4</sup> There is, furthermore, some evidence that repeat angioplasty of a previously dilated lesion in a native coronary artery is associated with a higher incidence of restenosis.<sup>5–9</sup> The Wiktor stent has been used to treat such patients. The incidence of recurrence of restenosis following Wiktor stent implantation in the first 50 consecutive patients has recently been published.<sup>10</sup> The purpose of this study was to try to identify angiographic predictors of recurrence of restenosis after Wiktor stent implantation. This may not only have important clinical consequences, but may also broaden our understanding of the pathophysiology of restenosis.

## METHODS

**Patients:** Between January 1990 and May 1992, Wiktor stent implantation was attempted in 193 patients because of recurrence of angina due to restenosis of a native coronary artery lesion after previous balloon angioplasty. The study population consisted of 91 of the 109 consecutive patients with successful stent implantation without clinical evidence of thrombotic stent occlusion during hospital stay and in whom the scheduled follow-up angiography was completed at  $5.7 \pm 1.9$  months (mean  $\pm$  SD) (Figure 1).

Eighty-one patients were men (89%); the mean age ( $\pm$  SD) was  $58 \pm 11$  years. A first restenosis was documented in 50 patients (55%), a second in 32 patients

From the Catheterization Laboratory and Laboratory for Quantitative Angiographic Analysis (Cardialysis), Thoraxcenter, Rotterdam, the Netherlands; Department of Cardiology, Hôpital Cardiologique, Lille, France; Department of Cardiology, Georg August Universität Göttingen, Germany; Department of Cardiology, University of Ottawa Heart Institute, Ottawa, Ontario, Canada; Department of Cardiology, University Hospital Gasthuisberg, Leuven, Belgium; Department of Cardiology, Clinique la Casamance, Marseille, France; Department of Cardiology, Klinikum der J.W. Goethe Universität Frankfurt, Germany; Department of Cardiology, Catharina Hospital, Eindhoven, the Netherlands; Department of Cardiology, University Hospital Berlin, Germany; Department of Cardiology, Medical Clinic I RWTH Aachen, Germany. Manuscript received October 14, 1992; revised manuscript received and accepted February 22, 1993.

Address for reprints: Patrick W. Serruys, MD, Catheterization Laboratory and Laboratory for Quantitative Angiographic Analysis (Cardialysis), Thoraxcenter, Erasmus University, P.O. Box 1738, 3000 DR Rotterdam, the Netherlands.

**TABLE I** Findings at Quantitative Angiography After Wiktor Stent Implantation (n = 91 patients)

	Before PTCA	After PTCA	After Stent Implantation	At Follow-Up
Reference diameter (mm)	2.85 ± 0.49	2.80 ± 0.48	3.02 ± 0.42	2.98 ± 0.47
Minimal luminal diameter (mm)	1.13 ± 0.36	1.77 ± 0.36	2.45 ± 0.34	1.73 ± 0.67
Diameter stenosis (%)	60 ± 10	35 ± 11	19 ± 7	42 ± 21

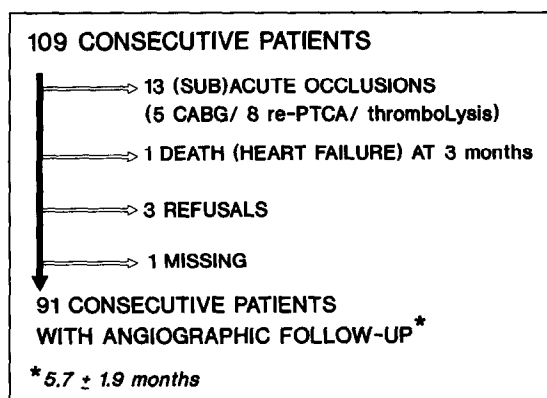
All parameters are expressed as mean ± SD. All changes were highly significant ( $p < 0.00001$ ) except for the reference diameter; only the difference in reference diameter after stent implantation and after percutaneous transluminal coronary angioplasty was statistically significant ( $p < 0.001$ ). PTCA = percutaneous transluminal coronary angioplasty.

(35%), a third in 8 patients (9%) and a fourth in one other patient (1%). In all patients, a single Wiktor stent was implanted except in one, in whom a single stent was implanted in both the left anterior descending and the right coronary artery. The target vessel was the left anterior descending artery in 48 patients (52%), the right coronary artery in 31 patients (34%), and the left circumflex in 12 patients (13%). In another patient (1%), a single Wiktor stent was implanted in the left main stem. The size of the stent used was  $3.4 \pm 0.4$  mm (mean ± SD): a 3.0 mm device in 38 patients (41%), a 3.5 mm device in 40 patients (44%) and a 4.0 mm device in 14 patients (15%). The stent is described in detail elsewhere as well as the associated drug protocol.<sup>11</sup>

**Angiographic variables and definition of restenosis:** Based on the quantitative angiographic data, multiple variables were identified and recorded for each lesion. These variables were of a priori clinical interest on the basis of previously published reports on balloon angioplasty and intracoronary stenting and of a more fundamental scientific interest based on experimental studies on stent implantation in animals.<sup>4,12-16</sup> The following continuous variables were selected: obstruction diameter before and immediately after stent implantation, baseline reference diameter and diameter stenosis, length of target lesion, plaque area and the relative gain defined by the increase in minimal luminal diameter immediately after stent implantation normalized to the

vessel size. In addition to these continuous variables, one discrete variable (left anterior descending artery) was selected. All coronary angiograms were analyzed with the computer-assisted Cardiovascular Angiography Analysis System. Its principles and definitions of angiographic variables has been described in a previous study on Wiktor stent implantation.<sup>11</sup> Since the primary objective of this study was to identify angiographic variables predicting restenosis, the process of restenosis was dichotomized and defined according to the 0.72 mm and 50% diameter stenosis criteria.<sup>17</sup>

**Statistics:** A relative risk analysis was performed for the aforementioned angiographic variables. To avoid an arbitrary subdivision of data in the continuous variables, the median value was chosen as cutoff point. The selection of this value as cutoff point has the advantage of being consistent for all values, and thus avoids any bias in the selection of subgroups that might be undertaken to emphasize a particular point. All values are expressed as mean ± SD. The risk for restenosis for each parameter according to the 0.72 mm and 50% diameter stenosis criteria was determined by using an univariate analysis and is expressed as odds ratio with corresponding 95% confidence interval. An odds ratio of 1.0 for a particular variable implies that the presence of that variable poses no additional risk for restenosis, an odds ratio >1.0 or <1.0 implies additional or reduction in risk. Furthermore, since experimental animal data indicate that there is a relation between the severity of vessel wall injury and the extent of subsequent neointimal thickening, the relation between relative gain (as index of vessel wall injury) and relative loss (as index of neointimal thickening) was studied using a regression analysis. The relative gain is previously defined. The relative loss is the difference between the minimal luminal diameter immediately after stent implantation and at follow-up normalized to the vessel size.



**FIGURE 1.** Flow diagram showing angiographic follow-up in the first 109 consecutive patients. In-hospital acute or sub-acute occlusion occurred in 13 patients (12%). Of the remaining 96 patients who were discharged without clinical evidence of (sub)acute occlusion, 91 underwent repeat angiography at  $5.7 \pm 1.9$  (mean ± SD) months after stent implantation. CABG = coronary artery bypass grafting; re-PTCA = repeat percutaneous transluminal coronary angioplasty.

## RESULTS

**Incidence of restenosis:** The changes in stenosis geometry are summarized in Table I. The incidence of restenosis was 44% (40 of 91 patients) according to the 0.72 mm criterion and 30% (27 of 91 patients) according to the 50% diameter stenosis criterion. When the stent is used as a unit, the incidence of restenosis was 45% (41 of the 92 stents) and 29% (27 of the 92 stents), respectively (Figure 2).

**Angiographic predictors:** The relative risk and 95% confidence intervals for each variable using either of the

Angiographic Variable		Restenosis Criteria	
		0.72 mm	50% Diameter
		Criterion	Stenosis Criterion
Relative gain (mm)	≥ 0.48	2.7 (1.1–6.4)	1.1 (0.4–2.7)
Minimal luminal diameter after (mm)	≥ 2.38	1.8 (0.8–4.2)	0.5 (0.2–1.4)
Minimal luminal diameter before (mm)	≤ 1.08	1.6 (0.7–3.7)	2.7 (1.0–7.2)
Lesion length (mm)	≥ 6.48	1.4 (0.6–3.2)	1.8 (0.7–4.6)
Reference diameter before (mm)	≤ 2.77	1.3 (0.6–2.9)	1.4 (0.5–3.4)
Plaque area (mm <sup>2</sup> )	≥ 7.47	1.3 (0.6–2.9)	1.1 (0.4–2.7)
Diameter stenosis before (%)	≥ 61	1.0 (0.4–2.3)	1.3 (0.5–3.2)
Left anterior descending artery		0.7 (0.3–1.7)	1.1 (0.5–2.8)

2 criteria are listed in Table II. The only statistically significant predictor of recurrence of restenosis according to the 0.72 mm criterion was the relative gain when it exceeded 0.48 (odds ratio 2.7, 95% confidence interval 1.1–6.4). Related to the relative gain is the obstruction diameter before and after stent implantation. Although their odds ratio exceeds 1.0, their corresponding 95% confidence interval precludes any firm conclusion. The same holds for lesion length, reference diameter and plaque area. The left anterior descending artery was not identified as a risk factor for recurrence of restenosis. When using the 50% diameter stenosis criterion, no angiographic predictor of restenosis was evident.

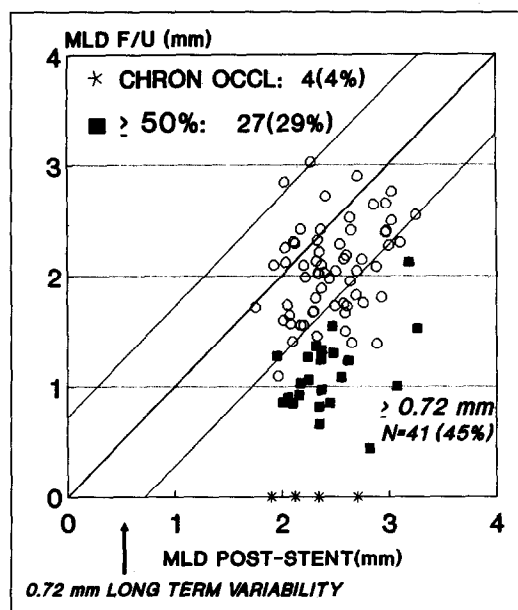
The number of balloon angioplasties performed before stent implantation did not influence the risk for sub-

sequent restenosis after stenting. The odds for restenosis in case of stent implantation for a second, third or fourth restenosis compared with stent implantation for a first restenosis was 0.8 (95% confidence interval 0.4–1.8) according to the 0.72 mm criterion and was 1.5 (95% confidence 0.6–3.7) according to the 50% diameter stenosis criterion.

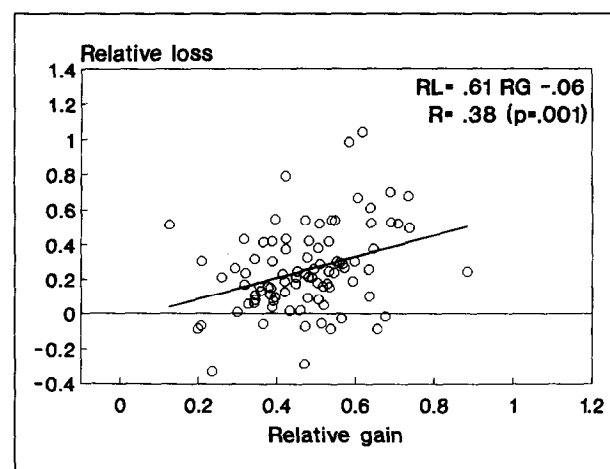
**Regression analysis:** The relation between relative gain, as index of vessel wall injury, and relative loss, as index of late neointimal hyperplasia as vessel wall response to injury, is shown in Figure 3. A Pearson product-moment correlation coefficient of 0.38 was found ( $p < 0.001$ , slope 0.61, intercept  $-0.06$ ).

## DISCUSSION

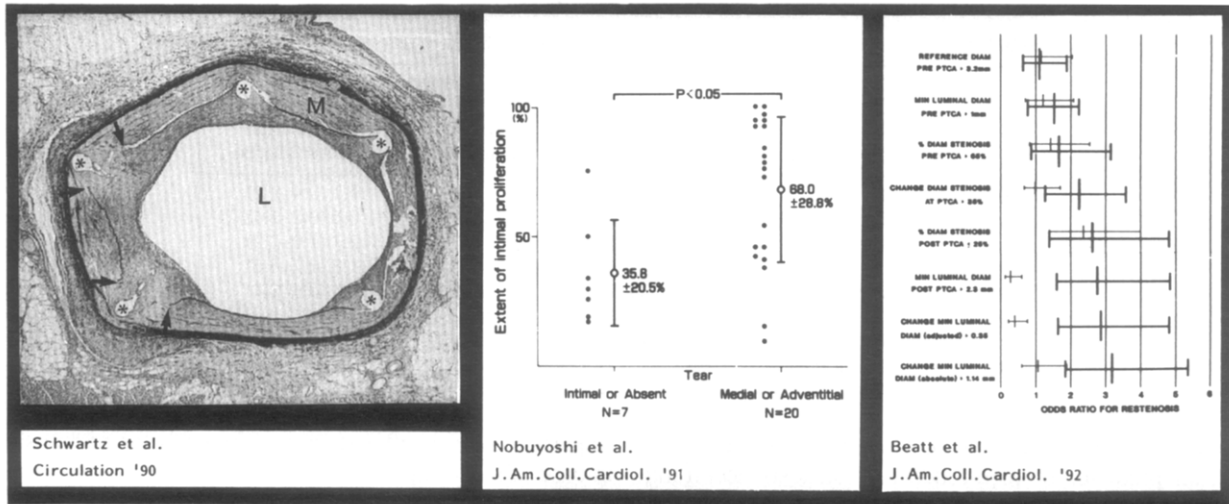
The primary objective of this study was not the determination of the incidence of recurrent restenosis after Wiktor stent implantation in patients with restenosis after previous balloon angioplasty. However, it is noteworthy that the incidence of poststent restenosis reported here in the 91 patients is identical to the incidence of recurrent restenosis in the first 50 consecutive patients.<sup>10</sup> Detailed analysis of a subgroup of 74 patients revealed that there was no late compression of the stent itself.



**FIGURE 2.** Changes in the minimal luminal diameter (MLD) at follow-up (F/U) after Wiktor stent implantation. The diameter of each segment immediately after stent implantation is plotted against the diameter at follow-up. The lines on each side of the line of identity (diagonal) represent twice the variability (95% confidence interval) of duplicate measurements (a change of  $\geq 0.72$  mm). A significant decrease in minimal luminal diameter according to the 0.72 mm criterion was found in 41 of the 92 stents implanted (45%). The incidence of restenosis according to the 50% diameter stenosis criterion was 29% (27 of the 92 stents). Of these, 4 stents were completely occluded at follow-up, as shown on the x axis. CHRON OCCL = chronic occlusion.



**FIGURE 3.** Graphic display of the relation between the relative gain (RG = increase in minimal luminal diameter immediately after stent implantation normalized to the vessel wall) and relative loss (RL = decrease in minimal luminal diameter at follow-up normalized to the vessel wall). A positive linear relation was found with a correlation coefficient (R) of 0.38 ( $p < 0.001$ ) with a slope of 0.61 and an intercept on the y axis of  $-0.06$ .



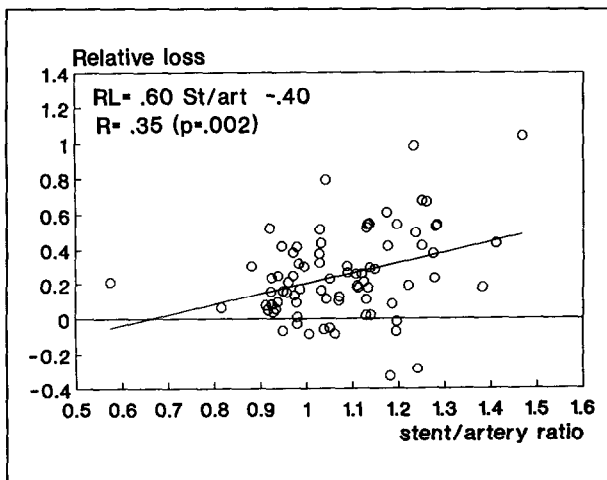
**FIGURE 4.** Experimental animal data, postmortem pathologic observations in humans and angiographic studies independently from each other indicate a proportional relationship between the degree of vessel wall injury and the extent of late neointimal thickening. *Left panel*, coil stent implantation in domestic pigs results in a more extensive smooth muscle cell proliferation in case of rupture of the internal elastic lamina and consequent medial injury (reproduced with permission from Schwarz et al<sup>14</sup>); *middle panel*, pathologic observations in humans indicate that deep arterial injury is associated with more extensive intimal proliferation (reproduced with permission from Nobuyoshi et al<sup>15</sup>); *right panel*, an angiographic study assessing the immediate and long-term changes in stenosis geometry after balloon angioplasty, showing that restenosis defined as  $\geq 0.72$  mm decrease in minimal (MIN) luminal diameter (DIAM) (bold line) was found to be significantly correlated with both a larger increase in minimal luminal diameter and larger absolute dimension after percutaneous transluminal coronary angioplasty (PTCA) (reproduced with permission from Beatt et al<sup>16</sup>). L = vessel lumen; M = media.

Therefore, late loss or restenosis was due to ingrowth of tissue into the lumen of the stented segment.<sup>18</sup>

The lack of randomized studies precludes any conclusion as to whether stent implantation in this subset of patients will reduce the incidence of subsequent restenosis. Moreover, the exact incidence of recurrent restenosis after repeat balloon angioplasty is not known. There is some evidence that it increases with the number of repeat angioplasties. A second restenosis has been reported to occur in 25 and 34%, but amounts to 39 and 40% after a third or fourth angioplasty, respectively.<sup>5-9</sup> These data should be interpreted with caution considering the difference between the study populations, the dif-

ference in definition of restenosis, and in the time and completeness of follow-up angiography. In the present study in which stents were implanted because of restenosis, the risk for recurrent restenosis after stenting did not differ between patients with a first restenosis and patients with a second, third or fourth restenosis. Two other studies failed to show a statistically significant difference in the restenosis rate for primary or de novo lesions compared with lesions that had undergone previous balloon angioplasty.<sup>12,13</sup> However, subgroup analysis of patients in whom a single Palmaz-Schatz stent was implanted showed a restenosis rate of 13% compared with 36% for patients with previous restenosis.<sup>13</sup>

The development of restenosis remains incompletely understood. Histologic data have shown that any injury to the vessel wall, whatever its nature, will invariably be associated with neointimal hyperplasia as a nonspecific tissue response leading to restenosis when excessive.<sup>14,19-23</sup> It is of both scientific and utmost clinical importance to know and understand its development and to know the factors controlling the extent of the vessel wall response following injury. Experimental animal studies, postmortem pathologic observations in humans and angiographic studies have shown that the extent of neointimal hyperplasia is proportional to the degree of injury applied to the vessel wall (Figure 4).<sup>14-16,24</sup> This is in accord with earlier work in the porcine model, describing a relation between the degree of injury and early platelet deposition.<sup>25,26</sup> In the present study, the relative gain was used as angiographic correlate of vessel wall injury. This parameter was found to be the only statistically significant predictor of recurrence of restenosis when using the 0.72 mm criterion. The drawback of the latter is, first, that the process of restenosis is dichotomized (present/not present) and second, that although



**FIGURE 5.** Graphic display of the relation between the stent/artery (St/art) ratio (x axis) and relative loss (RL) (y axis). A positive linear relation was found with a correlation coefficient (R) of 0.35 ( $p < 0.002$ ) with a slope of 0.60 and an intercept of -0.40.

statistically justifiable, cutoff points are used for the angiographic variables under investigation. However, the continuous approach underscores these findings by indicating a positive linear relation between the relative gain and relative loss. These observations were still valid when using absolute measurements. However, the correlation between the absolute gain and absolute loss was somewhat weaker ( $r = 0.21$ ,  $p = 0.05$ ). This is explained by the fact that the use of absolute values does not relate these changes to the vessel size. Although we found no difference in absolute loss between small and large vessels, an identical loss in minimal luminal diameter represents a larger relative loss in a small vessel than in a large vessel, and vice versa. This confirms other studies using a categorical approach to define restenosis after stenting, that small vessels are not, per se, more prone to restenosis than large vessels.<sup>12,13,27</sup>

This concept, describing a proportional relation between vessel wall injury and neointimal thickening, has been reported in other studies using quantitative coronary angiography. Beatt et al<sup>16</sup> found that restenosis (0.72 mm criterion) was significantly correlated with both a greater improvement in obstruction diameter and a larger absolute dimension after balloon angioplasty. Furthermore, in a recent study,<sup>28</sup> the absolute change in minimal luminal diameter was reported to be the greatest single determinant of late luminal narrowing after balloon angioplasty. In another report,<sup>29</sup> it was found that interventions achieving a "bigger" lumen provoke a concomitantly larger relative loss, so that the ultimate end point of various treatment methods is similar.

All these findings carry potential far-reaching clinical implications. Clearly, the greater the improvement in minimal luminal diameter achieved by intervention, the greater the magnitude of subsequent luminal narrowing will be. Unfortunately, what cannot be extrapolated from the data is how much damage the clinician may inflict on the vessel wall. On the one hand, a suboptimal angiographic result is associated with a higher risk of subacute occlusion due to rheologic factors and platelet deposition and a higher need for repeat balloon angioplasty but, on the other hand, improvement of the initial result may be at the price of more extensive late neointimal thickening.<sup>14-16,30,31</sup> This indistinctness can be circumvented by properly matching the balloon size or device with the vessel wall using on-line quantitative coronary angiography. This is underscored by the data displayed in Figure 5 indicating that the more the stent is oversized, the greater the loss in minimal luminal diameter will be.

So far, there are 2 other angiographic studies that have attempted to identify risk factors for restenosis or recurrence of restenosis, and they found, as in the present study, that the vessel size and severity of stenosis, expressed as diameter stenosis and length of the lesion, not to be associated with an increased risk for restenosis.<sup>12,13</sup> As mentioned, the indication (primary or secondary stenting) was not associated with an increased risk for restenosis.<sup>12,13</sup> In accordance with these 2 studies on stenting and 1 other study on balloon angioplasty, the target vessel was not associated with an increased risk for (recurrent) restenosis.<sup>12,13,32</sup>

**Study limitations:** The study limitations are essentially twofold. First, the precision of relative gain as an angiographic index of vessel wall injury and relative loss as an index of neointimal hyperplasia has not been studied. The coronary angiogram is a 2-dimensional echocardiogram describing the changes in stenosis geometry but not the nature or extent of the pathology explaining these angiographic changes. Therefore, the measurement of the minimal luminal diameter, and consequently the relative gain and loss, are subject to potential imprecision. Second, the effect of other clinical, procedural and lesion-related characteristics on the development of late neointimal hyperplasia has not been considered. It is conceivable that if these characteristics play a role in the pathogenesis of neointimal thickening, they may not be uniformly distributed over the study population.

**Acknowledgment:** We thank Marie-Angèle Morel for performing the quantitative analysis and for her assistance in the database management and statistical analysis.

1. Detre K, Holubkov R, Kelsey S, Bourassa M, Williams D, Holmes D, Dorros G, Faxon D, Myler R, Kent K, Cowley M, Cannon R, Robertson T, and the coinvestigators of the National Heart, Lung, and Blood Institute's Percutaneous Transluminal Coronary Angioplasty Registry. One-year follow-up results of the 1985-1986 National Heart, Lung, and Blood Institute's PTCA Registry. *Circulation* 1989;80:421-428.
2. de Feyter PJ, de Jaegere PPT, Murphy ES, Serruys PW. Abrupt coronary artery occlusion during percutaneous transluminal coronary angioplasty. *Am Heart J* 1992;123:1633-1642.
3. Serruys PW, Luijten HE, Beat KJ, Geuskeens R, de Feyter PJ, van den Brand M, Reiber JHC, ten Katen HJ, van Es GA, Hugenholtz PG. Incidence of restenosis after successful coronary angioplasty: a time-related phenomenon. *Circulation* 1988;77:361-371.
4. Bourassa M, Lesperance J, Eastwood C, Schwartz L, Cote G, Kazim F, Hudon G. Clinical, physiologic, anatomic and procedural factors predictive of restenosis after percutaneous transluminal coronary angioplasty. *J Am Coll Cardiol* 1991;18:368-376.
5. Williams DO, Gruentzig AR, Kent KM, Detre KM, Kelsey S, To T. Efficacy of repeat percutaneous transluminal coronary angioplasty for coronary restenosis. *Am J Cardiol* 1984;53:32C-35C.
6. Meier B, King SB III, Gruentzig AR, Douglas JS, Hollman J, Ischinger T, Galan K, Tankersley R. Repeat coronary angioplasty. *J Am Coll Cardiol* 1984;4:463-466.
7. Black AJ, Anderson VH, Roubin GS, Powelson SW, Douglas JS, King SB III. Repeat coronary angioplasty: correlates of a second restenosis. *J Am Coll Cardiol* 1988;11:714-718.
8. Teirstein PS, Hoover CA, Ligon RW, Giorgi LV, Rutherford BD, McConahay DR, Johnson WL, Hartzler GO. Repeat coronary angioplasty: efficacy of a third angioplasty for a second restenosis. *J Am Coll Cardiol* 1989;13:291-296.
9. Quigley PJ, Hlatky MA, Hinohara T, Rendall DS, Perez JA, Phillips HR, Califf RM, Stack RS. Repeat percutaneous transluminal coronary angioplasty and predictors of recurrent restenosis. *Am J Cardiol* 1989;63:409-413.
10. de Jaegere P, Serruys PW, Bertrand M, Wiegand V, Kober G, Marquis JF, Valeix B, Uebis R, Piessens J. Wiktor stent implantation in patients with restenosis following balloon angioplasty of a native coronary artery. *Am J Cardiol* 1992;69:598-602.
11. Serruys PW, de Jaegere P, Bertrand M, Kober G, Marquis JF, Piessens J, Uebis R, Valeix B, Wiegand V. Morphologic change in coronary artery stenosis with the medtronic Wiktor stent. Initial results from the core laboratory for quantitative angiography. *Cathet Cardiovasc Diagn* 1991;14:237-245.
12. Strauss BH, Serruys PW, de Scheerder IK, Tijssen JG, Bertrand ME, Puel J, Meier B, Kaufmann U, Stauffer JC, Rickards AF, Sigwart U. Relative risk analysis of angiographic predictors of restenosis within the coronary wallstent. *Circulation* 1991;84:1636-1643.
13. Fischman DL, Savage MP, Ellis SG, Schatz RA, Leon MB, Bain D, Goldberg S. Restenosis after Palmaz-Schatz Stent implantation. In: Serruys PW, Strauss BH, King SB III, eds. Restenosis After Intervention with New Mechanical Devices. Boston: Kluwer Academic Publishers, 1992:191-205.
14. Schwartz RS, Murphy JG, Edwards WD, Camrud AR, Vlietstra RE, Holmes DR. Restenosis after balloon angioplasty. A practical proliferative model in porcine coronary arteries. *Circulation* 1990;82:2190-2200.
15. Nobuyoshi M, Kimura T, Ohishi H, Horiuchi H, Nosaka H, Hamasaki N, Yokoi H, Kim K. Restenosis after percutaneous transluminal coronary angioplasty: patho-

logic observations in 20 patients. *J Am Coll Cardiol* 1991;17:433-439.

- 16.** Beatt KJ, Serruys PW, Luijten HE, Rensing BJ, Suryapranata H, de Feyter PJ, van den Brand M, Laarman GJ, Roelandt J. Restenosis after coronary angioplasty: the paradox of increased lumen diameter and restenosis. *J Am Coll Cardiol* 1992;19:258-266.
- 17.** Reiber JHC, Serruys PW, Kooijman CJ. Assessment of short-, medium-, and long-term variations in arterial dimensions from computer-assisted quantitation of coronary cineangiograms. *Circulation* 1985;71:280-288.
- 18.** de Jaegere P, Bertrand M, Wiegand V, Marquis JF, Vrolicx M, Piessens J, Valeix B, Kober G, Bonnier H, Rutsch W, Uebis R. Recoil following Wiktor stent implantation. Results of the European Registry and of the core lab for quantitative coronary angiography (abstr). *Circulation* 1992;86:1320A.
- 19.** van der Giessen WJ, Serruys PW, van Beusekom HMM, van Woerkens LJ, van Loon H, Loe Kie Soei, Strauss BH, Beatt KJ, Verdouw P. Coronary stenting with a new, radiopaque, balloon-expandable endoprosthesis in pigs. *Circulation* 1991;83:1788-1798.
- 20.** White IW, Ramee SR, Banks AK, Mesa JE, Chokshi S, Isner JM. A new balloon-expandable tantalum coil stent: angiographic patency and histologic findings in an atherogenic swine model. *J Am Coll Cardiol* 1992;19:870-876.
- 21.** Schatz RA, Palmaz C, Tio FO, Garcia F, Garcia O, Reuter SR. Balloon expandable intracoronary stents in the adult dog. *Circulation* 1987;76:450-457.
- 22.** Roubin GS, King SB, Douglas JS, Lembo NJ, Robinson KA. Intracoronary stenting during percutaneous transluminal coronary angioplasty. *Circulation* 1990;81 (suppl IV):IV-2-IV-100.
- 23.** van Beusekom HMM, van der Giessen WJ, van Suylen RJ, Bos E, Bosman FT, Serruys PW. Histology after stenting of human saphenous vein bypass grafts. Observations from surgically excised grafts 3 to 320 days after stent implantation. *J Am Coll Cardiol* 1993;21:45-54.
- 24.** Sarembock IJ, LaVeau PJ, Sigal SL, Timmis I, Sussman J, Haudenschild C, Ezekowitz M. Influence of inflation pressure and balloon size on the development of intimal hyperplasia after balloon angioplasty. A study in the atherosclerotic rabbit. *Circulation* 1989;80:1029-1040.
- 25.** Steele PM, Chesebro JH, Stanson AW, Holmes DR, Dewanjee MK, Bodiman L, Fuster V. Balloon angioplasty: natural history of the pathophysiologic response to injury in a pig model. *Circ Res* 1985;57:105-112.
- 26.** Wilentz JR, Sanborn TA, Haudenschild CC, Valeri CR, Ryan TJ, Faxon DP. Platelet accumulation in experimental angioplasty: time course and relation to vascular injury. *Circulation* 1987;75:636-642.
- 27.** Carrozza J, Schatz R, Kuntz R, Fischman R, Baim D. Variation in restenosis after Palmaz-Schatz stenting are due to differences in post-procedure lumen diameter. *Circulation* 1992;86:2116A.
- 28.** Rensing BJ, Hermans WR, Vos J, Beatt KJ, Bossuyt P, Rutsch W, Serruys PW. On behalf of the Carport Study Group. Angiographic risk factors of luminal narrowing after coronary balloon angioplasty using balloon measurements to reflect stretch and elastic recoil at the dilatation site. *Am J Cardiol* 1992;69:584-591.
- 29.** Foley DP, Serruys PW, Hermans WR, de Jaegere P, Morel MA, Roelandt JRTC. Is "bigger" really "better"? Immediate and long-term outcome following balloon angioplasty, directional atherectomy and stent implantation (abstr). *Eur Heart J* 1992;13:2226(A).
- 30.** Nichols AB, Smith R, Berke A, Shlofmitz RA, Powers ER. Importance of balloon size in coronary angioplasty. *J Am Coll Cardiol* 1989;13:1094-1100.
- 31.** Liu MW, Roubin GS, King SB III. Restenosis after coronary angioplasty. Potential determinants and role of intimal hyperplasia. *Circulation* 1989;79:1374-1387.
- 32.** Hermans WR, Rensing BJ, Kelder JC, de Feyter PJ, Serruys PW. Postangioplasty restenosis rate between segments of the major coronary arteries. *Am J Cardiol* 1992;69:194-200.