

## Surfactant therapy restores gas exchange in lung injury due to paraquat intoxication in rats

K.L. So\*, E. de Buijzer\*, D. Gommers\*, U. Kaisers<sup>†</sup>, P.J.J. van Genderen<sup>‡</sup>, B. Lachmann\*

*Surfactant therapy restores gas exchange in lung injury due to paraquat intoxication in rats. K.L. So, E. de Buijzer, D. Gommers, U. Kaisers, P.J.J. van Genderen, B. Lachmann. ©ERS Journals Ltd 1998.*

**ABSTRACT:** Paraquat is a weed killer which causes often fatal lung damage in humans and other animals. There is evidence that the pulmonary surfactant system is involved in the pathophysiology of respiratory failure after paraquat intoxication and, therefore, the possible therapeutic effect of intratracheal surfactant administration on gas exchange in rats with progressive lung injury induced by paraquat poisoning was studied.

In one group of rats, the time course of the development of lung injury due to paraquat intoxication was characterized. In a second group of rats, 72 h after paraquat intoxication, the animals underwent mechanical ventilation and only those animals in which the arterial oxygen tension/inspiratory oxygen fraction ( $P_{a,O_2}/F_{I,O_2}$ ) decreased to below 20 kPa (150 mmHg) received exogenous surfactant (200 mg·kg<sup>-1</sup> body weight).

Within 3 days the rats in group 1 developed progressive respiratory failure, demonstrated not only by impaired gas exchange and lung mechanics but also by increased minimal surface tension and increased protein concentration in broncho-alveolar lavage fluid.

In group 2, intratracheal surfactant administration increased  $P_{a,O_2}/F_{I,O_2}$  significantly within 5 min (14.4±2.4 kPa (108±18 mmHg)) to (55.2±5.3 kPa (414±40 mmHg)) and sustained this level for at least 2 h.

It is concluded that intratracheal surfactant administration is a promising approach in the treatment of severe respiratory failure caused by paraquat poisoning. *Eur Respir J 1998; 12: 284–287.*

\*Dept of Anesthesiology, Erasmus University Rotterdam, The Netherlands. <sup>†</sup>Dept of Anesthesiology and Intensive Care Medicine, Virchow Clinics, Humboldt University, Berlin, Germany. <sup>‡</sup>Dept of Hematology, University Hospital Dijkzigt, Rotterdam, The Netherlands.

Correspondence: B. Lachmann  
Dept of Anesthesiology (Room Ee 2393)  
Erasmus University Rotterdam  
Postbox 1738  
3000 DR Rotterdam  
The Netherlands  
Fax: 31 10 4367870

Keywords: Acute respiratory distress syndrome, artificial ventilation, oxygen radical, paraquat, pulmonary, surfactant

Received: October 24 1997  
Accepted after revision April 17 1998

Supported financially by the International Foundation for Clinically Oriented Research (IFCOR) and equipment was made available by Siemens Elema AB, Solna, Sweden.

Since 1962, paraquat (1,1'-dimethyl-4,4'-bipyridylum dichloride) has been widely used as a herbicide that is safe during normal use but causes severe, often fatal lung damage following accidental or experimental poisoning in a variety of animals [1] and humans [2], regardless of the route of administration. Paraquat preferentially causes lung toxicity, resembling acute respiratory distress syndrome, ending in either multiple organ failure or progressive lung fibrosis.

Until now, the rationale for treatment has concentrated on preventing progression to pulmonary fibrosis, limiting absorption from the gastrointestinal tract and enhancing elimination from the systemic circulation; however, no putative treatments of paraquat poisoning have proven clinical efficacy and as a consequence, the mortality rate remains high [3]. Thus, alternative treatment rationales have to be examined.

Lung damage following paraquat poisoning appears to be secondary to a derangement of pulmonary surfactant [4–7], probably resulting not only from the selective injury to type 1 and type 2 cells by paraquat itself but also from the increased permeability of alveolar capillaries following injury to endothelial cells by oxygen radicals [8]. The increased permeability of the alveolocapillary membrane for plasma proteins, leaking from the circulation into the alveolar space, leads to a further inhibition of the surfactant function. Finally, this results in a qualitative and

quantitative shortage of pulmonary surfactant at the air-liquid interface, favouring further accumulation of protein-rich oedema fluid into the alveolar space.

The hypothesis was proposed, that if surfactant deficiency contributed to the pathophysiology of respiratory failure in this animal model, then surfactant therapy should improve gas exchange in animals with respiratory failure due to paraquat poisoning. First, in one group of animals the time course of the development of lung injury after paraquat application was characterized by measurement of gas exchange, lung mechanics and surface tension. In a second group of animals, we investigated whether surfactant replacement therapy could improve gas exchange in rats suffering from severe respiratory failure due to experimental paraquat poisoning.

### Materials and methods

This study was approved by the Animal Use and Care Committee of the Erasmus University Rotterdam. Female adult Sprague-Dawley rats (body weight 200–250 g) were used. The animals were cared for in accordance with the guidelines of the United States Department of Agriculture.

The study consisted of two parts. In experiment 1 an animal model was set up and in experiment 2 the rats received surfactant replacement therapy.

### Experiment 1

The rats ( $n=48$ ) were randomly divided into two groups: one group of 12 untreated rats served as controls and the remaining 36 rats were given a subcutaneous injection of a 2% aqueous solution of paraquat (Methyl Viologen; Sigma, London, UK), 35 mg·kg<sup>-1</sup> body weight [9]. The rats receiving paraquat were then divided into three groups of 12 rats, each group to be killed at days 1, 2 and 3. Each day, the rats were used for *in vivo* assessment of respiratory failure and subsequently the rats were divided into two groups of 6 rats each. The first group was used for bronchoalveolar lavage (BAL) analysis, while the second group was used for the measurement of lung mechanics. All animals were housed in standard plastic cages, received standard food *ad libitum* and were weighed at 12 h intervals for 72 h.

**Assessment of severity of respiratory failure.** The animals were anaesthetized with nitrous oxide, oxygen and halothane (65%, 33% and 2%), a tracheotomy was performed, and a catheter was inserted into the carotid artery. The rats were ventilated with a Servo Ventilator 900C (Siemens Elema, Solna, Sweden) at the following ventilator settings: pressure controlled ventilation, inspiratory oxygen fraction ( $F_{I,O_2}$ )=1.0, respiratory frequency ( $f_R$ )=30 breaths·min<sup>-1</sup>, airway pressure ( $P_{aw}$ )=14 cmH<sub>2</sub>O and positive end-expiratory pressure (PEEP)=2 cmH<sub>2</sub>O at an inspiratory/expiratory ratio of 1:2. Anaesthesia was maintained with pentobarbital sodium (60 mg·kg<sup>-1</sup>·h<sup>-1</sup>, *i.p.*) and muscle relaxation with pancuronium bromide (0.5 mg·kg<sup>-1</sup>·h<sup>-1</sup>, *i.m.*). After a 5 min stabilization period, blood samples were taken from the carotid artery and analysed immediately (ABL 505 Radiometer, Copenhagen, Denmark). Subsequently, the  $P_{aw}$  was raised to 26 cmH<sub>2</sub>O and the PEEP was raised to 6 cmH<sub>2</sub>O. Again, arterial blood samples were taken and analysed after a 5 min stabilization period. Finally, the  $P_{aw}$  and PEEP were reduced back to 14 and 2 cmH<sub>2</sub>O. The rats then underwent either bronchoalveolar lavage (BAL) analysis or measurement of lung mechanics.

**Bronchoalveolar lavage.** The rat lungs were lavaged twice with saline (37°C, 30 mL·kg<sup>-1</sup> body weight<sup>-1</sup>) *via* the intratracheal tube. The animals were then killed with an overdose of pentobarbital sodium. The lavage fluid was pooled and immediately placed on ice. Any lavage fluid foam was included in the pooled sample. Within 30 min after the lavage, the lavage fluid was centrifuged at 500×g for 5 min at 4°C to remove the cell pellet. The supernatant was stored at -70°C until analysis.

**Bronchoalveolar lavage analysis.** The BAL supernatant was analysed for surface-active properties and total protein. The surface tension was measured using a modified Wilhelmy balance [10] (E. Biegler, Mauerbach, Austria). Surface activity in BAL fluid was measured by applying 500 µL BAL fluid to the surface of a saline-filled trough (37°C, trough maximally filled, baseline >70 mN·m<sup>-1</sup>) and minimal and maximal surface tensions were recorded after

three cycles (cycle time=3 min). Total protein concentration was determined in each sample by a modification of the Lowry method [11].

**Lung mechanics.** The anaesthetized animals were killed by ventilation with pure nitrogen for 15 min. Subsequently, the thorax was opened and the pressure-volume characteristics of the lungs in the opened chest were determined. Pressure-volume relations were recorded by injecting 0.5 mL increments of air *via* a tracheal cannula up to a maximum pressure of 30 cmH<sub>2</sub>O. Then, 0.5 mL increments of air were withdrawn from the lungs. After each change in volume the pressure was allowed to equilibrate for 15 s. At a pressure of 5 cmH<sub>2</sub>O the trachea was clamped. The pressures were recorded with a pressure transducer (Statham P23XL; Spectramed, Oxnard, CA, USA) connected to a polygraph (Grass Instrument Co., Quincy, MA, USA). From the pressure-volume curve, the stability index (SI) according to GRUENWALD [12] was calculated. The lungs (clamped at a pressure of 5 cmH<sub>2</sub>O to compensate for loss of intrapleural pressure) were then removed from the chest cavity and weighed. Total lung volume was measured by immersion in a liquid-filled graduated cylinder and the displaced volume was determined. From these results and the specific gravity of the lung tissue, the *post mortem* lung volume at end-expiration ( $V_5$ ), which supposedly approximates the functional residual capacity (FRC) [13], can be calculated.

### Experiment 2

**Surfactant therapy.** This experiment was performed 72 h after paraquat intoxication. The anaesthetized rats were prepared in the same way as described above (see *assessment of severity of respiratory failure*). They were then ventilated with a Servo Ventilator 900C (Siemens Elema, Solna, Sweden) at the following ventilator settings: pressure-controlled ventilation,  $F_{I,O_2}$ =1.0,  $f_R$ =30·min<sup>-1</sup>,  $P_{aw}$ =26 cmH<sub>2</sub>O, PEEP=6 cmH<sub>2</sub>O and inspiratory/expiratory ratio=1:2. After a 5 min stabilization period, blood samples were taken from the carotid artery and analysed (ABL 505 Radiometer, Copenhagen, Denmark). The animals were included in the study if, at a ventilation with  $P_{aw}$ =26 cmH<sub>2</sub>O and PEEP = 6 cmH<sub>2</sub>O, the arterial oxygen tension ( $P_{a,O_2}$ ) did not exceed 20 kPa (150 mmHg). The animals were randomly divided into three groups: group A ( $n=11$ ) received an intratracheal bolus of surfactant (200 mg·kg body weight<sup>-1</sup>; 50 mg·mL<sup>-1</sup> saline), group B ( $n=5$ ) received no treatment at all and group C ( $n=4$ ) received a bolus of saline (4 mL·kg<sup>-1</sup> body weight). After treatment the ventilator settings were left unchanged. Arterial blood samples were taken at 5, 30, 60, 90 and 120 min post-treatment. The blood samples were analysed for  $P_{a,O_2}$ , arterial carbon dioxide tension ( $P_{a,CO_2}$ ) and pH (ABL 505 Radiometer, Copenhagen, Denmark).

**Surfactant.** A freeze-dried natural pig surfactant preparation, as described previously [14], was used for the intratracheal surfactant administration. This preparation consists of approximately 90% phospholipids and 1% hydrophobic proteins (surfactant protein (SP)-B and SP-C), the remainder being other lipids (*e.g.* cholesterol, free fatty acids and glyceride). Owing to isolation procedures, there is no SP-A in this preparation. A 50 mg·mL<sup>-1</sup> suspension was pre-

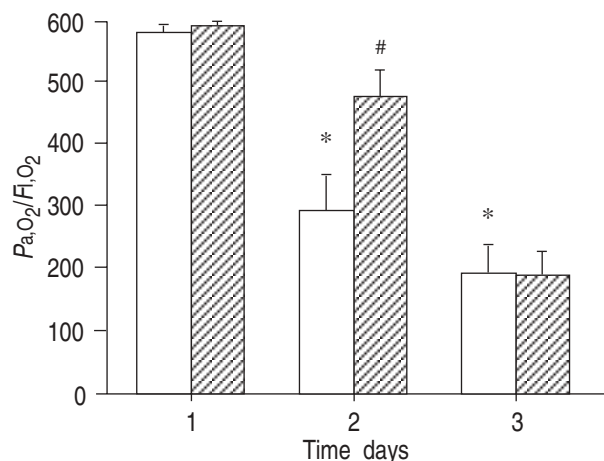


Fig. 1. – Effect of applying different ventilator settings. □: airway pressure ( $P_{aw}$ )=14 cmH<sub>2</sub>O, positive end-expiratory pressure (PEEP)=2 cmH<sub>2</sub>O and inspiratory oxygen fraction ( $F_{I,O_2}$ )=1.0; ▨:  $P_{aw}$ =26 cmH<sub>2</sub>O and PEEP=6 cmH<sub>2</sub>O. On day 1 n=12, on days 2 and 3 n=10.  $P_{a,O_2}$ : arterial oxygen tension. \*:  $p<0.05$  compared with day 1; #:  $p<0.05$  compared with ventilation at  $P_{aw}$ =14 cmH<sub>2</sub>O and PEEP=2 cmH<sub>2</sub>O. Presented as means  $\pm$  SEM.

pared by suspending the preparation in a 0.9% sodium chloride solution.

**Statistical analysis.** All data are expressed as mean  $\pm$  SEM. Standard analysis of variance (ANOVA) procedures were carried out for BAL and lung mechanics parameters. When significant differences between groups occurred, these differences were further analysed with the Bonferroni multiple comparison test. Statistical significance was set at  $p<0.05$ .

## Results

### Experiment 1

Within 24 h after exposure to paraquat the animals showed signs of toxicity, including rapid and shallow breathing. On day 2, two rats died and on day 3 another two rats died. On day 2, blood gas analyses showed signs of respiratory insufficiency with a reduced  $P_{a,O_2}$ . Figure 1 shows  $P_{a,O_2}$  data at different ventilator pressures. On day 1, blood gases were still within the normal range. On day 2, however, the arterial oxygenation was low when ventilated at a  $P_{aw}$ =14 cmH<sub>2</sub>O and PEEP=2 cmH<sub>2</sub>O but increased when ventilator settings were raised to  $P_{aw}$ =26 cmH<sub>2</sub>O and PEEP=6 cmH<sub>2</sub>O. On day 3, ventilator settings of  $P_{aw}$ =26 cmH<sub>2</sub>O and PEEP=6 cmH<sub>2</sub>O did not improve

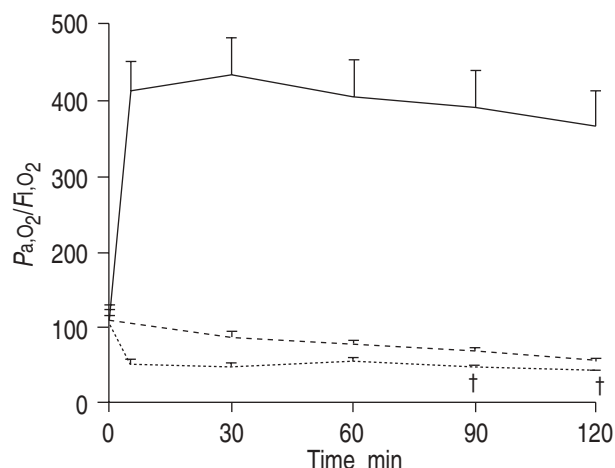


Fig. 2. – Effect of surfactant replacement therapy on arterial oxygen tension ( $P_{a,O_2}$ ), with inspiratory oxygen fraction ( $F_{I,O_2}$ )=1.0. —: group A (n=11) received surfactant; ----: group B (n=5) received no treatment; and .....: group C (n=4) received saline. Presented as means  $\pm$  SEM. †: one rat died during the course of the study.

blood gases. Table 1 gives the data on BAL analysis and lung mechanics. Body weight showed a decrease on day 1 after intoxication, which progresses during the course of the study. The  $V_3$  showed a reduction of almost 50% on day 1 and stayed low, whereas the SI started to decrease from day 2. The BAL fluid showed a clear increase in protein content from day 1 to day 3. Surface activity of the BAL fluid was reduced on day 1–3 (table 1).

### Experiment 2

Twenty of 25 rats matched the preset criteria. Figure 2 clearly shows an immediate significant ( $p<0.05$ ) improvement in  $P_{a,O_2}$  after surfactant therapy (n=11); this  $P_{a,O_2}$  level was sustained for a 120 min period. The rats receiving no treatment (n=5) show no change over time, whereas the rats receiving saline (n=4) show a decrease in  $P_{a,O_2}$  as a result of the instilled volume. In this latter group, two rats died during the study.

## Discussion

The results of this study are in line with several other reports [5–7, 15]. We confirmed the suggestion by FISHER *et al.* [5] that intra-alveolar oedema is present within 24 h after paraquat intoxication and that this model is a model not of primary surfactant synthesis damage, but of surfactant inhibition. The increased total protein and raised

Table 1. – Effect of paraquat on rat lungs on days 1, 2 and 3

	Control	Days after paraquat intoxication		
		1	2	3
Body weight g	240 $\pm$ 3	211 $\pm$ 3*	202 $\pm$ 4*	199 $\pm$ 5*
$V_3$ mL.kg body weight <sup>-1</sup>	27.8 $\pm$ 1.5	19.8 $\pm$ 4.3	13.5 $\pm$ 3.3*	16.3 $\pm$ 3.3*
Stability index	0.97 $\pm$ 0.02	0.89 $\pm$ 0.04	0.64 $\pm$ 0.10*	0.66 $\pm$ 0.09*
Recovery %	91.6 $\pm$ 1.7	85.5 $\pm$ 3.0	92.5 $\pm$ 2.8	92.5 $\pm$ 2.8
Total protein mg.mL <sup>-1</sup>	0.20 $\pm$ 0.01	0.55 $\pm$ 0.07	2.1 $\pm$ 0.6*	4.1 $\pm$ 0.7*
Minimal surface tension mN.m <sup>-1</sup>	26.0 $\pm$ 1.2	30.2 $\pm$ 2.0	29.2 $\pm$ 1.8	32.2 $\pm$ 1.3*

Values are means  $\pm$  SEM.  $V_3$ : *post mortem* lung volume at end-expiration. \*:  $p<0.05$ , intoxicated animals *versus* controls, by standard analysis of variance (ANOVA).

minimal surface tension at 24 h after intoxication clearly show that the properties of surfactant in the alveoli are changing. These findings are supported by the reduction in  $V_5$  and the SI. The intra-alveolar accumulation of oedema can be explained in a number of ways. Firstly, paraquat accumulates in alveolar type I and II cells, where cell injury is mediated by the formation of free oxygen radicals, leading to membrane lipid peroxidation and other forms of tissue damage [16]. Thus, a quantitative surfactant deficiency occurs as a result of destruction of the surfactant-producing type II cells. Secondly, since paraquat causes cell damage to the cells that are part of the alveocapillary membrane, leakage of plasma into the alveolar space is likely to occur. Furthermore, oxygen radicals are known to cause increased vascular permeability [8]. These events explain the massive increase in protein content of the lavage fluid and the increased minimal surface tension, indicating the presence of plasma-derived surfactant inhibitors.

The main goal of treatment of acute respiratory distress syndrome (ARDS) is to maintain adequate arterial and tissue oxygenation. This can often be achieved by artificial ventilation with PEEP and increased inspiratory oxygen concentration. In the present study, increased ventilatory airway pressures and PEEP could maintain normal arterial oxygenation for at least 48 h after paraquat poisoning. After 72 h, however, this was not sufficient to restore the  $P_{a,O_2}$  to values within the normal range. This can be explained by alveolar collapse, resulting from increased alveolar surface tensions. Higher  $P_{aw}$  would be needed to open up the lungs and a PEEP of 6 cmH<sub>2</sub>O was not high enough to prevent end-expiratory collapse. In this situation surfactant replacement therapy resulted in a direct improvement in arterial blood gases. The main advantage of surfactant therapy is that the  $F_{I,O_2}$  can be reduced. This is of great importance, because high inspiratory oxygen concentrations can enhance paraquat toxicity in both rats [17] and humans [18].

Currently, the debate continues as to the dose of surfactant that should be used in ARDS patients. In this respect, surfactant inhibition plays a major role and the aim is to achieve a more favourable surfactant/inhibitor ratio [19]. This can be done in several ways. Firstly, surfactant should be given as early as possible [20] and, secondly, surfactant should be given in high dosage (titrated) until blood gases improve.

The findings indicate that, initially, a surfactant-deficient state and resulting hypoxaemia in the acute phase of paraquat poisoning can be overcome by the application of PEEP. At a later stage, a higher  $P_{aw}$  with PEEP had no effect. Intratracheal instillation of exogenous surfactant reduces opening pressure, prevents alveolar collapse and, combined with ventilatory support, restores gas exchange almost to normal.

In summary, this study shows that paraquat poisoning in rats results in a surfactant-deficient state, due to surfactant inhibition by plasma proteins leaking through the damaged alveocapillary membrane. Initially, surfactant deficiency can be treated with respiratory support with high peak airway pressures and positive end-expiratory pressure. When respiratory insufficiency is fully developed, intratracheal instillation of exogenous surfactant can almost completely restore gas exchange to normal. It is speculated that surfactant administration, as early as possible can break the

vicious circle of surfactant inhibition and diminish the damaging side-effects of artificial ventilation with high pressures and high oxygen concentrations.

### References

1. Clark DG, McElligott TF, Hurst EW. The toxicity of paraquat. *Br J Indust Med* 1966; 23: 126–132.
2. Bullivant CM. Accidental poisoning by paraquat: report of two cases in man. *BMJ* 1966; 5498: 1272–1273.
3. Bismuth C, Garnier R, Baud FJ, Muszynski J, Keyes C. Paraquat poisoning. An overview of the current status. *Drug Saf* 1990; 5: 243–251.
4. Manktelow BW. The loss of pulmonary surfactant in paraquat poisoning: a model for the study of the respiratory distress syndrome. *Br J Exp Pathol* 1967; 48: 366–369.
5. Fisher HK, Clements JA, Tierney DF, Wright M. Pulmonary effects of paraquat in the first day after injection. *Am J Physiol* 1975; 228: 1217–1223.
6. Fisher HK, Clements JA, Wright M. Pulmonary effects of the herbicide paraquat studied 3 days after injection in rats. *J Appl Physiol* 1973; 35: 268–273.
7. Robertson B, Enhorning G, Ivemark B, Malmqvist E, Modee J. Experimental respiratory distress induced by paraquat. *J Pathol* 1971; 103: 239–244.
8. Risberg B, Smith L, Ortenwall P. Oxygen radicals and lung injury. *Acta Anaesthesiol Scand* 1991; 95: Suppl., 106–116; Discussion 116–118.
9. Lorke D. A new approach to practical acute toxicity testing. *Arch Toxicol* 1983; 54: 275–287.
10. Hills BA. Alveolar liquid lining: Langmuir method used to measure surface tension in bovine and canine lung extracts. *J Physiol (Lond)* 1985; 359: 65–79.
11. Markwell MA, Haas SM, Bieber LL, Tolbert NE. A modification of the Lowry procedure to simplify protein determination in membrane and lipoprotein samples. *Anal Biochem* 1978; 87: 206–210.
12. Gruenewald P. A numerical index of the stability of lung expansion. *J Appl Physiol* 1984; 18: 665–667.
13. van Daal GJ, Bos JAH, Eijking EP, Gommers D, Hannappel E, Lachmann B. Surfactant replacement therapy improves pulmonary mechanics in end-stage influenza pneumonia in mice. *Am Rev Respir Dis* 1992; 145: 859–863.
14. Gommers D, Vilstrup C, Bos JAH, et al. Exogenous surfactant therapy increases static lung compliance, and cannot be assessed by measurements of dynamic compliance alone. *Crit Care Med* 1993; 21: 567–574.
15. Robertson B, Enhorning G, Ivemark B, Malmqvist E, Modee J. Paraquat-induced derangement of pulmonary surfactant in the rat. *Acta Paediat Scand* 1970; 206: Suppl., 37–39.
16. Rose MS, Smith LL, Wyatt I. Evidence for energy-dependent accumulation of paraquat into rat lung. *Nature* 1974; 252: 314–315.
17. Fisher HK, Clements JA, Wright RR. Enhancement of oxygen toxicity by the herbicide paraquat. *Am Rev Respir Dis* 1973; 107: 246–252.
18. Douze JM, van Heyst AN, van Dijk A, Maes RA, Drost RH. Paraquat poisoning in man. *Arch Toxicol* 1975; 34: 129–136.
19. Lachmann B, Eijking EP, So KL, Gommers D. *In vivo* evaluation of the inhibitory capacity of human plasma on exogenous surfactant function. *Intensive Care Med* 1994; 20: 6–11.
20. Gregory TJ, Longmore WJ, Moxley MA, et al. Surfactant chemical composition and biophysical activity in acute respiratory distress syndrome. *J Clin Invest* 1991; 88:

1976–1981.