

THE HAND

Journal of the
BRITISH SOCIETY FOR SURGERY OF THE HAND

Editors: H. Graham Stack, F.R.C.S.
Harold Bolton, Ch.M., F.R.C.S.
Westhay, Mount Avenue,
Hutton, Brentwood, Essex

THE TREATMENT OF PROLAPSE AND COLLAPSE OF THE PROXIMAL INTERPHALANGEAL JOINT

J. C. VAN DER MEULEN, Rotterdam

It is intended here to discuss the correction of these deformities rather than the treatment of the conditions leading to prolapse and collapse. Most hand surgeons will agree that in this kind of surgery success and failure go hand in hand and that it is difficult to separate the two. The success of treatment, in our opinion, is determined by a number of factors which we have tried to summarise as follows:

1. Timing of correction.
2. Nature of correction.
3. Period of immobilisation.
4. Prevention of adhesion formation.
5. Effect of devascularisation.

TREATMENT OF PROLAPSE

Timing of correction

Disbalance, when corrected early will not result in prolapse. But when it is allowed to persist and herniation of the proximal interphalangeal joint takes place, the effect on the integrity of the extensor hood (luxation of the lateral tendons), the condition of the volar structures (contractures), and the growth of the skeleton (bony deformation) will be disastrous.

This process is best illustrated in cases of camptodactyly. In the early treatment of this deformity, good results are usually obtained by correction of the volar skin deficiency which in our opinion is the primary cause. This is in contrast with the opinion of Millesi (1968) who believes that the deformity of the extensor expansion is congenital, and that the volar skin deficiency is secondary. Following the advice of Wilhelm and Kleinschmidt (1968) we have looked for lumbrical dysplasia in some cases but so far without success.

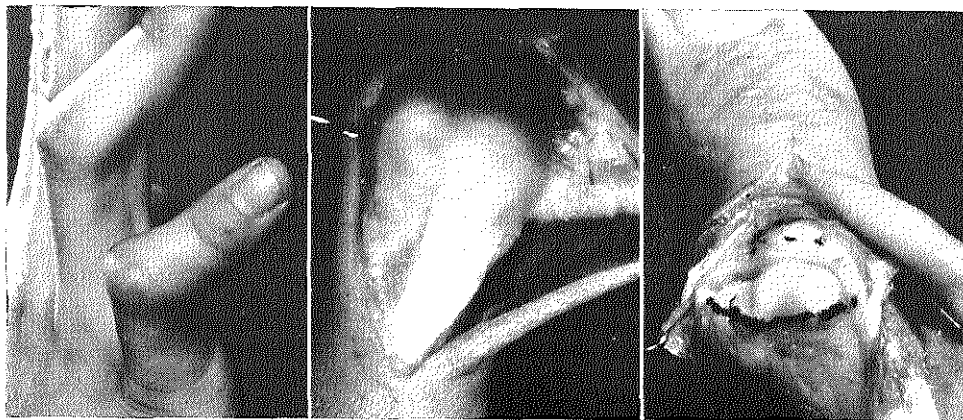


Fig. 1. Severe camptodactyly in a young man with prolapse of the proximal interphalangeal joint.
a. Ulnar dorsal view.
b. Ulnar dislocation of central and lateral extensor slips.
c. Ulnar deviation of articular surface of head of proximal phalanx.

In the late treatment correction of the volar skin deficiency alone will be of little value. Secondary changes will compromise a good result.

Contracture of the flexor tendon sheath, neurovascular bundles, collateral ligament (volar part) and retinacular ligament will usually be found. Exploration of the dorsal aspect will reveal bilateral luxation of the lateral slips or even the lateral slips and central tendon (Fig. 1). Finally bony deformations of the joint surface of the proximal interphalangeal joint in a longitudinal or transverse plane are more the rule than the exception. Early treatment of prolapse by conservative or operative measures is therefore indicated.

Nature of correction

Conservative measures can be very effective. Souter's review (1967) of 115 cases leaves no doubt about the value of splinting and Maisel's article (1965) on the treatment of burned proximal interphalangeal joints strengthened us in our belief that in general, splinting should be tried first to prevent or correct derormities.

In our department the following types of splints are used:

(1) A plaster of Paris splint. This method, which was advocated by Stewart (1962) works especially well in new or recent lesions of the extensor hood. The proximal interphalangeal joint is immobilised in extension and the distal interphalangeal joint is allowed to flex.

(2) A modified Odstock splint. (Dijkzigt splint) to correct secondary deformities when the skin is intact. For this splint only one S-shaped wire is used. It allows shortening and lengthening in a longitudinal direction and has a telescopic effect. Pressure on the finger seems to be more evenly distributed (Fig. 2a).

(3) A subcutaneous wire splint to correct secondary deformities when the skin is burned (Fig. 2b).

Operative measures are usually taken when conservative measures have failed, but here again no single approach has ever been uniformly successful despite the fact that numerous types of repair have been developed (Fig. 3).

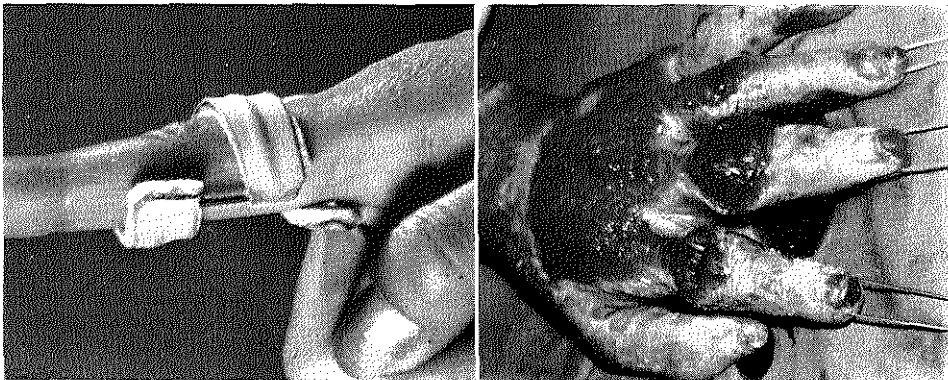


Fig. 2a. Simple S-shaped splint with telescoping effect used for prevention or correction of prolapse.

Fig. 2b. Bilateral extra-osseous Kirschner-wires used for prevention or correction of prolapse in burnt fingers.

The Treatment of Prolapse and Collapse of the Proximal Interphalangeal Joint
 —J. C. van der Meulen

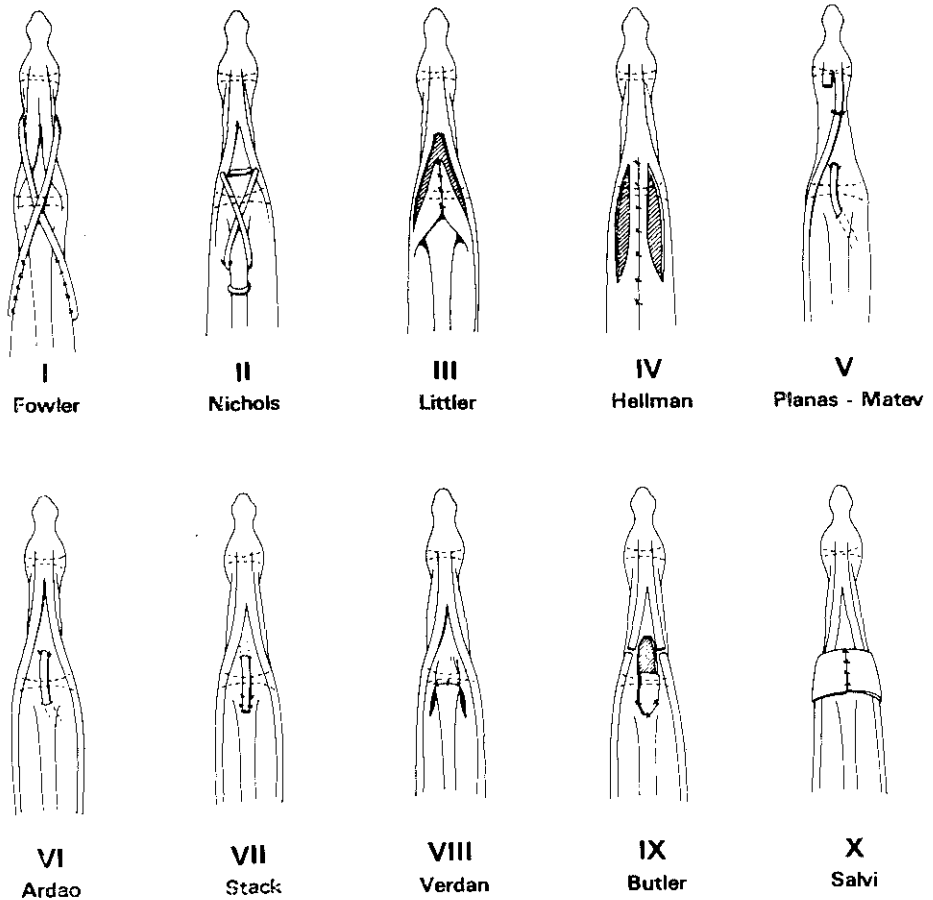


Fig. 3. Procedures used for correction of prolapse.

- I. Fowler: Reconstruction of extensor apparatus with tendon graft: lateral slips are used as motor.
- II. Nichols: Reconstruction of extensor apparatus with tendon graft: central slip is used as motor.
- III. Littler: Transposition of lateral slips; the oblique retinacular ligaments and insertion of the lumbrical tendon are left intact.
- IV. Hellman: Partial relocation of extensor hood.
- V. Planas-Matev: Transposition of lateral slip and lengthening of terminal slips.
- VI. Ardao: Transposition (antigrade) of superficial flexor tendon.
- VII. Stack: Transposition (retrograde) of superficial flexor tendon.
- VIII. Verdán: Plicature of central slip.
- IX. Butler: Reconstruction of central slip and release of lateral slips (Fowler-Dolphin).
- X. Salvi: Relocation of lateral slips by rotation of two dorsally based retinacular flaps.

Considering the great number of changes which may take place and the multitude of corrective procedures which may be necessary for correction, this is not surprising. Better results would probably be obtained however with a more universal realisation of the fact that it is not a lesion of the central tendon which causes prolapse (Micks 1971, Harris 1971) but the dislocation of the lateral extensor tendons. Relocation of these tendons is essential and should be a part of every reconstructive programme (Tubiana 1968, Elliot 1970, Zancolli 1968).

In planning this programme we agree with Zancolli and Curtis that a distinction should be made between reducible and irreducible deformities.

Reducible deformities

Here correction is usually possible by a combination of the following operative steps:—

- Restoration of the central extensor tendon.
- Relocation of the lateral extensor tendons.
- Release of the terminal extensor tendon.
- Reapproximation of the dorsal (transverse) retinacular ligament.
- Release of the lateral (oblique) retinacular ligament.

Irreducible deformities

When the deformity is irreducible, correction has to be preceded by the following steps:—

- Release of the oblique retinacular ligament.
- Release of the collateral ligament (volar part).
- Release of the volar capsule.
- Release of the flexor superficialis.

Period of immobilisation

Once correction has been achieved we will have to decide for how long immobilisation should be continued. We have seen older patients in whom three weeks was too long—the result being a finger stiff in extension and we have seen younger patients in whom four weeks was too short—the result being incomplete extension of the proximal interphalangeal joint because of the relaxation of newly formed scar-tissue. Since little can be done about the quality of adhesion formation which is probably related to the vascularisation of the finger it may be wise to vary the period of immobilisation with the age of the patient.

Method of immobilisation

It may also be wise to pay more attention to the method of immobilisation. Fixation of the proximal interphalangeal joint in extension with Kirschner-wires is a method favoured by many despite the fact that these wires may induce adhesion formation.

Tubiana removes his wires after one week and replaces them with an external splint. An alternative could be immobilisation not of the joint but of the extensor hood with the help of barbed pull-out wires.

Prevention of adhesions

Bad results are almost certain to follow when a tendon repair is done over bare bone.

To prevent the adherence of bone and tendon which is found in some of these cases we have used Silastic sheeting. So far there is reason to believe that the restoration of gliding is promoted by the presence of such an implant.

Effect of devascularisation

We would finally like to express our concern regarding the consequences of too aggressive surgery. On some occasions we have seen severe circulatory disturbances after straightening of a proximal interphalangeal joint and we know of one case in which complete necrosis led to amputation of the finger.

These circulatory disturbances are in our opinion almost invariably due to constriction of a stretched neurovascular bundle.

TREATMENT OF COLLAPSE

Timing of correction

As in the treatment of prolapse early correction is indicated to prevent secondary changes from developing. Delay will allow the deformity to become fixed. The dorsal structures will retract, permanent dislocation of the oblique retinacular ligament will result in contracture, the proximal synovial pouch will be obliterated (Harrison, 1965) and the volar structures will relax.

Nature of correction

Operative measures are to be taken when treatment of the condition leading to collapse (if indicated) has failed to correct the deformity. Here also a distinction should be made between reducible and irreducible deformities.

Reducible deformities

To correct a reducible deformity many procedures were developed (Fig. 4). The prevention of hyperextension is their common goal and good results can be obtained with most of these methods. Two warnings are in order however.

The first is the danger of over correction, with the method used by Kilgore and Graham (1967) (rerouting of the lateral extensor tendon) (Fig. 5).

The second is the danger of under correction with the method used by Littler (1967) (transposition of the lateral extensor tendon) (Fig. 6).

Irreducible deformities

To correct an irreducible deformity other steps should be taken, such as:—

Lysis of the central extensor tendon.

Lysis of the lateral extensor tendon.

Release of the dorsal-joint capsule.

Release of the collateral ligament (dorsal part).

Lysis of the volar joint capsule.

Lysis of the flexor tendons.

Proper execution of these steps following the directions given by Curtis (1954) may be rewarded with good results in cases otherwise considered hopeless (Fig. 7).

Period of immobilisation

Here again advice is difficult to give. In general it can be stated that immobilisation is not necessary when correction has been obtained. With the help of a tenolysis or tenotomy procedure the natural tendency to flex of the proximal interphalangeal joint will prevent recurrence. Immobilisation is imperative however when stabilisation is obtained by procedures in which tendon or cartilage are tethered to bone. Then periods from four to six weeks should be considered minimal.

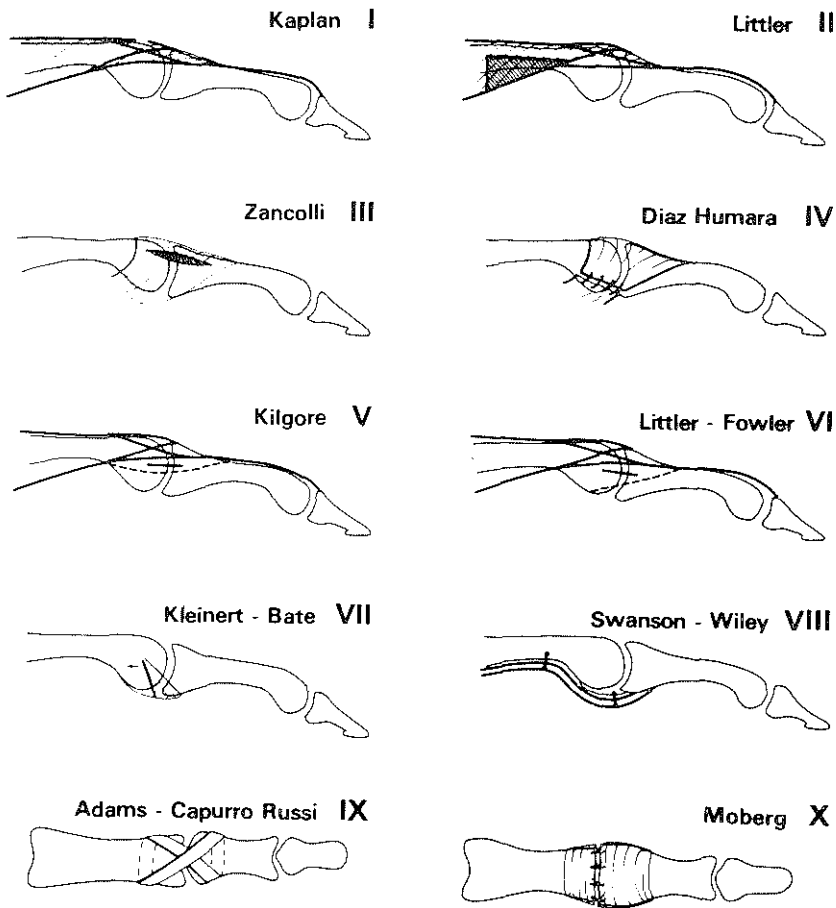


Fig. 4. Procedures used for the correction of collapse.

- I. Kaplan: Release of central slip.
- II. Littler: Release of lateral slips.
- III. Zancolli: Release of retinacular ligament (dorsal part).
- IV. Diaz-Hamara: Reefing of retinacular ligament (lateral part).
- V. Kilgore: Rerouting of lateral slip.
- VI. Littler-Fowler: Transposition of lateral slips. Homolateral (Littler) and heterolateral (Fowler).
- VII. Kleinert-Bate: Transposition of collateral ligament (volar part).
- VIII. Swanson-Wiley: Tenodesis of superficial flexor tendon.
 To joint capsule (Wiley).
 To proximal phalanx (Swanson).
- IX. Adams-Capurro Russi: Criss-cross graft. Tendon (Adams).
 Fascia lata (Capurro Russi).
- X. Moberg: Reapproximation of the volar capsule.

DISCUSSION

An attempt has been made to analyse some of the problems which may confront us in the treatment of prolapse and collapse.

Correction of disbalance resulting in prolapse or collapse can usually be achieved by restoration or redistribution of forces, acting on the proximal interphalangeal joint. An exact diagnosis of the underlying cause and careful evaluation of the condition of the musculo-tendineous and supporting structures surrounding the proximal interphalangeal joint is imperative.

Treatment will be more difficult when the condition of skin and skeleton contribute to the complexity of the deformity. Resurfacing of the integument using free or pedicled skin transplants or restabilisation of the proximal interphalangeal joint using Silastic-implants, may be indicated. Success is never guaranteed but the effort made is often worthwhile.

SUMMARY

Modern correction of prolapse and collapse of the proximal interphalangeal joint is reviewed. Reasons why no single method has been uniformly successful are discussed. A more selective approach in the treatment of these deformities is suggested and personal solutions to some of the problems are presented:—

- use of S-shaped-splints to prevent or correct flexion contractures of the proximal interphalangeal joint;
- use of extra-osseous Kirschner-wiring to prevent flexion contractures of proximal interphalangeal joint in burnt-fingers;
- use of silastic sheeting to inhibit formation of adhesions between tendon and bone in proximal interphalangeal surgery.

REFERENCES

- ADAMS, J. P. (1959) Correction of Chronic Dorsal Subluxation of the Proximal Interphalangeal Joint by Means of a Criss-Cross Volar Graft. *Journal of Bone and Joint Surgery*. 41-A 111-115.
- ARDAO (1961) Quoted by: Eduardo Zancolli. *Structural and Dynamic Bases of Hand Surgery*. Philadelphia, J. B. Lippincott Company. 1968. p. 125.
- BATE, J. T. (1945) An Operation for the Correction of Locking of the Proximal Interphalangeal Joint of Finger in Hyperextension. *Journal of Bone and Joint Surgery*. 27: 142-144.
- BUTLER, B. (1969) Another Boutonniere Procedure. *American Society for Surgery of the Hand*. Letters, October 6, 1969.
- CURTIS, R. M. (1954) Capsulectomy of the Interphalangeal Joints of the Fingers. *Journal of Bone and Joint Surgery*. 36-A 1219-1232.
- CURTIS, R. M. (1964) Treatment of injuries of proximal interphalangeal joint of fingers. *Current Practice in Orthopaedic Surgery*. 2: 125-139.
- DIAZ HUMARA, J. and INGLESIAS, L. (1958) Reconstruction of the extensor mechanism of two fingers in a congenital deformity. *Clinical Orthopaedics*. 11: 219-221.
- DOLPHIN, J. A. (1965) Extensor Tenotomy for Chronic Boutonniere Deformity of the Finger. *Journal of Bone and Joint Surgery*. 47-A 161-164.
- ELLIOTT, R. A. (1970) Boutonniere Repair: A Happy Nine Years. *American Society for Surgery of the Hand*. Letters, February 23, 1970.
- FOWLER, S. B. (1959) The Management of Tendon Injuries. *Journal of Bone and Joint Surgery*. 41-A 579-580.
- GARCIA CAPURRO, R. and RUSSI, J. C. (1943) Luxación interfalángica recidivante. *Archivos Uruguayos de Medicina, Cirugía y Especialidades*. 23: 134-137.
- HARRIS, E. C. (1971) Functional Anatomy of the Extensor Mechanism. 26th Annual Meeting of the American Society for Surgery of the Hand. San Francisco.
- HARRISON, S. H. (1965) Swan's Neck Deformity of the Fingers. *British Journal of Plastic Surgery*. 18: 79-87.
- HELLMANN, K. (1964) Die Wiederherstellung der Strecksehnen im Bereich der Finger-mittelgelenke. *Langenbeck's Archiv für Klinische Chirurgie*. 309: 36-38.

The Treatment of Prolapse and Collapse of the Proximal Interphalangeal Joint
—J. C. van der Meulen

- KAPLAN, E. B. (1962) Surgical Treatment of Spastic Hyperextension of the Proximal Interphalangeal Joints of the Fingers, Accompanied by Flexion of the Distal Phalanges. *Bulletin from the Hospital of Joint Diseases*. 23: 35–39.
- KAPLAN, E. B. (1936) Extension Deformities of the Proximal Interphalangeal Joints of the Fingers. An Anatomical Study. *Journal of Bone and Joint Surgery*. 18: 781–783.
- KILGORE, S. and GRAHAM, P. (1967) Operative Treatment of Swan Neck Deformity. *Plastic and Reconstructive Surgery*. 39: 468–471.
- KLEINERT, H. E. and KASDAN, M. L. (1965) Reconstruction of Chronically Subluxated Proximal Interphalangeal Finger Joint. *Journal of Bone and Joint Surgery*. 47–A 958–964.
- KUCZYNSKI, K. (1968) The Proximal Interphalangeal Joint. Anatomy and Causes of Stiffness in the Fingers. *Journal of Bone and Joint Surgery*. 50–B 656–663.
- LITTLER, J. W. and EATON, R. G. (1967) Redistribution of Forces in the Correction of the Boutonnière Deformity. *Journal of Bone and Joint Surgery*. 49–A 1267–1274.
- LITTLER, J. W. (1964) The Hand and Upper Extremity. *Reconstructive Plastic Surgery*. Ed. J. M. Converse. 4: Philadelphia, W. B. Saunders.
- LITTLER, J. W. (1960) The physiology and dynamic function of the hand. *Surgical Clinics of North America*. 40: 259–266.
- LITTLER, J. W. (1967) The Finger Extensor Mechanism. *Surgical Clinics of North America*. 47: 415–432.
- MAISELS, D. O. (1965) The Middle Slip or Boutonnière Deformity in Burned Hands. *British Journal of Plastic Surgery*. 18: 117–129.
- MATEV, I. (1964) Transposition of the Lateral Slips of the Aponeurosis in Treatment of Long-standing “Boutonnière Deformity” of the Fingers. *British Journal of Plastic Surgery*. 17: 281–286.
- MICKS, J. E. (1971) Isolated damage to the central slip of the extensor tendon. *American Society for Surgery of the Hand*. Letters. Jan. 4th, 1971.
- MILLESI, H. (1968) Zur Pathogenese und operativen Korrektur der Kamptodactylie. *Chirurgia Plastica et Reconstructiva*. 5: 55–61.
- MOBERG, E. and STENER, B. (1953) Injuries to the Ligaments of the Thumb and Fingers: Diagnosis, Treatment and Prognosis. *Acta Chirurgica Scandinavica*. 106: 166–186.
- NICHOLS, H. M. (1951) Repair of Extensor-tendon Insertions in the Fingers. *Journal of Bone and Joint Surgery*. 33–A 836–841.
- PORTIS, R. B. (1954) Hyperextensibility of the Proximal Interphalangeal Joint of the Finger Following Trauma. *Journal of Bone and Joint Surgery*. 36–A 1141–1146.
- SALVI, V. (1969) Technique for the Buttonhole Deformity. *The Hand*. 1: 96–97.
- SOUTER, W. A. (1967) The Boutonnière Deformity. *Journal of Bone and Joint Surgery*. 49–B 710–721.
- STEWART, I. M. (1962) Boutonnière Finger. *Clinical Orthopaedics*. 23: 220–226.
- SWANSON, A. B. and MATEV, I. B. (1970) The Proximal Interphalangeal Joint in Arthritic Disabilities and Experiences in the Use of Silicone Rubber Implant Arthroplasty in the Upper Extremity. Scientific Exhibit. American Academy of Orthopaedic Surgeons. Chicago, Jan., 1970.
- SWANSON, A. B. (1960) Surgery of the Hand in Cerebral Palsy and the Swan-neck Deformity. *Journal of Bone and Joint Surgery*. 42–A 951–964.
- TUBIANA, R. (1968) Surgical Repair of the Extensor Apparatus of the Fingers. *Surgical Clinics of North America*. 48: 1015–1031.
- VERDAN, C. E. (1966) Primary and Secondary Repair of Flexor and Extensor Tendon Injuries in Hand Surgery. Ed. J. E. Flynn. Baltimore, Williams and Wilkins Company. 220–275.
- WILEY, A. M. (1970) Instability of the Proximal Interphalangeal Joint, Following Dislocation and Fracture Dislocation: Surgical Repair. *The Hand*. 2: 185–191.
- WILHELM, A. and KLEINSCHMIDT, W. (1968) Neue ätiologische und therapeutische Gesichtspunkte bei der Kamptodactylie und Tendovaginitis stenosans. *Chirurgia Plastica et Reconstructiva*. 5: 62–66.
- ZANCOLLI, E. (1968) Structural and Dynamic Bases of hand surgery. Philadelphia, J. B. Lippincott Company. p. 94.