

Clinical and radiological outcomes of treatment of avascular necrosis of the femoral head using autologous osteochondral transfer (mosaicplasty). Preliminary report

Jacek Gagala · Marta Tarczyńska · Krzysztof Gawęda

Received: 3 February 2013 / Accepted: 31 March 2013 / Published online: 1 May 2013

© The Author(s) 2013. This article is published with open access at Springerlink.com

Abstract

Purpose The purpose of this study was to evaluate clinical and radiological outcomes of autologous osteochondral transfer (OATS) for femoral head osteonecrosis.

Methods Twenty-one hips in 20 patients (one woman and 19 men), average patients' age at the time of surgery of 35.4 (range 20–56) years, were treated with OATS for osteonecrosis of the femoral head (ONFH). Seven patients at pre-collapse ARCO stages IIA and IIB were treated with OATS alone. Thirteen patients with large pre-collapse ARCO IIC and post-collapse ARCO III and IV were treated with OATS and morselised bone allografts (OATS/allograft). Harris hip score (HHS) was used for clinical evaluation of outcomes; X-rays were performed to examine the evolution of the disease. Kaplan-Meier survival curves were used to determine the failure of the procedures with conversion to THR defined as endpoint.

Results Follow-up of patients treated with OATS alone was 46.14 (range 18–75) months with HHS improvement from a preoperative mean of 42 to 87.85 points at the latest follow-up examination. Only one patient in this group needed a revision operation with THR. The survival for this group of patients was 85.71 % at four years. Follow-up of patients treated with AOTS/allograft was 32.7 (range 7–84) months with HHS improvement from a preoperative mean of 35.2 to 65.7 points at the latest follow-up examination. One patient died six months after the surgery. There were five conversions to THR because of femoral head collapse in this group of patients with survival of 61.54 % at three years.

Conclusion The use of osteochondral grafts offers the possibility of successful treatment for ONFH at small and medium pre-collapse stages. The outcomes of large pre-collapse and post-collapse stages were below our expectations. OATS is a time buying procedure for young patients as it may defer total hip replacement.

Introduction

The prevalence of osteonecrosis of femoral head (ONFH) is not well known. It is assumed that from 10,000 to 20,000 new cases of ONFH are identified annually in the United States [1]. ONFH is a multi-aetiological disease with the death of osteocytes as the end stage of different pathological processes [2]. ONFH occurs mainly in young and active patients, usually between 30 and 50 years old [3, 4]. ONFH is a cause of 10 % of total hip arthroplasties performed every year in the United States and Western Europe and from 50 % to 65 % in Korea and Japan [1, 5, 6]. Despite advances in total hip replacement (THR) fixation techniques and improved durability of bearing surfaces [7, 8], there remains a risk of multiple revision arthroplasties due to osteolysis and loosening in high activity young patients [9]. That is why hip joint preserving procedures are treatment options of first choice as they may, at least, defer arthroplasty [10–16]. Autologous osteochondral transfer (OATS) or mosaicplasty is a well established method of treatment of focal cartilage lesions about the knee, talus and humeral capitellum which uses bone plugs covered with healthy hyaline cartilage [17]. Osteochondral plugs integrate with recipient tissues, thus restoring cartilage and healing bone defects. We present the results of treatment of ONFH with OATS performed via surgical hip joint dislocation.

J. Gagala · M. Tarczyńska · K. Gawęda (✉)
Orthopaedic Surgery and Traumatology,
Medical University, Lublin, Poland
e-mail: krzylub@o2.pl

Material and methods

This study presents an evaluation of treatment outcomes of OATS in 20 ONFH patients (21 hips). One woman and 19 men were treated. The average age was 35.4 (range 20–56) years. The diagnosis of ONFH was based on clinical and radiological examination. ARCO classification was used for radiological staging of ONFH [18, 19]. Operations were performed between June 2005 and May 2010. Patients without femoral head collapse (seven patients, seven hips) and with small or medium necrotic changes (ARCO IIA or IIB) were treated with OATS alone. Patients without collapse but with large necrotic involvement (ARCO IIC), with crescent sign (ARCO III) and patients with collapse, but without acetabular involvement (ARCO IV) (13 patients/14 hips) were treated with AOTS combined with reconstruction using morselised bone allografts (OATS/allograft). Exclusion criteria were age above 60 years and osteoarthritic changes in hip joint (ARCO V).

Operative technique

Surgical hip dislocation according to Ganz et al. [20] was performed with the patient placed in a lateral position. The femoral head was dislocated, and the part of the femoral head surface with an underlying necrotic lesion was identified. Mosaicplasty tools (Smith & Nephew, Andover, Massachusetts) were used to harvest and transfer osteochondral grafts. Osteochondral cylindrical donor grafts 8.5 mm in diameter and 25 mm in length were harvested from the non-weightbearing area of the proximal lateral femoral condyle of the ipsilateral knee through a small lateral parapatellar arthrotomy. Drill bits of the same diameter were used to make from three to five tunnels through articular cartilage into the necrotic portion of the femoral head. Care was taken to place drill bits perpendicular to the femoral head surface. In the cases in pre-collapse stage, the cylinders were transplanted and press-fitted through the necrotic lesion into the healthy recipient bone. Care was taken to recreate the curvature of femoral head. In the hips with large pre-collapse lesions or with collapse, necrotic bone was removed through cylindrical windows made in cartilage. The removal was performed using burrs, gouges and curettes until vital bleeding bone was reached, taking care not to damage the surrounding cartilage (Fig. 1). The bone defect was tightly packed with morselised allogenic bone grafts until the normal spherical shape of the femoral head was reconstructed. Drill bits were used once again to recreate tunnels in bone grafts. Osteochondral autografts were transplanted and press-fitted through the bone grafts into the healthy recipient bone. The hip was reduced and the capsule closed. The greater trochanter osteotomy was fixed with two cortical screws. Subtrochanteric derotational osteotomy was

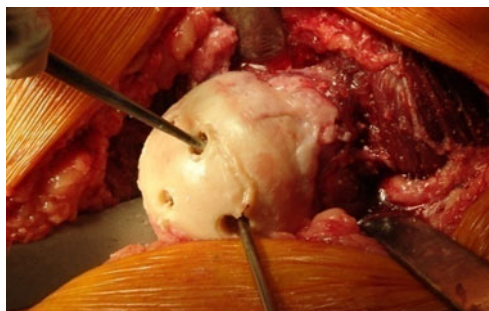

Fig. 1 Surgical technique of necrotic subchondral bone removing

performed simultaneously in one patient during the OATS procedure. The patients used two crutches with partial weightbearing for 12 weeks after surgery. Partial weightbearing with at least one crutch was advised for the following nine months.

Clinical follow-up

The following parameters were documented for the follow-up evaluation: age at surgery, gender, ONFH risk factors, preoperative Harris hip score (HHS) [21], postoperative HHS, postoperative complications, follow-up duration.

Radiological evaluation

The radiological evaluation included: preoperative, immediate postoperative and follow-up X-ray (anteroposterior and axial) examinations. X-rays were compared in order to analyse the outcome of the treatment.

Statistical analysis

Kaplan-Meier survival curves were used to determine the failure of the procedures. Conversion of the hip joint to THR was defined as a failure of the procedure.

Results

No patient was lost to follow-up. One patient from the OATS/allograft group died six months after the surgery of a cause unrelated to treatment and was excluded from the follow-up evaluation. Follow-up of patients treated with OATS alone was 46.14 (range 18–75) months. Follow-up of patients treated with AOTS/allograft was 32.7 (range 7–84) months.

Survival analysis

One conversion to THR in patients treated with OATS alone was performed 18 months after the surgery because of

persistent pain. The survival rate for this group of patients was 85.71 %. There were five conversions to THR in the OATS/allograft group. Femoral head collapse was the cause of all THR in this group of patients. Survival of the OATS/allograft group was 61.54 % (Fig. 2).

Harris hip score

The mean HHS of patients treated with OATS alone increased from a mean 42 (range 40–44) points to 87.85 (range 42–98) points at the latest follow-up examination. The mean HHS in the OATS/allograft group increased from a mean of 35.2 (range 28–40) points to 65.7 (range 38–96) points at the latest follow-up examination.

Radiological examination

No signs of disease radiological progression were observed in the group treated with OATS alone (Table 1). Collapse of the femoral head occurred in seven hips (53.8 %) treated with OATS/allograft. Five of these hips had been previously reconstructed because of ARCO IV, one because of ARCO IIC and one because of ARCO III (Table 2).

Complications

There were no cases of infection, thrombosis or embolism in the entire OATS group of patients. No patient complained of donor site numbness in the harvested knee. No cases of greater trochanter osteotomy non-union were reported.

Conversion to THR

No complications during conversion to THR were reported. All revision operations were performed in our department. Screws fixing the osteotomy of the greater trochanter were removed during these operations.

Discussion

The natural history of ONFH leads to progression of radiological changes even in asymptomatic cases. Non-operative treatment with rest and partial weight bearing is only indicated in early and small lesions, but is ineffective in 80–90 % of cases [22]. Core decompression is one of the most frequently used procedures to prevent progression of the disease [16]. It has been revealed that core decompression is effective in pre-collapse and small lesions [16, 23]. The treatment of large pre-collapse and post-collapse femoral heads consists of removing the necrotic bone and reconstruction with bone grafts. This procedure can be performed through a core decompression tract [24], trapdoor in the articular surface [25] or window made in femoral neck/head junction [26].

Resurfacing of the femoral head in avascular necrosis with fresh osteochondral allografts was introduced by Meyers in the 1970s and 80s [27, 28]. Patients were treated according to a protocol in which the choice of treatment depended on the results of arthroscopic examination of the articular surface. Osteochondral allografting of the femoral head was only indicated in patients with early degenerative changes, e.g., fibrillation, discoloration, or fissures in the cartilage. Meyers reported on the results of allogenic osteochondral transplantations of 25 femoral heads in 21 patients [29]. Twenty of his patients were treated because of ONFH and one because of Pipkin type II fracture dislocation. The procedure was bilateral in four patients. Eight hips (32 %) failed within the first year after the surgery and one failed after 18 months. Fifty percent of the transplants failed in the groups that had been operated upon for steroid-induced ONFH and femoral neck fractures. The rate of success in non-steroid induced ONFH was 80 % after follow-up of nine to 63 months. Meyers did not report any cases of rejection of the allografts.

Only a few papers discuss the results of autologous osteochondral transplantations in the treatment of articular

Fig. 2 Comparison of survival rate in mosaicplasty group and mosaicplasty/allograft group

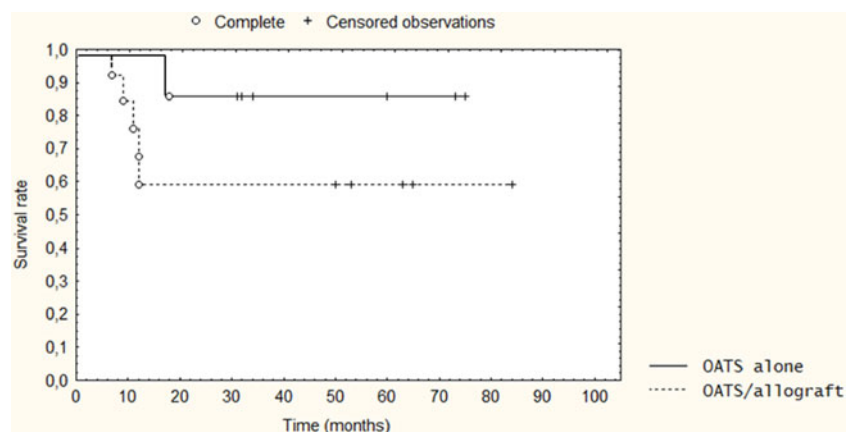


Table 1 Characteristics of OATS alone group

Patient	Gender	Age at surgery (years)	Risk factors	ARCO stage	Preoperative HHS (points)	Follow up (months)	Postoperative HHS (points)	End point
1	Male	40		IIA	40	73	96	
2	Male	32	Smoking	IIA	42	18	42	THR
3	Male	20		IIA	42	60	98	
4	Male	30	Corticosteroids	IIB	44	75	92	
5	Male	28	Smoking	IIB	42	32	95	
6	Male	22	Post-traumatic	IIA	44	31	96	
7	Female	46		IIB	40	34	96	
Mean value		31.14			42	46.14	87.85	

defects of the femoral head. In 2008, Hangody et al. [17] reported the long-term results of 1,097 mosaicplasties performed at their institution, of which 11 were done on femoral heads. Those authors, however, did not review the indications or the operative technique, only mentioning in passing that the patients with femoral head mosaicplasties were followed up regularly. Sotereanos et al. [30] described a case of a patient treated with mosaicplasty because of a subchondral cyst formed after previous treatment for ONFH with a free vascularised autograft. Osteochondral autografts were harvested from the femoral head–neck junction. After a follow-up of 66 months, the femoral head did not deteriorate, and the Harris hip score improved from 45 to 96 points. Cases of successful treatment of late sequelae of the Legg-Calvé-Perthes disease with OATS have also been reported [31, 32].

To the best of our knowledge, only one paper presenting the outcomes of ONFH reconstruction with autologous osteochondroplasty has been published so far. Rittmeister

et al. [33] reported on five-year results of osteochondral transplantation in the treatment of ONFH in five patients. All hips had preoperative collapse. From one to three osteochondral grafts of nine to 13 mm in diameter were used. The grafts were used only for hyaline cartilage resurfacing. The result was unsatisfactory in four hips. These hips underwent total hip arthroplasty after a mean of 49 months. The authors concluded that femoral head osteochondral grafting had proven technically possible in restoring the articular surface. Our study evaluated the clinical and radiological outcome of ONFH treatment with OATS in 20 hips. Seven patients treated with OATS alone for small and medium pre-collapse ARCO II lesions had a survival of 85.71 %. Thirteen hips treated with OATS/allograft for large pre-collapse ARCO IIC lesions and ARCO III and IV had a survival of 61.54 %. It is difficult to compare our results with those of Rittmeister and colleagues because of the small number of patients in

Table 2 Characteristics of OATS/allograft group

Patient	Gender	Age at surgery (years)	Risk factors	ARCO stage	Preoperative HHS (points)	Follow up (months)	Complications	Postoperative HHS (points)	End point
1	Male	32	Corticosteroids	IVC	38	12	Collapse	38	THR
2	Male	48	Diabetes, hepatitis C	IVC	28	12	collapse	42	THR
3	Male	32	Alcohol, smoking	IVB	28	9	Collapse	56	
4	Male	33	Gout	IVB	30	7	Collapse	48	THR
5	Male	40	Alcohol	IIIC	32	12	Collapse	48	
6	Male	36	Alcohol, smoking	IIC	30	65		85	
7	Male	56	Corticosteroids	IVC	36	84		90	
8	Male	41	Gout	IVC	36	9	Collapse	42	THR
9	Male	42	Alcohol	IIC	40	63		96	
10	Male	27	Smoking	IVC	38	53		87	
11	Male	27	Smoking	IVC	40	50		90	
12	Male	40	Alcohol	IIC	40	11	Collapse	40	THR
13	Male	26	Corticosteroids	IIIB	39	65		92	
Mean value		37.7			35.2	32.7		65.7	

both papers. We can only speculate that our patients with more advanced ONFH had better outcomes because necrotic changes had been debrided and reconstructed with bone grafts in their entirety, thus preventing collapse in some cases. The OATS/allograft group had more ONFH risk factors than the patients treated with OATS alone, which may influence graft incorporation. The outcomes of OATS did not differ from those of other treatments for ONFH. A meta-analysis of the literature performed by Lieberman et al. [16] revealed that 15 % of pre-collapse and 50 % of post-collapse hips had radiographic progression of the disease despite operative treatment. The authors concluded that no procedure was superior to others in preventing ONFH progression. The bone graft healing process can be enhanced with ancillary growth and differentiation factors [34]. Seyler et al. [35] evaluated 39 hips treated by nonvascularised bone grafting with supplemental OP-1 (BMP-7). After a mean follow-up of 36 months they reported a survival of 80 % in small and medium lesions, but only 22 % in large lesions.

An obvious disadvantage of autologous osteochondral transfer is the necessity to expose the knee joint. It has been reported that some patients complain of knee pain or functional problems. Reddy et al. [36] reported on morbidity associated with osteochondral harvesting from asymptomatic knees in the treatment of OCD of the talus. Out of a group of 11 patients, six complained of knee joint instability in daily activities. On the other hand Hangody [17] stated that knee complaints were relatively rare in the group of patients in which grafts were transferred outside the knee joint. In 98 % of these patients, knee complaints resolved completely within one year. Restoration of donor sites depends on their peripheral placement, small sizing and proper spacing of the individual grafts. None of our patients complained of knee pain.

OATS is a technically demanding procedure especially as regards the perpendicular placement of instruments towards the donor site during graft harvesting, which may influence the proper shape of the reconstructed articular surface and the congruity of the operated joint.

In conclusion, treatment of ONFH with OATS is neither better nor worse than other joint preserving procedures. The use of osteochondral grafts offers the possibility of successful treatment for ONFH at small and medium pre-collapse stages. The outcomes of large pre-collapse and post-collapse stages were lower than our expectations. A limitation of this study is the relatively small number of patients with different aetiologies of ONFH. OATS of the femoral head is a time-consuming procedure for young patients suffering from ONFH, as it may defer THR. Conversion to THR after OATS proceeded without any complications.

Open Access This article is distributed under the terms of the Creative Commons Attribution License which permits any use, distribution, and reproduction in any medium, provided the original author(s) and the source are credited.

References

- Vail TP, Covington DB (1997) The incidence of osteonecrosis. In: Urbaniak JR, Jones JP Jr (eds) *Osteonecrosis: etiology, diagnosis, and treatment*. The American Orthopaedic Association, Rosemont, pp 43–49
- Assouline-Dayan Y, Chang C, Greenspan A, Shoenfeld Y, Gershwin ME (2004) Pathogenesis and natural history of osteonecrosis. *Semin Arthritis Rheum* 32:94–124
- Akinyoola AL, Adediran IA, Asaleye CM, Bolarinwa AR (2009) Risk factors for osteonecrosis of the femoral head in patients with sickle cell disease. *Int Orthop* 33:923–926
- Kang JS, Moon KH, Kwon DG, Shin BK, Woo MS (2013) The natural history of asymptomatic osteonecrosis of the femoral head. *Int Orthop* 37:379–384
- Kim S-Y, Rubash HE (2006) Avascular necrosis of the femoral head: the Korean experience. In *The adult hip*, vol. 2. Lippincott Williams & Wilkins, Philadelphia, pp 1078–1086
- Fukushima W, Fujioka M, Kubo T, Tamakoshi A, Nagai M, Hirota Y (2010) Nationwide epidemiologic survey of idiopathic osteonecrosis of the femoral head. *Clin Orthop Relat Res* 468:2715–2724
- Kim Y-H, Chou Y, Kim J-S (2010) Cementless total hip arthroplasty with ceramic-on-ceramic bearing in patients younger than 45 years with femoral-head osteonecrosis. *Int Orthop* 34:1123–1127
- Moriya M, Uchiyama K, Tajahira N, Fukushima K, Yamamoto T, Hoshi K, Itoman M, Takaso M (2012) Evaluation of bipolar hemiarthroplasty for the treatment of steroid-induced osteonecrosis of the femoral head. *Int Orthop* 36:2041–2047
- Huo MH, Dumont GD, Knight JR, Mont MA (2011) What's new in total hip arthroplasty. *J Bone Joint Surg (Am)* 93(20):1944–1950
- Baksi DP, Pal AK, Bakshi DD (2009) Long-term results of core decompression and muscle–pedicle bone grafting for osteonecrosis of the femoral head. *Int Orthop* 33:41–47
- Gangji V, Rooze M, De Maertelaer V, Hauzeur JP (2009) Inefficacy of the cementation of femoral head collapse in glucocorticoid-induced osteonecrosis. *Int Orthop* 33:639–642
- Floerkemeier T, Thorey F, Daentzer D, Lerch M, Klages P, Windhagen H, von Lewinski G (2011) Clinical and radiological outcome of the treatment of osteonecrosis of the femoral head using the osteonecrosis intervention implant. *Int Orthop* 35:489–495
- Yin S, Zhang C, Jin D, Chen S, Sun Y, Sheng J (2011) Treatment of osteonecrosis of the femoral head in lymphoma patients by free vascularised fibular grafting. *Int Orthop* 35:1125–1130
- Yoshioka T, Mishima H, Akaogi H, Sakai S, Li M, Ochiai N (2011) Concentrated autologous bone marrow aspirate transplantation treatment for corticosteroid-induced osteonecrosis of the femoral head in systemic lupus erythematosus. *Int Orthop* 35:823–829
- Civinini R, De Biase P, Carulli C, Matassi F, Nistri L, Capanna R, Innocenti M (2012) The use of an injectable calcium sulphate/calcium phosphate bioceramic in the treatment osteonecrosis of the femoral head. *Int Orthop* 36:1583–1588
- Lieberman JR, Engstrom SM, Meneghini MD, SooHoo NF (2012) Which factor influence preservation of the osteonecrotic femoral head? *Clin Orthop Relat Res* 470:525–534
- Hangody L, Vásárhelyi G, Hangody LR, Sükösd Z, Tibay G, Bartha L, Bodó G (2008) Autologous osteochondral grafting—technique and long-term results. *Injury* 39(suppl 1):S32–S39
- Gardniers JW (1992) A new international classification of osteonecrosis of the ARCO-committee on terminology and classification. *ARCO News* 4:41–46

19. Lee G-C, Steinberg ME (2012) Are we evaluating osteonecrosis adequately? *Int Orthop* 36:2433–2439
20. Ganz R, Gill TJ, Gautier E, Ganz K, Krügel N, Berlemann U (2001) Surgical dislocation of the adult hip. A technique with full access to femoral head and acetabulum without the risk of avascular necrosis. *J Bone Joint Surg Br* 83:1119–1124
21. Harris WH (1969) Traumatic arthritis of the hip after dislocation and acetabular fractures: treatment by mold arthroplasty. An end result study using a new method of result evaluation. *J Bone Joint Surg (Am)* 51:737–755
22. Mont MA, Carbone JJ, Fairbank AC (1996) Core decompression versus nonoperative management for osteonecrosis of the hip. *Clin Orthop Relat Res* 324:169–178
23. Fairbank AC, Bhatia D, Jinnah RH, Hungerford DS (1995) Long-term results of core decompression for ischemic necrosis of the femoral head. *J Bone Joint Surg Br* 77:42–49
24. Rijnen WHC, Gardeniers JWM, Buma P, Yamano K, Sloof TJJH, Schreurs BW (2003) Treatment of femoral head osteonecrosis using bone impaction grafting. *Clin Orthop Relat Res* 417:74–83
25. Zeng Y-R, He S, Feng W-J, Li F-I, Li J, Jian L-Y, Zeng J-C, Fan Y-G (2013) Vascularised greater trochanter bone graft, combined free iliac flap and impaction bone grafting for osteonecrosis of the femoral head. *Int Orthop* 37:391–398
26. Wang B-L, Sun W, Shi Z-C, Zhang N-F, Yue D-B, Guo W-S, Shi S-H, Li Z-R (2010) Treatment of nontraumatic osteonecrosis of the femoral head using bone impaction grafting through a femoral neck window. *Int Orthop* 34:635–639
27. Meyers MH (1978) The treatment of osteonecrosis of the hip with osteochondral allografts and muscle pedicle graft technique. *Clin Orthop Relat Res* 130:202–209
28. Meyers MH, Jones RE, Bucholz RW, Wenger DR (1983) Fresh autogenous grafts and osteochondral allografts for the treatment of segmental collapse in osteonecrosis of the hip. *Clin Orthop Relat Res* 174:107–112
29. Meyers MH (1985) Resurfacing of the femoral head with fresh osteochondral allografts. Long term results. *Clin Orthop Relat Res* 197:111–114
30. Sotereanos NG, Demeo PJ, Hughes TB, Bargiotas K, Wohlrab D (2008) Autogenous osteochondral transfer in the femoral head after osteonecrosis. *Orthopedics* 31(2):177
31. Weisz MA (2006) Fokale Osteo-Chondro-Nekrose des Hüftkopfes beim Erwachsenen bei Zustand nach M. Perthes im Kindesalter. Ist die autologe Knorpel-Knochen-Transplantation am Hüftkopf eine Therapie-Option? *Z Orthop* 144:1–5
32. Girard J, Roumazeille T, Sakr M, Migaud H (2011) Osteochondral mosaicplasty of the femoral head. *Hip Int* 21(05):542–548
33. Rittmeister M, Hochmuth K, Kriener S, Richolt J (2008) 5-Jahres-Ergebnisse nach autologer Knorpel-Knochen-Transplantation bei Hüftkopfnekrose. *Orthopäde* 34:320–326
34. Mont MA, Jones LC, Einhorn TA, Hungerford DS, Reddi AH (1998) Osteonecrosis of the femoral head. Potential treatment with growth and differentiation factors. *Clin Orthop Relat Res* 355(Suppl):S314–S335
35. Seyler TM, Marker DR, Ulrich SD, Fatscher T, Mont MA (2008) Nonvascularized bone grafting defers joint arthroplasty in hip osteonecrosis. *Clin Orthop Relat Res* 466:1125–1132
36. Reddy S, Pedowitz DI, Parekh SG, Sennett BJ, Okereke E (2007) The morbidity associated with osteochondral harvest from asymptomatic knees for the treatment of osteochondral lesions of the talus. *Am J Sports Med* 35(1):80–85