

# Consensus on Current Injectable Treatment Strategies in the Asian Face

Woffles T. L. Wu<sup>1</sup> · Steven Liew<sup>2</sup> · Henry H. Chan<sup>3</sup> · Wilson W. S. Ho<sup>4</sup> ·  
Nantapat Supapannachart<sup>5</sup> · Hong-Ki Lee<sup>6</sup> · Adri Prasetyo<sup>7</sup> · Jonathan Nevin Yu<sup>8</sup> ·  
John D. Rogers<sup>9</sup> · Asian Facial Aesthetics Expert Consensus Group



Received: 16 June 2015 / Accepted: 8 January 2016 / Published online: 18 February 2016  
© The Author(s) 2016. This article is published with open access at [Springerlink.com](http://Springerlink.com)

## Abstract

**Background** The desire for and use of nonsurgical injectable esthetic facial treatments are increasing in Asia. The structural and anatomical features specific to the Asian face, and differences from Western populations in facial aging, necessitate unique esthetic treatment strategies, but published recommendations and clinical evidence for injectable treatments in Asians are scarce.

**Method** The Asian Facial Aesthetics Expert Consensus Group met to discuss current practices and consensus opinions on the cosmetic use of botulinum toxin and hyaluronic acid (HA) fillers, alone and in combination, for facial

applications in Southeastern and Eastern Asians. Consensus opinions and statements on treatment aims and current practice were developed following discussions regarding pre-meeting and meeting survey outcomes, peer-reviewed literature, and the experts' clinical experience.

**Results** The indications and patterns of use of injectable treatments vary among patients of different ages, and among Asian countries. The combination use of botulinum toxin and fillers increases as patients age. Treatment aims in Asians and current practice regarding the use of botulinum toxin and HA fillers in the upper, middle, and lower face of patients aged 18 to >55 years are presented.

**Conclusions** In younger Asian patients, addressing proportion and structural features and deficiencies are important to achieve desired esthetic outcomes. In older patients, maintaining facial structure and volume and addressing lines and folds are essential to reduce the appearance of aging. This paper provides guidance on treatment strategies to address the complex esthetic requirements in Asian patients of all ages.

**Level of Evidence V** This journal requires that the authors assign a level of evidence to each article. For a full description of these Evidence-Based Medicine ratings, please refer to the Table of Contents or the online Instructions to Authors [www.springer.com/00266](http://www.springer.com/00266).

**Keywords** Facial esthetics · Esthetic outcomes · Treatment strategies · Hyaluronic acid fillers · Botulinum toxin · Aging

On behalf of the Asian Facial Aesthetics Expert Consensus Group. The members of the Asian Facial Aesthetics Expert Consensus Group are given in Appendix.

✉ Woffles T. L. Wu  
[woffles@woffleswu.com](mailto:woffles@woffleswu.com)

<sup>1</sup> Camden Medical Centre, Woffles Wu Aesthetic Surgery and Laser Centre, 1 Orchard Boulevard, Suite #09-02, Singapore 249615, Singapore

<sup>2</sup> Shape Clinic, Sydney, Australia

<sup>3</sup> Department of Medicine, University of Hong Kong, Pokfulam, Hong Kong

<sup>4</sup> The Specialists: Lasers, Aesthetic and Plastic Surgery Central, Pokfulam, Hong Kong

<sup>5</sup> Department of Dermatology, Ramathibodi Hospital, Mahidol University, Bangkok, Thailand

<sup>6</sup> Image Plastic Surgery Clinic, Seoul, Korea

<sup>7</sup> REJUVA Clinic, Surabaya, Indonesia

<sup>8</sup> JY Dermatology and Aesthetic Center, Manila, Philippines

<sup>9</sup> Regional Medical Affairs, Allergan Asia Pacific, Singapore, Singapore

## Introduction

The advent of safe and predictable injectable agents, expanded indications for their use, and improved understanding of their role in facial volumization, has helped

practitioners advance from ‘two-dimensional’ treatment strategies previously used to reduce facial lines in aging, toward the use of injectable treatments aimed at creating three-dimensionality to achieve facial esthetic restructuring and rejuvenation in patients of all ages. These three-dimensional changes were previously only attainable through surgery, but now can be achieved with botulinum toxin and hyaluronic acid (HA) fillers in many situations.

In Asia, as in Western countries, botulinum toxin is used extensively to treat dynamic lines in the upper face [1]. Botulinum toxin is also used to reshape and recontour the face to correct perceived undesirable anatomical features (e.g., reduce bulk of the masseter and activity of the mentalis) in younger patients, and for rejuvenation in older patients [1–9]. Intradermal injection of minute doses of botulinum toxin into the full face and neck to achieve skin rejuvenation [4, 9–11] has also gained popularity in some parts of Asia.

HA fillers are used more commonly and extensively for facial restructuring purposes in young Asians than in young Western patients, to address structural features and deficiencies that are perceived as unesthetic [12]. Physicians commonly use HA to reshape and recontour facial features, to address structural deficiency in the projection of the midline facial features (medial malar, forehead, nose, chin, and glabella), to correct “flatness” of the infraorbital and medial malar regions, to reduce under-eye shadows, and to improve projection and definition of the nose and chin, thereby creating a visual illusion of “narrowing” to the whole face (Fig. 1a) [9, 13–19]. More recently, physicians have used HA to volumize and reshape the Asian forehead to create an esthetically pleasing, convex, and youthful contour.

For older Asians, fillers are mainly used to restore volume loss in areas of the face that show signs of aging due to volume deflation and tissue descent (such as the brow, midface, periorbital, pre-auricular, and perioral regions), and to address areas of intrinsic anatomical structural deficiency that become more pronounced with age-related volume loss, such as the medial malar, nose, inferior orbital rim, jawline, pre- and post-jowl regions, perialar recess, and chin (Fig. 1b).

Botulinum toxin and HA fillers are often used in combination to achieve the esthetic outcomes desired by Asians (Fig. 1). Combined treatment results in synergistic improvement compared to individual use of these agents and is used as “age-prevention” treatment in younger patients [20]. Although numerous papers describing these techniques in Western populations have been published [20–24], only one English-language paper that describes combination injectable treatment in Asians could be found in PubMed [25].

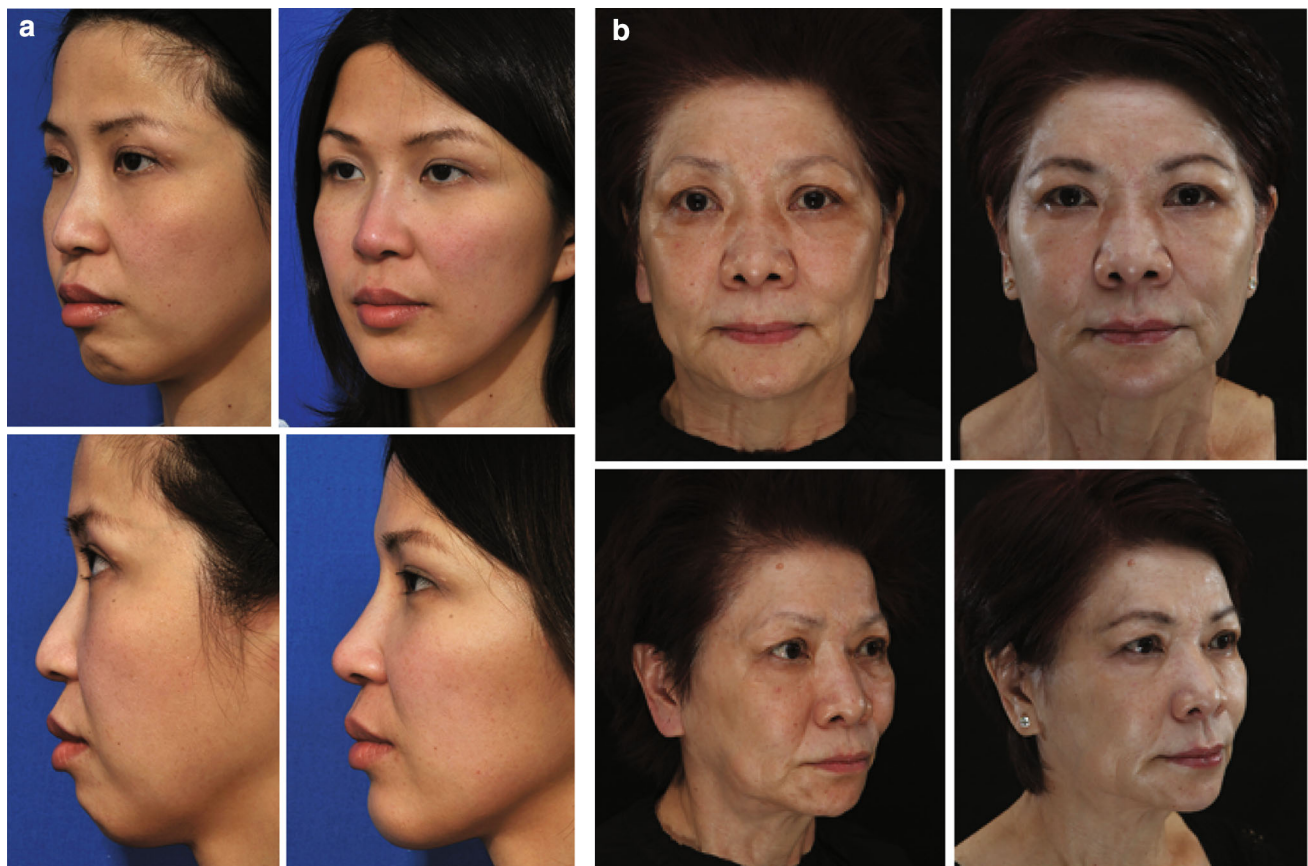
The physical features characteristic of the Asian face are related to specific skeletal and morphological features that differ from those of Caucasians [12]. Hence, different

treatment strategies are required to achieve esthetic or anti-aging outcomes in Asians. To address the lack of adequate recommendations and published clinical evidence available to physicians who treat Asian patients for facial esthetic concerns, the Asian Facial Aesthetics Expert Consensus Group, comprising eight plastic surgeons, 11 dermatologists, an esthetic physician, and an anatomist from 11 Asia Pacific countries (Table 1), met in Seoul on June 4–5, 2014 to discuss current local practices. The physicians had 7–30 years’ (mean 17 years) experience in facial esthetics [12]. These experts were chosen based on their vast experience of treating Asian patients, their presence on advisory boards, the frequency of their presentations at regional and international conferences, and their contribution to the literature. Described here are their consensus opinions regarding the cosmetic facial use of botulinum toxin and HA fillers in Asians from Southeast and Eastern Asia, alone and in combination.

## Methods of Consensus Development

To determine which noninvasive facial esthetic treatments are most commonly used in Asian patients of different age groups, the Expert Group members completed a pre-meeting online survey and then during the meeting, they were again surveyed to determine (i) the percentage of patients that they treat for each individual indication, based on the total number of patients who present to them for noninvasive facial esthetic treatment, and (ii) the treatment methods they use for each indication. The purpose of the meeting survey was to give an indication of how common each treatment concern is among their Asian patients, and to provide an overview of common practice patterns. Responses from the three Indian experts who attended were not included in the data presented here because treatment of patients from the Indian subcontinent is beyond the scope of this publication. Rare procedures and high-risk treatments requiring extensive experience were also not discussed at the meeting or mentioned in this review.

A PubMed review of the English-language medical literature conducted with the search terms “hyaluronic acid filler,” “botulinum,” “face,” “facial,” “Asia,” “Asian,” “Korea,” “Korean,” “China,” “Chinese,” “Thailand,” “Singapore,” “Indonesia,” “Japan,” and “Philippines” was completed before the meeting. Due to the paucity of prospective, randomized, comparative, controlled studies of botulinum toxin and HA fillers in Asian patients (with only one English-language paper on their combination use in Asians [25] being found), no formal process of evaluating the published clinical evidence could be conducted. The process used to develop the consensus statements presented here has been described [12].



**Fig. 1** Effects of combination treatment in **a** younger and **b** older Asian patients. **a** A 38-year-old Asian woman with a retruded supraorbital rim, low radix and nasal dorsum, retruded medial malar, recessed nasal spine, and hyperactive mentalis muscle, before treatment (*left panels*). An esthetically improved facial appearance (*right panels*) was achieved after dermal fillers were used to augment the supraorbital rim, the nasal dorsum, nasal spine, columella, and the medial cheek, and botulinum toxin and HA fillers were used to improve chin projection and relax the hyperactive mentalis muscle as follows: BOTOX® (Allergan, Inc.), 16 U to mentalis; Juvéderm® Voluma™ (Allergan, Inc.), 1.5 ml to both medial cheeks, 1.2 ml to the nose, 1.2 ml to the chin; Juvéderm® Ultra Plus (Allergan, Inc.), 0.4 ml to supraorbital rim. (Photos courtesy of Dr. Steven Liew). **b** A 65-year-old Asian woman showing pan-facial aging, particularly

tissue deflation and volume loss in the temple and periorcular region, the perioral region, and the rest of the lower face, before treatment (*left panels*). A significant improvement in appearance and youthfulness was achieved following combination therapy (*right panels*), in which botulinum toxin was used in the upper face to reshape her eyebrows; and HA filler was used to volumize and restructure the temple, the tear trough, lateral cheek, nasolabial fold, perioral region, jawline, and chin as follows: BOTOX®, 24 U in the upper face, 6 U in the mentalis, 30 U in the jawline and platysma; Juvéderm® Voluma™, 1.2 ml in temples, 1 ml in both cheeks, 0.8 ml in pre-auricular area, 1 ml in marionette lines and jowls; Juvéderm® Volift™ (Allergan, Inc.), 1 ml in supraorbital rims, 1.6 ml in lips, 0.4 ml in nasolabial folds; Juvéderm® Volbella™ (Allergan, Inc.), 1 ml in both tear troughs (Photos courtesy of Dr. Peter Peng)

This article does not contain any studies with human participants or animals performed by any of the authors.

## Results: Current Practice and Consensus Opinions

The following content reflects the proceedings of the Asian Facial Aesthetics Expert Consensus Group meeting. The consensus statements presented here were agreed by all the Expert Group members.

### Aims of Treatment in Asians

The aims of facial esthetic treatment in Asians are to achieve clear, youthful, and fair skin; an oval facial shape

with smooth facial contours; large expressive eyes with clearly defined palpebral creases; and an esthetically pleasing, structural definition of the nose, chin, eyebrows, and cheeks [12]. To achieve the ideal oval in Asian patients, treatments to narrow and lengthen the lower face may be required. This often involves reducing the bulk of the masseter muscle mass with botulinum toxin, and the use of HA fillers to project and lengthen the chin. Anterior projection of the forehead, brows, and midface (medial cheeks and nose) is a common goal, although the importance of this three-dimensional projection to the overall esthetic outcome may be under-recognized by the patient.

As the average Asian face presents specific esthetic challenges such as a square boxy face shape with lack of

**Table 1** Members of the Asian Facial Aesthetics Expert Consensus Group

| Member                      | Specialty          | Practice                    | Years of experience in esthetic practice | Country     |
|-----------------------------|--------------------|-----------------------------|--|-------------|
| Dr. Greg Goodman            | Dermatologist      | Private                     | 30                                       | Australia   |
| Dr. Woffles Wu              | Plastic surgeon    | Private                     | 25                                       | Singapore   |
| Dr. Hee Jin Kim             | Anatomist          | Public/university           | 23                                       | Korea       |
| Dr. Nantapat Supapannachart | Dermatologist      | Public/university hospital  | 20                                       | Thailand    |
| Dr. Hideaki Sato            | Plastic surgeon    | Public/university hospital  | 20                                       | Japan       |
| Dr. Taro Kono               | Plastic surgeon    | Public/university hospital  | 20                                       | Japan       |
| Dr. Nobutaka Furuyama       | Plastic surgeon    | Private/university hospital | 20                                       | Japan       |
| Dr. Henry Chan              | Dermatologist      | Private/university hospital | 19                                       | Hong Kong   |
| Dr. Wilson Ho               | Plastic surgeon    | Private/university hospital | 16                                       | Hong Kong   |
| Dr. Jonathan Yu             | Dermatologist      | Private                     | 16                                       | Philippines |
| Dr. Danru Wang              | Plastic surgeon    | Public/university hospital  | 16                                       | China       |
| Dr. Steven Liew             | Plastic surgeon    | Private                     | 15                                       | Australia   |
| Dr. Hong Ki Lee             | Plastic surgeon    | Private                     | 15                                       | Korea       |
| Dr. Hsien-Li Peter Peng     | Dermatologist      | Private                     | 15                                       | Taiwan      |
| Dr. Yan Wu                  | Dermatologist      | Public/university hospital  | 13                                       | China       |
| Dr. Rashmi Shetty           | Esthetic physician | Private                     | 13                                       | India       |
| Dr. Chytra Anand            | Dermatologist      | Private                     | 13                                       | India       |
| Dr. Vandana Chatrath        | Dermatologist      | Private                     | 12                                       | India       |
| Dr. Akiko Imaizumi          | Dermatologist      | Private                     | 12                                       | Japan       |
| Dr. Marisa Pongprutthipan   | Dermatologist      | Public/university hospital  | 10                                       | Thailand    |
| Dr. Adri Prasetyo           | Dermatologist      | Private                     | 7  | Indonesia   |

vertical height, lack of anterior projection, a flat broad nose, eyebags with prominent infraorbital hollows, retrusive maxilla and chin, deep nasolabial folds, and an obtuse cervicomenal angle, it is seldom possible to confine treatment to a specific site. Augmenting the nose with an HA filler automatically places emphasis on the adequacy of chin projection, infraorbital volume, and malar projection, all of which combine to give the face a more esthetic three-dimensionality. At the same time, botulinum toxins may be required to shape the eyebrows, relax mentalis strain, and reduce the volume of hypertrophic masseter muscles, which in turn narrows the width of the lower face and triangulates it [8, 9].

Modern treatment plans thus require attention to surface, volume, and movement in all facial areas. When treating aging patients, the focus of treatment should involve the whole face, rather than merely certain aspects, because treatment of just one feature will affect the overall balance and proportions of the face. To maintain balance and harmony, treatment of different areas of the face must be addressed in a logical sequential fashion, and a global approach can often provide optimal results [4].

It became apparent during this consensus meeting that the significant change in esthetic.

Asian facial concepts and trends over the past four decades have been the realization that Asian patients do not

want to look Western. Asian patients aspire to look more beautiful or attractive within their own ethnic esthetic boundaries. Some may desire a Pan-Asian (Eurasian) look, but none wished to look ‘Western,’ in contrast to a common misperception held by many Western doctors. These patients wish to look like good-looking Asians, rather than good-looking Caucasians [8].

#### Consensus Statements on Aims of Treatment in Asians

- The aims of esthetic facial treatment in Asians are clear, youthful, fair skin and a smooth, oval facial shape with adequately projected midline features.
- Increasing anterior projection of the midface/forehead and vertical lengthening of facial height are key components of achieving esthetic balance.
- Narrowing the lower face is the key to achieving the ideal oval face shape.
- A full-face approach is required to achieve a balanced, harmonious, more three-dimensional facial appearance.
- Full-face facial enhancement using botulinum toxin and HA fillers is aimed at achieving maximal beauty while maintaining the unique Asian appearance.
- Asian patients do not wish to look ‘Western.’



## Current Practice for Nonsurgical Facial Esthetic Treatment in Asians

The results of the surveys taken by the Expert Group are presented in Tables 2, 3, 4, 5, 6, 7, and 8. The ranges of values listed in Tables 3, 4, 5, 6, 7, and 8 include the responses regarding Asian patients that were given by the experts from China, Hong Kong, Indonesia, Japan, Korea, the Philippines, Singapore, Taiwan, Thailand, and Australia. When stating the range of botulinum toxin units they used, the experts were asked to cite onabotulinum toxin A (Botox®; Allergan) units for the sake of uniformity and consistency. To provide guidance regarding the most common responses where practices differed (e.g., between countries), smaller ranges that reflect the majority of the participants' responses are shown where applicable.

### Most Common Treatments According to Patient Age

The experts' responses regarding the most commonly used nonsurgical facial treatments in their Asian patients are shown in Fig. 2 and Table 2. The survey revealed that lasers/intense pulsed light are the most common treatments used in Asian women younger than 40 years, most likely because improvement of skin tone, color, texture, and clarity is universally desirable. Skin treatments are not described further because they are beyond the scope of this manuscript. The survey also showed that the use of botulinum toxin and fillers, alone and in combination, is very common in Asians (Fig. 2). Patterns of use vary among patients of different ages, according to the changes that result from facial aging and volume depletion, with combination use of botulinum toxin and fillers increasing as patients age. In young Asian patients wanting to increase

their attractiveness, treatment invariably involves increasing the vertical height and anterior projection of the face with fillers, and reducing lower facial width with botulinum toxin. Older patients request facial rejuvenation procedures to address age-related changes that are compounded by anatomical structural deficiencies [12].

### Treatment Areas, Indications, and Dosage

#### Upper Face

Being asked which are the most common types of dynamic lines observed in the upper face of their Asian patients, 69 % (11/16) of the experts responded that it is the crow's feet indication that is most commonly treated, while 31 % (5/16) mentioned glabella lines. The treatment used by these experts to address upper facial lines is summarized in Table 3.

Botulinum toxin doses used by this group of experts to treat horizontal lines on the forehead are generally lower than those used in Caucasians [26, 27] and in guidelines published by the Korean Academy of Corrective Dermatology [1]. Suggested reasons were as follows: Asians prefer a more natural-looking appearance (i.e., preservation of facial expression) for the forehead and often have fewer wrinkles in the upper face compared with age-matched Caucasians [28]. There is less use of muscles in facial expression and communication in the forehead area in Asians, compared with Caucasians [29]. Finally, Asians tend to have the appearance of "puffy" eyelids, and any inadvertent eyebrow ptosis and heaviness of the brow will exacerbate eyelid heaviness. Overtreatment and isolated treatment of the frontalis (without co-treatment of the glabella) is to be avoided. The dosage used in the forehead varies according to the reason for treatment (e.g., to

**Table 2** Summary of the most commonly used noninvasive esthetic treatments in Asian facial esthetics patients according to age

| Priority | Patient's age   |   |   |   |
|----------|---|---|---|---|
|          | 18–30 years   | 31–40 years                                   | 41–55 years                                   | >55 years                                     |
| 1        | Laser/IPL   | Laser/IPL/botulinum toxin for facial lines    | Botulinum toxin for facial lines              | Combination of botulinum toxin and HA fillers |
| 2        | Botulinum toxin for issues other than facial lines <sup>a</sup> | Combination of botulinum toxin and HA fillers | Combination of botulinum toxin and HA fillers | HA fillers                                    |
| 3        | Botulinum toxin for facial lines/HA fillers                     | HA fillers                                    | HA fillers/laser/IPL                          | Laser/IPL/botulinum toxin for facial lines    |

Based on results of a pre-meeting survey of the Asian Facial Aesthetics Expert Consensus Group

This table shows that younger Asian patients are more concerned about the color and texture of their skin as evidenced by their prioritization of lasers and IPL as their first choice of cosmetic treatments. In the 18–30-year age group, botulinum toxin was used mainly for reducing masseteric bulk, while HA fillers were used mainly for correcting structural deficiencies such as a low nasal bridge or retrusive chin. In the above 55-year age group, this sequence of priorities was reversed

HA hyaluronic acid, IPL intense pulsed light

<sup>a</sup> For example, masseter hypertrophy, mentalis hyperactivity

**Table 3** Current practice regarding injectable treatments to address upper face lines and folds in Asians

|   | Glabella                                    |  | Forehead  | Crow's feet  |
|---|---|--|---|--|
| <b>Dynamic lines</b>  |   |  |   |  |
| Botulinum toxin dosage <sup>a</sup>   | Dose<br>12–20 U<br>(88 %<br>use<br>15–20 U) | Injection points<br>3–10 points to address frowning<br>(for the purpose of movement<br>only, not brow shaping) 88 %<br>use ≥5 injection points | Dose<br>5–12 U (depends on the<br>number of injection points<br>and the dose used at each<br>point, e.g., 1–4 U per<br>point) | Dose (per side)<br>6–12 U (depends on the<br>number of injection points<br>and the dose used at each<br>point, e.g., 1–4 U per<br>point) |
| <b>Static lines</b>   |   |  |   |  |
| Percentage of Expert Group using a combination of botulinum toxin and HA fillers, or botulinum toxin only | Combination (100 %)                         |  | 95 % use combination<br>5 % use botulinum toxin only  | Botulinum toxin only<br>(100 %)  |

Based on Expert Consensus Group Meeting survey outcomes

In the glabella region, 88 % of injectors use five or more injection points to reduce frowning as well as shape the brow. All injectors use a combination of botulinum toxin and fillers here. In contrast, crow's feet were only treated with botulinum toxin using a range of 6–12 U per side HA hyaluronic acid

<sup>a</sup> Onabotulinum toxin A units were specified for the sake of uniformity

**Table 4** Proportion of Asian patients treated for volume deficit in the upper face and volumizing treatment used

|  | Forehead                               | Glabella                                       | Eyebrow (filling of lateral and superior orbital rim) | Temple                                 |
|--|--|--|---|--|
| Percentage of patients <sup>a</sup>  | <5–20 % (88 %<br>responded<br><5–10 %) | <5–20 % (ranges<br>were widely<br>distributed) | 5–20 % (88 %<br>responded<br><5–10 %)                 | 10–35 % (60 %<br>responded<br>20–30 %) |
| Percentage of Expert Group using a combination of botulinum toxin and HA fillers, or HA fillers only | 88 % combination                       | 100 % combination                              | 81 % combination                                      | 100 % HA fillers only                  |

Based on Expert Consensus Group Meeting survey outcomes. Injection technique and dosage of fillers were not discussed because this depends on the product used. Upper eyelids were not included because volumizing treatment of this area is uncommon

Volumization of the glabellar and forehead regions and the lateral and superior orbital rims was largely performed in combination with botulinum toxins to decrease associated wrinkles, whereas in the temples these are treated with fillers only

HA hyaluronic acid

<sup>a</sup> Percentage of Expert Group members' injectable facial esthetics patients

address lines in the forehead, elevate the lateral brow, or smoothen the forehead texture). The experts agreed that this relatively lower dosage in the forehead and the resulting shorter duration of effect are acceptable to their patients. To ensure a more natural appearance, patients accept that they must return for treatment more frequently.

The general consensus regarding the number of glabella injection points was at least five points, depending on the clinical presentation at the time of injection. The majority of experts (88 %) use 15–20 U onabotulinum toxin A in total. This is similar to, or slightly lower than, consensus recommendations of 5–30 U in Caucasian women [26, 27]. A lower dose in the glabella reduces the risk of splayed eyebrows, avoids medial brow ptosis, achieves a more

natural-looking result, and preserves more normal movement of the muscles. The number of injection points for crow's feet lines was not specified because of the wide range of techniques and the wide range of botulinum toxin dosage used.

The proportion of Asian patients who are treated for volume deficit in the upper face, and the treatment types used by these experts, is shown in Table 4. Volumization and contouring of the upper third of the face in Asians has been a well-established indication over the past 5 years among the members of the Expert Group, in contrast to the West, where facial volumization with HA fillers has only more recently gained popularity [20].

Most Asians prefer a smooth forehead and glabella, and full temples without hollows. In Korea, younger women are

**Table 5** Proportion of Asian patients treated for middle face lines or reshaping, and botulinum toxin dose used

| Bunny lines                                  |   | Dynamic lines under eyelid                  |                         | Nasal shape                                  |   | Gummy smile                 |   |
|--|---|---|-------------------------|--|---|-----------------------------|---|
| % patients <sup>a</sup>                      | Total dose <sup>b</sup>                     | % patients <sup>a</sup>                     | Total dose <sup>b</sup> | % patients <sup>a</sup>                      | Total dose <sup>b</sup>                   | % patients <sup>a</sup>     | Total dose <sup>b</sup>   |
| <10–50 %<br>(ranges were widely distributed) | 2–10 U (94 % use ranges that include 4–6 U) | 20–40 %<br>(ranges were widely distributed) | 4–12 U (88 % use 4–6 U) | 0–25 % <sup>c</sup><br>(88 % responded ≤5 %) | Lift nasal tip: 2–4 U Alar (flare): 2–8 U | <10 %<br>(81 % stated ≤5 %) | 2–12 U, depending on severity (69 % use 4 U or a range that includes 4 U) |

Based on Expert Consensus Group Meeting survey outcomes

Dynamic lines under the eyes and bunny lines were the most frequently treated areas in the midface, with dosages ranging from 4 to 6 U for both sides. Treatment of the nose with onabotulinum toxin, either to reduce alar flare or raise the tip by decreasing the action of the depressor muscles, was performed only by some experts

<sup>a</sup> Percentage of Expert Group members' injectable facial esthetics patients

<sup>b</sup> Onabotulinum toxin A units were specified for the sake of uniformity

<sup>c</sup> To lift the tip or to address alar flare, several experts only treat either flare or tip, but not both

**Table 6** Proportion of Asian patients treated for volume deficit in the middle third of the face

| Age group  | Location/indication                         |   |   |   |   |                                  |   |
|--|---|---|---|---|---|----------------------------------|---|
|  | Cheek complex                               |   |   | Tear trough/<br>lower orbital<br>rim        | Nasolabial fold                             | Nose (any<br>aspect)             | Alar base/<br>pyriform<br>margin        |
|  | Medial cheek                                | Lateral cheek                               | Subzygomatic<br>hollow                      |   |   |                                  |   |
| Percentage of patients aged <30 years <sup>a</sup> | <5–40 %<br>(ranges were widely distributed) | 0–20 % (75 % responded 0–10 %)              | 0–15 % (75 % responded 0–5 %)               | 0–50 % (75 % responded 0–30 %)              | 0–30 % (69 % responded 0–15 %)              | 10–60 % (88 % responded 20–40 %) | <5–40 % (94 % responded 5–20 %)         |
| Percentage of patients aged >55 years <sup>a</sup> | 10–60 % (81 % responded 30–50 %)            | <5–40 %<br>(ranges were widely distributed) | 10–50 %<br>(ranges were widely distributed) | 15–50 %<br>(ranges were widely distributed) | <5–70 %<br>(ranges were widely distributed) | <5–45 % (88 % responded 5–20 %)  | 5–60 % (ranges were widely distributed) |

Based on Expert Consensus Group Meeting survey outcomes

The most frequently filled areas in the under 30-year age group were the nose, tear trough, and medial cheek areas. In the over 55-year age group, the most frequently filled areas were the nasolabial fold, the medial cheek followed by the tear trough, and subzygomatic hollows

<sup>a</sup> Percentage of Expert Group members' injectable facial esthetics patients

more commonly treated to create a smooth, convex forehead than those in other parts of Asia. Glabella volumization is common in elderly East Asians (Chinese, Japanese, Koreans). Age-related volume loss compounds the effect of a flat, retruded frontal bone, which creates an obvious flattening of the glabella that is considered undesirable by many Asian women. Most experts agreed that there is a need for more volumization and shaping of the upper face for many of the Asian patients who request facial esthetic treatment. The forehead, temple, and glabella are the most commonly volumized areas. For volumization of the forehead and glabella, botulinum toxin is used in combination with fillers to minimize activity of the glabella and frontalis, and facilitate the integration of the filler into the tissue. The Expert Group highlighted that injecting the glabella is associated with a risk of vascular complications and should remain the domain of advanced practitioners.

Using fillers on the superior orbital rim improves the forward projection of the supraorbital ridge and reduces the appearance of “puffy” eyes. Although patients seldom request this treatment, these experts recommend it to achieve this outcome.

### Consensus Statements on Upper Face Treatment

- In Asia, most patients prefer a natural look, with a smooth forehead that retains the ability to show facial expression.
- The relatively lower botulinum toxin dosages used in the forehead, and the associated potential shorter duration of effect, are acceptable to Asian patients.
- Upper face volumization is common among Asian patients, to achieve optimal smoothness and anterior projection of the forehead and upper face.

**Table 7** Proportion of Asian patients treated for lines and folds of the lower face, and treatment used

| Variable  | Location/indication                                 |   |  |  |   |  |
|---|---|---|--|--|---|--|
|   | Perioral lines                                      | Mentalis                                      | Depressor anguli oris                                  | Masseter   | Platysma and/or neck lines                    | Intradermal botulinum toxin                    |
| <b>Dynamic lines</b>  |   |   |  |  |   |  |
| Percentage of patients <sup>a</sup>   | <5–30 %<br>(81 % responded<br>≤10 %)                | 5–60 %<br>(ranges were<br>widely distributed) | <5–40 %<br>(ranges were<br>widely distributed)         | 10–50 % (ranges<br>were widely<br>distributed)             | 5–60 %<br>(ranges were<br>widely distributed) | 0–40 %<br>(75 % responded<br>0–10 %)           |
| Botulinum toxin <sup>b</sup> dosage   | 2–8 U (75 %<br>use a range that<br>included<br>4 U) | 2–20 U<br>(56 % use<br>4–8 U)                 | 2–8 U (74 %<br>said a range<br>that included<br>4–6 U) | 20–100 U (81 %<br>use a range that<br>included<br>40–80 U) | 10–80 U<br>(69 % use<br>10–30 U)              | 10–50 U<br>(ranges were<br>widely distributed) |
| <b>Static lines</b>   |   |   |  |  |   |  |
| Percentage of Expert Group using combination treatment (C) or botulinum toxin (B) or HA fillers (F) alone | 69 % C<br>25 % B<br>6 % F                           | 69 % B<br>31 % C                              | 60 % B<br>40 % C                                       | 100 % B  | 87 % B<br>13 % C                              | 100 % B  |

Based on Expert Consensus Group Meeting survey outcomes

The mentalis and the platysma were the most frequently treated areas with botulinum toxin; the mentalis usually in combination with an HA filler. Reduction of masseteric hypertrophy was the third most frequently treated area of the lower face with botulinum toxin, with a range of 40–80 U used for both sides

<sup>a</sup> Percentage of Expert Group members' injectable facial esthetics patients

<sup>b</sup> Onabotulinum toxin A units were specified for the sake of uniformity

**Table 8** Proportion of Asian patients treated for volume/structural deficits in the lower face, and the type of treatment used

| Variable   | Location/indication           |   |                                |                               |
|--|-------------------------------|---|--------------------------------|-------------------------------|
|  | Lips                          | Marionette/pre-jowl sulcus                  | Chin                           | Jawline                       |
| Percentage of patients <sup>a</sup>  | 5–30 % (81 %<br>said 10–20 %) | 10–50 % (ranges were<br>widely distributed) | 10–60 % (88 %<br>said 20–40 %) | 5–40 % (81 %<br>said 10–30 %) |
| HA fillers (F) only or combination (C) treatment with botulinum toxin and HA fillers | 63 % F<br>37 % C              | 81 % C<br>16 % F                            | 100 % C                        | 75 % C<br>25 % F              |

Based on Expert Consensus Group Meeting survey outcomes

All experts responded that the chin was always treated with a combination of HA filler and botulinum toxin in order to achieve better chin projection and elongation free of any signs of mentalis strain

HA hyaluronic acid

<sup>a</sup> Percentage of Expert Group members' injectable facial esthetics patients

- In general, younger women want a smooth forehead, whereas older women want a smooth, contoured forehead without temporal hollows.

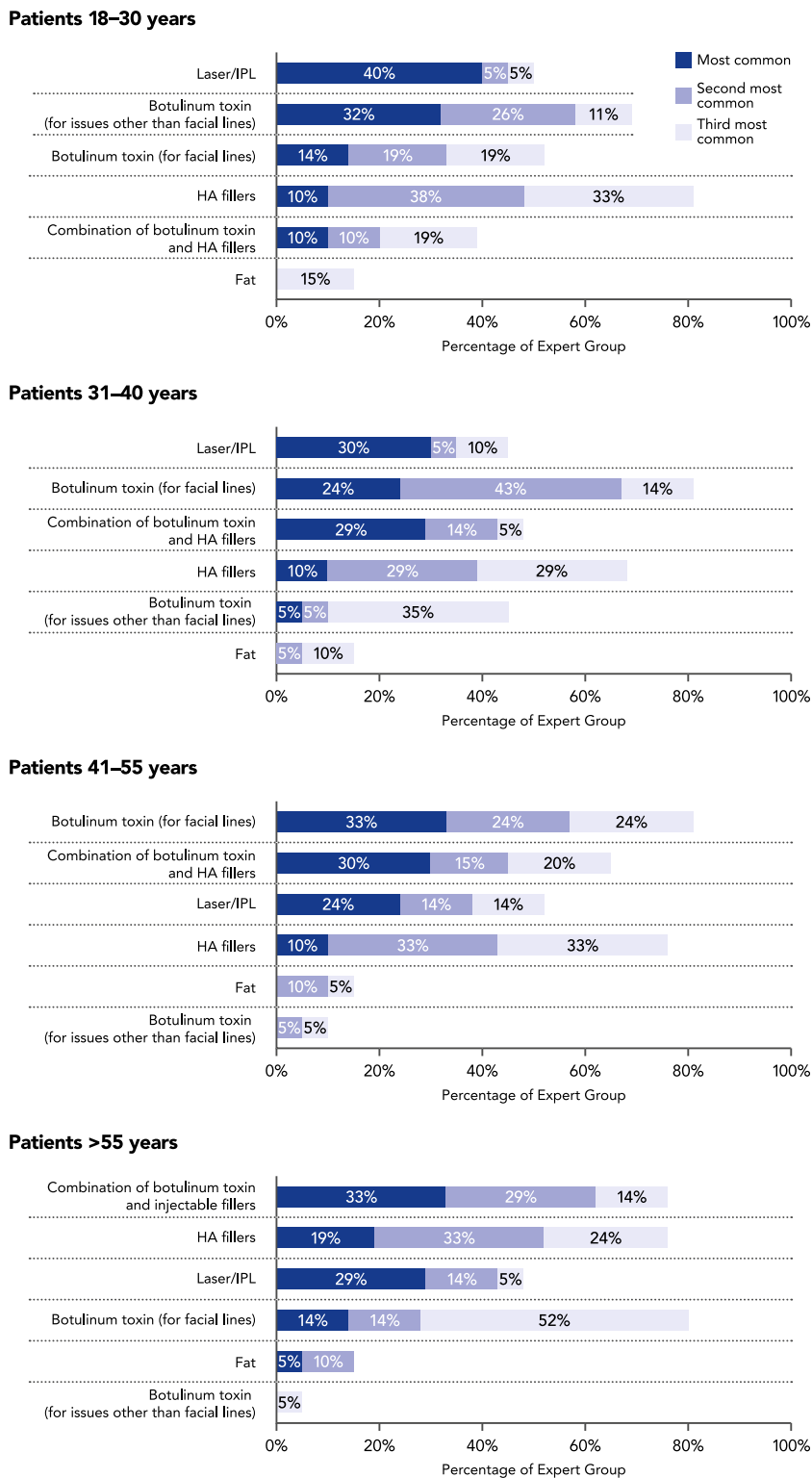
### Middle Face

The use of botulinum toxin to address dynamic lines in the middle face, nasal shape, and gummy smile, and the proportion of Asian esthetic patients treated for each indication, is summarized in Table 5. Dynamic lines under the eye can

result from muscle activity (facial expression) and/or volume deficiency (inadequate structural support for skin and tissue). The proportion of patients seeking treatment to address infraorbital and bunny lines is relatively high in some countries, although Asians are less prone to photoaging (those younger than 60 years generally have fewer facial wrinkles than age-matched Caucasians [28, 30, 31]). Any lines that become more noticeable are a concern for Asians. The proportion of patients seeking treatment may also reflect a lower tolerance of expression lines by Asians than Caucasians.



**Fig. 2** Nonsurgical treatments most commonly used by the Expert Group for their Asian facial esthetics patients, according to patient age. Based on results of a pre-meeting survey of the Asian Facial Aesthetics Expert Consensus Group. HA hyaluronic acid, IPL intense pulsed light



With its lack of dorsal height, poor tip support, and wide nasal alar base, the Asian nose can often be treated with HA fillers and botulinum toxin rather than surgery [25, 32].

Gummy smile can be caused by bony structural, dental, or gingival factors, or muscle hyperactivity, all of which may occur alone or in combination [33]. Bimaxillary protrusion

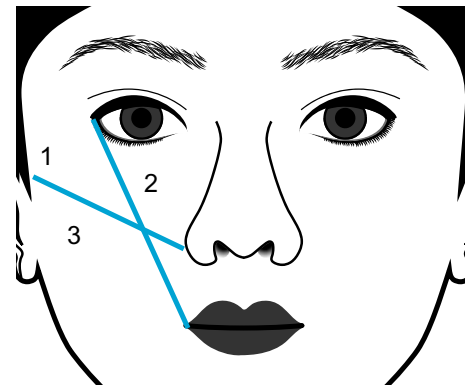
is a typical anatomical feature in Asians, which may also explain the common need to treat gummy smile and to relieve mentalis strain.

The proportion of Asian patients who are treated with HA fillers for volume deficit in the midface is shown in Table 5. Figure 3 shows the subregions treated for malar volumization described in Table 6. In Asian patients, HA fillers are most frequently used in the middle third of the face. Infraorbital and mid-cheek volume loss are very common and may occur as early as the second decade in Asians, giving the impression of tiredness. The desire to address the perceived undesirable facial features that correlate with underlying characteristic anatomical structures [12] accounts for the relatively high proportion of young patients seeking treatment to volumize the cheek area and alar base, and to address nasal shape. It is important to note that HA fillers are preferentially placed in the medial cheek, and rarely in the lateral part, which could cause widening of an already wide Asian midface. This is in contrast to treatment of Caucasians, where HA fillers are placed laterally to create cheekbones and widen the face.

In Asians, the resulting increased anterior projection of the medial cheek and other midline structures provides a visual narrowing effect, which is a more desirable esthetic outcome. The greater proportion of older patients who receive volumization treatment (Table 6) reflects increasing midface volume loss with aging, which is compounded by the aforementioned structural deficiencies. The use of HA fillers to treat nasolabial folds in Chinese and Korean patients has been described elsewhere [13, 34]. Among these experts, the common approach is first to address the midface, with subsequent treatment directed at the nasolabial folds, should it be necessary.

### Consensus Statements on Midface Treatment

- Because Asians are less prone to photoaging [28, 30, 31], they generally have fewer wrinkles than age-matched Caucasians. Hence, fine lines such as bunny lines and dynamic lines under the eye become a concern and lead to requests for treatment among Asians.
- In younger Asian patients, the main treatment requirements are structural support for an underdeveloped medial cheek, and optimization of nasal shape and chin contour; the medial cheek is the most common area for volumization.
- In older Asian patients, the main focus of treatment is to restore volume of the midfacial areas associated with age-related volume loss.



**Fig. 3** Locations of midface malar volumization. 1 Lateral cheek; 2 medial cheek; 3 subzygomatic hollow

### Lower Face

The proportion of Asian patients who receive injectable treatment for lines and folds of the lower face, and the treatments used, is shown in Table 7. Treatment for perioral wrinkles is less common in Asia than in Western countries [1]. The botulinum toxin dosage used by most of these experts to address perioral lines and the depressor anguli is similar to the dosing recommendations for Caucasians (4–6 and 2–15 U, respectively), but is lower for platysmal bands, being 10–30 U by most experts (30–60 U are recommended in Caucasians) [27]. A hyperactive mentalis associated with retro- and microgenia is very common in Asians, and treatment requires a similar dosage to the 4–10 U recommended for Caucasians [27].

The use of botulinum toxin to reduce masseter width is well established in Asia as the most effective nonsurgical shaping and facial slimming tool [1, 3, 5, 6, 35, 36]. Asian women regard a square jaw as esthetically displeasing, and masseter reduction treatment is common in patients aged 18–30 years. In older patients, due to age-related facial volume loss and loss of skin elasticity, reducing the masseter volume can lead to worsening facial appearance, with hollowness and jowl formation. Therefore, treating their masseters becomes less of a priority.

The use of intradermal botulinum toxin or Microbotox [10, 11] is growing, as evidenced by the wide variation in the proportions of patients given this treatment between Asian countries where the treatment concept is still relatively new (China, Philippines, Thailand) versus those in which it has been used for many years (Singapore, Korea, Japan, Taiwan). Microbotox is the injection of multiple microdroplets of diluted onabotulinumtoxinA into the dermis of the skin or the interface between the dermis and the superficial layer of facial muscles that are attached to its undersurface [10, 11]. A reduction of sweat and sebaceous gland activity gives a smooth, lustrous texture to the

skin, while the reduction of superficial facial muscle activity leads to a marked reduction of surface wrinkling. As the microdroplets are too small to diffuse into the deeper muscle, muscle function is retained, which gives a more natural, less frozen result. It is extremely useful in the forehead, where horizontal rhytides can be reduced without compromising eyebrow elevation and movement. It is also used to treat the glabellar and crow's feet regions, as well as the lower face and neck (platysma). Less botulinum toxin is used with the Microbotox technique than with standard botulinum toxin injections. Typically, 20–28 U (0.5–0.7 ml of a 100 U botulinum toxin vial diluted with 2.5 ml saline) is drawn into a 1-ml syringe and topped up with 0.5–0.3 ml of 0.5 % lidocaine, to make a total volume of 1 ml of solution. To treat the entire forehead, 7-point glabellar and 8-point crow's feet areas, and 1 ml of solution containing 20 U of botulinum toxin are sufficient. In the lower face and neck, 1 ml of solution containing 28 U is used per side (total of 56 U) to reduce superficial platysma activity and achieve better cervicomental and jawline contouring. The results of a Microbotox treatment can last for 3–4 months.

The proportion of Asian patients treated for volume or structural deficits in the lower face, and the types of treatments used, is shown in Table 8. In the Asian lower face, HA fillers are most commonly used in the chin (vs. the lips in Caucasians) [22]. Chin hypoplasia and mentalis hyperactivity are best treated with a combination of botulinum toxin and fillers [1]. Asians tend to have full lips; the top lip may be thicker than the lower lip. The moderate proportion of patients who request HA fillers in their lips do so, not to increase their volume, but rather to create better shape and esthetic balance. The Expert Group agreed that the “golden ratio” Phi (1:1.618) [37] is not applicable to the size and proportion of the upper and lower Asian lips. In Asians, while lips where the lower lip is larger than the upper by 1:1.618 are considered beautiful, not all Asian patients desire this relationship. Quite often Asians naturally have a larger upper lip in proportion to the lower lip and this helps offset an element of maxillary retrusion which is often seen in the Asian face. As such, most Asian patients prefer to have uniform enhancement of their lips and retain a relationship of upper to lower lip that may be the reverse of what is considered ideal in the Caucasian face.

### Consensus Statements for Lower Face Treatment

- A wide, square lower face is considered esthetically undesirable among Asian women, as reflected in the common request for treatment to reduce masseter muscle bulk.

- Chin retrusion is a common feature of the Asian face, which in turn leads to the high incidence of mentalis strain and hyperactivity of the mentalis muscle. This is reflected in the relatively high proportion of patients who are treated in the chin area with a combination of botulinum toxin and fillers.

### Conclusions

The use of nonsurgical esthetic facial treatments is increasing in Asia [38]. Surveys of current practice among this Expert Group showed that the types of treatment requested and provided correlate with anatomical structural deficiencies observed in the Asian face, as well as age-related changes, and they vary as patients age. Botulinum toxin and HA fillers are often used in combination. To achieve the desired esthetic outcome in younger Asian patients, addressing proportion is key. In older patients, maintaining facial structure and volume, in addition to addressing lines and folds, is essential to reducing the appearance of aging.

The desire for esthetic improvement, together with the complexity of the structural deficits and aging processes in the Asian face, often require a long-term management plan that involves multiple treatment modalities. The often wide variations in treatment practice and in the proportions of patients treated for particular indications (Tables 2, 3, 4, 5, 6, 7) are a reflection of different patient demographics, ethnicities, and “country-specific” popular desires; cultural differences; and varying injecting practices in the region, along with differences in perceptions of beauty that vary even among experts. In addition to a thorough understanding of the characteristic anatomy and morphology of the Asian face, a full-face approach and combination treatment strategies involving energy-based devices, botulinum toxin, and HA fillers are often required to address the complexity of many Asian patients' esthetic concerns.

**Acknowledgments** The consensus meeting was funded by an unrestricted educational grant from Allergan, but the authors are solely responsible for the contents of this article. Assistance with administration of the survey, survey data analysis, and editorial preparation of the manuscript was provided by Samantha Santangelo, Ph.D., of MediTech Media Asia Pacific.

**Disclosure** Dr. Wu sits on advisory boards for Allergan, Galderma, and Merz, and has received honoraria from these companies for attending board meetings and delivering local and international workshops and lectures. Dr. Liew sits on advisory boards for Allergan, Galderma, and Kythera, and has received honoraria from Allergan and Galderma for delivering local and international workshops and lectures. Dr. Chan has received financial support for travel on behalf of Allergan. Dr. Ho is a consultant for Allergan. Dr. Supannachart has no financial conflicts of interest to declare. Dr.

Lee sits on advisory boards for Allergan. Dr. Prasetyo is a consultant and sits on advisory boards for Allergan and Merz, and has also received from them grants, honoraria, and travel support for giving lectures. Dr. Yu sits on an advisory board of Allergan, Philippines, and has received payment from Allergan for conducting workshops for local and international activities; he has also received support from Allergan and Merz for travel to meetings and has previously received honoraria from Galderma, Ipsen, Teoxane, and Merz. Dr. Rogers was an employee of Allergan at the time of manuscript preparation. The consensus meeting was funded by an unrestricted educational grant from Allergan.

**Open Access** This article is distributed under the terms of the Creative Commons Attribution 4.0 International License (<http://creativecommons.org/licenses/by/4.0/>), which permits unrestricted use, distribution, and reproduction in any medium, provided you give appropriate credit to the original author(s) and the source, provide a link to the Creative Commons license, and indicate if changes were made.

## Appendix

The Asian Facial Aesthetics Expert Consensus Group also includes Drs. Danru Wang, China; Yan Wu, China; Rashmi Shetty, India; Vandana Chatrath, India; Chytra Anand, India; Akiko Imaizumi, Japan; Nobutaka Furuyama, Japan; Hideaki Sato, Japan; Greg J. Goodman, Australia; Peter H. L. Peng, Taiwan; and Marisa Pongprutthipan, Thailand.

## References

- Ahn BK, Kim YS, Kim HJ, Rho NK, Kim HS (2013) Consensus recommendations on the aesthetic usage of botulinum toxin type A in Asians. *Dermatol Surg* 39:1843–1860
- Ahn J, Horn C, Blitzer A (2004) Botulinum toxin for masseter reduction in Asian patients. *Arch Facial Plast Surg* 6:188–191
- Wu WT (2010) Botox facial slimming/facial sculpting: the role of botulinum toxin-A in the treatment of hypertrophic masseteric muscle and parotid enlargement to narrow the lower facial width. *Facial Plast Surg Clin N Am* 18:133–140
- Wu WTL (2007) Non surgical facial rejuvenation with the 4R principle: innovative uses of BOTOX and the Woffles lift. In: Panfilov D (ed) *Aesthetic surgery of the facial mosaic*. Springer, Berlin, pp 636–649
- Yu CC, Chen PK, Chen YR (2007) Botulinum toxin A for lower facial contouring: a prospective study. *Aesthetic Plast Surg* 31:445–451
- Park MY, Ahn KY, Jung DS (2003) Botulinum toxin type A treatment for contouring of the lower face. *Dermatol Surg* 29:477–483
- Gaofeng L, Jun T, Bo P, Bosheng Z, Qian Z, Dongping L (2010) Evaluation and selecting indications for the treatment of improving facial morphology by masseteric injection of botulinum toxin type A. *J Plast Reconstr Aesthet Surg* 63:2026–2031
- Wu WTL (2015) Botulinum toxin A injections for facial rejuvenation and reshaping. In: Chen YR, Li QF, Wu W, Park DH, Takayanagi S, Wei FC (eds) *Pu LLQ. Aesthetic plastic surgery in Asians: principles and techniques*, CRC Press, pp 149–169
- Wu WTL (2011) Facial and lower limb contouring. In: Benedetto AV (ed) *Botulinum toxins in clinical aesthetic practice*. 2nd edn. Informa Healthcare pp 206–222
- Wu WTL (2011) Skin resurfacing with Microbotox and the treatment of keloids. In: Benedetto AV (ed) *Botulinum toxins in clinical aesthetic practice*, 2nd edition. Informa Healthcare. pp 190–205
- Wu WTL (2015) Microbotox of the lower face and neck: evolution of a personal technique and its clinical effects. *Plast Reconstr Surg* 136(5 Suppl):92S–100S
- Liew S, Wu WTL, Chan HH, Ho WWS, Kim HJ, Goodman GJ, Peng PHL, Rogers JD (2015) Consensus on changing trends, attitudes, and concepts of Asian beauty. *Aesthetic Plast Surg*. doi: [10.1007/s00266-015-0562-0](https://doi.org/10.1007/s00266-015-0562-0)
- Ahn JY, Lee SH, Park KY, Hong CK, Song HJ, Park MY, Choi YS, Seo SJ (2012) Clinical comparison of two hyaluronic acid-derived fillers in the treatment of nasolabial folds: Mesoglow® and IAL System®. *Int J Dermatol* 51:601–608
- Bae JM, Lee DW (2013) Three-dimensional remodeling of young Asian women's faces using 20-mg/ml smooth, highly cohesive, viscous hyaluronic acid fillers: a retrospective study of 320 patients. *Dermatol Surg* 39:1370–1375
- Choi HS, Whipple KM, Oh SR, Priel A, Looi A, Korn BS, Kikkawa DO (2011) Modifying the upper eyelid crease in Asian patients with hyaluronic acid fillers. *Plast Reconstr Surg* 127:844–849
- Lee SK (2011) *Textbook of botulinum toxin and filler: better and safer procedures for cosmetic surgeons*. Hanmi Medical Publishing Co., Seoul
- Lee SK, Kim HS (2014) Recent trend in the choice of fillers and injection techniques in Asia: a questionnaire study based on expert opinion. *J Drugs Dermatol* 13:24–31
- Nanda S, Bansal S (2013) Upper face rejuvenation using botulinum toxin and hyaluronic acid fillers. *Indian J Dermatol Venereol Leprol* 79:32–40
- Vedamurthy M, Dermatology Task Force IADVL (2008) Standard guidelines for the use of dermal fillers. *Indian J Dermatol Venereol Leprol* 74(Suppl):S23–S27
- Raspaldo H, Gassia V, Niforos FR, Michaud T (2012) Global, 3-dimensional approach to natural rejuvenation: part 1—recommendations for volume restoration and the periorcular area. *J Cosmet Dermatol* 11:279–289
- Carruthers JD, Glogau RG, Blitzer A, Facial Aesthetics Consensus Group F (2008) Advances in facial rejuvenation: botulinum toxin type A, hyaluronic acid dermal fillers, and combination therapies—consensus recommendations. *Plast Reconstr Surg* 121:5S–30S
- Gassia V, Raspaldo H, Niforos FR, Michaud T (2013) Global 3-dimensional approach to natural rejuvenation: recommendations for perioral, nose, and ear rejuvenation. *J Cosmet Dermatol* 12:123–136
- Sadick NS, Manhas-Bhutani S, Krueger N (2013) A novel approach to structural facial volume replacement. *Aesthet Plast Surg* 37:266–276
- Yamauchi PS (2012) Soft tissue filler and botulinum toxin treatment techniques. *G Ital Dermatol Venereol* 147:29–44
- Wong GR, Chen WP (2011) Phosphatidylcholine/deoxycholate lipolysis and hyaluronic acid augmentation to enhance nonsurgical lower facial contouring using botulinum toxin type A. *J Cosmet Dermatol* 10:159–162
- Raspaldo H, Baspeyras M, Bellity P, Dallara JM, Gassia V, Niforos FR, Belhaouari L, Consensus G (2011) Upper- and mid-face anti-aging treatment and prevention using onabotulinum-toxin A: the 2010 multidisciplinary French consensus—part 1. *J Cosmet Dermatol* 10:36–50
- Carruthers A, Kane MA, Flynn TC, Huang P, Kim SD, Solish N, Kaeuper G (2013) The convergence of medicine and neurotoxins:

- a focus on botulinum toxin type A and its application in aesthetic medicine—a global, evidence-based botulinum toxin consensus education initiative: part I: botulinum toxin in clinical and cosmetic practice. *Dermatol Surg* 39:493–509
28. Nouveau-Richard S, Yang Z, Mac-Mary S, Li L, Bastien P, Tardy I, Bouillon C, Humbert P, de Lacharriere O (2005) Skin ageing: a comparison between Chinese and European populations. A pilot study. *J Dermatol Sci* 40:187–193
  29. Tzou CH, Giovanoli P, Ploner M, Frey M (2005) Are there ethnic differences of facial movements between Europeans and Asians? *Br J Plast Surg* 58:183–195
  30. Chung JH (2003) Photoaging in Asians. *Photodermatol Photomed* 19:109–121
  31. Tsukahara K, Fujimura T, Yoshida Y, Kitahara T, Hotta M, Moriwaki S, Witt PS, Simion FA, Takema Y (2004) Comparison of age-related changes in wrinkling and sagging of the skin in Caucasian females and in Japanese females. *J Cosmet Sci* 55:351–371
  32. Tanaka Y, Matsuo K, Yuzuriha S (2011) Westernization of the asian nose by augmentation of the retropositioned anterior nasal spine with an injectable filler. *Eplasty* 11:e7
  33. Hwang HS, Park MK, Lee WJ, Cho JH, Kim BK, Wilkinson CM (2012) Facial soft tissue thickness database for craniofacial reconstruction in Korean adults. *J Forensic Sci* 57:1442–1447
  34. Yan X, Xu J, Lu C, Ma Y, Li W (2009) A multicenter study of the efficacy and safety of restylane in the treatment of nasolabial folds in China. *Plast Reconstr Surg* 124:256e–257e
  35. Choe SW, Cho WI, Lee CK, Seo SJ (2005) Effects of botulinum toxin type A on contouring of the lower face. *Dermatol Surg* 31:502–507
  36. Kim HJ, Yum KW, Lee SS, Heo MS, Seo K (2003) Effects of botulinum toxin type A on bilateral masseteric hypertrophy evaluated with computed tomographic measurement. *Dermatol Surg* 29:484–489
  37. Swift A, Remington K (2011) BeautiPHication: a global approach to facial beauty. *Clin Plast Surg* 38:347–377
  38. GBI Research (2014) Facial aesthetics market to 2020. <http://www.researchmoz.us/facial-aesthetics-market-to-2020-economic-recovery-drives-growth-in-the-us-as-increasing-awareness-fuels-demand-in-developing-markets-report.html>. Accessed 8 July 2014