

## Prikaz slučaja / Case report

## Perkutano zatvaranje paravalvularnog propuštanja — prikaz prvog slučaja u Hrvatskoj

*Percutaneous closure of paravalvular leak — case report on first procedure in Croatia*

Robert Bernat\*, Aleksandar Trbović, Mladen Novkoski, Zvonimir Ante Korda

Magdalena — Klinika za kardiovaskularne bolesti Medicinskog fakulteta u Osijeku  
Krapinske Toplice, HrvatskaMagdalena — Clinic for cardiovascular diseases, Medical Faculty Osijek  
Krapinske Toplice, Croatia

**SAŽETAK:** Klinički značajna paravalvularna regurgitacija (PVL) nakon implantacije proteze valvule je rijetka, ali moguća ozbiljna komplikacija. Reoperacija je povezana sa značajnim rizicima i mogućim neuspjehom, budući da prvobitni uzrok regurgitacije nije uvijek moguće korigirati. Perkutano zatvaranje PVL uvedeno je kao važna alternativa s dokumentiranim dobrim kratkoročnim i dugoročnim rezultatima.

Prikazujemo slučaj zatvaranja PVL kod mladog bolesnika pomoću naprave Amplatzer Vascular plug III, vođenog periproceduralnom transezofagijskom ehokardiografijom. Dokumentiran je kratkoročan i srednjoročni rezultat. Obzirom na značajan broj implantacija valvularnih proteza u Hrvatskoj, tijekom godina se može očekivati porast potrebe za ovom vrstom intervencije.

**KLJUČNE RIJEČI:** implantacija valvularne proteze, paravalvularna regurgitacija, perkutano zatvaranje.

**SUMMARY:** Clinically significant paravalvular leak (PVL) after prosthetic valve implantation is a rare, but potentially serious complication. Repeat surgery is associated with significant risks and may fail, because the original cause of leak is not always amenable to correction. Percutaneous PVL closure has been introduced as an important alternative with documented good immediate and late results.

We present a case of PVL closure in a young patient using the Amplatzer Vascular plug III device, guided by periprocedural transesophageal echocardiography. Immediate success and mid-term result could be documented. In view of the significant number of prosthetic valve implantations in Croatia, an increase in the need for this type of intervention can be expected each year.

**KEYWORDS:** prosthetic valve replacement, paravalvular leak, percutaneous closure.

**CITATION:** *Cardiol Croat.* 2013;8(12):407-410.

## Uvod

Implantacija valvularne proteze jedan je od najčešćih kardio-kirurških zahvata s više od 700 implantacija koje se obave u Hrvatskoj<sup>1</sup> i više od 90.000 godišnje u Sjedinjenim Američkim Državama<sup>2</sup>. Učestalost postoperativnih paravalvularnih regurgitacija varira između 2% do 10% na aortnoj i 7% do 17% na mitralnoj poziciji<sup>3-5</sup>. Uzrok paravalvularne regurgitacije (PVL) obično je dehiscencija sutura nastala zbog infekcije, preosjetljivosti tkiva ili anularnih kalcifikacija. Većina PVL nije značajna i ostaje klinički neupadljiva, no kod 1% do 3% će postati simptomatska i zahtijevati reoperaciju<sup>6</sup>. Bolesnici s klinički značajnom PVL mogu pokazivati simptome i znakove kongestivnog zatajivanja srca, kao i hemolitičke anemije. Reoperacija predstavlja tradicionalni način liječenja ovih bolesnika, no povezana je sa značajnim rizicima i stoga se ponekad ne uzima kao moguća opcija<sup>7,8</sup>. Također i ponovni kirurški zahvat ne mora biti uspješan, jer će prvobitni anatomski problem i dalje biti prisutan. Stoga su razvijeni

## Introduction

Prosthetic valve implantation is one of the most common cardiac surgical procedures, with over 700 implantations performed in Croatia<sup>1</sup> and over 90.000 in the US annually<sup>2</sup>. The incidence of postoperative paravalvular regurgitation varies between 2% to 10% in the aortic position and 7% up to 17% in the mitral position<sup>3-5</sup>. The background for paravalvular leak (PVL) is usually dehiscence of sutures resulting from infection, tissue friability or annular calcification. Most of these leaks are not significant and remain clinically silent, however, 1% to 3% will become symptomatic and require reoperation<sup>6</sup>. Patients with clinically significant PVL may present with symptoms and signs of congestive heart failure, as well as haemolytic anaemia. Reoperation has been the traditional treatment for these patients, but it is associated with significant risks and therefore it is sometimes not considered<sup>7,8</sup>. Also, re-do surgery may not be successful because the original anatomic problem persists. Therefore, alternati-

alternativni perkutani transkateterski postupci za zatvaranje PVL koji su važna i održiva alternativa<sup>9,10</sup> s dobrim rezultatima kliničkog praćenja (koji prvenstveno ovise o stupnju preostale regurgitacije)<sup>11</sup>.

Ključni pregled u preproceduralnom planiranju je detaljna transezofagijska ehokardiografija (TEE), s 3D TEE koja je posebno važna u procjeni mitralnih PVL. Bolesnici s trenutnom infekcijom i velikom dehiscencijom koja uključuje više od 1/4 prstena valvule nisu prikladni za perkutano zatvaranje i, ako je moguće, ipak bi trebali biti kirurški liječeni.

## Prikaz slučaja

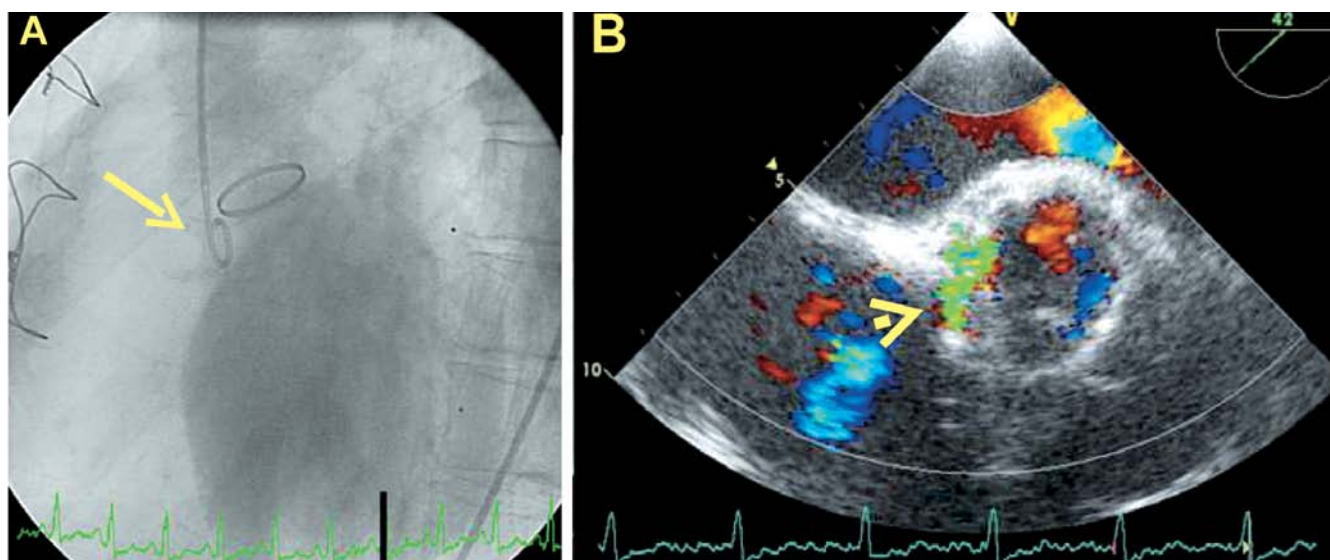
Prikazujemo slučaj 43 godišnjeg muškarca, radnika, kojemu je dijagnosticirana simptomatska ozbiljna kombinirana bolest aortne valvule (dominantna stenozna i regurgitacija 3+) radi čega je 2010. godine učinjena zamjena aortne valvule. U protokolu operacije zabilježena je nešto problematičnija ekscizija nativne valvule zbog značajne kalcifikacije u području nekoronarnog i lijevog koronarnog kuspisa. Inače je postupak protekao uredno i implantirana je proteza SJM 23 mm. Po otpustu, transtorakalna i transezofagusna ehokardiografija pokazala je umjeren 2+ PVL, a vrijednost LDH je također bila umjerenom povišena (629 IU/l). U toj fazi je sistolička funkcija lijeve klijetke bila normalna (LVEF 60%). Kasnije nije bilo nikakvih simptoma ili znakova infekcije, no ehokardiografijom je dokazano pogoršanje aortne regurgitacije s umjerenom oslabljenom funkcijom lijeve klijetke (LVEF 45%). Dvije godine kasnije, ponovljena je operacija, tijekom koje su učinjene resuture proteze. Ova operacija bila je otežana aritmogenom nestabilnošću, produljenim odbijanjem izvan-tjelesnog krvotoka i potrebom za inotropnom podrškom. Odmah nakon ovog postupka TEE i aortografija su pokazali perzistirajuću aortnu regurgitaciju teškog stupnja. Mjesto PVL je bilo između nekoronarnog i lijevog aortnog kuspisa (**Slika 1A i 1B**). Bolesnik se u potpunosti klinički oporavio, no perzistirala je aortna regurgitacija 4+ s umjerenom dilatacijom i oslabljenom sistoličkom funkcijom lijeve klijetke. Laboratorijski nalazi su pokazali vrlo značajno povećanje LDH od 1.680 IU/l.

ve percutaneous transcatheter procedures for PVL closure have been developed and emerged as an important and viable alternative<sup>9,10</sup> with good clinical follow-up results (which primarily depend on the degree of residual regurgitation)<sup>11</sup>.

The key examination in the preprocedural planning is a detailed transesophageal echocardiography (TEE), with 3D TEE being particularly important in assessment of mitral PVL. Patients with ongoing infection and large dehiscence involving more than 1/4 of the valve ring are not suitable for percutaneous closure and, if feasible, should still be surgically treated.

## Case report

We describe a case of a 43-year old male worker, who was diagnosed with symptomatic severe combined aortic valve disease (dominant stenosis and 3+ regurgitation) and underwent aortic valve replacement in 2010. In the operation protocol, a somewhat problematic excision of the native valve was noted, due to significant calcification in the area of the noncoronary and left coronary cusps. Otherwise, the procedure was uneventful and a 23 mm SJM prosthetic valve was implanted. On discharge, transthoracic and transesophageal echocardiography showed moderate 2+ paravalvular regurgitation, and the LDH value was also moderately elevated (629 IU/l). At this point, the systolic left ventricular function was normal (LVEF 60%). During the later course, there were no symptoms or signs of infection; however, echocardiography showed a deteriorating aortic regurgitation with moderately depressed left ventricular function (LVEF 45%). Two years later a re-do procedure was performed, during which the prosthesis was re-sutured. This operation was complicated by arrhythmic instability, prolonged weaning from extracorporeal circulation and need for inotropic support. Immediately after this procedure, TEE and aortography showed persisting severe aortic regurgitation. The location of the leak was between the former noncoronary and left aortic cusps (**Figure 1A and 1B**). The patient made a complete clinical recovery, however, a 4+ aortic regurgitation with moderate dilation and depressed systolic function of the

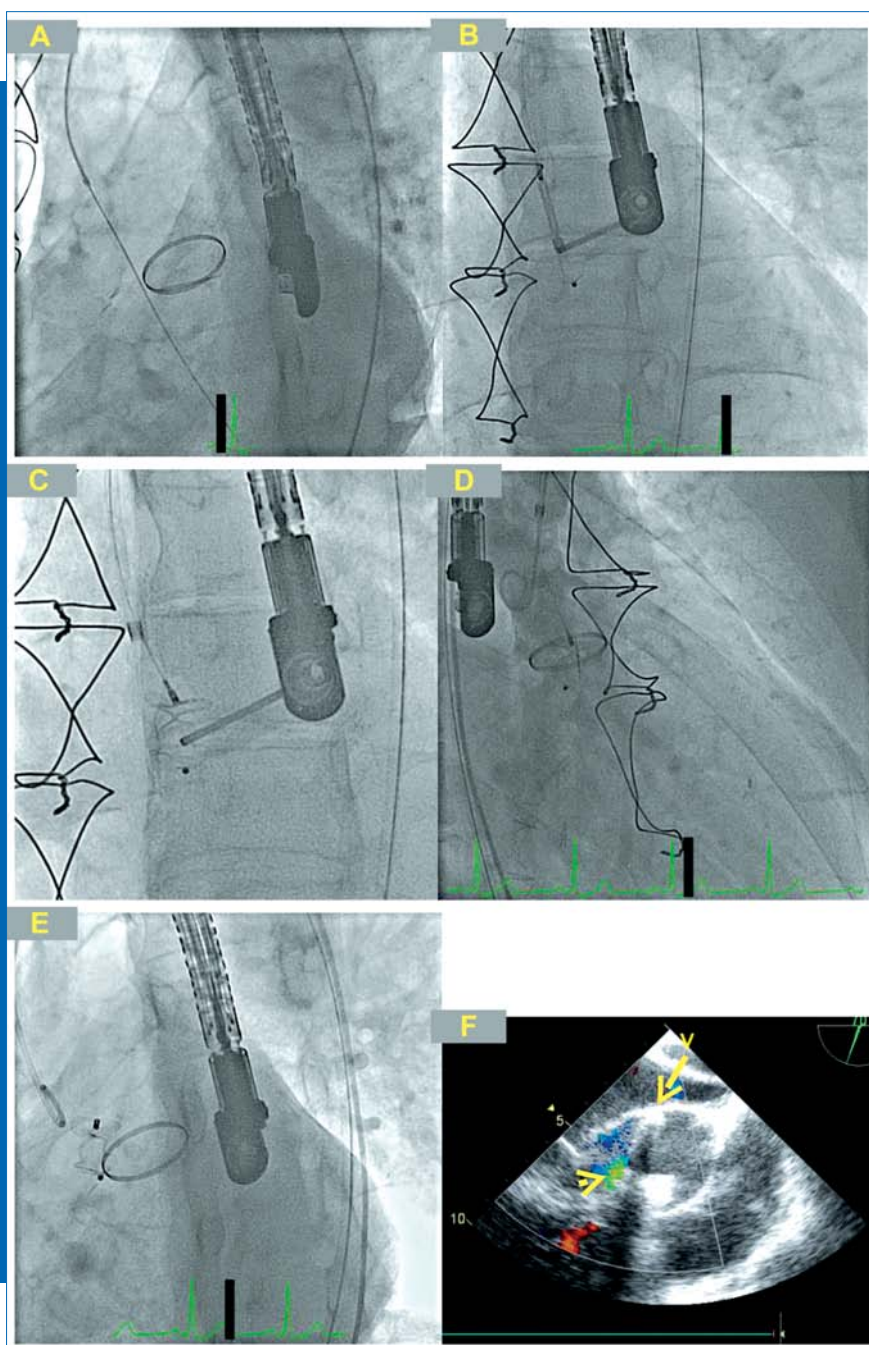


**Figure 1.** Preprocedural angiography (LAO 60) showing severe aortic regurgitation with pigtail catheter passing through the paravalvular defect (arrow) at the position corresponding to the area between the former noncoronary and left coronary cusps (A). The location of the defect (arrowhead) was confirmed with transesophageal echocardiography (B).

U srpnju 2013. godine izvršili smo zatvaranje PVL. Zahvat je izvršen u općoj anesteziji uz vođenje postupka pomoću TEE. Vaskularni pristup je izvršen preko 7F uvodnice u desnoj femoralnoj arteriji. Defekt je sondiran s 5F Amplatzer 2 dijagnostičkim kateterom i Terumo žicom s ravnim vrhom. Položaj žice kontroliran je periproceduralnim TEE (Slika 2A). Kateter je zamijenjen prethodno formiranom super-krutom žicom postavljenom u šupljinu lijeve klijetke. Ravna duga uvodnica od 7F uvedena je u lijevu klijetku i primjenjena za uvođenje naprave Amplatzer Vacular plug III (St Jude Medical, Maple Grove, Minnesota, SAD). Prema procijenjenoj veličini defekta korišten je okluder 12x5 mm (Slika 3). Čep je postavljen i otpušten na uobičajen način (Slika 2B, 2C). Angiografska kontrola je pokazala dobru poziciju čepa (Slika 2D, 2E) koji nije ugrozio listiće valvulne proteze. Zbog svog eliptičkog oblika, dobro se prilagođava polumjesečastom obliku defekta. Uočeno je značajno smanjenje stupnja regurgitacije sa samo blagim do umjerenim rezidualnim regurgitacijskim mlazom (Slika 2E, 2F). Invazivno mjerena tlak

left ventricle persisted. Laboratory findings showed highly significantly elevated LDH of 1680 IU/l.

In July 2013 we performed percutaneous paravalvular leak closure. The procedure was done in general anaesthesia with TEE guidance. The vascular access was through a 7F sheath in the right femoral artery. The defect was passed with a 5F Amplatzer 2 diagnostic catheter and straight-tip Terumo wire. The position of the wire was confirmed by TEE (Figure 2A). This was exchanged for a preformed super-stiff wire positioned in the left ventricular cavity. A straight long 7F sheath was introduced to the left ventricle and used for delivery of the Amplatzer Vacular plug III (St Jude Medical, Maple Grove, Minnesota, US). According to the estimated defect size, a 12x5mm occluder was used (Figure 3). The plug was positioned and released in the usual fashion (Figure 2B, 2C). Angiographic control showed good position of the plug (Figure 2D, 2E), which did not impinge upon the prosthetic valve leaflets. Due to its elliptic shape, it nicely

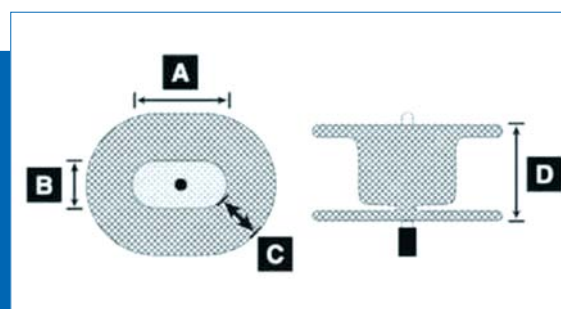



**Figure 2.** Periprocedural angiograms show passage of the wire through the defect (A), deployment of the occluder (B and C), confirmation of reduced regurgitation (D) and the final position (E). The result was confirmed by TEE (F); note the minimal residual regurgitation (arrowhead) and the shadow produced by the plug (arrow).



u aorti se odmah promijenio sa 140/40 mmHg na 120/70 mmHg. Bolesnik je otpušten dva dana nakon zahvata.

adapted to the crescent form of the defect. Significant reduction of the degree of regurgitation was observed, with only mild to moderate residual regurgitant jet (Figure 2E, 2F).



**Figure 3.** Amplatzer Vascular plug III used to close the paravalvular defect. Note the elliptical shape with two diameters.

Pregled ehokardiografijom je izvršen četiri mjeseca nakon okluzije i registrirano je daljnje smanjenje regurgitacije na stupanj 1+, vjerojatno zbog nastale endotelizacije. Tijekom razdoblja praćenja uočeno je značajno smanjenje hemolitičkih parametara (kontrolni LDL 432 IU/l), kao i povoljan klinički tijek.

## Zaključak

Klinički značajan PVL nakon implantacije proteze valvule je rijetka, ali potencijalno ozbiljna komplikacija. Perkutano zatvaranje PVL uvedeno je kao značajna alternativa ponovnom kirurškom zahvatu s povoljnim kratkoročnim i dugoročnim rezultatima. Obzirom na značajan broj implantacija valvularnih protetaza u Hrvatskoj, tijekom godina se može očekivati porast potrebe za ovom vrstom intervencije.

Received: 17<sup>th</sup> Nov 2013

\*Address for correspondence: Magdalena — Klinika za kardiovaskularne bolesti Medicinskog fakulteta Sveučilišta J. J. Strossmayera u Osijeku

Ljudevita Gaja 2, HR-49217 Krapinske Toplice, Croatia.

Phone: +385-49-244-115

E-mail: robert.bernat@zg.t-com.hr

The invasive aortic pressure changed immediately from 140/40 mmHg to 120/70 mmHg. The patient was discharged 2 days after the procedure.

The follow-up echocardiography was performed 4 months after the occlusion and showed further reduction of the regurgitation to 1+ degree, possibly due to ensuing endothelialisation. During the follow-up period, a marked reduction in haemolysis parameters (control LDL of 432 IU/l) and favourable clinical course has been observed.

## Conclusion

Clinically significant PVL after prosthetic valve implantation is a rare, but potentially serious complication. Percutaneous PVL closure has been introduced as an important alternative to re-do surgery with favourable immediate and late results. In view of the significant number of prosthetic valve implantations in Croatia, an increase in the need for this type of intervention can be expected each year.

## Literature

1. Mirat J, Čorić V, Bernat R, et al. Valvular heart diseases in Croatia in 2011. *Cardiol Croat.* 2012;7(3-4):57-64.
2. Pibarot P, Dumesnil JG. Prosthetic heart valves: selection of the optimal prosthesis and long-term management. *Circulation.* 2009;119(7):1034-48.
3. Hammermeister K, Sethi GK, Henderson WG, Grover FL, Oprian C, Rahimtoola SH. Outcomes 15 years after valve replacement with a mechanical versus a bioprosthetic valve: final report of the Veterans Affairs randomized trial. *J Am Coll Cardiol.* 2000;36:1152-8.
4. Ionescu A, Fraser AG, Butchart EG. Prevalence and clinical significance of incidental paraprosthetic valvar regurgitation: a prospective study using transoesophageal echocardiography. *Heart.* 2003;89:1316-21.
5. Dávila-Román VG, Waggoner AD, Kennard ED, et al. Prevalence and severity perivalvular regurgitation in the artificial valve endocarditis reduction trial (AVERT) echocardiography study. *J Am Coll Cardiol.* 2004;44:1467-72.
6. Ruiz CE, Jelmin V, Kronzon I, Dudy Y, Del Valle-Fernandez R, Einhorn BN. Clinical outcomes in patients undergoing percutaneous closure of periprosthetic paravalvular leaks. *J Am Coll Cardiol.* 2011;58:2210-7.
7. Miller DL, Morris JJ, Schaff HV, et al. Reoperation for aortic periprosthetic leakage: identification of patients at risk and results of operation. *J Heart Valve Dis.* 1995;4:160-5.
8. Akins CW, Bitondo JM, Hilgenberg AD, et al. Early and late results of the surgical correction of cardiac prosthetic perivalvular leaks. *J Heart Valve Dis.* 2005;14:792-800.
9. Sorajja P, Cabalka AK, Hagler DJ, et al. Successful percutaneous repair of paravalvular prosthetic regurgitation. *Cathet Cardiovasc Interv.* 2007;70:815-23.
10. Nietlispach F, Johnson M, Moss RR, et al. Transcatheter closure of paravalvular defects using a purpose-specific occluder. *J Am Coll Cardiol Intv.* 2010;3:759-65.
11. Sorajja P, Cabalka AK, Hagler DJ, Rihal CS. Long-term follow-up of percutaneous repair of paravalvular prosthetic regurgitation. *J Am Coll Cardiol.* 2011;58:2218-24.