

# Multifocal occurrence of extra-abdominal desmoid type fibromatosis – A rare manifestation. A clinicopathological study of 6 sporadic cases and 1 hereditary case<sup>☆</sup>

Elise M. Bekers<sup>a,b</sup>, Danique L.M. van Broekhoven<sup>c</sup>, Thijs van Dalen<sup>d</sup>, Johan J. Bonenkamp<sup>e</sup>, Ingrid C.M. van der Geest<sup>f</sup>, Jacky W.J. de Rooy<sup>g</sup>, Joost M. van Gorp<sup>h</sup>, David H. Creyten<sup>i</sup>, Wendy W.J. de Leng<sup>j</sup>, Blanca Scheijen<sup>a</sup>, Astrid Eijkelenboom<sup>a</sup>, Uta Flucke<sup>a,\*</sup>

<sup>a</sup> Department of Pathology, Radboud University Medical Center, Nijmegen, The Netherlands

<sup>b</sup> Department of Pathologie (DNA), Jeroen Bosch Hospital, Den Bosch, The Netherlands

<sup>c</sup> Erasmus MC Cancer Institute, Rotterdam, The Netherlands

<sup>d</sup> Department of Surgery Diaconessenhuis Utrecht, University Medical Center Utrecht, Utrecht, The Netherlands

<sup>e</sup> Department of Surgical Oncology, Radboud University Medical Center, Nijmegen, The Netherlands

<sup>f</sup> Department of Orthopedics, Radboud University Medical Center, Nijmegen, The Netherlands

<sup>g</sup> Department of Radiology and Nuclear Medicine, Radboud University Medical Center, Nijmegen, The Netherlands

<sup>h</sup> Department of Pathology, Diaconessenhuis Utrecht, The Netherlands

<sup>i</sup> Department of Pathology, Ghent University Hospital, Ghent, Belgium

<sup>j</sup> Department of Pathologie, University Medical Center Utrecht, Utrecht, The Netherlands

## ARTICLE INFO

### Keywords:

Desmoid  
Fibromatosis  
Soft tissue tumors

## ABSTRACT

Desmoid-type fibromatosis, also called desmoid tumor, is a locally aggressive myofibroblastic neoplasm that usually arises in deep soft tissue with significant potential for local recurrence. It displays an unpredictable clinical course.

β-Catenin, the genetic key player of desmoid tumors shows nuclear accumulation due to mutations that prevent its degradation leading to activation of Wnt signaling and myofibroblastic cell proliferation. The corresponding hot spot mutations are located in exon 3 of the *CTNNB1* gene or alternatively, in the *APC* tumor suppressor gene, most often as a germline mutation.

Multifocal desmoid tumors are very rare and clinical characteristics are poorly understood. Here we present six sporadic and one familial case of multifocal desmoid tumors.

Four female and three male patients, aged between 7 and 30 years (mean 18.4 years) were identified in a cohort of 1392 cases. Tumors were located in (distal) extremities, thorax, breast, abdominal wall, shoulder, and neck. Four cases showed a *CTNNB1* mutation and one an *APC* germline mutation. In two sporadic cases no *CTNNB1* mutation was identified. Four patients showed (multiple) recurrences and one patient was lost to follow-up.

In conclusion, multifocal desmoid tumors are a very rare disease and may occur in sporadic cases that are characterized by recurrent *CTNNB1* mutations. However, the underlying pathogenesis of multifocal desmoid tumors remains poorly understood with often aggressive clinical behavior and challenging therapeutical management.

## 1. Introduction

Desmoid-type fibromatosis, or desmoid tumor, is a locally aggressive, infiltrative growing myofibroblastic lesion with unpredictable clinical behavior. It may originate at any part of the body with

extremities, abdominal wall and mesentery being the most common sites [1]. The peak incidence is in the third decade [1].

Desmoid tumors arise sporadically in approximately 90% of the cases with the remaining 10% being familial [1]. Dysregulation of the Wnt signaling pathway is characteristic in both settings with β-catenin

<sup>☆</sup> This research did not receive any specific grant from funding agencies in the public, commercial, or not-for-profit sectors.

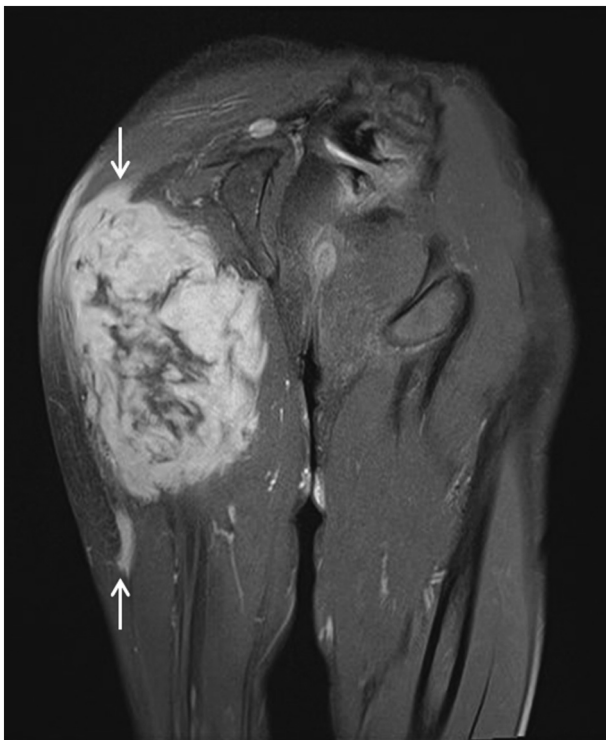\* Corresponding author at: Radboud University Medical Center, Department of Pathology, HP 824, P.O. Box 9101, 6500 HB Nijmegen, The Netherlands.  
E-mail address: [uta.flucke@radboudumc.nl](mailto:uta.flucke@radboudumc.nl) (U. Flucke).

**Table 1**  
Clinical data and mutation status.

Case nr.	Sex (m/f)	Age of first presentation (y)	Tumor localizations	Therapy	<i>CTNNB1</i> Mutation status	Recurrence (after n months)
1	m	13	Knee and gluteus	Resection, RT	c.121A > G <sup>a</sup> p.Thr41Ala	No
2	f	24	Breasts (left + right)	Resection	No mutation found	No
3	m	17	Upper leg and hallux	Resection	c.134C > T; p.Ser45Phe	Upper leg (10) and hallux (63)
4	f	27	Upper leg and lower leg	Resection	c.121A > G p.Thr41Ala	Lost to follow-up
5	m	11	Upper leg and hallux	Resection	c.121A > G <sup>a</sup> p.Thr41Ala	Hallux (36)
6	f	30	Abdominal wall, thorax, back, shoulder, neck	Resection, Lucrin, LHRH antagonist, Tamoxifen, RT	No mutation found	Multiple, in all locations (6)
7	f	7	Ankle, back and lower leg	Resection	<i>APC</i> mutation <sup>a</sup> (Gardner)	Ankle (7, 18 and 28), back (10)

M, male; f, female.

<sup>a</sup> Mutation in two lesions tested.



**Fig. 1.** Coronal contrast-enhanced spinecho T1-weighted MR-images with fat saturation of the buttock and proximal posterior side of the right lower leg showed an irregular lesion compatible with desmoid tumor. The extension of the lesion is displayed between the white arrows (Case 1).

being the key player. In sporadic cases, the most common activating mutations are located in exon 3 of the *CTNNB1* gene (chr 3p22.1) coding for  $\beta$ -catenin. Alternatively, in the remaining sporadic cases and the familial cases that occur in the context of Gardner syndrome (a form of familial adenomatous polyposis), there is a somatic or germline inactivating mutation or allelic deletion in the *APC* tumor suppressor gene (5q22.2) [1–4]. Both mechanisms lead to stabilization of  $\beta$ -catenin with cytoplasmic and subsequently nuclear accumulation. Within the nucleus,  $\beta$ -catenin acts as a transcription factor regulating cell proliferation of myofibroblastic cells [1,5,6].

In the recent years, a paradigm shift in terms of treatment modalities has taken place for desmoids tumors and the overall management

is increasingly complex. It has been shown that invasive treatment should be used with caution because of the potential of recurrence, irrespective of the margin status [5,7–9]. In this context, mutational analysis of *CTNNB1* can give prognostic information, where the hot spot mutation p.Ser45Phe (p.S45F), has been proposed as a possible marker for recurrence [10–12].

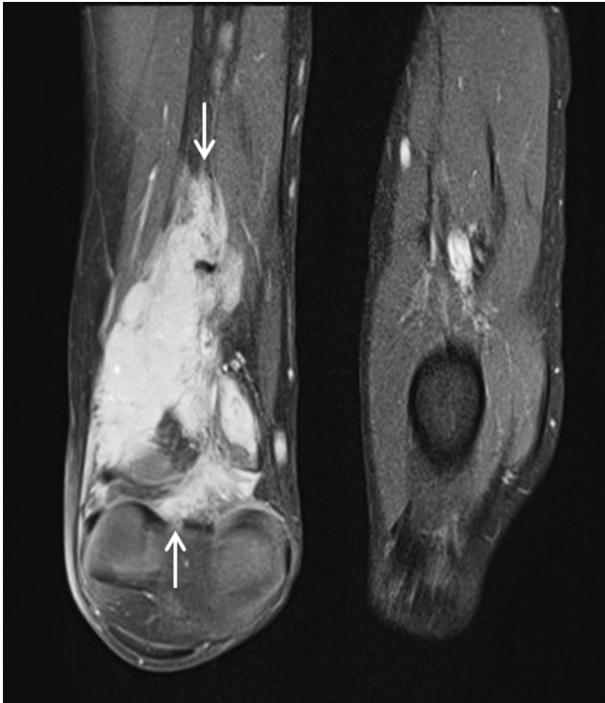Single cases of multifocal desmoid tumors have been described [13–15], but their genetic and clinical characteristics are not well understood. We describe herein a series of multifocal desmoid tumors and their mutational status to pay attention on these rare cases.

## 2. Material and methods

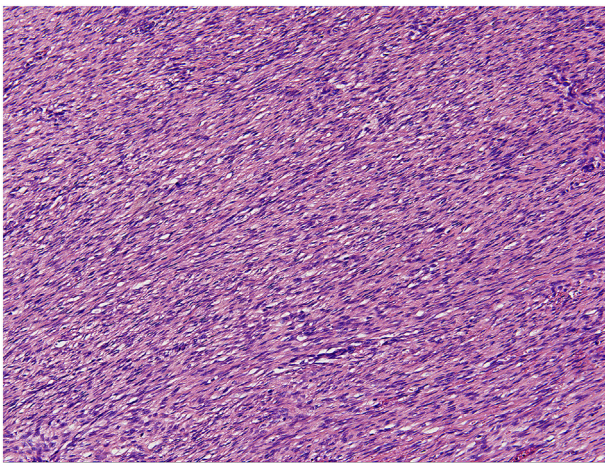
The cases were collected from the authors' files and the nationwide network and registry of histopathology and cytopathology in the Netherlands. Clinical data and follow-up were obtained from the patient records. The study was performed in accordance with the Code of Conduct of the Federation of Medical Scientific Societies in the Netherlands.

In all cases the tissue was fixed in 4% buffered formalin and embedded in paraffin; 2–4  $\mu$ m thick sections were stained with hematoxylin and eosin and immunohistochemically by the labelled Streptavidin Biotin technique using a commercially available antibody against  $\beta$ -catenin (BD Biosciences, clone 14, dilution 1:100). Appropriate positive and negative controls were used throughout.

DNA was isolated from formalin-fixed, paraffin-embedded material (without decalcification) by proteinase K digestion and the crude DNA extract was used in a standard PCR. The hot spot region for *CTNNB1* was amplified using primers: 5'-ATGCCATGGAACCAGACAGA-3' and 5'-GCTACTTGTCTTGTAGTGAAGGACTG-3'. The region most frequently mutated in *APC* (NM\_000038.5: amino acids 1200–1580) was amplified using the following primer pairs: 1) 5'-CAGATATTCCTTCATCACAGAAC-3' and 5'-GGAGTATCTTCTACACAATAAGTCTG-3', 2) 5'-GCCACTTGCAAAGTTTCTTC-3' and 5'-TCACAGGATCTTCAGCTGACCT-3', 3) 5'-TCAGACGACACAGGAAGCAGAT-3' and 5'-TTTTGGGTGTCTGAGCACCACT-3', 4) 5'-AGCCAGGCACAAAGCTGTTGAA-3' and 5'-TGTCCAGGGCTATCTGGAAGATCA-3', 5) 5'-ACCATGCAGTGAATGGTAAGTGG-3' and 5'-TGGAAGAACCTGGACCCTCTGAA-3', 6) 5'-TGGACCTAAGCAAGCTGCAGTA-3' and 5'-CTGCTCTGATTCTGTTTCATCCCAT TGT-3', 7) 5'-TCTGAGCCTCGATGAGCCATTT-3' and 5'-ACGTGATGAC TTTGTTGGCATGG-3'. All PCR products were analyzed by fluorescent di-deoxysequencing.



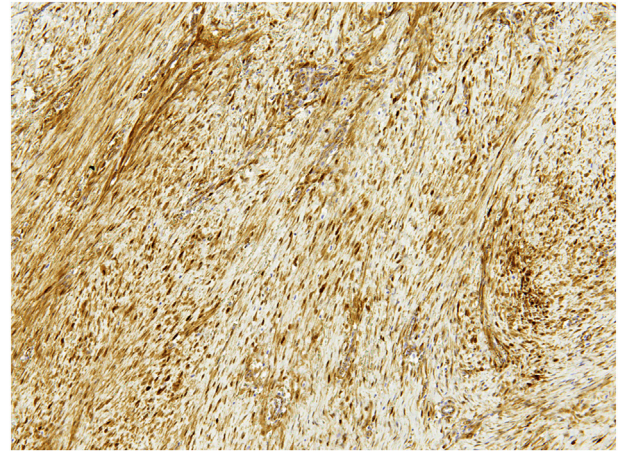
**Fig. 2.** Coronal contrast-enhanced spinecho T1-weighted MR-images with fat saturation of the knee/distal posterior side of the right lower leg showed the second desmoid tumor. The extension of the neoplasm is displayed by the white arrows (Case 1).



**Fig. 3.** Classical features of desmoid tumor showing long fascicles of monomorphic elongated myofibroblasts were seen in all cases.

### 3. Results

Out of 1392 cases, seven cases with multifocal desmoid tumors were selected; clinicopathological and genetic results are summarized in Table 1. Of the seven patients four were female and three were male. Age ranged from 7 to 30 years (mean 18.4 years). Lesions were located in knee and gluteus (1), thigh and lower leg (1), thigh and foot (2), trunk, shoulder and neck (1), lower leg and back (1) and both mammae (1). In all cases neoplasms were resected. (Multiple) local recurrences were reported in 4 patients. Two patients experienced no recurrences so far and one patient was lost to follow-up. One patient was additionally treated with systemic (Lucrin, LHRH antagonist, Tamoxifen) and radiation therapy and one patient with radiotherapy only.



**Fig. 4.** Immunohistochemistry showed nuclear accumulation of  $\beta$ -catenin in all cases.

Coronal contrast-enhanced spinecho T1-weighted MR-images with fat saturation of the buttock and proximal (Fig. 1) and distal (Fig. 2) posterior side of the right lower leg in Case 1 showed an irregular lesion compatible with desmoid tumor. The extension of the lesion is displayed between the white arrows.

Histologically, all cases showed classical features of desmoid tumor according to the current WHO classification of tumors of soft tissue and bone [16]: lesions consisted of long fascicles myofibroblastic cells with monomorphic elongated nuclei. There was a variable collagenous background with sometimes coarse collagen bundles. Myxoid features were sometimes focally present. Small vessels were found parallel to the fascicles of tumor cells. A perivascular edema was often seen (Fig. 3).

Immunohistochemically, nuclear expression of beta catenin was detected in all cases (Fig. 4).

By Sanger sequencing, mutations in *CTNNB1* were found in four cases with p.(Thr41Ala) being the most frequent ( $n = 3$ ) (Fig. 5). One case harbored a p.(Ser45Phe) mutation. Two sporadic cases showed no *CTNNB1* mutation and one case was known with a germline *APC* mutation.

In case 1, 5 and 7 two lesions each were tested and yielded the same mutation.

### 4. Discussion

It has been shown that desmoid-type fibromatosis derives from mesenchymal progenitor cells (MPC) harboring a mutation in the *CTNNB1* gene with consecutive  $\beta$ -catenin stabilization [6]. The nuclear accumulated protein binds to transducing beta-like protein leading to expression of several Wnt/APC/ $\beta$ -catenin pathway target genes including proliferation-stimulating factors such as S100A4 resulting in growth of myofibroblastic cells [1].

The capacity of circulation of mesenchymal progenitor cells (MPCs) including *CTNNB1* mutated MPCs could explain multifocal development of this tumor type [6]. This is reflected by the occurrence of the same mutation in the different lesions tested per patient in our series ( $n = 3$ ). However, cases of multifocal desmoid tumors are exceedingly rare and mostly known in patients with germline *APC* mutations and a subsequent second somatic hit [4]. Different *CTNNB1* mutations in multifocal diseases are also reported hypothesizing that genetic alterations can take place in different stages of myofibroblastic progenitor cells [15].

Our small series consist of mainly sporadic multifocal cases and shows that clinical management is naturally more difficult than in the common unilocular cases. In terms of age, localization and mutational status the herein described cases are similar to solitary cases representing young aged patients with lesions mainly in the lower

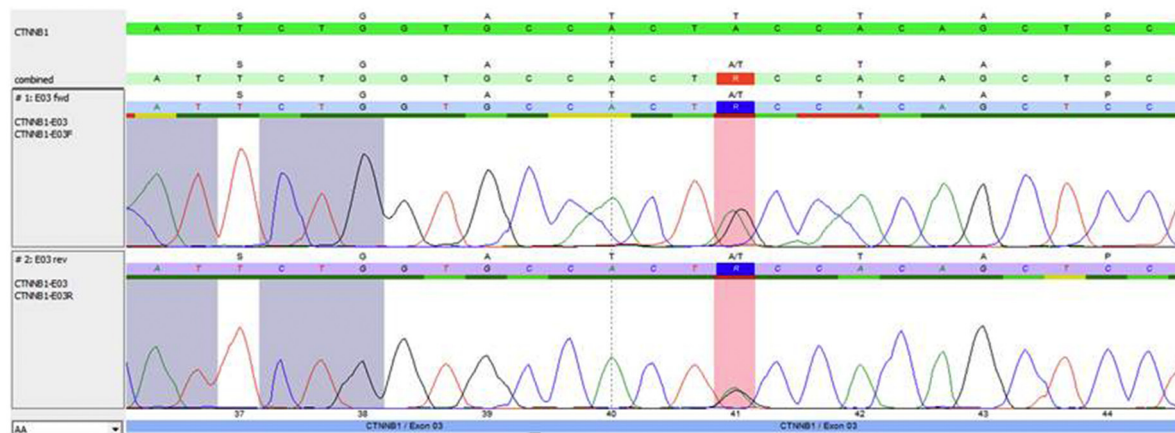


Fig. 5. By Sanger sequencing, a c.121A > G (p.Thr41Ala) were detected in three cases.

extremities [1].

The course of desmoid tumors is unpredictable, as spontaneous regression, long-lasting stable disease and disease progression can occur. Reliable and validated predictive factors are lacking [1]. In several studies it has been shown that mutational status of the hot spots influences prognosis with p.Ser45Phe (p.S45F) *CTNNB1* mutation being a risk factor for local recurrence after curative intended surgery [10–12]. Nevertheless this is not confirmed by others [17,18].

In terms of mutational status and associated prognosis of multifocal lesions, we cannot draw any conclusion since our series is very small and one case is known with an *APC* germline mutation. However, p.Thr41Ala (p.T41A) is the most common genetic event in our series.

In our cases, recurrences were common (4/7 cases) and surgical intervention limited in some cases due to additional mutilation.

Multimodality treatment including systemic (targeted) therapy could be of special interest [9,19] and identification of reliable clinical or genomic biomarkers predicting behavior of (multifocal) desmoid tumors is needed to facilitate a more patient tailored approach for successful management.

## References

- Penel N, Chibon F, Salas S. Adult desmoid tumors: biology, management and ongoing trials. *Curr Opin Oncol* 2017;29:268–74.
- Tejpar S, Nollet F, Li C, Wunder JS, Michils G, Dal Cin P, et al. Predominance of beta-catenin mutations and beta-catenin dysregulation in sporadic aggressive fibromatosis (desmoid tumor). *Oncogene* 1999;18:6615–20.
- Salas S, Chibon F, Noguchi T, Terrier P, Ranchere-Vince D, Lagarde P, et al. Molecular characterization by array comparative genomic hybridization and DNA sequencing of 194 desmoid tumors. *Genes Chromosom Cancer* 2010;49:560–8.
- Lips DJ, Barker N, Clevers H, et al. The role of APC and  $\beta$ -catenin in the aetiology of aggressive fibromatosis (desmoid tumors). *Eur J Surg Oncol* 2009;35:3–10.
- Kattentidt Mouravieva AA, Geurts-Giele IR, de Krijger RR, van Noesel MM, van de Ven CP, van den Ouweland AM, et al. Identification of familial adenomatosis carriers among children with desmoid tumours. *Eur J Cancer* 2012;48:1867–74.
- Wu C, Nik-Amini S, Nadesan P, Stanford WL, Alman BA. Aggressive fibromatosis (desmoid tumor) is derived from mesenchymal progenitor cells. *Cancer Res* 2010;70:7690–8.
- Janssen ML, van Broekhoven DL, Cates JM, et al. Meta-analysis of the influence of surgical margin and adjuvant radiotherapy on local recurrence after resection of sporadic desmoid-type fibromatosis. *Br J Surg* 2017;104:347–57.
- Broekhoven DL, Grünhagen DJ, van Dalen T, van Coevorden F, Bonenkamp HJ, Been LB, et al. Tailored beta-catenin mutational approach in extra-abdominal sporadic desmoid tumor patients without therapeutic intervention. *BMC Cancer* 2016;16:686.
- Eastley N, McCulloch T, Esler C, Hennig I, Fairbairn J, Gronchi A, et al. Extra-abdominal desmoid fibromatosis: a review of management, current guidance and unanswered questions. *Eur J Surg Oncol* 2016;42:1071–108.
- Lazar AJ, Tuvin D, Hajibashi S, Habeeb S, Bolshakov S, Mayordomo-Aranda E, et al. Specific mutations in the  $\beta$ -catenin gene (*CTNNB1*) correlate with local recurrence in sporadic desmoid tumors. *Am J Pathol* 2008;173:1518–27.
- Colombo C, Miceli R, Lazar AJ, Perrone F, Pollock RE, Le Cesne A, et al. *CTNNB1* 45F mutation is a molecular prognosticator of increased postoperative primary desmoid tumor recurrence: an independent, multicenter validation study. *Cancer* 2013;119:3696–702.
- Van Broekhoven DL, Verhoef C, Grünhagen DJ, van Gorp JM, den Bakker MA, Hinrichs JW, et al. Prognostic value of *CTNNB1* gene mutation in primary sporadic aggressive fibromatosis. *Ann Surg Oncol* 2015;22:1464–70.
- Shimoyama T, Hiraoka K, Shoda T, Hamada T, Fukushima N, Nagata K. Multicentric extraabdominal desmoid tumors arising in bilateral lower limbs. *Rare Tumors* 2010;2:e12.
- Garg P, Chufal SS, Gupta N, Pant P, Thapliyal NC. Multicentric aggressive mammary fibromatosis with cytological features and review of literature. *J Clin Diagn Res* 2014;8:FD01–3.
- Doyen J, Duranton-Tanneur V, Hostein I, Karanian-Philippe M, Chevreau C, Breibach F, et al. Spatio-temporal genetic heterogeneity of *CTNNB1* mutations in sporadic desmoid type fibromatosis lesions. *Virchows Arch* 2016;468:369–74.
- Goldblum JR, Fletcher JA. Desmoid-type fibromatosis. In: Fletcher CDM, Bridge JA, Hogendoorn PCW, Mertens F, editors. WHO classification of tumours of soft tissue and bone. Lyon: IARC; 2013. p. 72–3.
- Dömöt J, Salas S, Lacroix L, Brouste V, Saulnier P, Terrier P, et al. High frequency of  $\beta$ -catenin heterozygous mutations in extra-abdominal fibromatosis: a potential molecular tool for disease management. *Br J Cancer* 2010;102:1032–6.
- Mullen JT, DeLaney TF, Rosenberg AE, Le L, Iafrate AJ, Kobayashi W, et al.  $\beta$ -Catenin mutation status and outcomes in sporadic desmoid tumors. *Oncologist* 2013;18:1043–9.
- Heinrich MC, McArthur GA, Demetri GD, Joensuu H, Bono P, Herrmann R, et al. Clinical and molecular studies of the effect of imatinib on advanced aggressive fibromatosis (desmoid tumor). *J Clin Oncol* 2006;24:1195–203.