

Isolated Cerebral Sinovenous Thrombosis: A Rare Case of Neonatal Antiphospholipid Syndrome

DE CAROLIS MARIA PIA, *SALVI SILVIA, BERSANI ILIANA AND *DE CAROLIS SARA

From the Division of Neonatology, Department of Paediatrics; and *Department of Obstetrics and Gynecology, Catholic University of Sacred Heart, Rome, Italy.

Correspondence to:

Dr. Maria Pia De Carolis,
Division of Neonatology, Department of
Paediatrics, University Hospital "A.

Gemelli", Catholic University of the Sacred
Heart, Largo A. Gemelli, 8 00168 – Rome –
Italy. mpia.decarolis@rm.unicatt.it

Received: May 31, 2011;

Initial review: June 24, 2011;

Accepted: August 20, 2011.

We describe a case of neonatal cerebral sinovenous thrombosis associated with the presence of anti-phospholipid antibodies (aPL). We recommend that in all cases of neonatal thrombosis, the couple mother-infant should be extensively tested for the presence of both acquired (aPL) and congenital thrombophilia.

Key words: Anticardiolipin, Antiphospholipid syndrome, Neonate, Thrombosis.

Neonatal antiphospholipid syndrome (APS) is a rare clinical entity characterized by neonatal thrombotic disease due to the presence of antiphospholipid antibodies (aPL); its occurrence may depend on the transplacental transfer or on the *de novo* production of such antibodies. We describe a rare case of isolated sinovenous thrombosis associated with anticardiolipin IgG (aCL IgG) and anti-prothrombin antibodies.

CASE REPORT

A full-term neonate (birth weight 3120 grams; Apgar score 7 and 9 at 1 and 5 minutes, respectively) developed severe respiratory distress due to pneumonia soon after his delivery. During the first two weeks, his clinical condition gradually improved; serially performed cerebral ultrasound examinations were normal. On day 18, for the first time, a hyperechoic area behind the right Sylvian fissure was highlighted by routine cerebral ultrasound, in the absence of clinical manifestations. Brain magnetic resonance imaging showed a right parieto-temporal sub cortical malacic lesion associated with thrombosis of the superior sagittal sinus. The lesion extended from its medium third to the Torcular Haerophili (**Fig 1**) and was confirmed by the magnetic resonance angiography. Coagulation profile was normal; inherited thrombophilia was negative (antithrombin, protein C and protein S were normal for the age, factor V Leiden and G20210A prothrombin gene mutation were absent and total plasma homocystein level was normal) while anticardiolipin (aCL) IgG (30 U/mL, normal <19 U/mL) and anti-prothrombin IgG antibodies (61 U/ml, normal <15 U/mL) were elevated.

His primipara mother, without familiar and personal history of thromboses and autoimmune disease, was

additionally screened. Anti-prothrombin IgG and anticardiolipin IgM (aCL IgM) were positive (30 U/mL and 19 U/mL, respectively) and still present three months later.

On day 30, the neonate was discharged in good clinical conditions. Neurologic examinations, performed on the 3rd, 6th and 12th months of life showed normal neurological development.

DISCUSSION

In the neonatal period, the aPL-related thrombosis seems to be exceedingly rare, with only sixteen cases reported between 1987 and 2007 and analyzed in a recent review [1]. Arterial thromboses represent about eighty percent of the reported thromboses. To date, only three cases of venous thromboses are described: two of these affected only peripheral circulation [2, 3]; while in the third case, both the peripheral and central circulation were involved, since thrombosis of superior sagittal sinus with right middle cerebral artery infarct was detected in association to aortic and left renal artery thrombus [4].

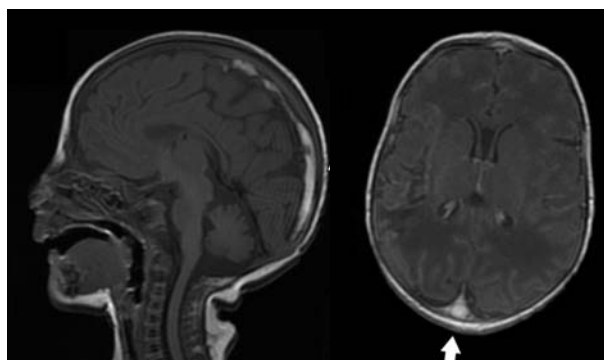


FIG.1 Magnetic resonance imaging of the head showing occlusion of the superior sagittal sinus.

Cerebral sinovenous thrombosis (CVT) occurs in neonates with an incidence of at least 0.67 per 100,000 per year [5]. However, this impact is likely underestimated for several reasons as the lack of knowledge of this condition by many clinicians, the difficulty in obtaining a correct radiological diagnosis and, above all, the absence of a specific clinical presentation [6]. In recent years, the diagnosis of neonatal CVT has dramatically increased by the improved sensitivity of the neuroimaging techniques and the more frequent application of cranial imaging in the neonatal period.

It is necessary to consider several genetic and acquired conditions that are predisposing factors for thrombosis in neonatal age: inherited thrombophilias, aPL antibodies, and additional perinatal conditions asphyxia, dehydration and infection. The presence of aPL antibodies and infection are the only risk factors for thrombotic event detectable in our patient. In the present case, the occurrence of thrombotic phenomena is associated with the presence of aPL antibodies. The presence of anti-prothrombin IgG antibodies in the serum of both neonate and his mother suggests the transplacental transfer of these antibodies. Instead, the aCL IgG were positive in the neonate and negative in his mother.

Neonatal APS is rare, if not exceptional, disease; it is likely that its rarity is attributable to the fact that aPL alone are not sufficient to cause disease and others factors are probably implicated. So, in the pathogenesis of neonatal thrombosis, a second hit (usually an inflammatory event) is required as an additional prothrombotic risk factor [7,8]. In the present case, probably pneumonia was the second trigger event for the onset of thrombotic event.

This case supports a previous reported observation: not-treated women with unknown aPL are probably at greater risk to have neonatal thrombosis than women successfully treated with aspirin and low molecular weight heparin [9]. Motta, *et al.* [7] proposed that heparin, when administered to the mother during gestation, is able to bind circulating aPL, limiting the transplacental transfer to the fetal circulation and thus reducing their pathogenicity.

We recommend that in all cases of neonatal venous and/or arterial thrombosis, the mother-infant pair should be extensively tested for the presence of both acquired (aPL) and congenital thrombophilia.

Acknowledgments: Papacci Patrizia (Department of Pediatrics, Division of Neonatology, for echographic evaluation; Costantino Romagnoli (Department of Pediatrics, Division of Neonatology, Catholic University of Sacred Heart) and Angela Botta (Department of Obstetrics and Gynecology for other support.

Contributors: All authors contributed to the literature search, drafting manuscript. Final manuscript was approved by all authors.

Funding: None; *Competing interests:* None stated.

REFERENCES

1. Boffa MC, Lachassinne E. Infant perinatal thrombosis and antiphospholipid antibodies: a review. *Lupus*. 2007;16:634-41.
2. Contractor S, Hiatt M, Kosmin M, Kim HC. Neonatal thrombosis with anticardiolipin antibody in baby and mother. *Am J Perinatol*. 1992;9:409-10.
3. Hage ML, Liu R, Marcheschi DG, Bowie JD, Allen NB, Macik BG. Fetal renal vein thrombosis, hydrops fetalis, and maternal lupus anticoagulant. A case report. *Prenat Diagn*. 1994;14:873-7.
4. Tabbutt S, Griswold WR, Ogino MT, Mendoza AE, Allen JB, Reznik VM. Multiple thromboses in a premature infant associated with maternal phospholipid antibody syndrome. *J Perinatol*. 1994;14:66-70.
5. deVeber G, Andrew M, Adams C, Bjornson B, Booth F, Buckley DJ, *et al.* Cerebral sinovenous thrombosis in children. *N Engl J Med*. 2001;345:417-23.
6. Ramenghi LA, Govaert P, Fumagalli M, Bassi L, Mosca F. Neonatal cerebral sinovenous thrombosis. *Semin Fetal Neonatal Med*. 2009;14:278-83.
7. Motta M, Rodriguez-Perez C, Tincani A, Lojacono A, Nacinovich R, Chirico G. Neonates born from mothers with autoimmune disorders. *Early Human Development*. 2009;85:S67-70.
8. Meroni PL, Borghi MO, Raschi E, Tedesco F. Pathogenesis of antiphospholipid syndrome: understanding the antibodies. *Nat Rev Rheumatol*. 2011;7:330-9.
9. Boffa MC, Lachassinne E, Boinot C, De Carolis S, Rovere-Querini P, Avcin T, *et al.* European registry of babies born to mothers with antiphospholipid syndrome. A result update. *Lupus*. 2009;18:900-4.