




## Open Archive Toulouse Archive Ouverte (OATAO)

OATAO is an open access repository that collects the work of some Toulouse researchers and makes it freely available over the web where possible.

This is an author's version published in: <https://oatao.univ-toulouse.fr/23129>

**Official URL :** <https://doi.org/10.1097/BPO.0000000000001163>

**To cite this version :**

Accadbled, Franck  and N'Dele, Daniel *Arthroscopic Treatment of Pediatric Fractures*. (2018) *Journal of Pediatric Orthopaedics*, 38. S29-S32. ISSN 0271-6798

Any correspondence concerning this service should be sent to the repository administrator:

[tech-oatao@listes-diff.inp-toulouse.fr](mailto:tech-oatao@listes-diff.inp-toulouse.fr)

# Arthroscopic Treatment of Pediatric Fractures

Franck Accadbled, MD, PhD, and Daniel N'Dele, MD

**Abstract:** Management of pediatric articular fractures has evolved over the years with a growing interest in arthroscopic handling. Several factors account for this recent appeal among which are progress in technology with increased availability of diagnostic methods, rise in athletic activities responsible for these fractures, and pediatric orthopaedic surgeons getting familiar with arthroscopic techniques. In our institution, 9 of 100 arthroscopic procedures are performed as a consequence of an articular fracture. In total, 80% of the fractures concern the knee (56% of tibial eminence fracture, 24% osteochondral fracture). Most of the remaining 20% are located at the ankle joint. Given the thorough articular exploration that arthroscopy provides, any associated cartilaginous or meniscal lesions is identified and addressed in the same procedure as the fracture fixation. Being a less invasive surgery with low complication rate, arthroscopic management of pediatric articular fractures provides very satisfactory results with earlier recovery. Of note, it is technically demanding and requires constant training. The operative time should be monitored and alternative options considered for each surgery. In this regard, arthroscopy has to be viewed as a means not an end.

**Key Words:** arthroscopy, tibial eminence, osteochondral fracture, children

Twenty years had passed between the popularization of the modern arthroscopy and the first article related to arthroscopy in children. New surgical techniques are most often practiced on adult patients before being adapted in children. There are 3 main reasons for the increased use of arthroscopy in pediatric fractures: improved technology, which includes cameras, high definition screens, small-sized instruments and implants; increased incidence of sports injuries responsible for articular fractures;<sup>2</sup> and adoption of the arthroscopic techniques by pediatric orthopaedic surgeons. Nearly 700 arthroscopic cases have been performed in the last 5 years in our department in a tertiary care University Hospital. The vast majority involved the knee (80%) and the ankle (8%). About 10% were indicated for fracture management (Table 1). The majority of the cases can be managed with regular instruments. A wrist arthroscope and

smaller instruments can be helpful when operating upon small joints or for use in treating the youngest individuals.<sup>3</sup>

## TIBIAL EMINENCE FRACTURE

The most common fracture managed with arthroscopy is the tibial eminence avulsion. The amount of displacement is appreciated according to the modified Meyer and Mc Keever's classification.<sup>4</sup> In the presence of a traumatic knee effusion, it is recommended to always obtain plain radiographs before any knee ligament testing, to prevent any displacement of an initially nondisplaced avulsion fracture. Type III and IV fractures require surgical reduction and fixation. The management of type II fractures remains controversial. The rationale for an operative management of a type II fracture includes arthroscopic inspection for associated cartilaginous or meniscal tears such as a medial meniscus entrapped within the fracture (Fig. 1). Surgery also allows accurate reduction and even "countersinking" to tighten the anterior cruciate ligament and try to prevent residual anterior laxity.<sup>5</sup> In the operating room, it is helpful to set the image intensifier around the knee, to obtain a true lateral view before prep and drape, with the screens next to each other. The hemarthrosis is first flushed out thoroughly. The avulsed fragment is lifted up, and the fracture site is debrided from blood clots and bone fragments. An arthroscopic burr is useful to dig into the fracture bed to a depth of 1 or 2 mm to obtain perfect reduction or countersinking. A small cannula is introduced through an accessory medial parapatellar portal. The arthroscopic probe may be used to rotate the fragment if needed, and the reduction is obtained by pushing the cannula onto the fragment. The guidewire is introduced without crossing the growth plate. One cannulated screw is introduced without drilling or taping. Tightening should be gentle under both arthroscopic and radioscopic control to prevent the

**TABLE 1.** Arthroscopic Cases Performed at Our Institution Between 2012 and 2016

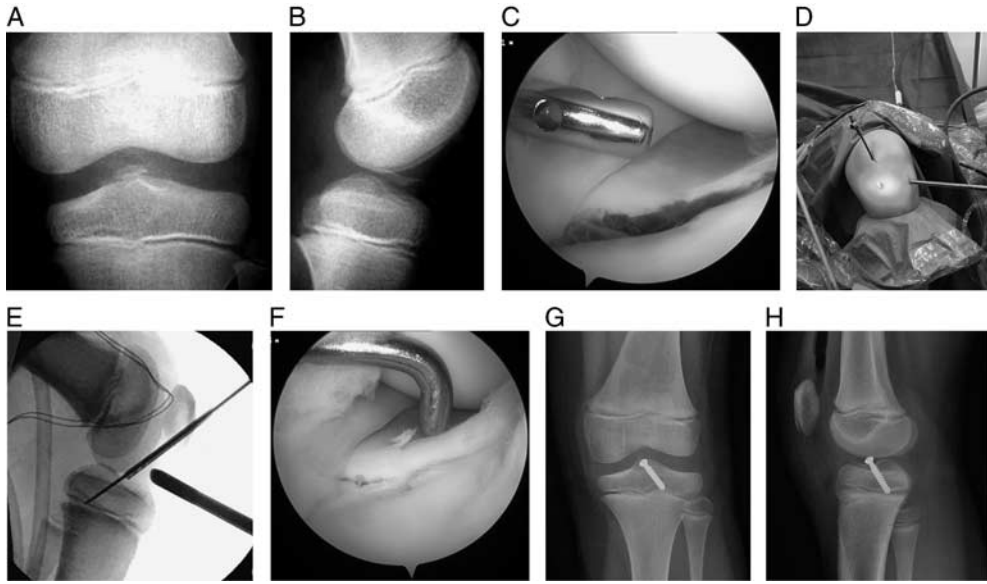
Procedures	No. Cases
ACL reconstruction	209
Meniscal repair	166
Saucerisation/meniscectomy	78
Septic arthritis	43
Tibial eminence fracture	34
Patellofemoral instability	24
Synovitis	23
Osteochondritis dissecans	18
Osteochondral fracture	15
SH type III and IV fracture	12
Total fractures	61
Total	695

ACL indicates anterior cruciate ligament; SH, Salter and Harris.

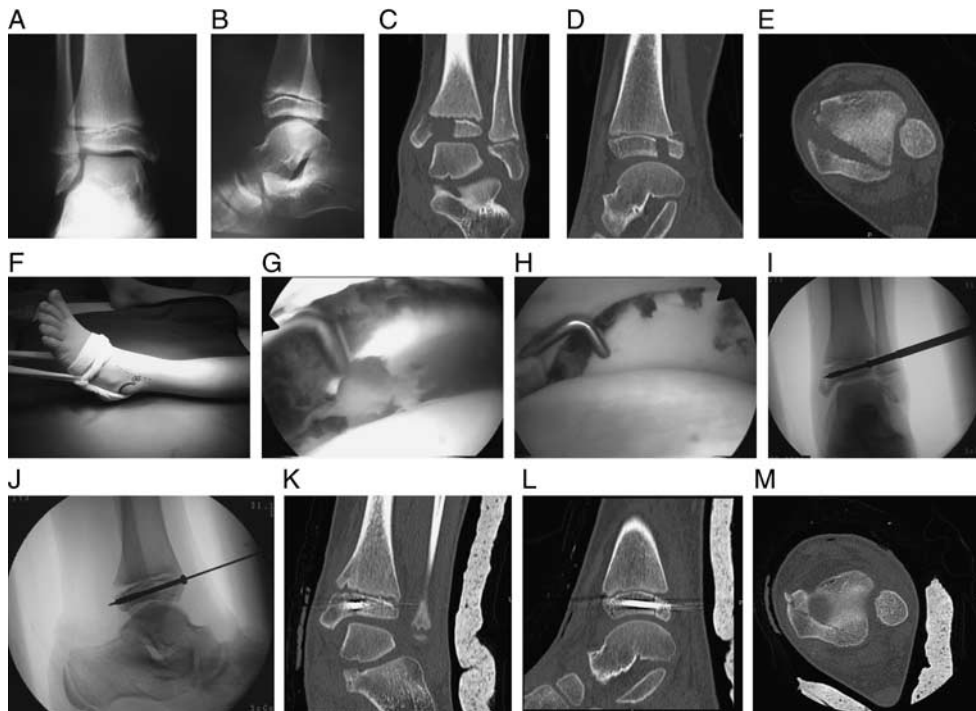
From the Department of Orthopaedics, Children's Hospital, Toulouse University Hospital, France.

The authors declare no conflicts of interest.

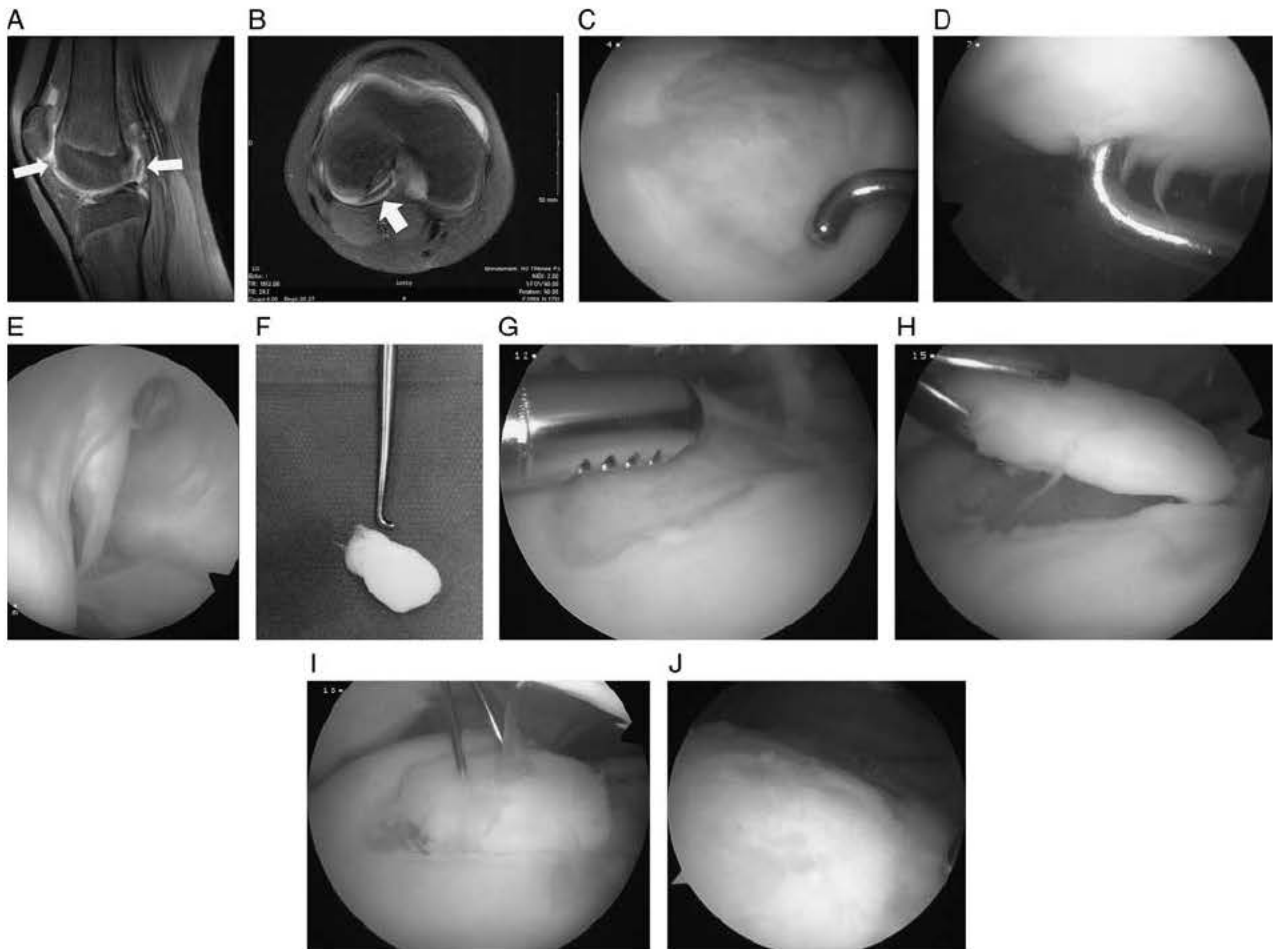
Reprints: Franck Accadbled, MD, PhD, Department of Orthopaedics, Children's Hospital, Toulouse University Hospital 330, avenue de Grande Bretagne, 31059 Toulouse cedex 9, France. E mail: faccadbled@gmail.com.



**FIGURE 1.** A and B, A 7 year old girl sustained a type II tibial eminence fracture to her left knee while skiing downhill. C, Arthroscopy showed that the medial meniscus was entrapped within the fracture. D, A cannula was introduced via a medial parapatellar portal. E, After reduction was achieved, a guidewire was introduced through the cannula under arthroscopic and radioscopic control. F, Digging the fracture bed allowed countersinking. G and H, Postoperative radiographs showed satisfactory reduction and screw placement.



**FIGURE 2.** A 9 year old girl presented with an injured left ankle after falling off her bike. A and B, Plain radiographs only showed a double contour at the medial malleolus on the anteroposterior view, whereas the lateral view was unremarkable. C E, A CT scan better demonstrated a displaced Salter and Harris type III injury. Arthroscopic operative management was decided. F, Clinical picture in the operating room showing noninvasive traction using a sterile strap. The superficial peroneal nerve and the anterolateral portal were marked on the skin. G and H, The fracture was reduced using a percutaneous sharp bone clamp under both arthroscopic and fluoroscopic control. I and J, A guidewire was introduced according to the preoperative CT scan planning followed by a 4 mm diameter percutaneous cannulated screw. K M, Postoperative CT scan demonstrated accurate joint surface reduction and closing of the fracture gap. The outcome was excellent without any growth disturbance. CT indicates computed tomography.



**FIGURE 3.** A 13 year old athlete was complaining about his right knee 10 months after a direct blow playing rugby. Physical examination showed mild effusion, normal range of motion, normal ligament laxity. Knee radiographs were unremarkable. A and B, Magnetic resonance imaging scan showed a loose body (arrows) in the posterior compartment, missing at the lateral condyle (arrow). Arthroscopy confirmed a cartilage loss of 4 cm<sup>2</sup> (C) and International Cartilage Repair Society II kissing injury on the patella (D). E, The cartilage fragment was retrieved behind the lateral condyle and extracted via a posteromedial portal. F, As expected, its edges were then round, and its volume increased; hence, it did not match the donor site anymore. The defect was refreshed (G) and the fragment reshaped and then repositioned (H), and fixed using 3 headless screws (I). J, The outcome was excellent and arthroscopic second look and screw removal 10 months postoperatively demonstrated complete healing.

screw from cutting through the fragment or violating the growth plate. A knee extension brace is placed for 4 weeks, and weight-bearing is encouraged. Najdi et al<sup>6</sup> have recently reported satisfactory results using this technique, although alternatives exist such as bone suture or, more recently, cortical fixation devices<sup>7</sup> and absorbable implants.<sup>8</sup> A prolonged operative time represents a risk for arthrofibrosis. Open reduction and fixation remains an acceptable option, and surgeons should approach tibial eminence fractures with whichever mode they can accomplish the task with higher efficiency.<sup>9</sup> Screw removal is not recommended in case of full recovery.

### SALTER HARRIS TYPE III AND IV FRACTURES

Displaced Salter and Harris type III and IV fractures require accurate reduction and fixation to prevent later growth disturbance and premature osteoarthritis. Arthroscopic

control of the percutaneous reduction is appropriate for proximal and distal tibial fractures and also distal femur fractures. Ankle fractures are the most frequent (medial malleolus, Tillaux, triplane) (Fig. 2). The literature is rather scarce but shows satisfactory results.<sup>10,11</sup>

Arthroscopically assisted reduction and percutaneous wire fixation of the lateral condyle of the humerus fracture has been reported with satisfactory outcome by small series reports.<sup>12,13</sup> Although no complication was reported, one must bear in mind the high risk of neurovascular injuries. Nonoperative treatment and percutaneous pinning are reasonable options when a cartilage hinge is preserved over the joint line. Arthroscopy has been recently used as a diagnostic tool in this regard.<sup>14</sup> In case the cartilage was disrupted, an arthrotomy was performed for reduction and fixation. It seems that magnetic resonance imaging can accurately provide the same information noninvasively.<sup>15</sup>

## OSTEOCHONDRAL FRACTURES

The vast majority of osteochondral fractures involve the knee joint, especially after traumatic patella dislocation, because of the shear stress produced when the patella dislocates and reduces. One author recommended obtaining a magnetic resonance imaging scan within 3 weeks after the first episode of traumatic patella dislocation given the high incidence of concomitant cartilage injuries in the adolescent population.<sup>16</sup> The fragment may involve the lateral femoral condyle or the patellar medial facet. The volume of the fragment is often underestimated by plain radiographs and computed tomographic scan because of the large cartilage content of the fragment. Treatment consists of loose body removal or fixation depending on the surface and location of the injury. Late diagnosis may preclude refixation, as the fragment is often increased in size and round in shape, because of the hydrophilic properties of the cartilage. The healing potential is high even if there is little or even no bony component to the fragment (Fig. 3).<sup>17</sup> Headless screws or absorbable pins, darts, or screws may be used. Chotel et al<sup>18</sup> reported satisfactory outcome after fragment fixation through a retrospective multicentre study and insisted on the importance of early diagnosis. In case of fragment fixation, we systematically perform medial patellofemoral ligament repair or reconstruction, to prevent repeat dislocation and protect the fragment from further shear forces in case of subluxation.

## CONCLUSIONS

In case of an intra-articular fracture, arthroscopy allows comprehensive joint exploration and provides very satisfactory results in children and adolescents. It is truly beneficial with fast track and earlier recovery. It bears a low complication rate. However, arthroscopy remains a means not an end to manage articular injuries, and operative time has to be considered. It is quite technically demanding and requires appropriate training

## REFERENCES

1. Eilert RE. Arthroscopy of the knee joint in children. *Orthop Rev.* 1976;9:61-65.
2. Werner BC, Yang S, Looney AM, et al. Trends in pediatric and adolescent anterior cruciate ligament injury and reconstruction. *J Pediatr Orthop.* 2016;36:447-452.
3. Accadbled F. Arthroscopic surgery in children. *Orthop Traumatol Surg Res.* 2010;96:447-455.
4. Zaricznyj B. Avulsion fracture of the tibial eminence: treatment by open reduction and pinning. *J Bone Joint Surg Am.* 1977;59:1111-1114.
5. McLennan JG. Lessons learned after second look arthroscopy in type III fractures of the tibial spine. *J Pediatr Orthop.* 1995;15:59-62.
6. Najdi H, Thevenin Lemoine C, Sales de Gauzy J, et al. Arthroscopic treatment of intercondylar eminence fractures with intraepiphyseal screws in children and adolescents. *Orthop Traumatol Surg Res.* 2016;102:447-451.
7. Hardy A, Casabianca L, Grimaud O, et al. Speed bridge arthroscopic reinsertion of tibial eminence fracture (complementary to the adjustable button fixation technique). *Orthop Traumatol Surg Res.* 2017;103:129-132.
8. Brunner S, Vavken P, Kilger R, et al. Absorbable and non absorbable suture fixation results in similar outcomes for tibial eminence fractures in children and adolescents. *Knee Surg Sports Traumatol Arthrosc.* 2016;24:723-729.
9. Watts CD, Larson AN, Milbrandt TA. Open versus arthroscopic reduction for tibial eminence fracture fixation in children. *J Pediatr Orthop.* 2016;36:437-439.
10. Laffosse JM, Cariven P, Accadbled F, et al. Osteosynthesis of a triplane fracture under arthroscopic control in a bilateral case. *Foot Ankle Surg.* 2007;13:83-90.
11. Jennings MM, Lagaay P, Schubert JM. Arthroscopic assisted fixation of juvenile intra articular epiphyseal ankle fractures. *J Foot Ankle Surg.* 2007;46:376-386.
12. Perez Carro L, Golano P, Vega J. Arthroscopic assisted reduction and percutaneous external fixation of lateral condyle fractures of the humerus. *Arthroscopy.* 2007;23:1131.e1-1131.e4.
13. Hausman MR, Qureshi S, Goldstein R, et al. Arthroscopically assisted treatment of pediatric lateral humeral condyle fractures. *J Pediatr Orthop.* 2007;27:739-742.
14. Temporin K, Namba J, Okamoto M, et al. Diagnostic arthroscopy in the treatment of minimally displaced lateral humeral condyle fractures in children. *Orthop Traumatol Surg Res.* 2015;101:593-596.
15. Thevenin Lemoine C, Salanne S, Pham T, et al. Relevance of MRI for management of non displaced lateral humeral condyle fractures in children. *Orthop Traumatol Surg Res.* 2017;103:777-781.
16. Nomura E, Inoue M, Kurimura M. Chondral and osteochondral injuries associated with acute patellar dislocation. *Arthroscopy.* 2003;19:717-721.
17. Walsh SJ, Boyle MJ, Morganti V. Large osteochondral fractures of the lateral femoral condyle in the adolescent: outcome of bioabsorbable pin fixation. *J Bone Joint Surg Am.* 2008;90:1473-1478.
18. Chotel F, Knorr G, Simian E, et al. Knee osteochondral fractures in skeletally immature patients: French multicenter study. *Orthop Traumatol Surg Res.* 2011;97:S154-S159.

## Commentary

The role of arthroscopy in the management of fractures, particularly periarticular fracture, in adults is fairly well-defined. Whether a part of the primary fracture management or an adjunct to percutaneous or open fixation, arthroscopy is especially useful for fixation of tibial plateau fractures and for removal of osteochondral loose bodies after fracture. In their discussion of the

arthroscopic treatment of pediatric fractures, Drs Accadbled and N'Dele have demonstrated reasons for considering the use of arthroscopy in children, particularly for tibial eminence fractures and removal of osteochondral loose bodies after periarticular fractures around the knee. The 2 situations are by far the most common indications for the use of arthroscopy in the management of pediatric fractures.

As noted in the article, arthroscopy may be helpful in percutaneous fracture reduction and fixation in the ankle, particularly distal tibial physeal and articular injuries.