



Open Archive Toulouse Archive Ouverte (OATAO)

OATAO is an open access repository that collects the work of some Toulouse researchers and makes it freely available over the web where possible.

This is an author's version published in: <https://oatao.univ-toulouse.fr/23124>

Official URL : <https://doi.org/10.1302/1863-2548-11-160282>

To cite this version :

Accadbled, Franck[✉] and Murgier, Jérôme and Delannes, Bernard and Cahuzac, Jean-Philippe and Sales de Gauzy, Jérôme[✉] *In situ pinning in slipped capital femoral epiphysis: long-term follow-up studies.* (2017) *Journal of Children's Orthopaedics*, 11 (2). 107-109. ISSN 1863-2521

Any correspondence concerning this service should be sent to the repository administrator:

tech-oatao@listes-diff.inp-toulouse.fr

In situ pinning in slipped capital femoral epiphysis: long-term follow-up studies

F. Accadbled
J. Murgier
B. Delannes
J. P. Cahuzac
J. Sales de Gauzy

Abstract

Background Management of moderately displaced slipped capital femoral epiphysis (SCFE) is debated, mostly because of the risks related to open reduction on one hand, and subsequent evolution toward femoroacetabular impingement (FAI) on the other.

Method All SCFE cases treated with *in situ* fixation (ISF) and a minimum of ten years of follow-up beyond skeletal maturity were analysed in a retrospective multicentre study. Coxometry parameters were measured. Long-term results of ISF were meanwhile analysed at our Institution.

Results A total of 222 patients were included. Patient reported outcome measurements were related to the severity of the initial slip. It suggested a 35.5° threshold for slip angle beyond which FAI was more frequent. Only slight remodelling at the head-neck junction is to be expected.

Conclusion Based on these findings, it seems reasonable to perform ISF only in SCFE with a slip angle below 35°.

Keywords: slipped capital femoral epiphysis; SCFE; *in situ* pinning; femoroacetabular impingement; hip

Introduction

Back in 2012, commonly admitted guidelines for slipped capital femoral epiphysis (SCFE) management in France

Department of Orthopaedics, Children's Hospital, CHU de Toulouse, France

Correspondence should be sent to: Professor F. Accadbled, Service de Chirurgie Orthopédique et Traumatologique, Hôpital des Enfants 330, avenue de Grande Bretagne, 31059 Toulouse cedex 9, France. E-mail: faccadbled@gmail.com

consisted of *in situ* fixation (ISF) in cases of mild displacement and open reduction in cases of severe displacement. Ideal management of moderately displaced cases was debated, mostly because of the risks related to open reduction on one hand and subsequent evolution toward femoroacetabular impingement (FAI) on the other. The French Orthopedic Society (SoFCOT) therefore carried out a retrospective multicentre study to assess mid- and long-term outcomes of ISF and to determine a critical slip angle threshold above which FAI is likely.¹ Long-term results of ISF were meanwhile analysed at our institution.²

Material and methods

All SCFE cases treated with ISF with a minimum follow-up of ten years beyond skeletal maturity were included. Post-operative radiographs included Dunn lateral hip view with measurement of posterior slip angle and coxometry. At latest follow-up, clinical impingement tests and Oxford-12 Hip score were applied. Imaging included the same data as on immediate post-operative assessment, with the alpha angle on lateral hip view. Osteoarthritis was assessed according to Tönnis classification. Signs of FAI included: convexity at the junction between femoral head and neck; head flattening; osteophytes; and herniation pit. Any revision surgery other than metal removal was recorded.

Results

A total of 222 patients were included (222 hips). Mean age at diagnosis was 12.8 years. Mean pre-operative slip angle was 38.8° (14° to 70°). Mean age at latest follow-up was 28.2 years and mean follow-up was 11.2 years. At latest follow-up, mean acetabular roof angle was 11.4° (3° to 46°), centre edge (CE) angle was 30° (10° to 68°) and anterior coverage angle 31° (8° to 70°). There were no significant differences between pre-operative and latest follow-up coxometric variables ($p < 0.05$). Mean alpha angle at latest follow-up was 69° (27° to 110°). Mean global Oxford score was 14.86 (12 to 37), corresponding to satisfactory joint function not requiring formal treatment. In total, 88% of hips were Tönnis grade 0 or 1 (122 grade 0 and 73 grade 1). While 17 hips underwent revision surgery over the mean 11.2 years of follow-up: FAI in six cases; disabling pain due to advanced osteoarthritis in six cases; avascular necrosis

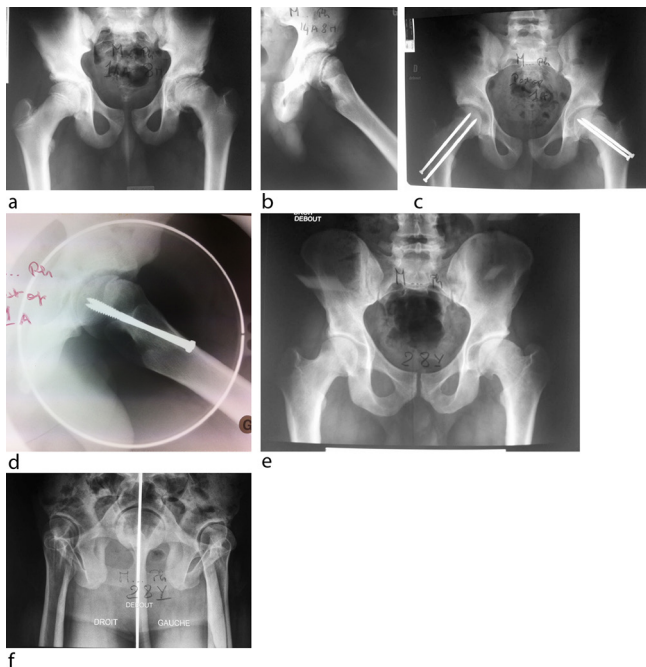


Fig. 1 (a, b) Left 60° acute slipped capital femoral epiphysis in a 14.8-year-old male. (c, d) Inadvertent closed reduction to 45° and fixation using two screws associated with contralateral fixation. (e, f) At 13-year follow-up: Tönnis grade 1. Satisfactory functional outcome (Oxford hip score = 17).

in three cases; and joint impingement due to prominent screws in two cases. The 15 hips showed pain in flexion and/or abduction, suggesting FAI, six of which required surgical revision. The Wilcoxon test for small samples displayed no correlation between pre- or post-operative slip angle and FAI. Spearman correlation between pre-operative Southwick angle and severity on follow-up Oxford score showed a highly significant coefficient of 0.0003: the greater the angle, the poorer the score. Receiver operating characteristic survival curves, used to determine an epiphyseal slip threshold beyond which impingement would be significantly more frequent and Oxford score impaired, plotting onset of impingement against pre-operative slip angle, found median sensitivity and specificity both around 0.53 for 35.5° to 39.5° slips; there was thus a trend for impingement after ISF in SCFE exceeding 35°. A retrospective analysis of a series of 12 cases at our institution demonstrated the same results at a mean 26 years of follow-up (Fig. 1).²

Discussion

Our study demonstrated that patient reported outcome measurements (PROMs) were related to the severity of the initial slip. It suggested a 35.5° threshold for slip angle beyond which FAI was more frequent. In the 222 hips, there were only 15 cases of FAI and relatively low medium-term osteoarthritis, with 88% of patients graded

Tönnis 0 or 1. A recent study from de Poorer et al about 78 hips also treated with ISF at a mean of 18 years of follow-up showed no differences between mild and moderate slips in terms of functional and radiological outcomes.³ However, severe slips were associated with a high rate of hip osteoarthritis and bad PROMs.

This was the first report of coxometric results in SCFE with such a long follow-up. It indicated only slight remodelling at the head-neck junction. This is consistent with previous work from DeLullo et al, which showed persistence of femoral neck deformity at a mean 7.5 year follow-up.⁴ When secondary surgery is indicated in the case of FAI, it is recommended that anatomy is considered (coxometry, coxa vara, acetabular retroversion, etc) to select the treatment option.⁵

Based on these findings, it seems reasonable to perform ISF in SCFE with a slip angle less than 35°. High-grade slips are best managed with open reduction. For those cases with a slip in the range of 35° to 50°, initial ISF and secondary osteochondroplasty or subtrochanteric osteotomy when the patient shows signs of FAI is acceptable. Initial open reduction, provided an experienced surgeon is available, is an alternative.⁶

COMPLIANCE WITH ETHICAL STANDARDS

FUNDING STATEMENT

No benefits in any form have been received or will be received from a commercial party related directly or indirectly to the subject of this article.

OA LICENCE TEXT

This article is distributed under the terms of the Creative Commons Attribution-Non Commercial 4.0 International (CC BY-NC 4.0) licence (<https://creativecommons.org/licenses/by-nc/4.0/>) which permits non-commercial use, reproduction and distribution of the work without further permission provided the original work is attributed.

ETHICAL STATEMENT

Ethical approval: All procedures performed in studies involving human participants were in accordance with the ethical standards of the institutional and/or national research committee and with the 1964 Helsinki Declaration and its later amendments or comparable ethical standards.

No funding was received for this study.

REFERENCES

1. **Nectoux E, Décaudain J, Accadbled F, et al.** French society of Orthopedic, Traumatologic Surgery (SoFCOT). Evolution of slipped capital femoral epiphysis after in situ screw fixation at a mean 11 years' follow-up: a 222 case series. *Orthop Traumatol Surg Res* 2015;101:51–54.
2. **Murgier J, de Gauzy JS, Jabbour FC, et al.** Long-term evolution of slipped capital femoral epiphysis treated by in situ fixation: a 26 years follow-up of 11 hips. *Orthop Rev (Pavia)* 2014;6:5335.

3. **de Poorter JJ, Beunder TJ, Gareb B, et al.** Long-term outcomes of slipped capital femoral epiphysis treated with in situ pinning. *J Child Orthop* 2016;10:371-379.

4. **DeLullo JA, Thomas E, Cooney TE, McConnell SJ, Sanders JO.** Femoral remodeling may influence patient outcomes in slipped capital femoral epiphysis. *Clin Orthop Relat Res* 2007;457:163-170.

5. **Mamisch TC, Kim YJ, Richolt JA, Millis MB, Kordelle J.** Femoral morphology due to impingement influences the range of motion in slipped capital femoral epiphysis. *Clin Orthop Relat Res* 2009;467:692-698.

6. **Hosalkar HS, Pandya NK, Bomar JD, Wenger DR.** Hip impingement in slipped capital femoral epiphysis: a changing perspective. *J Child Orthop* 2012;6:161-172.