





## Open Archive Toulouse Archive Ouverte (OATAO)

OATAO is an open access repository that collects the work of some Toulouse researchers and makes it freely available over the web where possible.

This is an author's version published in: <https://oatao.univ-toulouse.fr/23097>

**Official URL :** <https://doi.org/10.1016/j.jse.2017.11.007>

**To cite this version :**

Pham, Thuy Trang and Delclaux, Stéphanie and Huguet, Sandrine and Wargny, Matthieu and Bonneville, Nicolas  and Mansat, Pierre  *Coonrad-Morrey total elbow arthroplasty for patients with rheumatoid arthritis: 54 prostheses reviewed at 7 years' average follow-up (maximum, 16 years)*. (2018) *Journal of Shoulder and Elbow Surgery*, 27 (3). 398-403. ISSN 1058-2746

Any correspondence concerning this service should be sent to the repository administrator:

[tech-oatao@listes-diff.inp-toulouse.fr](mailto:tech-oatao@listes-diff.inp-toulouse.fr)

# Coonrad-Morrey total elbow arthroplasty for patients with rheumatoid arthritis: 54 prostheses reviewed at 7 years' average follow-up (maximum, 16 years)

Thuy Trang Pham, MD<sup>a,\*</sup>, Stéphanie Delclaux, MD<sup>b</sup>, Sandrine Huguet, MD<sup>c</sup>,  
Matthieu Wargny, MD<sup>d</sup>, Nicolas Bonneville, MD, PhD<sup>b</sup>, Pierre Mansat, MD, PhD<sup>b</sup>

<sup>a</sup>*Service de Chirurgie Orthopédique et Traumatologique Pédiatrique, Hôpital des Enfants, Toulouse, France*

<sup>b</sup>*Service de Chirurgie Orthopédique et Traumatologique, Hôpital Pierre Paul Riquet, CHU Toulouse, Toulouse, France*

<sup>c</sup>*Service de Chirurgie de la Main et de Chirurgie Plastique et Reconstructrice de l'Appareil Locomoteur, Centre Chirurgical Emile Gallé, Nancy, France*

<sup>d</sup>*Inserm UMR 1087/CNRS UMR 6291, Nantes, France*

**Background:** Total elbow arthroplasty is a therapeutic option for severe rheumatoid arthritis. We hypothesized that the semiconstrained characteristics of the Coonrad-Morrey prosthesis do not compromise the survival rate of the implant in a rheumatoid elbow.

**Methods:** Between 1997 and 2012, there were 54 Coonrad-Morrey total elbow prostheses performed for rheumatoid arthritis in 46 patients. Minimum follow-up was 2 years. There were 35 women and 11 men with a mean age of 60 years (29-83 years). According to the Mayo classification for rheumatoid elbow, there were 30 type IIIA, 21 type IIIB, and 3 type IV. The surgical procedure was the same for all patients. Survivorship was assessed with use of the Kaplan-Meier method, with revision surgery as the end point.

**Results:** The survival rate was 97% (95% confidence interval, 83.6-99.6) at 5 years and 85% (95% confidence interval, 68.3-93.7) at 10 years. At an average of 7 years of follow-up (2-16 years), the mean Mayo Elbow Performance Score was 91 points (55-100 points), and the shortened version of the Disabilities of the Arm, Shoulder, and Hand score was 34 points (0-75 points). There was a significant improvement in Mayo Elbow Performance Score and in all range of motion at latest follow-up in comparison to preoperative values ( $P < .0001$ ). Radiolucencies were observed in 6 cases around the humeral component and in 6 cases around the ulnar component. Bushing wear was observed in 16 cases (29%). There were 14 complications (26%). Revisions were performed in 6 of them (11%).

**Conclusion:** The Coonrad-Morrey prosthesis provides satisfactory results with follow-up. The rate of complications remains high even if the rate of implant revision stayed low.

Institutional Review Board approval was not required for this study. All patients were informed about the use of their personal data for this study, and all accepted.

\*Reprint requests: Thuy Trang Pham, MD, Service de Chirurgie Orthopédique et Traumatologique Pédiatrique, Hôpital des Enfants, CHU Toulouse, 31059 Toulouse cedex 9, France.

E-mail address: [francethuytrang@yahoo.fr](mailto:francethuytrang@yahoo.fr) (T.T. Pham).

**Level of evidence:** Level IV; Case Series; Treatment Study

**Keywords:** Semiconstrained; total elbow arthroplasty; Coonrad-Morrey total elbow prosthesis; rheumatoid arthritis; survival rate; linked prosthesis

Rheumatoid arthritis (RA) affects roughly 1%-2% of the general population; it affects the elbow in 20%-65% of patients and is isolated to the elbow in 5% of cases.<sup>19</sup> Despite progress in the medical treatment of RA, notably in biotherapies, total elbow arthroplasty remains a therapeutic option in severe cases after failure of medical treatment.

The problems to consider are often pain during joint movement, loss of mobility, and elbow instability in the case of advanced osseous destruction or ligament insufficiency.<sup>2,6,17,24</sup> The elbow prosthesis used should thus eliminate pain, allow recuperation of a functional elbow range of motion, and ensure stability of the elbow. A semiconstrained prosthesis fulfills these criteria.<sup>9,10</sup> However, this type of prosthesis presents the potential risk of complications, notably due to mechanical failure but also due to loosening in the long term as well as infection in patients who are often immunosuppressed. Few studies report the long-term results in this context.<sup>4,10,18,20</sup> The objective of this study was to evaluate the long-term outcomes and survival of the Coonrad-Morrey semiconstrained prosthesis in RA. It was hypothesized that the prosthesis would be viable in the long term, with a survival rate of 80% at 10 years. The principal judgment criterion was the prosthesis survival curve at 5 and 10 years. Secondary judgment criteria included clinical results according to the Mayo Elbow Performance Score (MEPS), radiography results, and complication and revision rates.

## Materials and methods

### Patients

This was a retrospective, monocentric study of a cohort prospectively observed since 1997. Inclusion criteria included all patients presenting with elbow RA for which a Coonrad-Morrey prosthesis was used as first-line treatment between 1997 and 2012 and reviewed within a minimum of 2 years. Exclusion criteria included patients who had Coonrad-Morrey total elbow arthroplasty for a condition other than RA, for the revision of a previous prosthesis, or with a follow-up period of <2 years. During this period, 151 Coonrad-Morrey prostheses were administered in our department, 80 of which were for elbow RA. Sixty-six had a follow-up of at least 2 years, 6 of which were admitted for distal humerus fracture. Six prostheses were placed for the revision of another prosthesis. Overall, 46 patients (54 elbows) were included, with an average follow-up of 7 years (2-16 years). Surgery was bilateral for 8 cases. Patients included 35 women and 11 men, with an average age of 60 years (29-83 years) at the time of surgery. According to the Mayo classification for rheumatoid elbow, 30 cases were type IIIA, 21 cases were type IIIB, and 3 cases were type IV.

### Evaluation criteria

Clinical evaluation was carried out preoperatively and at final follow-up by MEPS.<sup>14</sup> Joint mobility was measured using a goniometer. Strength was analyzed by an evaluation against resistance and against gravity in flexion and extension, with elbow flexed 90°, and compared with the opposite elbow. Strength was considered normal when it was between 80% and 100% of the opposite elbow. Loss of strength was considered moderate when strength was observed as 50%-80% of the opposite elbow and severe if <50%. The shortened version of the Disabilities of the Arm, Shoulder, and Hand (QuickDASH) score was also evaluated at final follow-up.<sup>1,13</sup>

Radiographic analysis was carried out at final follow-up by standard radiography of the elbow in anterior-posterior and lateral views. Loosening was evaluated between 0 and 4 according to Morrey et al.<sup>15</sup> Wear of the polyethylene bushings in the prosthetic hinge was judged by anterior-posterior radiography of the elbow; an absence of bushing wear was considered when the angle of the ulnar implant in relation to the humeral implant was <3.5°, wear was considered partial for an angle of up to 5°, and total wear was considered for an angle >5°. <sup>8</sup>

### Surgical technique

Surgical intervention was similar for all patients. Patients were placed in a supine position with the forearm on the abdomen. The Bryan-Morrey approach was used in all cases. Ulnar nerve transposition was systematically carried out. Bone preparation and implant positioning were performed according to Morrey's recommendations.<sup>14</sup> The implant was fixed with cement according to recommendations by Faber et al<sup>3</sup>: after washing and drying of the canals, a low-viscosity cement with antibiotics was injected with an adapted cement gun. The triceps were then reinserted by transosseous sutures according to the description by Morrey.<sup>14</sup> Postoperatively, the elbow was immobilized in extension using an anterior splint for 48 hours, then a simple sling was left for 3 weeks. No rehabilitation was prescribed, and the patient was allowed to move the elbow according to the level of pain. Lifting was limited to 5 kg for a single effort or 1 kg for repeated efforts.

### Statistical analysis

Statistical analysis was by  $\chi^2$  test for qualitative variables and by Student test for quantitative variables. A difference was estimated to be statistically significant when the *P* value was < .05. The survival rate was analyzed according to the Kaplan-Meier method, with 95% confidence interval, with revision due to any cause considered an end point. Calculations were performed with the statistical analysis program R (version 2.14.1).

## Results

### Principal judgment criterion

The survival rate was calculated, with the revision of the implant, irrespective of the cause, considered an end point. The survival rate, analyzed according to the Kaplan-Meier method, was 97% at 5 years (95% confidence interval, 83.6-99.6) and 85% at 10 years (95% confidence interval, 68.3-93.7) (Fig. 1).

### Secondary judgment criteria

#### Clinical results

At an average follow-up of 7 years (2-16 years), the mean MEPS score was 91 points (range, 55-100 points) and the QuickDASH score was 34 points (range, 0-75 points). Patients had no or minimal pain in 92.5% of cases. All elbows were stable. There was a significant improvement in MEPS score and in all range of motion at latest follow-up in comparison to preoperative values ( $P = .0001$ ) (Table I). Strength in flexion was normal in 44 cases (81%). There was a slight diminution of strength in 9 cases and severe diminution in 1 case. On the other hand, a loss of extension strength was observed in 19 cases (35%), 15 of which showed moderate loss and 4 of which showed severe loss. At latest follow-up, results according to MEPS were excellent in 38 cases (70%), good in 11 cases (20%), moderate in 3 cases (6%), and poor in 2 cases (4%).

#### Radiography results

At latest follow-up, periprosthetic humeral lucent lines were found in 6 cases (11%), including 1 type 1, 1 type 2, 1 type 3, and 3 type 4. Periprosthetic ulnar lucent lines were observed

**Table I** Preoperative and latest follow-up functional results

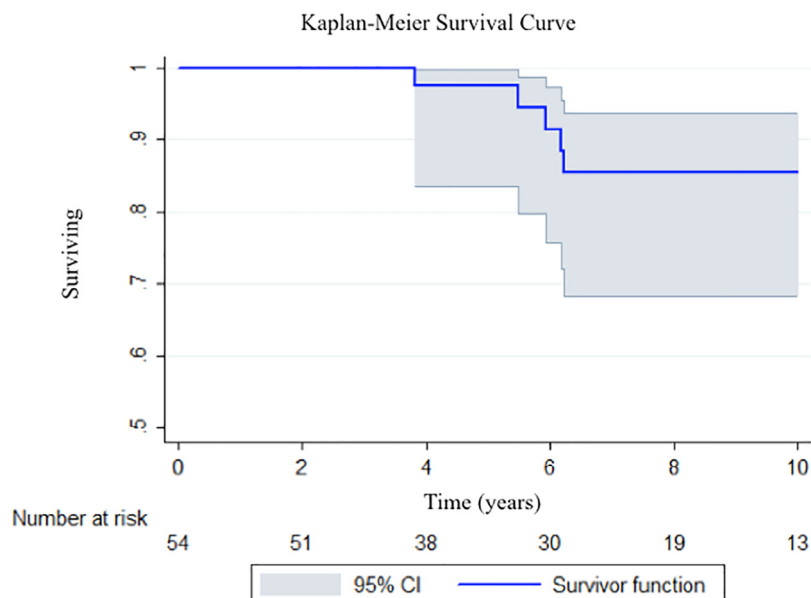
	Preoperative	Latest follow-up	<i>P</i>
	Mean $\pm$ standard deviation	Mean $\pm$ standard deviation	
Flexion	121 $\pm$ 14	136 $\pm$ 12	$<10^{-4}$
Extension	42 $\pm$ 18	23 $\pm$ 16	$<10^{-4}$
Arc of flexion-extension	78 $\pm$ 27	110 $\pm$ 25	$<10^{-4}$
Pronation	53 $\pm$ 24	69 $\pm$ 14	$<10^{-4}$
Supination	47 $\pm$ 28	70 $\pm$ 16	$<10^{-4}$
Arc of pronation-supination	100 $\pm$ 49	138 $\pm$ 27	$<10^{-4}$
MEPS score	37 $\pm$ 11	91 $\pm$ 12	$<10^{-4}$
Pain	5 $\pm$ 7	40 $\pm$ 9	$<10^{-4}$
Mobility	15 $\pm$ 4	18 $\pm$ 2	$<10^{-4}$
Stability	5 $\pm$ 3	10 $\pm$ 1	$<10^{-4}$
Function	12 $\pm$ 5	22 $\pm$ 4	$<10^{-4}$

MEPS, Mayo Elbow Performance Score.

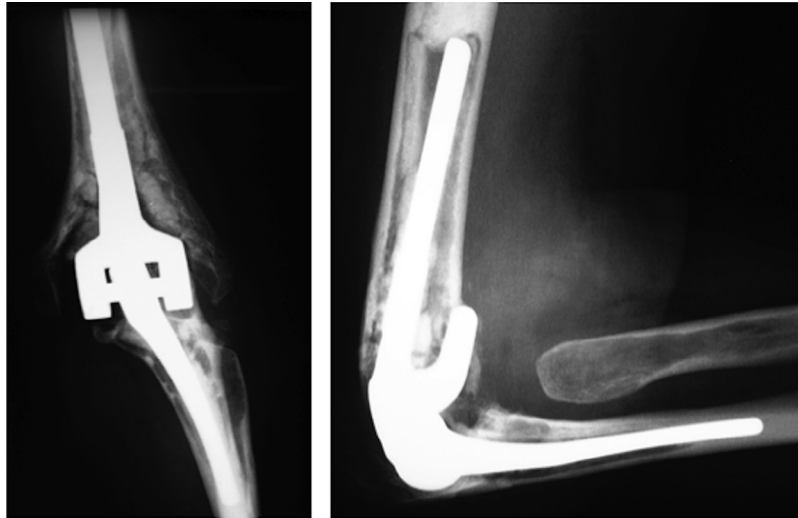
in 6 cases, 2 type 1 and 4 type 4. Implant loosening was observed for 3 humeral and 4 ulnar implants (Fig. 2). Bushing wear was observed in 16 cases (29%); it was moderate for 11 cases and severe for 5 cases.

### Complications and revisions

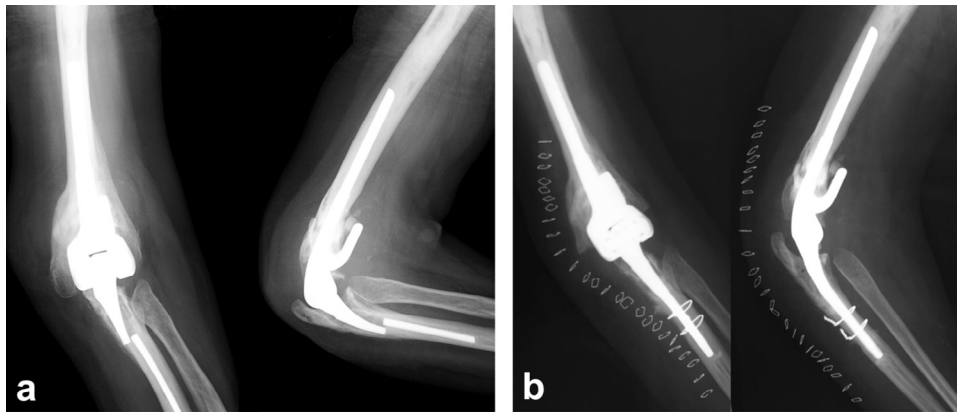
There were 14 complications (26%). Weakness of the triceps was noted in 4 cases. Ulnar nerve lesion involving paresthesia without sensory-motor deficiency was observed in 3 cases, but all cases resolved spontaneously. Seven complications (13%) required surgical revision. Deep infection was found in 3 cases (5.5%), for which 2 required surgery for resection



**Figure 1** Kaplan-Meier survivorship curve with revision surgery for all causes as the end point, with 95% confidence interval (CI).



**Figure 2** Bipolar loosening at 6 years after initial surgery.



**Figure 3** (A) Elbow radiographs, anteroposterior and lateral views of the ulnar component fracture. (B) Postoperative elbow radiographs, anteroposterior and lateral views after replacement of the ulnar implant. A diaphyseal corticotomy was performed to remove the broken ulnar component.

arthroplasty and 1 for bipolar prosthesis replacement. Among 3 cases of aseptic implant loosening, 2 cases were symptomatic, including 1 ulnar component loosening that required ulnar implant replacement and 1 bipolar implant loosening that required bipolar prosthetic replacement. One asymptomatic humeral loosening did not require surgical revision. One fracture of the ulnar implant was observed and required replacement of the ulnar implant (Fig. 3), and a periprosthetic fracture of the ulna was treated orthopedically. None of the patients with bushing wear (29%) required exchange of bushings.

## Discussion

The results of this study confirm our hypothesis that the semiconstrained Coonrad-Morrey prosthesis is viable in the long term, with a survival rate of 80% at 10 years. Few studies have evaluated the long-term results of the Coonrad-Morrey

prosthesis in RA. Indeed, results from the longest follow-up study, published by Gill and Morrey,<sup>4</sup> of 78 prostheses carried out in the context of RA showed a survival rate of 94.4% at 5 years and 92.4% at 10 years. This study was recently updated by Sanchez-Sotelo et al,<sup>20</sup> who reviewed 461 primary total elbow arthroplasties using the Coonrad-Morrey prosthesis performed in 387 patients with RA with 10 years of median follow-up (range, 2-30 years). The rate of survivorship free of implant revision or removal for any reason was 92% at 10 years, 83% at 15 years, and 68% at 20 years. The survivorship at 20 years was 88% with revision due to aseptic loosening as the end point and 89% with isolated bushing exchange as the end point. The survival rate in our study, 97% at 5 years and 85% at 10 years, was lower than that reported by the prosthesis designer's study but comparable to survival rates reported in the literature. A study derived from the Finnish Arthroplasty Register,<sup>21</sup> which evaluated the different types of total elbow prosthesis in RA, found no difference between survival rates for unconstrained prostheses,

Souter-Strathclyde (n = 912) and i.B.P/Kudo (n = 218), and semiconstrained prostheses, Coonrad-Morrey (n = 164) and NESimplavit/Norway (n = 63). The overall survival rate for the implants at 10 years was 83% (95% confidence interval, 81-86). A comparative study by Little et al<sup>10</sup> found the survival rate at 5 years to be 85% for the Souter-Strathclyde prosthesis, 93% for the Kudo prosthesis, and 90% for the Coonrad-Morrey prosthesis, with no significant differences. The functional results for these 3 prostheses were equivalent, with the Coonrad-Morrey semiconstrained prosthesis showing an advantage for preventing the risk of dislocation without increasing the rate of loosening. Prasad and Dent<sup>18</sup> evaluated the Souter-Strathclyde prosthesis (n = 44; mean follow-up of 108 months) and the Coonrad-Morrey prosthesis (n = 55; mean follow-up of 60 months) in RA and found the survival rate at 5 years to be 92.9% and 100%, respectively. The Scottish Arthroplasty Project,<sup>7</sup> which assessed the outcome of 1146 total elbow prostheses, 79% of which were implemented because of an inflammatory arthropathy, found that a better survival rate was associated with implants that were carried out by experienced surgeons who performed >10 implants per year.

The primary indication for total elbow arthroplasty in severe RA of the elbow is pain and, to a lesser extent, loss of mobility and functional limitation. In the study of Gill and Morrey,<sup>4</sup> reviewing 78 Coonrad-Morrey prostheses performed for RA of the elbow, 46 with an average follow-up of 136 months (120-184 months) showed satisfactory results with a MEPS score of 90 points in 91% of cases at latest follow-up evaluation. Furthermore, 98% of elbows presented with minimal or no pain, and all cases regained normal functional elbow motion and elbow stability. In the study of Sanchez-Sotelo et al,<sup>20</sup> the MEPS was 90 points, and pain was graded mild or absent in 87% of the elbows. In our study, at mean follow-up of 7 years, the mean MEPS was 91 points and the QuickDASH score was 34 points. Patients had minimal or no pain in 92.5% of cases, and all elbows were stable. Mansat et al<sup>11</sup> evaluated 78 Coonrad-Morrey prostheses that were performed for different conditions and found that at a mean follow-up of 5 years, patients treated for inflammatory arthritis had better functional results than those treated for traumatic conditions.

Despite an improvement in pain level and function, the complication and revision rates remained high compared with those of shoulder, hip, and knee prostheses. In our study, the complication rate was 26% and the revision rate was 11%. The rate of infection (5.5%) was higher than the rates of other arthroplasties but comparable to previously published infection rates for total elbow prostheses.<sup>10,20,22,23</sup> Infection rate may appear higher in patients suffering RA because of a modification of the immune response as a result of medical treatment. Bushing wear at the position of the hinge was found in 29% of cases. None of these patients required revision surgery for isolated replacement of the bushing. Lee et al<sup>8</sup> found a greater risk of bushing wear in younger patients with post-traumatic arthritis or with severe initial deformation. Pham et al<sup>16</sup> reported

1 case of iterative revision surgery for polyethylene bushing wear without implant loosening, requiring a custom-designed locking hinge to stabilize the implants. Finally, a study by Mansat et al,<sup>12</sup> evaluating 15 Coonrad-Morrey prostheses at >10-year follow-up, found a correlation between bushing wear and the follow-up. Lucent lines were observed around the humeral component in 6 cases and around the ulnar component in 6 cases, requiring a revision mainly at the ulna. Loosening was found mainly around the polymethyl methacrylate precoated ulnar component that is no longer used. Hildebrand et al<sup>5</sup> had already pointed out this complication in their series. It seems that with the titanium plasma-spray coating ulnar component used nowadays, the incidence of lucent lines decreases.<sup>20,22</sup>

The limitations of our study were its retrospective and noncomparative nature. Not all patients had the same follow-up, which could influence the survival analysis. However, our study represented a continuous series carried out in a single center, using a single type of semiconstrained prosthesis and an identical surgical technique in all patients. The strength of our study was the long follow-up (mean follow-up of 7 years and maximum follow-up of 16 years), which allows us to evaluate the long-term reliability of this implant in RA.

## Conclusion

The Coonrad-Morrey semiconstrained prosthesis in RA gave satisfactory results in the long term, with a survival rate of 85% at 10 years of follow-up. The clinical results are satisfactory in 90% of cases with the recuperation of a pain-free, functional, and stable elbow. The complication rate is not negligible with the follow-up, and complications include predominantly infections, bushing wear, and implant loosening, particularly around the ulnar component.

## Disclaimer

The authors, their immediate families, and any research foundations with which they are affiliated have not received any financial payments or other benefits from any commercial entity related to the subject of this article.

## References

1. Beaton DE, Wright JG, Katz JN, Upper Extremity Collaborative Group. Development of the QuickDASH: comparison of three item-reduction approaches. *J Bone Joint Surg Am* 2005;87:1038-46. <http://dx.doi.org/10.2106/JBJS.D.02060>
2. Ewald FC, Simmons ED, Sullivan JA, Thomas WH, Scott RD, Poss R, et al. Capiteltocondylar total elbow replacement in rheumatoid arthritis. Long-term results. *J Bone Joint Surg Am* 1993;75:498-507.
3. Faber KJ, Cordy ME, Milne AD, Chess DG, King GJ, Johnson JA. Advanced cement technique improves fixation in elbow arthroplasty. *Clin Orthop* 1997;334:150-6.

4. Gill DR, Morrey BF. The Coonrad-Morrey total elbow arthroplasty in patients who have rheumatoid arthritis. A ten to fifteen-year follow-up study. *J Bone Joint Surg Am* 1998;80:1327-35.
5. Hildebrand KA, Patterson SD, Regan WD, MacDermid JC, King GJ. Functional outcome of semiconstrained total elbow arthroplasty. *J Bone Joint Surg Am* 2000;82:1379-86.
6. Ikävalko M, Lehto MUK, Repo A, Kautiainen H, Hämäläinen M. The Souter-Strathclyde elbow arthroplasty. A clinical and radiological study of 525 consecutive cases. *J Bone Joint Surg Br* 2002;84:77-82. <http://dx.doi.org/10.1302/0301-620X.84B1.11848>
7. Jenkins PJ, Watts AC, Norwood T, Duckworth AD, Rymaszewski LA, McEachan JE. Total elbow replacement: outcome of 1,146 arthroplasties from the Scottish Arthroplasty Project. *Acta Orthop* 2013;84:119-23. <http://dx.doi.org/10.3109/17453674.2013.784658>
8. Lee BP, Adams RA, Morrey BF. Polyethylene wear after total elbow arthroplasty. *J Bone Joint Surg Am* 2005;87:1080-7. <http://dx.doi.org/10.2106/JBJS.D.02163>
9. Little CP, Graham AJ, Carr AJ. Total elbow arthroplasty: a systematic review of the literature in the English language until the end of 2003. *J Bone Joint Surg Br* 2005;87:437-44. <http://dx.doi.org/10.1302/0301-620X.87B4.15692>
10. Little CP, Graham AJ, Karatzas G, Woods DA, Carr AJ. Outcomes of total elbow arthroplasty for rheumatoid arthritis: comparative study of three implants. *J Bone Joint Surg Am* 2005;87:2439-48. <http://dx.doi.org/10.2106/JBJS.D.02927>
11. Mansat P, Bonneville N, Rongièrès M, Mansat M, Bonneville P. Experience with the Coonrad-Morrey total elbow arthroplasty: 78 consecutive total elbow arthroplasties reviewed with an average 5 years of follow-up. *J Shoulder Elbow Surg* 2013;22:1461-8. <http://dx.doi.org/10.1016/j.jse.2013.07.042>
12. Mansat P, Bonneville N, Rongièrès M, Mansat M, Bonneville P, French Society for Shoulder and Elbow SOFEC. Results with a minimum of 10 years follow-up of the Coonrad/Morrey total elbow arthroplasty. *Orthop Traumatol Surg Res* 2013;99(Suppl):S337-43. <http://dx.doi.org/10.1016/j.otsr.2013.07.002>
13. Matheson LN, Melhorn JM, Mayer TG, Theodore BR, Gatchel RJ. Reliability of a visual analog version of the QuickDASH. *J Bone Joint Surg Am* 2006;88:1782-7. <http://dx.doi.org/10.2106/JBJS.F.00406>
14. Morrey BF, Adams RA. Semiconstrained arthroplasty for the treatment of rheumatoid arthritis of the elbow. *J Bone Joint Surg Am* 1992;74:479-90.
15. Morrey BF, Bryan RS, Dobyns JH, Linscheid RL. Total elbow arthroplasty. A five-year experience at the Mayo Clinic. *J Bone Joint Surg Am* 1981;63:1050-63.
16. Pham TT, Bonneville N, Rongièrès M, Bonneville P, Mansat P. Mechanical failure of the Coonrad-Morrey linked total elbow arthroplasty: a case report. *Orthop Traumatol Surg Res* 2014;100:831-4. <http://dx.doi.org/10.1016/j.otsr.2014.07.013>
17. Pöll RG, Rozing PM. Use of the Souter-Strathclyde total elbow prosthesis in patients who have rheumatoid arthritis. *J Bone Joint Surg Am* 1991;73:1227-33.
18. Prasad N, Dent C. Outcome of total elbow replacement for rheumatoid arthritis: single surgeon's series with Souter-Strathclyde and Coonrad-Morrey prosthesis. *J Shoulder Elbow Surg* 2010;19:376-83. <http://dx.doi.org/10.1016/j.jse.2009.09.016>
19. Sanchez-Sotelo J. Elbow rheumatoid elbow: surgical treatment options. *Curr Rev Musculoskelet Med* 2016;9:224-31. <http://dx.doi.org/10.1007/s12178-016-9328-9>
20. Sanchez-Sotelo J, Baghdadi YMK, Morrey BF. Primary linked semiconstrained total elbow arthroplasty for rheumatoid arthritis. A single-institution experience with 461 elbows over three decades. *J Bone Joint Surg Am* 2016;98:1741-8. <http://dx.doi.org/10.2106/JBJS.15.00649>
21. Skyttä ET, Eskelinen A, Paavolainen P, Ikävalko M, Remes V. Total elbow arthroplasty in rheumatoid arthritis: a population-based study from the Finnish Arthroplasty Register. *Acta Orthop* 2009;80:472-7. <http://dx.doi.org/10.3109/17453670903110642>
22. Toulemonde J, Ancelin D, Azoulay V, Bonneville N, Rongièrès M, Mansat P. Complications and revisions after semi-constrained total elbow arthroplasty: a mono-centre analysis of one hundred cases. *Int Orthop* 2016;40:73-80. <http://dx.doi.org/10.1007/s00264-015-3008-z>
23. Voloshin I, Schippert DW, Kakar S, Kaye EK, Morrey BF. Complications of total elbow replacement: a systematic review. *J Shoulder Elbow Surg* 2011;20:158-68. <http://dx.doi.org/10.1016/j.jse.2010.08.026>
24. Weiland AJ, Weiss AP, Wills RP, Moore JR. Capitellocondylar total elbow replacement. A long-term follow-up study. *J Bone Joint Surg Am* 1989;71:217-22.