

Review Article

Bleomycin-Induced Lung Injury

Tomás Reinert, Clarissa Serodio da Rocha Baldotto, Frederico Arthur Pereira Nunes, and Adriana Alves de Souza Scheliga

Serviço de Oncologia Clínica, Instituto Nacional de Câncer (INCA), Praça da Cruz Vermelha 23, 20230-130 Rio de Janeiro, RJ, Brazil

Correspondence should be addressed to Tomás Reinert; tomasreinert@hotmail.com

Received 8 April 2013; Accepted 16 September 2013

Academic Editor: Rainald Knecht

Copyright © 2013 Tomás Reinert et al. This is an open access article distributed under the Creative Commons Attribution License, which permits unrestricted use, distribution, and reproduction in any medium, provided the original work is properly cited.

Bleomycin is a chemotherapeutic agent commonly used to treat curable diseases such as germinative tumors and Hodgkin's lymphoma. The major limitation of bleomycin therapy is pulmonary toxicity, which can be life threatening in up to 10% of patients receiving the drug. The mechanism of bleomycin-induced pneumonitis (BIP) involves oxidative damage, relative deficiency of the deactivating enzyme bleomycin hydrolase, genetic susceptibility, and the elaboration of inflammatory cytokines. Ultimately, BIP can progress to lung fibrosis. The diagnosis of BIP is established by the combination of systemic symptoms, radiological and histological findings, and respiratory function tests abnormalities, while other disorders should be excluded. Although the diagnosis and pathophysiology of this disease have been better characterized over the past few years, there is no effective therapy for the disease. In general, the clinical picture is extremely complex. A greater understanding of the BIP pathogenesis may lead to the development of new agents capable of preventing or even treating the injury already present. Physicians who prescribe bleomycin must be aware of the potential pulmonary toxicity, especially in the presence of risk factors. This review will focus on BIP, mainly regarding recent advances and perspectives in diagnosis and treatment.

1. Introduction

Bleomycin is one of the first described chemotherapeutic agents and has been used for cancer treatment for many years. Despite the development of new drugs in oncology, bleomycin remains an important component of chemotherapy regimens for curable diseases such as germinative tumors and Hodgkin's lymphoma. These neoplasias commonly affect young individuals, who may survive for long periods. In this regard, early diagnosis and treatment, and prevention of limiting toxicities such as bleomycin-induced lung injury, is crucial. This review addresses this important side effect, focusing on recent advances and perspectives on diagnosis and treatment.

2. Bleomycin Pharmacology

An antibiotic agent with antitumor activity, bleomycin was discovered by Umezawa in 1966 and was originally isolated from the fungus *Streptomyces verticillus*. Bleomycin exerts its antitumor effect by inducing tumor cell death, while

inhibition of tumor angiogenesis may also be important. It is most commonly used as part of adriamycin, bleomycin, vinblastine, and dacarbazine (ABVD), the standard chemotherapeutic regimen for the treatment of Hodgkin's disease, and bleomycin, etoposide, and cisplatin (BEP), used for the treatment of germ-cell tumors. It is also used in the treatment of several tumor types, such as Kaposi's sarcoma, cervical cancer, and squamous cell carcinomas of the head and neck [1]. Recently, percutaneous sclerotherapy by using bleomycin is being successfully used to provide symptomatic relief to patients with craniofacial venous malformations and lymphangiomas [2].

As small peptide with a molecular weight of 1,500, bleomycin contains a DNA-binding region and an iron-binding region (at opposite ends of the molecule). Iron is an essential cofactor for free radical generation and the cytotoxic activity of bleomycin. Bleomycin forms a complex with Fe^{2+} , which is subsequently oxidized to Fe^{3+} , resulting in the reduction of oxygen to free radicals. These free radicals cause single- and double-strand DNA breaks, which ultimately lead to cell death [3]. Moreover, bleomycin mediates the oxidative

degradation of all major classes of cellular RNA. The effects of bleomycin are cell cycle specific, with its main effects occurring during the G2 and M phases of the cell cycle [4].

After intravenous administration, there is rapid biphasic disappearance from the circulation. The terminal half-life is approximately 3 h in patients with normal renal function. Bleomycin is rapidly inactivated in tissues, especially the liver and kidneys, by the enzyme bleomycin hydrolase. Elimination of bleomycin primarily occurs via the kidneys, with 50–70% of a given dose being excreted unchanged in the urine. Patients with impaired renal function may experience increased drug accumulation and are at risk of increased toxicity. Dose reduction is required in the presence of renal dysfunction. Phenothiazines enhance the activity of bleomycin by competing with liver P450 enzymes. Cisplatin reduces the renal clearance of bleomycin and in doing so may enhance toxicity [5].

3. Common Side Effects

Skin reactions are the most common side effects and include erythema, hyperpigmentation of the skin, striae, and vesiculation. Skin peeling, thickening of the skin and nail beds, hyperkeratosis, and ulceration may also occur. These manifestations usually occur in the second and third weeks after treatment, when the cumulative dose has reached 150–200 U. Directly after its administration, fever chills and sometimes hypotension can occur. Other common side effects are alopecia, stomatitis, and fatigue. Vascular events, including myocardial infarction, stroke, and Raynaud's phenomenon, are occasionally reported [1, 5].

The major limitation of bleomycin therapy is usually pulmonary toxicity, which can be life threatening and has been described in up to 10% of patients receiving the drug. One of the potential determinants of bleomycin toxicity is bleomycin hydrolase, the enzyme that is primarily responsible for metabolizing bleomycin to nontoxic molecules. Interestingly, the two organs that are the most common sites of bleomycin toxicity (the lungs and the skin) have the lowest levels of the enzyme. Due to the feasibility of cloning the gene that encodes bleomycin hydrolase, studies are now needed to determine whether genetic variability in this enzyme accounts for individual susceptibility to or protection from bleomycin-induced pulmonary toxicity [6].

4. Clinical Features

Several distinct pulmonary syndromes have been linked to the use of bleomycin, including bronchiolitis obliterans with organizing pneumonia (BOOP) [7], eosinophilic hypersensitivity, and, most commonly, interstitial pneumonitis, which may ultimately progress to fibrosis [1]. The latter, bleomycin-induced pneumonitis (BIP), occurs in 0 to 46% of patients treated with bleomycin-containing chemotherapy, depending on the diagnostic criteria used [8]. A reasonable estimate of BIP incidence is 10%. The mortality of patients with BIP has been reported to be approximately 10–20% in patients who develop bleomycin-induced lung injury (2–3% of all patients

treated with bleomycin) [9]. To our knowledge, there are no reported cases of BIP secondary to the use of intralesional bleomycin for the treatment of vascular anomalies [10].

While BIP normally develops gradually during treatment, the development of BIP up to two years after discontinuation of bleomycin therapy has also been reported [11]. The clinical diagnosis of BIP is difficult and sometimes delayed by its similarity to other conditions that are often encountered in cancer patients, such as respiratory tract infections, pulmonary metastasis, and lymphangitic carcinoma. Bleomycin-induced hypersensitivity pneumonitis may present with more rapidly progressive symptoms.

The most common symptoms are exertional dyspnea and nonproductive cough. With progressive pneumonitis, dyspnea at rest, tachypnea, and cyanosis may occur. Physical examination of the lungs may be normal or may reveal end-inspiratory bibasilar crepitations or rhonchi. Pleural rubbing and finger clubbing are unusual [1].

Because of the resemblance of the symptoms of BIP with other diseases, the diagnosis of BIP is often one of exclusion. Infectious diseases are often excluded by culture and Gram-staining of sputum, polymerase chain reaction analysis of pathogens such as viruses, serology, or identification of antigens of pneumonia-causing pathogens. Patients have often been treated unsuccessfully with antibiotics because the suspicion of pneumonia before the diagnosis is established. *Pneumocystis jiroveci* pneumonia (PJP) should always be investigated. The clinical and radiological features of PJP (dyspnea, dry cough, bilateral infiltrates, and ground-glass opacities) may resemble those of bleomycin-induced pneumonitis. PJP incidence is increased in patients with non-Hodgkin's lymphoma and those receiving long-term steroids. Empirical treatment of PJP is recommended in cases of clinical suspicion [12]. Patients who survive an episode of BIP almost always recover completely, with disappearance of symptoms, signs, and disturbances of pulmonary function [13].

5. Pathogenesis

The mechanism of bleomycin-induced lung injury is not entirely clear but likely involves oxidative damage, relative deficiency of the deactivating enzyme bleomycin hydrolase, genetic susceptibility, and elaboration of inflammatory cytokines [1].

Bleomycin induces the generation of reactive oxygen radicals by forming a complex with Fe^{3+} . Consistent with a direct pathologic role for this mechanism, iron chelators ameliorate the pulmonary toxicity of bleomycin in animal models [14]. Reactive oxygen species can produce direct toxicity through participation in redox reactions and subsequent fatty acid oxidation, which leads to membrane instability. Oxidants can cause inflammatory reactions within the lung. For example, the oxidation of arachidonic acid is the initial step in the metabolic cascade that produces active mediators including prostaglandins and leukotrienes. Cytokines such as interleukin-1, macrophage inflammatory protein-1, platelet-derived growth factor (PDGF), and transforming growth

factor (TGF)- β are released from alveolar macrophages in animal models of bleomycin toxicity, resulting in fibrosis [15]. Damage and activation of alveolar epithelial cells may result in the release of cytokines and growth factors that stimulate proliferation of myofibroblasts and secretion of a pathologic extracellular matrix, leading to fibrosis.

Specifically, TGF- β , PDGF receptor- α (PDGFR- α), and tumor necrosis factor- (TNF)- α are believed to stimulate the transformation, proliferation, and accumulation of fibroblasts, which leads to the deposition of extracellular matrix. The progressive accumulation of this collagen matrix causes distortion and destruction of alveolar structures and, eventually, loss of lung function. In animal models, it has been demonstrated that PDGFR- α expression is increased in BIP. PDGFR- α has also been shown to be increased in epithelial cells and alveolar macrophages in the lungs of patients with idiopathic pulmonary fibrosis [16]. Recent evidence obtained using a bleomycin-induced lung fibrosis model indicates that some fibroblasts in fibrosis may be formed from bone marrow progenitors, as well as from epithelial cells through epithelial-mesenchymal transition [17].

Cytotoxic drugs may also affect the local immune system. Because the lung is exposed to numerous substances that can activate its immune system, there appears to be pulmonary immune tolerance, which avoids overreactions. This tolerance may, in part, be the result of an effector and suppressor cell balance. Cytotoxic drugs can alter the normal balance, leading to tissue damage [18].

Other homeostatic systems within the lung can also be affected, such as the balance between collagen formation and collagenolysis. Bleomycin may upregulate collagen synthesis by modulating fibroblast proliferation through a TGF- β response. Excessive collagen deposition may result in severe, irreversible pulmonary fibrosis. Bleomycin also has profound effects on the fibrinolytic system, altering the balance between fibrin deposition and fibrinolysis on the alveolar surface, thereby leading to fibrin deposition [19].

The alveolar macrophage is thought to play a central role in the development of bleomycin-induced lung injury due to its ability to induce the release of a number of effector molecules (e.g., cytokines, lipid metabolites, and oxygen radicals). The mechanism by which alveolar macrophages are activated is unknown. Bleomycin receptors have been identified on the surfaces of rat alveolar macrophages, suggesting that macrophage activation may occur via a second messenger [20].

6. Histopathology

Gross lung specimens from subjects with bleomycin-induced lung injury typically demonstrate subpleural lung injury and fibrosis. Various forms of interstitial lung disease have been described, including end-stage fibrosis, nonspecific interstitial pneumonia, diffuse alveolar damage, organizing pneumonia, and hypersensitivity (eosinophilic) pneumonia. More than one of these patterns may be present at the same time [21].

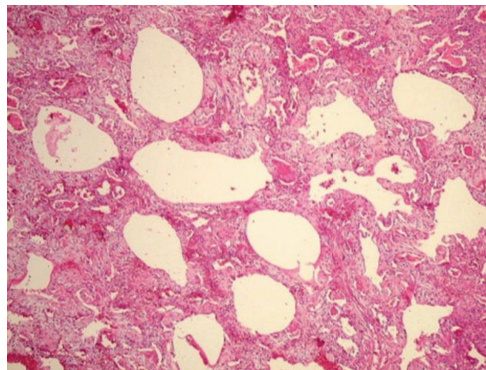


FIGURE 1

The main abnormalities in bleomycin-induced pulmonary toxicity occur in endothelial and epithelial cells. Destruction and desquamation of type I pneumocytes occur, as does the proliferation of type II pneumocytes. Mononuclear cell infiltration, fibroblast proliferation, and fibrosis are common findings. Bronchoalveolar lavage studies in patients with bleomycin-induced pneumonitis have shown the presence of polymorphonuclear alveolitis [22].

Figure 1 shows histology examination of biopsy proven BIP, revealing important disarrangement of alveolar architecture, interstitial fibrosis, intra-alveolar hemorrhage, and alveoli coated by hyperplastic type II pneumocytes, beyond chronic and acute infiltrated inflammatory.

7. Radiological Findings

Typical chest radiographic findings are bilateral, bibasilar infiltrates, sometimes followed by diffuse interstitial and alveolar infiltrates. Fine nodular densities and subpleural opacification with volume loss and blunting of costophrenic angles may also be present. These early findings may evolve to progressive consolidation and honeycombing [23]. Pneumothorax and pneumomediastinum are rare complications of bleomycin-induced pulmonary fibrosis [24].

High-resolution computed tomography (HRCT) of the chest is more sensitive than chest radiography in identifying lung abnormalities in bleomycin-exposed patients. HRCT patterns usually reflect the underlying histopathology [21]. Diffuse alveolar damage is associated with airspace consolidation and ground-glass opacities. Findings suggestive of end-stage fibrosis include extensive reticular markings, traction bronchiectasis, and honeycombing. Organizing pneumonia manifests as ground-glass opacities in a bilateral but asymmetric pattern or by airspace consolidation with a subpleural or peribronchial distribution. Organizing pneumonia may occasionally present as one or more nodular densities that may mimic tumor metastases [25].

Figures 2 and 3 show chest X-ray and CT scan demonstrating diffuse interstitial and alveolar damage with the presence of patchy bilateral air-space consolidation and areas of ground-glass attenuation.

A recent report evaluated the use of 18-fluorodeoxyglucose (FDG) positron emission tomography (PET)

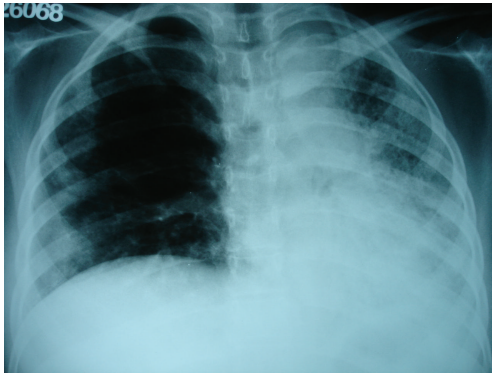


FIGURE 2

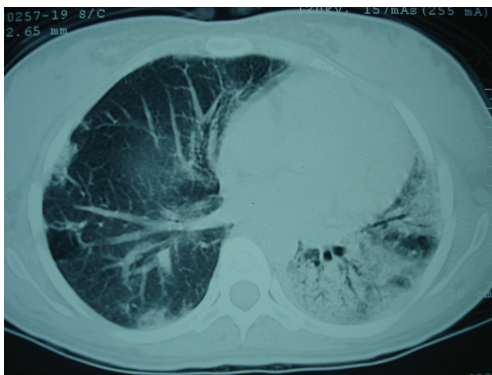


FIGURE 3

scanning in patients with BIP. It was shown that FDG uptake is lost after successful immunosuppressive treatment, even if the CT scan still shows abnormalities. This observation highlights the potential of PET scanning to distinguish between active inflammation and residual lung damage. As BIP is only reversible in the inflammatory phase and not in the fibrotic stage, PET might be useful for deciding whether to initiate/continue treatment with anti-inflammatory agents [26].

8. Assessment of Pulmonary Function

Many clinicians obtain a baseline set of pulmonary function test results before starting bleomycin. This practice is recommended in guidelines from the National Comprehensive Cancer Network (NCCN). The most common abnormalities associated with bleomycin-induced pulmonary toxicity are a reduced carbon monoxide diffusion capacity and a restrictive ventilator defect [18]. Isolated gas transport abnormalities, manifested by a decrease in diffusing capacity and/or arterial hypoxemia, especially with exercise, have been seen. In a randomized trial comparing a cisplatin plus etoposide regimen, with or without bleomycin, the reduction in carbon monoxide diffusion capacity was 14 to 20% in the bleomycin arms compared to 0 to 2% without bleomycin [27].

The usefulness of serial pulmonary function tests (PFTs) for identification of patients who are developing BIP was

assessed by Wolkowicz and colleagues [28]. Fifty-nine patients with nonseminomatous testicular carcinoma were treated with bleomycin-containing regimens. Serial PFTs, chest radiography and medical assessments were performed prior to each course of bleomycin. Nine patients (15.3%) developed pulmonary symptoms due to bleomycin and 23 (39%) had significant changes in chest X-ray films. The carbon monoxide diffusion capacity decreased significantly after bleomycin treatment and was the most sensitive indicator of its pulmonary effects. However, it failed to differentiate patients with BIP from those without BIP. Total lung capacity was found to be a much more specific indicator of BIP because its reduction correlated with the development of pulmonary symptoms and radiographic changes.

So far, no standard guidelines address restriction of bleomycin prescription according to pulmonary function test results. Most clinicians tend to avoid its use in patients who have previously suffered from moderate impairment of pulmonary function or extensive lung disease that could potentially compromise respiratory performance.

9. Risk Factors

Many studies have been performed to identify risk factors for the development of bleomycin-induced lung toxicity. However, most of these studies used different diagnostic criteria. Furthermore, to establish BIP diagnoses, many studies used lung function assessments that have since been shown not to be specific for BIP when bleomycin is used in a multidrug regimen. Therefore, comparison of studies is severely hampered; indeed some are not suitable for the purpose for which they were designed [1].

The risk of bleomycin-induced lung toxicity is higher in older patients. A British study reported that, among 835 patients with germ-cell tumors who were treated with bleomycin-containing regimens, age over 40 years was associated with a 2.3-fold higher risk of pulmonary complications [29]. In a study of 141 patients with Hodgkin's lymphoma who underwent regimens including bleomycin, the mean age of those with and without lung toxicity was 49 and 29 years, respectively (Martin, 2005). Cumulative doses of >400 U are also associated with higher rates of pulmonary toxicity. Although high-grade lung injury is very rare with cumulative doses <400 U, injury can occur at doses less than 50 U. Rapid intravenous infusion may also increase the risk of pulmonary toxicity [30].

Concomitant use of other chemotherapeutic agents is associated with an increased risk of pulmonary toxicity. This association is classically demonstrated with cisplatin, but there are reports of an increase in the risk of lung toxicity with regimens containing cyclophosphamide and gemcitabine. At least some data suggest that high cumulative doses of cisplatin also contribute to late impairment of pulmonary function and restrictive lung disease in long-term testicular cancer survivors. Since more than 80% of bleomycin is eliminated by the kidneys in normal individuals, renal insufficiency is an established risk factor for bleomycin toxicity [31].

The evidence that inhalation of high oxygen concentrations may increase the risk of pulmonary toxicity in humans is largely anecdotal. Nonetheless, the anecdotal data from humans, combined with the results of laboratory studies in animals, have led to widespread recommendations for lifelong avoidance of high concentrations of supplemental oxygen in patients previously exposed to bleomycin, unless it is necessary to maintain adequate arterial oxygen saturation [32].

Thoracic irradiation increases the risk of bleomycin-induced lung toxicity. It is unclear whether a long interval between irradiation and administration of bleomycin eliminates the increased risk of lung injury. However, preliminary evidence from a study of 15 patients with advanced-stage Hodgkin's lymphoma suggests that the risk of pulmonary toxicity during consolidative irradiation is low when there is an interval of at least four weeks between chemotherapy and irradiation [33].

Concomitant treatment with granulocyte colony-stimulating factor (G-CSF) was identified as a possible risk factor for the development of bleomycin-induced lung injury in animal studies. However, human data are conflicting. One reason for the conflicting results may be the confounding influence of age on the incidence of bleomycin-induced lung toxicity. Regardless, many clinicians avoid using G-CSF in conjunction with regimens containing bleomycin, particularly ABVD [34].

O'Sullivan et al. described a prospectively collected series of 835 patients with germ-cell tumors treated with bleomycin-containing regimens. Fifty-seven patients (6.8%) had bleomycin pulmonary toxicity, ranging from X-ray/computed tomography (CT) changes to dyspnea. Deaths in eight patients (1% of treated patients) were directly attributed to bleomycin-induced lung toxicity. The median time from the start of bleomycin administration to documented lung toxicity was 4.2 months (range 1.2–8.2 months). In a multivariate analysis, the factors that independently predicted increased risk of bleomycin-induced pulmonary toxicity were GFR < 80 mL/min [hazard ratio (HR) 3.3, 95% CI 1.4–8.0], age > 40 years (HR 2.3, 95% CI 1.2–4.1), stage IV disease at presentation (HR 2.6, 95% CI 1.2–4.1), and cumulative dose of bleomycin > 300,000 IU (HR 3.5, 95% CI 2–6) [29].

10. Prevention and Treatment

The most effective way to manage pulmonary toxicity associated with chemotherapeutic agents is to prevent it. One of the most efficient ways to prevent bleomycin-induced lung injury is to lower the total cumulative dose of bleomycin. Studies in patients with good-prognosis germ-cell cancer showed that bleomycin could not be omitted completely from combination chemotherapy without compromising results [35]. However, Einhorn et al. showed that lowering the total dose of bleomycin from 360 to 270 mg does not reduce the efficacy of treatment of good-prognosis disseminated testicular cancer [36]. In patients with an unacceptably high risk of developing bleomycin-induced pulmonary toxicity, physicians can consider treating with nonbleomycin-containing regimens.

In the treatment of germ-cell cancer, a regimen containing etoposide, ifosfamide, and cisplatin had the same efficacy as BEP but increased bone marrow suppression [37].

The other malignancy for which bleomycin is often applied is Hodgkin's disease. The total cumulative dose of bleomycin is 120 mg/m². Although the main cause of pulmonary toxicity during treatment is the applied radiotherapy, in patients at high risk of BIP, a non-bleomycin-containing regimen such as mechlorethamine, vincristine, procarbazine, and prednisone (MOPP) can be used [38]. The etoposide, vinblastine, and doxorubicin (EVA) regimen appears to have an overall survival (OS) outcome comparable to that of ABVD and unexpected lung toxicity [39]. Omitting radiotherapy in patients with early-stage Hodgkin's disease is a strategy that is gaining acceptance and that would significantly reduce the incidence of bleomycin-induced lung injury. A recently published trial showed that, among patients with stages I and IIA nonbulky Hodgkin's lymphoma, ABVD therapy alone, as compared with treatment that included subtotal nodal radiation therapy, was associated with higher OS owing to a lower rate of death from other causes. PET-CT is also becoming an important tool for safely suppressing the need for radiotherapy [40].

In animals, agents including soluble Fas antigen [41], IL-1 receptor antagonists [42], dexrazoxane [14], amifostine [43], and antibodies against TNF- α [44] and TGF- β [45] have been successfully tested for the prevention or attenuation of BIP. Recently, Dackor et al. showed that prostaglandin E₂ (PGE₂) protects murine lungs from bleomycin-induced pulmonary fibrosis and lung dysfunction. PGE₂ prevented the decline in lung static compliance and protected against lung fibrosis when it was administered before bleomycin challenge but had no therapeutic effect when administered after bleomycin challenge [46]. However, to our knowledge, no published studies have identified agents that may prevent bleomycin-induced pulmonary toxicity in humans.

Bleomycin should be discontinued in all patients with documented or strongly suspected bleomycin-induced lung injury. Treatment with glucocorticoids is reserved for patients with symptomatic lung toxicity as spontaneous resolution of asymptomatic radiographic opacities has been described [47]. Although no controlled studies in humans have systematically examined the efficacy of corticosteroids, a trial of these agents is probably warranted. Case reports and case series have described substantial recovery when significant inflammatory pneumonitis was present. The optimal dosing and duration of glucocorticoid therapy for bleomycin-induced lung injury are not known. Based on data from case series, most authors recommend initiating treatment with prednisone at 0.75 to 1 mg/kg. After four to eight weeks, the dose of prednisone is gradually tapered over an additional four to six months, in accordance with the patient's condition and clinical response. Short-term improvement occurs in 50 to 70% of glucocorticoid-treated patients, but symptoms may relapse when therapy is tapered [48]. Unlike the most common form of pulmonary pneumonitis, patients who present with disease patterns compatible with organizing

pneumonia and hypersensitivity pneumonia are known to respond much better to corticosteroid therapy.

Clinical response usually occurs within weeks rather than days and is most likely in those with a significant inflammatory component. Doses can be tapered slowly over weeks based on clinical response, with radiological improvements and improvements in pulmonary function lagging behind. Some clinicians argue that the improvements seen with corticosteroids in small study groups may well be due to incorrect diagnoses. Bleomycin-induced pneumonitis closely resembles cryptogenic organizing pneumonia, which is known to respond to corticosteroid therapy [33].

Bleomycin-induced pneumonitis is thought to resolve in the majority of patients over time, with improvements in pulmonary function and radiology at >15 months. Complete resolution of symptoms, signs, and abnormal radiology and pulmonary function test results are less likely if the diagnosis is delayed, if bleomycin therapy is continued, or if established fibrosis occurs [49]. Therefore, early suspicion is very important and may guarantee a better prognosis.

11. Future Perspectives

Increased knowledge of the pathogenesis of bleomycin-induced lung injury may lead to the development of agents capable of preventing or treating established BIP. Preclinical studies reporting promising results with therapies such as immunomodulators, tyrosine kinase inhibitors, monoclonal antibodies, anti-inflammatory agents, and transplantation of human amnion epithelial cells were recently published. Some of these therapies will be reviewed here.

Sirolimus, an immunosuppressant used to prevent rejection of transplanted organs, was effective in reducing fibrosis score in a bleomycin-induced pulmonary fibrosis model, especially in the early phases of the disease [50].

A study by Wang et al. recently showed that gefitinib reduces pulmonary fibrosis induced by bleomycin in mice and suggested that administration of small-molecule epidermal growth factor receptor (EGFR) tyrosine kinase inhibitors has the potential to prevent pulmonary fibrosis by inhibiting the proliferation of mesenchymal cells and that targeting tyrosine kinase receptors might be useful for the treatment of pulmonary fibrosis in humans [51].

Montelukast, a cysteinyl-leukotriene type 1 receptor antagonist used in the treatment of inflammatory lung disorders such as asthma, was studied in a mouse bleomycin-induced lung injury model. Treatment with montelukast significantly reduced the fibrotic area and hydroxyproline content in the fibrotic lungs of bleomycin-exposed mice. Montelukast exhibits its beneficial effects by inhibiting the overexpression of IL-6, IL-10, IL-13, and TGF- β 1 [52].

Nilotinib has been approved for the treatment of chronic myeloid leukemia in patients with resistance or intolerance to imatinib. Like imatinib, nilotinib selectively inhibits the tyrosine kinase activity of PDGFR. In a therapeutic model, nilotinib showed more potent antifibrotic effects than imatinib [53].

A recent report evaluated the influence of the renin-angiotensin system (RAS). Angiotensin-converting enzyme (ACE-) generated angiotensin II contributes to lung injury. ACE2, a recently discovered ACE homolog, acts as a negative regulator of the RAS and counterbalances the action of ACE. Treatment of mice with intraperitoneal recombinant human (rh) ACE2 (2 mg/kg) for 21 days improved survival, exercise capacity, and lung function and reduced lung inflammation and fibrosis. rhACE2 may have the potential to attenuate respiratory morbidity in patients with bleomycin-induced lung injury, as well as patients with acute respiratory distress syndrome of other causes [54].

Pravastatin is best known for its antilipidemic action. Recent studies have shown that statins have immunomodulatory and anti-inflammatory effects. In one recent study, pravastatin effectively attenuated histopathological changes, the accumulation of neutrophils, and the production of TNF- α in a mouse model of bleomycin-induced lung injury and pulmonary fibrosis [55].

The importance of HER2/HER3 signaling in reducing the effects of lung injury was recently demonstrated. Transgenic mice unable to signal through HER2/HER3 had significantly less bleomycin-induced pulmonary fibrosis and showed a survival benefit [56]. A recent preclinical study that evaluated the administration of 2C4, a monoclonal antibody directed against HER2, demonstrated that HER2/HER3 blockade reduced collagen deposition and changes in lung morphology. In addition, it resulted in a significant survival advantage with 50 versus 25% at 30 days. These results confirm that HER2 is a potential target that could be pharmacologically targeted to reduce lung fibrosis and remodeling after injury [57]. Human amnion epithelial cells (hAECs) have attracted recent attention as a promising source of cells for regenerative therapies, with reports suggesting that cells derived from human term amnion possess multipotent differentiation ability, low immunogenicity, and anti-inflammatory properties. Specifically, in animal models of lung disease characterized by significant loss of lung tissue secondary to chronic inflammation and fibrosis, the transplantation of hAECs has been shown to reduce both inflammation and subsequent fibrosis. A recent study performed using a mouse model of bleomycin-induced pulmonary fibrosis showed that transplantation of hAECs 24 h after the administration of bleomycin reduced expression of the genes encoding the proinflammatory cytokines TNF- α , TGF- β , IFN- γ , and IL-6. It also decreased subsequent pulmonary fibrosis, reducing pulmonary collagen deposition, levels of α -smooth muscle actin, and inflammatory cell infiltration. It was shown that hAECs are able to prevent the decline in pulmonary function associated with bleomycin-induced lung damage [58].

To our knowledge, the first publication reporting successful treatment of bleomycin-induced lung injury was a study describing a case of complete resolution of life-threatening bleomycin-induced pneumonitis after treatment with imatinib mesylate, a potent and specific receptor tyrosine kinase inhibitor of ABL, BCR-ABL, KIT, and PDGFR. A patient with Hodgkin's lymphoma who developed severe BIP after undergoing an ABVD regimen was completely cured with

imatinib mesylate after steroids and all other therapies had failed [59].

12. Conclusion

Bleomycin-induced lung injury is a major pulmonary toxicity. The mortality of this complication is high, ranging from 10 to 20%, and significantly impacts quality of life and five-year OS. The diagnosis of interstitial lung disease and BIP is particularly challenging and often depends on clinical, radiological, and cytological findings. Progress in understanding the mechanisms behind the therapeutic efficacy and unwanted toxicity of bleomycin, as well as elucidation of its biosynthetic pathway, may lead to the development of agents capable of preventing or treating BIP. Until then, physicians administering bleomycin should be aware of potential lung toxicity, especially in the presence of risk factors.

Conflict of Interests

There is no conflict of interests.

References

- [1] S. Sleijfer, "Bleomycin-induced pneumonitis," *Chest*, vol. 120, no. 2, pp. 617–624, 2001.
- [2] J. Spence, T. Krings, K. G. TerBrugge, L. B. Da Costa, and R. Agid, "Percutaneous sclerotherapy for facial venous malformations: Subjective clinical and objective MR imaging follow-up results," *American Journal of Neuroradiology*, vol. 31, no. 5, pp. 955–960, 2010.
- [3] R. M. Burger, J. Peisach, and S. B. Horwitz, "Activated bleomycin. A transient complex of drug, iron, and oxygen that degrades DNA," *The Journal of Biological Chemistry*, vol. 256, no. 22, pp. 11636–11644, 1981.
- [4] J. Chen and J. Stubbe, "Bleomycins: towards better therapeutics," *Nature Reviews Cancer*, vol. 5, no. 2, pp. 102–112, 2005.
- [5] E. Chu and V. T. DeVita Jr., *Cancer Chemotherapy Drug Manual*, Jones and Bartlett, Boston, Mass, USA, 2011.
- [6] A. A. Ferrando, A. M. Pendás, E. Llano, G. Velasco, R. Lidereau, and C. López-Otín, "Gene characterization, promoter analysis, and chromosomal localization of human bleomycin hydrolase," *The Journal of Biological Chemistry*, vol. 272, no. 52, pp. 33298–33304, 1997.
- [7] P. J. Santrach, F. B. Askin, R. J. Wells, R. G. Azizkhan, and D. F. Merten, "Nodular form of bleomycin-related pulmonary injury in patients with osteogenic sarcoma," *Cancer*, vol. 64, no. 4, pp. 806–811, 1989.
- [8] K. Jules-Elysee and D. A. White, "Bleomycin-induced pulmonary toxicity," *Clinics in Chest Medicine*, vol. 11, no. 1, pp. 1–20, 1990.
- [9] A. B. Simpson, J. Paul, J. Graham, and S. B. Kaye, "Fatal bleomycin pulmonary toxicity in the west of Scotland 1991–95: a review of patients with germ cell tumours," *British Journal of Cancer*, vol. 78, no. 8, pp. 1061–1066, 1998.
- [10] G. Kessell, S. Panchatsharam, E. Kothmann et al., "General anaesthesia for intralesional bleomycin therapy of vascular malformations: initial 3 yr experience," *British Journal of Anaesthesia*, vol. 102, no. 3, pp. 431–432, 2009.
- [11] I. Uzel, M. Ozguroglu, B. Uzel et al., "Delayed onset bleomycin-induced pneumonitis," *Urology*, vol. 66, no. 1, pp. 195e.23–195e.25, 2005.
- [12] G. Bollée, C. Sarfati, G. Thiéry et al., "Clinical picture of Pneumocystis jiroveci pneumonia in cancer patients," *Chest*, vol. 132, no. 4, pp. 1305–1310, 2007.
- [13] P. W. Van Barneveld, D. T. Sleijfer, T. W. van der Mark et al., "Natural course of bleomycin-induced pneumonitis. A follow-up study," *American Review of Respiratory Disease*, vol. 135, no. 1, pp. 48–51, 1987.
- [14] E. H. Herman, B. B. Hasinoff, J. Zhang et al., "Morphologic and morphometric evaluation of the effect of ICRF-187 on bleomycin-induced pulmonary toxicity," *Toxicology*, vol. 98, no. 1–3, pp. 163–175, 1995.
- [15] D. B. Chandler, "Possible mechanisms of bleomycin-induced fibrosis," *Clinics in Chest Medicine*, vol. 11, no. 1, pp. 21–30, 1990.
- [16] M. Yoshida, J. Sakuma, S. Hayashi et al., "A histologically distinctive interstitial pneumonia induced by overexpression of the interleukin 6, transforming growth factor β 1, or platelet-derived growth factor b gene," *Proceedings of the National Academy of Sciences of the United States of America*, vol. 92, no. 21, pp. 9570–9574, 1995.
- [17] K. Kuwano, N. Hagimoto, M. Kawasaki et al., "Essential roles of the Fas-Fas ligand pathway in the development of pulmonary fibrosis," *The Journal of Clinical Investigation*, vol. 104, no. 1, pp. 13–19, 1999.
- [18] J. A. D. Cooper Jr., D. A. White, and R. A. Matthay, "Drug-induced pulmonary disease. Part I: cytotoxic drugs," *American Review of Respiratory Disease*, vol. 133, no. 2, pp. 321–340, 1986.
- [19] S. L. King, A. C. Lichtler, D. W. Rowe et al., "Bleomycin stimulates pro- α 1(I) collagen promoter through transforming growth factor β response element by intracellular and extracellular signaling," *The Journal of Biological Chemistry*, vol. 269, no. 18, pp. 13156–13161, 1994.
- [20] E. M. Denholm and S. H. Phan, "Bleomycin binding sites on alveolar macrophages," *Journal of Leukocyte Biology*, vol. 48, no. 6, pp. 519–523, 1990.
- [21] C. Isabela, S. Silva, and N. L. Müller, "Drug-induced lung diseases: most common reaction patterns and corresponding CT manifestations," *Seminars in Ultrasound, CT and MRI*, vol. 27, no. 2, pp. 111–116, 2006.
- [22] D. A. White, M. G. Kris, and D. E. Stover, "Bronchoalveolar lavage cell populations in bleomycin lung toxicity," *Thorax*, vol. 42, no. 7, pp. 551–552, 1987.
- [23] M. De Lena, A. Guzzon, S. Monfardini, and G. Bonadonna, "Clinical, radiologic, and histopathologic studies on pulmonary toxicity induced by treatment with bleomycin (NSC-125066)," *Cancer Chemotherapy Reports*, vol. 56, no. 3, pp. 343–356, 1972.
- [24] T. Sikdar, D. Macvicar, and J. E. Husband, "Pneumomediastinum complicating bleomycin related lung damage," *British Journal of Radiology*, vol. 71, pp. 1202–1204, 1998.
- [25] M. B. Cohen, J. H. M. Austin, A. Smith-Vaniz, J. Lutzky, and M. M. Grimes, "Nodular bleomycin toxicity," *American Journal of Clinical Pathology*, vol. 92, no. 1, pp. 101–104, 1989.
- [26] T. Buchler, J. Bomanji, and S. M. Lee, "FDG-PET in bleomycin-induced pneumonitis following ABVD chemotherapy for Hodgkin's disease—a useful tool for monitoring pulmonary toxicity and disease activity," *Haematologica*, vol. 92, no. 11, pp. 120–121, 2007.

- [27] R. de Wit, G. Stoter, S. B. Kaye et al., "Importance of bleomycin in combination chemotherapy for good-prognosis testicular nonseminoma: a randomized study of the European Organization for Research and Treatment of Cancer Genitourinary Tract Cancer Cooperative Group," *Journal of Clinical Oncology*, vol. 15, no. 5, pp. 1837–1843, 1997.
- [28] J. Wolkowicz, J. Sturgeon, M. Rawji, and C. K. Chan, "Bleomycin-induced pulmonary function abnormalities," *Chest*, vol. 101, no. 1, pp. 97–101, 1992.
- [29] J. M. O'Sullivan, R. A. Huddart, A. R. Norman, J. Nicholls, D. P. Dearnaley, and A. Horwich, "Predicting the risk of bleomycin lung toxicity in patients with germ-cell tumours," *Annals of Oncology*, vol. 14, no. 1, pp. 91–96, 2003.
- [30] H. S. Haugnes, N. Aass, S. D. Fosså et al., "Pulmonary function in long-term survivors of testicular cancer," *Journal of Clinical Oncology*, vol. 27, no. 17, pp. 2779–2786, 2009.
- [31] K. Kawai, S. Hinotsu, M. Tomobe, and H. Akaza, "Serum creatinine level during chemotherapy for testicular cancer as a possible predictor of bleomycin-induced pulmonary toxicity," *Japanese Journal of Clinical Oncology*, vol. 28, no. 9, pp. 546–550, 1998.
- [32] S. M. Donat and D. A. Levy, "Bleomycin associated pulmonary toxicity: is perioperative oxygen restriction necessary?" *Journal of Urology*, vol. 160, no. 4, pp. 1347–1352, 1998.
- [33] S. Danson, F. Blackhall, P. Hulse, and M. Ranson, "Interstitial lung disease in lung cancer: Separating disease progression from treatment effects," *Drug Safety*, vol. 28, no. 2, pp. 103–113, 2005.
- [34] S. B. Saxman, C. R. Nichols, and L. H. Einhorn, "Pulmonary toxicity in patients with advanced-stage germ cell tumors receiving bleomycin with and without granulocyte colony stimulating factor," *Chest*, vol. 111, no. 3, pp. 657–660, 1997.
- [35] P. J. Loehrer, D. Johnson, P. Elson et al., "Importance of bleomycin in combination with chemotherapy for good-prognosis testicular non-seminoma," *Journal of Clinical Oncology*, vol. 15, pp. 1837–1843, 1997.
- [36] L. H. Einhorn, S. D. Williams, P. J. Loehrer et al., "Evaluation of optimal duration of chemotherapy in favorable-prognosis disseminated germ cell tumors: a Southeastern Cancer Study Group Protocol," *Journal of Clinical Oncology*, vol. 7, no. 3, pp. 387–391, 1989.
- [37] C. R. Nichols, P. J. Catalano, E. D. Crawford, N. J. Vogelzang, L. H. Einhorn, and P. J. Loehrer, "Randomized comparison of cisplatin and etoposide and either bleomycin or ifosfamide in treatment of advanced disseminated germ cell tumors: an Eastern Cooperative Oncology Group, Southwest Oncology Group, and cancer and leukemia group B study," *Journal of Clinical Oncology*, vol. 16, no. 4, pp. 1287–1293, 1998.
- [38] G. P. Canellos, J. R. Anderson, K. J. Propert et al., "Chemotherapy of advanced Hodgkin's disease with MOPP, ABVD, or MOPP alternating with ABVD," *The New England Journal of Medicine*, vol. 327, no. 21, pp. 1478–1484, 1992.
- [39] G. P. Canellos, J. Gollub, D. Neuberger, P. Mauch, and L. N. Shulman, "Primary systemic treatment of advanced Hodgkin's disease with EVA (etoposide, vinblastine, doxorubicin): 10-year follow-up," *Annals of Oncology*, vol. 14, no. 2, pp. 268–272, 2003.
- [40] R. M. Meyer, M. K. Gospodarowicz, J. M. Connors et al., "ABVD alone versus radiation-based therapy in limited-stage Hodgkin's lymphoma," *The New England Journal of Medicine*, vol. 366, no. 5, pp. 399–408, 2012.
- [41] N. Hashimoto, S. H. Phan, K. Imaizumi et al., "Endothelial-mesenchymal transition in bleomycin-induced pulmonary fibrosis," *American Journal of Respiratory Cell and Molecular Biology*, vol. 43, no. 2, pp. 161–172, 2010.
- [42] P. F. Piguet, C. Vesin, G. E. Grau, and R. C. Thompson, "Interleukin 1 receptor antagonist (IL-1ra) prevents or cures pulmonary fibrosis elicited in mice by bleomycin or silica," *Cytokine*, vol. 5, no. 1, pp. 57–61, 1993.
- [43] L. Nici and P. Calabresi, "Amifostine modulation of bleomycin-induced lung injury in rodents," *Seminars in Oncology*, vol. 26, no. 2, pp. 28–33, 1999.
- [44] P. F. Piguet, M. A. Collart, G. E. Grau, Y. Kapanci, and P. Vassalli, "Tumor necrosis factor/cachectin plays a key role in bleomycin-induced pneumopathy and fibrosis," *The Journal of Experimental Medicine*, vol. 170, no. 3, pp. 655–663, 1989.
- [45] S. N. Giri, D. M. Hyde, and M. A. Hollinger, "Effect of antibody to transforming growth factor β on bleomycin induced accumulation of lung collagen in mice," *Thorax*, vol. 48, no. 10, pp. 959–966, 1993.
- [46] R. T. Dackor, J. Cheng, J. W. Voltz et al., "Prostaglandin E2 protects murine lungs from bleomycin-induced pulmonary fibrosis and lung dysfunction," *American Journal of Physiology—Lung Cellular and Molecular Physiology*, vol. 301, no. 5, pp. L645–L655, 2011.
- [47] E. A. Bellamy, J. E. Husband, R. M. Blaquiére, and M. R. Law, "Bleomycin-related lung damage: CT evidence," *Radiology*, vol. 156, no. 1, pp. 155–158, 1985.
- [48] D. A. White and D. E. Stover, "Severe bleomycin-induced pneumonitis. Clinical features and response to corticosteroids," *Chest*, vol. 86, no. 5, pp. 723–728, 1984.
- [49] A. J. Fyfe and P. McKay, "Toxicities associated with bleomycin," *Journal of the Royal College of Physicians of Edinburgh*, vol. 40, no. 3, pp. 213–215, 2010.
- [50] B. Tulek, E. Kiyani, H. Toy, A. Kiyici, C. Narin, and M. Suerdem, "Anti-inflammatory and anti-fibrotic effects of sirolimus on bleomycin-induced pulmonary fibrosis in rats," *Clinical and Investigative Medicine*, vol. 34, no. 6, p. E341, 2011.
- [51] P. Wang, Q. Tian, Z.-X. Liang et al., "Gefitinib attenuates murine pulmonary fibrosis induced by bleomycin," *Chinese Medical Journal*, vol. 123, no. 16, pp. 2259–2264, 2010.
- [52] C. Shimbori, N. Shiota, and H. Okunishi, "Effects of montelukast, a cysteinyl-leukotriene type 1 receptor antagonist, on the pathogenesis of bleomycin-induced pulmonary fibrosis in mice," *European Journal of Pharmacology*, vol. 650, no. 1, pp. 424–430, 2011.
- [53] C. K. Rhee, S. H. Lee, H. K. Yoon et al., "Effect of nilotinib on bleomycin-induced acute lung injury and pulmonary fibrosis in mice," *Respiration*, vol. 82, no. 3, pp. 273–287, 2011.
- [54] G. J. Rey-Parra, A. Vadivel, L. Coltan et al., "Angiotensin converting enzyme 2 abrogates bleomycin-induced lung injury," *Journal of Molecular Medicine*, vol. 90, no. 6, pp. 637–647, 2012.
- [55] J. W. Kim, C. K. Rhee, T. J. Kim et al., "Effect of pravastatin on bleomycin-induced acute lung injury and pulmonary fibrosis," *Clinical and Experimental Pharmacology and Physiology*, vol. 37, no. 11, pp. 1055–1063, 2010.
- [56] P. D. Vermeer, L. A. Einwalter, T. O. Moninger et al., "Segregation of receptor and ligand regulates activation of epithelial growth factor receptor," *Nature*, vol. 422, no. 6929, pp. 322–326, 2003.
- [57] J. A. Faress, D. E. Nethery, E. F. O. Kern et al., "Bleomycin-induced pulmonary fibrosis is attenuated by a monoclonal antibody targeting HER2," *Journal of Applied Physiology*, vol. 103, no. 6, pp. 2077–2083, 2007.

- [58] S. Murphy, R. Lim, H. Dickinson et al., "Human amnion epithelial cells prevent bleomycin-induced lung injury and preserve lung function," *Cell Transplantation*, vol. 20, no. 6, pp. 909–923, 2011.
- [59] F. Carnevale-Schianca, S. Gallo, D. Rota-Scalabrini et al., "Complete resolution of life-threatening bleomycin-induced pneumonitis after treatment with imatinib mesylate in a patient with hodgkin's lymphoma: hope for severe chemotherapy-induced toxicity?" *Journal of Clinical Oncology*, vol. 29, no. 24, pp. e691–e693, 2011.



Hindawi
Submit your manuscripts at
<http://www.hindawi.com>

