

CASE REPORT

Diagnosing Pediatric Intussusception Through Bedside Ultrasound by Novice Emergency Department Sonographers: A Case Report

FARAH NA, ISMAIL MS

Department of Emergency Medicine, Faculty of Medicine, Universiti Kebangsaan Malaysia Medical Centre, Jalan Yaacob Latif, Bandar Tun Razak, 56000 Cheras, Kuala Lumpur, Malaysia.

ABSTRAK

Intususepsi merupakan satu kejadian kecemasan gastrousus yang terjadi dalam kalangan populasi pediatrik dan selalunya didiagnosa melalui kaedah radiologi barium enema atau ultrabunyi. Kebolehan menggunakan mesin ultrabunyi dalam kalangan pegawai perubatan yang menjalani sedikit latihan bagi mendiagnosa kes-kes sebegini di Jabatan Kecemasan adalah sangat membantu dalam mempercepatkan rawatan pesakit. Kami ingin mengemukakan satu kes melibatkan kanak-kanak berumur 7 bulan yang datang ke Jabatan Kecemasan dengan mengadu terdapat darah di dalam najisnya. Secara klinikal, beliau kelihatan dehidrasi, iritasi dan dalam kejutan yang terkompensasi. Terdapat kesakitan pada abdomen apabila ditekan tetapi ianya masih lembut dan tidak kembung. Tidak terdapat massa yang boleh dirasai di abdomen dan bunyi usus adalah normal. Resusitasi dengan cecair telah dimulakan dengan segera. Ujian ultrabunyi telah dilakukan oleh pegawai perubatan Jabatan Kecemasan dan mendapati satu massa berukuran 1.8cm x 2.5cm yang memberi kesan gelang gema-tinggi dan gema-rendah secara berselang-seli di kuadran bawah sebelah kanan abdomen yang kelihatan seperti tanda 'sasaran' sebuah intususepsi. X-ray supina abdomen tidak menunjukkan sebarang keganjilan. Apa yang dilihat dari ujian ultrabunyi pegawai perubatan Jabatan Kecemasan ini kemudiannya telah disahkan oleh pakar radiologi. Pesakit telah menjalani rawatan reduksi hidrostatik dan telah didiscaj dengan selamatnya.

Kata kunci: diagnosis, Jabatan Kecemasan, intususepsi, pediatrik, ultrabunyi

ABSTRACT

Intussusception is a common cause of gastrointestinal emergency in the paediatric population and it is usually diagnosed through Barium enema radiography or

Address for correspondence and reprint requests: Ismail Mohd Saiboon. Department of Emergency Medicine, Faculty of Medicine, Universiti Kebangsaan Malaysia Medical Centre, Jalan Yaacob Latif, Bandar Tun Razak, 56000 Cheras, Kuala Lumpur, Malaysia. Tel: +603-91455491 Fax: +603-91456577 E-mail: fadzmail69@yahoo.com.my

ultrasound. The skill of using an ultrasound by a minimally trained medical officer in diagnosing these cases in the Emergency Department are very helpful and expedite the management. We present the case of a 7-month-old girl who presented to Emergency Department (ED) with the chief complaint of passing blood in stool. Clinically she was dehydrated, irritable and in compensated shock. There was generalised tenderness per abdomen but it was soft and not distended. There was no palpable mass and bowel sound normal. Immediate fluid resuscitation commenced. Bedside abdominal ultrasound performed by ED medical officer showed a 1.8 cm x 2.5 cm mass of alternating hypo-echoic and hyper-echoic rings at the right lower quadrant, consistent with the 'target' sign of intussusception. Supine plain abdominal X-ray did not reveal any abnormality. The ultrasound finding of intussusception was later confirmed by the radiologist. She underwent immediate hydrostatic reduction and was discharged well.

Keywords: diagnosis, Emergency Department, intussusception, paediatric, ultrasound

INTRODUCTION

The diagnosis of intussusception in a child presenting with vague symptoms is always very challenging for the Emergency Physicians. Barium enema used to be the gold standard for diagnosis (Ramsay & Halm 2014). Ultrasound has emerged as a valuable tool for the diagnosis of paediatric intussusception (Chen & Baker 2007). The use of bedside ultrasound in the diagnosis of paediatric intussusception first appeared in the literature in the 1980's but now there are overwhelming case reports on physicians successfully diagnosing this condition at bedside. In a case series by Shanbogue et al. (1994) performed between 1980 and 1989, ultrasound had a reported sensitivity and specificity as high as 98.5% and 100% respectively in diagnosing intussusception (Shanbogue et al. 1994). The use of ultrasound is particularly attractive in the paediatric

population as it carries no radiation risk, painless and non-invasive hence negating the need for sedation (Gale et al. 2016).

This begets the question whether ultrasounds performed at bedside by novice sonographers are comparable in terms of sensitivity and specificity to those performed by trained diagnostic radiologists. Here, we present a case of a 7-month-old child who had blood in stools. An ultrasound diagnosis of intussusception was made at bedside by a resident medical officer. This led to expedited consultation with paediatric surgeon and successful hydrostatic reduction.

CASE REPORT

A 7-month-old girl with no prior medical illness presented to Emergency Department (ED) with chief complaint of passing blood in stool. The child was irritable, had reduced level of activity

and reduced feeding for the past 12 hrs prior to presentation. She vomited twice but it was not associated with fever, diarrhoea or urinary symptom. Her mother also noticed that her urine has become very concentrated. The child had no contact with any sick person and had no recent travelling history.

On examination the child appeared lethargic and dehydrated. She was in distress during paroxysm of pain but remained relatively well in between attacks. Vitals signs were as follows: blood pressure of 106/60 mmHg, pulse rate of 140 beats/min, respiratory rate of 30 breaths/min, temperature of 37.5°C and she was saturating at 98% under room air. The mucosa appeared dry and coated. Tips of fingers were cold with capillary refill time of 2 seconds and moderate pulse volume. Tonsils were not enlarged. Lungs and heart auscultation was unremarkable. Abdomen was soft and not distended but there was generalised tenderness. No mass was palpable and bowel sounds were normal on auscultation. There was blood stained faeces on the child's diapers. The remainder of the physical examination was non-contributory. An episode of non-bilious vomiting was observed while child was in the Emergency Department.

Laboratory results showed raised white cell count of $15 \times 10^3/\mu\text{L}$ with neutrophil predominance, normal Hb (12.2 g/dL) and platelet ($230 \times 10^3/\mu\text{L}$) Renal profile showed raised Urea (9 mmol/L) and creatinine of 67 micromol/L, potassium was slightly low at 3.1 mmol/L, sodium was 140 mmol/L and chloride was 101

mmol/L. Venous blood gas showed compensated metabolic acidosis with pH of 7.36, bicarbonate level of 17 mmol/L raised anion gap of 25, no lactate value was available. Capillary blood sugar was 6.7 mmol/L.

As the child was in compensated shock, initial treatment included giving 10 mls/kg of normal saline bolus along with IV fentanyl at 1 mcg/kg for immediate pain relief. After the 1st fluid bolus child appears more alert, less tachycardic at 110 beats/min and BP of 110/66. Maintenance drip along with 5% correction over 24 hrs was given subsequently. Supine, plain film abdominal radiograph was performed and the finding was unremarkable; there was no evidence of distended bowel loop or soft tissue mass. Bedside abdominal ultrasound was performed by the attending medical officer. A transverse cross sectional view of a portion of small bowel at the Right lower quadrant was identified as a 1.8 cm x 2.5 cm mass of alternating hypo echoic and hyper echoic rings. This is consistent with the 'target' sign of intussusception (Figure 1). When a longitudinal cross sectional view of the particular bowel segment was attempted, a 'pseudokidney sign' was obtained (Figure 2). The fat containing the mesentery which is dragged into the intussusception is reminiscent of the renal hilum while the oedematous bowel resembles renal parenchyma. Appendix was not visualised and there was no intra-peritoneal free fluid. Urgent referral was made to the paediatric surgical team.

Intussusception was confirmed by ultrasound performed by radiologist.

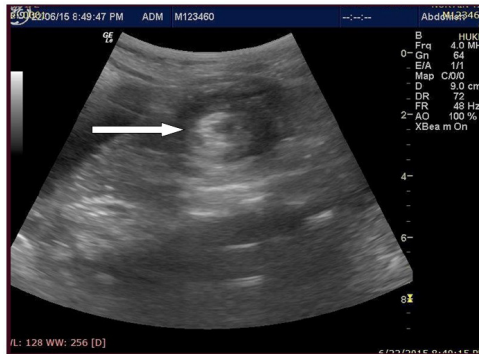


Figure 1: Target sign. Thick arrow indicating the 'target-sign'

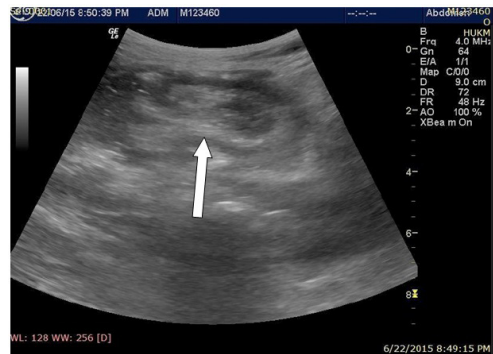


Figure 2: Pseudokidney sign. Arrow showing the 'Pseudokidney sign'

Hydrostatic reduction was done using saline and successful reduction was achieved with the third attempt. Child was observed in the ward for recurrence. The child remained well and was discharged home after 72 hrs observation.

DISCUSSION

Intussusception is a common cause of gastrointestinal emergency in the paediatric population. It is the most common cause of small bowel obstruction in children. The incidence of intussusception is quoted to be 2.4 per 1000 live births in the US (Waseem & Rosenberg 2008). It usually occurs between the age of 6 months to 2 yrs. Male to female ratio is 3 to 1 and this discrepancy increases with older children. Intussusception in adults is rare and is often a complication of pre-existing colonic disease like malignancy.

Intussusception results from invagination of a segment of bowel into its lumen and become telescoped into the adjacent bowel segment. The most common site for paediatric

intussusception is ileocolic, where a segment of ileum invaginated through the ileocecal valve into the colon (del-Pozo et al. 1999). The mesentery is being pulled along with the intussusceptum (the leading invaginating segment) into the recipient bowel segment and is propelled distally through peristalsis. The venous drainage become blocked causing the bowel mucosa to become engorged, oedematous and bleed into the lumen. As time passes, the perpetuating oedema compromise the arterial blood supply to the intestine, leading to bowel necrosis, perforation, peritonitis and shock.

The classic triad of colicky abdominal pain, vomiting and red currant jelly stools is only present in 30-40% of cases (Daneman & Alton 1996). Typically, pain occurs first and is episodic; pain lasts for 4-5 mins with 30 mins of pain free interval in between attacks. In infants and younger children, the only presenting complain may be irritability and in some cases, lethargy predominates. Diagnosing intussusception requires a high level of suspicion and is particularly challenging in a child who comes with

vague symptoms. Plain abdominal radiographs are usually unremarkable and laboratory results are non-specific. Barium enema used to be considered as the gold standard for diagnosis. However, it is invasive, carries the risk of radiation exposure and requires the presence of on-site radiologist which is difficult to be done timely during the after hours. This delays institution of treatment. The longer time lapses, the least likely non-surgical reduction will be successful and the risk of bowel necrosis and perforation becomes greater.

The advent of ultrasound as a reliable tool to diagnose intussusception has been proven over the recent years. It is readily available, non-invasive and negates the radiation risk. It is much safer compared to barium enema, as leakage of contrast into the peritoneum carries high morbidity. When performed by an experienced operator, the sensitivity is as high as 98-100% and specificity is between 88-100% (Hryhorczuk & Strouse 2009). Typical ultrasound signs of intussusception are target sign and pseudo kidney sign, a transverse and cross longitudinal view of intussusception, respectively.

In this case report, the resident medical officer who attended to this case is a trainee in Emergency Medicine postgraduate programme. He had underwent 1 month of intensive training on bedside ultrasound in the emergency setting which includes bedside teaching and lectures. At the end of the 1 month period, the trainee is required to complete a logbook and related assessments. This 1-month period

exposed the trainee to multiple skill sets but he was not trained specifically in diagnosing intussusception in the paediatrics population. Almost all of the case reports and studies on this area involve emergency physicians who was given focused training on performing abdominal ultrasound in children. Ramsay and Halm (Ramsay & Halm 2014) published the first case report of a paediatric resident diagnosing intussusception by bedside ultrasound in a 4-year-old boy under the guidance of a pediatric emergency attending with ultrasound training. This begets the question whether novice sonographers are capable to accurately diagnose intussusception in the paediatrics population? And what kind of training is considered sufficient for their ultrasound findings to be consistent and reproducible?

A retrospective review (Lam et al. 2014) compared the accuracy of bedside ultrasound diagnosis of intussusception made by Emergency Physicians to the "formal" diagnostic study such as ultrasound, CT and barium enema performed in the Radiology Department. Out of 1631 of the medical records been reviewed in a single centre, 44 met the inclusion criteria. Bedside ultrasound was found to be 100% sensitive (95% CI was 66-100%) and 94% specific (95% CI was 79-99%).

In another study (Riera et al. 2012), a prospective observational study was conducted in the emergency department of a paediatrics tertiary centre. A total of 82 patients aged between 3 months and 10.5 yrs with suspected intussusception

were enrolled. They first underwent bedside ultrasound by paediatrics emergency physicians. Afterwards, another ultrasound was performed by diagnostic radiologists and these results were used as the reference standard. Bedside ultrasound had a sensitivity or positive predictive value of 85% (95% CI was 54% to 97%) and specificity or negative predictive value of 97% (95% CI was 89 or 99%).

These two studies brought forward several issues and implications. Firstly, bedside ultrasound diagnosis has the potential to be quickly learned and accurately performed by novice sonographers with limited and focused training. Secondly, the ability to perform rapid and serial ultrasound at bedside is invaluable in a busy emergency setting as it can improve patient care and resource utilization. Bedside diagnosis is particularly advantageous in a centre where comprehensive paediatric radiology services are not available or during the after hours. Timely diagnosis at bedside will expedite referral to surgical and radiology services, transfer to referral centre and time to successful reduction (Gingrich et al. 2013).

These two studies however showed contrasting result in term of the positive predictive value of bedside ultrasound. The first study demonstrated sensitivity to be as high as 100% whereby the second study quoted 85%. The 1st study's major limitations are in its retrospective design and the possibility that bedside ultrasound results that are incongruent with formal study were not recorded, allowing for underestimation of false negative rates.

The ability of bedside ultrasound to rule in intussusception is high in both study; at 94% and 97%, respectively.

It is generally accepted that ultrasound training is required for physicians performing point-of care ultrasound in the emergency setting. One study (Chang et al. 2013) demonstrated statistically better outcomes when bedside ultrasound in children with suspected intussusception were performed by emergency physicians with training compared to those without training. However, there has been no agreement on what constitute as sufficient training for novice sonographers. The first study by Lam (Lam et al. 2014) subjected the emergency physicians to a minimum 1 hr of didactic training on the use of bedside ultrasound using paediatric transducers. They did not go on to explain what the didactic training comprise of. Riera (Riera et al. 2012) subjected the 6 emergency physicians to 1 hr of training under paediatric radiologists. The session included a didactic component on sonographic appearances of ileocolic intussusception, review of images with positive and negative results for intussusceptions, and a hands-on component with a live child model. In the study by Chang (Chang et al. 2013), the emergency physicians received 1 month of training in abdominal ultrasound supervised by gastroenterologist. All of the studies did not mention whether any assessment was done at the end of training to assess competency.

A recent review (Raymond-Dufresne & Ghanayem 2012) concluded that

although bedside ultrasound performed by emergency physicians are specific enough to rule in intussusception, its ability to rule out the diagnosis needs to be further explored. This is because of the clinically unacceptable and large variation in reported sensitivities. Due to relative rarity of intussusception and paucity of skilled physician sonographers, there is a need for a further study on this topic involving collaboration with multiple centres and larger sample size. It would be immensely helpful if a standardised training for the recruited physicians is drawn up for future studies. The ease of use even among the novice sonographers highlight the importance of providing training on pediatric abdominal ultrasound to the trainees and residents in Emergency Medicine.

CONCLUSION

Bedside ultrasound is a safe and cost effective tool for rapid diagnosis of intussusception in the paediatric population. With focused didactic training, it has been shown that even novice physician sonographers are able to competently identify the classic ultrasound signs of intussusception. In children who present with vague symptoms and non-contributory physical examination, bedside ultrasound performed in the Emergency Department can be invaluable and negates the need for extensive investigations like CT scan or barium enema. It has a high specificity to accurately rule in the diagnosis. However, in cases with negative finding on bedside ultrasound,

continuing observation and serial focused ultrasound may be warranted, as well as referral to radiologist for formal diagnostic study.

REFERENCES

- Chang, Y.J., Hsia, S.H., Chao, H.C. 2013. Emergency physicians performed ultrasound for paediatric intussusception. *Biomed J* 36 (4): 175-8.
- Chen, L, Baker, M.D. 2007. Novel applications of ultrasound in pediatric emergency medicine. *Pediatr Emerg Care* 23(2):115-23.
- Daneman, A., Alton, D.J. 1996. Intussusception. Issues and controversies related to diagnosis and reduction. *Radiol Clin North Am* 34(4):743-56.
- del-Pozo, G., Albillos, J.C., Tejedor, D., Calero, R., Rasero, M., de-la-Calle, U., Lopez-Pacheco, U. 1999. Intussusception in children: current concepts in diagnosis and enema reduction. *Radiographics* 19(2):299-319.
- Gale, H.I., Gee, M.S., Westra, S.J., Nimkin, K. 2016. Abdominal ultrasonography of the pediatric gastrointestinal tract. *World J Radiol* 8(7): 656-67.
- Gingrich, A.S., Saul, T., Lewiss, R.E. 2013. Point-of-care ultrasound in a resource-limited setting: diagnosing intussusception. *J Emerg Med* 45(3): e67-70.
- Hryhorczuk, A.L., Strouse, P.J. 2009. Validation of US as a first-line diagnostic test for assessment of pediatric ileocolic intussusception. *Pediatr Radiol* 39(10):1075-9.
- Lam, S.H., Wise, A., Yenter, C. 2014. Emergency ultrasound for the diagnosis of paediatric intussusception. *World J Emerg Med* 5(4): 255-8.
- Ramsay, K.W., Halm, B.M. 2014. Diagnosis of intussusception using bedside ultrasound by a paediatric resident in the emergency department. *Hawaii J Med Public Health* 73(2): 58-60.
- Raymond-Dufresne, E., Ghanayem, H. 2012. BET 2: Can emergency physicians safely rule in or rule out paediatric intussusception in the emergency department using bedside ultrasound. *Emerg Med J* 29(10): 854-5.
- Riera, A., Hsiao, A.L., Langhan, M., Goodman, T.R., Chen, L. 2012. Diagnosis of intussusception by physician novice sonographers in the emergency department. *Ann Emerg Med* 60(3): 264-8.
- Shanbogue, R.L, Hussain S.M., Meradji, M., Robben, S.G., Vernooij, J.E., Molenaar, J.C. 1994. Ultrasonography is accurate enough for the diagnosis of intussusception. *J Pediatr Surg*

29(2): 324-7.

Waseem, M., Rosenberg, H.K. 2008.
Intussusception. *Pediatr Emerg Care* 24(11):
793–800.

Received: 10 January 2017

Accepted: 26 April 2017