

1962


A Middle Miocene Rhinoceros Quarry in Morrill County, Nebraska (with Notes on Hip Disease in Diceratherium)

Robert M. Stecher

C. Bertrand Schultz

Lloyd G. Tanner

Follow this and additional works at: <http://digitalcommons.unl.edu/museumbulletin>

 Part of the [Entomology Commons](#), [Geology Commons](#), [Geomorphology Commons](#), [Other Ecology and Evolutionary Biology Commons](#), [Paleobiology Commons](#), [Paleontology Commons](#), and the [Sedimentology Commons](#)

Stecher, Robert M.; Schultz, C. Bertrand; and Tanner, Lloyd G., "A Middle Miocene Rhinoceros Quarry in Morrill County, Nebraska (with Notes on Hip Disease in Diceratherium)" (1962). *Bulletin of the University of Nebraska State Museum*. 11.
<http://digitalcommons.unl.edu/museumbulletin/11>

This Article is brought to you for free and open access by the Museum, University of Nebraska State at DigitalCommons@University of Nebraska - Lincoln. It has been accepted for inclusion in Bulletin of the University of Nebraska State Museum by an authorized administrator of DigitalCommons@University of Nebraska - Lincoln.

BULLETIN OF
The University of Nebraska State Museum VOLUME 4, NUMBER 7
DECEMBER 1962

Robert M. Stecher
C. Bertrand Schultz
Lloyd G. Tanner

*A Middle Miocene Rhinoceros
Quarry in Morrill County,
Nebraska (with Notes on Hip
Disease in Diceratherium)*



BULLETIN OF

The University of Nebraska State Museum

Pp. 101-111 Figs. 1-6

VOLUME 4, NUMBER 7

DECEMBER 1962

ABSTRACT

*A Middle Miocene Rhinoceros Quarry in Morrill County,
Nebraska (with Notes on Hip Disease in Diceratherium)*

ROBERT M. STECHER C. BERTRAND SCHULTZ LLOYD G. TANNER

Extensive deposits of fossil rhinoceros bones have been excavated from University of Nebraska State Museum collecting localities Mo-113, -114, -115, -116, and -118 some 8½ to 9½ miles north of Bridgeport, Morrill County, Nebraska. The fossils were associated with other faunal elements in the lower portion of the Marsland formation (middle Miocene) of the Hemmingford group. The rhinoceros is considered to be *Diceratherium niobrarensis* Peterson, geologic variety.

A pathologic right femur of *D. niobrarensis* provides evidence of hip disease in the medial Miocene rhinoceroses.

CONTRIBUTION OF the Department of Medicine of Western Reserve Medical School and the Metropolitan General Hospital, Cleveland; the Division of Vertebrate Paleontology of the University of Nebraska State Museum and the Department of Geology (College of Arts and Sciences).

Stecher¹
Schultz²
Tanner³

*A Middle Miocene Rhinoceros Quarry
in Morrill County, Nebraska (with
Notes on Hip Disease in Diceratherium)*

During the past thirty years considerable paleontologic evidence has been gathered relative to the Miocene sediments of Morrill County, Nebraska. The most extensive deposits of fossil vertebrates (University of Nebraska State Museum collecting localities Mo-113, -114, -115, -116, and -118) are located 8½ to 9½ miles north of Bridgeport, Nebraska. The collecting localities were originally called the "Bridgeport Quarries." The fossils are from the lower portion of the Marsland formation (middle Miocene) of the Hemingford group, and are associated with shore line (lacustrine) deposits. The bones were embedded chiefly in fine sands and silts, but some were in fine textured limy silts and clays. The U.N.S.M. Coll. Loc. Mo-114, which was discovered in 1932,⁴ yielded the largest quantity of fossil

¹ Chairman of the Board of the Cleveland Health Museum and Physician at Metropolitan General Hospital, Cleveland, Ohio.

² Director of University of Nebraska State Museum, Curator of Vertebrate Paleontology, and Professor of Geology.

³ Associate Curator of Vertebrate Paleontology in the Museum and Coordinator of Field Activities.

⁴ The U.N.S.M. 1932-1935 field parties working at the lower Marsland collecting localities north of Bridgeport consisted of the following personnel: E. L. Blue, Frank Crabill, Everett DeGroot, Bee Denton, Frank Denton, Loren C. Eiseley, Charles H. Falkenbach, Marian Schultz, C. Bertrand Schultz, Thompson M. Stout, S. R. Sweet, Eugene Vanderpool, and associates. In 1940 the localities were again extensively excavated by a U.N.S.M.-Works Progress Administration field party under the leadership of E. E. Brier and Lloyd G. Tanner.

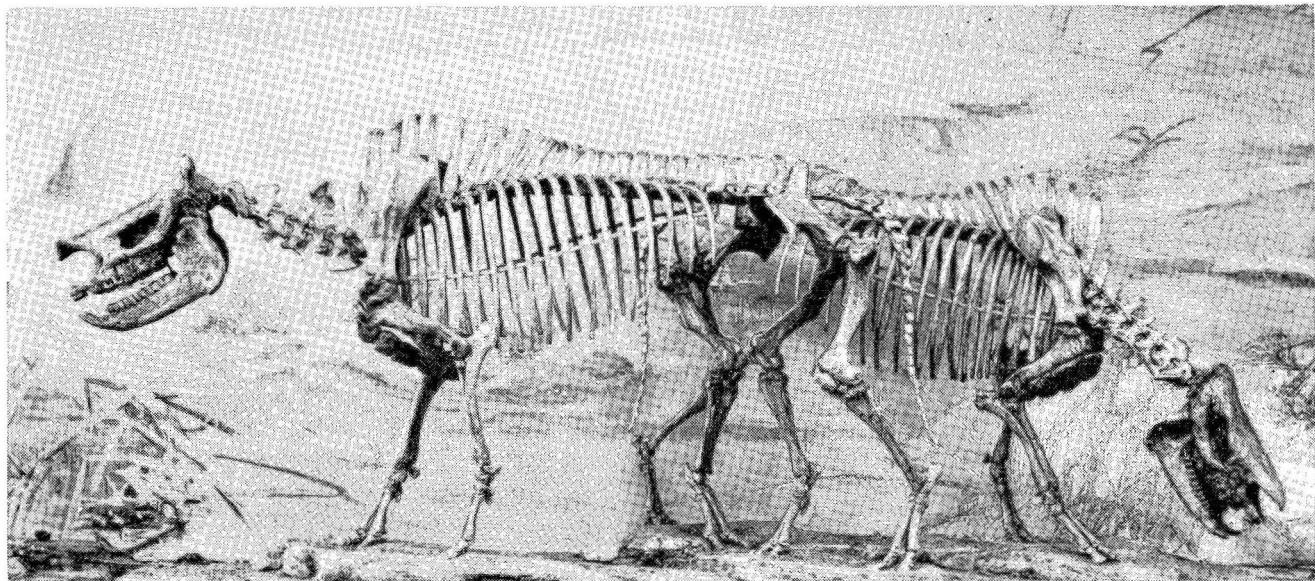


FIG. 1—Mounted skeletons of *Diceratherium niobrarensis* Peterson, geologic variety, from the lower portion of the Marsland formation (middle Miocene), Hemingford group, U.N.S.M. Coll. Loc. Mo-114, 9½ miles north of Bridgeport, Morrill County, Nebraska. Skeletons of male, U.N.S.M. 1241, on left, and of female, U.N.S.M. 1238, on right are exhibited in the University of Nebraska State Museum. Note normal femora on skeletons. X 1/19.

A Middle Miocene Rhinoceros Quarry in Morrill County, Nebraska

vertebrates of any of these lower Marsland localities. The remains of the rhinoceros, *Diceratherium niobrarenensis* Peterson, geologic variety, were most abundant. The examples of this species are somewhat larger than those described by Peterson (1906) from the lower Miocene deposits (Harrison formation) at the Agate Spring Fossil Quarry, and appear to represent a geologic variety of the Harrison species (see Schultz and Stout, 1961, p. 7, for the stratigraphic relationship of the Harrison and Marsland formations).

FAUNA OF THE MARSLAND FORMATION

The fauna of the Marsland is distinct from that of the Harrison formation. The following genera have been recorded from the Marsland: *Metechinus* (insectivore), *Gregorymys* (rodent), *Plevorlicus* (rodent), *Dikkomys* (rodent), *Promylagaulus* (rodent), *Oreolagus* (rabbit), *Megalicitis* (carnivore), *Cynarctus* (carnivore), *Aelurocyon* (carnivore), *Phlaocyon* (carnivore), *Hypohippus* (horse), *Archaeohippus* (horse), *Parahippus*¹ (horse), *Moropus* (chalicothere), *Diceratherium* (rhinoceros), rhinocerotid, gen. undet., *Desmathyus* (peccary), *Oxydactylus* (camel), *Stenomylus* (camel), *Merycochoerus* (oreodont), *Merychys* (oreodont), *Phenacocoelus* (oreodont), *Aletomeryx* (deer), *Barbouromeryx* (deer), *Probarbouromeryx* (deer), *Machaeromeryx* (deer), *Problastomeryx* (deer), *Pseudoblastomeryx* (deer), and *Syndyoceras* (deer-like).

The lower Marsland faunal elements associated with *Diceratherium niobrarenensis* Peterson, geologic variety, at the Bridgeport Quarries (Mo-113, -114, -115, -116, and -117) include the following: *Hypohippus* sp.—horse, *Archaeohippus* sp.—horse, *Parahippus* sp.—horse, *Oxydactylus* sp.—camel, *Merychys arenarum* Cope—oreodont, *Probarbouromeryx sweeti* Frick—deer, and *Pseudoblastomeryx schultzi* Frick—deer.

HIP DISEASE IN *Diceratherium niobrarenensis*²

A pathologic right femur, U.N.S.M. 5479, of *Diceratherium niobrarenensis* Peterson, geol. var., has proven to be of much interest, since it represents a case of hip disease which occurred some 14,000,000 years ago (the approximate age of the lower Marsland deposits). This specimen proved to be the only patho-

¹ *Merychippus* is recorded from the upper Marsland.

² This section of the report has been prepared primarily by the senior writer, Robert M. Stecher, M.D.

logic one of more than sixty rhinoceros femora obtained from the lower Marsland fossil quarries north of Bridgeport, in Morrill County, Nebraska. Two mounted rhinoceros skeletons of *D. niobrarensis*, geol. var., from the same U.N.S.M. collecting locality (Mo-114) as the pathologic specimen, are illustrated in Fig. 1 in order to show the approximate articular position of a normal femur.

Comparative pathology is the study of diseases in different races of animals. Paleopathology is the study of diseases in prehistoric animals of the different eras of geologic time. Both fields of study are interesting and can be instructive for understanding human ills. Stecher (1958, p. 307) has reported the occurrence of three cases of osteoarthritis of the hip in gorillas; and also has studied a case of osteoarthritis of the knee in a gorilla and has noted numerous instances of spur formation, bridging, and ankylosis in the spines of horses and bears. It

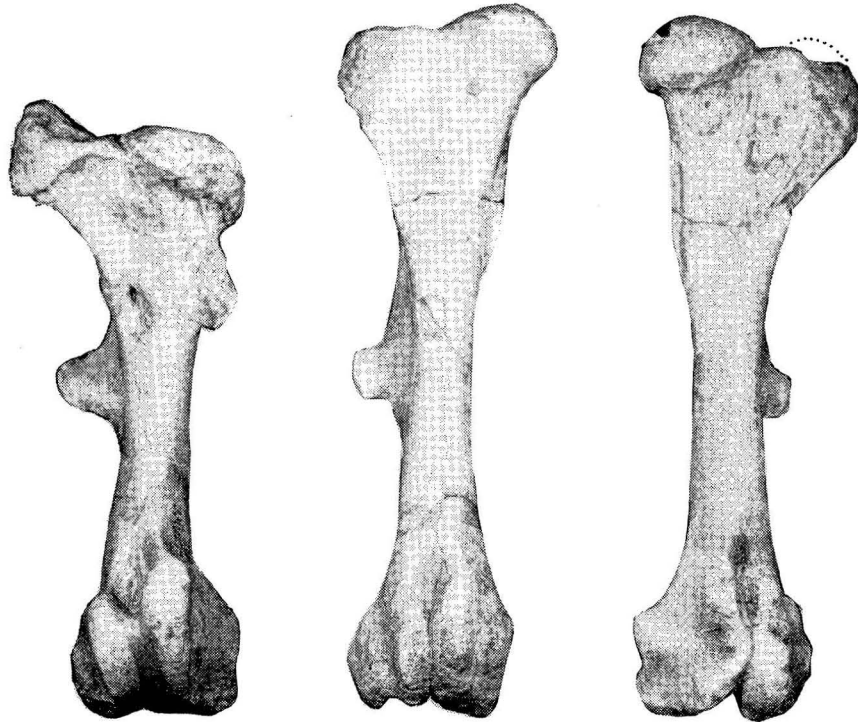


FIG. 2—Anterior views of three femora of *Diceratherium niobrarensis* Peterson, geologic variety, from the lower portion of the Marsland formation (middle Miocene), U.N.S.M. Coll. Loc. Mo-114, Morrill County, Nebraska. Pathologic right femur, U.N.S.M. 5479, at left; normal right femur, U.N.S.M. 5480, center; and normal left femur, U.N.S.M. 5481, at right. X 1/4.

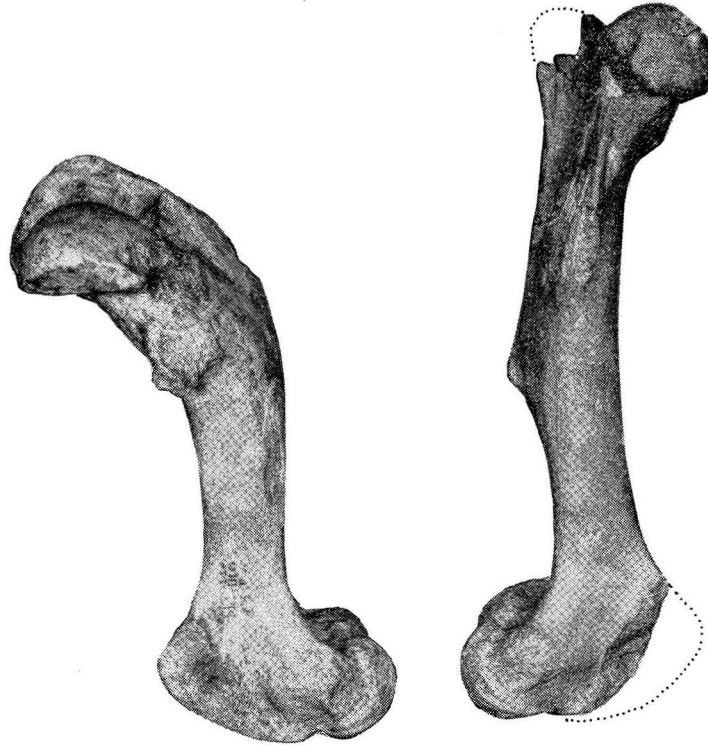

FIG. 3—Lateral views of pathologic right femur, U.N.S.M. 5479, on left, and normal left femur, U.N.S.M. 5481, of *Diceratherium niobrarensis* Peterson, geologic variety, from U.N.S.M. Coll. Loc. Mo-114. X 1/4.

is, therefore, of interest to present this case of hip disease in a prehistoric rhinoceros and to compare it with two normal hips.

The condition of these femora is clearly shown in Fig. 2. This illustration shows the anterior views of three rhinoceros femora—the diseased right femur (U.N.S.M. 5479) and normal right and left femora (U.N.S.M. 5480 and 5481). There is no proof that any two came from the same individual. (See measurement chart for comparative size of the three specimens.) The diseased right femur is obviously shortened in the proximal half. The head of this femur is depressed below the level of the greater trochanter and is wider, flatter, and lower than the normal ones. The lesser trochanter seems to be enlarged. Figure 4 shows the same deformities from the posterior. In Fig. 3 the lateral view of the pathologic right femur shows the abnormal posterior curvature in the upper half of the bone. A radius drawn through the center of the curvature in the joint

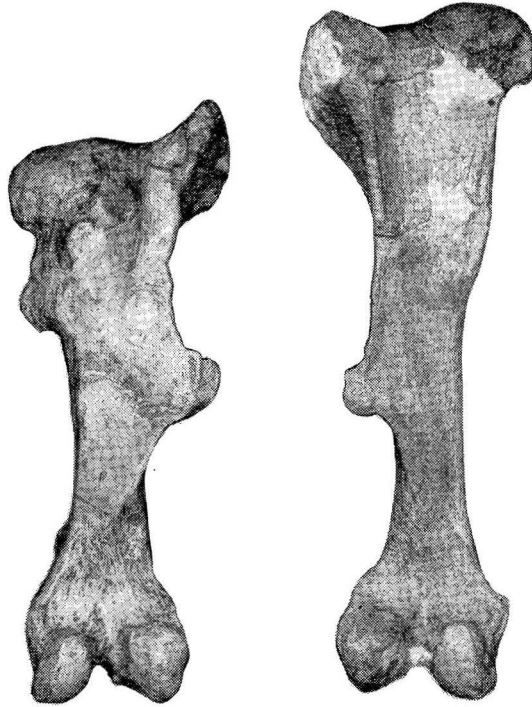


FIG. 4—Posterior views of pathologic right femur, U.N.S.M. 5479, and normal left femur, U.N.S.M. 5481, of *Diceratherium niobrarenensis* Peterson, geologic variety, from U.N.S.M. Coll. Loc. Mo-114. The heads of the femora show differences in size, shape, and position. X 1/4.

of the diseased femur is almost parallel with the long axis of the bone, instead of pointing forward about 35 degrees as in the normal femur.

COMPARATIVE MEASUREMENTS OF THREE FEMORA OF
Diceratherium niobrarenensis PETERSON, GEOL. VAR.

	U.N.S.M. 5479 ¹	U.N.S.M. 5480 ²	U.N.S.M. 5481 ³
Articular length	310	385	372
Proximal end length (Ant.-Post.)	100	75	70
Proximal end width	120	120	122
Distal end length (Ant.-Post.)	125	110	((122)) ⁴
Distal end width	88	80	80
Width at third trochanter	60	75	75

¹ Pathologic right femur

² Normal right femur

³ Normal left femur

⁴ (()) = approximate

A Middle Miocene Rhinoceros Quarry in Morrill County, Nebraska

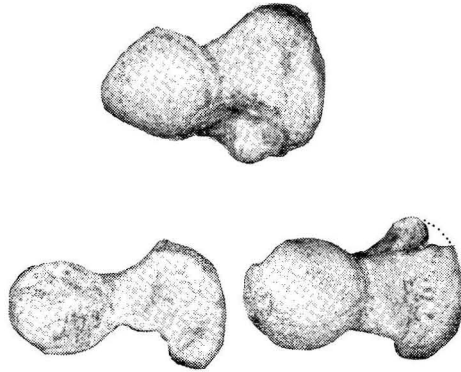


FIG. 5—Proximal ends of three femora of *Diceratherium niobrarensis* Peterson, geologic variety, from U.N.S.M. Coll. Loc. Mo-114. Pathologic right femur, U.N.S.M. 5430, at lower left; and normal left femur, U.N.S.M. 5481, at right. X 1/4.

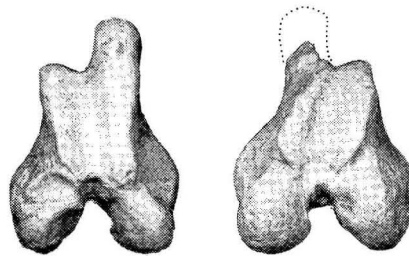


FIG. 6—Distal ends of pathologic right femur, U.N.S.M. 5479, on left, and normal left femur, U.N.S.M. 5481, of *Diceratherium niobrarensis* Peterson, geologic variety, from U.N.S.M. Coll. Loc. Mo-114. X 1/4.

At the distal end of the normal left femur, U.N.S.M. 5481, the condyles are shaped very much like those of a human femur with their articulating surfaces each resembling a half circle and projecting posteriorly. A radius drawn through the mid-point of the articulating surface is nearly perpendicular to the shaft, instead of being parallel with it as in the human femur. The facies patellaris is not continuous with the condyles but is separated from the median condyle by a ridge. The lateral lower border is separated from the lateral condyle by a distance of 15 mm. The facies patellaris occupying the anterior portion of the shaft, is roughly convex and is deeply grooved in the longitudinal direction. It is about 100 mm. long on the medial border and 80 mm. in the lateral border. Both condyles start at the femur's distal extremity at a point where the extended posterior surface of the shaft crosses the end of the bone. The condyles extend beyond the end of the posterior surface of the

femur, forming two hemispheres with a radius of 20-25 mm. separated by a deep sulcus. These characters are shown in Fig. 6 on the distal ends of two femora.

The posterior portion of the normal femur is a flattened surface, the lateral edge of which curves backward and bends forward as it ascends. At its origin above the condyle it is in the same transverse plane with them. The neck and head are anteriorly rotated about 30 degrees from the flattened surface of the lower end of the shaft. On the lateral border, 165 mm. above the distal end of the femur, there is a flat projection, the third trochanter, extending 30 mm. laterally beyond the shaft surface. A portion of this projection extends posteriorly as an extension of the flat surface of the femur.

The head of the femur, U.N.S.M. 5480, forms a somewhat flattened hemisphere. The projected size is 60 mm. x 50 mm. x 40 mm. The head projects upward about 10 mm. beyond the greater trochanter. The greater trochanter is large and massive and extends 60 mm. beyond the lateral edge of the head. It is 70 mm. deep in an anterior-posterior direction, and is roughly triangular in shape with the apex pointing posteriorly. Figure 5 illustrates the proximal ends of three femora. The deformed bone differs in size and shape from the two normal ones which also vary considerably in size. These differences in size of the normal femora may be due to differences in age and sex. The anterior portion of the normal femur is rounded, beginning at the distal end above the limit of the facialis patellaris, and ending in a flattened surface between the head and the trochanter.

The normal left femur, U.N.S.M. 5481, is similar to the one mentioned above except that it is a little more massive at both ends and is slightly shorter (see chart of measurements). A considerable amount of individual variation occurs in the *Diceratherium* femora from this collecting locality. The medial portion of the facies patellaris of U.N.S.M. 5481 has been damaged and its crest has been broken.

The right femur, U.N.S.M. 5479, is markedly deformed in the proximal half. The lower portion of this femur, however, is similar in size, shape, and form to those of the normal femora below the area of the third trochanter. The third trochanter of the pathologic specimen is much larger than its normal counterpart, and extends laterally 40 mm., while the normal one extends 30 mm. The overall length of the diseased femur is 310 mm. compared to 386 mm. and 372 mm. in the normal ones. The length is reduced even more since the head has been de-

pressed below the greater trochanter. On the side below the head there is a large bony protuberance 40 mm. x 20 mm. instead of the normal, long, narrow, curved edge. The facies patellaris is roughly convex and is deeply grooved in its longitudinal axis. Its length on the lateral border is about 80 mm. and on the opposite side is about 100 mm.

The flattened posterior surface of the deformed femur is not rotated as in a normal one. The upper half of the femur bends forward sharply and the proximal portion stands at an angle of 45 degrees with the lower end of the shaft.

The head of the femur is depressed and is flattened transversely rather than being hemispherical. The antero-posterior diameter is increased, its projected length being 70 mm. Along the anterior and lateral border of the joint surface there is a small margin of osteophytic bone growth. The posterior margin is widely eroded in the lateral and the medial third, the middle third being spared. Figure 5 shows the proximal ends of the three femora illustrating the differences in size, shape, and position of the articular surfaces.

The upper half of the diseased right femur is shortened and thickened, and bent forward at an angle of about 45 degrees compared to the normal left example, which is bent forward only about 10 degrees. The articulating surface has not been bent forward but is actually rotated on the upper end of the femur. A radius drawn to the center of this articulating surface is almost parallel with the lower end of the femur and distinctly out of line with a similar radius on the left femur.

No history of this case is available, of course, so it is necessary to speculate about the condition present in an effort to arrive at a diagnosis. The deformity of the entire upper end of the femur is so great as to suggest an abnormal process of the femur itself, instead of the hip alone. This animal might have sustained a green stick fracture of the upper half of the bone producing misalignment without actual displacement, with the misalignment increasing as time went on because of the necessity of weight bearing. This would account for the deformity of the shaft itself and the reinforcement of the bend and the upper end. It does not account for the deformity of the head itself, its change in shape, its displacement downward, and its altered projection.

By drawing an analogy from human pathology it seems possible that an injury producing a green stick fracture might also

have injured the ligamentum teres and thus impaired the blood supply to the head leading to an osteochondritis such as occurs in Legg-Calve-Perthes disease. An untreated Legg-Calve-Perthes disease results in a flattened and depressed head of the femur in which osteoarthritis finally develops. Such an injury with a green stick fracture might also have produced a slipped epiphysis and a deformity similar to the one described.

The pelvis associated with the pathologic femur during the life of the rhinoceros is not available so that its condition is not known. It is likely that the right acetabulum into which the effected femur articulated was deformed and its margins were deepened by osteophytic growth. In view of the lack of apparently normal anteversion of the head of the right femur the acetabulum must have been placed farther forward and faced more anteriorly than would have been normal. The lack of anteversion of the neck of the femur, the forward position of the acetabulum in the pelvis, and the facing forward of the acetabulum (rather than in a lateral position) are characteristic of the dysplastic hip in the human, and are considered to be a predisposing cause of osteoarthritis.

The enlargement of the head of the femur, its altered shape, its abnormal position in relation to the shaft of the femur, as well as the spur formation around it, justify a diagnosis of osteoarthritis of the hip. The condition, in the human, may occur spontaneously in middle or later life but often occurs secondarily after an injury, an osteochondritis, a slipped epiphysis, or a congenital dysplasia. In the case of this rhinoceros it seems best explained on a basis of early injury.

The nature and severity of its deformity indicates that this animal was greatly handicapped. It may have had much pain, accompanied by an impairment of normal locomotion due to a shortened leg. A rhinoceros might easily survive for many years with such a handicap, since it had few natural enemies and depended primarily on browsing for obtaining food, rather than on pursuing and capturing prey. The injured medial Miocene rhinoceros discussed in this paper survived long enough that the diseased condition was no longer progressive, but was chronic and static at the time of its death.

References

- FRICK, CHILDS. 1937. Horned ruminants of North America. *Bul. Amer. Mus. Nat. Hist.* 69: 135, 259, figs. 4, 4a, 14, 24.
- PETERSON, O. A. 1906. Preliminary description of two new species of the genus *Diceratherium* Marsh, from the Agate Spring Fossil Quarry. *Science (N.S.)* 24 (609): 281-283.
- SCHULTZ, C. BERTRAND, and CHARLES H. FALKENBACH. 1947. Merychyinae, a subfamily of oreodonts. *Bul. Amer. Mus. Nat. Hist.* 88 (4): 186.
- . 1961. Faunal list of the oreodonts from Nebraska (in field conference on the Tertiary and Pleistocene of western Nebraska). *Guide Book for the Ninth Field Conference of the Society of Vertebrate Paleontology*, *Spec. Publ. Univ. Nebr. State Museum* (2): 11-14.
- SCHULTZ, C. BERTRAND, and HENRY P. REIDER. 1943. Modern methods in the preparation of fossil skeletons. *The Compass*, May: 275 (illustration of two skeletons of *Diceratherium niobrarense* Peterson, geologic variety, in U.N.S.M. display).
- SCHULTZ, C. BERTRAND, and THOMPSON M. STOUT. 1961. Field conference on the Tertiary and Pleistocene of western Nebraska (with contributions by Charles H. Falkenbach and Lloyd G. Tanner). *Guide Book for the Ninth Field Conference of the Society of Vertebrate Paleontology*, *Special Publ. Univ. Nebr. State Mus.* (2): 7, figs. 1-3, 25.
- STECHEER, ROBERT M. 1958. Osteoarthritis in the Gorilla. *Laboratory Investigation*, 7: 445-457.
- . 1958. Osteoarthritis of the Hip in a Gorilla: Report of a Third Case. *Clinical Orthopedics*, 12: 307-314.
- . Osteoarthritis or Ankylosing Lesions of the Spine: Anatomical Description of Two Bears and a Bull. (To be published in *Clinical Orthopedics*.)
- STECHEER, ROBERT M. and LEONARD J. GOSS. 1961. Ankylosing Lesions of the Spine of the Horse. *Journal of the American Veterinary Medical Association*, 138: 248-255.
- STEVENSON-HAMILTON, MAJOR J. 1912. *Animal Life in Africa*. E. P. Dutton and Co., New York.
- STOKES, C. S. 1942. *Sanctuary*. Sanctuary Production Committee, Cape Times, Limited, Cape Town.
- TAYLOR, N. W. Y., J. B. KING, and R. M. STECHER. 1955. Osteoarthritis of the hip in gorillas. *Clinical Orthopedics* (6), J. B. Lippincott Co., Philadelphia.
- TOOHEY, LOREN. 1950. Equidae of the upper part of the Marsland formation. M.Sc. Thesis, Dept. Geol., Univ. Nebr.