



CASE REPORT

Acute parotitis due to MRSA causing Lemierre's syndrome

Edward Alabraba*, Nichola Manu, Gemma Fairclough and Robert Sutton

Liverpool NIHR Pancreas Biomedical Research Unit, Royal Liverpool University Hospital, University of Liverpool, Liverpool L69 3GA, UK

*Correspondence address. Liverpool NIHR Pancreas Biomedical Research Unit, Royal Liverpool University Hospital, University of Liverpool, Liverpool L69 3GA, UK. E-mail: Edward.Alabraba@liverpool.ac.uk

Abstract

We report a case of septic thrombophlebitis of the right internal jugular vein linked with right-sided acute parotitis caused by methicillin-resistant *Staphylococcus aureus* (MRSA) in a patient who had recently undergone a pylorus-preserving pancreaticoduodenectomy. Our case is unique because acute parotitis is a less-recognized cause of Lemierre's syndrome, never previously linked with MRSA infection in this context. We review the literature on diagnosis and management of Lemierre's syndrome caused by acute parotitis. Prompt diagnosis and aggressive antibiotics ensured a favourable outcome.

INTRODUCTION

Lemierre's syndrome, also termed necrobacillosis or post-anginal septicaemia, is characterized by primary oropharyngeal infection causing septic thrombophlebitis of the internal jugular vein (IJV) with potential for disseminated metastatic abscesses to the lungs in particular. Sound clinical diagnosis is supported by positive microbial cultures and diagnostic imaging with computed tomography or ultrasound scan. The main pathogen is *Fusobacterium necrophorum*.

We present the first case of a hospitalized patient who, following major abdominal surgery, developed septic thrombophlebitis of the right IJV due to ipsilateral acute parotitis linked with methicillin-resistant *Staphylococcus aureus* (MRSA) bacteraemia.

CASE REPORT

A 79-year-old lady underwent an elective pylorus-preserving pancreaticoduodenectomy for a pancreatic malignancy. A right IJV (RIJV) central venous line was inserted pre-operatively and removed

on the fifth post-operative day. On the sixth post-operative day, she developed sudden onset swelling of her right neck associated with pain, fever and tachycardia. Ear, nose and throat (ENT) assessment diagnosed a swollen inflamed right parotid gland with cellulitis of the overlying skin. Features were consistent with right-sided acute parotitis, facial nerve function being preserved (Fig. 1). Bacterial cultures revealed MRSA in her blood and abdominal drain fluid, and also *Klebsiella* in abdominal drain fluid. They respectively showed microbial sensitivity to Teicoplanin and Tazocin, with which she was treated.

Computed tomography (CT) scan confirmed parotid gland enlargement, mainly the superficial lobe with some extension into the deep lobe, consistent with acute parotitis (Figs 2 and 3). There was no parotid gland abscess or duct calculus. CT also revealed a non-occlusive thrombus at the site of her previous RIJV central venous line.

Tazocin and Teicoplanin were continued for 2 weeks, with good clinical response evident by the fifth day of the antibiotic course. Therapeutic Dalteparin was commenced for her RIJV thrombosis with a plan to continue for 6 months

Received: January 12, 2017. Revised: July 13, 2017. Accepted: 0, 0

© The Author 2017. Published by Oxford University Press.

This is an Open Access article distributed under the terms of the Creative Commons Attribution Non-Commercial License (<http://creativecommons.org/licenses/by-nc/4.0/>), which permits non-commercial re-use, distribution, and reproduction in any medium, provided the original work is properly cited. For commercial re-use, please contact journals.permissions@oup.com

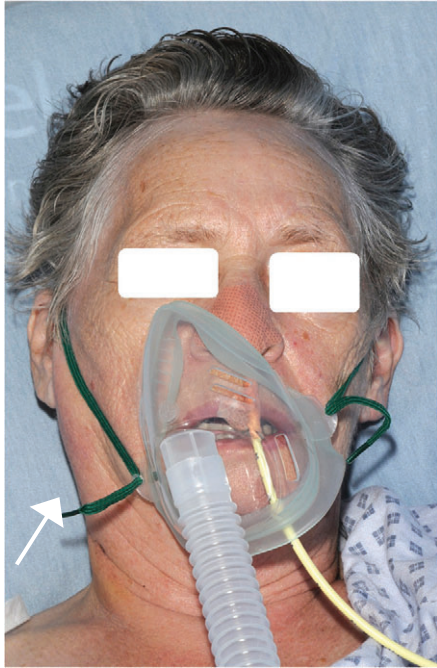

Figure 1: Medical photograph of right parotid gland swelling. Asymmetry of the neck with enlargement of the right parotid gland (arrowed).

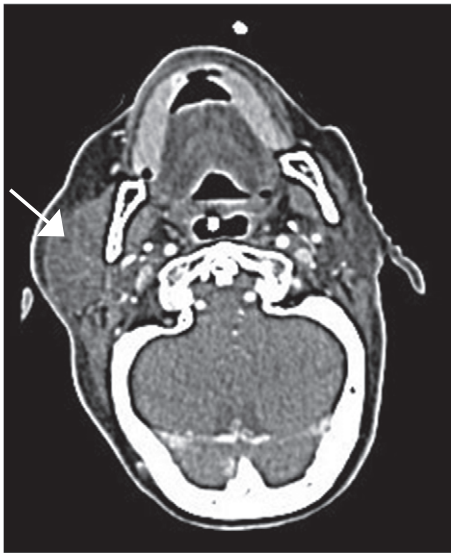

Figure 2: Axial image from a contrast-enhanced neck CT scan. Inflammation involving both the superficial and deep lobes of the right parotid gland (arrowed).

based on haematology advice. She suffered no abdominal or cardiorespiratory post-operative complications and was discharged home the week after finishing her course of antibiotics.

The neck swelling had completely settled when she was reviewed in clinic 4 weeks after discharge.

DISCUSSION

Central venous catheterization is the most common cause of IJV thrombosis, and central venous catheter infections usually

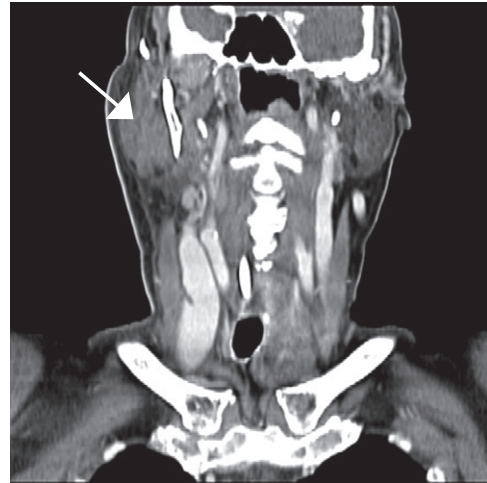

Figure 3: Coronal image from a contrast-enhanced neck CT scan. Thrombosis of the right internal jugular vein (black arrow) and inflammation of the right parotid gland (white arrow).

arise from colonization of the catheter tip by *Staphylococcus aureus*. IJV thrombosis can itself have life-threatening complications but secondary infection of the thrombus may result in septic thrombophlebitis. Septic thrombophlebitis has the hallmark features of venous thrombosis, inflammation and bacteraemia. Lemierre's syndrome describes the unique situation where an infected IJV thrombus arises due to extension of an oropharyngeal infection. The primary localized oropharyngeal infection from which the dangerous systemic septic thrombophlebitis arises is usually pharyngitis caused by *F. necrophorum* [1]. Our case is the first report of Lemierre's syndrome due to MRSA-induced bacterial parotitis. Only two reports indexed on Medline have described acute parotitis as the localized primary infection causing Lemierre's syndrome [2, 3]; the patients in both cases presented as emergencies to hospital and were aggressively treated with empiric followed by microbial sensitivity-based antibiotics. One report described a 73-year-old man whose microbial cultures grew *F. necrophorum* [2], and the other described a 38-year-old man for whom the causative organism was *Streptococcus salivarius* [3]. Acute parotitis associated with RIJV thrombosis has also been reported in the absence of bacteraemia [4] in an otherwise healthy 46-year-old lady who presented to outpatient ENT clinic, had parotitis confirmed by ultrasound with CT scan imaging 48 h after admission additionally showing RIJV thrombosis. All bacterial cultures were negative and her parotitis was successfully treated with empiric antibiotics [4].

Bacterial parotitis is usually caused by *S. aureus* [5], the methicillin-resistant variety (MRSA) likely to be encountered in hospitalized patients as seen in our case. Eleven publications indexed on Medline have reported a total of 17 cases of MRSA-induced parotitis in hospitalized patients [6–10], or community-acquired including cases in nursing home residents [8, 11–14]. Antibiotic therapy remains the mainstay of treatment for Lemierre's syndromes and has effectively obliterated the incidence of the life-threatening complication of Lemierre's syndromes: septic emboli migration to the lungs. Unlike the previous reports of acute parotitis causing Lemierre's syndrome [2, 3] in which the patients presented as emergencies to hospital and were thus initially treated with empiric antibiotics, the patient in our case was in post-operative care following

major surgery and so had recent microbial cultures that had grown MRSA whose antibiotic sensitivities were also available. This allowed us to use sensitivity-based antimicrobials from the outset.

The use of anticoagulants in IJV thrombosis linked with oropharyngeal infection remains controversial, largely due to a lack of controlled studies. It has been proposed that anticoagulation should be reserved for cases where thrombosis fails to resolve following treatment of the infection and those cases in which thrombosis is extensive [15]. The incidence of PE is so rare, and that of fatal PE much rarer, in IJV thrombosis [16] that there is a good argument for withholding therapeutic anticoagulation. Of the two reported cases of septic thrombophlebitis of IJV secondary to acute parotitis [2, 3], the patient in only one case received therapeutic anticoagulation [2], though both were aggressively treated with antibiotics. We chose to anticoagulate our patient because of increased risk of thromboembolism due to risk factors such as recent major surgery and diagnosed malignancy.

Supporting microbial pus cultures are unavailable as we did not identify any discharge from Stensen's duct in our case. Our diagnosis of parotid gland infection precipitating Lemierre's syndrome is consequently based on clinical features, radiological evidence and positive blood culture microbiology. It must be noted that the primary infection in Lemierre's syndrome has usually been pharyngitis accompanied by subtle signs such as pharyngeal hyperaemia [1] rather than frank pharyngeal abscess. Although previous reports have thus ascribed Lemierre's syndrome to oropharyngeal infection without supporting pus cultures, we accept that a limitation of our report is the lack of pus cultures from the parotid gland such that we cannot prove with absolute certainty that the Staphylococcal sepsis was of parotid gland origin. The sceptic may also argue that the observed parotitis in our case was a consequence of MRSA infection caused by the RIJV line. The counterargument to this claim is that unlike reports of IJV septic thrombophlebitis [2, 3] or thrombosis [4] secondary to acute parotitis, there are no reports of acute parotitis caused by IJV line infection. A single case report ascribed clinically suspected parotitis in a patient with an IJV line to migration of the venous catheter outside of the IJV into the soft tissue of the neck [17]. The acute parotitis, IJV thrombosis and MRSA-septicaemia identified in our case are all unified by the diagnosis of Lemierre's syndrome. Lemierre's syndrome, though rare, offers a much better explanation for the clinical picture than the alternative hypothesis of the three aforementioned pathologies being coincidental independent events. Although *F. necrophorum* is the typically described pathogen, several recent publications highlight the emerging role of MRSA as a causative agent of Lemierre's syndrome [18–23]. The recognition of MRSA as a cause of Lemierre's syndrome is important not only to guide the empirical antibiotic treatment but also because community-acquired strains of MRSA are believed to be more virulent than nosocomial MRSA [20].

The link between acute parotitis and IJV thrombosis may be explained by two mechanisms. The first mechanism based on proximity of the parotid gland to the IJV proposes infection involving the deep lobe of the parotid gland transgresses fascial planes leading to thrombophlebitis and thus thrombosis of the IJV. The second mechanism based on shared venous flow between the two structures proposes thrombus propagates from the region of the infected parotid gland to the IJV via the facial vein which drains the parotid gland and then itself drains into the IJV (Fig. 4). IJV thrombosis is of course likely to be

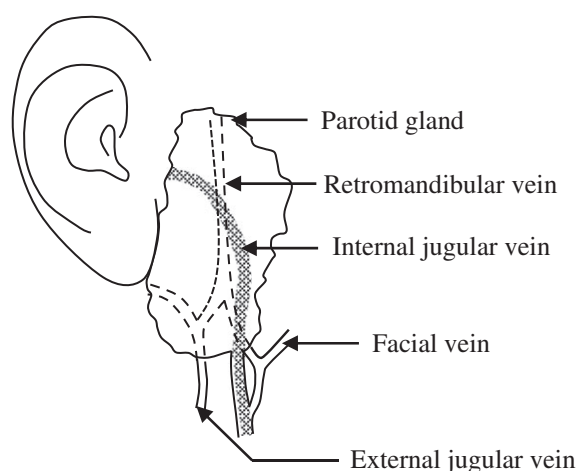


Figure 4: Sagittal schematic illustration of the relationship between right parotid gland and right internal jugular vein. Parotid gland infection may spread to the internal jugular vein by directly breaching fascial planes, or, by venous drainage through the retromandibular to the facial and then to the internal jugular vein.

enhanced by the hypercoagulable state rendered by recent major surgery in our case despite our patient having appropriate thromboprophylaxis.

Lemierre's syndrome remains an important, though rare, condition with potentially lethal consequences. Our report adds to the expanding literature of the increasingly important role of MRSA as a causative agent in the aetiology of Lemierre's syndrome. Prompt accurate diagnosis by timely microbial cultures and imaging using ultrasonography or CT scan can permit early commencement of aggressive treatment, usually with favourable outcome.

CONFLICT OF INTEREST STATEMENT

None declared.

REFERENCES

- Chirinos JA, Lichtstein DM, Garcia J, Tamariz LJ. The evolution of Lemierre syndrome: report of 2 cases and review of the literature. *Medicine* 2002;81:458–65. Epub 2002/11/21.
- Valleix B, Floccard B, Hautin E, Faure F, Allaouchiche B. [A parotitis as primary infection of Lemierre's syndrome]. *Ann Fr Anesth Reanim* 2011;30:692–5. Epub 2011/07/19. A propos d'un syndrome de Lemierre secondaire a une parotidite.
- Rosado P, Gallego L, Junquera L, de Vicente JC. Lemierre's syndrome: a serious complication of an odontogenic infection. *Med Oral Patol Oral Cir Bucal* 2009;14:e398–401. Epub 2009/03/21.
- Hadjihannas E, Kesse KW, d'E Meredith AP. Thrombosis of internal jugular vein associated with acute parotitis. *J Laryngol Otol* 2000;114:721–3. Epub 2000/11/25.
- Brook I. Acute bacterial suppurative parotitis: microbiology and management. *J Craniofac Surg* 2003;14:37–40. Epub 2003/01/25.
- Manfredi R, Primerano AM, Muratori R, Mastroianni A, Gandolfi L, Chiodo F. Bilateral acute suppurative parotitis due to *Staphylococcus aureus*: an hospital acquired case with fatal outcome. *Panminerva Med* 1997;39:56–60. Epub 1997/03/01.

7. Mohammed I, Hofstetter M. Acute bacterial parotitis due to methicillin-resistant *Staphylococcus aureus*. *South Med J* 2004; **97**:1139. Epub 2004/12/14.
8. Enoch DA, Karas JA, Emery MM, Borland C. Two cases of parotid gland infection with bacteraemia due to methicillin-resistant *Staphylococcus aureus*. *J Med Microbiol* 2006; **55**:463–5. Epub 2006/03/15.
9. Lee VK, Kimbrough DJ, Jarquin-Valdivia AA. Acute bacterial parotitis following acute stroke. *Infection* 2009; **37**:283–5. Epub 2008/06/03.
10. Richards W, Steehler M. MRSA parotitis. *Ear Nose Throat J* 2013; **92**:E66. Epub 2013/06/20.
11. Cohen MA, Docktor JW. Acute suppurative parotitis with spread to the deep neck spaces. *Am J Emerg Med* 1999; **17**:46–9. Epub 1999/02/03.
12. Chien JW, Kucia ML, Salata RA. Use of linezolid, an oxazolidinone, in the treatment of multidrug-resistant gram-positive bacterial infections. *Clin Infect Dis* 2000; **30**:146–51. Epub 2000/01/05.
13. Kristensen RN, Hahn CH. Facial nerve palsy caused by parotid gland abscess. *J Laryngol Otol* 2012; **126**:322–4. Epub 2011/10/25.
14. Rousseau P. Acute suppurative parotitis. *J Am Geriatr Soc* 1990; **38**:897–8. Epub 1990/08/01.
15. Eilbert W, Singla N. Lemierre's syndrome. *Int J Emerg Med* 2013; **6**:40. Epub 2013/10/25.
16. Levy MM, Albuquerque F, Pfeifer JD. Low incidence of pulmonary embolism associated with upper-extremity deep venous thrombosis. *Ann Vasc Surg* 2012; **26**:964–72. Epub 2012/07/04.
17. Linden DH. Rhinorrhea with total parenteral nutrition fluid complicating central venous catheterization. *CMAJ* 1988; **138**:1119–20. Epub 1988/06/15.
18. Chanin JM, Marcos LA, Thompson BM, Yusen RD, Dunne WM Jr., Warren DK, et al. Methicillin-resistant *Staphylococcus aureus* USA300 clone as a cause of Lemierre's syndrome. *J Clin Microbiol* 2011; **49**:2063–6. Epub 2011/03/25.
19. Abhishek A, Sandeep S, Tarun P. Lemierre syndrome from a neck abscess due to methicillin-resistant *Staphylococcus aureus*. *Braz J Infect Dis* 2013; **17**:507–9. Epub 2013/06/26.
20. Gunatilake SS, Yapa LG, Gallala M, Gamlath R, Rodrigo C, Wimalaratna H. Lemierre's syndrome secondary to community-acquired methicillin-resistant *Staphylococcus aureus* infection presenting with cardiac tamponade, a rare disease with a life-threatening presentation: a case report. *Int J Emerg Med* 2014; **7**:39. Epub 2015/01/31.
21. Kizhner V, Samara G, Panesar R, Krespi YP. Methicillin-resistant *Staphylococcus aureus* bacteraemia associated with Lemierre's syndrome: case report and literature review. *J Laryngol Otol Suppl* 2013; **127**:721–3. Epub 2013/05/25.
22. Molloy A, Towersey G, Shackleton D, Aali A, Ash S. The changing face of an old disease: case report of nonclassical Lemierre's syndrome caused by a Pantone-Valentine leucocidin-positive methicillin-susceptible *Staphylococcus aureus* isolate. *J Clin Microbiol* 2012; **50**:3144–5. Epub 2012/07/05.
23. Jariwala RH, Srialluri S, Huang MZ, Boppana SB. Methicillin-resistant *Staphylococcus aureus* as a cause of Lemierre's syndrome. *Pediatr Infect Dis J* 2017; **36**:429–31. Epub 2016/12/16.