

47. Green D, Roberts PR, New DI *et al.* Sudden cardiac death in hemodialysis patients: an in-depth review. *Am J Kidney Dis* 2011; 57: 921–929
48. Rigatto C, Levin A, House AA *et al.* Atheroma progression in chronic kidney disease. *Clin J Am Soc Nephrol* 2009; 4: 291–298
49. Herzog CA, Asinger RW, Berger AK *et al.* Cardiovascular disease in chronic kidney disease. A clinical update from Kidney Disease: Improving Global Outcomes (KDIGO). *Kidney Int* 2011; 80: 572–586
50. Gaudet D, Kereiakes DJ, McKenney JM *et al.* Effect of alirocumab, a monoclonal proprotein convertase subtilisin/kexin 9 antibody, on lipoprotein(a) concentrations (a pooled analysis of 150 mg every two weeks dosing from phase 2 trials). *Am J Cardiol* 2014; 114: 711–715
51. Romagnuolo R, Scipione CA, Boffa MB *et al.* Lipoprotein(a) catabolism is regulated by proprotein convertase subtilisin/kexin type 9 through the low density lipoprotein receptor. *J Biol Chem* 2015; 290: 11649–11662
52. Kostner GM, Gavish D, Leopold B *et al.* HMG CoA reductase inhibitors lower LDL cholesterol without reducing Lp(a) levels. *Circulation* 1989; 80: 1313–1319
53. Khera AV, Everett BM, Caulfield MP *et al.* Lipoprotein(a) concentrations, rosuvastatin therapy, and residual vascular risk: an analysis from the JUPITER Trial (justification for the use of statins in prevention: an intervention trial evaluating rosuvastatin). *Circulation* 2014; 129: 635–642
54. O'Donoghue M, Morrow DA, Tsimikas S *et al.* Lipoprotein(a) for risk assessment in patients with established coronary artery disease. *J Am Coll Cardiol* 2014; 63: 520–527
55. Kronenberg F. Lipoprotein(a): there's life in the old dog yet. *Circulation* 2014; 129: 619–621

Received for publication: 17.8.2015; Accepted in revised form: 23.11.2015

Nephrol Dial Transplant (2016) 31: 1908–1914  
doi: 10.1093/ndt/gfw051  
Advance Access publication 8 April 2016

## A novel *COL4A1* frameshift mutation in familial kidney disease: the importance of the C-terminal NC1 domain of type IV collagen

Daniel P. Gale<sup>1</sup>, D. Deren Oygur<sup>2</sup>, Fujun Lin<sup>1,3</sup>, P. Derin Oygur<sup>4</sup>, Nadia Khan<sup>1</sup>, Thomas M.F. Connor<sup>5</sup>, Marta Lapsley<sup>6</sup>, Patrick H. Maxwell<sup>7</sup> and Guy H. Neild<sup>1</sup>

<sup>1</sup>UCL Centre for Nephrology, University College, London, UK, <sup>2</sup>Nephrology Department, Nicosia State Hospital, Nicosia, North Cyprus, <sup>3</sup>Department of Nephrology, Xin Hua Hospital, School of Medicine, Shanghai Jiao Tong University, Shanghai, China, <sup>4</sup>Department of Pediatrics, Nicosia State Hospital, Nicosia, North Cyprus, <sup>5</sup>West London Renal and Transplant Institute, Imperial College, London, UK, <sup>6</sup>South West Thames Institute for Renal Research, St Helier Hospital, Carshalton, UK and <sup>7</sup>School of Clinical Medicine, Cambridge University, Cambridge, UK

Correspondence and offprint requests to: Daniel P. Gale; E-mail: [d.gale@ucl.ac.uk](mailto:d.gale@ucl.ac.uk)

### ABSTRACT

**Background.** Hereditary microscopic haematuria often segregates with mutations of *COL4A3*, *COL4A4* or *COL4A5* but in half of families a gene is not identified. We investigated a Cypriot family with autosomal dominant microscopic haematuria with renal failure and kidney cysts.

**Methods.** We used genome-wide linkage analysis, whole exome sequencing and cosegregation analyses.

**Results.** We identified a novel frameshift mutation, c.4611\_4612insG:p.T1537fs, in exon 49 of *COL4A1*. This mutation predicts truncation of the protein with disruption of the C-terminal part of the NC1 domain. We confirmed its presence in

20 family members, 17 with confirmed haematuria, 5 of whom also had stage 4 or 5 chronic kidney disease. Eleven family members exhibited kidney cysts (55% of those with the mutation), but muscle cramps or cerebral aneurysms were not observed and serum creatine kinase was normal in all individuals tested.

**Conclusions.** Missense mutations of *COL4A1* that encode the CB3 [IV] segment of the triple helical domain (exons 24 and 25) are associated with HANAC syndrome (hereditary angiopathy, nephropathy, aneurysms and cramps). Missense mutations of *COL4A1* that disrupt the NC1 domain are associated with antenatal cerebral haemorrhage and porencephaly, but not kidney disease. Our findings extend the spectrum of *COL4A1* mutations linked with renal disease and demonstrate that the highly conserved C-terminal part of the NC1 domain of the  $\alpha 1$  chain of type IV collagen is important in the integrity of glomerular basement membrane in humans.

**Keywords:** *COL4A1*, familial nephropathy, genetic renal disease, glomerular basement membrane, type IV collagen

## INTRODUCTION

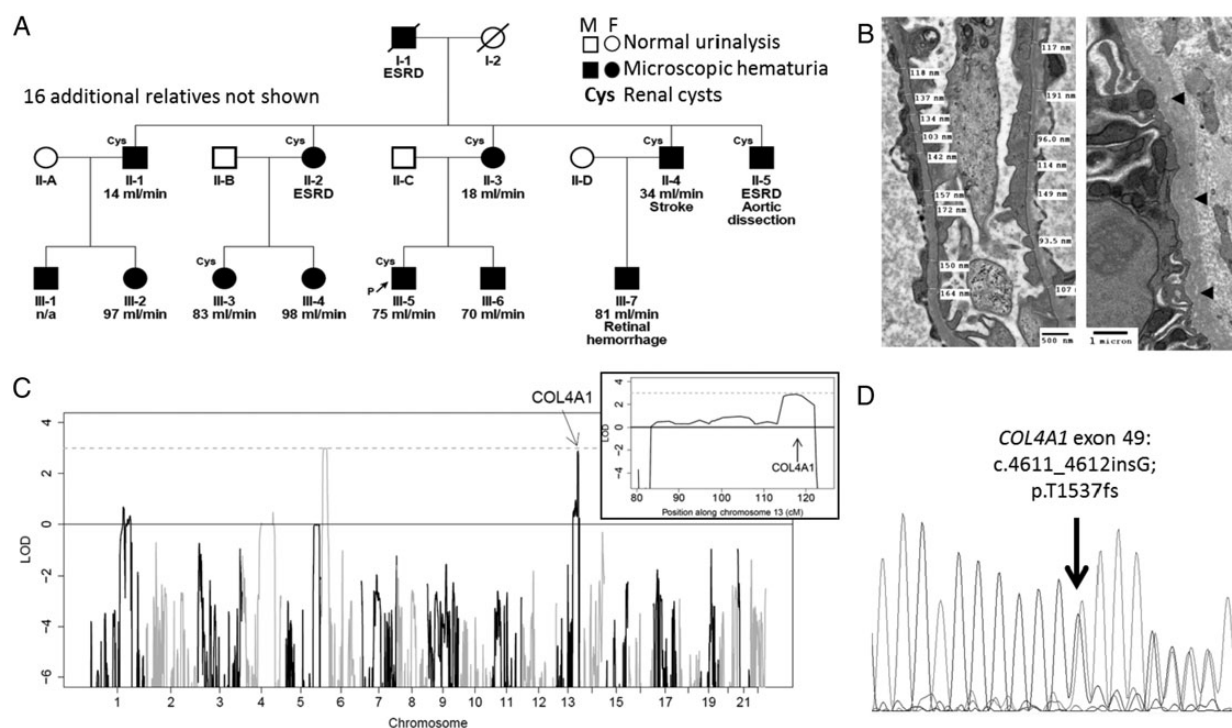
Isolated microscopic haematuria is a significant risk factor for kidney failure in later life [1] and can be the presenting feature of a number of disorders, which can be monogenic or non-familial. Since kidney biopsy is seldom performed where there is no evidence of kidney damage (i.e. proteinuria, hypertension or renal impairment), a firm diagnosis has traditionally only been possible in patients with more advanced kidney disease. Today, however, the cause of familial kidney disease may be identified at an early stage using genetic testing. This can have important implications for the patient and his/her family because prognosis and risk to family and offspring depends on the diagnosis [2].

The most common inherited cause of microscopic haematuria is thin basement membrane nephropathy (TBMN), which is characterized by thinning or irregularity of the glomerular basement membrane visible on electron microscopy. In many families a cause is not identified, however, in 40–50% cases, TBMN is linked with a heterozygous mutation of the *COL4A3*, *COL4A4* or *COL4A5* genes that encode type IV collagen, and the clinical features overlap with the carrier state for autosomal recessive or X-linked Alport syndrome [3–5]. Most carriers of a heterozygous *COL4A3/4* mutation have an

excellent prognosis; however, 15–20% will develop renal impairment or even end-stage renal disease (ESRD), usually in later life [4, 6]. Other monogenic causes of kidney disease that can present with isolated microscopic haematuria include Alport syndrome, which is either X-linked (caused by hemizygous mutation of *COL4A5*) or autosomal recessive (caused by bi-allelic mutation of the *COL4A3* or *COL4A4* genes); CFHR5 nephropathy (caused by an internal duplication of *CFHR5* [7]); MYH9-associated glomerulopathy (caused by mutations of *MYH9* and also associated with proteinuria, deafness and platelet abnormalities [8]); and hereditary angiopathy, nephropathy, aneurysms and cramps (HANAC) syndrome, which is associated with heterozygous mutations in exons 24 and 25 of the *COL4A1* gene [9]. We investigated a family of Turkish Cypriot origin in which microscopic haematuria and renal impairment segregated as a dominant trait (Figure 1).

## MATERIALS AND METHODS

All research involving human participants was performed with written informed consent and was approved by the ethics committee of Lefkosa Burhan Nalbantoğlu State Hospital. All participants provided informed consent for their involvement in the research in accordance with the Declaration of Helsinki and for publication of the study results. Individuals were genotyped on the Linkage IV panel (Illumina, San Diego, CA, USA)



**FIGURE 1:** (A) Family tree showing affected individuals participating in the genome-wide linkage study. P denotes proband. Estimated glomerular filtration rate in mL/min is shown for each individual (where known) and ESRD denotes end-stage renal disease. (B) Electron micrographs of kidney biopsy from individual III-5 showing thin glomerular basement membranes and lamellation and lucencies in the tubular basement membranes (arrowheads). (C) Genome-wide linkage excluded loci containing genes previously associated with haematuria, except for a locus on chromosome 13 that contains the *COL4A1* gene (inset), LOD score = 3. (D) Sanger sequencing of exon 49 of *COL4A1* demonstrated a G insertion, predicting a p.T1537fs mutation of the type IV collagen  $\alpha$ 1 chain.

according to the manufacturers' instructions. Linkage analysis was performed using GeneHunter v2.1 [10]. Exome sequencing was performed by enrichment with the Agilent SureSelect All Exon array and sequencing using an Illumina Genome Analyzer IIx. Reads were aligned to the reference genome (GRCh37) using Novoalign (Novocraft Technologies, Selangor, Malaysia). Variants were called using GATK [11] and annotated with Annotvar [12]. Resequencing of *COL4A1* exon 49 was performed using the primers 5'-TGCTTGTTGTCCAGCTGAAAT-3' and 5'-ACAGGAGGAAAGGCAACCAC-3', amplified by polymerase chain reaction at an annealing temperature of 58°C. Three-dimensional models were generated using Jmol [13], based on the crystal structure 1li1 from the protein database [14].

Retinol-binding protein (RBP) was assayed as previously described using a polyclonal in-house sandwich ELISA [15]. Urinary N-acetyl-beta-D-glucosaminidase (NAG) activity was measured using a kit from PPR Diagnostics (London, UK). Albumin and creatinine (enzymatic) were measured on an Abbott Architect (Abbott Diagnostics, Lake Forest, IL, USA).

## RESULTS

Clinical information was available for 29 family members, of whom 19 exhibited >1+ microscopic haematuria on urine dipstick testing. Fifteen family members had renal impairment [(estimated glomerular filtration rate eGFR) <90 mL/min], three requiring renal replacement therapy.

### Genotype

Genes associated with autosomal dominant thin basement membrane nephropathy (*COL4A3* and *COL4A4*) were sequenced in the proband by amplification of each exon and Sanger sequencing. This did not reveal any rare or likely pathogenic variants. A genome-wide linkage study was performed using DNA from 12 affected family members. This excluded linkage with loci containing the genes *COL4A3*, *COL4A4*, *COL4A5*, *MYH9* and *CFHR5* (LOD < -2 at each locus), but did demonstrate linkage (LOD = 3) with loci on chromosomes 6 and 13 that include the *COL4A1* gene on chromosome 13 (Figure 1C). Whole exome sequencing was performed in the proband, which identified no likely pathogenic variants in *COL4A3*, *COL4A4*, *COL4A5*, *MYH9* or *CFHR5*. Across the whole exome, 688 variants that were both rare (i.e. occur with an allele frequency of <0.5% in the 1000 genomes database) and predicted a change in amino acid sequence of a protein (including amino acid substitutions, insertions, deletions, splicing, frameshift or termination mutations) were identified. Of these, 644 were heterozygous and 270 were novel (i.e. not reported in dbSNP). Two rare variants, both heterozygous, occurred within the linked loci. One variant predicted a missense mutation p.A101T in *TMEM14C* (NM\_016462) on chromosome 6. This gene has not previously been associated with kidney disease and the variant is predicted to be benign, with SIFT and Polyphen scores of 0.42 and 0.023, respectively. The other variant was in the *COL4A1* gene and encodes a novel frameshift mutation c.4611\_4612insG; p.T1537fs (transcript NM\_00185). This was considered a good candidate for causing

disease since other mutations in this gene are associated with HANAC syndrome, in which haematuria, kidney cysts and renal impairment are features.

The *COL4A1* mutation was confirmed by Sanger sequencing (Figure 1D), and screening across all available samples revealed its presence in all affected individuals participating in the linkage study and in a further eight relatives, seven of whom had one or more of haematuria, cysts or evidence of reduced renal function (eGFR <90 mL/min). The individual lacking clear evidence of kidney disease was 23 years old at the time of assessment and had trace haematuria on dipstick testing. Eight offspring of affected family members were found not to harbour the *COL4A1* variant, of whom one was found to have dipstick haematuria on a single occasion, associated with normal renal function and imaging, and one (designated individual II-6) exhibited renal impairment, haematuria, proteinuria and kidney cysts (Table 1). We regard these individuals as phenocopies, which is not an unexpected finding given the high prevalence of clinical evidence of kidney disease known to be present in this and other populations [16–18]. The mutation is not present in any online databases of human genetic variation and was not detected by sequencing a cohort of 63 unrelated healthy Turkish Cypriot adults.

To determine whether an additional mutation might be segregating in other family members we went on to sequence *COL4A3*, *COL4A4* and *COL4A5* in individual II-2 (who harboured the *COL4A1* mutation and had developed ESKD) and individual II-6. No rare or likely pathogenic mutations of these genes were identified in either of these individuals. We conclude that the *COL4A1* mutation is responsible for the familial renal disease in this kindred. We went on to examine whole exome sequencing data from four other families in which glomerular basement membrane abnormalities and microscopic haematuria segregated as a dominant trait in the absence of a *COL4A3*, *COL4A4* or *COL4A5* mutation but did not find any additional likely pathogenic variants in *COL4A1*.

**Table 1. Clinical features in family members with and without the *COL4A1* p.T1537fs frameshift mutation**

Clinical feature		With mutation	Without mutation
Haematuria	Present	17	2
	Absent/trace	2	6
Proteinuria	Present	7	1
	Absent	12	7
Kidney cysts	Present	11	1
	Absent	7	4
Creatine kinase	Elevated	0	0
	Normal	16	6
Retinal vessels	Tortuous	0	0
	Normal	4	0
Kidney function	eGFR > 90	5	7
	eGFR 31–90	14	1
	eGFR < 30	4	0
	ESRD	3	0
Total family members		20	8

Proteinuria: albumin:creatinine ratio >3.0 mg/mmol; kidney cysts: as seen on renal ultrasound; retinal vessels: as seen by retinal photography.



## Clinical phenotype

Renal failure was unpredictable, with creatinine rising above the normal range in some affected members after the age of 40 years. End-stage renal failure ranged from 63 to 70 years in three of nine siblings in the first generation. In those affected, one or more kidney cysts were detectable by ultrasound from the age of 40 years in 12 family members. Hypertension was variable, but could be present from 35 years of age. No family members reported a history of muscle cramps or cerebral aneurysms, and serum creatine kinase was normal in all 22 family members tested. Some family members had evidence of vascular disease (summarized in Figure 1A). Hyperuricaemia was not found and no patient had a history of gout. Brain MRI scanning and retinal photography in four affected members of the family revealed no evidence of cerebral or ocular angiopathy.

Little or no proteinuria (albumin:creatinine ratio <3 mg/mmol) was found until the eGFR was <50 mL/min/1.73 m<sup>2</sup>. Urine samples from 15 affected people were also investigated for tubular proteinuria. Of the 10 mutation carriers without microalbuminuria, 5 had an elevated RBP:creatinine ratio ≥25 mg/mmol (97.5th upper centile <18 mg/mmol creatinine) and 3 had an elevated NAG:creatinine ratio (normal range <28 μmol/h/L).

A kidney biopsy was performed in one family member at age 47 years to investigate familial nephropathy and reduced eGFR. Light microscopic examination was normal with the exception of minimal global glomerulosclerosis (1 of 25 glomeruli) and <1% tubular atrophy. Immunostains for type IV collagen were not performed, but stains for immunoglobulins and complement were negative. Electron microscopy demonstrated areas of thinning of glomerular basement membranes (down to 93.5 nm) and subtle lamellation of tubular basement membranes (Figure 1B). Glomerular basement membrane splitting or irregularity of the outer surface was not observed and the ultrastructural appearances were judged to represent thin basement membrane nephropathy rather than Alport syndrome.

## DISCUSSION

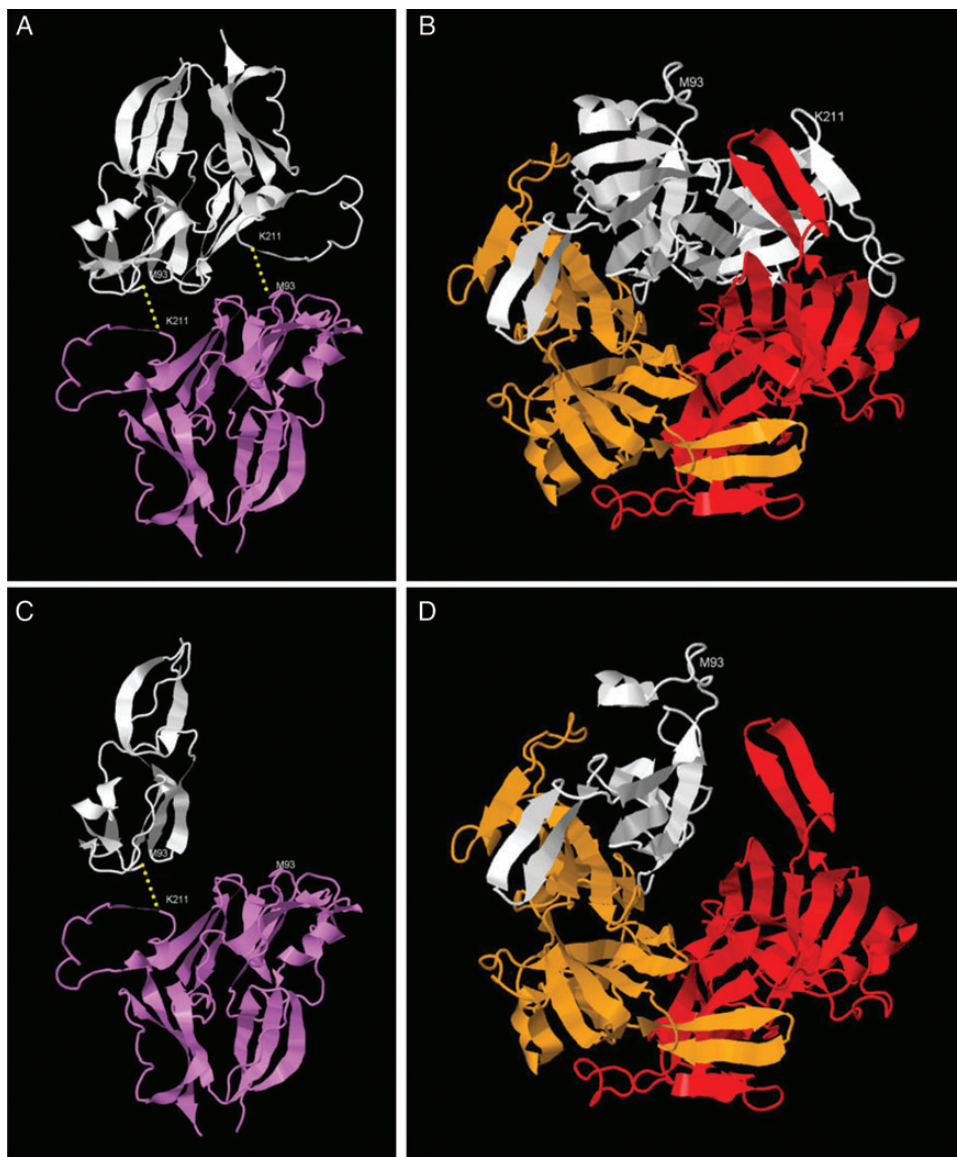
Type IV collagen is an important constituent of the extracellular matrix and forms a complex meshwork that provides structural integrity to basement membranes [19]. Individual type IV collagen molecules are made up of three alpha chains that form a heterotrimeric structure that includes a non-collagenous (NC1) domain at the C-terminus that initiates heterotrimer formation [20], and a long collagenous 'tail' interspersed with non-collagenous interruptions. The collagenous domains of three alpha chain subunits interweave to form a stiff triple helical structure and the non-collagenous interruptions likely confer flexibility and allow intermolecular cross-linking, leading to formation of the macromolecular collagen network [21]. The NC1 domains of adjacent trimers are themselves covalently cross-linked by sulfilimine bonds at conserved residues to form hexamers [22]. The α1.α1.α2 isoform of type IV collagen is composed of two α1 chains and one α2 chain, encoded by the genes *COL4A1* and *COL4A2*, respectively, and is very highly conserved across species, forming an important component of most basement membranes. This contrasts with the other naturally occurring type IV collagen isoforms (α3.α4.α5 and α5.α5.α6) that have a more restricted distribution of expression and are less broadly conserved across species [21].

Pathogenic mutations of *COL4A1* are associated with neurological, vascular and renal disorders. Previously described phenotypes cluster into primarily neurological disease, in which porencephaly (the occurrence of fluid filled cavities in the brain) and cerebral vasculopathy or haemorrhage cause significant neurological damage early in life [23], and HANAC syndrome, in which neurological involvement tends to be milder and haematuria, kidney cysts and occasionally late-onset renal impairment are features [9]. The mechanisms of pathogenicity in *COL4A1*-associated diseases are incompletely understood. However, it is unlikely that haplo-insufficiency is a major contributor in most cases: previously described pathogenic mutations

Table 2. The C-terminal NC1 domain of *COL4A1* is highly conserved across species

Common name	Phylum	Latin name	Sequence
Mutant allele			TPEPMPMSMAPITGGGKHKT <u>Y</u>
Human	Chordata	<i>Homo sapiens</i>	TPEPMPMSMAPITGENIRPFISRCV...PTPSTLKAGELRTHVSRQCVCMRRT
Chimpanzee	Chordata	<i>Pan troglodytes</i>	TPEPMPMSMAPITGENIRPFISRCV...PTPSTLKAGELRTHVSRQCVCMRRT
Monkey	Chordata	<i>Macaca mulatta</i>	TPEPMPMSMAPITGDNIRPFISRCV...PTPSTLKAGELRTHVSRQCVCMRRT
Wolf	Chordata	<i>Canis lupus</i>	TPEPMPMSMAPIAGDNIRPFISRCV...PTPSTLKAGELRTHVSRQCVCMRRT
Cow	Chordata	<i>Bos taurus</i>	TPEPMPMSMAPITGENIRPFISRCV...PTPSTLKAGELRTHVSRQCVCMRRT
Mouse	Chordata	<i>Mus musculus</i>	TPEPMPMSMAPISGDNIRPFISRCV...PTPSTLKAGELRTHVSRQCVCMRRT
Rat	Chordata	<i>Rattus norvegicus</i>	TPEPMPMSMAPISGDNIRPFISRCV...PTPSTLKAGELRTHVSRQCVCMRRT
Chicken	Chordata	<i>Gallus gallus</i>	TPEPMPMSMAPITGESIRPFISRCV...PTPSTLKAGDLRSNVSRQCVCMRNT
Zebrafish	Chordata	<i>Danio rerio</i>	TPEPMPMSMAPVPTGESIKPFISRCV...PVPATLKAGSLRTHISRCQCVCMKRV
Xenopus	Chordata	<i>Xenopus tropicalis</i>	TPEPMPMSMAPITGDGKPFISRCTV...PTPSTLKAGDLRTHVSRQCVCMRRTS
Fruit Fly	Arthropoda	<i>Drosophila melanogaster</i>	T-TNAAIPMPVENVIEIRQYISRCV...PQQQTIKAGERQSHVSRQCVCMKNSS
Roundworm	Nematoda	<i>Ascaris suum</i>	LSTTAPIPMPVSEGGIEPYISRCV...PESETLKAGSLRTRVSRQCVCIRSPDVQPYRG
Roundworm	Nematoda	<i>Caenorhabditis elegans</i>	TDEPMTPMNPNVTGTAIRPYISRCV...PMSQTLKAGGLKDRVSRQCVCCLKNR
Pink Hydroid	Cnidaria	<i>Ectopleura larynx</i>	TPEPMPMMMNPVEGRDIEKYVSRCSV...PQSQTLKAGNQRSRISRCQCVMRRR
Freshwater Jellyfish	Cnidaria	<i>Craspedacusta sowerbyi</i>	STEQEPNMMRPSKGIENRDYISRCIV...PVPETIKAGQLRQVSRCAVCMKNNKANEP

The residues (M<sup>93</sup> and K<sup>211</sup>) that participate in the sulfilimine bond between adjacent heterotrimers are in bold. Approximately 100 residues (denoted by '...') are omitted for clarity. The mutant terminal peptide present in the family is underlined and lacks K<sup>211</sup>. Adapted from Fidler *et al.* [25].



**FIGURE 2:** (A) The NC1 domain of one  $\alpha 1$  chain (white) of a trimeric type IV collagen molecule forms two sulfilimine bonds (yellow) with the NC1 domain of an  $\alpha 1$  chain of the adjacent trimer (violet). Additional alpha chains in each trimer not shown. (B) The NC1 domains of two  $\alpha 1$ (IV) chains (white and orange) and one  $\alpha 2$ (IV) chain (red) interact to form a heterotrimer, viewed face on to the dimerization surface [i.e. perpendicular to the view shown in (A)]. (C) The truncated protein predicted by the p.T1537fs mutation lacks the C-terminal  $K^{211}$  residue and hence is only able to form a single sulfilimine bond. (D) Truncation of the protein is predicted to disrupt the normal interaction with one other subunit of a type IV collagen heterotrimer, although the surface interacting with the other subunit is intact.

in humans are almost all missense variants and do not include early nonsense mutations or heterozygous whole gene deletions; only a single collagenous-domain frameshift mutation that reduced transcript levels has been reported to date [23]. Moreover, mice heterozygous for a null *Col4A1* allele do not display any detectable phenotype [21]. Mutations causing HANAC syndrome have been reported only in exons 24 and 25 of *COL4A1*, encoding a region of the protein that contains multiple potential integrin-binding sites, and it has been suggested that disruption of normal interaction between type IV collagen and integrins might be responsible for HANAC syndrome [21, 24]. Thinning of glomerular basement membranes (in which  $\alpha 3.\alpha 4.\alpha 5$  is the predominant type IV collagen isoform) is not reported in either HANAC syndrome or other *COL4A1*-associated diseases.

Frameshift variants of *COL4A1* are exceedingly rare, with only one example observed (encoding p.P438fs) in >120 000 alleles tested in the ExAC project and a single pathogenic allele (p.G696fs) reported previously in the medical literature [23]. The p.T1537fs mutation we identified is predicted to result in the substitution of the 132 C-terminal amino acids of the protein with the peptide ‘GGGKHKTIY’ followed by a premature termination codon. The missing C-terminal domain is highly conserved across evolution (present even in cnidarian and nematode species; see Table 2) and includes Lysine 211 ( $K^{211}$ ), which is essential for the sulfilimine bond cross-linking adjacent trimers to form hexameric type IV collagen [25]. It also encodes the part of the protein that interacts with one (but not both) of the other subunits in a heterotrimer (Figure 2).

One possible mechanism whereby loss of this part of the NC1 domain could cause disease includes disruption of sulfhydryl bond(s) by inclusion of one or more defective  $\alpha 1$  chain missing the C-terminal part of its NC1 domain within an  $\alpha 1$ .  $\alpha 1$ .  $\alpha 2$  type IV collagen heterotrimer (Supplementary Video S1). Alternatively, since it is known that  $\alpha 1$  type IV chains are expressed in podocytes and present in glomeruli of healthy adults [26, 27], it is possible that the defective NC1 domain resulting from this mutation could cause incorrect recognition and assembly of glomerular type IV collagen heterotrimers [20], perhaps resulting in incorporation of the mutant  $\alpha 1$  subunit in  $\alpha 3$ .  $\alpha 4$ .  $\alpha 5$  type IV collagen trimers of glomerular basement membranes. This might explain the observed thinning of glomerular basement membranes. Our data clearly do not exclude a dominant negative or gain-of-function effect of the mutation mediated by a mechanism unrelated to trimer formation, such as interaction of monomeric mutant protein with type IV collagen via the non-collagenous interruptions within the alpha chains. The possibility that the disease mechanism is disruption of basement membrane formation due to haplo-insufficiency for *COL4A1* is considered less likely for the reasons stated above. A homozygous truncating mutation within the C-terminal NC1 domain of *COL4A4* has previously been reported in association with autosomal recessive Alport syndrome, but the phenotype of the obligate carrier parents was not documented in this report [28], so it is not known whether this similar mutation in a different type IV collagen chain in heterozygosity has similar phenotypic effects to the mutation described here.

In summary, we present a novel *COL4A1* mutation linked with kidney disease that is predicted to cause loss of a highly conserved part of the C-terminal NC1 domain of the  $\alpha 1$  type IV collagen chain that is important in interactions within and between type IV collagen heterotrimers. This demonstrates that this part of the protein is important in the normal function of type IV collagen in humans.

## SUPPLEMENTARY DATA

Supplementary data are available online at <http://ndt.oxfordjournals.org>.

## ACKNOWLEDGEMENTS

The authors thank the patients and their families. We also thank Meral Yükseliş for assistance with data and sample collection. An abstract related to this work was presented at the European Renal Association conference in London in May 2015. D.P.G. is supported by the UK Medical Research Council and P.H.M. by a Wellcome Trust Investigator Award. This work was also supported by funding from the European Renal Association, Rosetrees and St Peter's Trusts. Funding to pay the Open Access publication charges for this article was provided by the Medical Research Council.

## CONFLICT OF INTEREST STATEMENT

The authors have no competing interests. The results presented in this paper have not been published previously in whole or part, except in abstract format.

(See related article by Savige. A further genetic cause of thin basement membrane nephropathy. *Nephrol Dial Transplant* 2016; 31: 1758–1760)

## REFERENCES

1. Vivante A, Afek A, Frenkel-Nir Y *et al*. Persistent asymptomatic isolated microscopic hematuria in Israeli adolescents and young adults and risk for end-stage renal disease. *JAMA* 2011; 306: 729–736
2. Gale DP. How benign is hematuria? Using genetics to predict prognosis. *Pediatr Nephrol* 2013; 28: 1183–1193
3. Pierides A, Voskarides K, Athanasiou Y *et al*. Clinico-pathological correlations in 127 patients in 11 large pedigrees, segregating one of three heterozygous mutations in the *COL4A3*/*COL4A4* genes associated with familial haematuria and significant late progression to proteinuria and chronic kidney disease from focal segmental glomerulosclerosis. *Nephrol Dial Transplant* 2009; 24: 2721–2729
4. Temme J, Peters F, Lange K *et al*. Incidence of renal failure and nephroprotection by RAAS inhibition in heterozygous carriers of X-chromosomal and autosomal recessive Alport mutations. *Kidney Int* 2012; 81: 779–783
5. Buzza M, Wang YY, Dagher H *et al*. *COL4A4* mutation in thin basement membrane disease previously described in Alport syndrome. *Kidney Int* 2001; 60: 480–483
6. Voskarides K, Damianou L, Neocleous V *et al*. *COL4A3*/*COL4A4* mutations producing focal segmental glomerulosclerosis and renal failure in thin basement membrane nephropathy. *J Am Soc Nephrol* 2007; 18: 3004–3016
7. Gale DP, de George EG, Cook HT *et al*. Identification of a mutation in complement factor H-related protein 5 in patients of Cypriot origin with glomerulonephritis. *Lancet* 2010; 376: 794–801
8. Han KH, Lee H, Kang HG *et al*. Renal manifestations of patients with MYH9-related disorders. *Pediatr Nephrol* 2011; 26: 549–555
9. Plaisier E, Gribouval O, Alamowitch S *et al*. *COL4A1* mutations and hereditary angiopathy, nephropathy, aneurysms, and muscle cramps. *N Engl J Med* 2007; 357: 2687–2695
10. Markianos K, Daly MJ, Kruglyak L. Efficient multipoint linkage analysis through reduction of inheritance space. *Am J Hum Genet* 2001; 68: 963–977
11. McKenna A, Hanna M, Banks E *et al*. The Genome Analysis Toolkit: a MapReduce framework for analyzing next-generation DNA sequencing data. *Genome Res* 2010; 20: 1297–1303
12. Wang K, Li M, Hakonarson H. ANNOVAR: functional annotation of genetic variants from high-throughput sequencing data. *Nucleic Acids Res* 2010; 38: e164
13. *Jmol: an open-source Java viewer for chemical structures in 3D*. 2015. <http://jmol.sourceforge.net/>
14. Than ME, Henrich S, Huber R *et al*. The 1.9-Å crystal structure of the non-collagenous (NC1) domain of human placenta collagen IV shows stabilization via a novel type of covalent Met-Lys cross-link. *Proc Natl Acad Sci USA* 2002; 99: 6607–6612
15. Lapsley M, Akers K, Norden AG. Sensitive assays for urinary retinol-binding protein and beta-2-glycoprotein-1 based on commercially available standards. *Ann Clin Biochem* 1998; 35(Pt 1): 115–119
16. Chadban SJ, Briganti EM, Kerr PG *et al*. Prevalence of kidney damage in Australian adults: The AusDiab kidney study. *J Am Soc Nephrol* 2003; 14 (7 Suppl 2): S131–S138
17. Levine AP, Connor TMF, Oygur DD *et al*. Combinatorial Conflicting Homozygosity (CCH) analysis enables the rapid identification of shared genomic regions in the presence of multiple phenocopies. *BMC Genomics* 2015; 16: 163

18. Connor TME, Oygur DD, Gale DP *et al.* Incidence of end-stage renal disease in the Turkish-Cypriot population of Northern Cyprus: a population based study. *PLoS One* 2013; 8: e54394
19. Ricard-Blum S. The collagen family. *Cold Spring Harb Perspect Biol* 2011; 3: a004978
20. Boutaud A, Borza DB, Bondar O *et al.* Type IV collagen of the glomerular basement membrane.: Evidence that the chain specificity of network assembly is encoded by the noncollagenous NC1 domains. *J Biol Chem* 2000; 275: 30716–30724
21. Kuo DS, Labelle-Dumais C, Gould DB. COL4A1 and COL4A2 mutations and disease: insights into pathogenic mechanisms and potential therapeutic targets. *Hum Mol Genet* 2012; 21(R1): R97–110
22. Vanacore R, Ham A-JL, Voehler M *et al.* A sulfilimine bond identified in collagen IV. *Science* 2009; 325: 1230–1234
23. Lemmens R, Maugeri A, Niessen HWM *et al.* Novel COL4A1 mutations cause cerebral small vessel disease by haploinsufficiency. *Hum Mol Genet* 2013; 22: 391–397
24. Plaisier E, Chen Z, Gekeler F *et al.* Novel COL4A1 mutations associated with HANAC syndrome: a role for the triple helical CB3[IV] domain. *Am J Med Genet A* 2010; 152A: 2550–2555
25. Fidler AL, Vanacore RM, Chetyrkin SV *et al.* A unique covalent bond in basement membrane is a primordial innovation for tissue evolution. *Proc Natl Acad Sci USA* 2014; 111: 331–336
26. Uhlen M, Fagerberg L, Hallström BM *et al.* Proteomics. Tissue-based map of the human proteome. *Science* 2015; 347: 1260419
27. Byron A, Randles MJ, Humphries JD *et al.* Glomerular cell cross-talk influences composition and assembly of extracellular matrix. *J Am Soc Nephrol* 2014; 25: 953–966
28. Storey H, Savige J, Sivakumar V *et al.* COL4A3/COL4A4 mutations and features in individuals with autosomal recessive Alport syndrome. *J Am Soc Nephrol* 2013; 24: 1945–1954

Received for publication: 15.12.2015; Accepted in revised form: 18.2.2016