

# Intestinal intussusception in an adult caused by helminthic parasitosis

Irene Pecorella,<sup>1</sup> Tom R. Okello,<sup>2</sup> Gaia Ciardi,<sup>1</sup> David M. Ogwang,<sup>2</sup> Cyprian Opira<sup>3</sup>

<sup>1</sup>Department of Radiological, Oncological and Anatomic Pathology Sciences, La Sapienza University, Rome, Italy;

<sup>2</sup>Department of Surgery and

<sup>3</sup>Department of Radiology, Gulu University Medical School, St. Mary's Hospital Lacor, Gulu, Uganda

## Abstract

Intestinal intussusception is an uncommon acute condition in adults and is most commonly caused by an intestinal tumor mass. Helminthic parasitosis is a widespread infection in Africa, and the load of worms is often high in individuals living in areas with inadequate sanitation. We report a case of intestinal obstruction caused by *Ascaris lumbricoides* infection, which was complicated by ileo-caecal intussusception and required surgical treatment in a 40-year-old Ugandan woman. This case reinforces the importance of anthelmintic prophylaxis in African rural areas.

## Introduction

Intestinal intussusception is a serious disorder characterized by *internal prolapse* of the proximal bowel with its mesenteric fold within the lumen of the adjacent distal bowel. This *telescoping* obstructs the free passage of intestinal contents and, more severely, cuts off the mesenteric blood supply of the intussuscepted segment, leading to bowel infarction and perforation, and subsequent acute peritonitis. It is more likely to occur in the small intestine. While it is the most common cause of intestinal obstruction in children younger than 3, bowel intussusception in adults is considered a rare condition, accounting for only 5% of all cases.<sup>1,2</sup> Almost 90% instances of adult intussusception are secondary to organic lesions, with malignancy accounting for up to 30% of the ileal cases.<sup>2,3</sup> Other medical conditions include inflammatory bowel disease, postoperative adhesions, Meckel's or colonic diverticuli, and benign neoplastic lesions, which are usually discovered intraoperatively.<sup>2</sup> Of cases, 8-20% are idiopathic, without a lead point lesion.

This paper describes a distinct surgical complication of intestinal obstruction caused by *Ascaris lumbricoides* helminthic parasitosis, *i.e.* ileo-colic intussusception, defined as the prolapse of the terminal ileum within the ascending colon. The association of intussusception with helminthic parasitosis in humans is occasionally mentioned in descriptions of pediatric *Ascariasis* abdominal complications requiring surgery. However, we were unable to retrieve from the scientific literature any such published case occurring in adults.

## Case Report

A 40-year-old lady presented to St. Mary's Hospital Lacor, Gulu (north Uganda) with a history of worsening abdominal pain of 3-days duration. A tender mass was palpated in the left lower abdominal quadrant and exploratory laparotomy was carried on to confirm the suspicion of ileo-caecal intussusception associated with a tumor in the caecum. Intraoperatively, the abdominal contents revealed massive congestion of the terminal ileum, resulting from a non-reducible intussusception of approximately 5 cm. Resection of the infarcted portion of the small intestine cranial to the ileo-caecal junction and partly of the ileo-caecal valve region was performed. A primary anastomosis between healthy and viable tissue was then constructed.

Grossly, two fragments of intestine measuring 3.5×3×1.5 cm in aggregate were received. The intestinal wall was necrotic covered externally by fibrinous exudate. The cranial adjacent portion was markedly dilated and the associated mesenteric blood vessels were engorged. The intestinal lumen contained numerous thick worms.

Microscopically, the lumen of both the necrotic large bowel segment and the ileal cranial portion contained numerous worm eggs entrapped in a fibrinous exudate (Figures 1 and 2). The large prevalence of *A. lumbricoides* in Uganda favored the diagnosis of ascariasis.

## Discussion

*A. lumbricoides* (roundworm) infection may be the most prevalent human infection in the world,<sup>4</sup> and it occurs after ingestion of fully embryonated eggs present in contaminated soil. Ascariasis is a common problem in the tropics and subtropics, where the moist humid climates of alternating dry season and rainy season permit all-year embryonation of the ova. The prevalence of ascariasis in Uganda is unevenly distributed among the various regions of the country, with greatest preva-

Correspondence: Irene Pecorella, Department of Radiological, Oncological and Anatomic Pathology Sciences, University Sapienza, Viale Regina Elena, 324, 00161, Rome, Italy. Tel.: +39.06.49974561 - Fax: +39.06.4940896. E-mail: irene.pecorella@uniroma1.it

Key words: *Ascaris lumbricoides*; Roundworm; Intestinal nematode; ileo-colic intussusception.

Contributions: IP is a volunteer Pathologist at St. Mary's Hospital Lacor, Gulu (Uganda) and is responsible for the present histopathological diagnosis. TRO and DMO are responsible for the Surgical Department and CO is the Radiologist in charge at St. Mary's Hospital Lacor- Gulu (Uganda). GC is a Medical Student and has participated in the text writing.

Conflict of interest: the authors declare no potential conflict of interest.

Received for publication: 18 March 2016.

Revision received: 7 May 2016.

Accepted for publication: 11 May 2016.

This work is licensed under a Creative Commons Attribution NonCommercial 4.0 License (CC BY-NC 4.0).

©Copyright I. Pecorella et al., 2016

Licensee PAGEPress, Italy

*Gastroenterology Insights* 2016; 7:6469

doi:10.4081/gi.2016.6469

lence in southwestern areas,<sup>5</sup> where as many as 42.5% of the adults harbor the parasite.<sup>6</sup> Land surface temperature <38°C and heavy rainfall have been shown to be important determinants of ascariasis in Uganda.<sup>5</sup> *Ascaris* eggs are resistant to desiccation and, given favorable environmental conditions, they have been reported to survive for up to 15 years.<sup>7</sup> They also easily stick to food, flies and cockroaches.<sup>7</sup> Ingested eggs hatch in small intestine and larvae penetrate the intestinal mucosa and enter circulation. Upon reaching the lungs, they undergo further maturation in the pulmonary capillaries and progress to the upper airways in order to be re-swallowed. In the small bowel they become adult worms within 2 or 3 months, ranging in sizes up to 40 cm in length. Alternatively, the larvae may migrate through intestinal tissues and develop into adult worms in the peritoneal cavity, causing a granulomatous peritonitis. Light intestinal infestations are usually asymptomatic. In other cases, overt disease is characterized by abdominal pain, nausea and vomiting, diarrhea or bloody stools, weight loss, up to intestinal obstruction. Systemic involvement is also possible.

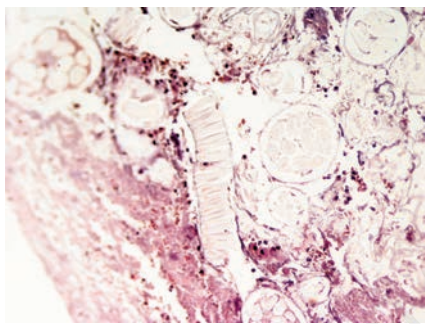
Intestinal intussusception occurs when a solid abnormality in the bowel wall is drawn

into the lumen by peristalsis. Due to the large size of roundworms, ascari-related intestinal obstruction is a complication of heavy infections affecting people living in areas where there are poor sanitation and hygiene practices. As *Ascaris* do not multiply within their host, high worm loads are acquired over time by continual exposure to infectious eggs. Multiple worms can form a large bolus, resulting in mechanical obstruction of the bowel lumen. These aggregate roundworm masses may then cause volvulus, or intussusception in the ilio-caecal region in children,<sup>8,9</sup> whereas in adults these are rare complications even in poor rural areas. According to Basavaraju and Hotez,<sup>10</sup> the prevalence of *Ascaris*-related intestinal obstruction in India is 9.2/100,000 persons and the average age of the infected person is 11 years. Surendran and Paulose<sup>11</sup> observed 22 acute intestinal obstructions with complications (including 10 volvuli) requiring surgery out of 142 children presenting with ascari-related abdominal symptoms. No instances of intussusception were noted. Only 7 intestinal *Ascaris* obstructions complicated by intussusception were noted in 311 Colombian children over a period of 25 years.<sup>12</sup> However, other parasites, such as *Schistosoma*

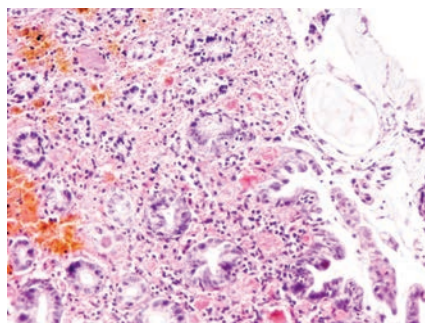
*species*<sup>13</sup> or *Anisakis*,<sup>14</sup> are occasionally involved in adult obstructions complicated by intussusception. Differently from the present case, in most published instances of *Anisakis* infestations complicated by intussusception, eosinophilic granulomata surrounding worm bodies were microscopically detected in the affected intestinal mucosa or submucosa.<sup>14</sup> Granulomata associated to the presence of *Schistosoma* eggs in the bowel wall were also described by Pinto and colleagues in their case report of intestinal intussusception in an adult.<sup>13</sup> The lack of granulomatous inflammatory reaction to a foreign body in our case can be explained by the fact that *A. lumbricoides* was not embedded in the intestinal wall, as these worms inhabit the gut lumen without being attached to the wall, and maintain their position by muscular movement.

Acute complications of *A. lumbricoides* infections (mainly intestinal obstruction and biliary complications) may be fatal if not treated timely. It has been estimated that this condition could result in approximately 10,000 deaths/year, mostly affecting children below the age of 10 years.<sup>15</sup> Intestinal intussusception with infarction is an ominous complication, and it requires a high index of suspicion. Preoperative diagnosis could be missed or delayed because of nonspecific and often subacute symptoms.<sup>2</sup> Furthermore, high eosinophilia is a usual finding in larval *Ascaris*, but not in adult worm infection.

An ultrasound, X-ray or computed tomography (CT) scan may reveal intestinal obstruction caused by intussusception. CT is the most sensitive diagnostic modality and can distinguish between intussusceptions with and without a lead point. Unfortunately, CT was not available in this private hospital and our patient underwent surgery, as this is the definitive treatment of adult intussusceptions. Resection with end-to-end anastomosis of the affected bowel was deemed necessary, as there was intestinal gangrene.



**Figure 1. Transmural intestinal infarction with presence in the lumen of helminthic eggs embedded in a fibrinous exudate (Haematoxylin & eosin, 100×).**



**Figure 2. Adjacent partially necrotic cecal mucosa (Haematoxylin & eosin, 250×).**

## Conclusions

This case of *Ascaris*-related ileal intussusception in an adult illustrates important practical aspects of managing the common problem of helminthic infestation in Africa. Symptoms of bowel obstruction or intussusception are often nonspecific, and challenging to identify.

Earlier recognition of this condition would have permitted surgical relief of the intestinal obstruction. This case also reinforces the importance of antihelminthic prophylaxis in African rural areas,<sup>4</sup> particularly when considering that often co-infection with other parasites is present.<sup>16</sup>

## References

1. Azar T, Berger DL. Adult intussusception. *Ann Surg* 1997;226:134-8.
2. Marinis A, Yiallourou A, Samanides L, et al. Intussusception of the bowel in adults: a review. *World J Gastroenterol* 2009;28;15:407-11.
3. Begos DG, Sandor A, Modlin IM. The diagnosis and management of adult intussusception. *Am J Surg* 1997;173:88-94.
4. Hotez PJ. Pediatric geohelminth infections: trichuriasis, ascariasis, and hookworm. *Semin Pediatr Infect Dis* 2000;11:236-44.
5. Brooker S, Kabatereine NB, Tukahebwa EM, Kazibwe F. Spatial analysis of the distribution of intestinal nematode infections in Uganda. *Epidemiol Infect* 2004;132:1065-71.
6. Betson M, Nejsum P, Llewellyn-Hughes J, et al. Genetic diversity of *Ascaris* in southwestern Uganda. *Trans R Soc Trop Med Hyg* 2012;106:75-83.
7. Scott ME. *Ascaris lumbricoides*: a review of its epidemiology and relationship to other infections. *Ann Nestlé [Engl]* 2008;66:7-22.
8. Wiersma R, Hadley GP. Small bowel volvulus complicating intestinal ascariasis in children. *Br J Surg* 1988;75:86-7.
9. Vilamizar E, Mendez M, Bonilla E, et al. *Ascaris lumbricoides* infestation as a cause of intestinal obstruction in children: experience with 87 cases. *J Pediatr Surg* 1996;31:201-5.
10. Basavaraju SV, Hotez PJ. Acute GI and surgical complications of *Ascaris lumbricoides* infection. Available from: <http://www.medscape.com/viewarticle/451597>
11. Surendran N, Paulose MO. Intestinal complications of round worms in children. *J Pediatr Surg* 1988;23:931-5.
12. Ochoa B. Surgical complications of ascariasis. *World J Surg* 1991;15:222-7.
13. Pinto JP, Cordeiro A, Ferreira AM, et al. Egg parasite: case of intussusception of the small intestine. *World J Gastroenterol* 2014;20:13191-4.
14. Miura T, Iwaya A, Shimizu T, et al. Adult intussusception caused by anisakiasis. *World J Gastroenterol* 2010;16:1804-7.
15. de Silva NR, Chan M-S, Bundy DAP. Morbidity and mortality due to ascariasis: re-estimation and sensitivity analysis of global numbers at risk. *Trop Med Int Health* 1998;2:517-28.
16. Kabatereine NB, Tukahebwa EM, Kazibwe F, et al. Soil-transmitted helminthiasis in Uganda: epidemiology and cost of control. *Trop Med Int Health* 2005;10:1187-9.