

Technical Note

Anterior Cruciate Ligament Reconstruction With Suture Tape Augmentation



Matt Daggett, D.O., M.B.A., Andrea Redler, M.D., and Kevin Witte, D.O., M.B.A.

Abstract: The advent of suture tape augmentation has led to increased use in knee, elbow, and ankle ligament repairs and reconstructions. Recent biomechanical analysis of the use of suture tape augmentation have shown superior strength characteristics compared with repair or reconstruction alone. Despite its increased use in extra-articular ligament procedures, its use as an augment to anterior cruciate ligament reconstruction has not been widely described. This article details a simple technique to incorporate the use of suture tape augmentation during concurrent anterior cruciate ligament reconstruction using hamstring autograft.

Anterior cruciate ligament (ACL) injury is among the most common orthopaedic injuries.¹ Despite the presence of many different techniques and technological advances in ACL reconstruction, a significant number of patients still suffer reruptures of the ACL graft as well as decreased ability to return to sport at varying speeds.²

The use of synthetic grafts for ACL reconstruction or repair has historically been met with skepticism and mixed results.³⁻⁷ Most notably, synthetic grafts resulted in effusion, pain, and oftentimes explantation of the device.³ Recently, authors have reported increased biomechanical strength of ligament repair with the use of suture tape augmentation.³⁻⁵ The use of a suture tape augmentation has been published in the repair/reconstruction of medial knee injuries,^{6,8} ulnar collateral ligament,⁹ and ACL repair or reconstruction with allograft.^{10,11} This article presents a technique that enhances a previously published technique for ACL reconstruction¹² with the addition of suture tape

augmentation (Internal Brace; Arthrex, Inc, Naples, FL). The ACL remnant is preserved and reconstruction is performed with a hamstring autograft. The suture tape augmentation is incorporated into the hamstring autograft construct and is independently fixated alongside the ACL graft.

Surgical Technique

Patient Setup

The patient is placed supine on an operative table in the standard arthroscopy position with a lateral post just proximal to the knee for access into the medial compartment and prevention of hip external rotation. A foot bump is also placed to keep the knee flexion at 90° (Video 1). In this way, the knee can be moved freely through the full range of motion (ROM).

Incisions

Standard anterolateral and anteromedial arthroscopic incisions are made on the anterior knee. A diagnostic arthroscopy is performed, and any concurrent intra-articular pathology addressed. The femoral origin is identified and prepared while the ACL remnant is preserved using the previously published ACL reconstruction technique.¹²

Graft Harvest/Preparation

The semitendinosus is harvested using an open-ended tendon stripper (Pigtail Hamstring Tendon Stripper; Arthrex, Naples, FL). The attachment site is maintained. The gracilis is then whip-stitched using a fiber loop suture (Arthrex). The semitendinosus (ST) is then measured from its insertion and marked using a skin marker at 4.5 cm and 11 cm for a female and 5.5 cm

From Kansas City University of Medicine and Biosciences (M.D., K.W.), Kansas City, Missouri, U.S.A.; and Sapienza University (A.R.), Rome, Italy.

The authors report that they have no conflicts of interest in the authorship and publication of this article. Full ICMJE author disclosure forms are available for this article online, as [supplementary material](#).

Received September 5, 2017; accepted October 24, 2017.

Address correspondence to Matt Daggett, D.O., M.B.A., 2000 SE Blue Parkway Suite 230, Lee's Summit, MO 64063, U.S.A. E-mail: matthewdaggett@gmail.com

© 2017 by the Arthroscopy Association of North America. Published by Elsevier. This is an open access article under the CC BY-NC-ND license (<http://creativecommons.org/licenses/by-nc-nd/4.0/>).

2212-6287/171100

<https://doi.org/10.1016/j.eats.2017.10.010>

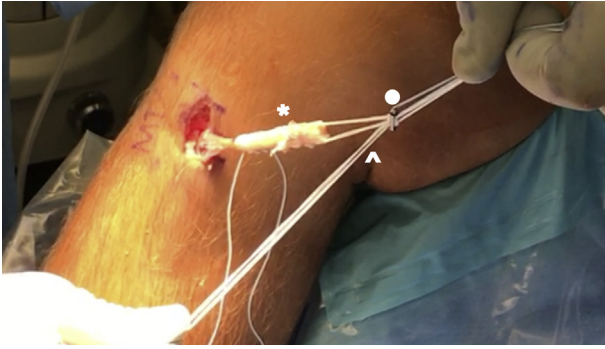


Fig 1. Once the hamstring graft is prepared as shown in this right knee, a no. 2 FiberWire is sutured through the base of the semitendinosus (asterisk) and the needle removed to act as a tension suture for graft fixation and passage. A LabralTape (Arthrex) (arrowhead) is then shuttled through each hole of the button of the Tigtrope (Arthrex) fixation device (circle).

and 12 cm for a male. A Tigtrope device (Arthrex) is placed on the ST at the distal mark, and graft folded onto itself and tagged with No. 2-0 FiberWire (Arthrex) sutures at the proximal mark. The graft is then tripled over itself and tubularized with No. 2-0 FiberWire. A No. 2 Fiberwire is then sutured through the base of the ST and needle removed to act as a tension suture for graft fixation and passage. A LabralTape (Arthrex) is then shuttled through each hole of the button of the Tigtrope (Arthrex) fixation device (Fig 1). Shuttling of the LabralTape through the button can be assisted by a nitinol suture passer. The graft is then sized, and returned inside the incision site while tunnel preparation occurs.

Drilling of the Tibial ACL Tunnel

Drilling of the tibial ACL tunnel is performed in an ACL remnant-sparing manner.¹² The tibial guide is placed at 60° at the ACL insertion (Fig 2) and guidewire taken from the external cortex into the ACL remnant at

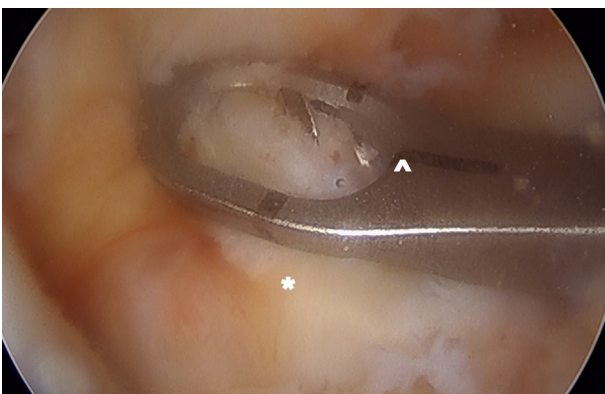


Fig 2. The tibial guide is placed at 60° (arrowhead) at the anterior cruciate ligament insertion (asterisk) during anterior cruciate ligament reconstruction in a right knee.

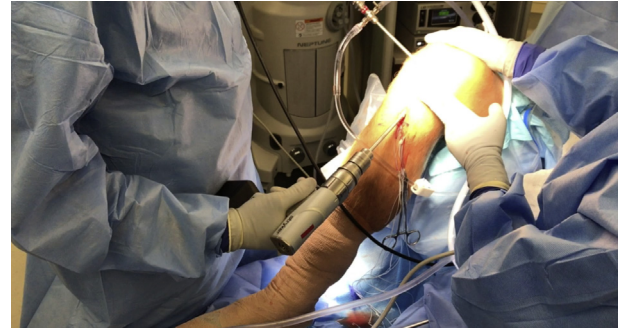


Fig 3. The guidewire and subsequent drills are taken from the external cortex into the anterior cruciate ligament remnant at low rpm to reduce iatrogenic damage to the remnant during anterior cruciate ligament reconstruction of the right knee in the supine position.

low rpm to reduce iatrogenic damage to the remnant (Fig 3). Sequential reaming is performed using a size 6 reamer and then increasing to the previously measured ACL graft size.

Drilling of the Femoral ACL/Anterolateral Ligament Tunnel

Using the FlipCutter guide (Arthrex), the femoral tunnel is drilled through an accessory lateral incision using an outside-in technique. After anatomic placement of the retrograde drill at the ACL insertion within the intercondylar notch (Fig 4), the tunnel is prepared to a depth of 20 mm (Fig 5).

Graft Passage

A TigerStick (Arthrex) is then placed into the femoral tunnel and taken transtibially out the tibial tunnel. The suture is then used to shuttle the ACL graft transtibially into and then out of the femoral tunnel. The cortical button is visualized arthroscopically under direct visualization, and as the button is shuttled through the tunnel, it is then deployed on the lateral cortex (Fig 6). Once secured, the graft is then advanced into the

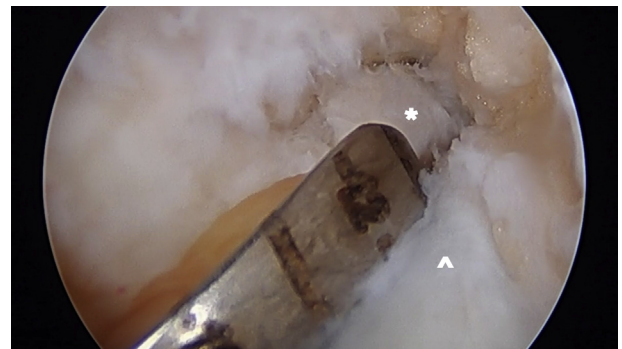


Fig 4. Anatomic placement of the retrograde drill (asterisk) at the anterior cruciate ligament insertion within the intercondylar notch with the outside-in drill guide (arrowhead) is placed during anterior cruciate ligament reconstruction of a right knee.

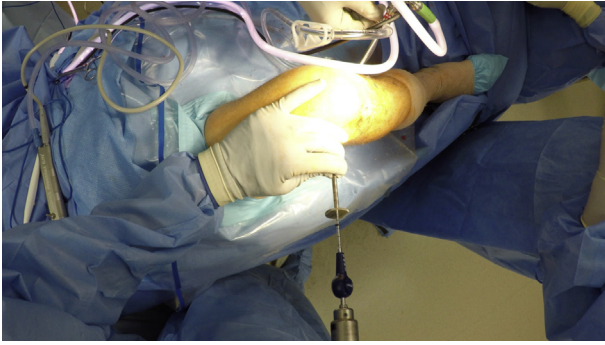


Fig 5. The femoral tunnel is prepared to a depth of 20 mm using a FlipCutter (Arthrex) device on a right knee in the supine position.

femoral tunnel using the suspensory sutures. Of note, the LabralTape suture free ends are maintained outside the tibial tunnel during graft passage. After complete advancement, the knee is cycled through a full range of motion. The suspensory sutures are then tied onto the top of the button.

Fixation of ACL Graft

A SwiveLock screw (Arthrex) measuring the same diameter as the graft is then used as an interference screw to secure the graft in the tibia. A nitinol wire is passed through the SwiveLock to shuttle the LabralTape sutures through the cannula of the SwiveLock (Fig 7). The LabralTape sutures serve as a guide then for tibial fixation. With the knee at 30° of flexion and a posterior force placed on the tibia, the SwiveLock is advanced into the tunnel and tightened while tension is placed also on both the LabralTape and the No. 2 FiberWire tension sutures within the base of the ACL graft. Once secured, the delivery screwdriver is removed.

Fixation of the Suture Tape

Once the ACL graft is fixated, a SwiveLock drill (Arthrex) is used to make a hole near the ST insertion site. The hole is then tapped and both the LabralTape

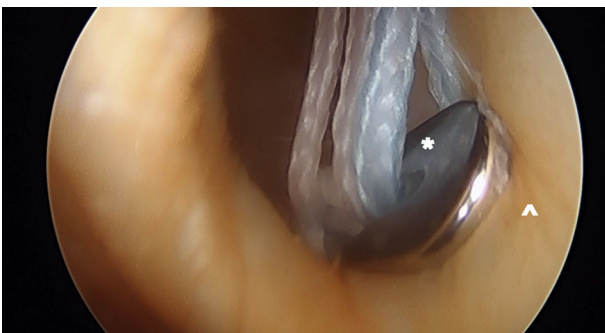


Fig 6. The cortical button (asterisk) is visualized arthroscopically as the button is shuttled through the tunnel and then deployed on the lateral cortex (arrowhead) during anterior cruciate ligament reconstruction in a right knee.

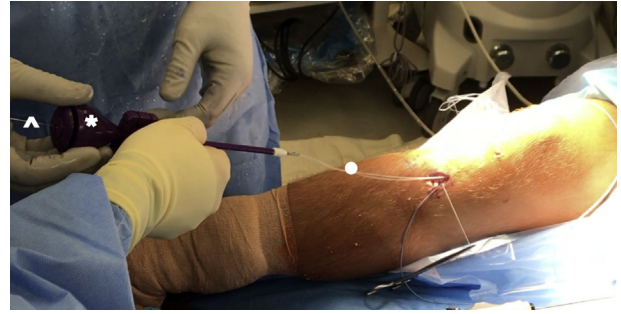


Fig 7. A nitinol wire (arrowhead) is passed through the SwiveLock (Arthrex) (asterisk) to shuttle the LabralTape (Arthrex) sutures (circle) through the cannula of the SwiveLock (Arthrex) to secure the tibial side of the hamstring autograft in a right knee anterior cruciate ligament reconstruction using suture tape augmentation.

and No. 2 FiberWire used as a tension suture is passed through a 4.75-mm SwiveLock. To complete the suture tape augmentation (Internal Brace, Arthrex), the SwiveLock is then secured into the tibia in full extension, neutral rotation to prevent any overextension of the knee (Fig 8). Excess suture is then removed.

Postoperative Course

Routine ACL rehabilitation program is initiated immediately after surgery, entailing full weight bearing after the procedure and progressive range of motion exercises. Early rehabilitation is focused on obtaining full extension and quadriceps activity. A gradual return to sports activities is allowed as rehabilitation progresses.

Discussion

The present technique marries a previously published technique with the potential advantages of suture tape augmentation to increase the biomechanical strength of

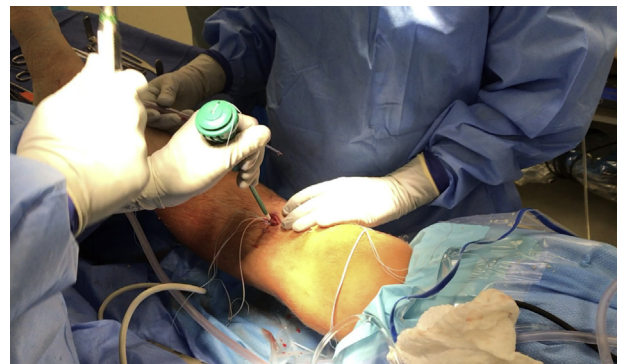

Fig 8. The SwiveLock (Arthrex) is secured into the tibia in full extension, neutral rotation to prevent any overextension of the knee in a right knee undergoing anterior cruciate ligament reconstruction with hamstring autograft using a suture tape augmentation.

Table 1. Pearls and Pitfalls of the Suture Tape Augmentation Technique

Stage	Pearls	Pitfalls
Loading LabralTape through TightRope	Use a nitinol guide to thread the LabralTape through each end of the TightRope button	Ensure that the LabralTape has not inadvertently incorporated one of the suspension sutures
Graft passage	Maintain gentle tension on LabralTape sutures to prevent bundling within the tunnel or ACL remnant	Bundling of the LabralTape may lead to difficult graft passage
Anterior cruciate ligament graft interference screw fixation in the tibia	Maintain and frequently check tension on LabralTape during interference screw fixation of the tibia	Incomplete tensioning of LabralTape during fixation may prevent complete tightening of the interference screw into the tibia
Fixation of LabralTape into the tibia with SwiveLock	Perform in full extension and without tension on the LabralTape	Overtensioning of LabralTape and knee may occur if the LabralTape is tensioned during implantation of SwiveLock

the reconstruction at the time of surgery and potentially reinforcing the graft thereafter.

Suture tape augmentation in ligament repair and reconstruction has gained in popularity as a result of the potential biomechanical superiority seen in some studies. Dugas et al.⁹ found that a repair of the ulnar collateral ligament (UCL) augmented with suture tape demonstrated a failure strength equal to UCL reconstruction with a graft in a cadaveric model. Gilmer et al. found similar findings in medial knee injuries. They identified that suture tape augmentation was also equal to allograft reconstruction in strength and significantly superior to repair alone.⁸

Although there are promising early biomechanical results on the use of suture tape augmentation, the clinical data on its use is sparse. Yoo et al.¹³ investigated the use of suture tape augmentation in modified Brostrom repairs. With suture tape augmentation, patients were able to return to sport and activity more quickly than the tradition Brostrom repair group alone. Smith et al.¹¹ have previously demonstrated a technique for ACL reconstruction with suture tape augmentation using allograft tissue. Suture tape augmentation has also been described in use with concurrent ACL repair in pediatric patients, with promising early results.¹⁰

ACL reconstruction using modern techniques still results in high revision rates and inconsistent return to play, especially in a young population.² In a high-risk population, rerupture can be seen in 16% to 18% of patients in short-term follow-up.¹⁴ Patients undergoing ACL reconstruction also have a high rate of reoperation, reaching nearly 27%.¹⁵ Given the high rerupture rates after surgery in a high-risk population, a recent review suggested that waiting 2 years after ACL reconstruction to return to play would significantly reduce the incidence of reinjury as graft incorporation, neuromuscular control, and functional movement are closer to baseline after 6 to 12 months, which is the current typical timeline for return to play.¹⁶

The addition of a suture tape augmentation to a previously published surgical technique would

theoretically improve the biomechanical strength of the ACL reconstruction at time zero while reinforcing the graft until mature incorporation. The authors also believe the load to failure of this construct is significantly higher in this construct compared to ACL reconstruction alone, and are currently conducting research to investigate this further.

Although the addition of a suture tape augmentation may expose the knee to new, previously unknown complications, its use has been studied in canines and prevented early failure, complete graft to bone healing, and functional graft remodeling.¹⁷ The use of suture tape augmentation also has the theoretical potential to overconstrain the knee, and to prevent this, we fixate the LabralTape in full extension and without excessive tension on the LabralTape during fixation with the SwiveLock (Table 1).

We believe the use of a suture tape augmentation during ACL reconstruction can reinforce and protect the ACL graft during early incorporation and can potentially strengthen the construct to reduce the chance of reinjury in high-risk athletes.

References

1. Frank RM, Verma NN. Graft selection in revision ACL reconstruction. In: Bach Jr BR, Provencher MT, eds. *ACL surgery: How to get it right the first time and what to do if it fails*. Thorofare, NJ: SLACK, 2010;217-229.
2. Ardern CL, Webster KE, Taylor NF, Feller JA. Return to sport following anterior cruciate ligament reconstruction surgery: a systematic review and meta-analysis of the state of play. *Br J Sports Med* 2011;45:596-606.
3. Dahlstedt L, Dalen N, Jonsson U. Goretex prosthetic ligament vs. Kennedy ligament augmentation device in anterior cruciate ligament reconstruction. A prospective randomized 3-year follow-up of 41 cases. *Acta Orthop Scand* 1990;61:217-224.
4. Batty LM, Norsworthy CJ, Lash NJ, Wasiak J, Richmond AK, Feller JA. Synthetic devices for reconstructive surgery of the cruciate ligaments: A systematic review. *Arthroscopy* 2015;31:957-968.

5. Lubowitz JH. Editorial commentary: Synthetic ACL grafts are more important than clinical nonbelievers may realize. *Arthroscopy* 2015;31:969-970.
6. Lubowitz JH, MacKay G, Gilmer B. Knee medial collateral ligament and posteromedial corner anatomic repair with internal bracing. *Arthrosc Tech* 2014;3:e505-e508.
7. Waterman BR, Johnson DH. Synthetic grafts—Where is the common sense? *Arthroscopy* 2015;31:1849-1850.
8. Gilmer BB, Crall T, DeLong J, Kubo T, Mackay G, Jani SS. Biomechanical analysis of internal bracing for treatment of medial knee injuries. *Orthopedics* 2016;39:e532-e537.
9. Dugas JR, Walters BL, Beason DP, Fleisig GS, Chronister JE. Biomechanical comparison of ulnar collateral ligament repair with internal bracing versus modified Jobe reconstruction. *Am J Sports Med* 2016;44:735-741.
10. Smith JO, Yasen SK, Palmer HC, Lord BR, Britton EM, Wilson AJ. Paediatric ACL repair reinforced with temporary internal bracing. *Knee Surg Sports Traumatol Arthrosc* 2016;24:1845-1851.
11. Smith PA, Bley JA. Allograft anterior cruciate ligament reconstruction utilizing internal brace augmentation. *Arthrosc Tech* 2016;5:e1143-e1147.
12. Sonnery-Cottet B, Freychet B, Murphy CG, Pupim BH, Thaunat M. Anterior cruciate ligament reconstruction and preservation: The Single-Anteromedial Bundle Biological Augmentation (SAMBBA) Technique. *Arthrosc Tech* 2014;3:e689-e693.
13. Yoo JS, Yang EA. Clinical results of an arthroscopic modified Brostrom operation with and without an internal brace. *J Orthop Traumatol* 2016;17:353-360.
14. Webster KE, Feller JA. Exploring the high reinjury rate in younger patients undergoing anterior cruciate ligament reconstruction. *Am J Sports Med* 2016;44:2827-2832.
15. Kartus J, Magnusson L, Stener S, Brandsson S, Eriksson BI, Karlsson J. Complications following arthroscopic anterior cruciate ligament reconstruction: A 2–5-year follow-up of 604 patients with special emphasis on anterior knee pain. *Knee Surg Sports Traumatol Arthrosc* 1999;7:2-8.
16. Nagelli CV, Hewett TE. Should return to sport be delayed until 2 years after anterior cruciate ligament reconstruction? Biological and functional considerations. *Sports Med* 2017;47:221-232.
17. Cook JL, Smith P, Stannard JP, et al. A canine arthroscopic anterior cruciate ligament reconstruction model for study of synthetic augmentation of tendon allografts. *J Knee Surg* 2017;30:704-711.