

Sectioning of the Inferior Dental Nerve in Rats

D. H. RETIEF and C. J. DREYER

Joint Dental Research Unit, Council for Scientific and Industrial Research, and University of the Witwatersrand, Johannesburg, Republic of South Africa

Often in dental research, a technic for sectioning the inferior dental nerve is required. For example, a technic is required in research concerning the effects of neural damage on the repair of bone in rat mandibles. Sectioning the inferior alveolar nerve before it enters its canal by an extraoral or an intraoral approach has proved unsatisfactory. The other alternative has been to section the nerve somewhere along its course within the inferior alveolar canal (J. M. STEWART, *J Dent Res* 44: 830, 1965). Another relatively simple technic which results in minimal trauma and vascular damage is presented in this paper.

The operation was performed on 30 rats under ether anesthesia. The extraoral horizontal incision, (Fig 1, *CD*), was made halfway between an imaginary line, (*AB*), drawn from the outer canthus of the eye to the base of the ear, and a line, (*EF*), which was the elongation of the lipline. The length of the incision, (*CD*), was approximately equal to *AB*. The exposed masseter muscle was incised to the bone by means of a vertical incision, (*GH*), situated midway along *CD*. The attachment of the masseter muscle was reflected to expose the underlying lateral surface of the mandible. A prominence overlying the incisor tooth germ and a bony ridge extending from the prominence to the condyle were clearly seen (Fig 2). The inferior dental

Additional information available on request to authors.
Received for publication January 17, 1969.

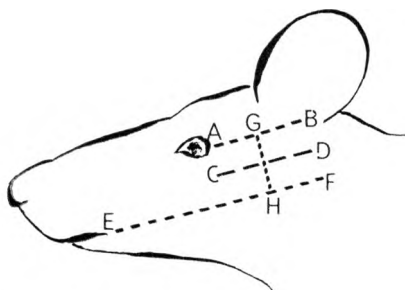


FIG 1.—Diagram of incisions.

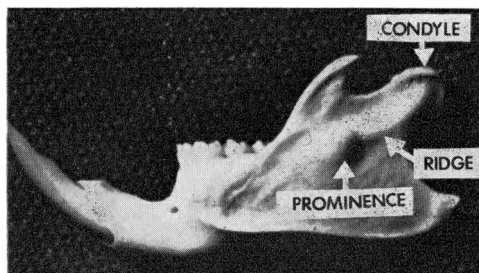


FIG 2.—Lateral surface of mandible.

nerve was exposed by removing the cortex of the ridge just distal to the prominence by means of a small dental round bur. After exposure, the clearly visible nerve was readily elevated from the bony canal by means of a curved probe (Fig 3). The exposed inferior alveolar nerve was sectioned and a portion of it was removed. The internal incision was closed by approximating the cut margins of the muscle with a single suture. Two or three sutures were sufficient to close the external incision.

In contrast with other methods, no animals died during the operation and the recovery of all the rats was uneventful.

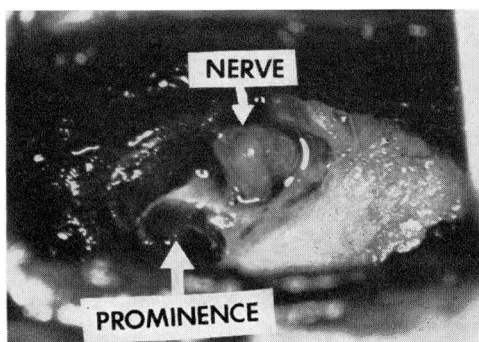


FIG 3.—Exposed nerve at operation.