

## rat secondary palate

*P. Cleaton-Jones\**

### ABSTRACT

The surfaces of the developing secondary palatal shelves and palate, in Wistar strain albino rats, were examined using scanning electron microscopy. Beginning on the 16th day after insemination there was a progressive degeneration of the cell surfaces on the medial aspect of the shelves. This took the form of a loss of surface microvilli and intercellular boundaries accompanied by the appearance of clefts between the cells. Fusion of the palate was complete by the 18th day and two epithelial zones could be recognized in the soft palate. The cell surface degeneration is possibly an essential change prior to shelf fusion.

### INTRODUCTION

In the formation of the secondary palate, fusion of the epithelium covering the two palatal shelves is followed by the establishment of continuity of mesenchyme through the epithelial seam.

Fusion of the two palatal shelves occurs once the epithelium covering their surfaces are in contact but it does seem that a potential for this fusion is already present some time before palatal shelf contact. It has been shown in *in vitro* culture studies, for example, that the frequency of fusion of the palatal shelves increased with increasing age of the donor embryo (Moriarty *et al.* 1963; Konegni *et al.* 1965; Pourtois 1966; Nanda 1969), a phenomenon attributed by Pourtois (1966) to an epithelial differentiation.

Angelici and Pourtois (1968) and Shapiro and Swency (1969) have demonstrated a number of enzyme differences in the epithelial cells in the region of future fusion, while Hayward (1969) and Smiley (1970) have reported degeneration and desquamation. All these observations tend to support the concept that epithelial cell death may begin prior to shelf contact (Mato *et al.* 1967; Hudson & Shapiro 1973).

The present study was undertaken to see whether there were any surface changes on the palatal shelves in rats prior to fusion and complements a similar study begun at about the same time in A/Jax mice (Waterman *et al.* 1973).

### MATERIALS AND METHODS

Female Wistar albino rats were placed together with male rats of the same strain from 4.00 p.m. to the following 8.00 a.m. The vaginal plug was looked for and vaginal smears made. In cases of positive recordings it was assumed that copulation had taken place at midnight. The following day was termed day 0 and subsequent days as 1, 2, 3 etc.

---

\*Dental Research Unit of the South African Medical Research Council and the University of the Witwatersrand, Johannesburg 2001, South Africa.

Later the pregnant rats were anaesthetized with a droperidol-fentanyl mixture (Thalamonal, Janssens Pharmaceuticals, Belgium) and their foetuses removed on days 14.9 (days.hours), 15.9, 16.9, 16.16, 17.9, 18.9 and 19.9. The foetuses were immediately placed in 10 per cent neutral buffered formol saline and fixed for 48 hours. A total of 40 foetuses was studied, the numbers at each age being: 14.9 days — 5; 15.9 days — 5; 16.9 days — 6; 16.16 days — 7; 17.9 days — 7; 18.9 days — 5 and 19.9 days — 5. Each foetus was from a different mother. Following this the developing secondary palate was exposed by microdissection. The specimens were then dehydrated in ethanol followed by amyl acetate and the critical point technique using liquid carbon dioxide (Polaron Critical Point Apparatus E2000, Watford, U.K.). They were then placed with the developing secondary palate uppermost onto aluminium stubs and attached to these by means of a colloidal silver solution (M154 Colloidal Silver, Polaron Equipt. Ltd, Watford, U.K.). Finally the specimens were coated with a thin layer of gold palladium in an Edwards Coating Unit E12E4 (Edwards Ltd, Crawley, Kent, U.K.) and examined in a Cambridge S4 Stereoscan operated at 10 and 20 kV.

## RESULTS

The positions of the palatal shelves at the various ages corresponded with those described by Nanda (1969), Cox (1973) and Diewert (1973) and so the description of the results of this study are limited to the fine structure of the surface.

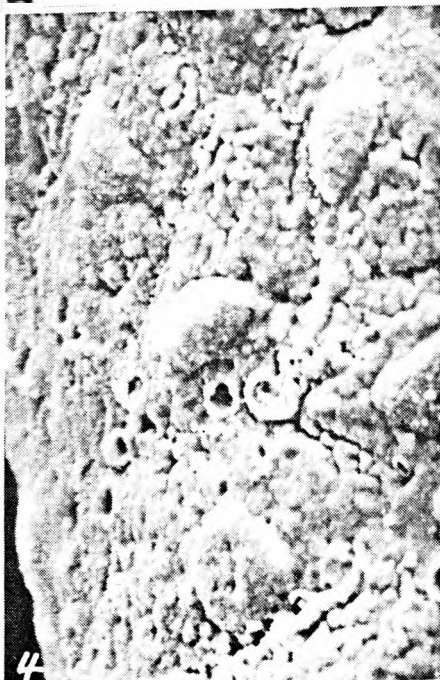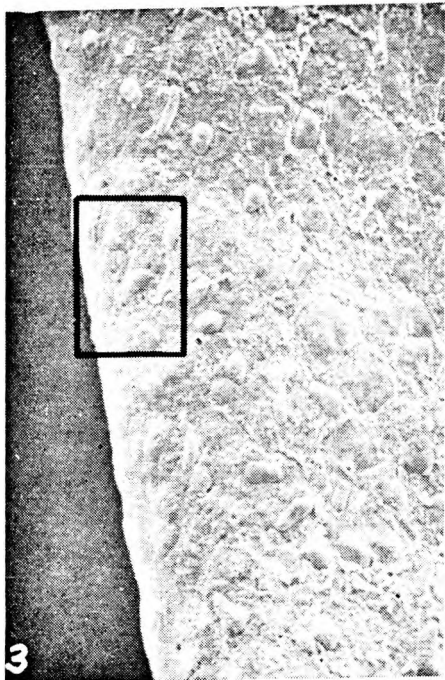

The appearances of the cells covering the surfaces of the palatal shelves on days 14.9 and 15.9 were similar. They consisted of polygonal cells separated by distinct raised intercellular boundaries (Figure 1) which were made up of numerous stubby microvilli. The surfaces of the cells themselves were also covered with short microvilli. This polygonal cell arrangement, the intercellular boundaries and the microvilli were seen all over the surface of the palatal shelves including the future medial surface (Figure 2). The cells always appeared bulbous with the greatest elevation in the centre of the cell, and the intercellular boundaries situated in the valleys between them.

The first change in this surface appearance was seen in foetuses aged 16.9 days. In these on the medial surface of the palatal shelves, the regular cell arrangement described above was lost. The cells were no longer bulbous but flatter, with only some areas raised above the surface (Figure 3). The intercellular boundaries had disappeared and clefts were appearing between the cells, while microvilli were seldom seen (Figure 4).

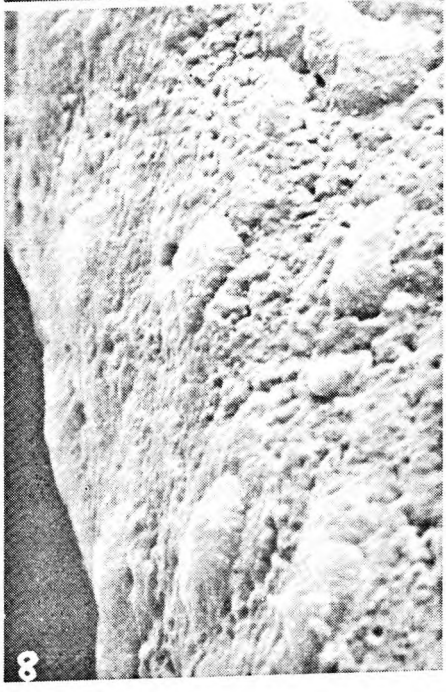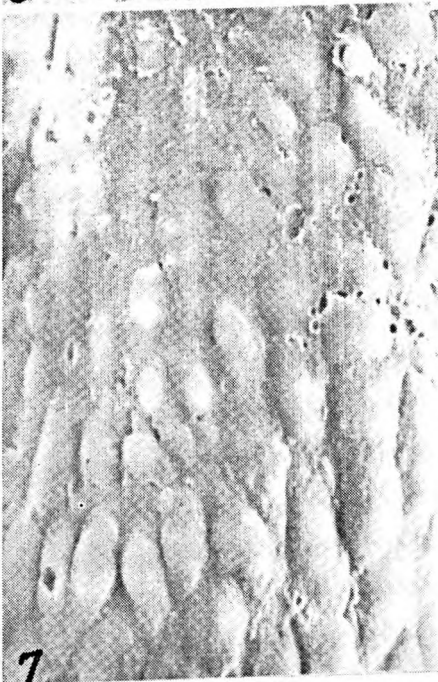
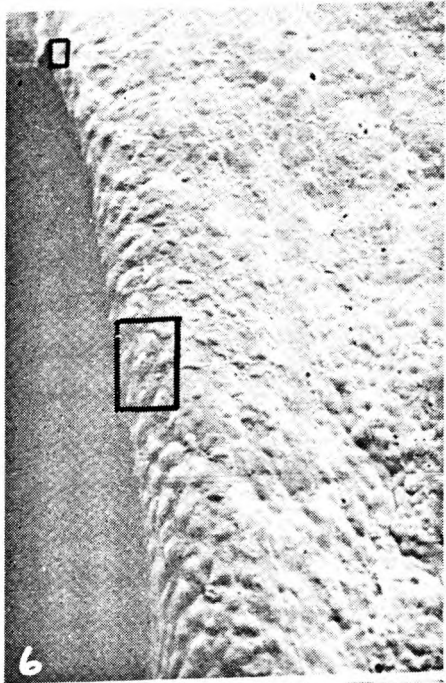
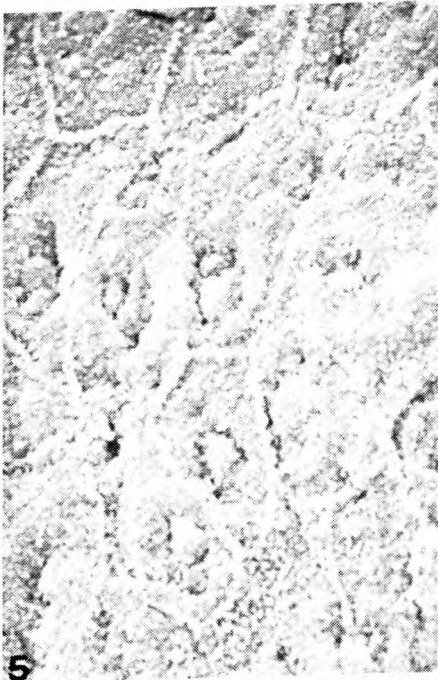In contrast, the oral epithelium covering the rest of the palatal shelves still showed their polygonal shape. Intercellular boundaries were prominent as were numerous microvilli on the cell surface (Figure 5). There was however an irregularity in the centre of the cells.

By the 16.16th day fusion of the palatal shelves had begun (Figure 6). The surface changes seen in the 16.9 day specimens were present and were most marked in the region just before fusion (Figure 7). Here the intercellular cracks or craters were particularly prominent. Further down the palatal shelf the changes were less evident (Figure 8) while the rest of the palatal shelf surface had the appearance seen in Figure 5.

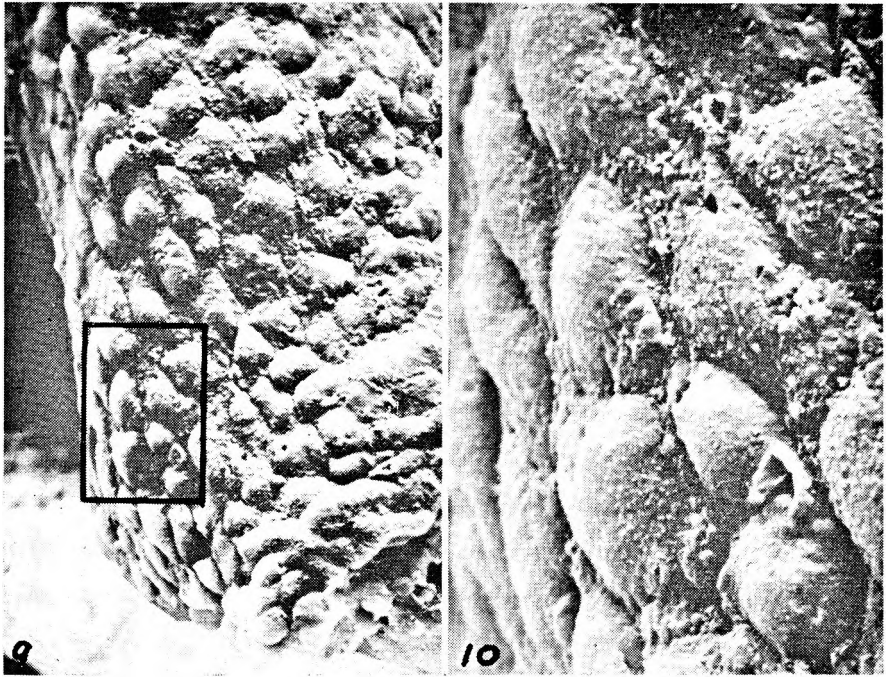
At the distal end of the palatal shelf, i.e., in the region of the future soft palate, the cells were still bulbous although intercellular boundaries were indistinct (Figure 9). Microvilli were still present on the cell surface (Figure 10).



*For captions see page 7.*



*For captions see page 7.*



*See captions below.*

**CAPTIONS TO FIGURES**

*Figure 1.* Surface of a palatal shelf in a 14.9 day fetus showing polygonal cells separated by intercellular boundaries containing many microvilli.  $\times 1\ 100$ .

*Figure 2.* Future medial surface of a palatal shelf in a 15.9 day fetus. The surface shows polygonal cells with distinct intercellular boundaries. Microvilli are present.  $\times 1\ 100$ .

*Figure 3.* Surface of the medial edge of a palatal shelf in a 16.9 day fetus prior to shelf contact.  $\times 480$ .

*Figure 4.* High magnification of the area outlined in Figure 3. The surface cells show a loss of their neat polygonal arrangement and intercellular boundaries. Clefts are present between the cells. The projections may be cell nuclei.  $\times 2\ 400$ .

*Figure 5.* Oral surface of a palatal shelf in a 16.9 day fetus showing the intercellular boundaries as well as microvilli on the cell surface.  $\times 1\ 800$ .

*Figure 6.* Medial surface of the unfused portion of a palatal shelf in a 16.16 day fetus.  $\times 200$ .

*Figure 7.* High magnification of upper area in Figure 6. Notice the lack of surface detail and intercellular cracks.  $\times 800$ .

*Figure 8.* High magnification of the lower area. Nuclei are prominent but few intercellular cracks are seen although intercellular boundaries are not evident.  $\times 1\ 000$ .

*Figure 9.* Medial surface of the distal end of a palatal shelf in a 16.16 day fetus.  $\times 700$ .

*Figure 10.* High magnification of area outlined in Figure 9. The cells are raised with numerous microvilli on the surface. Intercellular boundaries are not seen.  $\times 2\ 100$ .

Similar appearances as were seen in the 16.16 day specimens were present in those of 17.9 days in areas which had not yet fused.

By 18.9 days fusion was complete. The epithelium covering the area of fusion could not be distinguished from elsewhere and had the appearance shown in Figure 5. A similar appearance was noted in the 19.9 day specimens.

At no stage was any shedding of cells seen, either from the medial surface of the palatal shelves, or from elsewhere on the oral surface of the shelves. Similarly there was no obvious accumulation of any substance on the medial surface of the shelves.

Careful examination did not reveal an abrupt change between the altered cells on the medial surface, and the rest of the cells covering the oral surface of the palatal shelves. Rather, there was a gradual change over some 2-4 cells on the oral side of the medial surface of the shelves.

## DISCUSSION

In this study it was shown that changes occurred on the surface of cells on the medial aspect of the palatal shelves just prior to fusion. These were first seen in foetal rats aged 16.9 days. They occurred in the region of future fusion and were not seen in the cells covering the rest of the oral aspect of the palatal shelves during the period studied.

When the surface changes were seen they were present along the entire medially orientated shelf surface as well as along the future medial shelf surface when this faced vertically downwards. This was however variable in degree being most marked anteriorly and less marked posteriorly. As the changes were not seen in 15.9 day animals but were present in all the 16.9 day foetal rats they are of very rapid onset developing sometime between 15.9 days and 16.9 days, i.e., over a period of some 24 hours. These findings differ somewhat from those of Waterman *et al.* (1973) in the mouse. They found a gradual spread posteriorly of essentially similar changes which began in the region of the 2nd and 3rd palatal rugae.

Another feature that was different between the two studies was the accumulation of filamentous material over the degenerating cells. Although Waterman *et al.* (1973) found a good deal of this, it was not found in the present study. Perhaps this is specific to the mouse, an artefact due to amniotic debris or in the present study it may have been removed during processing. Certainly there was no evidence of the adhesive surface coat postulated by Farbman (1968, 1969) and Hayward (1969).

It is felt that the surface changes seen are unlikely to be due to mechanical damage as all the material received minimal handling. Waterman *et al.* (1973) also felt that mechanical trauma was not responsible for these.

Although there was a loss of distinct cell outlines no obvious desquamation was seen. At first glance this appears to be against the concept of desquamation of cells reported *in vivo* by Hayward (1969) and Sweney and Shapiro (1970), and *in vitro* by Smiley and Koch (1971). But it is possible that the cracks and craters seen between the cells represented the initial stage of desquamation.

## ACKNOWLEDGEMENTS

I am very grateful to Mrs D. Banks, Mrs H. Wilton-Cox and Miss E. Vieira for their expert technical assistance, as well as to all the staff of the electron microscope unit.

## REFERENCES

- Angelici, D. & Pourtois, M. (1968) The role of acid phosphatase in the fusion of the secondary palate. *Journal of Embryology and Experimental Morphology*, **20**, 15-23.
- Cox, N. H. (1973) *Morfogenese en Vascularisatie van het Secundaire Palatum van de Rat*. M.D. Thesis, pp. 21-39, University of Nijmegen, The Netherlands.
- Diewert, V. M. (1973) The course of the palatine arteries during secondary palate development in the rat. *Journal of Dental Research*, **52**, 1273-1280.
- Farbman, A. I. (1968) Electron microscope study of palate fusion in mouse embryos. *Developmental Biology*, **18**, 93-116.
- Farbman, A. I. (1969) The epithelium-connective tissue interface during closure of the secondary palate in rodent embryos. *Journal of Dental Research*, **48**, 617-624.
- Hayward, A. F. (1969) Ultrastructural changes in the epithelium during fusion of the palatal processes in rats. *Archives of Oral Biology*, **18**, 67-75.
- Hudson, C. D. & Shapiro, B. L. (1973) A radioautographic study of deoxyribonucleic acid synthesis in embryonic rat palatal shelf epithelium with reference to the concept of programmed cell death. *Archives of Oral Biology*, **18**, 77-84.
- Konegni, J. S., Chan, B. C., Moriarty, T. M., Weinstein, S. & Gibson, R. D. (1965) A comparison of standard organ culture and standard transplant techniques in the fusion of the palatal processes of rat embryos. *Cleft Palate Journal*, **2**, 219-228.
- Mato, M., Aikawa, E. & Katahira, M. (1967) Alteration of the fine structure of the epithelium on the lateral palatal shelf during the secondary palate formation. *Gunma Journal of Medical Sciences*, **16**, 79-99. Cited by Waterman *et al.*, 1973.
- Moriarty, T., Weinstein, S. & Gibson, R. D. (1963) The development in vitro and in vivo of fusion of the palatal processes of rat embryos. *Journal of Embryology and Experimental Morphology*, **11**, 605-619.
- Nanda, R. (1969) *The Normal Palate and Induced Cleft Palate in Rat Embryos*. M.D. Thesis, pp. 26-33, University of Nijmegen, The Netherlands.
- Pourtois, M. (1966) Onset of the acquired potentiality for fusion in the palatal shelves of rats. *Journal of Embryology and Experimental Morphology*, **16**, 171-182.
- Shapiro, B. L. & Swency, L. (1969) Electron microscopic and histochemical examination of oral epithelial-mesenchymal interaction (programmed cell death). *Journal of Dental Research*, **48**, 652-660.
- Smiley, G. R. (1970) Fine structure of mouse embryonic palatal epithelium prior to and after midline fusion. *Archives of Oral Biology*, **15**, 287-296.
- Smiley, G. R. & Koch, W. E. (1971) Fine structure of mouse secondary palate development in vitro. *Journal of Dental Research*, **50**, 1671-1677.
- Swency, L. R. & Shapiro, B. L. (1970) Histogenesis of swiss white mouse secondary palate from nine and one-half days to fifteen and one-half days *in utero*. I. Epithelial-mesenchymal relationships — light and electron microscopy. *Journal of Morphology*, **130**, 435-450.
- Waterman, R. E., Ross, L. M. & Meller, S. M. (1973) Alterations in the epithelial surface of A/Jax mouse palatal shelves prior to and during palatal fusion. A scanning electron microscope study. *Anatomical Record*, **176**, 361-375.