


AUTHORS:Edward J. Odes^{1,2}Patrick S. Randolph-Quinney^{1,2*} Maryna Steyn¹Zach Throckmorton^{2,3}Jacqueline S. Smilg^{2,4,5}Bernhard Zipfel^{2,6}Tanya N. Augustine¹Frikkie de Beer⁷Jakobus W. Hoffman⁷Ryan D. Franklin⁸Lee R. Berger^{2,6} **AFFILIATIONS:**¹School of Anatomical Sciences, University of the Witwatersrand, Johannesburg, South Africa²Evolutionary Studies Institute, School of Geosciences, University of the Witwatersrand, Johannesburg, South Africa³De Busk College of Osteopathic Medicine, Lincoln Memorial University, Harrogate, Tennessee, USA⁴School of Radiation Sciences, University of the Witwatersrand, Johannesburg, South Africa⁵Department of Radiology, Charlotte Maxeke Academic Hospital, Johannesburg, South Africa⁶DST/NRF South African Centre of Excellence in Palaeosciences, University of the Witwatersrand, Johannesburg, South Africa⁷Radiography/Tomography Section, South African Nuclear Energy Corporation (NECSA), Pelindaba, South Africa⁸Archaeological and Historical Conservancy, Davie, Florida, USA

*Current address: School of Forensic and Applied Sciences, University of Central Lancashire, Preston, Lancashire, United Kingdom

CORRESPONDENCE TO:

Patrick Randolph-Quinney

EMAIL:

prandolph-quinney@uclan.ac.uk

POSTAL ADDRESS:

School of Forensic and Applied Sciences, University of Central Lancashire, Preston, Lancashire, PR1 2HE, UK

DATES:**Received:** 11 Dec. 2015**Revised:** 16 Mar. 2016**Accepted:** 17 Mar. 2016**KEYWORDS:**

palaeopathology; oncology; malignant neoplasia; metatarsal; micro-computed tomography

HOW TO CITE:Odes EJ, Randolph-Quinney PS, Steyn M, Throckmorton Z, Smilg JS, Zipfel B, et al. Earliest hominin cancer: 1.7-million-year-old osteosarcoma from Swartkrans Cave, South Africa. *S Afr J Sci.* 2016;112(7/8), Art. #2015-0471, 5 pages. <http://dx.doi.org/10.17159/sajs.2016/20150471>

© 2016. The Author(s).

Published under a Creative Commons Attribution Licence.

Earliest hominin cancer: 1.7-million-year-old osteosarcoma from Swartkrans Cave, South Africa

The reported incidence of neoplasia in the extinct human lineage is rare, with only a few confirmed cases of Middle or Later Pleistocene dates reported. It has generally been assumed that pre-modern incidence of neoplastic disease of any kind is rare and limited to benign conditions, but new fossil evidence suggests otherwise. We here present the earliest identifiable case of malignant neoplastic disease from an early human ancestor dated to 1.8–1.6 million years old. The diagnosis has been made possible only by advances in 3D imaging methods as diagnostic aids. We present a case report based on re-analysis of a hominin metatarsal specimen (SK 7923) from the cave site of Swartkrans in the Cradle of Humankind, South Africa. The expression of malignant osteosarcoma in the Swartkrans specimen indicates that whilst the upsurge in malignancy incidence is correlated with modern lifestyles, there is no reason to suspect that primary bone tumours would have been any less frequent in ancient specimens. Such tumours are not related to lifestyle and often occur in younger individuals. As such, malignancy has a considerable antiquity in the fossil record, as evidenced by this specimen.

Introduction

The reported incidence of neoplastic disease in the extinct human lineage is rare. Only a few confirmed cases of Middle or Later Pleistocene dates (780 000 to 120 000 years old) have been reported.^{1,2} It is generally assumed that pre-modern incidence of neoplastic disease of any kind is rare and limited to benign conditions, but new fossil evidence suggests this is not so. We here present the earliest identifiable case of malignant neoplastic disease from an early human ancestor dated to 1.8–1.6 million years old (Ma). The diagnosis is possible only because of advances in 3D imaging methods as an aid in diagnosis.

A neoplasm ('new-growth' or tumour) is defined as a mass of localised tissue growth in which cellular proliferation is no longer subject to the effects of normal growth-regulating mechanisms.^{1,2} A tumour may be benign or malignant in nature; malignant tumours are often colloquially referred to as a cancer.³ Malignancy is the primary cause of death in industrialised countries and the second foremost cause of death in developing countries.^{4,5} Since 1999, malignancy has surpassed cardiac disease as the leading cause of death for humans younger than 85 years in the USA⁶, and is often perceived to be a disease of modernity^{7–9}. At present, true neoplastic diseases seem to be restricted to complex vertebrate animals. Only one observation of true malignancy has been described in one of the simpler living vertebrates, specifically hepatomas in the cartilaginous skeleton of the jawless hagfish.² This is a very important case for the comparative pathology of malignancy, because lampreys are among the simplest living vertebrates.

The fact that malignancy has great antiquity is demonstrated from the fossil record. The earliest definitive evidence for neoplastic disease comes from pre-Cenozoic contexts, with purported cases of neoplasm found in fossil fish from the Upper Devonian. The earliest unequivocal case dates from 300 Ma, with evidence of benign osteoma with focal hyperostosis affecting a partial skeleton of the fish *Phanerosteon mirabile* from the North American Lower Carboniferous.² Later cases include diagnoses of benign haemangioma and eosinophilic granuloma in Jurassic dinosaurs; benign osteoma in mosasaurs; and haemangioma, metastatic disease, desmoplastic fibroma, and osteoblastoma in Cretaceous hadrosaurs.^{10,11} Benign osteoid osteoma and osteoblastoma have been identified in European mammoths dating from 24 to 23 thousand years ago (ka).¹² Evidence for neoplastic disease is not unknown in the human fossil, archaeological and historical records,^{1,3,13} but is generally considered rare. Historically, the earliest fossil evidence for neoplastic disease in the human lineage was suggested to be from a mandible of archaic *Homo* from Kanam in Kenya. This lesion has variously been attributed to osteosarcoma, bone keloid, Burkitt's lymphoma, or traumatic osteomyelitis.^{2,14–17} The first substantive evidence for hominin neoplastic disease is derived from a juvenile skeleton of *Australopithecus sediba*, dated to 1.98 Ma, from the site of Malapa in South Africa. An invasive spinal lesion has been attributed by Randolph-Quinney and colleagues to benign osteoid osteoma, a non-malignant tumour.¹⁸ Later significant evidence for near-human neoplastic disease is suggested by Monge and colleagues¹⁹, who present a case of fibrous dysplasia from a Neanderthal rib dated to 120 000 ka from the site of Krapina.

Here we present the earliest fossil evidence for malignant neoplastic disease in the hominin record, with a detailed description and differential diagnosis of malignant osteosarcoma. Our report is based on re-analysis of a hominin metatarsal specimen (SK 7923) (*gen. et spec. indet.*) from the cave site of Swartkrans in the Cradle of Humankind, South Africa. SK 7923 is a metatarsal recovered from the Member 1 Hanging Remnant, which has yielded fossils of both *Homo ergaster* and *Paranthropus robustus*.²⁰ Several faunal estimates have indicated the age of the Hanging Remnant at between 1.5 Ma and 1.8 Ma.^{21–23} Recent electron spin resonance dating has estimated the age of the Hanging Remnant of Swartkrans at 1.6 Ma.²⁴ The oldest southern African specimens of early *Homo* and *Paranthropus* present around 2.1–1.9 Ma in Member 1, and are recorded until around 1.0–0.6 Ma in Member 3 of the Swartkrans cave.²⁵

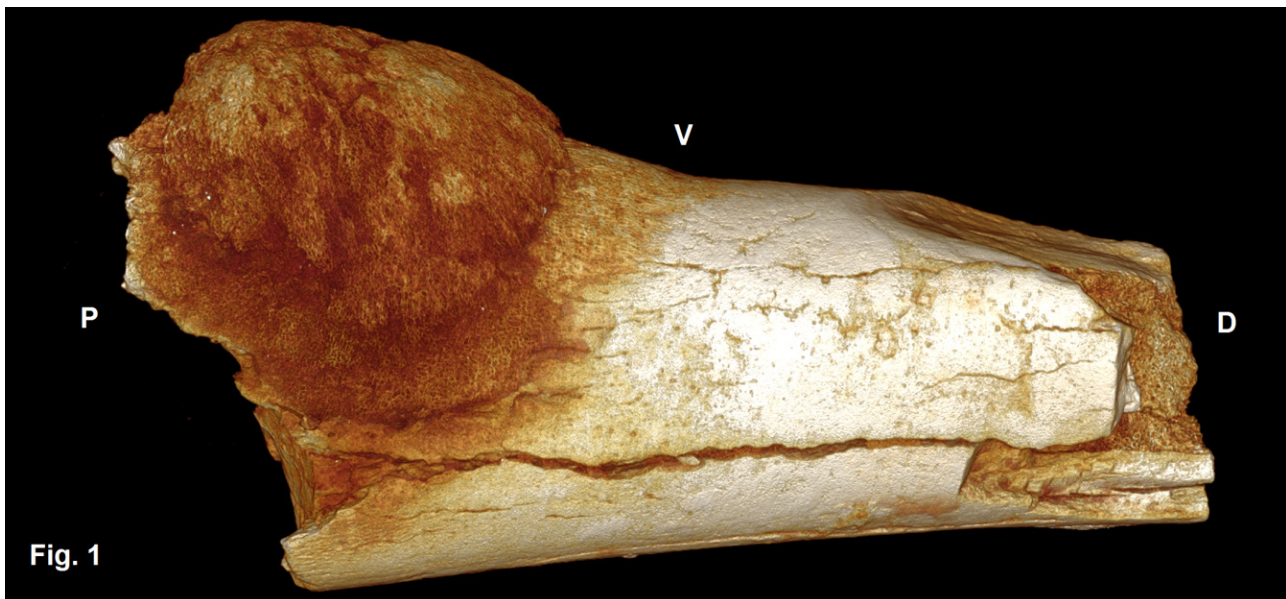


Figure 1: SK 7923, a hominin 5th metatarsal, exhibits a hemi-spherical bony mass located on the proximo-ventral aspect of the shaft, abutting the cortical bone surface. P – proximal, D – distal, V – ventral.

Swartkrans hominin site

Swartkrans was discovered in 1948. The site is situated approximately 40 km northwest of Johannesburg, on the bank of the Blaauwbank River in the province of Gauteng, South Africa. It is arguably one of the most important palaeocave sites in southern Africa, if not globally, and is best known for its rich heritage of *Paranthropus robustus* fossils, and purported evidence for early hominin use of controlled pyrotechnology. During much of their early research, Broom and his assistant Robinson excavated a considerable sample of hominin remains attributable to *Paranthropus robustus* and *Homo* from the site.^{26,27} Swartkrans was the first site where these two genera of hominins were considered to be contemporary.

After an approximately 12-year hiatus of non-activity, Brain's subsequent excavations at Swartkrans from the mid-1960s to the mid-1980s produced a significant addition to the faunal²⁰, fossil and archaeological collection. From the total number of specimens obtained at the Swartkrans site, 415 accessioned specimens are identified as hominin.²⁰ Brain's work demonstrated that the stratigraphy of the site was much more complex than originally posited. Brain subsequently demonstrated five members at Swartkrans.²² Member 1 consists of two distinct masses, the Hanging Remnant and Lower Bank²², each of them yielding *Homo ergaster* and *Paranthropus robustus*²⁸. *Homo* and *Paranthropus* have been discovered from Member 2.²⁸

SK 7923 case study

SK 7923 is a left 5th metatarsal, preserving the proximal diaphysis and much of the distal portion, but lacking the articular end. The specimen is hominin, but cannot be allocated to a specific taxon. Pathologically, SK 7923 presents a growth on the proximo-ventral aspect of the shaft. Here, an irregular hemi-spherical mass abuts the cortex (Figure 1), measuring 5.2 mm x 4.7 mm. The specimen was originally studied as part of an unpublished doctoral thesis, where the morphology led one of us (R.F.) to diagnose osteoid osteoma. However, recent internal imaging has led to a re-evaluation of the pathology.

The bone was examined using micro-focus X-ray computed tomography (μ XCT) at the South African Nuclear Centre for Radiography and Tomography (located at the South African Nuclear Energy Corporation, NECSA). The bone was scanned by F.d.B. and J.W.H. using a Nikon XTH225ST μ XCT system, at an energy potential of 100 kV and resolution of 17 microns. Reconstruction was performed by E.J.O. and P.R.Q. using Avizo Amira 5.4 to generate both 2D orthoslice and 3D surface rendered views. The cross-section shows that the hemispherical mass is not fully

fused to or integrated with the cortex, but adheres to the bone surface, displaying an irregular spongy woven bone texture with a cauliflower-like external appearance (Figure 2a). The cortical bone directly underlying the mass is covered with a thin layer of new woven bone, with a Codman triangle displayed at the margins. The texture is granular and exhibits ellipsoid lytic lesions in transverse view. There is localised sub-periosteal invasion by the mass into the cortex (Figure 2a). Surprisingly, μ XCT showed much of the medullary cavity to be infilled with bone, with clear internal remodelling and *de-novo* bone formation (Figure 2b). Inside the cortex are several irregular and large circular voids, caused by bony encapsulation of normal vascular channelling found within the endosteal surface of the medullary cavity. The remaining medullary space is obliterated by new bone growth.

A number of bone-forming conditions should be considered in the differential diagnosis: chondrosarcoma, Ewing's sarcoma, metastatic carcinoma, osteochondroma, osteoblastoma and osteosarcoma (see Supplementary Appendix for a more detailed breakdown).^{3,29-46} Osteosarcoma usually starts in the medulla and characteristically arises within the metaphysis of long bones, growing circumferentially through the cortex into soft tissue and raising the periosteum. This seems to have occurred in SK 7923, with a Codman triangle visible. Osteosarcoma (osteogenic sarcoma) prefers fast-growing regions and usually occurs around the knee. It presents in metatarsals in less than 1% of clinical cases. According to Vigorita⁴⁷, the periosteal reaction may have a 'sunburst' appearance, which is to some extent visible in Figure 2a. Given the internal and external morphology of this specimen, it seems most likely that this pathology is attributable to osteosarcoma, with a strong possibility of the parosteal variant of this condition. Diagnosis was supported by μ XCT imaging of a modern clinically diagnosed case of osteosarcoma of the distal femur. Comparison of Figures 2b and 2c shows clear similarities between the appearance of the fossil and modern medullary infills.

Osteosarcoma is a primary malignant tumour that typically exhibits cortical and medullary disruption and some degree of mineralisation. It also typically shows aggressive periosteal new bone reaction, which can include either lamination, Codman triangle, or spiculated sunburst reaction. The most common form is central osteogenic sarcoma, which could be osteoblastic or osteolytic in nature, or both. This typically occurs in the metaphyseal and diaphyseal area of the major long bones. Parosteal osteosarcoma is the most common type of juxtacortical or surface osteosarcoma. This often presents as a lobulated 'cauliflower' mass with central ossification adjacent to the bone, and may infiltrate the bone marrow. Bone destruction is rare, but when present is regional.

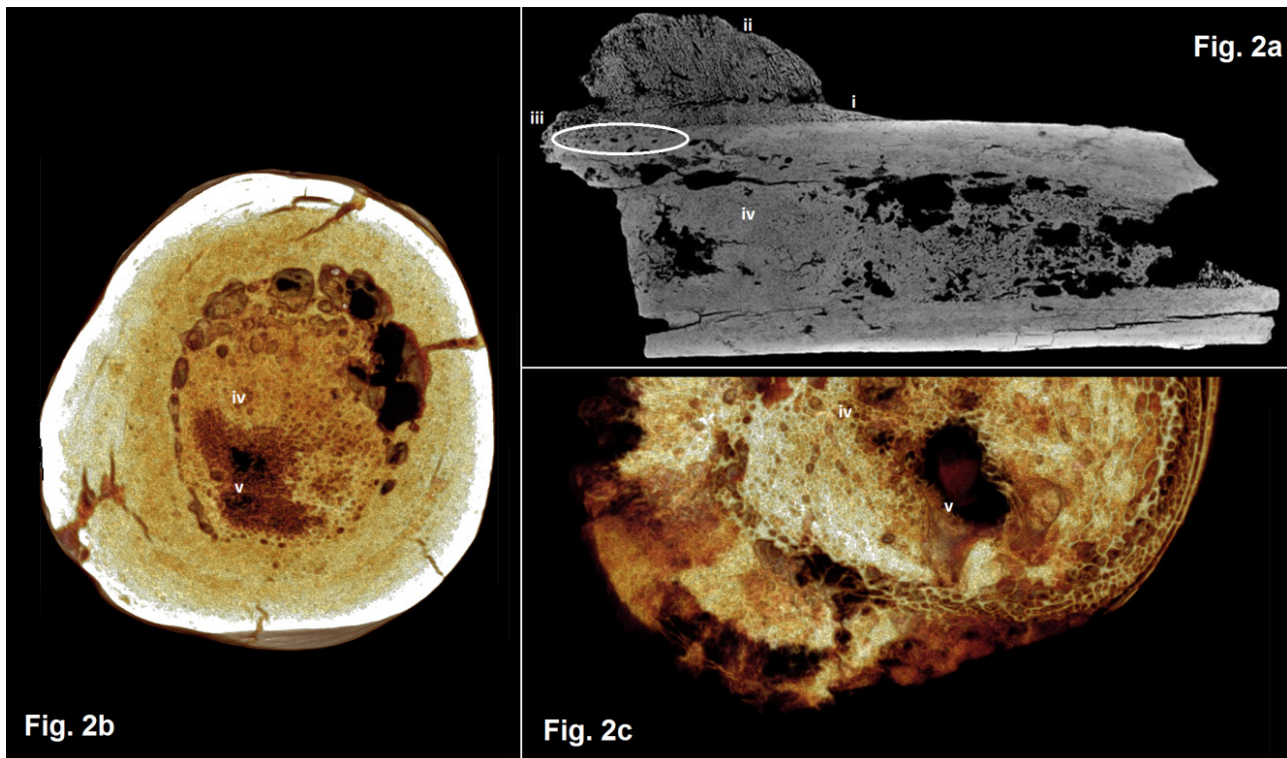


Figure 2: (a) Axial micro-CT orthoslice indicating (i) reactive new bone formation subperiosteally forming a Codman triangle, (ii) ossified exophytic (cauliflower-like) and/or spiculated mass adjacent to the bone, (iii) localised sub-periosteal invasion by the mass into the cortex, (iv) remodelled bone infill; (b) transverse rendered view of SK 7923; (c) transverse rendered view of modern clinical case of osteoblastic osteosarcoma with aggressive local medullary infilling (Courtesy: Department of Anatomy, University of Pretoria). Note (v) the homologous combination of spongy and solid bone between the fossil and clinical specimens.

Most parosteal osteosarcomas are found in the metaphyseal region of long tubular bones. The most common site is the distal femur, followed by the upper shaft of the tibia, and then the proximal humerus.

Functionally, this malignancy may have presented secondary consequences in our case study. The belly of *abductor digiti minimi* may have been displaced laterally, and with *fibularis brevis* and *f. tertius* inserting just proximal and distal to the growth, some influence on gait was likely. The presence of sub-periosteal bone formation in the form of a Codman triangle, cortical invasion, spiculated mass abutting the exostem, and aggressive medullary infilling (including the combination of trabeculated and avascular bone) indicates that what was originally diagnosed as a benign exosteal growth is now shown to represent a malignant bone malignancy. This change in diagnosis is entirely the result of advances in high-resolution 3D imaging, together with the judicious use of comparative clinical pathology. It is thus possible that cases of malignancy might remain unknown in fossil assemblages awaiting imaging and discovery.

Discussion

This case highlights a significant issue with regard to modern clinical incidence and expression of neoplastic disease, and malignancy in particular. That is, how can we understand ancient disease evolution when sample sizes are extremely small? As noted above⁷⁻⁹, malignancy is perceived as a disease of modernity. However, it is worth noting that primary skeletal malignant tumours are not commonly encountered in the modern clinical environment, and although rare they do feature in the archaeological and fossil record^{3,18}. Historically, factors of preservation have limited the study of human neoplasia to the skeleton, from which the confident diagnosis of tumours has been problematical.⁴⁸ Recent work on artificially mummified Egyptian remains has suggested to some scholars^{9,49} that malignancy was almost absent in pre-modern human populations. For example, Gray⁴⁹ reported no radiological confirmation

of malignant neoplasia among 193 examined Egyptian mummies. However, we view this assertion as tautological, because the samples on which the claim is based are not representative of the bulk of the human species living in antiquity; they represent only a small fraction of all humans living at that time⁵⁰. From the global historical sample available to us for study, malignancy does exist, albeit rarely – and a subset of those cases include osteosarcoma. Probable pre-modern cases are reported from Hawaii⁵¹, the Czech Republic⁵², and the Peruvian Andes¹.

The precise range of causes underlying malignancies is still largely unknown. Where causes have been established, these are generally understood to fall into three categories: physical, chemical, and viral.¹ Physical causes include being exposed to ultraviolet light (which increases the risk of basal cell carcinoma and malignant melanoma) and levels of background radiation.¹ Causative examples in the historical modern environment include the effects of radiation from the dropping of atomic bombs on Japan during World War II, which has been linked to an escalation in myelogenous leukaemia and thyroidal malignancy.¹ Chemical carcinogens in humans have historically been known to target skin and lungs, urinary bladder, and nasal sinuses and pleura. Potts demonstrated a relationship between scrotal malignancy in chimney sweepers and exposure to soot as early as 1775.⁵³ Many chemicals are widely accepted to be carcinogenic. Radon from granite, for example, is a radioactive gas causing lung malignancy.¹ Several viruses can cause malignancy in animals, and the association of some viruses with human malignancy is considerable. Examples include human papilloma virus (cervix malignancy), hepatitis B or C virus (liver malignancy), Epstein-Barr virus (non-Hodgkin lymphomas and nasopharyngeal malignancy), and human immunodeficiency virus (linked to non-Hodgkin lymphoma and Kaposi sarcoma).¹

Whilst most modern human malignancies are thought to be caused by environmental agents of a chemical nature, the evidence for this is not entirely conclusive.^{1,p.373} The internal environment, namely

diet and lifestyle, is thought to play a significant role in malignancy disposition. Some malignancies are certainly triggered by modern lifestyle factors, such as smoking, drinking (which can lead to liver and oesophageal malignancy), sunbathing, and obesity (which can lead to gastrointestinal gut malignancy).¹ Pesticides and industrial chemicals can cause malignancy, but their contribution is thought to be relatively minor. Of perhaps greatest impact is colorectal malignancy, which kills approximately 700 000 people every year worldwide⁸, and is most prevalent in developed countries such as USA and Europe. The lowest incidence occurs in underdeveloped countries in Africa, which have vastly different dietary regimes available to the population. Brody⁸ has named colorectal cancer a disease of modernity and development. In other words, economic growth is associated with a rise in the incidence of colorectal malignancy, with corresponding lifestyle changes possibly playing a strong role in the prevalence of this disease. An example is China, where a marked increase in the prevalence of colorectal malignancy is occurring.⁸

In addition, whilst the modern lifestyles of humans may enhance the frequency of cancer, longer life expectancies mean malignancy would logically occur at a higher rate among modern people than in our prehistory. We are unable to assess the age at death of the Swartkrans SK 7923 hominin (other than skeletally adult), but it was likely to have been substantially less than modern life expectancy, based on demographic studies of early hominin taxa⁵⁴.

The expression of malignant osteosarcoma in the Swartkrans SK 7923 specimen indicates that whilst the explosion of malignancy incidence is clearly correlated with the hazards of the modern world and increased life expectancy, primary bone tumours evidently occurred throughout history. Then, as now, such tumours would have occurred predominantly in younger individuals. Neoplastic disease has considerable antiquity, as evidenced by this specimen and further supported by numerous published case studies of benign neoplasms with deep antiquity in the fossil record, as noted above.^{1-3,10-12,18,55,56} The theory that the almost total lack of malignancies in Egyptian mummies indicates that the disease occurs only in industrialised societies⁹ is thus questionable.

The lack of substantial evidence of malignancy in the fossil and bio-archaeological records might arguably be an artefact of preservation, or of sampling bias and tiny sample sizes, or of analytical techniques or the application of inefficient imaging modalities⁵⁷. For example, the results would differ if plain radiography or clinical magnetic resonance imaging are used rather than micro-computed tomography. The absolutely small sample sizes arise from short life expectancy among pre-modern societies. Hence, the rare incidence of cancer cases found in the record can be seen as most likely non-representative, and should not be construed as indicating the true prevalence of disease. It is important to note that because of the worldwide demographic transition and average increased age at death for humans, non-primary bone malignancy can be expected to occur at a higher rate today than in pre-transition populations.⁵⁰

As highlighted in the introduction, malignancy occurs in almost all metazoans, suggesting that the mechanisms of malignancy have an extremely old evolutionary history. For example, neoplasms have been recorded in dinosaurs and other fossil forebears.^{2,11,56} A number of oncogenes are particularly archaic, with their antecedents exhibited in some form in primitive common ancestor metazoans of chordates and arthropods.^{55,58} Thus, the *capacity* for malignancy is ancient, and the higher incidence of malignancy in today's developed and developing world may be related to the unique interaction between environmental factors – which have no parallel in prehistory⁵⁹. It is also important to note that modern non-invasive imaging techniques (such as micro-computed tomography or phase-contrast synchrotron tomography), together with the appropriate use of clinical homologues, play a considerable role in enabling accurate diagnoses. These new techniques hold considerable potential for re-investigating previously reported palaeopathological lesions.

Acknowledgements

We would like to thank Stephany Potze and Lazarus Kgasi of the Ditsong National Museum of Natural History for providing access to the Swartkrans fossil specimen. E.J.O. would like to acknowledge the National Research Foundation of South Africa, the DST/NRF South African Centre of Excellence in Palaeosciences, and the University of the Witwatersrand for funding this research. We would like to thank the Department of Anatomy, University of Pretoria for permission to image and analyse the comparative clinical specimen used in this study. M.S. is supported by the National Research Foundation of South Africa.

Authors' contributions

E.J.O. and P.S.R.Q. wrote the original draft of the manuscript, incorporating additional information and data on SK 7923 obtained from M.S., J.S., Z.T., B.Z., T.N.A. and L.R.B. P.S.R.Q. and L.R.B. supervised the research. Critical input on the pathology of malignant neoplasms was provided by M.S. and J.S., and Z.T. and B.Z. gave input on functional aspects of pedal pathology. E.J.O. provided the differential diagnoses and historical pathological and palaeoanthropological data. J.W.H. and F.d.B. undertook the micro-computed tomographic scanning of the hominin specimen and the primary reconstruction. E.J.O. and P.S.R.Q. undertook secondary reconstruction from orthoslice and 3D volume data. All authors contributed equally to analysis and editing.

References

1. Aufderheide AC, Rodríguez-Martin C. The Cambridge Encyclopedia of human paleopathology. Cambridge: Cambridge University Press; 1998.
2. Capasso LL. Antiquity of cancer. *Int J Cancer*. 2005;113:2–13. <http://dx.doi.org/10.1002/ijc.20610>
3. Ortner DJ. Tumors and tumor-like lesions of bone. In: Ortner DJ, editor. Identification of pathological conditions in human skeletal remains. Amsterdam: Academic press; 2003. p. 503–544. <http://dx.doi.org/10.1016/b978-012528628-2/50057-0>
4. Jemal A, Bray F, Center M, Ferlay J, Ward E, Forman D. Global cancer statistics. *CA-Cancer J Clin*. 2011;61:69–90. <http://dx.doi.org/10.3322/caac.20107>
5. World Health Organization. The global burden of disease: 2004 update. Geneva: WHO Press; 2008. 153 pages.
6. Jemal A, Siegal R, Xu J, Ward E. Cancer statistics, 2010. *CA-Cancer J Clin*. 2010;60:277–300. <http://dx.doi.org/10.3322/caac.20073>
7. Binder M, Roberts C, Antoine D, Cartwright C. On the antiquity of cancer: Evidence for metastatic carcinoma in a young man from Ancient Nubia (c. 1200BC). *PLoS ONE* [Internet]. 2014;9, Art. #e90924 11 pages. <http://dx.doi.org/10.1371/journal.pone.0090924>
8. Brody H. Colorectal cancer. *Nature*. 2015;521, Art. #a7551. http://www.nature.com/nature/journal/v521/n7551_suppl/jul/521S1a.html
9. David RA, Zimmerman MR. Cancer: An old disease, a new disease or something in between? *Nat Rev Cancer*. 2010;10:728–32. <http://dx.doi.org/10.1038/nrc2914>
10. Rothschild BM, Tanke DH, Hebling M, Martin LD. Epidemiologic study of tumors in dinosaurs. *Naturwissenschaften*. 2003;90:495–500. <http://dx.doi.org/10.1007/s00114-003-0473-9>
11. Rothschild BM, Martin LD. Paleopathology: Disease in the fossil record. Boca Raton, FL: CRC Press; 1993.
12. Leshchinsky SV. Paleoeological investigation of mammoth remains from the Kraków Spadzista Street (B) site. *Quatern Int*. 2012;(276–277):155–169. <http://dx.doi.org/10.1016/j.quaint.2012.05.025>
13. Retief FP, Cilliers L. Breast cancer in antiquity. *S Afr Med J*. 2011;101(8):513–515.
14. Phelan J, Weiner MJ, Ricci JL, Plummer T, Gauld S, Potts R, et al. Diagnosis of the pathology of the Kanam mandible. *Oral Surg Oral Med O*. 2007;103(4), Art. #e20. <http://dx.doi.org/10.1016/j.tripleo.2006.12.041>
15. Stathopoulos G. Kanam mandible's tumour. *Lancet*. 1975;305(7899). p. 165. [http://dx.doi.org/10.1016/S0140-6736\(75\)91462-2](http://dx.doi.org/10.1016/S0140-6736(75)91462-2)

16. Tobias PV. The Kanam jaw. *Nature*. 1960;185:946-947. <http://dx.doi.org/10.1038/185946a0>
17. Tobias PV. A re-examination of the Kanam mandible. In: Mortelmans G, Nenquin J, editors. *Actes du IVe Congrès Panafricain de Préhistoire et de l'Étude du Quaternaire, Sections I and II. Tervuren, Belgique: Annales Ser. Qu-8o, Sciences Humaines 40; 1962. p. 341–350. [French].*
18. Randolph-Quinney PS, Williams SA, Steyn M, Meyer MR, Smilg JS, Churchill SE, et al. Osteogenic tumour in *Australopithecus sediba*: Earliest hominin evidence for neoplastic disease. *S Afr J Sci*. 2016;112(7/8), Art. #2015-0470, 7 pages. <http://dx.doi.org/10.17159/sajs.2016/20150470>
19. Monge J, Kricun M, Radovčić J, Radovčić D, Mann A, Frayer DW. Fibrous dysplasia in a 120,000+ year old Neandertal from Krapina, Croatia. *PLoS ONE*. 2013;8(6), Art. #e64539. <http://dx.doi.org/10.1371/journal.pone.0064539>
20. de Ruiter DJ. Revised faunal lists for Members 1–3 of Swartkrans, South Africa. *Ann Trans Mus*. 2003;40:29–41.
21. Berger L, Lacruz R, De Ruiter D. Revised age estimates of *Australopithecus*-bearing deposits at Sterkfontein, South Africa. *Am J Phys Anthropol*. 2002;119:192–197. <http://dx.doi.org/10.1002/ajpa.10156>
22. Brain C. Structure and stratigraphy of the Swartkrans cave in light of the new excavations. In: Brain C, editor. *Swartkrans: A cave's chronicle of early man*. Pretoria: Transvaal Museum; 1993. p. 23–34.
23. Vrba E. Early hominids in southern Africa: Updated observations on chronological and ecological background. In: Tobias P, editor. *Hominid evolution: Past, present and future*. New York: Alan R. Liss; 1985. p. 195–200.
24. Curnoe D, Grun R, Taylor L, Thackeray J. Direct ESR dating of a Pliocene hominin from Swartkrans. *J Hum Evol*. 2001;40:379–391. <http://dx.doi.org/10.1006/jhev.2000.0459>
25. Herries A, Curnoe D, Adams J. A multi-disciplinary seriation of early Homo and Paranthropus bearing palaeocaves in southern Africa. *Quatern Int*. 2009;202(1):14–28. <http://dx.doi.org/10.1016/j.quaint.2008.05.017>
26. Brain C. New finds at the Swartkrans australopithecine site. *Nature*. 1970;225:1112–1119. <http://dx.doi.org/10.1038/2251112a0>
27. Broom R, Robinson J. A new type of fossil man. *Nature*. 1949;164:322. <http://www.nature.com/nature/journal/v164/n4164/pdf/164322a0.pdf>
28. Brain C. A taphonomic overview of the Swartkrans fossil assemblages. In: Brain C, editor. *Swartkrans: A cave's chronicle of early man*. Pretoria: Transvaal Museum; 1993. p. 257–264.
29. Burchill S. Ewing's sarcoma: Diagnostic, prognostic, and therapeutic implications of molecular abnormalities. *J Clin Pathol*. 2003;56(2):96–102. <http://dx.doi.org/10.1136/jcp.56.2.96>
30. Eisenberg R. Bubbly lesions of bone. *Am J Roentgenol*. 2009;193(2):W79–94. <http://dx.doi.org/10.2214/AJR.09.2964>
31. Geirnaerd M, Hogendoorn P, Bloem J, Taminiau A, van der Woude H. Cartilaginous tumors: Fast contrast-enhanced MR Imaging 1. *Radiology*. 2000;214(2):539–546. <http://dx.doi.org/10.1148/radiology.214.2.r00fe12539>
32. Huvos A. Ewing's sarcoma. In: Huvos A, editor. *Bone tumors: Diagnosis, treatment and prognosis*. 2nd ed. Philadelphia PA: Sanders; 1991. p. 523–552.
33. Llauger J, Palmer J, Amores S, Bague S, Camins A. Primary tumors of the sacrum: Diagnostic imaging. *Am J Roentgenol*. 2000;174(2):417–424. <http://dx.doi.org/10.2214/ajr.174.2.1740417>
34. Lucas D, Unni K, McLeod R, O'Connor M, Sim F. Osteoblastoma: Clinicopathologic study of 306 cases. *Hum Pathol*. 1994;25(2):117–134. [http://dx.doi.org/10.1016/0046-8177\(94\)90267-4](http://dx.doi.org/10.1016/0046-8177(94)90267-4)
35. McLeod R, Dahlin D, Beabout J. The spectrum of osteoblastoma. *Am J Roentgenol*. 1976;126:321–325. <http://dx.doi.org/10.2214/ajr.126.2.321>
36. Murphey M, Walker E, Wilson A, Kransdorf M, Temple H, Gannon F. From the archives of the AFIP: Imaging of primary chondrosarcoma: Radiologic-pathologic correlation. *Radiographics*. 2003;23(5):1245–1278. <http://dx.doi.org/10.1148/rg.235035134>
37. Osborne R. The differential radiologic diagnosis of bone tumors. *CA-Cancer J Clin* 1974;24(4):194–211. <http://dx.doi.org/10.3322/canjclin.24.4.194>
38. Trübenbach J, Nägele T, Bauer T, Ernemann U. Preoperative embolization of cervical spine osteoblastomas: Report of three cases. *Am J Neuroradiol*. 2006;27(9):1910–1912.
39. Unni K, Dahlin D. Osteosarcoma: Pathology and classification. *Semin Roentgenol*. 1989;24(3):143–152. [http://dx.doi.org/10.1016/0037-198X\(89\)90010-2](http://dx.doi.org/10.1016/0037-198X(89)90010-2)
40. Berry M, Mankin H, Gebhardt M, Rosenberg A, Hornicek F. Osteoblastoma: A 30-year study of 99 cases. *J Surg Oncol*. 2008;98:179–183. <http://dx.doi.org/10.1002/jso.21105>
41. Binning M, Klimo Jr P, Gluf W, Goumnerova L. Spinal tumors in children. *Neurosurg Clin N Am*. 2007;18(4):631–658. <http://dx.doi.org/10.1016/j.nec.2007.07.001>
42. de Souza Dias L, Frost HM. Osteoid Osteoma – Osteoblastoma. *Cancer*. 1974;33:1075–1081. [http://dx.doi.org/10.1002/1097-0142\(197404\)33:4<1075::AID-CNCR2820330427>3.0.CO;2-4](http://dx.doi.org/10.1002/1097-0142(197404)33:4<1075::AID-CNCR2820330427>3.0.CO;2-4)
43. Giannico G, Holt G, Holmar K, Johnsson J, Pinnt J, Bridge J. Osteoblastoma characterized by a three-way translocation: Report of a case and review of the literature. *Cancer Genet Cytogen*. 2009;195:168–171. <http://dx.doi.org/10.1016/j.cancergencyto.2009.06.024>
44. Lucas DR. Osteoblastoma. *Arch Pathol Lab Med*. 2010;134:1460–1466.
45. Osborn AG. Tumors, cysts, and tumorlike lesions of the spine and spinal cord. In: Osborn AG, editor. *Diagnostic neuroradiology*. St. Louis: Mosby; 1994. p. 876–918.
46. Saccomanni B. Osteoid osteoma and osteoblastoma of the spine: A review of the literature. *Curr Rev Musculoskel Med*. 2009;2:65–67. <http://dx.doi.org/10.1007/s12178-009-9047-6>
47. Vigorita VJ. *Orthopaedic pathology*. 2nd ed. Philadelphia: Lippincott Williams & Wilkins; 2008.
48. Rothschild BM, Rothschild C. Comparison of radiologic and gross examination for detection of cancer in defleshed skeletons. *Am J Phys Anth*. 1995;96(4):357–363. <http://dx.doi.org/10.1002/ajpa.1330960404>
49. Gray PHK. The radiography of mummies of ancient Egyptians. *J Hum Evol*. 1973;2:51–53. [http://dx.doi.org/10.1016/0047-2484\(73\)90098-5](http://dx.doi.org/10.1016/0047-2484(73)90098-5)
50. Chamberlain AT. *Demography in archaeology*. Cambridge: Cambridge University Press; 2006. <http://dx.doi.org/10.1017/CBO9780511607165>
51. Suzuki T. Paleopathological study on a case of osteosarcoma. *Am J Phys Anth*. 1987;74:309–318. <http://dx.doi.org/10.1002/ajpa.1330740305>
52. Strouhal E, Vyhnanek L, Horackova L, Benesova L, Nemeckova A. A case of osteosarcoma in a late medieval–early modern skull from Kyjov (Czech Republic). *Int J Osteoarchaeol*. 1997;7:82–90. [http://dx.doi.org/10.1002/\(SICI\)1099-1212\(199701\)7:1<82::AID-OA320>3.0.CO;2-J](http://dx.doi.org/10.1002/(SICI)1099-1212(199701)7:1<82::AID-OA320>3.0.CO;2-J)
53. Clayson D. *Chemical carcinogenesis*. Boston: Little, Brown & Co; 1962.
54. Mann A. *Paleodemographic aspects of the South African australopithecines*. Philadelphia: University of Pennsylvania; 1975.
55. Davies PCW, Lineweaver CH. Cancer tumors as Metazoa 1.0: Tapping genes of ancestors. *Phys Biol*. 2011;8, Art. #a015001. <http://dx.doi.org/10.1088/1478-3975/8/1/015001>
56. Rothschild BM, Witzke BJ, Hershkovitz I. Metastatic cancer in the Jurassic. *Lancet*. 1999;354. p. 398. [http://dx.doi.org/10.1016/S0140-6736\(99\)01019-3](http://dx.doi.org/10.1016/S0140-6736(99)01019-3)
57. Beckett RG, Conlogue GJ. *Paleoimaging: Field applications for cultural remains and artefacts*. Boca Raton, FL: CRC Press; 2010.
58. Weinberg R. Oncogenes and the molecular biology of cancer. *J Cell Biol*. 1983;97:1661–1662. <http://dx.doi.org/10.1083/jcb.97.6.1661>
59. Klepinger L. The evolution of human disease: New findings and problems. *J Biosoc Sci*. 1980;12(4):481–486. <http://dx.doi.org/10.1017/s0021932000013067>

Note: This article is accompanied by supplementary material.

