

THE SKULL AND MANDIBLE OF THE  
SOUTH AFRICAN BABOON,

A Morphological study.

---

Trevor Rubidge Trevor-Jones .

This Thesis is submitted to the University of the  
Witwatersrand, Johannesburg, in fulfilment of the  
requirements for the degree of Master of Surgery.  
The examination for this degree was completed in  
1947.

Johannesburg, 1975.



THE SKULL AND MANDIBLE OF THE  
SOUTH AFRICAN BABOON.

A Morphological study.

---

Trevor Rubidge Trevor-Jones.

This Thesis is submitted to the University of the  
Witwatersrand, Johannesburg, in fulfilment of the  
requirements for the degree of Master of Surgery.  
The examination for this degree was completed in  
1947.

Johannesburg, 1975.

I hereby declare that this thesis entitled  
the 'SKULL AND MANDIBLE OF THE SOUTH AFRICAN  
BABOON' is my own unaided work and that the  
substance or any part of it has not been  
submitted in the past or is being, or about  
to be submitted for a degree at any other  
University

T.R.Trevor-Jones

## ABSTRACT

The skull and mandible of the baboon.

This is a morphological study of the skulls and mandibles of 102 specimens from known localities in Southern Africa.

A detailed reference book on the anatomy of the baboon is particularly important because of the increasing use of this animal in medical science.

The skulls and mandibles of captive animals are referred to but are not included in the comparative study since animals in captivity are subject to dietetic disturbances and other factors not yet fully understood.

The cranium of an adult male skull is described in all normae. Comparisons are made with the crania of seven adult male baboons from widely separated known localities. This study shows that two main craniofacial types, with intermediate types, occur among the crania of South African baboons.

Type 1. crania have small maxillary ridges, shallow maxillary fossae, ventrally directed zygomatic bones, large ventral orbital apertures, well developed superciliary ridges, high temporal lines and sagittal crests. Type 11. crania have large flared maxillary ridges, deep maxillary fossae, ventro-laterally directed zygomatic bones, small ventral orbital apertures, large supraorbital tori, low temporal lines and no sagittal crests.

This apparently supports the specific and subspecific claims of some observers. However, a critical examination of the crania of six adult female baboons from the same troop at Bindura, Rhodesia, shows that similar craniofacial types occur among female baboons.

It is possible to associate mandibular types with the craniofacial types in adult male baboons. This is not the case with female baboon mandibles.

Specimens from the Cape Colony, the Transvaal and Rhodesia were dissected. These dissections provide the material for the anatomical study of soft tissues relating to the external and internal aspects of the craniofacial skeleton.

Special attention is paid to the disarticulated bones of the cranium. This procedure enables one to establish the correct bony structure of the hard palate, the nasal and orbital cavities. The sutural arrangement between the cranial bones enables one to establish definite stress patterns at intercranial, craniofacial and facial sutures.

In conclusion the morphological features of the baboon skull are discussed. This study clearly indicates that there is only one baboon species in Southern Africa, south of the Zambezi river.

## ACKNOWLEDGEMENTS

I am indebted to the following for their assistance in preparing this thesis :

Mr. Vivian J. Wilson and Dr. D.G. Broadley curators of the National Museums of Rhodesia at Bulawayo and Umtali respectively. Mr. Wilson and Dr. Broadley allowed me unrestricted use of all the baboon skulls and mandibles from known localities in their museums.

Mr. B.J. Hoole, regional warden in Mashonaland for the Department of National Parks and Wild Life for Rhodesia. Mr. Hoole assisted Mr. R.E. King in the collection of baboon skeletal remains from Bindura.

Professor L.H. Wells of the Department of Anatomy, Medical School, University of Cape Town, for dissecting material and advice.

Professor P.V. Tobias, of this University for dissecting material and advice.

Dr. George van Dugteren, who collected preserved baboon heads from the primate centre at the Carl Bremmer Hospital, University of Stellenbosch. Also to Professor F. van Zyl of the same University for allowing me to examine the live baboons in this colony.

Dr. G.S. Saayman, of the University of Pretoria, who conducted baboon troop studies for me in the Kruger National Park.

Dr. C.K. Brain, Director of the Transvaal Museum, Pretoria, who kindly allowed me access to the Museums' collection of baboon skulls.

Professor P.J. du Plessis, Head of the Department of Surgery for advice and encouragement.

Mrs. J. McInnes for the typing, Mrs. B. Bruce-Brand for labelling and mounting the illustrations and Mrs. M. Jansen for the photography.

## TABLE OF CONTENTS

<u>Contents :</u>	<u>Pages</u>
Introduction	1 - 4
Methods	5
Material	6 - 8
The cranium of the male baboon	9 - 30
The interior of the cranium	31 - 36
The cranium of the female baboon	37 - 42
The separate cranial bones of an immature specimen	43 - 53
The mandible of the male baboon	54 - 58
The mandible of the adult female baboon	58 - 60
Discussion :	61 - 75
The cranium	
The interior of the skull	
Sexual dimorphism and Taxonomy	
The individual bones of the skull	
The mandible	
General conclusions	76 - 77
References	78 - 81

## ILLUSTRATIONS

<u>Page No.</u>	<u>Fig.No.</u>	
9	1.	Norma facialis.
10	2.	Cross sections of muzzles.
11	3.	Norma facialis of 7 adult male baboon crania from known localities.
11	4.	Orbits and supraorbital regions of adult male baboons from known localities.
12	5.	The ventral aspect of the right orbital cavity.
14	6.	Norma lateralis.
18	7.	Norma lateralis of the crania of 7 adult male baboons from known localities.
19	8.	Norma occipitalis.
19	9.	Norma occipitalis of the crania of 7 adult male baboons from known localities.
21	10.	Norma cranialis.
21	11.	Norma cranialis of the crania of 7 adult male baboons from known localities.
23	12.	Norma basalis.
16/26	13.	The base of the cranium.
26	14A & B.	The foramen lacerum with pterygospinous and pterygoalar bars.
30	15.	The attachment of the cervical fascia and muscles to the nuchal area.
31	16A & B.	The endocranial aspect.
38	17.	Norma facialis of the crania of 6 adult female baboons from the same troop.
39	18.	Norma lateralis of the crania of 6 adult female baboons from the same troop.
40	19.	Norma cranialis of the crania of 6 adult female baboons from the same troop.
42	20.	Norma occipitalis of the crania of 6 adult female baboons from the same troop.
		Individual bones of the skull.
43	21.	The frontal bone.
44	22.	The parietal bone.
44	23.	The occipital bone.



<u>Page No.</u>	<u>Fig.No.</u>	
45	24.	The temporal bone.
46	25.	The sphenoid bone.
48	26A.	The ethmoid bone.
48	26B.	The vomer.
49	26C.	The palatine bone.
49	27.	The left lacrimal bone.
49	28.	The right zygomatic bone.
50	29.	The right maxillary bone.
51	30.	The premaxilla.
52	31.	The nasal bone.
52	32.	The sagittal section of young adult male cranium.
		The male mandible.
54	33A.	The mandible, medial aspect.
55	33B.	The mandible, lateral aspect.
55	34A.	The mandible, muscle attachments, lateral aspect.
55	34B.	The mandible, muscle attachments, medial aspect.
56	35A.	The mandible, ventral aspect.
56	35B.	The mandible, dorsal aspect.
56	36A.	The mandible, cranial aspect.
57	36B.	The mandible, caudal aspect.
58	37.	The lateral and ventral aspects of the mandibles of 2 adult male baboons. ( $\frac{1}{2}$ Normal size).
		The female mandible.
58	38.	The lateral aspects of the mandibles of 6 adult female baboons from the same troop.
59	39.	The ventral aspects of the mandibles of 6 adult female baboons from the same troop.
59	40.	The cranial aspects of the mandibles of 6 adult female baboons from the same troop.
59	41.	The caudal aspects of the mandibles of 6 adult female baboons from the same troop.
59	42.	The dorsal aspect of the mandibles of 6 adult female baboons from the same troop.
60	43.	The medial aspect of the mandible of an adult female baboon.
62	44.	Radiographs of the skull of an adult male baboon.
62	45A.	The peg and socket articulation between the maxilla and premaxilla.

<u>Page No.</u>	<u>Fig.No.</u>	
62	45B.	The zygomaticomaxillary suture.
63	46.	Radiographs of the frontal bones of adult and adolescent baboons.
63	47.	Radiographs of the crania of captive adult male baboons from the Pretoria Zoo.
73	48.	Sphenoidal synchondroses.
74	49.	Radiograph of the lateral aspect of the mandible.

## INTRODUCTION

In South Africa the anatomy of the baboon has been studied for many years. Primate anatomy, as exemplified by the baboon, has always been a recognised course for Anatomy 11 students at the Universities of Cape Town and the Witwatersrand. However, despite this extensive research, no reference book, on the lines of Hartman and Strauss (1933) has been published.

In the past three decades baboons have replaced the smaller cercopithecoidea as experimental animals. Baboon colonies are features at most of our medical schools and research institutions, and provide material for research in all fields of biology and medicine.

The need for a standard reference book on the anatomy of the baboon was so essential that Freedman (1957) found it necessary to give a brief description of the cranium and mandible of Papio ursinus before commencing his study of the fossil Cercopithecoidea of South Africa. There is no doubt that other workers have experienced similar difficulties and it is essential that a standard text should be compiled without further delay.

### The cranium and mandible.

In the present study dissections of the baboon head provide the basis for detailed descriptions of the cranium and structures related to its external and internal aspects. Reference is made to muscle attachments and the structures related to the various foramina, fossae, cavities, sulci, fissures and processes.

In addition, this morphological study forms the basis for a comparison of the crania and mandibles of adult baboons of both sexes from known localities in Rhodesia, the Republic of South Africa and South West Africa.

There are two main craniofacial types among the 102 specimens studied. These are : i) with large ventral orbital openings, ventrally facing zygomata, relatively small maxillary ridges, shallow maxillary recesses and well developed sagittal crests; ii) with smaller ventral orbital openings, ventrolateral facing zygomata, large scrolled maxillary ridges, deep maxillary recesses and poorly developed sagittal crests.

This observation would seem to support the claims made by Austin Roberts (1951) and Goldblatt (1926) that there are different species and subspecies among South African baboons. However, an examination of the crania and mandibles of adult male baboons from known localities reveals intermediate profiles between these two types. Evidence for a variety of craniofacial types is found when the crania and mandibles of six adult females from the same troop are scrutinised.

#### The separate bones of the skull.

While the individual bones of the human skull have been described in detail, similar studies on the skull bones of lower mammals have been neglected. Neal and Rand (1936) claimed that 'except in proportion there is little differences between the skull of man and other animals'.

It is relatively simple to compare the external and internal appearances of the skull bones of various mammals on an examination of intact skulls. A detailed examination and the drawing of accurate conclusions is, however, impossible unless the disarticulated cranial bones are examined. This applies especially to the bony architecture of the palate, the nasal cavity, the orbital cavity and the anterior cranial fossa.

It is generally accepted that the bony structure of the palate, nose and orbit, with minor modifications is similar in all mammals. Broom (1930) found the human palate to be similar to that of a typical mammal. He also held that the bones of the nasal septum, except the mesethmoid, were similar in all mammals. Reynolds (1913) showed that the bony framework of the nasal septum in the edentata was formed by the vomer and mesethmoid.

Hill's (1957) description of the bony structure of the medial wall of the orbit in platyrrhine monkeys is generally accepted

as being standard for all primates i.e., frontal cranially, lacrimal, ethmoid and orbitosphenoid medially with a large element of palatine bone dorsally.

Clark (1971) noted that the osseous mozaic of the medial wall of the orbit varies significantly among primates. In Lemuriformes the orbital plate of the palatine bone extends forward to meet the lacrimal bone and so separates the frontal bone from the maxillary bone. In Lorisiformes, Tarsius and the Anthropoidea the ethmoid separates the frontal bone from the maxillae and the palatine bone from the lacrimal. Clark considered that these variations reflected the forward rotation of the eyes.

As demonstrated by Trevor-Jones (1972) the ethmoid, vomer and palatine bones of the baboon and vervet monkey differ markedly from those of man. It was this misidentification of the vomer that led Freedman (1957) to believe that the ethmoid participated in the formation of the medial wall of the orbit. Personal experience with the disarticulated cranial bones from other mammals has indicated that a valuable field of research still awaits comparative anatomists. In Dart's (1972) opinion all primate skulls should be studied in this way.

Zuckerman's (1962) detailed description of growth changes in the skull of the baboon would have been an even more valuable contribution if he had examined the separate cranial bones of the immature baboon. Freedman (1957) contends that the status of many subspecies and even species of the living Cercopithecoidea - particularly the baboons is at present a most contentious problem. He also feels that a thorough restudy of the whole group is urgently required and quotes Washburn (1949) as stating - 'The attempt has been made repeatedly to divide baboons into sharply defined groups. The chaos that has resulted is the result of expecting that plain forms, which have vast reaches of similar habitat open to them, will divide as the tree restricted monkeys do'.

This confused state has many possible explanations. Farmers and hunters in this country refer to 'lang-kop' (long headed), 'Kort-kop' (short headed), 'perde-kop' (horse headed), 'geel-bobbejaan' (yellow baboon) 'swart-bobbejaan' (black baboon) and so on. Eugene Marais (1939) identified four subspecies - the yellow-baboon, the green-baboon, the black-baboon

and the Rhodesian-baboon. Later Marais (1939) however, concluded that all the South African baboons belonged to the same species.

Roberts (1951) divided the South African baboons into three species - Papio ursinus, Papio cynocephalus and Papio rhodesiae. Under Papio ursinus he recognised seven subspecies : P.u. ursinus, P.u.orientalis, P.u. occidentalis, P.u. ruacana, P.u. griseipes, P.u. ngamiensis and P.u. chobiensis. Freedman (1957) pointed out that Robert's (1951) classification was based entirely on colour and size differences. Freedman had hoped to establish, on craniometric grounds, interspecific differences but was unable to do so. He concluded that 'no definite evidence of subspecies was found in the cranial and tooth statistics calculated. Further no important differences could be detected between samples representing a local population and the rest of the species'.

Jolly, as quoted by Napier and Napier (1967), on the other hand, recognises five Papio species in Africa of which only Papio ursinus with four subspecies occur in Southern Africa.

On a purely metrical analysis of Papio ursinus (Kerr) Freedman (1957) could find no definite evidence of subspecies in the cranial or tooth statistics. Indeed, he found no important differences between samples from a local population and the rest of the species.

The present morphological study not only confirms Freedman's findings but, because of the great variation of neurocranial and mandibular profiles, casts doubts on our accepted classification of the fossil Ceropithecoidea of South Africa

## METHODS

For the purposes of description the skull of the adult male baboon from the Zambezi Valley was used. This skull was chosen as it resembled Freedman's specimen most closely (Freedman, 1957). The skull was examined using a condylar-molar plane since this plane gives a clearer appreciation of the relationship between the facial and neurocranial skeleton. However, for the comparative studies between individual specimens the standard plane as defined by Trevor (1959) was used. For the comparative study the crania of seven adult male baboons from known areas were used. Line drawings, using a camera lucida at a reduction to  $\frac{3}{4}$  actual size were used in preference to photographs which, because of the size of the muzzle gave distorted pictures in *norma facialis* and *norma verticalis*.

The variation of osteological features among the 102 baboon crania studied is so marked, that it is not possible to accept any one of the profiles as standard for *Papio ursinus*. The profile descriptions are therefore presented before reference is made to specimen differences. In order to study the separate bones of the crania six immature crania were disarticulated after boiling in a weak solution of caustic soda. In the case of resistant crania the process was accelerated by filling the vault with dried peas, rice or maize prior to boiling.

## MATERIAL

The skeletal material examined consists of the crania and mandibles of adult male and female baboons from known areas in the Republic of South Africa, South West Africa and Rhodesia. The crania and mandibles of captive animals were not used since, as De Klerk (1973) pointed out, the metabolism of animals in captivity is markedly altered.

This material is detailed as follows. The numbers of male and female skulls from each locality are as follows:

## A. Personal collection.

<u>Locality</u>	<u>Male</u>	<u>Female</u>
Riversdale, Cape Province	6	5
Oamites, South West Africa	2	1
Magaliesberge	2	0
Waterberg	0	1
Bindura, Rhodesia	1	6

## B. Skulls of Rhodesian specimens on loan from the National Museum, Bulawayo.

<u>Locality</u>	<u>Male</u>	<u>Female</u>
Cloudlands, Umtali	N.M.4424	0
Chipinga, Rhodesia	N.M.27048	0
Fern Valley, Umtali	1	0
Gona-Re-Zhou	3	1
Kariba Gorge	N.M.13852	N.M.13826
	N.M.13853	N.M.13841
		N.M.13850
Limpopo	N.M.9955	0
Murahwas Kraal, Umtali	1	0
Ziwa, Umtali	1	0
West Nicholson	1	0
Zambezi Valley	1	0
Unknown	1	0



C. Skulls of adult male baboons at the Transvaal Museum, Pretoria.

<u>Locality</u>	<u>T.M. numbers</u>
Schierkloof, Albany. E.Cape.	280, 783, 784, 788, 792, 797, 803, 808, 950.
Graaff Reinet	1025
Kafue River, Zambezi	776
Lundi River, Rhodesia	11560
Makapansgat N.Tvl.	13291
Magaliesberge Tvl.	4443
Mulabezi, Zambia	12351
Maluzi River, Zambia	919
Phillipstown, E.Cape.	720, 722, 723
Sabi River	7777
Transvaal	11741
Waterberg, Transvaal	4
Western, Transvaal	11706
Locality unknown	983, 11708, 11767, 11769, 16449.

<u>Type specimens</u>	<u>Locality</u>	<u>Number</u>
<u>Papio rhodesiae</u>	Marandellas and Pretoria Zoo	4073
<u>Papio ursinus occidentalis</u>	Rustenburg	11707
<u>Papio ursinus orientalis</u>	Queenstown	11705
<u>Papio ursinus chobiensis</u>	Maun, Nyamiland.	6614, 6615
<u>Skulls of captive animals.</u>	<u>Pretoria Zoo</u>	<u>Number</u>
<u>Papio ursinus</u>		68, 4078, 4696, 13290
A bear		1067

D. Skulls of adult male baboons from Zambia in the National Museum,  
Bulawayo.

<u>Locality</u>	<u>N.M. Numbers.</u>
Choma	5102, 11814.
Fort Jamieson	8383, 17377, 20127, 20145, 20146, 20307, 20360, 20368, 20372, 22717, 22729, 22730, 27573.
Kalomo	5045
Mulabezi River	5047
Luangwa River	20378, 20394, 22397, 22738, 22941, 27821.
Total.	Males 85. Females 17.

## THE CRANIUM OF THE ADULT MALE BABOON

The illustrations (Figures 1,6,8,10 & 12) are of the cranium of an adult male baboon from the Zambezi Valley. The most striking feature of the cranium of a male baboon is the greatly elongated muzzle and exceptionally large canines. These two features dominate all normae and especially norma facialis.

### Norma facialis (Figure 1.)

The face presents a rough quadrangle with a small rounded dome formed cranially by the fused frontal bones. Ventrally the united premaxillae, bearing the incisors, form a large wedge shaped bone. On either side they articulate with the maxillae and end dorsally as small angular processes separating the nasal bones from the maxillae.

The premaxillae form the ventral and lateral boundaries of the ventral nasal aperture. The dorsal border of this aperture is formed by the nasal bones. The nasal aperture varies in size and shape. It is usually an ovoid, flattened at the nasal bones. The premaxillary margins are rounded or sharp and fuse centrally at an acute angle or as an even curve. There is thus no nasal spine. The dorsal boundary formed by the nasal bones has an even curve.

The maxillae form the greater part of norma facialis. They bear the canines, premolars and molars and are characterized by large maxillary ridges which form the lateral and cranial margins of the muzzle and the cranial boundaries of the maxillary fossae.

The maxillary ridges extend from the alveoli of the canines to the infraorbital region dorsally. They vary in size and shape. In some specimens the maxillary ridges form rounded borders at the junction of the cranial and lateral borders of the muzzle. In others these ridges are large, sinuous and form flared rounded ridges between the cranial and lateral borders of the muzzle. The different types of maxillary

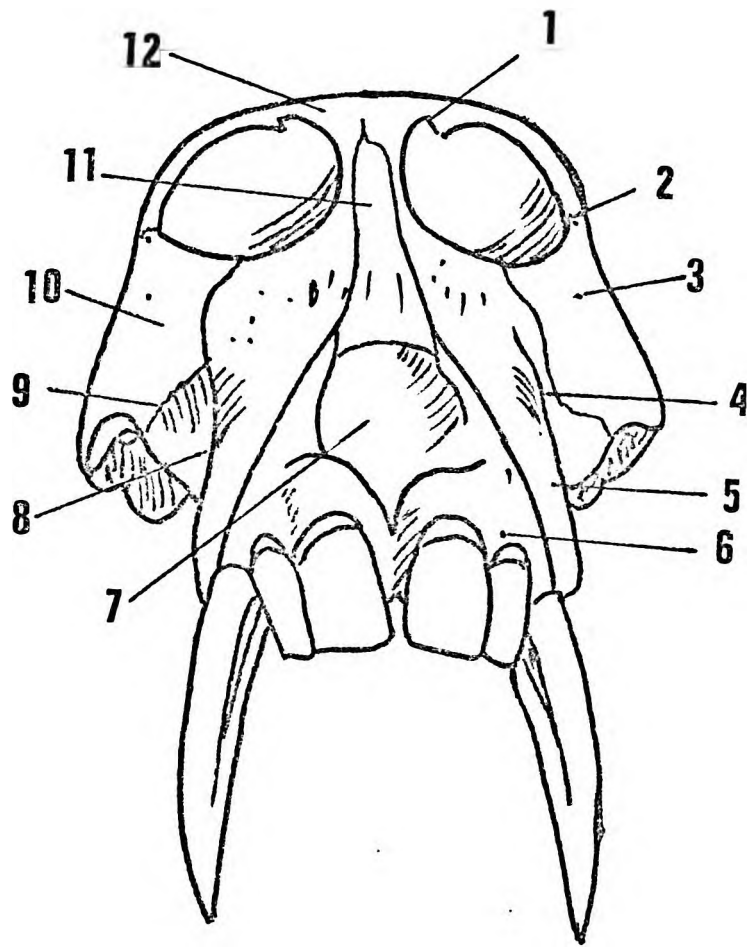


Figure 1.

Figure 1. Norma facialis.

1. Supraorbital notch.
2. Zygomaticotemporal foramen.
3. Zygomaticofacial foramen.
4. Maxillary ridge.
5. Canine buttress.
6. Premaxilla.
7. Nasal aperture.
8. Maxillary fossa.
9. Zygomaticomaxillary suture.
10. Zygomatic bone.
11. Nasal bone.
12. Frontal bone.

ridges are associated with different types of cross sections of the muzzles (Figure 2). When rounded the section is a flattened triangle but when flared the nasal bones are bounded by deep grooves in the adjacent maxillae and the section resembles a cupid's bow.

The maxillary ridges, especially at the level of the nasal apertures, are covered by numerous cross striations for the attachment of the nasiolabialis muscles.

The maxillary ridges also determine the depth of the maxillary fossae. These fossae are formed on the lateral side of the maxillae. Ventrally they are bounded by the alveoli covering the roots of the canines, cranially by the maxillary ridges, dorsally by the zygomatic bones and the zygomatic processes of the maxillae and caudally by the alveoli of the premolars and molars. Flared maxillary ridges are associated with deep maxillary fossae and rounded ridges with shallow fossae respectively.

The maxillae have zygomatic and frontonasal processes. The zygomatic processes commence ventrocaudally as strong buttresses and extend cranially from the alveolar sockets of the third molars. These buttresses and the adjoining zygomaticomaxillary sutures form the dorsal walls of the maxillary fossae. The frontonasal processes articulate with the lacrimal bones and then form a narrow bridge to articulate with the nasal processes of frontal bone. In some specimens these processes of the maxillae participate in the formation of the inferior orbital margins.

The infraorbital nerves and vessels emerge through 10 or 15 foramina on the cranial and lateral surfaces of the maxillae, and are arranged in an orbital group dorsally and a nasal group ventrally. The external nasal branches of the anterior ethmoidal nerves pass through foramina in the nasal processes of the premaxillae.

The nasal bones fuse early in the life of a baboon to form a single nasal bone in the midline. Dorsally the nasal bone articulates with the nasal process of the frontal bone, laterally with the maxillae and ventrally with the nasal processes of the premaxillae. In outline the nasal bone may resemble a long, narrow based isosceles triangle or a manubrium sterni. Its articulation with the frontal bone may be triangular or include a series of small Wormian bones.

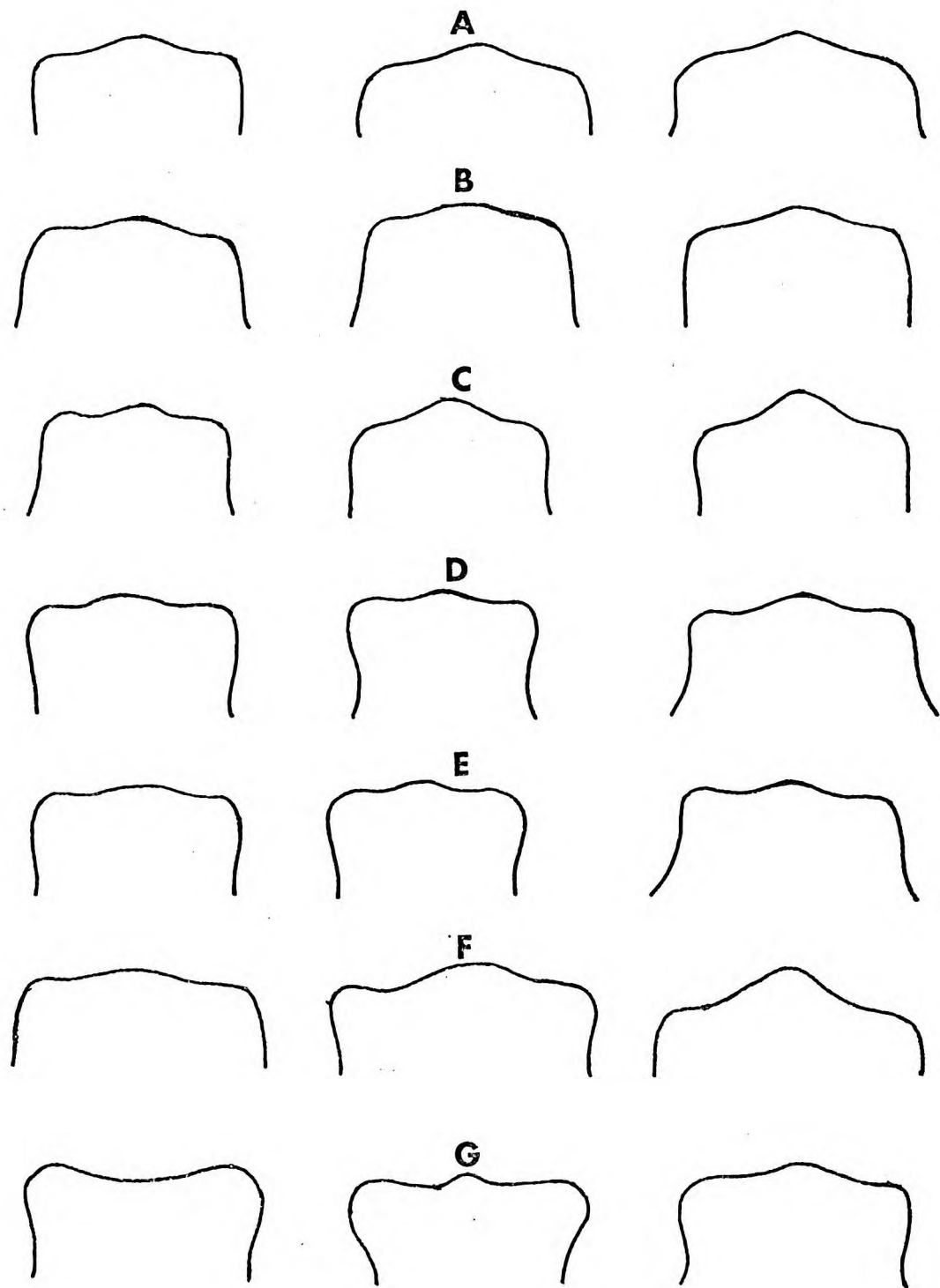


Figure 2.

Figure 2. Cross sections through the muzzles of  
adult male baboons from different localities.

---

From left to right at levels of M1, M2, and M3  
respectively.

- A. Zambezi Valley.
- B. Chipinga, Rhodesia.
- C. Magaliesberge.
- D. South West Africa.
- E. Riversdale, Cape Province.
- F. Murahwas Kraal, Umtali.
- G. Fern Valley, Umtali.



The zygomatic bones have maxillary, frontal and temporal processes. The zygomaticomaxillary sutures extend from middle of the inferior orbital margins to the alveolar buttresses of the maxillae. The zygomatic bones are roughly quadrangular and may face ventrally (Figure 3 A,B,C and D). The ventrolateral facing type give an almost Mongoloid appearance to the facial skeleton. Large foramina for the zygomaticofacial branches of the maxillary nerves occur on the cranial portion of the zygomatic bones. Bony canals connect these foramina with grooves in the lateral and caudal angles of the orbital cavities.

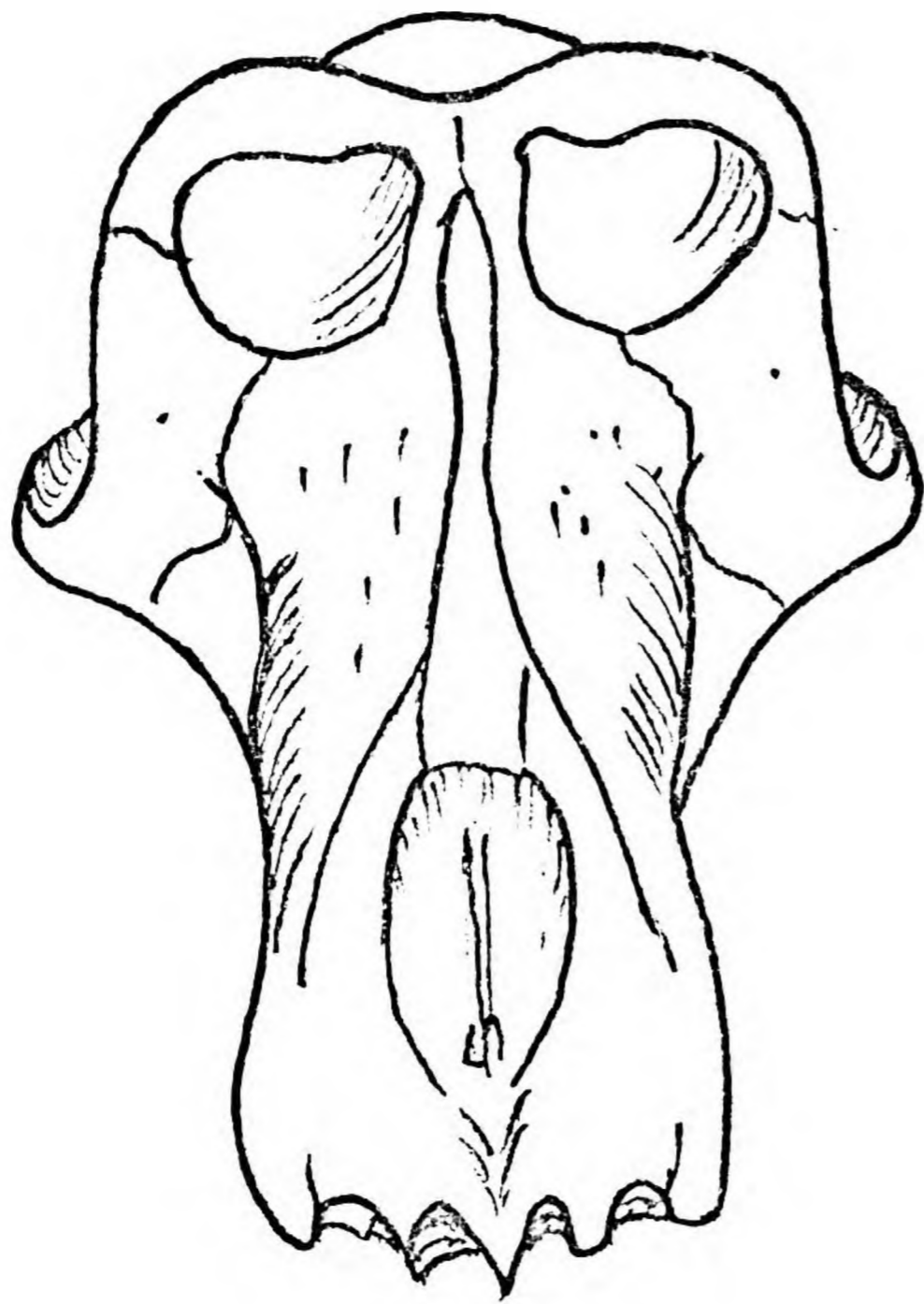
The frontal processes pass dorsally to form the lateral and ventral margins of the orbital cavities. Foramina for the zygomaticotemporal branches of the maxillary nerves occur either at the dorsal extremities of the frontal processes or in the frontozygomatic sutures.

The temporal processes are large strong processes passing dorsally and laterally to articulate with the zygomatic processes of the temporal bones. Their caudal surfaces are grooved or roughened for the attachment of the masseter muscles.

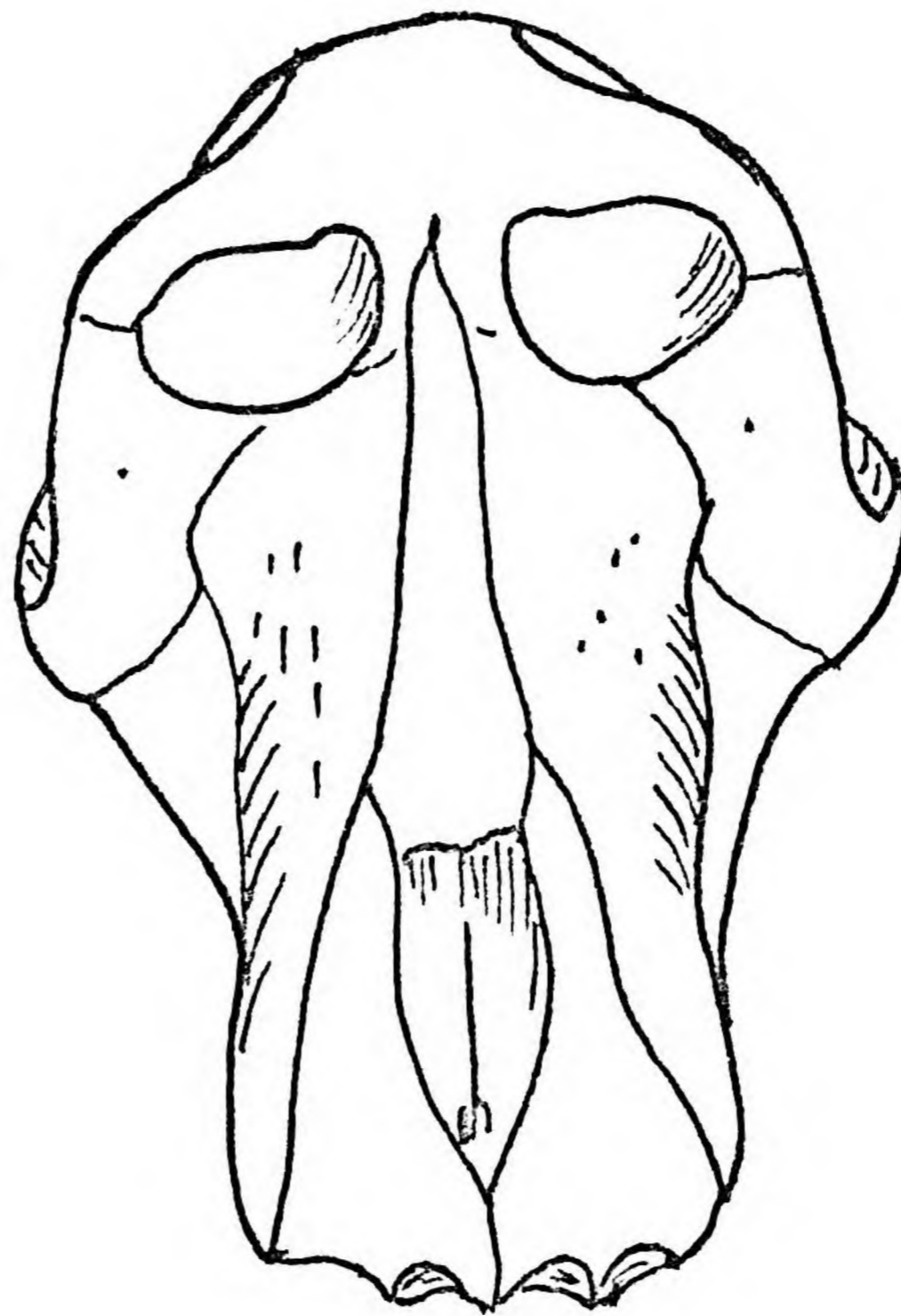
The bony margins of the orbital cavities vary in size, shape and composition (Figure 4). The margins face ventrally and may be round (Figure 4.A,B,C and D) or roughly quadrangular (Figure 4 E,F, and G). In some specimens the caudal margins are rounded whereas in others angulations occur at the zygomaticomaxillary sutures or slightly more laterally.

The ventral margins of the orbital cavities consist of the following bones: cranially, frontal bones; laterally, the zygomatic processes of the frontal bones and the frontal processes of the zygomatic bones; medially, the nasal processes of the frontal bones - cranially and the lacrimal zygomatic bones - caudally. In some specimens the lacrimal bones do not emerge from the medial orbital wall and the maxillae then form the caudal part of the medial margin (Figure 4 C and F). In specimens with flared maxillary ridges the paranasal grooves extend dorsally to the ventral surfaces of the orbital margins.

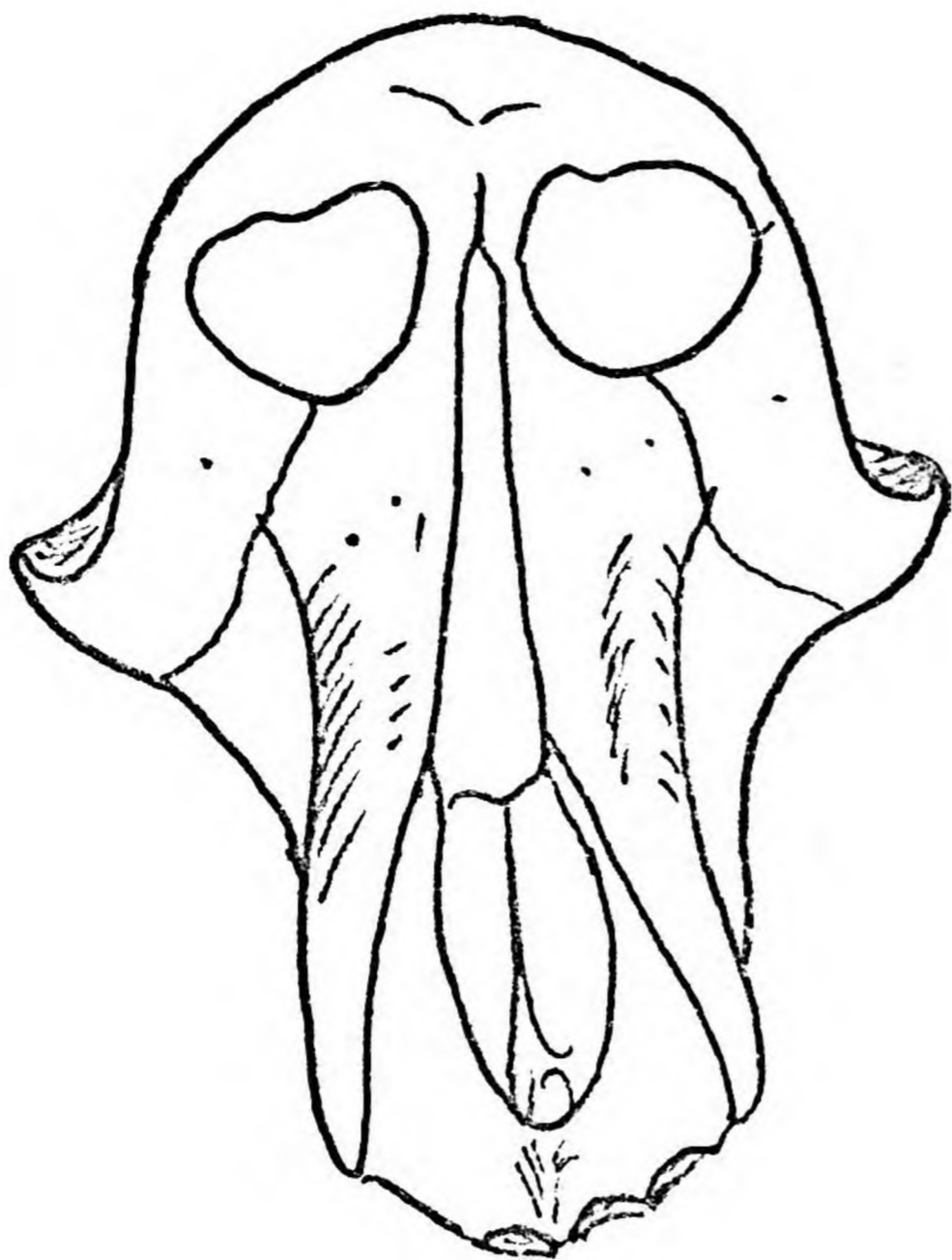
The cranial margins of the orbital cavities are notched medially for the passage of the frontal nerves. The lateral ends of these



**E**

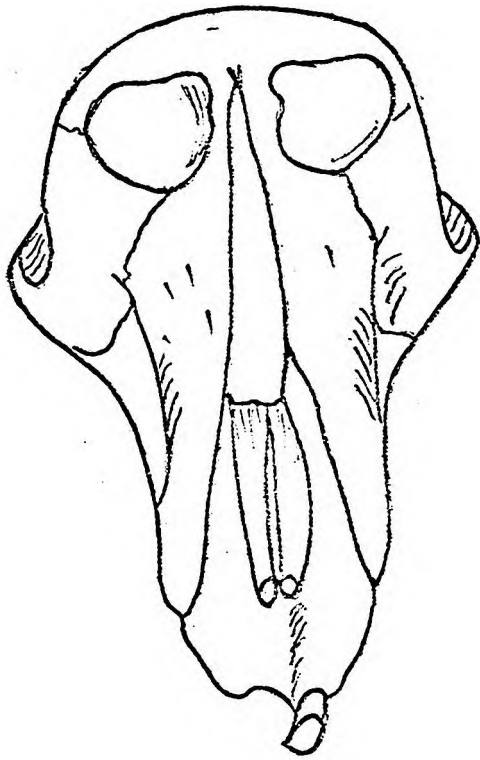


**F**

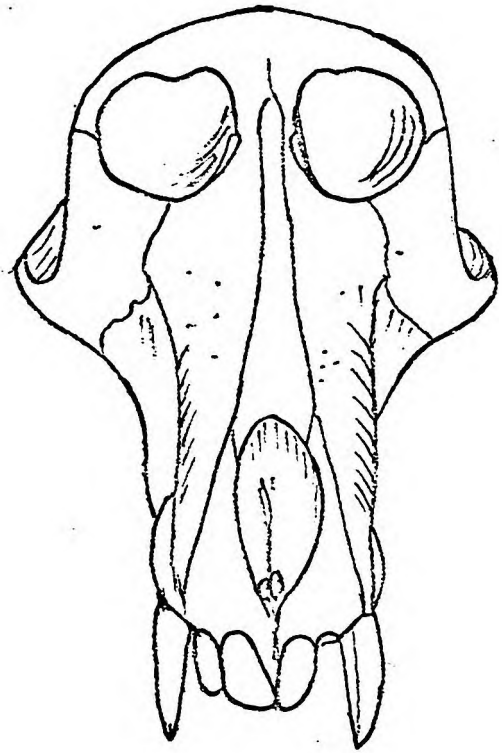


**G**

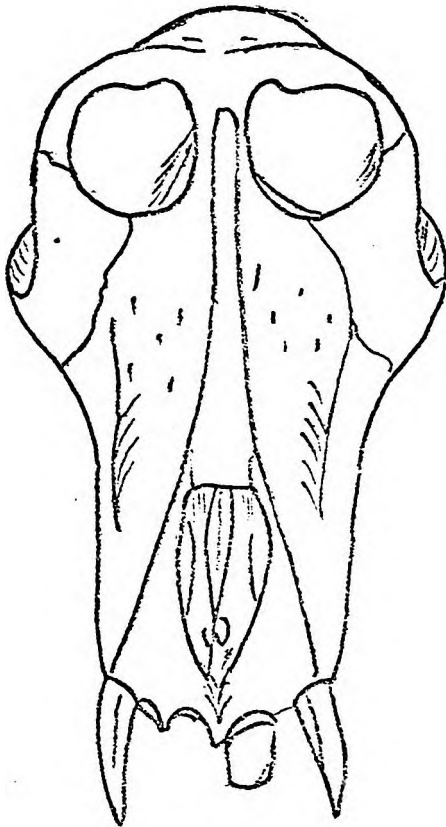
Figure 3.



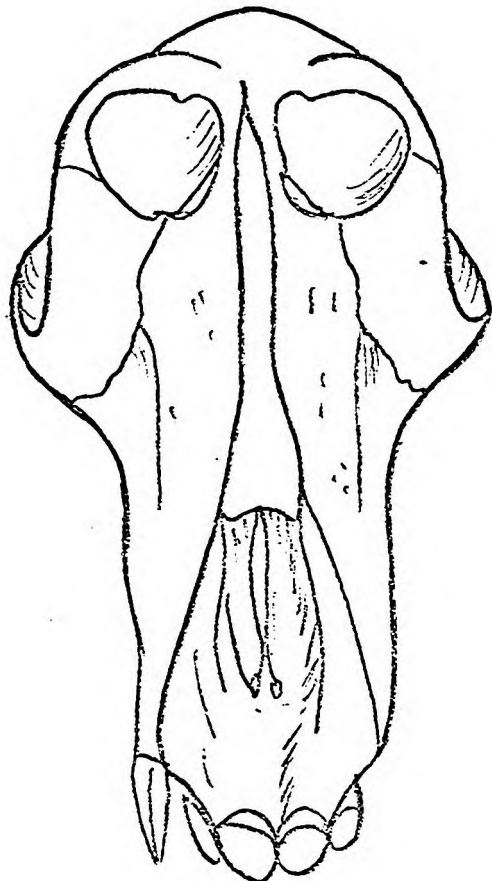
**A**



**B**



**C**



**D**

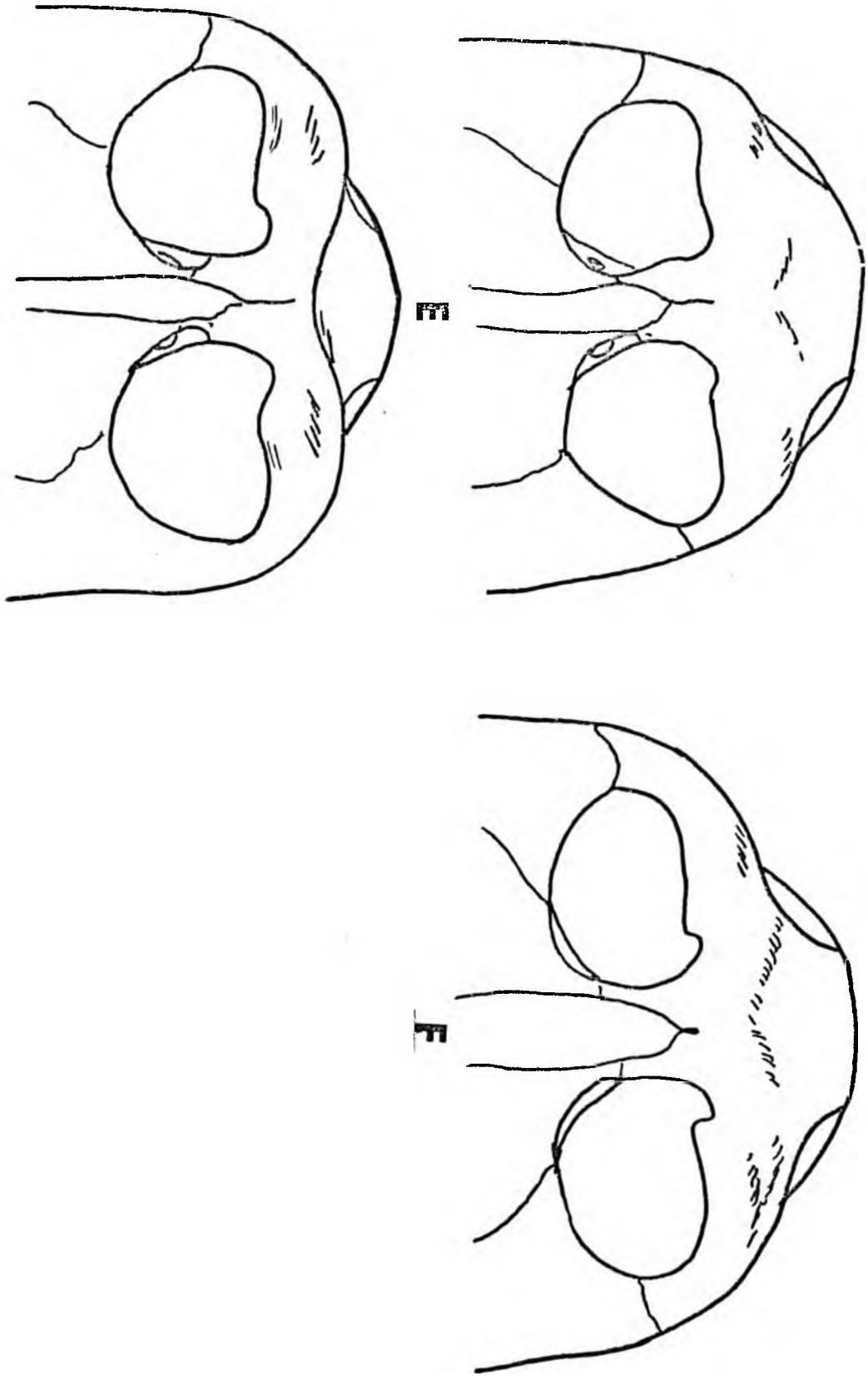
Figure 3.

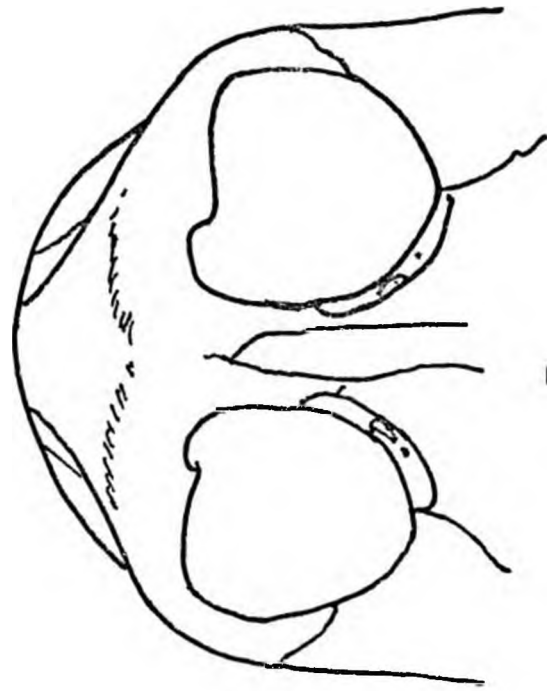
Figure 3. Norma facialis of 7 adult male baboon crania  
from known localities.

---

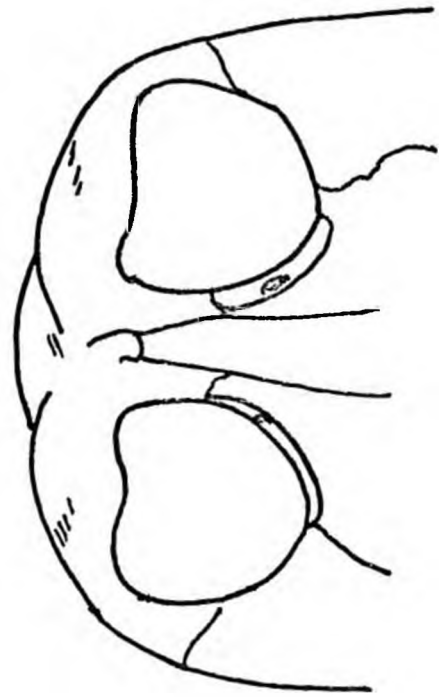
- A. Oamites, South West Africa.
- B. Magaliesberge,
- C. Zambezi Valley.
- D. Chipinga, Rhodesia.
- E. Fern Valley, Umtali.
- F. Murahwas Kraal, Umtali.
- G. Riversdale, Cape Province.

Figure 4.

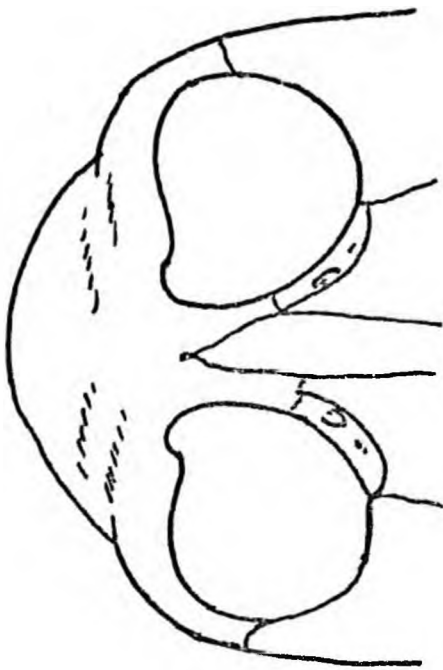




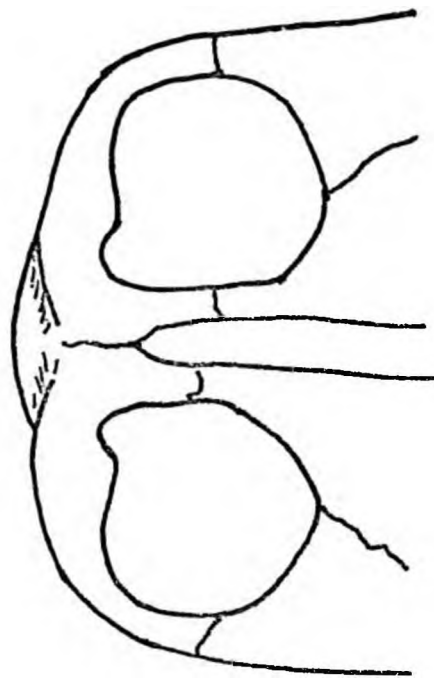
B



D



A



C

Figure 4.

Figure 4. Orbits and supraorbital regions of adult male baboons from known localities. (Natural size)

- A. Chipinga, Rhodesia.
- B. Zambezi Valley.
- C. Magaliesberge.
- D. Oamites, South West Africa.
- E. Riversdale, Cape Province.
- F. Murahwas Kraal, Umtali.
- G. Fern Valley, Umtali.

notches may be rounded or present small spicules. Each orbital cavity is roughly cone shaped (Figure 5). The optic foramen forms the apex of the cone and the orbital margin forms the base of the cone. The axis of the cone lies in a ventrolateral direction and faces slightly cranially. The cranial half of the orbital cavity, for the greater part, is made up of the frontal bone. The orbitosphenoid contributes a small area dorsally, around the optic foramen. The caudal half of the orbital cavity is divided into medial and lateral parts of the caudal orbital fissure. The medial part consists of the orbitosphenoid dorsally, the lacrimal bone ventrally and the orbital surface of the vomer filling in the area between these bones. The orbital plates of the vomer were erroneously identified as part of the ethmoid by Freedman (1957). The lateral part is made up of alisphenoid dorsally and zygomatic bone ventrally.

The lacrimal gland occupies a deep fossa in the craniolateral angle of the orbital cavity. Foramina for the anterior and posterior ethmoidal nerves and vessels are found on the medial wall of the orbital cavity formed by the frontal bone. A craniocaudally directed ridge, for the attachment of the orbital fascia, divides the ventral portion of the orbitonasal process of the frontal bone into orbital and nasal surfaces.

The lacrimal bone lies between the frontal bone cranially, the vomer dorsally, the maxillae ventrally and extends to the inferior orbital fissure where it forms the medial wall of the infraorbital foramen. It presents a large fossa and canal for the nasolacrimal sac and duct and lateral to this major canal are one or two small canals for accessory nasolacrimal ducts. The nasolacrimal duct and the accessory duct open into the craniodorsal aspect of the inferior nasal meatus.

The caudal orbital fissure extends ventrally as an open 'V' from the cranial orbital fissure and divides the floor of the orbital cavity into medial and lateral parts. Ventrally the fissure is continuous with the infraorbital sulcus, the floor of which is formed by the dorsocranial part of the maxilla.

Dorsally, corresponding to the superior orbital fissure in man, is a triangular opening bounded by the body of the sphenoid medially,



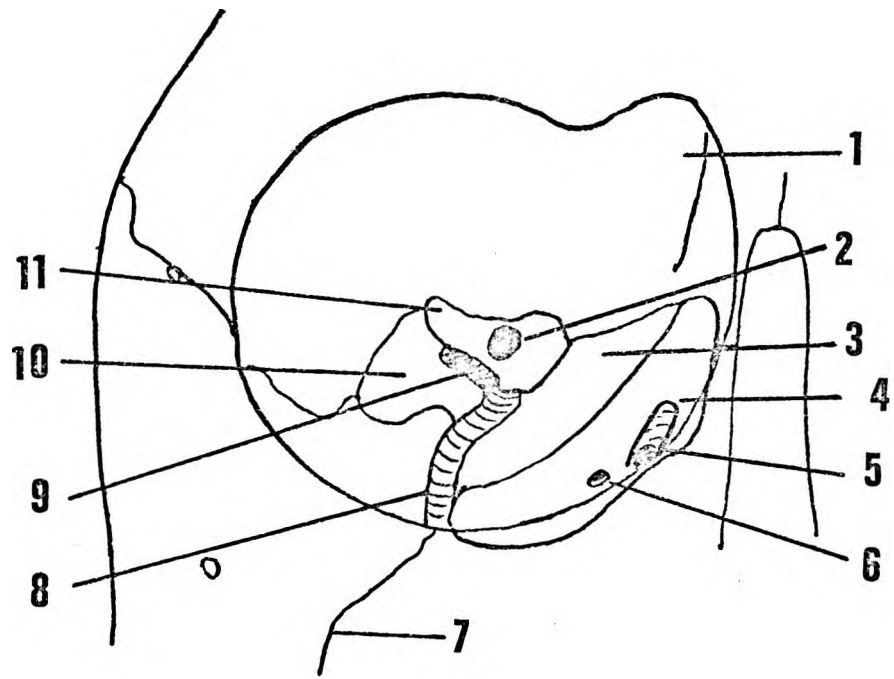


Figure 5.

Figure 5. Ventral aspect of the right orbital cavity.

1. Frontal bone.
2. Optic foramen.
3. Vomer.
4. Lacrimal bone.
5. Nasolacrimal duct.
6. Accessory duct.
7. Zygomaticomaxillary suture.
8. Infraorbital canal.
9. Inferior orbital.
10. Alisphenoid.
11. Orbitosphenoid.

the orbitosphenoid cranially and the alisphenoid caudolaterally. The foramen for the optic nerve is situated cranially and medially to this triangular opening.

The triangular opening is the dorsal component of the long caudal orbital fissure - dorsally it is continuous with the cranial cavity, ventrally with the orbital cavity, caudally with the nasal cavity, and caudolaterally with the 'pterygopalatine' fissure. This is not a 'pterygopalatine' fissure but rather a pterygomaxillary fissure since the palatine bone of the baboon does not extend cranially to participate in the formation of the walls of the fissure. The foramen rotundum and opening of the pterygoid canal communicate with the pterygomaxillary fissure dorsally. The contents of the pterygomaxillary fissure are :

1. Cranially 3-4 branches of the maxillary nerve.
2. The sphenopalatine ganglion suspended from the most caudal branch of the maxillary nerve.
3. The infraorbital branches of the maxillary artery, veins and fat.

The infraorbital canal and sulcus become narrower with age.

The supraorbital torus consists of medial and lateral portions. The medial portion corresponds with superciliary ridges in man and forms a 'V' shaped elevation cranial to the nasal process of the frontal bone. From the apex of the 'V' the glabella, the superciliary ridges extend dorsolaterally.

The lateral portions are formed by the cranial orbital margins and the zygomatic processes of the frontal bone. These lateral portions are the supraorbital ridge and show considerable variation. In specimens with large ventral orbital apertures they are poorly developed but in crania with smaller orbital apertures they are well developed and project ventrally and laterally to give such specimens a beetle-browed appearance (Figure 4. A to G).

The superciliary and supraorbital ridges are usually separated by distinct supraorbital grooves. Again, there is considerable variation among specimens. Those with large orbital apertures have confluent superciliary ridges and small supraorbital grooves (Figure 4, A,B,C, and D) whereas in those specimens with beetle-brows and small orbital apertures there are distinct supraorbital grooves (Figure 4. E,F and G).

Norma lateralis (Figure 6.)

In this profile a ventral facial portion, and a dorsal neurocranial part i.e., cranial to the zygomatic arch can be distinguished. The facial portion is formed by the premaxilla, maxilla, nasal, zygomatic and frontal bones. The neurocranium is formed by the frontal and parietal bones cranially with the alisphenoid, the squamous part of the temporal and occipital bones caudally. The basicranium is formed by the dorsal portion of the maxilla separated from the lateral pterygoid plate by a wedge of palatine bone, the petrous and mastoid parts of the temporal bone, and the basioccipital, occipital and nuchal portions of the occipital bone.

The facial portion: the premaxilla, the maxilla, the nasal bone, the orbits and the zygomatic bones.

The premaxilla bears the incisors. The medial incisor is larger than the lateral and has a larger alveolar process. A wide diastema separates the premaxilla from the maxilla. A thin lamina dura is interposed between the canine and the premaxillamaxillary suture.

As in norma facialis it is seen that the maxilla forms the greater part of the facial skeleton. However, its separate processes are more obvious. The canine alveolus is large and becomes continuous with the maxillary ridge. Dorsal to the canine the alveolus for the premolars and molars gradually enlarges to join the large zygomatic buttress cranial to the third molar.

The maxillary ridge and maxillary fossa are grooved by infraorbital sulci leading from the infraorbital foramina. The boundaries of the maxillary fossa are well defined in this norma. The lateral portion of the zygomaticomaxillary suture is often roughened.

The zygomatic bone forms the dorso cranial part of the face. All its processes are large. The zygomaticofacial and zygomaticotemporal foramina are easily identified. The latter frequently occurs in the frontozygomatic suture. The caudal surface of the zygomatic bone and its temporal process are grooved or roughened for the attachment of the masseter muscles. The temporal fascia is attached to the dorsal edge of the zygomatic bone and its frontal and temporal processes.

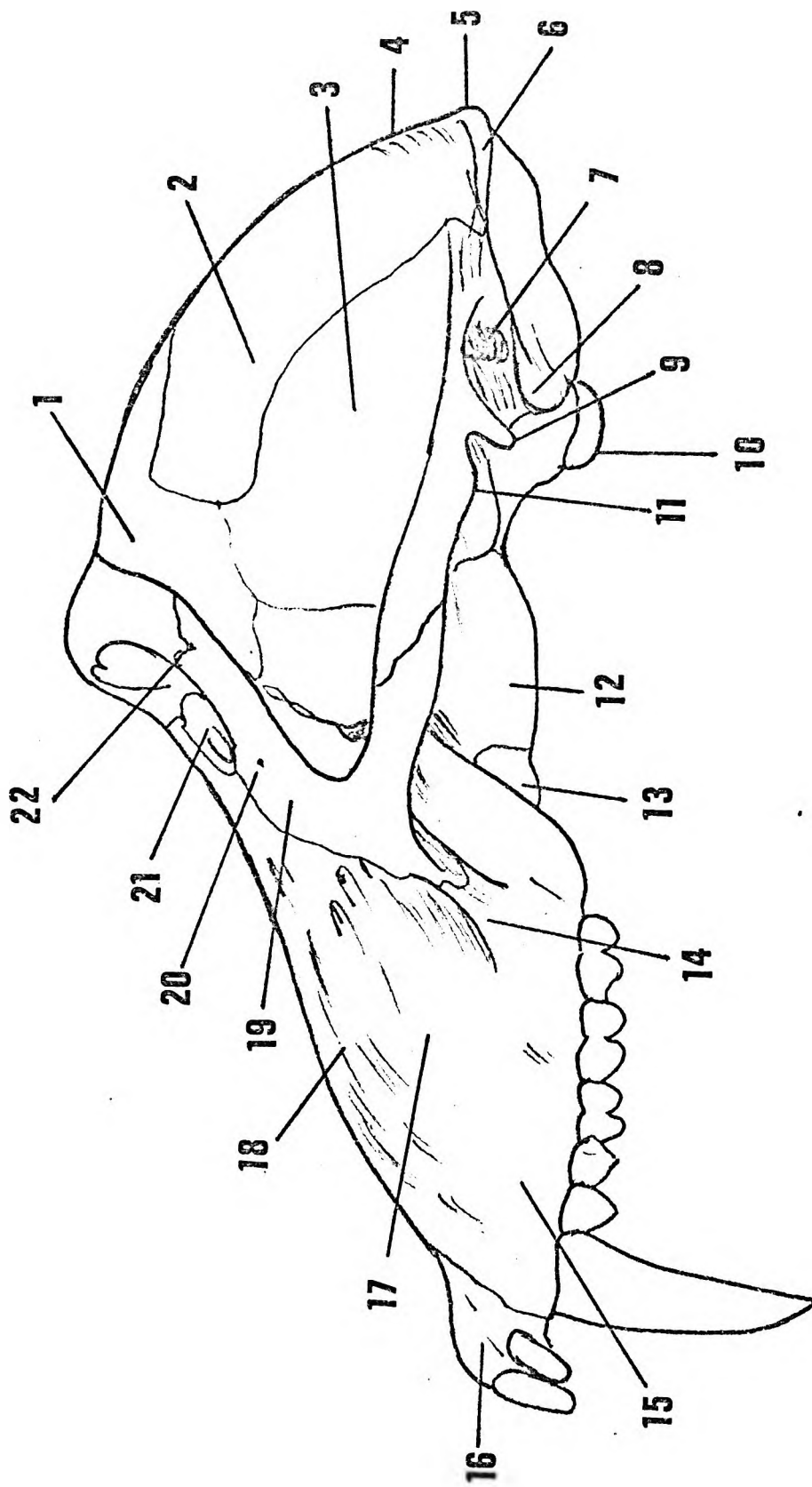


Figure 6.

Figure 6. Norma lateralis.

1. Frontal bone.
2. Parietal bone.
3. Temporal bone
4. Sagittal crest.
5. Inion.
6. Nuchal crest.
7. External auditory meatus.
8. Mastoid area.
9. Postglenoid tubercle.
10. Occipital condyle.
11. Articular tubercle.
12. Lateral pterygoid plate.
13. Palatine bone.
14. Lateral buttress.
15. Maxilla.
16. Premaxilla.
17. Maxillary fossa.
18. Medial buttress.
19. Zygomatic bone.
20. Zygomaticofacial foramen.
21. Lacrimal bone.
22. Zygomaticotemporal foramen.

The orbit and supraorbital torus form the cranial part of the face with the nasal process of the frontal bone, the nasal bone and the frontal process of the maxilla in the midline.

The medial wall of the orbit is masked by the zygomatic process of the frontal bone and the frontal process of the zygomatic bone. Despite this the lacrimal bone and fossa for the nasolacrimal duct are visible. The nasal bone extends ventrally from the medial orbital margin as a narrow wedge.

#### The neurocranium.

The neurocranium consists of frontal and parietal bones cranially, alisphenoid and the squamous part of the temporal bone caudally and the squamous part of the occipital bone dorsally. Except for a triangular area medially between the superior temporal lines, this part of the neurocranium is covered by the temporal muscle and temporal fascia. Caudally the neurocranium is limited by the zygomatic arch ventrally and supramastoid and nuchal crests dorsally. This area together with the dorsal concavity of the zygomatic bone forms the temporal fossa.

The parietal, frontal and temporal bones form a convex floor to the temporal fossa but ventrally the alisphenoid and zygomatic bones form a concavity. The temporal lines extend dorsally and medially from the dorsal edge of the zygomatic process of the frontal bone. The superior temporal line to which the temporal fascia is attached is less distinct, whereas the inferior line is well marked by the attachment of the temporal muscle. Both lines may eventually meet in the midparietal region to form a sagittal crest over the interparietal suture.

The zygomatic arch is robust and consists of the temporal process of the zygomatic bone and the zygomatic process of the temporal bone. The suture between these processes is oblique and lies approximately in the same plane as the standard horizontal plane. The temporal process extends ventrally from a deep concave base on the squamous part of the temporal bone. From this base the supramastoid crest passes dorsally cranial to the external auditory meatus and becomes continuous with the nuchal crest. The nuchal crest is a thick ridge of bone which meets its fellow from the opposite side of the midline at the inion.

The temporal fascia is attached to the cranial margins of the dorsal margin of the zygomatic bone, the cranial margin of the zygomatic arch, the supramastoid crest and the nuchal crest. The temporal muscle arises from the deep surface of the temporal fascia, the floor of the temporal fossa and a bony crest on the dorsal aspect of the zygomatic bone. In dissected specimens it completely covers the lateral aspect of the neurocranium. A roughened area on the lateral aspect of the zygomatic arch defines the attachment of the muscle zygomaticus.

Pterion, the suture pattern made by the adjoining sutures of the frontal, alisphenoid, parietal and squamous temporal bones is approximately H-shape with the cranial limbs divergent. This pattern varies bilaterally and no significant differences are apparent.

A wide, concave cranially, flange of bone connects the zygomatic process of the temporal bone to the squamous part of the temporal bone. This flange gives origin to the temporal muscle cranially and caudally is related to the articular facet of the temporomandibular joint.

The infratemporal fossa lies medial and caudal to the zygomatic arch. It has the following boundaries: ventrally the dorsal surfaces of the maxilla and zygomatic bones; laterally the zygomatic arch and medially the alisphenoid and lateral pterygoid plate. The lateral pterygoid muscle is a short petal-shaped muscle arising from the lateral surface of the lateral pterygoid plate and from the infratemporal surface of the alisphenoid. These attachments are separated from each other by a groove leading to the foramen ovale. The buccal division of the mandibular nerve and the middle meningeal artery occupy this groove. The dorsal end of the groove is often converted into a bony canal by a bridge of bone connecting the lateral pterygoid plate to the base of the alisphenoid. This is the equivalent of the pterygo-alar bar in man (Figure 13). A bony crest separates the lateral head of the lateral pterygoid muscle from the origin of the temporal muscle on the squamous part of the temporal bone.

The pterygomaxillary fissure lies between the dorsal aspect of the maxilla and the alisphenoid. Cranially it is bounded by the junction between the alisphenoid and the zygomatic bone and caudally by the suture between the lateral pterygoid plate and the maxilla.



A triangular wedge of the palatine bone occupies the caudal gap between these bones. A bridge of bone extends forwards from the ventral aspect of the base of the lateral pterygoid plate to divide the fissure into cranial and caudal parts. Freedman (1957) considered that this bridge could develop from either the alisphenoid or the maxilla. Disarticulated crania show, however, that it only develops from the alisphenoid.

The infraorbital vessels enter the cranial compartment of the pterygomaxillary fissure. Branches of the sphenopalatine ganglion occupy the caudal compartment. The middle and posterior palatine nerves pass caudally in a deep groove formed between the maxilla ventrally and the alisphenoid dorsally.

The postglenoid tubercle is a large caudoventrally directed projection dorsal to the articular facet and articular tubercle. A deep groove separates it from the external auditory meatus. The external auditory meatus faces dorsolaterally. It is often incomplete dorsally and is wedged in between the supramastoid crest and the mastoid area.

The mastoid area is large and has two prominences. The more medial prominence faces ventrocaudally dorsal to the external auditory meatus, and has a lateral ridge which becomes continuous dorsally with the nuchal crest. The sternocleidomastoid muscle has a 'comma' shaped attachment medial to the ridge. The lateral prominence lies more dorsally and is a triangular roughened area between the supramastoid crest and the crest from the medial prominence.

A narrow tongue of parietal bone 'the mastoid angle' projects ventrally between the squamous and mastoid portions of the temporal bone to reach the dorsal aspect of the mastoid process. Two foramina for mastoid emissary veins are present, one on the lateral mastoid prominence and the other at the tip of the mastoid angle. Foramina for parietal emissary veins are absent.

The nuchal crest extends dorsomedially to inion. Laterally, it lies on the parietooccipital suture but as it approaches inion it lies caudal to this suture. As the nuchal crest approaches inion it may remain as a single crest or may bifurcate to send a cranial limb towards the superior sagittal crest.

The profile of the occipital bone varies. Inion will be described in *norma occipitalis*. From inion the occipital squama passes caudo-ventrally to the foramen magnum. Its outline in this profile is affected by the degree of development of the external occipital crest. This crest, when well developed, obscures the cerebellar fossae, and gives a straight outline.

The occipital condyles usually project below the level of the most caudal part of the occipital squama but in a few specimens they are nearly on the same level.

The styloid process is a small bony spike ventral to the occipital condyles. Ventral to the styloid process is the larger bony spike of the petrous temporal bone, for the attachment of the sphenomandibular ligament.

In *norma lateralis* profiles of the crania of seven adult baboons from known areas, demonstrate many variations (Figure 7). The pre-maxillomaxillary region is usually a gentle ventral convexity but in some specimens the alveolus for the medial incisor has an accentuated dorsal convexity which gives the muzzle a 'tip tilted' appearance in this region (Figure 7. B and D).

The various maxillary ridges of the muzzle, too, are apparent in this view. The flared type of ridge reaches its greatest height at the level of the dorsal margin of the nasal aperture giving the muzzle a 'hooked nose' appearance (Figure 7 A,D,E and G). The less well developed type of ridge attains its maximum development dorsal to the level of the nasal aperture and the muzzle then has a gentle cranial convexity (Figure 7 B and C). The depth of the different maxillary fossae is also apparent. There is a great variation of the profile of the face ventral to glabella. This variation is produced by the degree of concavity of the frontonasal area. In some specimens this concavity is so slight that the nose has a nearly straight profile as in Parapapio, (Jones, 1937). In others the outline is markedly concave. In the former type a considerable area of the medial orbital wall is visible whereas in the latter type the medial orbital wall is practically obscured.

The zygomatic bones may be directed ventrally or ventrolaterally. Ventral facing zygomatic bones are associated with less robust frontozygomatic and zygomaticofrontal processes. In such specimens the orbital

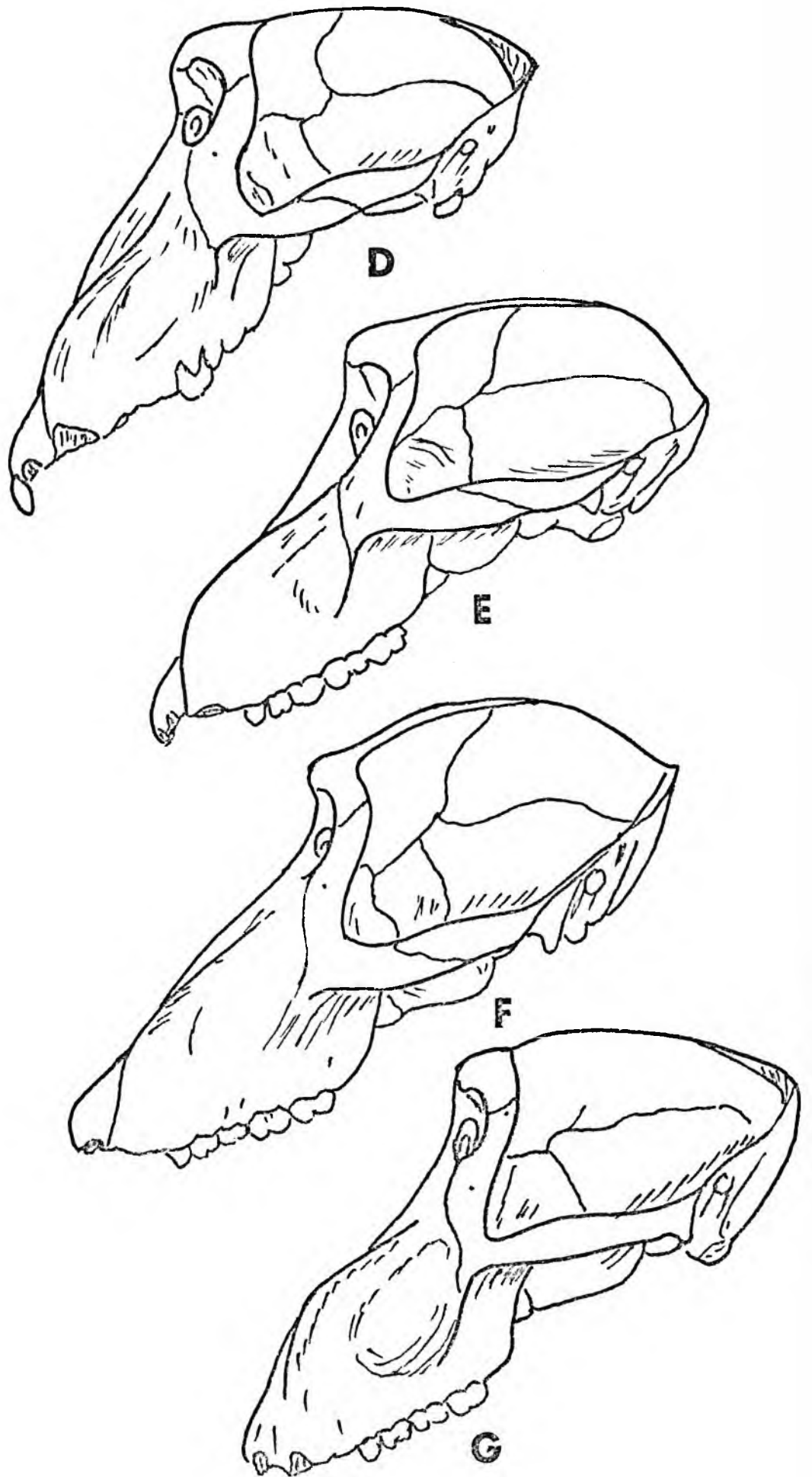


Figure 7.

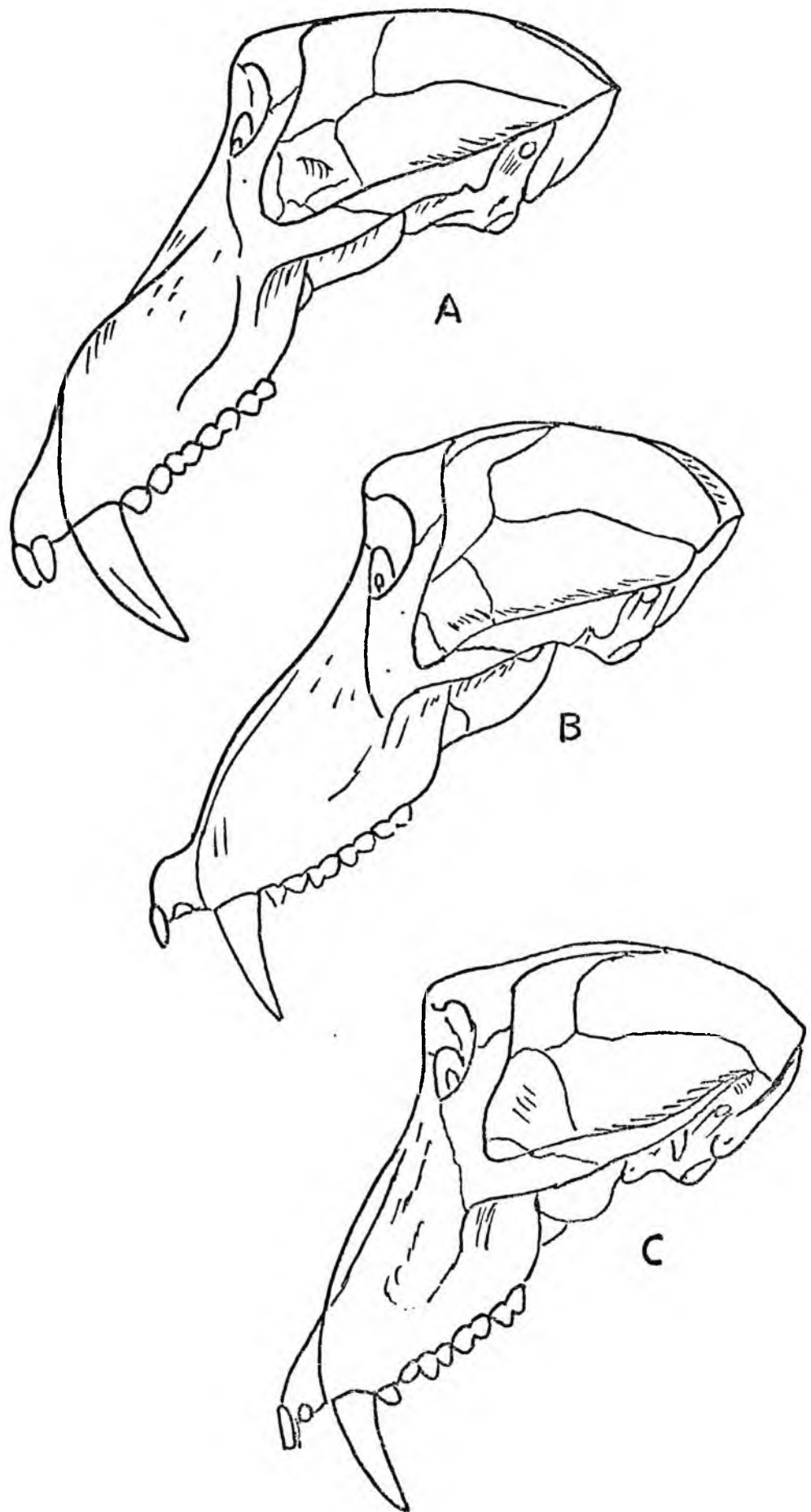


Figure 7.

Figure 7. Norma lateralis of the crania of 7 adult male baboons from known localities ( $\frac{1}{2}$  Natural size).

- A. Chipinga, Rhodesia.
- B. Zambezi Valley.
- C. Magaliesberge.
- D. Oamites, South West Africa.
- E. Riversdale, Cape Province.
- F. Murahwas Kraal, Umtali.
- G. Fern Valley, Umtali.

margin is larger, and the medial wall of the orbit more exposed. Ventrolateral facing zygomata have more robust processes which not only obscure more of the medial orbital wall but form a larger supra-orbital torus.

The angle formed by the frontal and temporal processes of the zygomatic bone also varies. In specimens in which the zygomatic bone is directed ventrolaterally this angle is obtuse (Figure 7. D,E,F and G) whereas in the specimens in which the zygomatic bone is directed ventrally this angle is acute. In addition the bony crest on the dorsal aspect of the frontal process of the zygomatic bone is larger in some specimens (Figure 7. D,E,F and G).

A postorbital groove interrupts the curve of the neurocranium ventrally. The depth of this groove is dependent on the degree of development of the superciliary and supraorbital ridges and is marked in specimens with large ridges.

Dorsally the profile of the neurocranium is modified by the development of the sagittal crest, which in turn is dependent on the development of the superior and inferior temporal lines. The height of the temporal lines varies and influences the development of a sagittal crest. Cranially placed superior temporal lines are associated with well developed crests, and occur in specimens with straight nasofrontal profiles, large ventral orbital apertures, small rounded maxillary ridges, shallow maxillary fossae and ventrally facing zygomatic bones with slender zygomatic processes. In these specimens the superior temporal lines meet near bregma to form a large crest which extends dorsally to inion. More caudally placed temporal lines do not meet in midline to form a sagittal crest. Such specimens usually have concave nasofrontal profiles, smaller ventral orbital apertures, large scrolled maxillary ridges, deep maxillary fossae and large ventrolaterally directed zygomata.

#### Norma occipitalis (Figure 8 and 9).

In this norma the profile of the neurocranium is partially obscured by the zygomatic arches laterally and the zygomaticofrontal and frontozygomatic processes cranioventrally

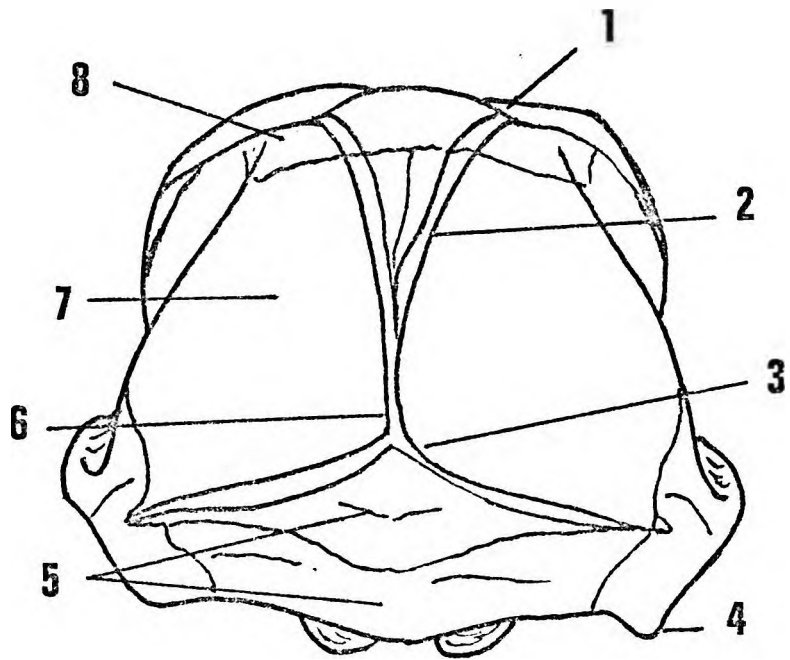
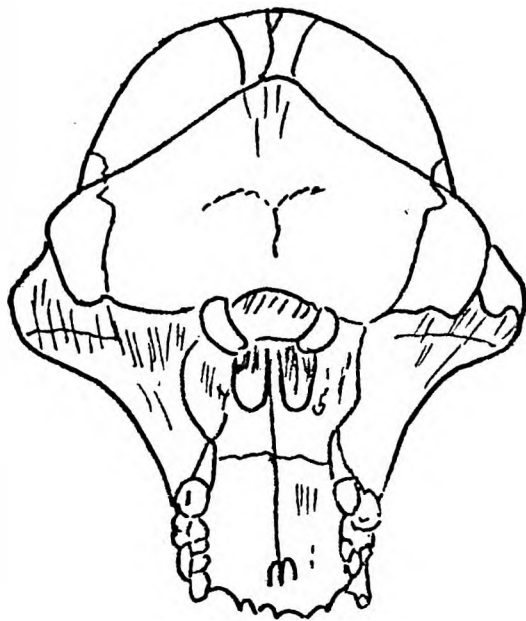


Figure 8.

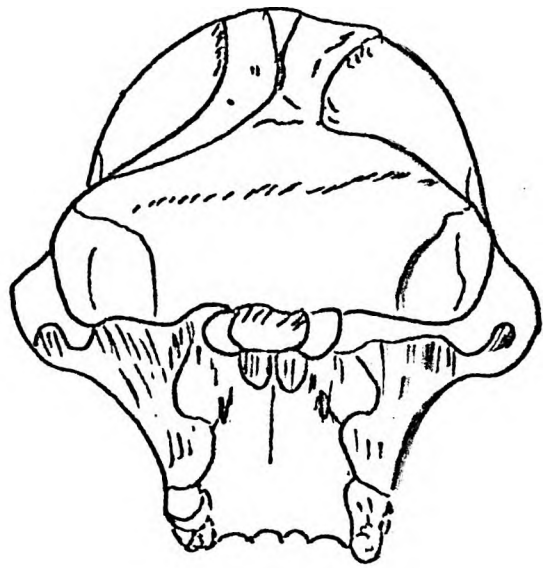
Figure 8. Norma occipitalis.

1. Superior temporal line.
2. Inferior temporal line.
3. Inion.
4. Mastoid area.
5. Nuchal surface.
6. Sagittal crest.
7. Parietal bone.
8. Frontal bone.

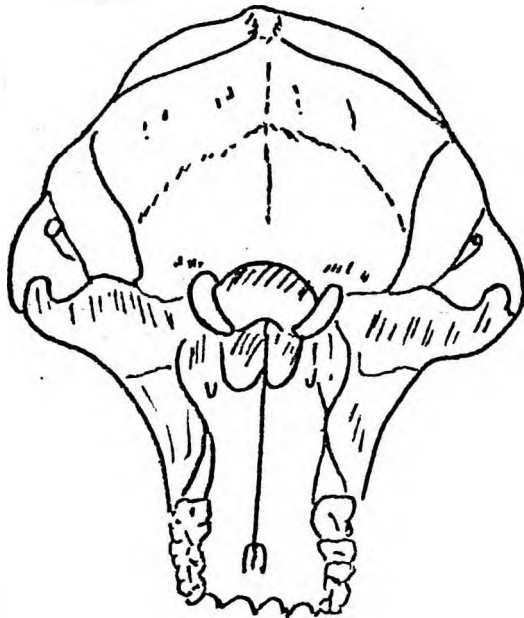




**E**

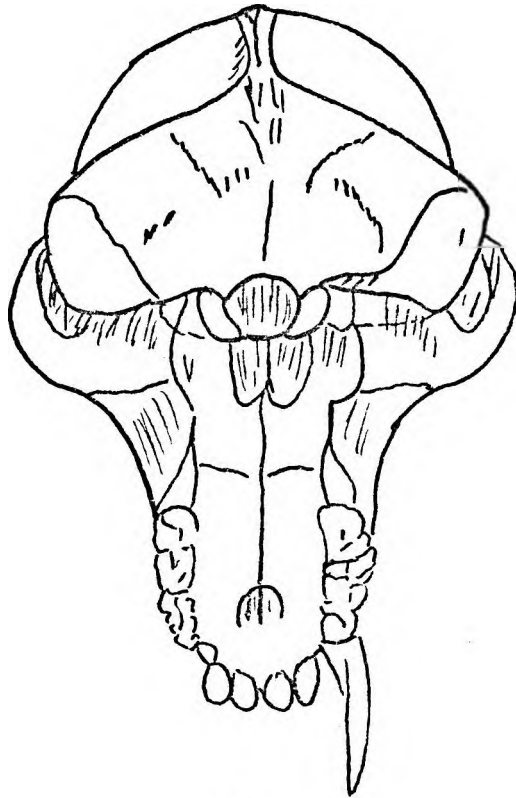


**F**

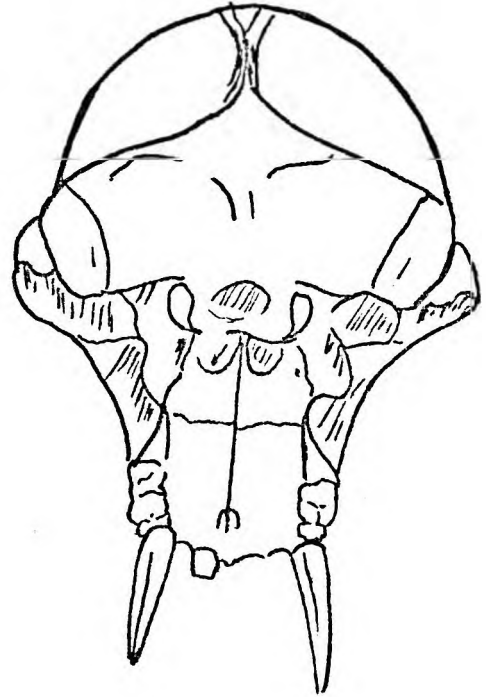


**G**

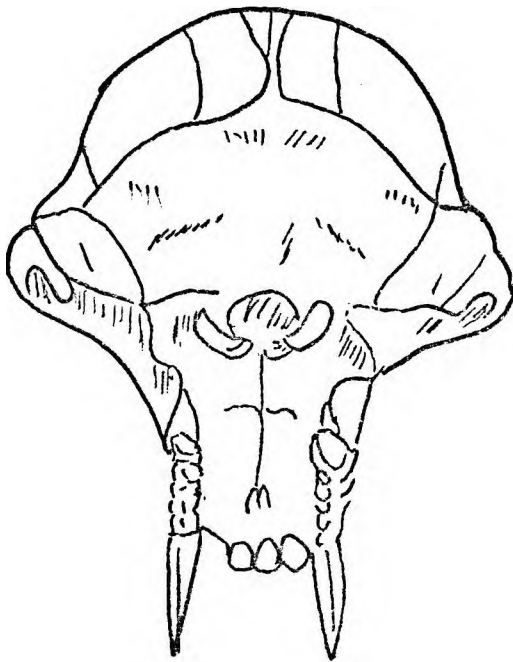
Figure 9



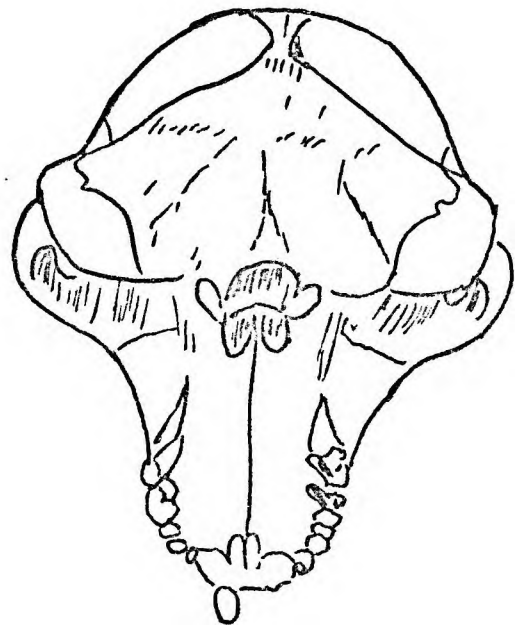
**A**



**B**



**C**



**D**

Figure 9.

Figure 9. *Norma occipitalis* of the crania of 7 adult male baboons from known localities. ( $\frac{1}{2}$  Natural Size).

---

- A. Chipinga, Rhodesia.
- B. Zambezi Valley.
- C. Magaliesberge.
- D. Oamites, South West Africa.
- E. Riversdale, Cape Province.
- F. Murahwas Kraal. Umtali.
- G. Fern Valley, Umtali.

Cranial to the nuchal crests the frontal, parietal and squamous parts of the temporal bones form an arch. This arch is divided into a medial portion and right and left lateral portions by the inferior temporal lines.

The medial segment is triangular and ends in the midparietal area where both temporal lines unite to form a sagittal crest. The superior temporal lines are less distinct than the inferior but follow the contour of the inferior lines. A median area covered by the occipitofrontalis muscle, a small area lateral to this covered by the temporal fascia and a large area covered by the temporal muscle can be distinguished.

The median segment is made up of frontal and parietal bones whereas the lateral segments consists of frontal bones ventrally, parietal bones cranially with the squamous parts of the temporal bones occupying the lower thirds. The greatest bi-temporal width cannot be defined since the squamous parts of the temporal bones continue as gentle convexities onto the temporal part of the zygomatic arch. A small portion of the occipital bone lies cranial to the nuchal crest.

Inion, the external occipital protuberance, is formed at the junction of the sagittal and nuchal crests. The shape of inion varies (Figure 8). When the sagittal and nuchal crests are well developed it is a triradiate bony projection. In specimens in which the external occipital crest and sagittal crests are well developed inion has a cruciform appearance. In the majority of specimens, however, it is a triangular bony projection. The shape appears to be dependent on muscular development rather than on age.

Each half of the nuchal crest affords attachment for the temporal fascia cranially. The temporal muscle is attached to the cranial base of the nuchal crest. Caudally, arising from each half of the nuchal crest are more medially the trapezius and laterally sternocleidomastoid muscles. The occipitofrontalis muscle forms a complete muscle sheet under the skin of the scalp. It consists of superficial and deep parts. The superficial part is continuous with platysma colli while the deeper part is attached to inion and to the medial edge of the nuchal crest superficial to the trapezius.

Norma cranialis (Figure 10 and 11).

This norma reveals many features already emphasized in norma facialis, norma lateralis and norma occipitalis. Again the projecting muzzle is a striking feature. The cranium is divided into a ventral facial portion and a dorsal neurocranium by a constriction of the frontal bone at pterion. This post orbital 'waist' is produced by the angulation between the lateral wall of the orbit and the neurocranium.

The facial portion.

In outline it is an approximate quadrangle with the premaxillae forming a rounded ventral end. The zygomatic arches project laterally between the face and neurocranium. In this profile the different types of maxillary ridges, zygomatic bones and brow ridges are seen (Figure 11).

In the baboon the supraorbital or brow ridges clearly consist of the medial superciliary ridges and lateral to these the zygomatic processes of the frontal bone. The superciliary ridges form a wide 'V' shaped eminence. The apex of the 'V' points ventrally and forms glabella cranial to the frontonasal suture. Dorsally the opening of the 'V' becomes continuous with the postorbital groove.

The supraorbital notch on either side leads to supraorbital grooves which separate the superciliary ridges from the zygomatic processes of the frontal bone.

Laterally the zygomatic arches connect facial and neurocranial portions. The cranial surface of the zygomatic arch is sharp and becomes continuous with the supramastoid crest. The zygomatic process of the temporal bone is robust and concave cranially. The floor of the temporal fossa is separated from the medial aspect of the zygomatic arch by a wide gap.

The neurocranium.

In this profile the neurocranium is ovoid with the narrowest part ventrally at the postorbital constriction. The frontal and parietal bones form the greater part of the neurocranium.

The coronal suture slopes dorsally to meet the interparietal suture at bregma. The suture pattern at bregma varies from a 'Y' shape in the narrow muzzled types to an open goblet type in those specimens with flared maxillary ridges.

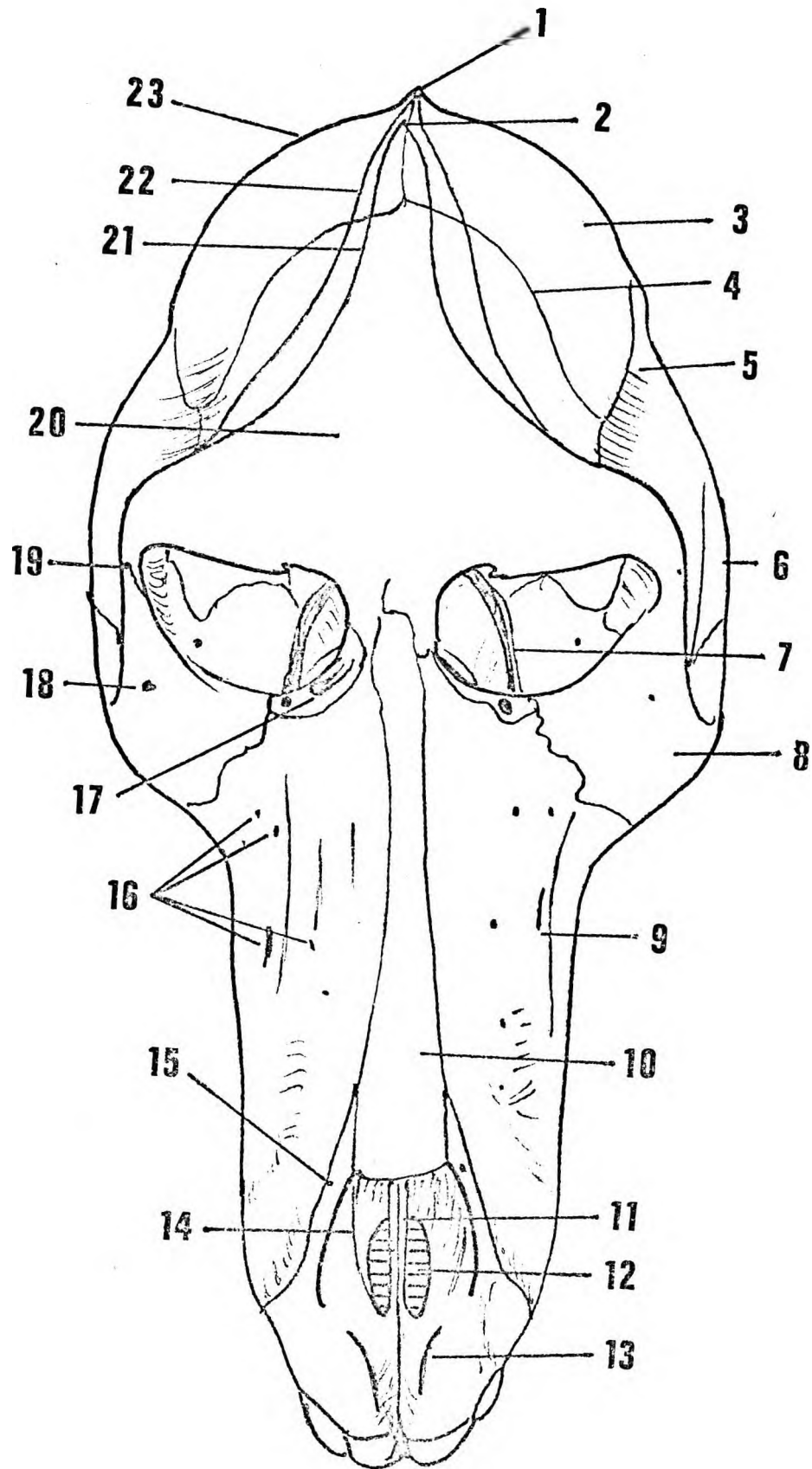
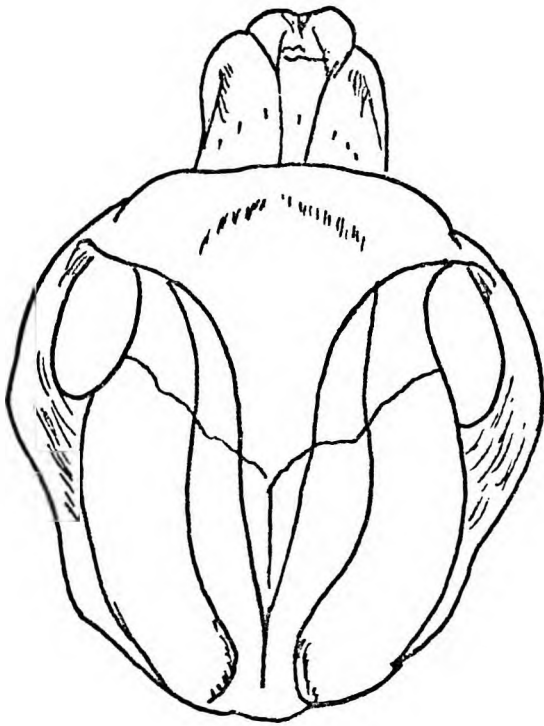


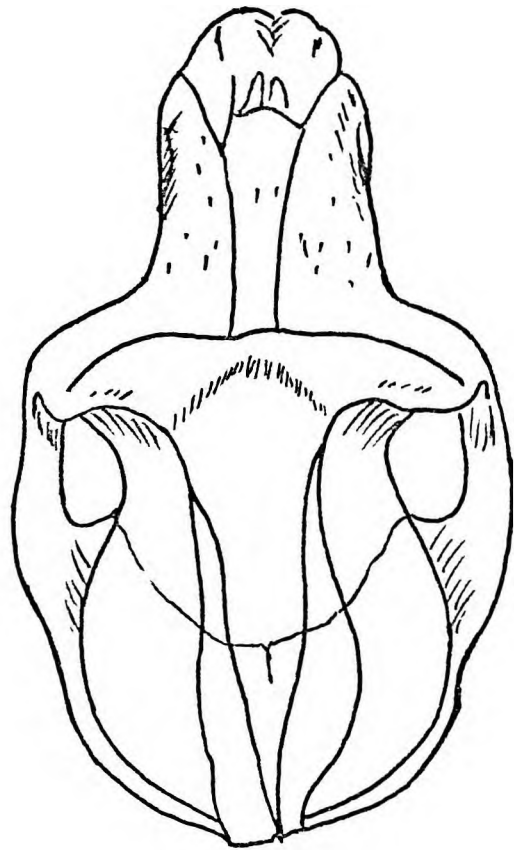
Figure 10.

Figure 10. Norma cranialis.

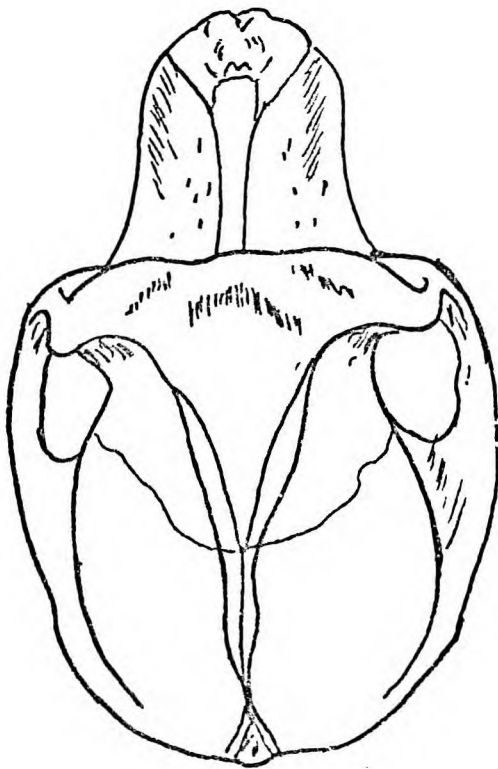
1. Inion.
2. Sagittal crest.
3. Parietal bone.
4. Coronal suture.
5. Temporal bone.
6. Zygomatic arch.
7. Caudal orbital fissure.
8. Zygomatic bone.
9. Maxillary ridge.
10. Nasal bone.
11. Lamina of premaxilla.
12. Incisive foramen.
13. Premaxilla.
14. Nasal aperture.
15. Ext. nasal N. foramen.
16. Infraorbital foramina.
17. Lacrimal bone with nasolacrimal and accessory ducts.
18. Zygomaticofacial foramen.
19. Zygomaticotemporal foramen.
20. Frontal bone.
21. Superior temporal line.
22. Inferior temporal line.
23. Nuchal crest.



E



F



G

Figure 11.



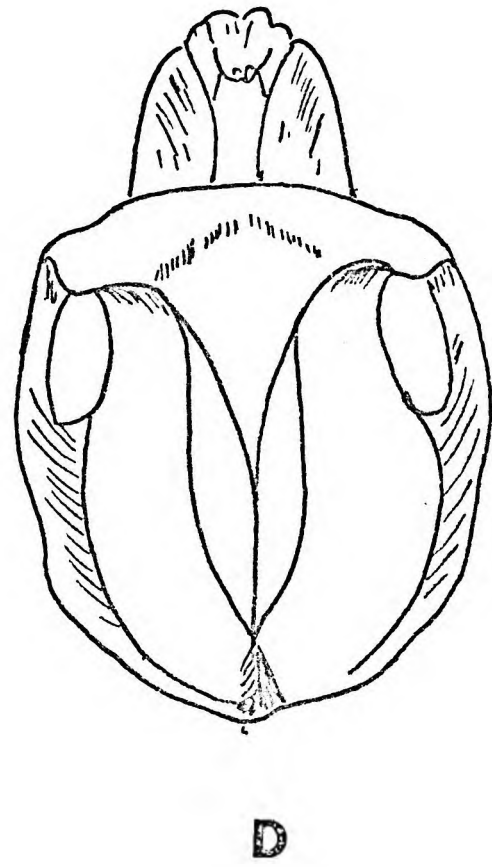
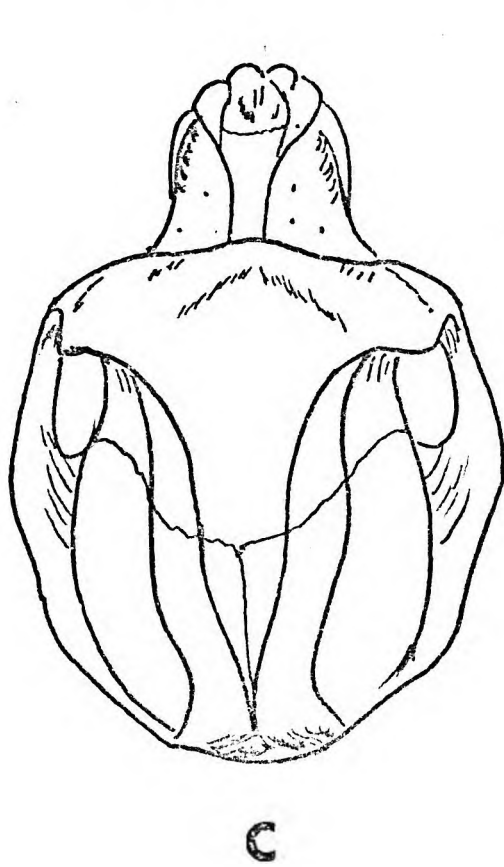
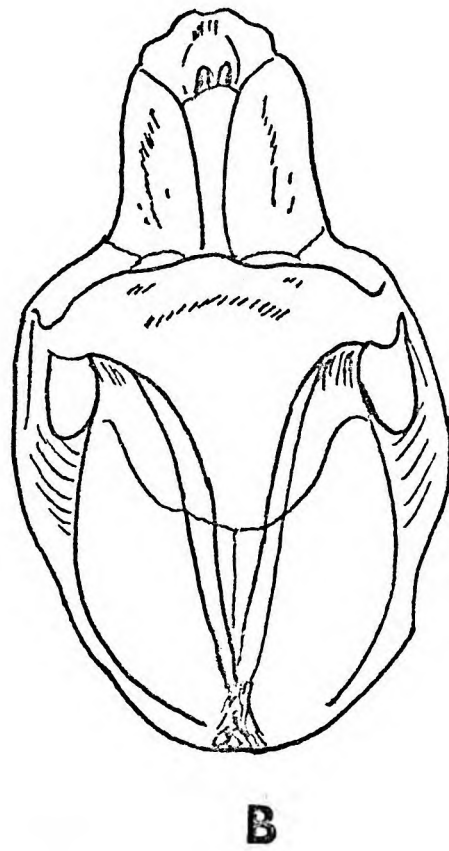
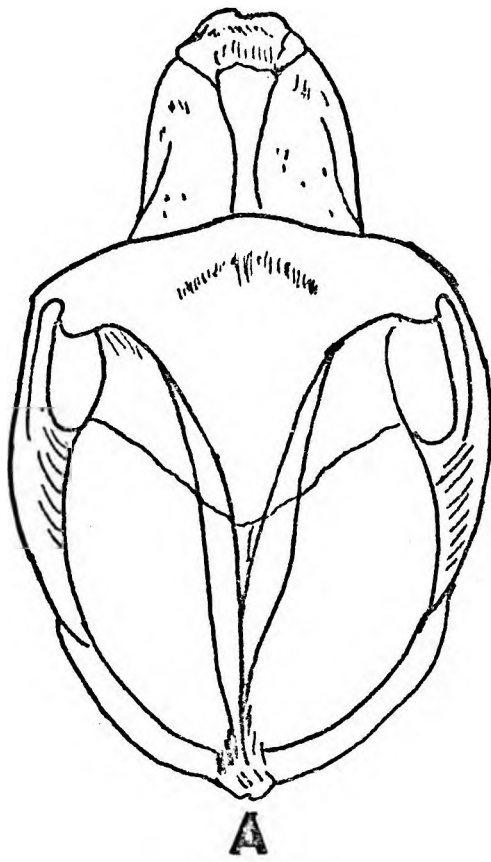


Figure 11.

Figure 11. Norma cranialis of the crania of 7 adult male baboons from known localities. ( $\frac{1}{2}$  Natural Size).

- A. Chipinga, Rhodesia.
- B. Zambezi Valley.
- C. Magaliesberge.
- D. Oamites, South West Africa.
- E. Riversdale, Cape Province.
- F. Murahwas Kraal, Umtali.
- G. Fern Valley, Umtali.

The parietal bones form the dorsal two thirds of the neurocranium and meet at the midline in the sagittal or interparietal suture. Laterally they articulate with the squamous parts of the temporal bones. The squamoparietal suture is almost hidden in this view. The squamous portions of the temporal bones slope laterally and caudally to meet the zygomatic processes of the temporal bones in wide shallow cranial concavities.

The lateral prominences of the mastoid area project laterally on either side dorsal to the external auditory meatuses which are barely visible in this norma.

The temporal lines are prominent. Both commence ventrally at the zygomaticofrontal sutures and pass medially and dorsally. The superior temporal lines enclose between them a smooth area of frontal and parietal bones. The superior temporal lines meet near bregma and continue dorsally as a low sagittal crest. At about the junction of the dorsal and middle thirds of the interparietal suture, the superior and inferior temporal lines meet to form the sagittal crest which continues dorsally to inion.

The crania of seven adult male baboons from known areas reveal many variations in this norma (Figure 11).

The outlines of the premaxillae vary from round to square. The amount of ventral projection of the muzzle varies and depends not only on the length of the muzzle but also on the variability of the prebasal dyphosis. This feature is also apparent in norma lateralis (Figure 7) and norma occipitalis (Figure 9).

The nasal aperture and incisive foramina are more exposed in some specimens than in others. The nasal bones vary in shape. Large scrolled maxillary ridges (Figure 11. C, E and F) are not only associated with deep maxillary fossae but also project over the molar alveolar regions. Figure 9 also illustrates the variation in the orientation of the zygomata and the variability of the zygomatic arches referred to in norma lateralis. The size of the caudal aperture of the temporal fossa not only reflects the robustness of the zygomatic arch but also indicates the bulk and disposition of the temporal muscle. Thus it may be inferred that ventrodorsally long, narrow-opening temporal fossae are associated with flat temporal muscles spreading over the dorsal aspect of the neurocranium whereas transversely wider-opening temporal fossae are related to temporal muscles with greater

ventral bulk. This observation is confirmed by the differing sizes of the zygomatic bones and their processes.

The supraorbital region varies from specimen to specimen. In only the Zambezi cranium (Figure 11B) is the ventral orbital margin visible, while all the remaining crania have projecting supraorbital regions. This feature is related to the development of the zygomatic processes of the frontal bones.

Figure 11. further illustrates the great variation of the supraorbital regions. The specimens from Zambezi (B) and the Magaliesberge (C) exhibit well developed superciliary ridges, whereas those from Murahwas Kraal (F) Umtali (G) and Riversdale (E) have large zygomatic processes of the frontal bones.

The neurocranium in general has an ovoid outline although on purely morphological grounds one can recognise dolichocephalic types and brachycephalic types. No two specimens have identical temporal lines. As seen in *normae lateralis* and *normae occipitalis* these lines vary in the positions occupied on the cranial vault. In general the more cranially placed lines are associated with large sagittal crests. Sagittal crests are smaller and even absent in specimens with caudally placed temporal lines. A critical evaluation of the *normae* presented, reveals that although there are numerous craniofacial variations, two main types may be recognised. Type 1. as exemplified by the specimens from the Zambezi Valley (B), Chipinga (A), South West Africa (D) and the Magaliesberge (C) exhibit small maxillary ridges, shallow maxillary fossae, ventrally directed zygomatic bones, large ventral orbital apertures, well developed superciliary ridges, high temporal lines and sagittal crests. Type 11. as exemplified by the specimens from Murahwas Kraal (F) and Riversdale (E), exhibit large and flared maxillary ridges, deep maxillary fossae, ventrolaterally directed facing zygomatic bones, small ventral orbital apertures, large supraorbital tori, low temporal lines and no sagittal crests.

#### Norma basalis (Figure 12).

The bony palate consists of the fused premaxillae, bearing the incisors ventrally, the maxillae bearing the canines, premolars and molars, and dorsally the palatine bones.

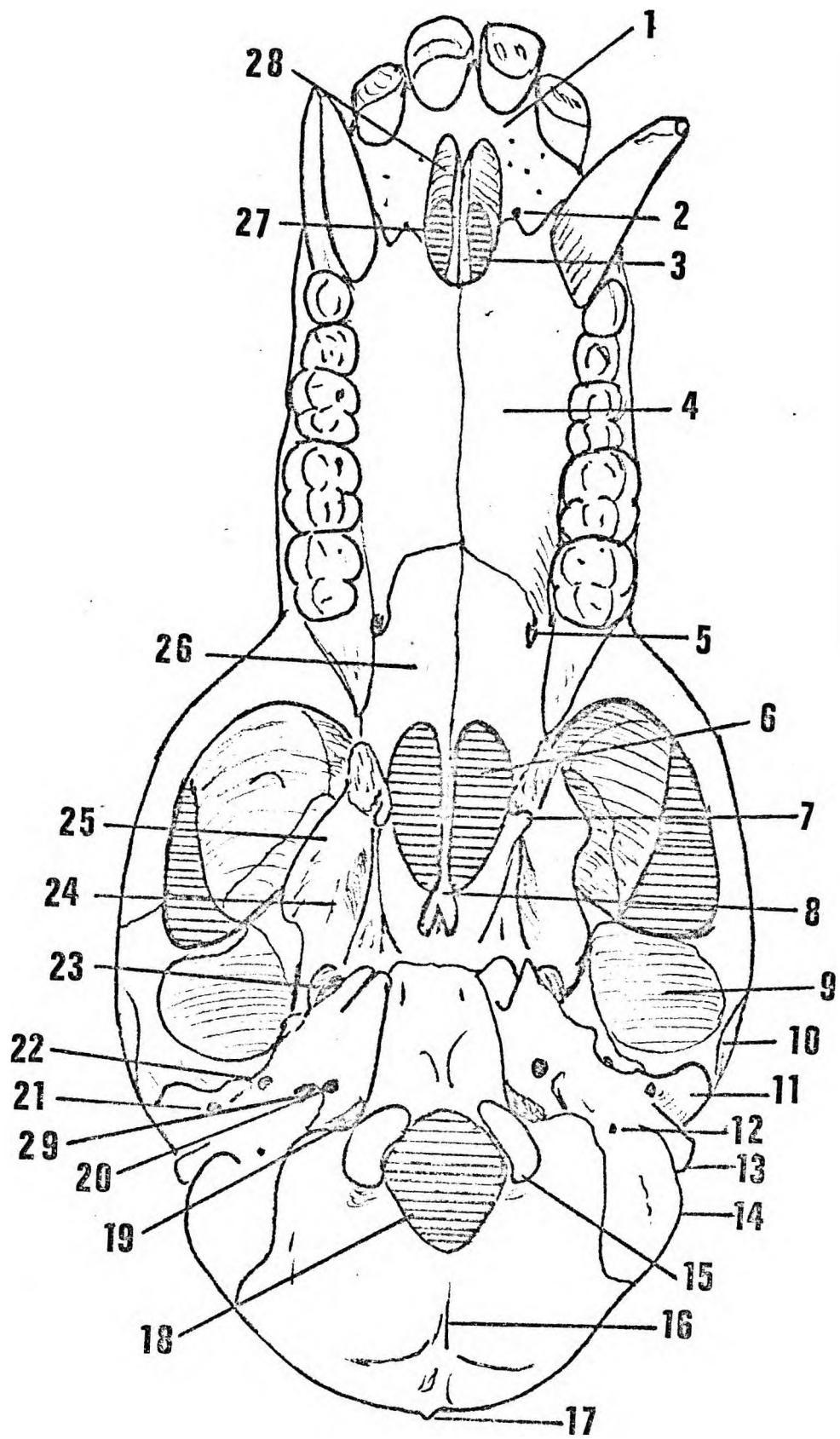


Figure 12.

Figure 12. Norma basalis.

1. Premaxilla.
2. Anterior palatine foramen.
3. Premaxilla laminae.
4. Palatal process of maxilla.
5. Posterior palatine foramen.
6. Choanae.
7. Hamulus of pterygoid bone.
8. Vomer.
9. Mandibular articular fossa.
10. Articular tubercle.
11. Postglenoid tubercle.
12. Stylomastoid foramen.
13. External auditory meatus.
14. Mastoid area.
15. Occipital condyle.
16. External occipital crest.
17. Inion.
18. Foramen magnum.
19. Jugular foramen.
20. Carotid foramen.
21. Postglenoid foramen.
22. Foramen spinosum.
23. Foramen ovale.
24. Pterygoid fossa.
25. Lateral pterygoid plate.
26. Palatine bone.
27. Incisive foramen.
28. Incisive fossa.
29. Styloid process.

An inverted 'W' shaped premaxillomaxillary suture separates the premaxillae and maxillae. This suture passes from side to side across the bony palate ventral and medial to the alveolar sockets of the canines. In the midline it is interrupted by the dorsal boundary of the incisive foramina. Wide diastemata for the lower canines, separate the incisors from the canines.

The premaxilla consists of alveolar, palatal and nasal parts. The palatal part is concave transversely, rugose and pitted by numerous foramina for blood vessels. Opposite the diastemata are two large foramina for the right and left nasopalatine nerves. The palatal processes are two thin lamina passing dorsally to form the medial walls of the incisive foramina. The incisive fossae are depressions in the premaxillae separated from each other by the nasal processes. The ampullae of the palatonasal canals rest on these fossae.

The maxillary bones form the greater part of the hard palate. In the midline they are separated from each other by a slightly raised median palatine suture. Laterally they form high alveolar processes bearing the canines, premolars and molars. The palatal surface is smooth with numerous vascular foramina. Dorsally the maxillae unite with the palatine bones at a curved or 'V' shaped suture. In cross section this part of the palate is 'U' shaped transversely and slightly concave in the ventrodorsal direction.

The maxillae continue dorsally on either side of the palatine bones. Laterally they form stout zygomaticomaxillary buttresses which pass cranially to articulate with the zygomatic bones. In immature specimens these buttresses commence at a level opposite the second molars but in mature specimens they arise at the level of the third molars. The tuberosities of the maxillae form sharp or rounded ridges dorsal to the third molars. The pterygoid portions of the maxillae extend cranially and dorsally to the pterygomaxillary sutures and fissures respectively.

Triangular portions of palatine bones separate the maxillae from the lateral pterygoid plates.

The palatine bones are enclosed ventrally and laterally by the maxillary bones. Dorsally they articulate with the medial pterygoid processes of the sphenoid bone and cranially with the septal process of the vomer. They form the dorsal part of the hard palate and remain separate bones even in old adults. The dorsal margins of the palatine bones are concave and form the dorsal boundaries of the choanae, and their septal processes form a dorsal nasal spine but the dorsal limit of this spine is not easily defined since it curves gently onto the vomer. The pterygoid processes of the palatine bones pass dorsally to articulate with the pterygoid processes of the sphenoid bone. They also participate in the formation of the ventral part of the pterygoid fossae lateral to the pterygoid hamuli.

The middle palatine nerves emerge through large foramina in the lateral part of the palatamaxillary suture dorsal to the third molar. These nerves, accompanied by vessels, pass ventrally on the lateral borders of the hard palate. The posterior palatine nerves lie in grooves on the lateral aspect of the maxillopalatopterygoid suture.

The vomer extends ventrally from the caudal surface of the basisphenoid to articulate with the nasal processes of the palatine bones. It forms the dorsal part of the medial wall of the choanae. The sphenoidal attachment is 'V' shaped and covers a vein.

The basisphenoid forms the dorsal boundaries of the choanae. Laterally it articulates with the apices of the petrous temporal bones as they pass ventrally to the base of the medial pterygoid process. The basisphenoid has three processes on either side.

Laterally are the temporal processes passing towards the articular area for the mandibular condyles on the temporal bone. The alisphenoids pass cranially into the infratemporal fossae. The medial and lateral pterygoid laminae enclosing deep pterygoid fossae, extend caudally. The medial pterygoid processes are small and form the lateral walls of the choanae; ventrally they bear large spike-like hamuli around which the tendons of the tensor palati muscles pass. The tensor palati muscles arise from bony spines on the caudoventral aspects of the apices of the petrous temporal bones, from the lateral walls of the pharyngotympanic tubes and the caudal edges of the medial pterygoid



plates and from long narrow scaphoid fossae on the lateral aspects of the medial pterygoid plates.

The pterygoid fossae are deep pits between the medial and lateral pterygoid plates. They are filled by the medial pterygoid muscles. The medial pterygoid muscles are large with tendinous ventral portions. The ventral tendinous portions arise from the ventral aspects of the pterygoid fossae and both pterygoid plates. The fleshy dorsal portions of the medial pterygoid muscles arise from the pterygoid fossae and medial aspects and edges of the lateral pterygoid plates.

The lateral pterygoid plates are large and project laterally and caudally. On the craniolateral aspect of each lateral pterygoid plate a ridge and a groove separate the two heads of the lateral pterygoid muscle. The groove is occupied by the buccal nerve and the middle meningeal artery and extends dorsally to the foramen lacerum (Figure 13). The dorsal end of this groove is often converted into a canal by a pterygoalar bar (Figure 14B). The lateral pterygoid muscle is small and petal-shaped with medial and lateral heads of origin. The medial head arises from the lateral surface of the lateral pterygoid plate and the lateral and more cranial head from a shallow fossa on the ventral aspect of the temporal processes of the sphenoid bone.

The temporal bones present petrous, articular and mastoid portions. The foramina lacera are extensive fissures between the petrous temporal bones dorsally and the temporal processes of the sphenoid and articular processes of the temporal bones ventrally. The lateral parts of these fissures correspond with the Glaserian (or petrotympanic) fissures in man, the ventral parts with the foramina lacera. The foramina ovalia and foramina spinosa are incorporated in the foramina lacera.

Medially deep fissures extend ventrally from the jugular foramina to separate the petrous temporal bones from the basiocciput and basisphenoid. The apices of the petrous temporal bones extend ventromedially to articulate with bases of the medial pterygoid processes.

#### Structures related to the foramen lacerum (Figure 13 and 14A).

Most medial are the bony walls of the pharyngotympanic tube. The levator palati muscle arises from a bony crest on the petrous temporal bone on

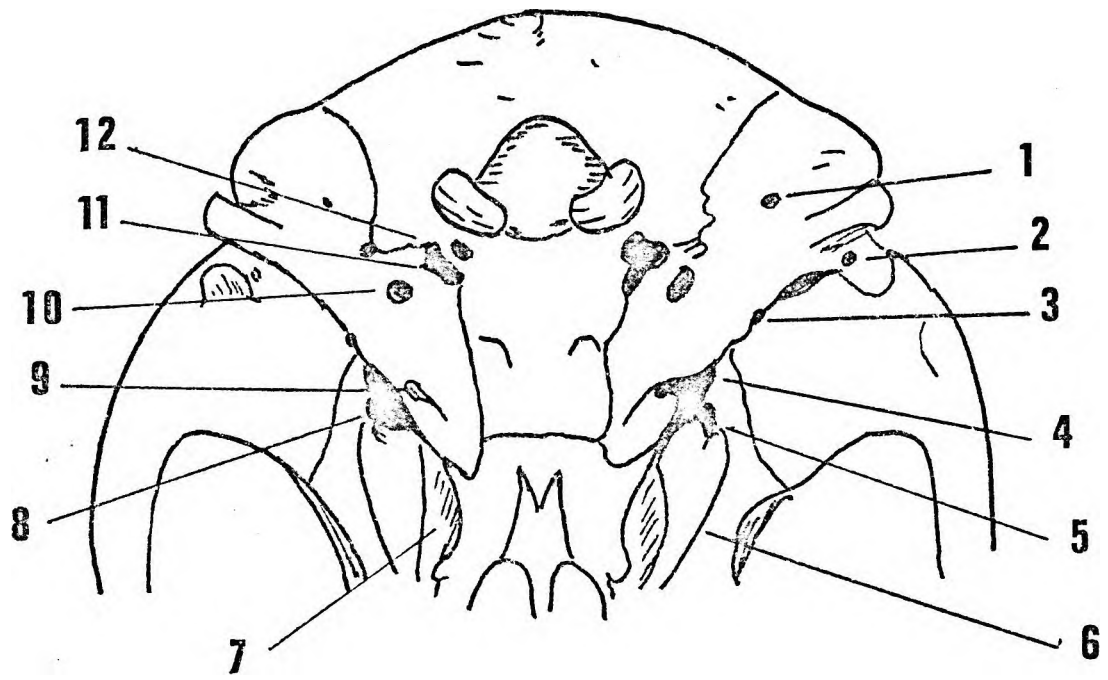


Figure 13.

Figure 13. The base of the cranium.

1. Stylomastoid foramen.
2. Postglenoid foramen.
3. Foramen for chorda tympani nerve.
4. Foramen spinosum.
5. Foramen ovale.
6. Lateral pterygoid plate.
7. Pterygoid fossa.
8. Groove for buccal nerve.
9. Bony portion of auditory tube.
10. Carotid foramen.
11. Jugular foramen.
12. Foramen for hypoglossal nerve.

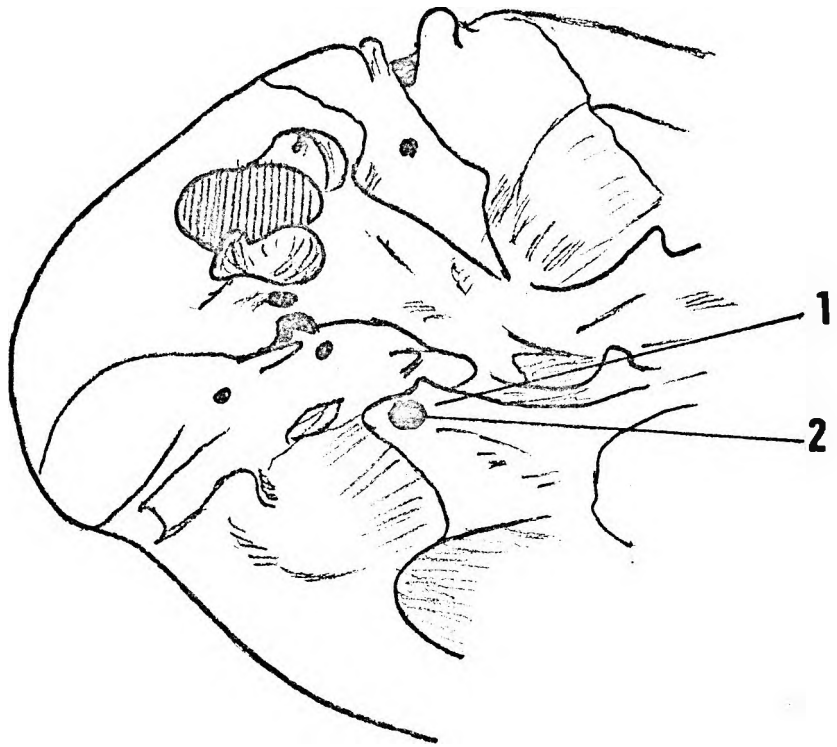
the medial aspect of the pharyngotympanic tube. The pharyngotympanic tube is a complete fibrocartilaginous tube and does not have medial and lateral laminae as in man. The tensor palati and levator palati muscles also arise from medial and lateral sides of the pharyngotympanic tube respectively.

The 'foramen ovale' is a large oval expansion of the ventromedial end of the foramen lacerum. From the lateral border of the foramen ovale a groove passes ventrally between the heads of the lateral pterygoid muscle. The middle meningeal artery and buccal branch of the mandibular division of the trigeminal nerve lie in this groove. The chorda tympani nerve emerges from a rounded expansion in the foramen lacerum just lateral to the foramen ovale. The middle meningeal artery enters the cranium through the foramen lacerum between the buccal branch of the mandibular and the chordatympani nerves. This ventromedial part of the foramen lacerum is often, even in immature specimens, converted into a separate foramen spinosum compartment by dorsal extensions from the pterygoalar bar laterally and the base of the lateral pterygoid plate medially. The latter process is probably the pterygospinous bar (Fig.14A).

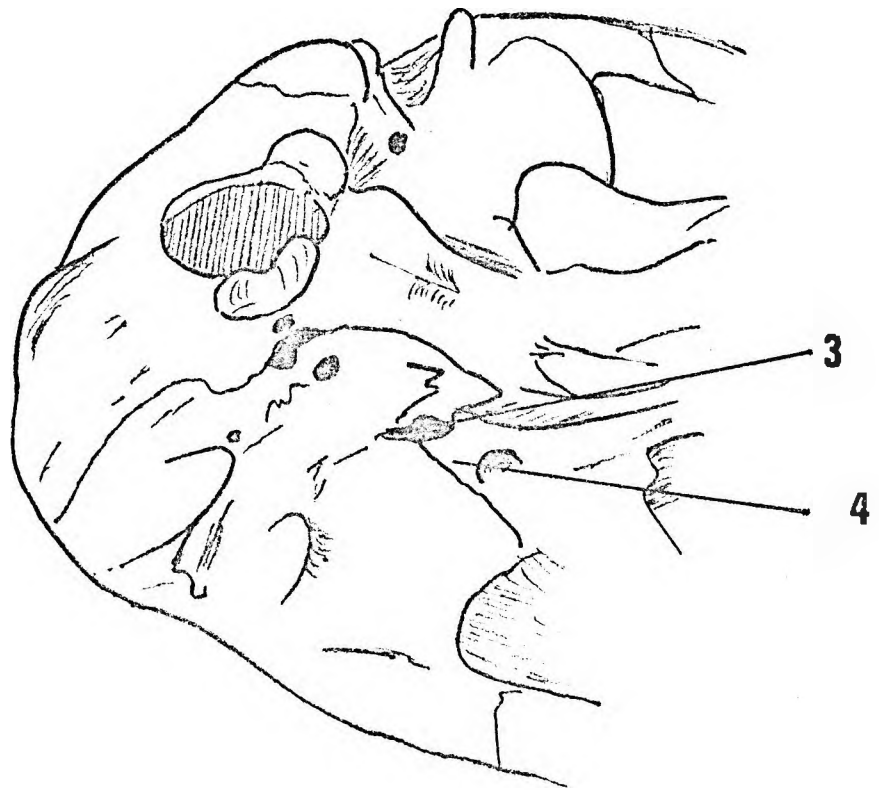
The foramen lacerum continues dorsolaterally as far as the medial aspect of the postglenoid tubercle where it ends in a foramen, the postglenoid foramen, for the prootic venous sinus. The capsule of the temporomandibular joint is attached to the ventral edge of the Glaserian fissure. The sphenomandibular ligament is attached to a bony crest in the Glaserian fissure lateral to the foramen spinosum.

The articular surface of the temporal bone is nearly  $2\frac{1}{2}$  times the size of the mandibular condyle. The intraarticular disc covers it completely. Its ventral half is flat whereas the dorsal half is concave in a transverse direction. The joint capsule is attached to the periphery of the articular facet and the ventral margins of the postglenoid tubercle. The articular tubercle is a small raised eminence on the dorso lateral angle of the articular facet. There is no eminentia articularis. A deep groove separates the postglenoid tubercle from the articular facet.

The postglenoid tubercle or postarticular process, (Hartmar & Strauss 1933), is a large projection of bone on the dorsal edge of the



**A**



**B**

Figure 14. The foramen lacerum with pterygospinous and pterygoalar bars.

---

- A. Pterygospinous bar.
- B. Pterygoalar bar.
- 1. Pterygospinous bar.
- 2. Foramen ovale.
- 3. Foramen ovale.
- 4. Pterygoalar bar.

articular facet. It projects caudally and laterally. Its apex is roughened by the attachment of a strong posterior temporomandibular ligament.

The postglenoid foramen, for the prootic venous sinus, lies on the medial and dorsal aspect of the postglenoid tubercle.

The external opening of the carotid canal is a round foramen in the petrous temporal bone ventral to the styloid process. The internal carotid artery and the cranial branch of the sympathetic plexus of nerves enter the canal. The sympathetic plexus does not surround the artery but forms a single nerve on its ventromedial aspect.

The styloid process is a small bony projection of the petrous temporal bone lateral to the lateral wall of the jugular foramen. It is not always a separate bone as in man. The stylohyoid ligament and the stylohyoid, styloglossus and stylopharyngeus muscles are attached to the styloid process. A ridge of bone may connect the styloid process to the dorsal edge of the carotid foramen.

The jugular foramen is a crescentic-shaped opening in the petro-occipital fissure dorsomedial to the carotid foramen. Internally, definite medial and less well defined middle and lateral compartments are apparent. The inferior petrosal sinus emerges through the medial compartments, anastomoses with its fellow from the opposite side of the cranium on the caudal surface of the basiocciput, and then passes caudally between the glossopharyngeal, vagus and accessory nerves to join the internal jugular vein about 1cm caudal to the cranium. The internal jugular vein occupies the most lateral compartment.

The glossopharyngeal, vagus and accessory cranial nerves lie in the middle compartment. The vagus nerve lies most medial with the accessory nerve between it and the glossopharyngeal nerve which is most lateral. The superior ganglion of the glossopharyngeal cranial nerve lies in a little fossa from which two small canals extend towards the tympanic cavity. The canals contain the tympanic branches of the glossopharyngeal and vagus nerves. The stylomastoid foramen, for the facial nerve, is situated midway between the styloid process and the medial prominence of the mastoid area. The foramen lies ventral to the ridge for the attachment of the cervical fascia to the mastoid area.

The hypoglossal nerve emerges from a foramen ventral to the occipital condyle. A thin bony bar separates it from the jugular foramen. On its internal aspect this foramen is often divided into two compartments for separate divisions of the hypoglossal nerve.

The external auditory meatus faces dorsolaterally. The osseous part of the canal is directed ventromedially and lies between the mastoid area and the postglenoid tubercle. The canal may be a complete bony ring or may be deficient cranially. In mature specimens a bony crest develops on the caudal aspect of the canal and the external auditory meatus projects beyond the level of the supramastoid crest.

The occipital bone, as seen in norma basalis consists of a basilar part ventrally, a squamous part dorsally, and condylar parts laterally. The basilar part articulates ventrally with the basi-sphenoid and laterally with the petrous part of the temporal bone. An external occipital crest divides the nuchal area into two nearly equal halves. The degree of development of this crest varies. The foramen magnum opens dorsocaudally and is flanked by the two occipital condyles. Caudally projecting ridges are formed by the sutures between the occipital bones and the mastoid parts of the temporal bones. Foramina for emissary veins frequently occur in these sutures. These veins connect internally with the sigmoid sinuses. The medial prominences of the mastoid area lie laterally and cover the dorsal borders of the external auditory meatuses.

The occipital condyles are bilateral reniform projections on either side of the ventral half of the foramen magnum. The articular surfaces are convex and directed ventromedially in both dorsoventral and lateral directions. The medial surfaces are notched for the attachment of the alar ligaments. The articular condyles are raised on pedicles of variable height. Ventral and dorsal condylar fossae occur at the poles of the condyles. The hypoglossal nerve emerges from the ventral fossa while the dorsal fossa may be pierced by a foramen for an emissary vein.

The foramen magnum is ovoid and wider ventrally than dorsally. The lateral margins dorsal to the condyles are grooved for the attachment of the posterior atlantooccipital ligament. The foramen magnum lies at an angle of about  $45^{\circ}$  in relation to the standard horizontal plane.



The attachment of the cervical fascia and muscles to the nuchal area are illustrated in (Figure 15).

The investing layer of the cervical fascia is attached to the nuchal crest frominion to the tip of the medial prominence of the mastoid area, and then passes medially, dorsal to the stylo-mastoid foramen and jugular foramen and encloses rectus capitis lateralis, rectus capitis and the longus colli muscles. The ligamentum nuchae is attached to the external occipital crest and separates the nuchal muscles into right and left halves.

The trapezius muscle with the rhomboideus capitis muscle is attached to the medial half of the nuchal crest. The sternocleidomastoid muscle has an aponeurotic attachment to the lateral half of the nuchal crest and a fleshy comma-shaped attachment to the mastoid area. The semi-spinalis capitis muscle is attached to the roughened area caudal toinion and lateral to the dorsal third of the external occipital crest. The muscles splenius capitis, longissimus capitis and the posterior belly of the digastric muscle are attached to a roughly semilunar area medial to the sternocleidomastoid. The posterior belly of the digastric muscle lies in a shallow fossa and has a tendinous caudal portion.

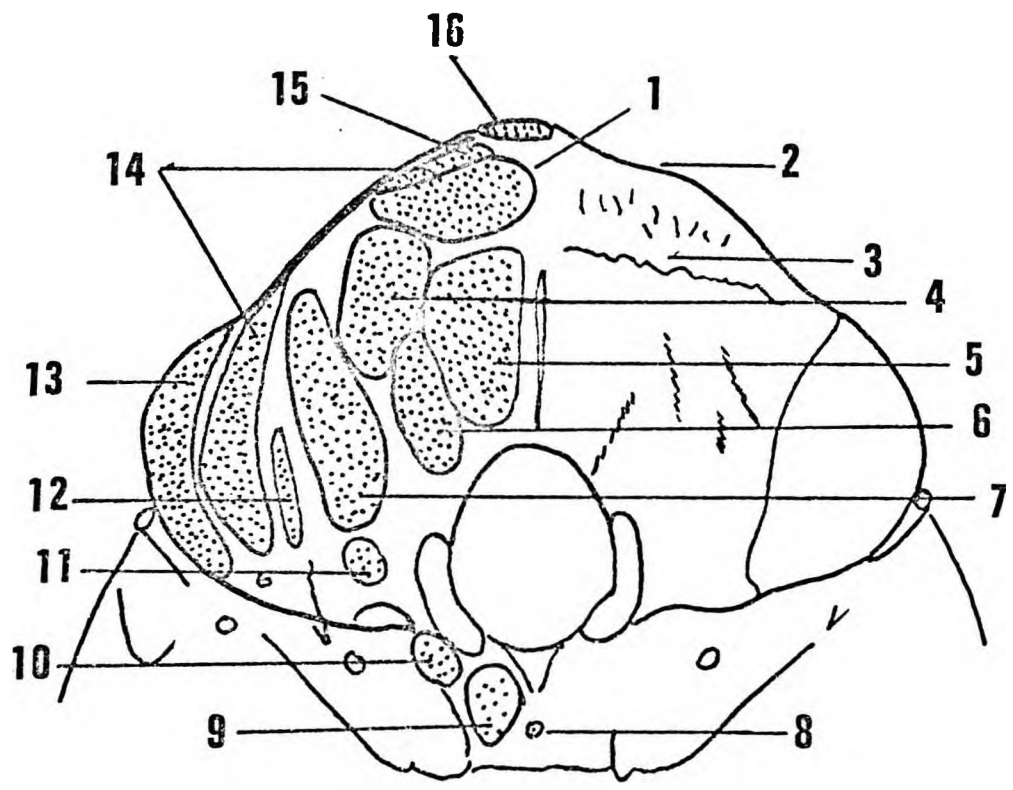


Figure 15.

Figure 15. The attachment of the cervical fascia and muscles to the nuchal area.

---

1. Semispinalis capitis.
2. Nuchal crest.
3. Rough nuchal area
4. Superior oblique.
5. Rectus capitis posterior minor.
6. Rectus capitis posterior major.
7. Posterior belly of digastric.
8. Pharyngeal tubercle.
9. Longus colli.
10. Rectus capitis anterior.
11. Rectus capitis lateralis.
12. Longus capitis.
13. Sternocleidomastoid.
14. Splenius capitis.
15. Rhomboideus capitis.
16. Trapezius.

## THE INTERIOR OF THE CRANIUM

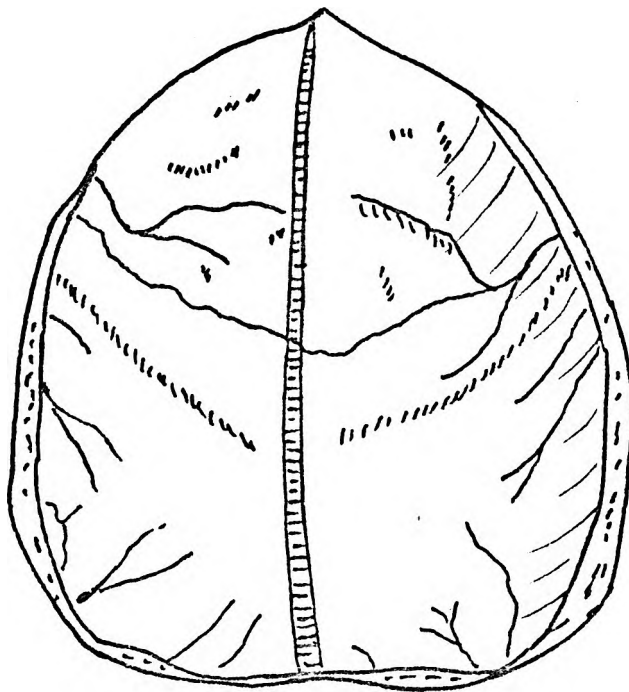
The endocranial cavity is ovoid. The roof is formed by the frontal bone, the parietal bones and the squamous part of the occipital bone. The lateral walls are formed by the frontal, alisphenoid, temporal and occipital bones. The floor, or basal part, consists of three fossae, ventral, middle and dorsal.

The roof (Figure 16A) shows the well defined endocranial markings on the frontal bone but the endocranial surface dorsal to the frontal bone is smooth except for a faint elevation corresponding with the central sulcus. Sutures seen on the endocranial aspect of the cranial vault correspond with those seen on the exterior. The coronal and the sagittal sutures are readily identified but the temporoparietal sutures are not easily discernible. The crista frontalis is small or absent and flanked on right or left sides by a sulcus for the superior sagittal sinus which increases in size as it passes dorsally.

Foramina for diploic veins are evident over the frontal and interparietal areas but there are no pits for the arachnoid granulations. No foramina for parietal emissary veins are apparent. The ventral divisions of the middle meningeal vessels form sulci on the parieto-frontal sutures and arborise ventrally over the frontal bone and dorsally over the parietal bones. Parietal branches of the dorsal divisions of the middle meningeal vessels form well defined grooves over the dorsal aspects of the parietal bones.

The ventral cranial fossa is shown in Figure 16B. Ventrally the fossa is bounded by the thick bone of the superciliary and supraorbital ridges. There are no frontal air sinuses. The lateral walls are formed by the thin frontal bone. The dorsal boundary is formed by the jugum sphenoidale of the presphenoid in the midline and the sutures between the alisphenoids and orbitosphenoids laterally.

The floor consists of the cone-shaped orbital plates of the frontal bone ventrally and the endocranial surfaces of the orbitosphenoid dorsally and is divided into right and left halves by a bony median ridge extending from the deep olfactory pit ventrally to the jugum sphenoidale dorsally.



**A**

Figure 16A

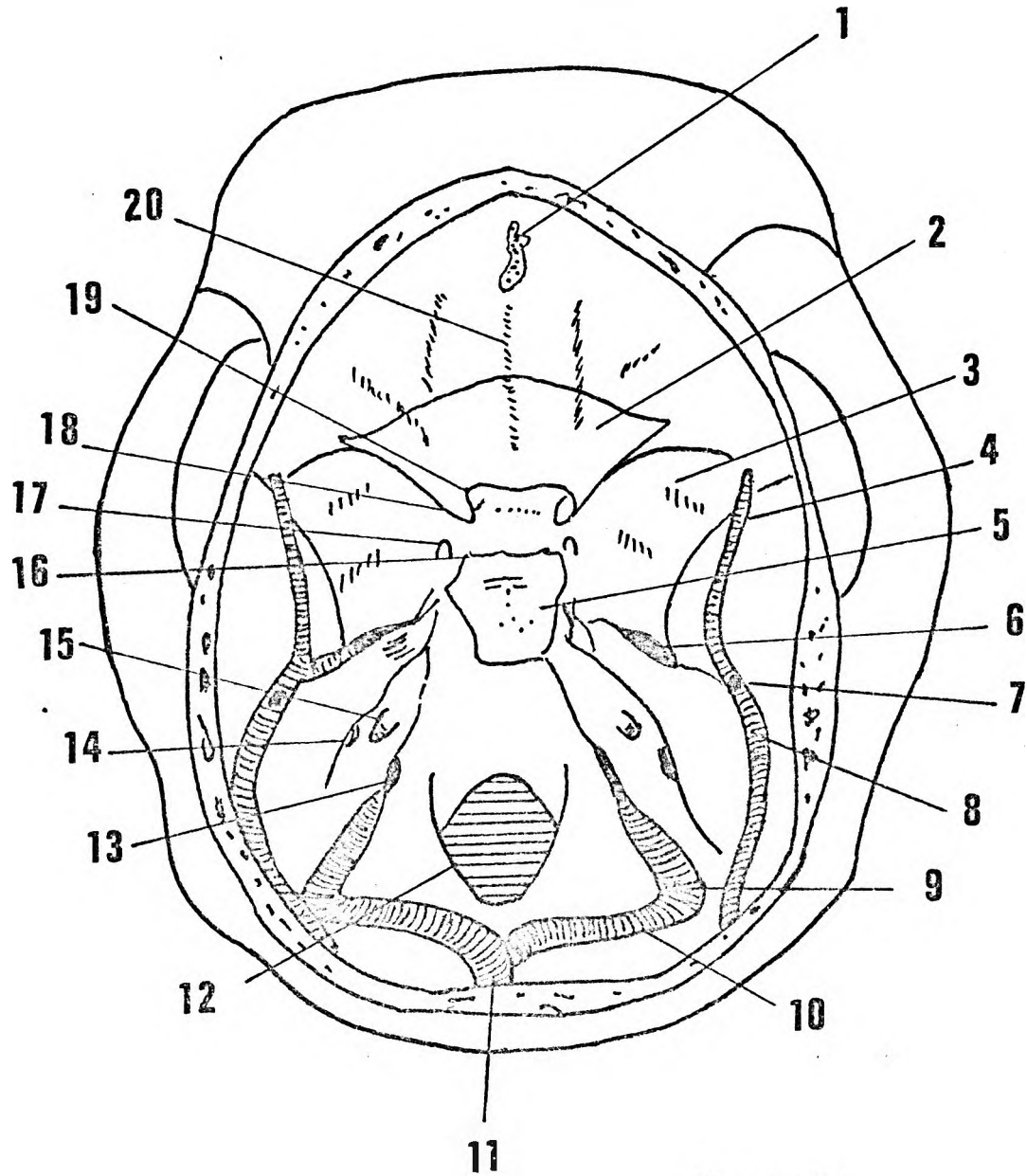


Figure 16B.

**B**

Figure 16A. Endocranial aspect of vault of the  
cranial bones.

---

Figure 16B. Endocranial aspect of the cranial fossae.

---

1. Olfactory pit.
2. Orbitosphenoid.
3. Alisphenoid.
4. Grooves for middle meningeal vessels.
5. Dorsum sellae.
6. Foramen ovale.
7. Postglenoid foramen.
8. Prootic sinus.
9. Sigmoid sinus.
10. Transverse sinus.
11. Confluens sinuum.
12. Foramen magnum.
13. Jugular foramen.
14. Flocculonodular fossa.
15. Internal auditory meatus.
16. Posterior clinoid process.
17. Foramen rotundum.
18. Anterior clinoid process.
19. Optic foramen.
20. Interfrontal ridge.

The orbital plates are roughened by digital impressions corresponding with the sulci and gyri of the cerebrum. A small cribriform plate lies at the bottom of the olfactory pit. There is no crista galli. A foramen caecum, containing a large vein lies ventrally. Anterior and posterior ethmoidal nerves and vessels are not found on the endocranial surface. The lateral walls of the pit present two or three bony tubercles. The dorsal wall of the pit is a smooth groove on which the olfactory nerves lie. A thin sheet of dura mater covers the endocranial opening of the pit ventral to the olfactory nerves. The falx cerebri is attached to this sheet of dura and extends dorsally as a narrow lamina attached to the median ridge. On either side of the median ridge are two shallow grooves for the olfactory nerves. The presphenoid has no sphenoidal spur and the frontosphenoidal suture forms a gentle curve.

The middle cranial fossa (Figure 16B) consists of lateral parts separated by a medial central part. Ventrally it is bounded by the dorsal boundary of the ventral cranial fossa and dorsally by the sharp margins of the petrous parts of the temporal bones. The lateral parts lie dorsal and caudal to the orbital cavities and contain the poles of the temporal lobes. The ventral walls are formed entirely by the alisphenoids, the lateral walls by the alisphenoids, the squamous parts of the temporal bones and the dorsal parts of the petrous parts of the temporal bones.

The sulci of the temporal lobes form two well defined crests in the ventrolateral portions of the middle cranial fossa. The sphenotemporal sutures are easily identified and just lateral to these are deep sulci for the ventral divisions of the middle meningeal vessels. On the internal aspect of pterion these vessels turn cranially along the coronal suture. At pterion, too, are numerous small vascular foramina formed by nutrient branches of the ventral division of the middle meningeal artery.

On either side the alisphenoids and squamous parts of the temporal bones are separated from the petrous parts of the temporal bones by deep petrosquamous fissures, extending dorsolaterally from the internal opening of the foramina lacera. Each fissure consists of a medial portion between the apex of the petrous part of the temporal bone and the basilar part of the occipital bone. This part is related to the endocranial portion

of the internal carotid artery. Lateral to the apex of the petrous part of the temporal bone the petrosquamous fissure forms an oval compartment - the foramen ovale, for the mandibular division of the trigeminal nerve which grooves the petrous temporal bone lateral to the internal opening of the carotid canal. A slight bony constriction separates the nerve from the middle meningeal artery. This artery and the prootic venous sinus lie in the petrosquamous fissure which ends laterally at the postglenoid foramen.

The prootic venous sinus is not connected with either the basilar venous plexus medially or the transverse sinus laterally. The ventral and dorsal branches of the middle meningeal veins drain into it and it in turn drains into the retromandibular venous plexus via the postglenoidal vein.

The middle meningeal artery divides into ventral and dorsal branches soon after entering the cranial vault. The ventral branch passes ventrolaterally across the floor of the middle cranial fossa while the dorsal branch accompanied by the dorsal meningeal vein lies in the deep sulcus between squamous and petrous parts of the temporal bone.

The central part of the middle cranial fossa is formed largely by the sella turcica of the sphenoid bone. Ventrally a groove on the presphenoid for the optic chiasma connects the two optic foramina. The limbus of the presphenoid forms a bow-shaped lip over the optic chiasma. The tuberculum sellae is a gentle elevation flanked on either side by grooves for the ophthalmic arteries. The ventral clinoid processes arise from two stout columns of the orbitosphenoid. Medially they are related to the endocranial termination of internal carotid artery and the optic chiasma. The hypophyseal fossa is large and nearly completely covered by the dorsum sellae. In many specimens a median foramen in the dorsum sellae connects the hypophyseal fossa with the dorsal cranial fossa. The internal carotid arteries lie in sulci formed on the body of the sphenoid. These sulci are flanked laterally by a bar of sphenoidal bone which separates the internal carotid arteries from the maxillary division of the trigeminal nerve and gives attachment to the lateral wall of the cavernous sinus. The maxillary divisions of the trigeminal nerve pass ventrally, in grooves lateral to the sphenoidal bars in the dorsal aspects of the lateral walls of the cavernous sinus, to the foramina rotunda. The foramina rotunda are not true foramina but rather canals leading to the caudal orbital fissure.



The cranial surface of the petrous temporal bone forms the dorsal part of the floor of the middle cranial fossa. The petrous temporal bone is convex cranially and presents a lateral sulcus on which the inferior temporal gyrus lies. A sulcus for the greater superficial petrosal nerve is found midway between the prootic fissure and the medial border of the bone. A hiatus of the facial canal is absent. The medial border of the petrous part of the temporal bone is sharp. Ventrally, near the apex, two bony spurs mark the ventral and dorsal boundaries of the impression made by the ganglion of the trigeminal nerve.

Opposite the middle of the foramen magnum the medial borders of the petrous temporal bones are notched over the deep subarcuate fossa for the paraflocculus of the cerebellum.

The dorsal cranial fossa encloses the foramen magnum (Figure 16B). The floor is formed in a ventrodorsal direction by the dorsum sellae lying on the body of the sphenoid, the basilar part, the condylar parts and the squamous portion of the occipital bone. The lateral walls are formed by the medial surfaces of the petrous parts of the temporal bones.

The dorsum sellae is a large shield of bone fixed onto the body of the sphenoid like a postage stamp. The ventral boundary is sharp and pointed laterally to form the dorsal clinoid processes. The lateral edges are rounded but the dorsal edge is sharp and where these two boundaries meet there are bony spurs for the attachment of the attached portion of the tentorium cerebelli. Thus laterally between the dorsal edges of the dorsum sellae and the apices of the petrous parts of the temporal bones, sheets of dura mater invaginated by the cavum trigeminale, complete the dorsal cranial fossa.

The dorsal surfaces of the dorsum sellae and the basilar part are concave for the reception of the pons and medulla oblongata respectively. The nearly constant foramen on the dorsum sellae is covered by dura mater and communicates with the subarachnoid space around the hypophysis.

The foramen magnum is irregularly ovoid in shape and flanked on its lateral aspects by the condylar parts of the occipital bone.

If the cranium is held to the light the clivus, the cerebellar fossae and the fossae for the occipital poles are seen to consist of thin translucent bone.

Petrooccipital fissures separate the petrous parts of the temporal bones from the basilar and lateral parts of the occipital bone. Dorsally these fissures become continuous with the deep grooves for the sigmoid sinuses. Three parts are recognised in each petrooccipital fissure :

- i) a narrow ventral portion containing the inferior petrosal sinus;
- ii) a spur of bone from the petrous part of the temporal bone separates this narrow ventral portion from an oval opening through which the glossopharyngeal, vagus and accessory nerves pass; iii) dorsal to this spur of bone the groove for the sigmoid sinus is separated by an even larger spur of bone.

The endocranial opening of the hypoglossal canal lies on the sloping ventral wall of the foramen magnum in the same vertical plane as the condylar notch.

The squamous part of the occipital bone presents five fossae separated by five bony ridges. The single fossa for the vermis of the cerebellum is found in the midline dorsal to the foramen magnum and this fossa is separated from the cerebellar fossae on either side by the bony buttresses around the foramen magnum. The fossae for the occipital poles lie dorso-cranially to the cerebellar fossae from which they are separated by grooves for the transverse sinuses. A sagittal ridge of bone, grooved by the dorsal part of the superior sagittal sinus, separates the fossae for the occipital poles.

The internal occipital protuberance on which the confluens sinuum lies does not correspond with inion and is formed about 1 cm dorsal to the dorsal limit of the foramen magnum. In most crania the superior sagittal sinus leads into the left transverse sinus while the sinus rectus passes to the right transverse sinus.

The medial surface of the petrous parts of the temporal bones face craniomedially. On each surface a canal and two fossae are found. The internal auditory canal is situated directly cranial to the oval opening for the glossopharyngeal, vagus and accessory nerves, and consists of two parts separated from each other by a bony ridge; i) a smaller ventral canal for the facial nerve and ii) a larger dorsal canal for the vestibulo-cochlear nerve. Dorsocranial to the internal auditory canal is the deep loculated subarcuate fossa. The groove for the sigmoid sinus is formed in the occipital bone medial to the petrooccipital suture.

The lateral lobe of the cerebellum lies across the sigmoid sinus, and occupies a shallow fossa on the dorsomedial aspect of the petrous part of the temporal bone as well as the cerebellar fossa on the occipital bone.

The superior petrosal sinus forms a groove on the medial edge of the petrous part of the temporal bone extending dorsally from the subarcuate fossa to the internal aspect of asterion. The dorsal branch of each middle meningeal artery on reaching the internal aspects of asterion divides into a dorsal branch to supply the occipitoparietal region and a caudal branch that passes to the cerebellar fossa of the occipital bone. These vessels cross the transverse and sigmoid sinuses on their osseous aspects.

## THE CRANIUM OF THE FEMALE BABOON

Anatomically the cranium of the female baboon resembles that of the male, however, baboons show a high degree of sexual dimorphism. This dimorphism is particularly striking when the crania of the two sexes are compared. The female cranium is smaller, lighter and less rugged than that of the male. The crests and ridges, so prominent in the male cranium, are either absent or poorly developed in the female cranium. The muzzle of baboon male is greatly elongated with well developed maxillary ridges. This is not the case in the female.

Freedman (1957) considers sexual dimorphism in detail and regards the following features as relevant -

- 1 The female cranium is smaller.
- 2 The maxillary ridges are weakly developed.
- 3 As the result of the weaker development of the ridges in the female and also because of the more abrupt upward curve of the nasals and maxillae in the infraorbital region, the maxillae, in the female slope downwards quite sharply from the nasals to the maxillary ridges where the vertical and lateral surfaces of the muzzle begin.
- 4 The supraorbital ridge is only slightly developed in the female. The supraorbital notch and the spine on the medial side of the dorsal margin of the orbital cavity are also more marked in the male.
- 5 There is no sagittal crest in the female.
- 6 The inferior temporal line is also prominent in the female but extends only as far as the coronal suture; the superior temporal line is weak and barely visible.
- 7 The nuchal crest and markings on the squamous part of the occipital bone are less well developed in the female. The external occipital protuberance is also less well developed.
- 8 In the female, the orbit is almost round with some outward expansion of the mesiodorsal corner for the supraorbital notch. In the male, as the result of the heavy supraorbital torus and strengthening of the infraorbital margin, the orbit is flattened and becomes oval in a mesiolateral direction.

- 9 In norma lateralis the profile view of the muzzle again reveals marked differences between the sexes. The almost vertical drop in the interorbital region of the female is relatively greater and longer than in the male. The succeeding slope of the muzzle is relatively steeper in the female.
- 10 In the female, the canines project only slightly beyond the occlusal plane and are altogether much smaller teeth than in the male. They show a similar structure to the male equivalents but the twisting and grooves in those teeth are virtually absent. Because of their smaller size the wear on the female canines is rather different to that of the male canines.

An examination of the crania of six adult baboons from the same troop at Bindura not only confirms these claims but adds additional information. The specimens are named Bindura A, B, C, D, E, and F respectively.

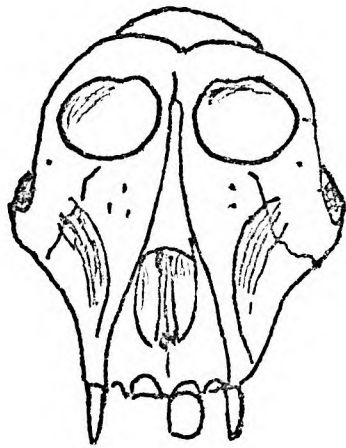
Norma facialis (Figure 17).

The outline of the facial portion is triangular with the apex blunted at the premaxilla. As in the male the nasal aperture varies from a narrow ovoid in the crania, D and E, to a wide ovoid in the crania, C and F. The shapes of the nasal bones vary.

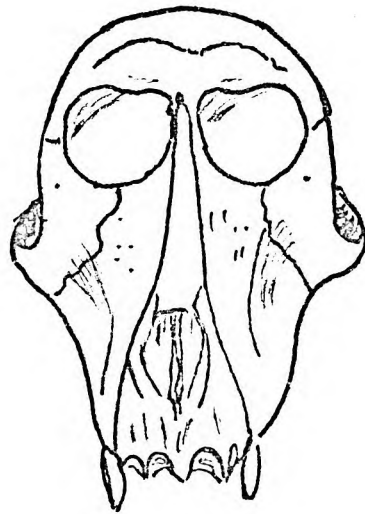
Infraorbital fossae occur in all these specimens but are deepest in specimens A and B and shallowest in E and F. Specimen A has the deepest maxillary fossae while E and F have the shallowest fossae. Specimens A, B and C have fairly well developed maxillary ridges but these are not scrolled or grooved as in the male. Again specimens A, B and C have ventral directed zygomatic bones whereas D, E and F have ventrolateral directed zygomatic bones.

The canine buttress forms the ventral border of the maxillary fossa and continues dorsally as the maxillary ridge on the muzzle. This maxillary ridge is well developed in specimens C and F but less prominent in the younger adult females.

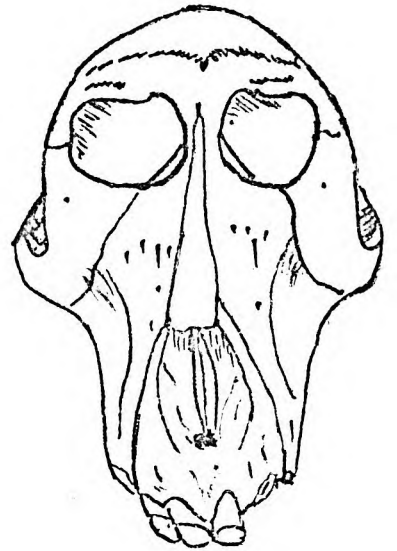
The shapes of the ventral margins of the orbital cavities also vary from nearly circular openings in specimens B and D to nearly elliptical openings in A and F. The cranial margins of the orbital cavities influence their shape. As in the male the shape is affected by the presence or absence of a supraorbital groove and spine, the degree of development



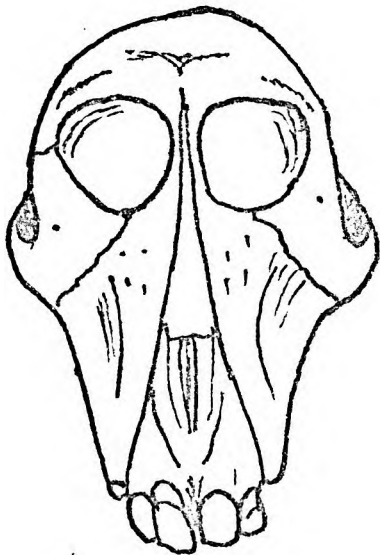
**A**



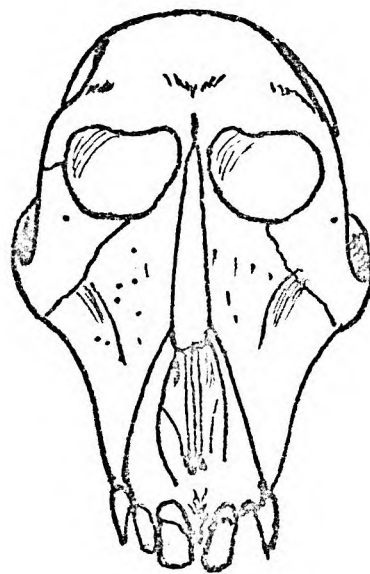
**B**



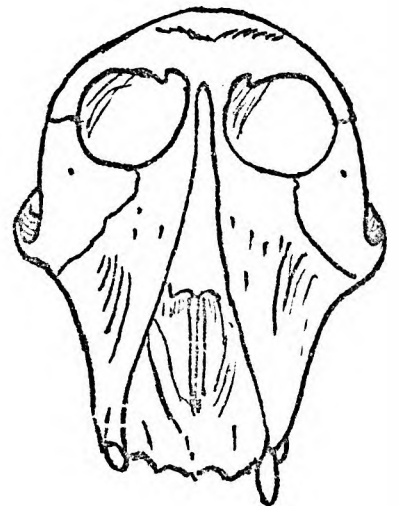
**C**



**D**



**E**



**F**

Figure 17.

Figure 17. Norma facialis of the crania of 6  
adult female baboons from the same  
troop.

---

of the superciliary ridges and glabella and the degree of development of the zygomatic process of the frontal bone.

Specimen D has poorly developed supraorbital grooves whereas in specimens A, C and F these grooves are prominent. Large superciliary ridges with prominent glabellae are found in all the specimens except E. The degree of development of the zygomatic processes of the frontal bone is better illustrated in norma lateralis.

#### Norma lateralis (Figure 18).

In this profile the outline of the premaxilla may be a straight line continuous with that of the nasal bone as in F or convex cranially as in A and C. Variations between these outlines occur among the other female specimens examined.

The zygomatic bone may face ventrally or ventrolaterally. Ventrally directed zygomatic bones are associated with deep maxillary fossae, specimen A, whereas ventrolaterally directed facing zygomata are associated with shallow recesses, D, E and F.

The outlines of the neurocrania and their cranial projections above the supraorbital margins vary. Thus specimens A, B and F have low foreheads while in E a considerable amount of frontal bone is exposed.

The nasofrontal area too, may vary. In specimen B and D it is nearly straight but in A is markedly concave.

The lateral margin of the orbital cavity is constituted by frontal and zygomatic elements as in the male. This lateral border is concave ventrally and depending on the degree of concavity reveals greater or lesser degrees of the medial orbital wall. As in the male, a well developed supraorbital ridge is associated with well developed frontal and zygomatic processes which not only obscure more of the medial wall of the orbit but give a hooded effect to the orbital cavities. Such is the case in specimen A but not in specimens C and D.

The postorbital outline of the neurocranium is a smooth convexity. A coronal flattening only occurs in D. The temporal lines are visible in all the specimens but are not as prominent as in the male.



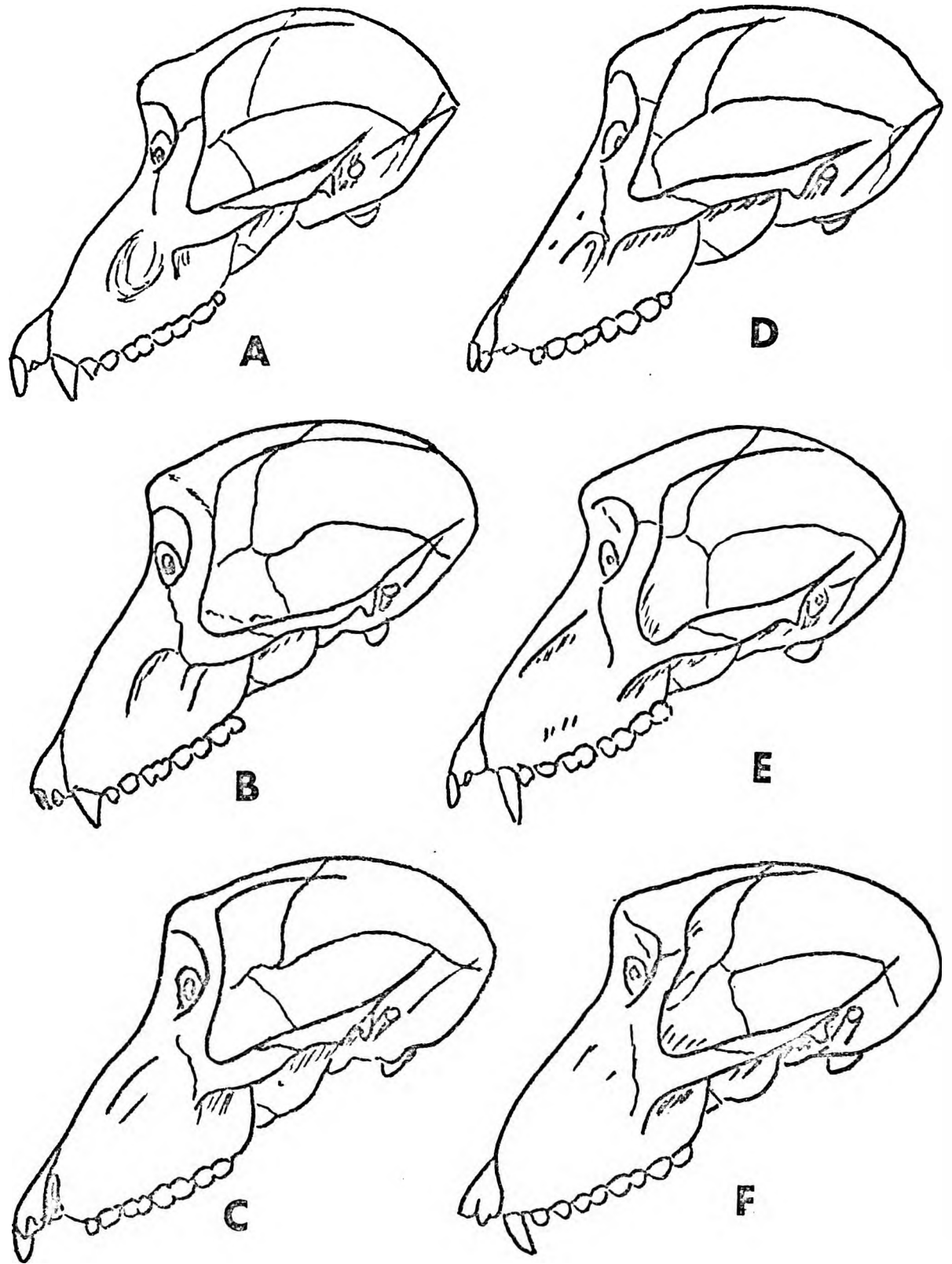


Figure 18.

Figure 18.      Norma lateralis of the crania of 6  
adult female baboons from the same  
troop.

---

The temporal lines are more distinct ventrally, and also vary in height. The height of the temporal lines is associated with particular types of zygomatic bone. A relatively slight ventrally directed zygomatic bone is associated with temporal lines which ascend to nearer the sagittal suture; whereas the stouter ventrolaterally directed zygomatic bones are related to low temporal lines. This distinction is also noted in the male crania but is equally apparent in the females. As in the male, high temporal lines are also associated with a spur-like inion.

Inion and the nuchal crest are present in varying degrees of development but less well developed than in the male. Inion is a sharp bony spur in specimens A and D, but a blunt knob in the other specimens.

The zygomatic process is slender as compared with that of the male. Dorsally it continues onto the supramastoid crest which is also less well developed. The external auditory meatus never projects beyond the level of the supramastoid crest.

#### Norma cranialis (Figure 19).

The premaxillae in all six specimens terminates in a narrow point but the alveolar tubercles for the teeth roots become more prominent with age. The nasal apertures are ovoid with dorsally flattened bases and variable transverse widths.

The supraorbital margins and glabella in outline resemble an archer's bow. Glabella forms a midline prominence which is marked in specimens A, C, D and F but flattened in B and E.

The superciliary ridges extend dorsolaterally from the glabella as longitudinal elevations and are well developed in specimens A, C, D and F and less prominent in B and E.

In all the crania a median frontal boss is separated from the superciliary ridges by a postorbital groove. This groove is most marked in specimens A, C, D and F. The degree of frontal bossing is dependent on the depth of the postorbital groove.

In all specimens the dorsal surface of the zygomatic process of the frontal bone shows a ridge for the attachment of the temporal muscle.

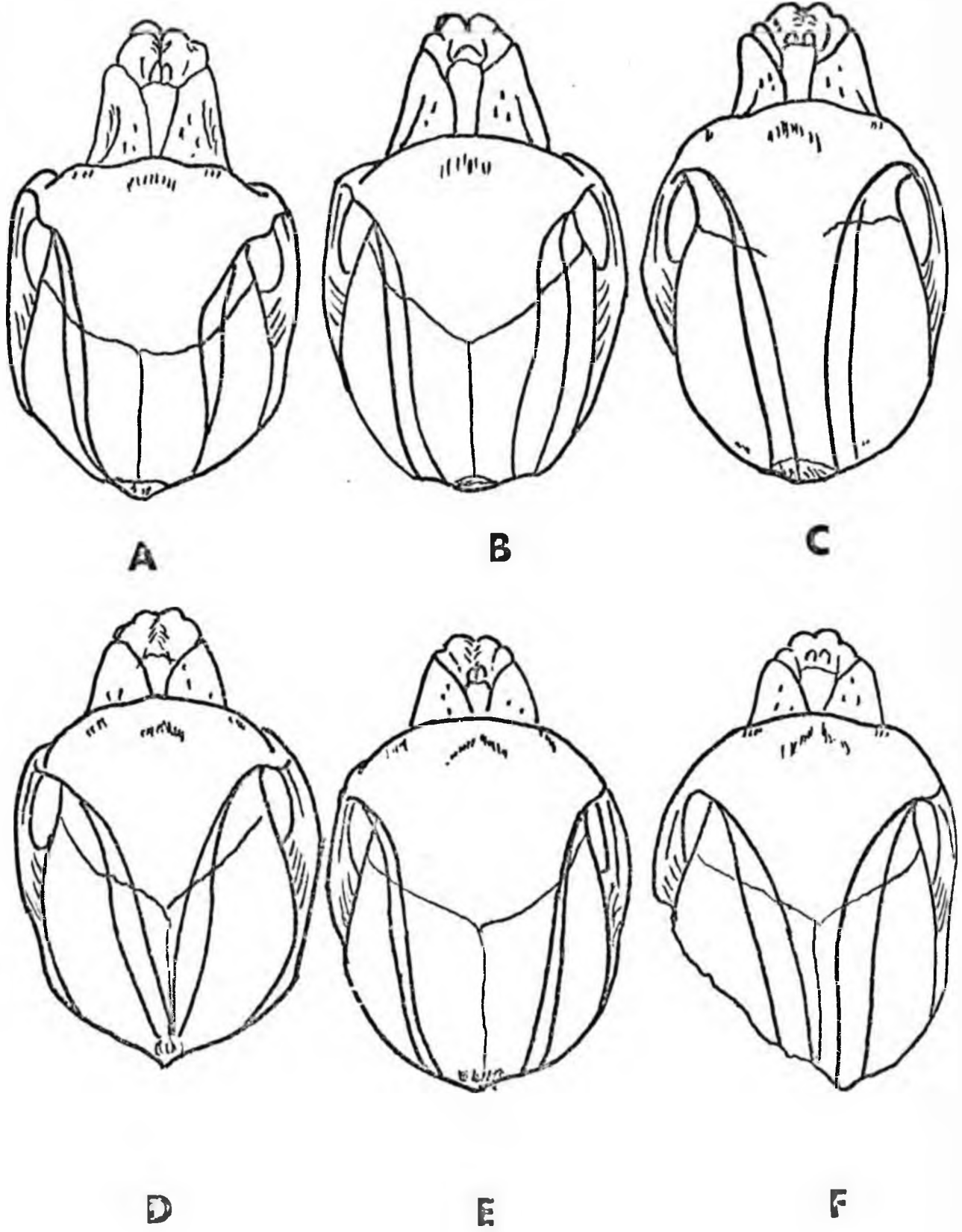


Figure 19.

Figure 19. Norma cranialis of the crania of 6  
adult female baboons from the same  
troop.

---

The temporal lines extend dorsally from the sharp dorsal margins of the zygomatic processes of the frontal bone. The development of the zygomatic processes and the height of the superior temporal lines on the parietal bones influence the degree of frontal constriction in the general ovoid outline of the neurocranium. In specimens B and C zygomatic processes of the frontal bone are narrow in a ventrodorsal direction and the frontal constriction more marked. In the other specimens these processes are well developed and form bony shelves over the ventral aspects of the cranial ends of the temporal fossae thus obscuring the frontal constriction.

The degree of the development of the zygomatic processes of the frontal bone also affects the height of the temporal lines. Small processes are associated with high temporal lines - seen in specimens B, C and D whereas the other specimens have large processes and low temporal lines.

The temporal lines of which the inferior is the more prominent, form distinct ridges over the frontal and parietal bones, when high they nearly reach the sagittal suture but do not form a crest.

Inion varies in development from a flattened eminence in specimen C to a sharp projection as in D. The development of inion does not appear to be related to the height or degree of prominence of the temporal lines. There is a slight concavity just cranial to inion in all the specimens.

#### Norma basalis.

The massive maxillae, large zygomatic bones and zygomatic arches dominate this norma view in the males. This is not the case in female crania. The maxillae are much smaller. The dental arcade is 'U' shaped with converging ends in the molar region, whereas in the male the canine incisor region gives the arcade a rectangular outline.

The temporal fossae and pterygoid fossae are not as capacious as in the male. The choanae, too, are much smaller.

The postglenoid tubercle is much smaller than in the male whereas the articular tubercle is relatively the same size as that of the male. A low articularis eminentia is present on the mandibular fossa of the female cranium.

Norma occipitalis (Figure 20)

In the female the outline of the neurocranium dominates this profile. The facial portion projects caudoventrally but is not as prominent as in the male. In the female, too, the mastoid area, zygomatic arches and palate are smaller and less robust.

The outline of the neurocranium is about  $\frac{2}{3}$  of the circumference of a circle whereas in the male it only forms about half a circle. The temporal lines are less distinct than in the male and never form a sagittal crest, although the superior temporal lines occasionally meet in the midline - as in specimen D. Thus the neurocranial outline is smooth.

The nuchal crest is not nearly as well developed as in the male. Lambda is nearer inion in the female. Inion is usually formed by the confluents of the nuchal line and external occipital crest. It varies considerably in size and shape.

The nuchal surface of the occipital bone is concave and the muscular markings are not prominent.

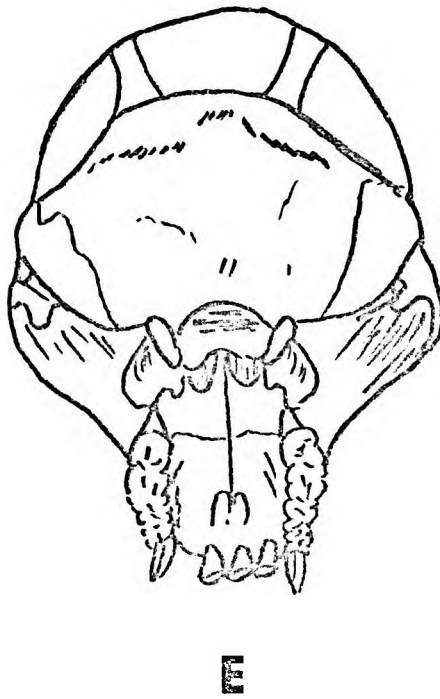
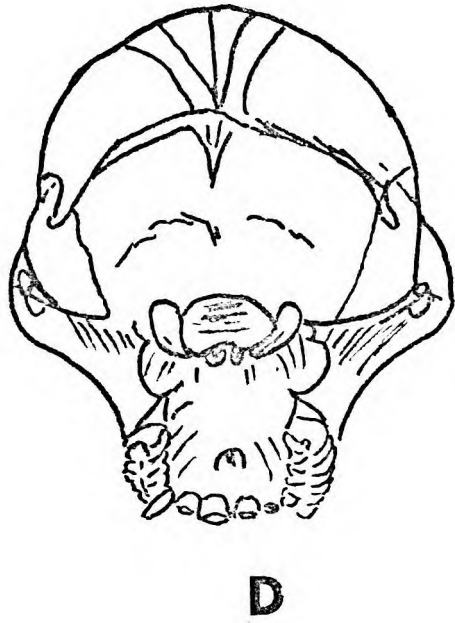
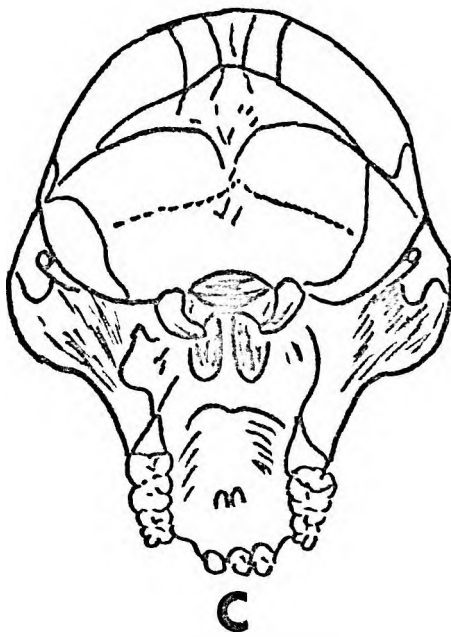
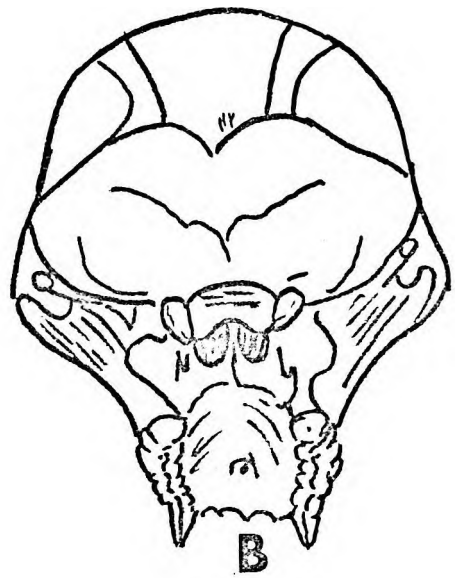
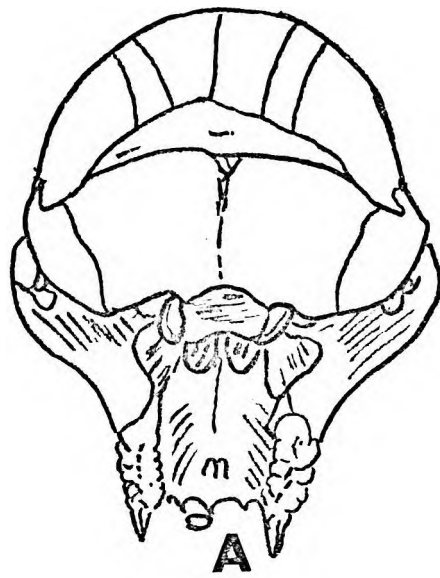


Figure 20.



Figure 20. Norma occipitalis of the cranis of 6  
adult female baboons from the same  
troop.

---

## THE SEPARATE CRANIAL BONES OF AN IMMATURE SPECIMEN

The majority of cranial bones are adequately described in the chapters on the external and internal morphology of the skull. In a description of the individual bones of the cranium only features not revealed by a study of the intact cranium will be referred to. It is significant that during the preparation of a disarticulated cranium the occipital, parietal and temporal bones, in that order, are the first to separate. Accordingly the sutural pattern between the different bones is emphasized.

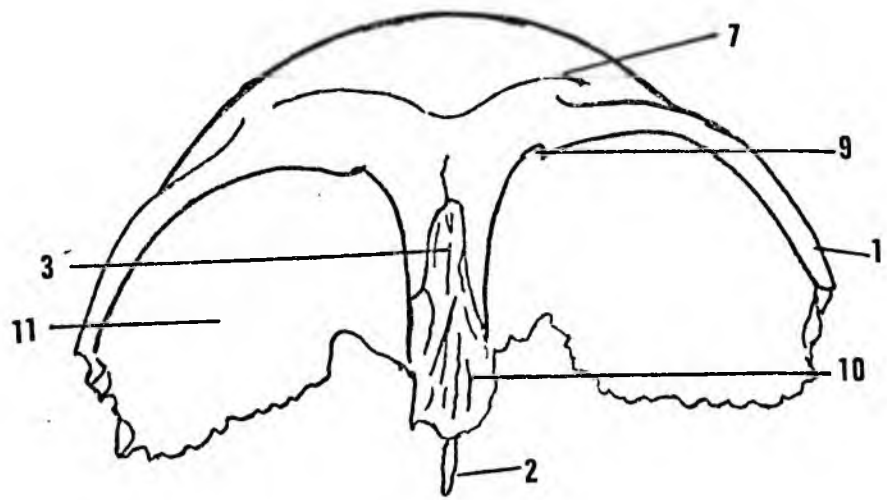
All the cranial bones except the occipital, sphenoid, vomer and ethmoid are developmentally paired bones.

The frontal bone (Figure 21) presents frontal, temporal, orbital and endocranial surfaces. The frontal surface, except for the superciliary and supraorbital ridges is convex in sagittal and transverse directions. A metopic ridge is present in young specimens whereas a metopic suture is seldom seen. The temporal surface, caudal to the temporal line, is relatively small, and convex laterally. The orbital surfaces are separated by the narrow frontonasal process. The orbital surfaces constitute the cranial two thirds of the bony walls of the orbital cavities. Two small foramina, corresponding with the anterior and posterior ethmoidal foramina in man, are found on the orbital parts of the nasal process of the frontal bone.

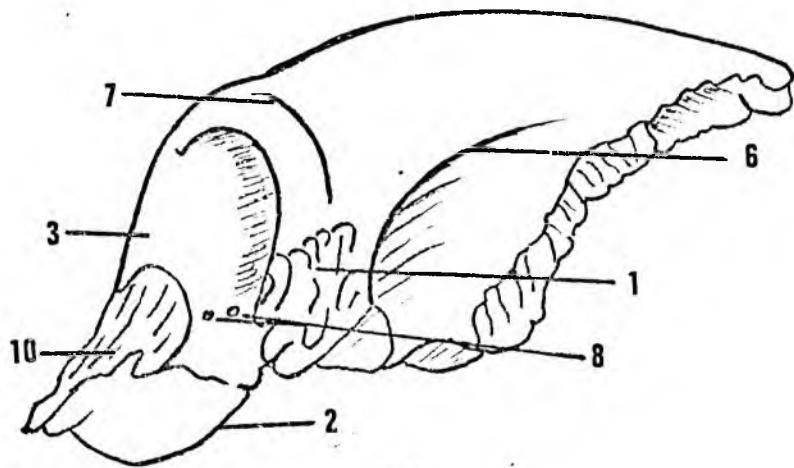
The endocranial surface forms the ventral part of the cranial cavity, It is concave in coronal and sagittal directions. The conical orbital plates are separated from each other by the olfactory pit ventrally and the olfactory sulci dorsally. Dorsal to the olfactory pit the orbital plates are separated from each other by a median ridge or suture.

#### Sutures:

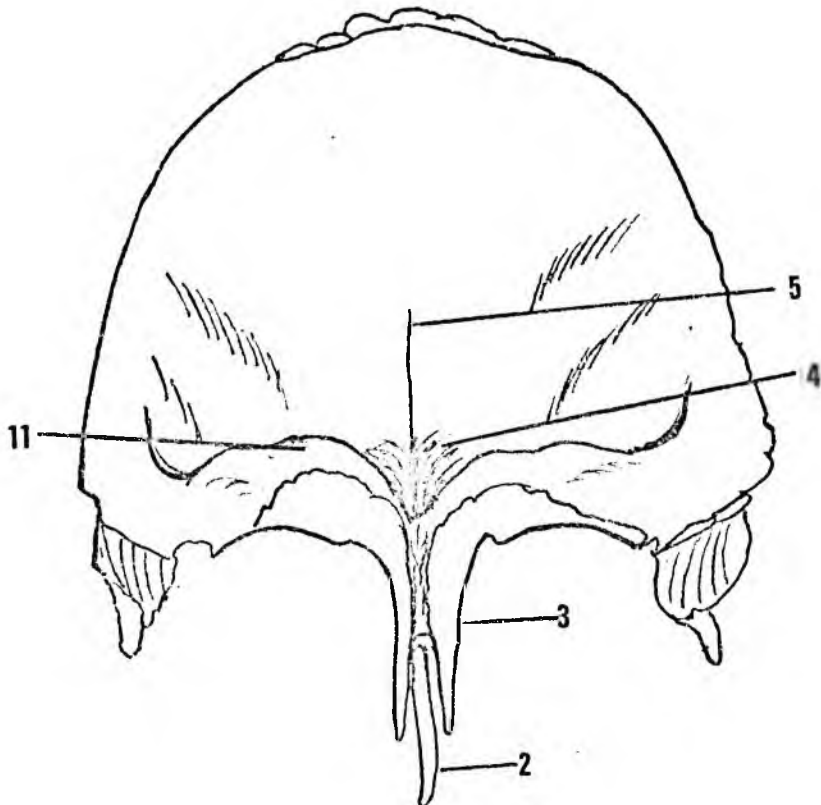
The nasal processes of the frontal bone enclose the ethmoid bone between them and give the appearance of a diploic type bone. A plane suture unites the ethmoid to the nasal processes of the frontal bone. The nasal bones have sagittally laminated tenons which fit into corresponding mortises on the nasal process of the frontal bone. Squamous sutures join the lacrimal bones to the lateral aspects of the nasal process of the frontal bone. A short metopic suture persists from the frontonasal process to the glabella.



**A**



**B**



**C**

Figure 21.

Figure 21. Frontal bone.  
A. Ventral aspect.  
B. Lateral aspect.  
C. Internal aspect.

---

1. Zygomatic process.
2. Mesethmoid.
3. Interorbital process.
4. Olfactory pit.
5. Crista frontalis.
6. Inferior temporal line.
7. Superciliary ridge.
8. Anterior and posterior ethmoidal foramina.
9. Supraorbital notch.
10. Nasal spine.
11. Orbital plate.

On the endocranial surface a fine serrated suture separates the orbital plates of the frontal bone. This suture is continued ventrally between the nasal processes of the frontal bone as a diploic type of suture. Frontal air sinuses are not present.

The frontozygomatic suture consists of a deeply laminated serrated suture cranially and a squamous portion ventrally.

Dorsally the frontal bone articulates with the presphenoid, the orbitosphenoid and the alisphenoid. These sutures are serrated except at the lateral tip of the alisphenoid where the suture is squamous.

The frontoparietal suture is a deep serratosquamous type of suture.

#### The parietal bone (Figure 22) :

The parietal bones are curved plates of bone convex on the outer surfaces and concave on their endocranial surfaces. They articulate with the frontal bone ventrally, with each other in the midline, with the alisphenoid, the squamous and the mastoid parts of the temporal bone laterally and dorsally with the squamous part of the occipital bone. The sphenoidal angle is a sharp tongue of bone while the mastoid angle is thickened to form an external prominence.

#### Sutures :

The interparietal suture is serrated, the frontoparietal and parieto-occipital are serratosquamous, while the parietotemporal and parietosphenoidal are squamous sutures. The mastoid angle articulates with the mastoid part of the temporal bone by means of a shallow mortise and tenon type of suture.

#### Occipital bone (Figure 23) :

The occipital bone is approximately leaf-shaped with squamous, condylar (exoccipital), and basilar (basioccipital) parts. The stem of the leaf is formed by the stout basilar part. The jugular processes project laterally dorsal to the jugular foramina. The grooves for the sigmoid sinuses end at the jugular notches medial to the jugular angles. The thickest parts of this bone are dorsally at lambda, at the jugular angles and ventrally where it articulates with the basisphenoid.

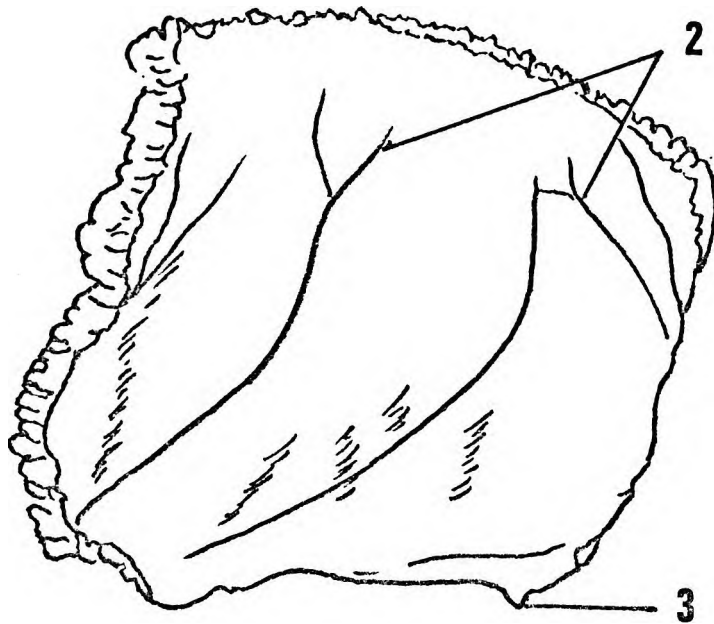
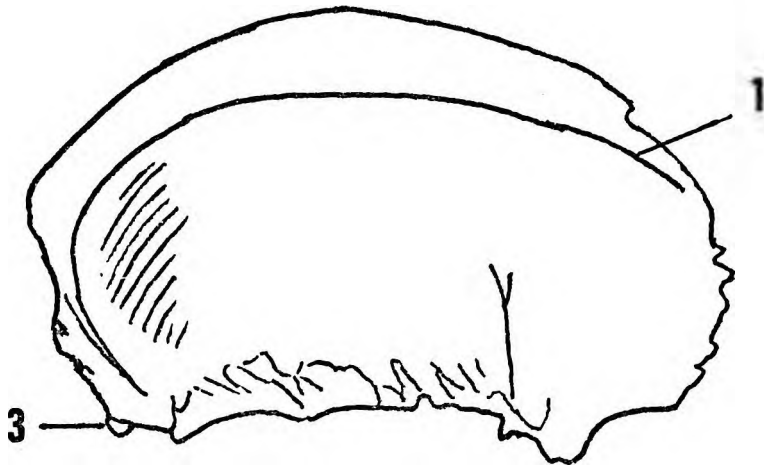


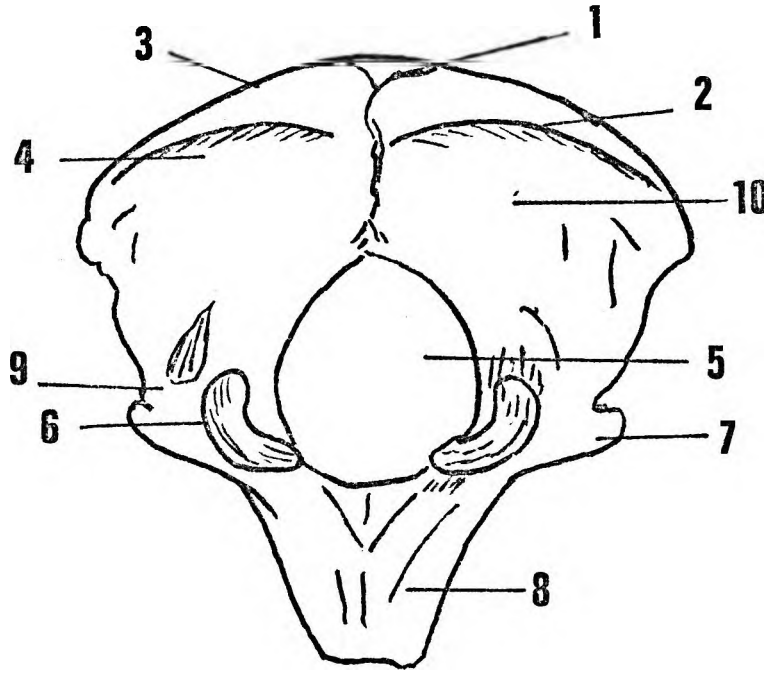
Figure 22.

Figure 22. Right parietal bone.

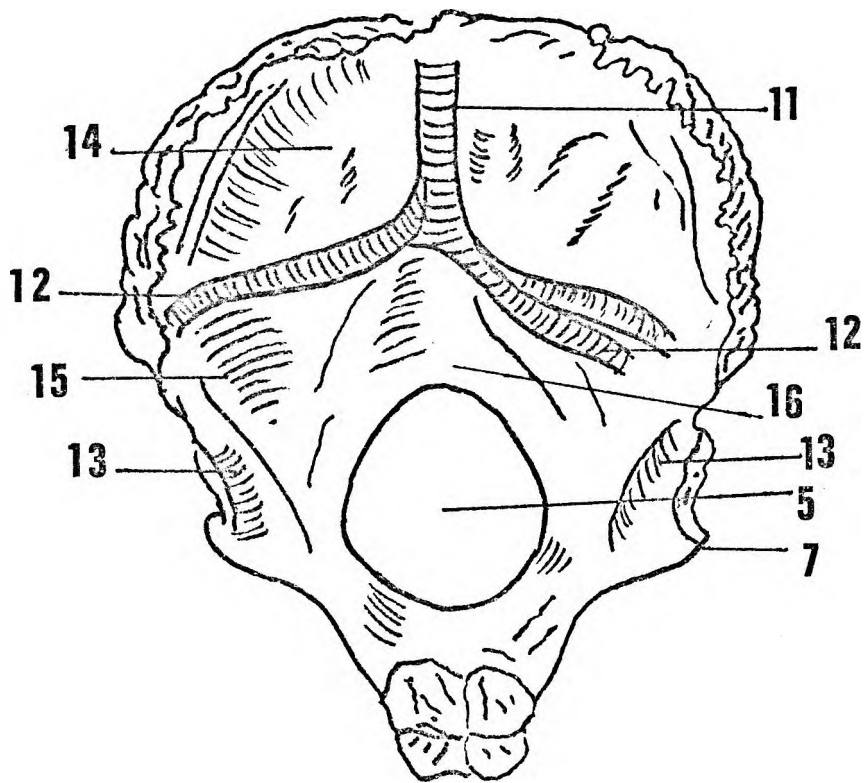
A. Lateral aspect

B. Internal aspect.

1. Inferior temporal line.
2. Branches of middle meningeal vessels.
3. Temporal process.



**A**



**B**

Figure 23.



Figure 23. Occipital bone.  
A. Nuchal aspect.  
B. Internal aspect.

---

1. Inion.
2. External occipital crest.
3. Nuchal crest.
4. Inferior nuchal line.
5. Foramen magnum.
6. Occipital condyle.
7. Jugular process.
8. Basioccipital part.
9. Exoccipital part.
10. Squamous occipital part.
11. Groove for superior sagittal sinus.
12. Groove for transverse sinus.
13. Groove for sigmoid sinus.
14. Fossa for occipital pole.
15. Cerebellar fossa.
16. Fossa for vermis.

### Sutures:

Ventrally the sphenoccipital synchondrosis joins the basilar part of the occipital bone to the basisphenoid. The basilar part is separated from the petrous parts of each temporal bone by a deep fissure which enlarges to form the jugular foramen and continues dorsally as a serrated suture between the squamous part of the occipital bone and the mastoid portion of the temporal bone. The jugular angle forms an overlapping plane joint with the ventromedial part of the mastoid portion of the temporal bone. The parietooccipital suture is a squamoserrated type of suture.

### The temporal bone (Figure 24):

Each temporal bone consists of zygomatic, squamous, petrous, tympanic and mastoid parts. The zygomatic portion is separated from the squamous portion by a wide cranially concave ledge. Ventrally it articulates with the temporal process of the zygomatic bone. The cranial surface is smooth. The caudal surface bears the articular facet for the temporomandibular joint. The articular facet is flanked laterally by the articular tubercle and dorsally by the large postglenoid tubercle. The prootic fissure corresponds with the petrotympanic fissure in man and the dorsal wall is composed of ragged spurs of bone derived from the petrous portion.

The squamous portion is gently convex and slopes cranially and medially towards the parietal bone. Internally it is separated from the petrous and tympanic parts by the deep prootic fissure which extends from the bony opening of the Eustachian canal medially to the postglenoid foramen laterally.

The caudal surface of the temporal bone presents an articular facet, a tympanic portion, a petrous portion and a mastoid area. The articular facet is shallow - concave transversely and concave ventrodorsally. It is separated from the postglenoid tubercle by a deep groove. The articular tubercle is a slight ridge on the lateral border of the articular facet. The tympanic portion is a bony tube extending dorsolaterally from the petrous part of the bone. The external auditory meatus is nearly a complete ring of bone lying in a deep furrow between the postglenoid tubercle and the mastoid area.

The petrous part is smooth and roughly pyramidal in shape. Ventrolaterally a bony spur covers the bony part of the Eustachian tube.

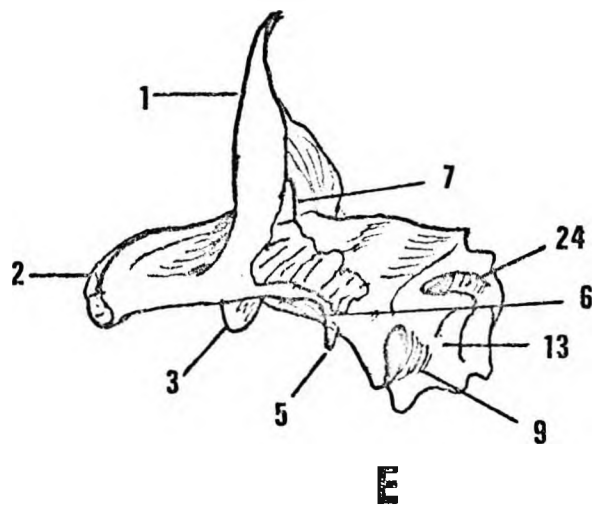
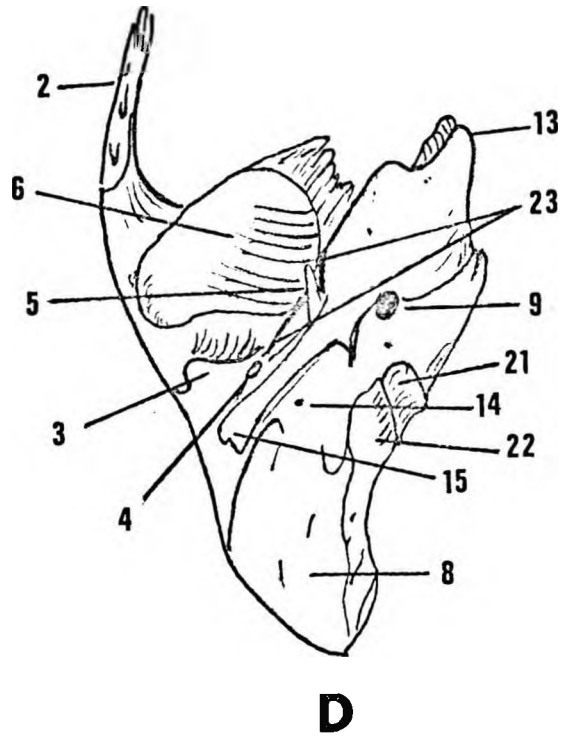


Figure 24.

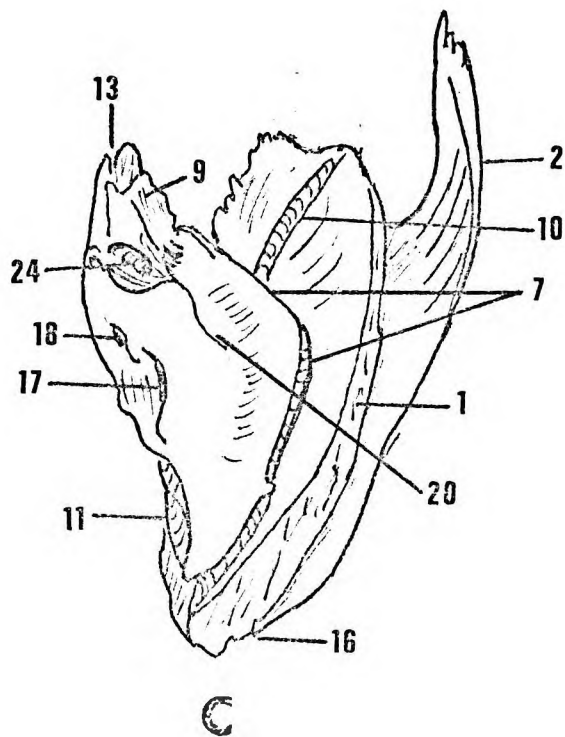
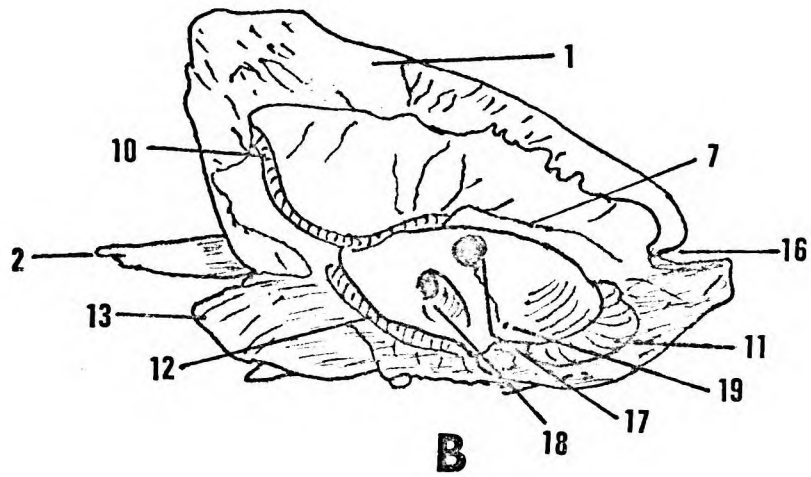
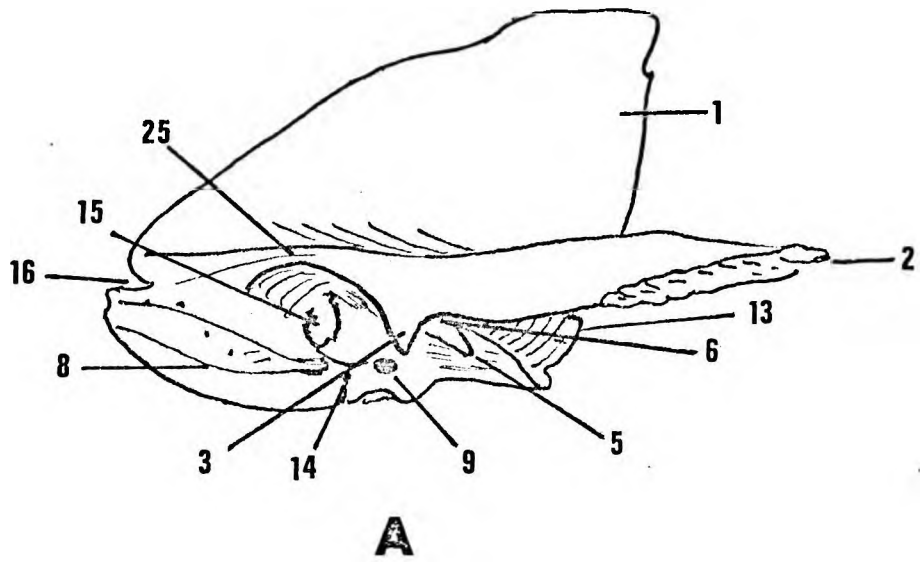


Figure 24.

Figure 24. Right temporal bone.  
A. Lateral aspect.  
B. Medial aspect.  
C. Cranial aspect.  
D. Caudal aspect.  
E. Ventral aspect.

---

1. Squamous portion.
2. Zygomatic process.
3. Postglenoid tubercle.
4. Postglenoid foramen.
5. Process for sphenomandibular ligament.
6. Mandibular fossa.
7. Petrosquamous fissure and Prootic sinus.
8. Mastoid area.
9. Carotid canal.
10. Middle meningeal vessels.
11. Sigmoid sinus.
12. Inferior petrosal sinus.
13. Articulation with sphenoid.
14. Stylomastoid foramen.
15. External auditory meatus.
16. Parietal notch.
17. Floccular fossa.
18. Internal auditory meatus.
19. Ductus endolymphaticus.
20. Groove for greater superficial petrosal nerve.
21. Jugular fossa.
22. For jugular process.
23. Petrotympenic fissure.
24. Eustachian tube.
25. Supramastoid crest.

The external opening of the carotid canal lies at the medial extremity of the Eustachian tube and is separated from the stylo-mastoid foramen by a bony ridge. The styloid process varies in size from a spine of about half a centimetre in length to a small bony spur, and is not always a separate bone.

The external opening for the chorda tympani nerve occurs either in the depths of the prootic fissure or as a separate foramen at the ventromedial end of the Eustachian tube. The stylo-mastoid foramen lies on the ventromedial aspect of the medial mastoid prominence. In adult males this prominence may partly cover the foramen. A shallow sulcus for the occipital artery occurs dorsal to the facet for the jugular process of the occipital bone.

The mastoid portion is roughened externally by muscle attachments. It consists of thick bone containing numerous air sinuses and extends from the medial prominence to the lateral prominence dorsal to the external auditory meatus.

When viewed from the ventral aspect (Figure 24) the apex of the petrous part of the temporal bone separates the internal opening of the carotid canal medially and from the bony opening of the Eustachian tube laterally. Dorsolateral to the internal opening of the carotid canal two small sulci on the cerebral surface indicate the positions of the greater and lesser superficial petrosal nerves. Dorsal to these sulci is the large arcuate eminence covering the subarcuate fossa.

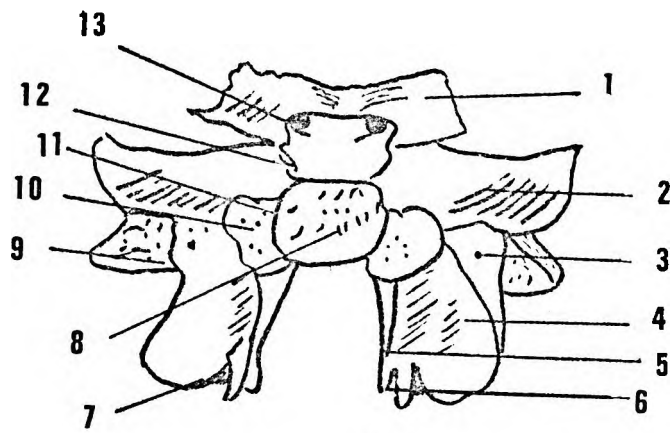
The medial aspect of the petrous part of the temporal bone presents the internal auditory meatus, the subarcuate fossa and caudal to this a bony shelf covering the opening of the ductus endolymphaticus.

#### Sutures :

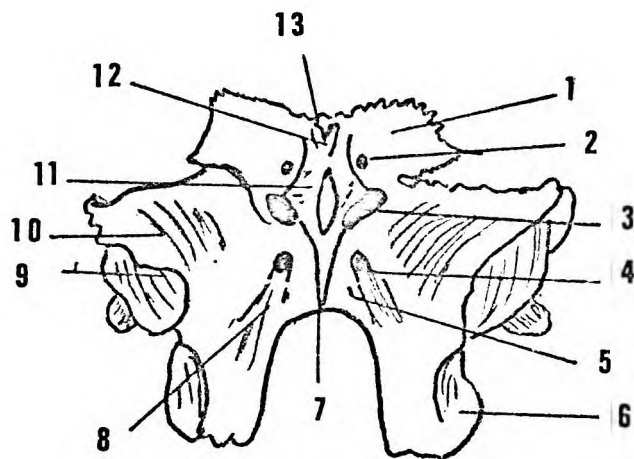
The temporosphenoidal and temporozygomatic sutures are deep mortise and tenon type sutures.

#### The sphenoid bone (Figure 25).

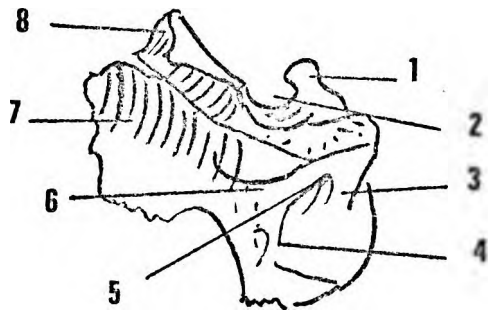
The sphenoid bone consists of a central body from which project ventrally the orbitosphenoids (lesser wings), laterally the alisphenoids (greater wings) and caudally the pterygoid processes. The body is also separated by a synchondrosis just dorsal to the tuberculum sellae into a presphenoid and a postsphenoid. In young specimens lateral synchondroses separate the alisphenoids from the postsphenoid.



**A**



**B**



**C**

Figure 25.

Figure 25. The sphenoid bone.

A. Dorsal aspect.

- |    |                           |     |                         |
|----|---------------------------|-----|-------------------------|
| 1. | Orbitosphenoid.           | 7.  | Palatine articulation   |
| 2. | Alisphenoid.              | 8.  | Basisphenoid.           |
| 3. | Middle meningeal foramen. | 9.  | Pterygoalar bar.        |
| 4. | Lateral plate.            | 10. | Petrous articulation.   |
| 5. | Medial plate.             | 11. | Pterygoid canal         |
| 6. | Hamulus.                  | 12. | Dorsal orbital fissure. |
|    |                           | 13. | Optic foramen.          |

B. Ventral aspect.

- |    |                        |     |                        |
|----|------------------------|-----|------------------------|
| 1. | Orbitosphenoid         | 6.  | Lateral plate.         |
| 2. | Optic foramen          | 7.  | Rostrum crest.         |
| 3. | Dorsal orbital fissure | 8.  | Sphenomaxillary fossa. |
| 4. | Foramen rotundum       | 9.  | Temporal surface.      |
| 5. | Pterygoid canal        | 10. | Alisphenoid.           |
|    |                        | 11. | For vomer.             |
|    |                        | 12. | Interorbital process.  |

C. Lateral aspect.

- |    |                    |    |                           |
|----|--------------------|----|---------------------------|
| 1. | Dorsum sellae.     | 5. | Middle meningeal foramen. |
| 2. | Hypophyseal fossa. | 6. | Sphenomaxillary fossa.    |
| 3. | Pterygoalar bar.   | 7. | Alisphenoid.              |
| 4. | Lateral pterygoid. | 8. | Orbitosphenoid.           |



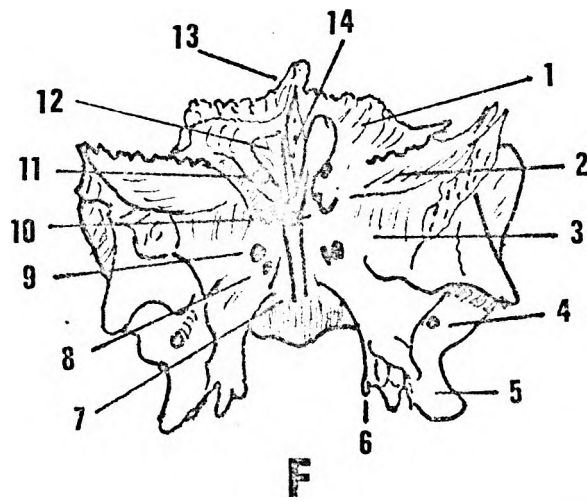
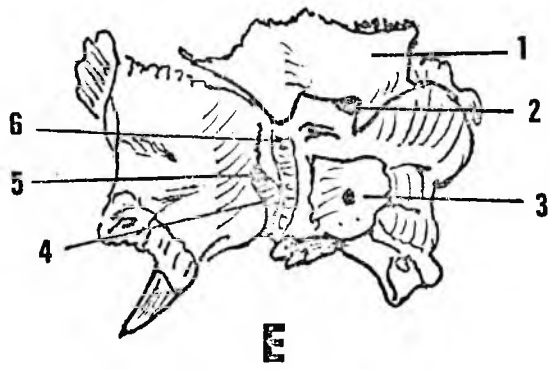
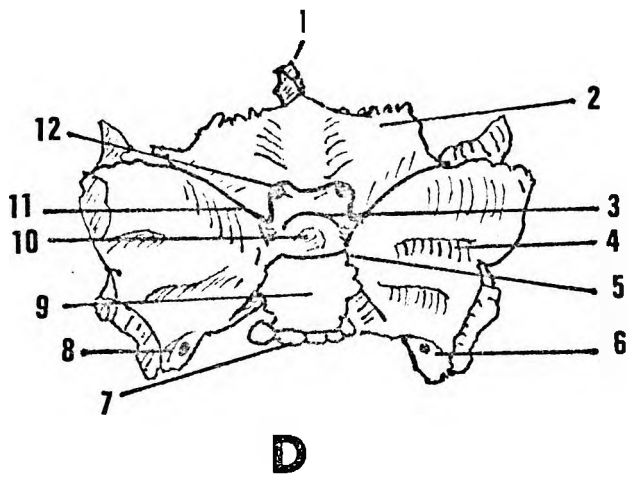


Figure 25.

Sphenoid D. Cranial aspect.

1. Interorbital process.
2. Orbitosphenoid.
3. Pre-post sphenoid synchondrosis.
4. Alisphenoid.
5. Dorsal clinoid process.
6. Pterygoalar bar.
7. Basisphenoid synchondrosis.
8. Middle meningeal foramen.
9. Dorsum sellae.
10. Hypophyseal fossa.
11. Ventral clinoid process.
12. Optic foramen.

Sphenoid E. Oblique view dorsal aspect.

1. Orbitosphenoid.
2. Optic foramen.
3. Dorsum sellae.
4. Groove for maxillary nerve.
5. Foramen rotundum.
6. Groove for internal carotid artery.

Sphenoid F. Caudal aspect.

1. Orbitosphenoid
2. Alisphenoid
3. Sphenomaxillary fossa.
4. Middle meningeal foramen.
5. Lateral pterygoid plate.
6. Hamulus.
7. For vomer.
8. Pterygoid canal.
9. Foramen rotundum.
10. Dorsal orbital fissure.
11. Optic foramen.
12. Presphenoid.
13. Interorbital process
14. Postsphenoid.

The body, consisting of presphenoids and postsphenoids is rectangular, and consists of a thick core of cancellous bone.

There are no sphenoidal air sinuses. The presphenoid gives rise to the orbitosphenoids and is related to the optic chiasma. The hypophyseal fossa and the dorsum sellae are found on the dorsal aspect of the post sphenoid. Laterally are the alisphenoids and caudally the pterygoid processes.

Laterally, on either side, a suture separates the orbitosphenoid from the alisphenoid. The endocranial surface of the orbitosphenoid faces craniodorsally. The orbitosphenoids are separated from each other by a medial ridge on the presphenoid and the grooves for the olfactory nerves. The jugum sphenoidale is smooth and there is no ethmoidal spine. The wings of the orbitosphenoid form the dorsal parts of the roofs of the orbital cavities while the presphenoid projects caudally as a wedge of bone forming the dorsal and medial parts of the orbital cavities.

The alisphenoids, on their endocranial surfaces, form deep fossae for the temporal lobes of the cerebrum. Medially they are joined to the postsphenoid by wide thick bars of bone through which the canals for the maxillary divisions of the trigeminal nerve and the nerves of the pterygoid canal pass. Laterally the alisphenoids are thick and articulate with the temporal bone. The orbital surfaces of the alisphenoid are directed ventromedially and form the dorsal parts of the orbital cavities and the dorsolateral walls of the caudal orbital fissure.

The ventral openings of the canals for maxillary nerves and the nerves of the pterygoid canals are found ventral to the body of the postsphenoid in a deep sulcus between the pterygoid plates and the alisphenoids. The openings of the pterygoid canals may be round or linear slits (Figure 25B).

The medial and lateral pterygoid processes arise caudally from the post sphenoid and alisphenoids respectively. The medial processes are small while the lateral processes are large and enclosed between them are the pterygoid fossae. On the craniodorsal aspects of the medial pterygoid processes and on either side of the postsphenoid are concavities which receive the apices of the petrous parts of the temporal bones. The dorsal openings of the pterygoid canals lie cranial to these concavities. Caudally the medial pterygoid plates give rise to the pterygoid hamuli and then fuse with the lateral plates to articulate with palatine bones.

### Sutures :

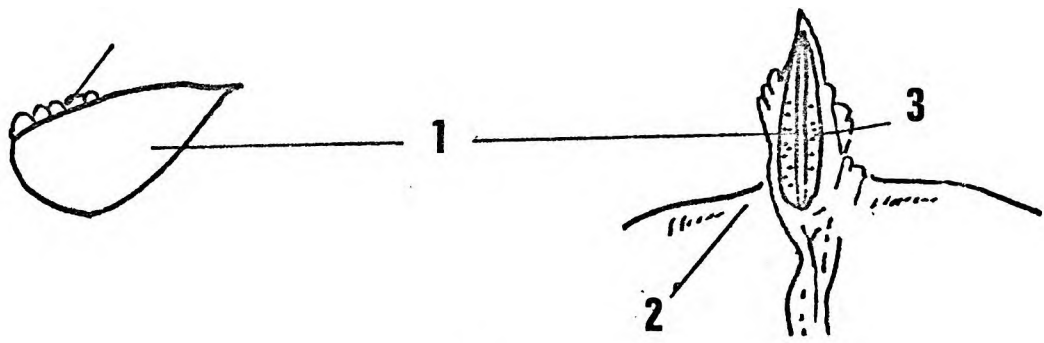
The orbitosphenoid has a jagged serrated fissure uniting it to the orbital plates of the frontal bone. The presphenoid has a 'T' shaped ventral process which articulates with the dorsal part of the interorbital processes of the frontal bone. Caudally the presphenoid has a flange which articulates with the separate halves of the vomer. Serrated sutures join the alisphenoids on either side to the orbital plates of the frontal bone while squamous sutures articulate the lateral angles of the alisphenoid with the temporal surfaces of the frontal bone. Ventrally wide serratosquamous sutures form the union between the alisphenoids and zygomatic bones in the floors of the orbital cavities. The pterygopalatine sutures are serrated.

### The ethmoid (Figure 26A) :

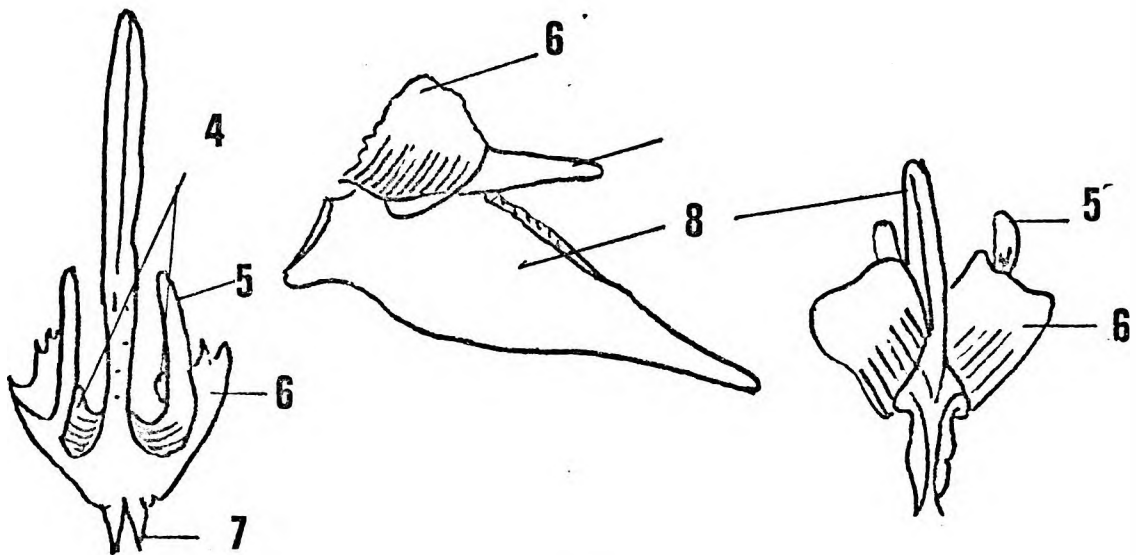
The ethmoid consists of cribriform and median nasal septal parts. The cribriform part lies in the depth of the pear shaped olfactory pit between the nasal and interorbital processes of the frontal bone. Each plate is pierced by 6 to 8 foramina. The septal part is semilunar in outline and passes ventrally to articulate with the cranial surface of the vomer.

### The vomer (Figure 26B) :

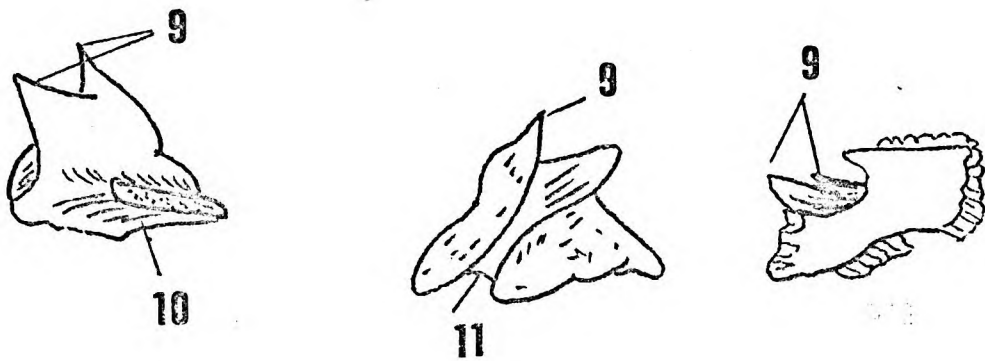
The vomer has sphenoidal, nasal septal and orbital portions. It does not resemble an old fashioned plough share but is more like a modern double flanged ridging share. The sphenoidal part is bilaminar and articulates with the nasal aspect of the body of the sphenoid. The nasal septal portion is a long narrow triangle extending ventrally to articulate with cranial aspects of the interpalatine and intermaxillary sutures. The palatal edge of the vomer is flattened and forms a triradiate type of articulation with the bones of the hard palate. Cranially the nasal septal part articulates with the septal part of the ethmoid. The orbital portions arise from the sphenoidal part as wide flanges and extend ventrally to form parts of the medial walls of the orbital cavities as well as portions of the dorsolateral walls of the nasal cavities. Dorsally they form shallow 'sphenoidal' air sinuses on either side of the nasal septum. Superior and middle conchae develop on the nasal side of the orbital plates.



A



B



C

Figure 26.

Figure 26. A. Ethmoid.

Right side.

Nasal and caudal aspect.

1. Mesethmoid.
2. Interorbital process.
3. Cribriform plate.

B. Vomer.

Caudal, lateral and cranial aspects.

4. Superior turbinals.
5. Middle turbinal.
6. Orbital plate.
7. Ala.
8. Nasal septum.

C. Left palatine bone.

Medial, lateral and caudal aspect.

9. Nasal spines.
10. Palatal surface.
11. Greater palatine canal.

The palatine bone (Figure 26) :

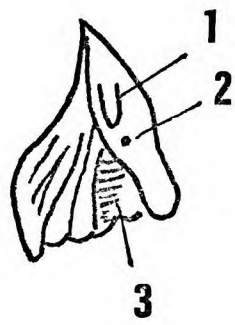
Each palatine bone has a horizontal palatal portion, a dorsal pterygoid portion and a cranial nasal portion. The palatal portions articulate in the midline at the interpalatine suture. Ventrally and laterally they articulate with the maxillary bones. The foramina for the middle palatine nerve are covered by bony spurs, and lie between the palatine and the maxillary bones. Dorsally and medially each palatine bone forms a palatine spine which extends cranially to septal part of the vomer. The pterygoid processes extend dorsolaterally to complete the ventral aspects of the pterygoid fossae. Lateral to the pterygoid hamuli the pterygoid processes are roughened by the attachment of the muscles of the soft palate. Small triangular portions of the pterygoid processes of the palatine bones are interposed between the lateral pterygoid laminae and the maxillary bones to form part of the bony wall of the infratemporal fossae. The nasal portions have ventral and dorsal projections, which form part of the dorsolateral walls of each nasal cavity and cover the dorsomedial aspects of the maxillae. The dorsal projections lie on the medial pterygoid lamina and their apices reach up to the vomer. The ventral projections are smaller and pass cranially to articulate with the inferior conchae.

The lacrimal bones (Figure 27) :

The lacrimal bones are small approximately triangular bones on the ventral aspects of the medial walls of the orbital cavities. Each lacrimal bone has orbital, nasal and ventral surfaces. The orbital surface is concave and is pierced by the large bony canal for the nasolacrimal ducts. Lateral to this larger canal are 1 to 3 smaller canals for the accessory nasolacrimal ducts. The nasal surface forms the cranial part of the lateral wall of the nasal cavity and lies adjacent to the cribriform plate. The ventral surface is covered medially by the nasal bone and laterally by the nasal processes of the maxilla. The nasolacrimal duct enters the nasal cavity between these bones. The sutures for articulation with adjoining bones are squamous.

The zygomatic bones (Figure 28) :

The zygomatic bones are irregular in shape. Each has orbital, temporal and ventral surfaces as well as temporal, maxillary and frontal processes articulating respectively with temporal, maxillary and frontal bones.



**A**



**B**

Figure 27.

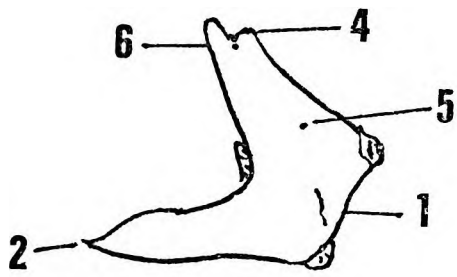


Figure 27. The left lacrimal bone.

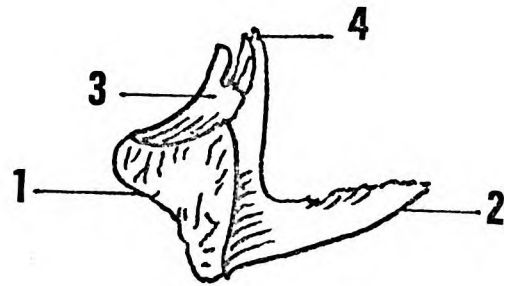
A. Orbital surface.

B. Nasal surface.

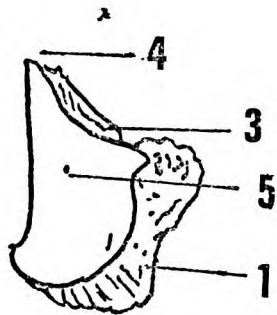
1. Nasolacrimal fossa.
2. Accessory duct.
3. Nasolacrimal duct.



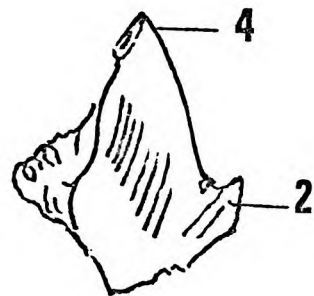
**A**



**B**



**C**



**D**

Figure 28.

Figure 28.     Right zygomatic bone.

- A. Lateral aspect.
- B. Medial aspect.
- C. Ventral aspect.
- D. Dorsal aspect.

- 1. Maxillary process.
- 2. Temporal process.
- 3. Orbital surface.
- 4. Frontal process.
- 5. Zygomaticofacial foramen.
- 6. Zygomaticotemporal foramen.

The orbital surface is deeply concave and crossed in a ventrolateral direction by a groove leading to a canal (in the body of the zygomatic bone) for the zygomaticofacial nerve. The temporal surface is concave dorsally and may present a vertical bony ridge. The ventral surface is rounded cranially and concave ventrally where it participates in the formation of the maxillary fossa.

#### Sutures :

The zygomaticomaxillary suture is a mortise and tenon device so arranged that the ventral, cranial and dorsal regions are raised to articulate with corresponding depressions on the maxilla. This arrangement gives an interlocking effect which is not easily disarticulated and once disarticulated defies accurate reduction. The orbital plate and frontal process articulate with the alisphenoid and zygomatic process of the frontal bone respectively. The former is a mortise and tenon type of articulation, the intervening portion serratosquamous and the zygomaticofrontal suture a 'V' shaped interlocking mortise and tenon type. The articular surface on the temporal process faces craniodorsally, and consists of a series of deep serrations on a central elevation. These serrations fit into linear pitted depressions on the caudoventral aspect of the zygomatic process of the temporal bone.

#### The maxillae (Figure 29) :

The maxillae are paired bones which together with the fused nasal bones and premaxillae form the upper jaw. Each maxillae has a nasal, a cranial and a palatal surface, as well as a nasal, zygomatic, palatine and alveolar processes. Dorsally the maxilla projects into the infratemporal fossa and sphenomaxillary fissure. The body of the maxilla is large and robust and carries the alveolar process for the canines, premolars and molars. A maxillary ridge separates the cranial surface from the lateral surface. The cranial surface is flat or slightly concave. The maxillary ridge can be traced dorsally from the root of the canine to the infraorbital region. The maxillary fossa varies in size and depth. Seven or more foramina occur where the maxillary ridge joins the infraorbital region. A number of these foramina lie in the dorsal part of the maxillary fossa. The numerous branches of the infraorbital nerve emerge through these foramina and pass ventrally lying at first in shallow grooves ventral to the foramina. The frontal process projects cranially as a sharp spike. Its lateral edge forms the medial border of the orbital cavity. The tip of the frontal process articulates with the frontal bone at the medial wall of the orbital cavity.

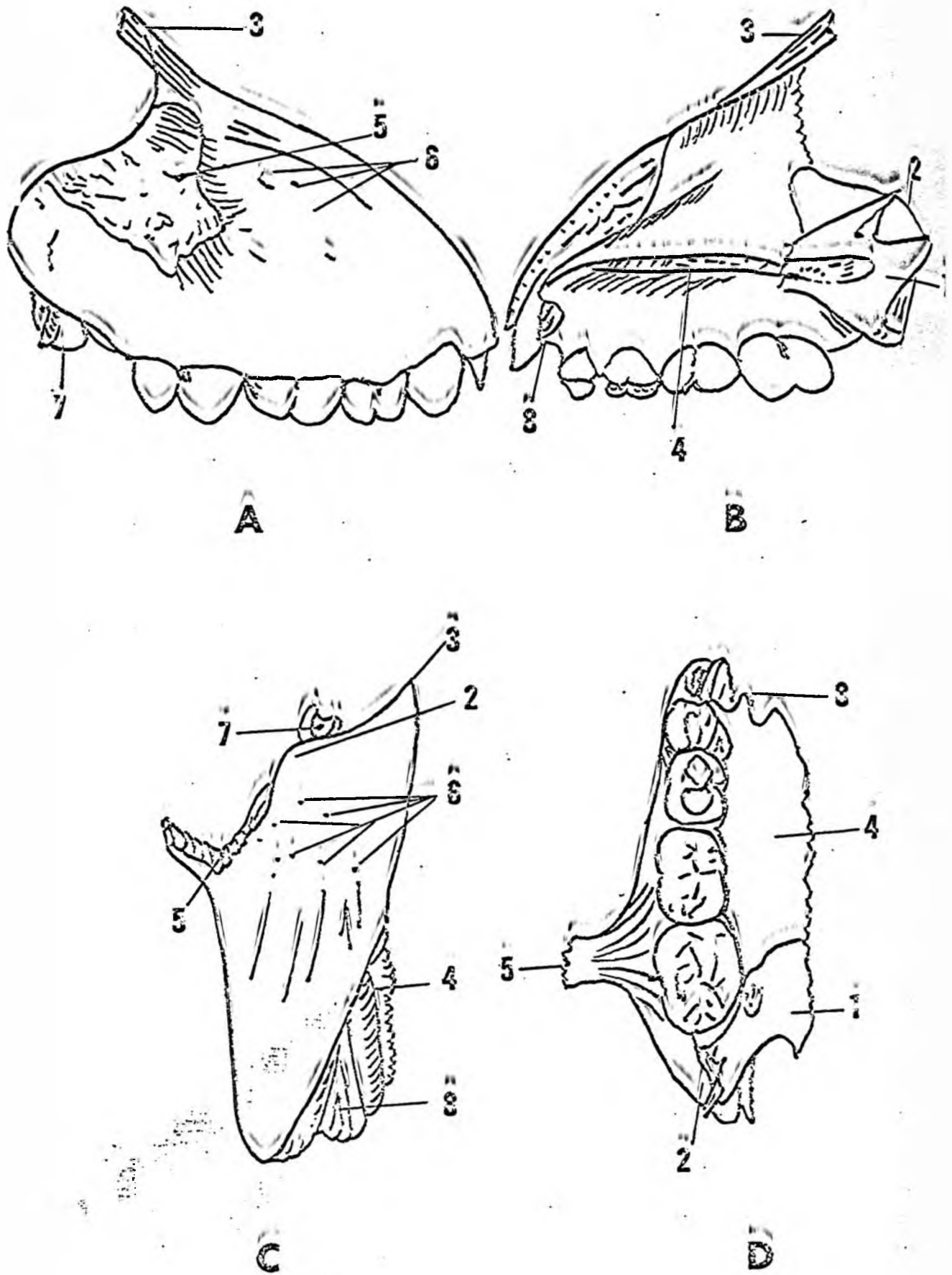


Figure 29.

Figure 29. The right maxilla.

- A. Lateral aspect.
  - B. Medial aspect.
  - C. Cranial aspect.
  - D. Caudal aspect.
- 

- 1. Palatine bone.
- 2. Tuberosity.
- 3. Orbital process.
- 4. Palatine process.
- 5. Zygomatic process.
- 6. infraorbital foramina.
- 7. Alveolar canals.
- 8. Premaxilia socket.

The nasal bone articulates with the medial border of the body of the maxilla and the frontal process.

The zygomatic process extends dorsolaterally to articulate with the zygomatic bone. A large stout buttress which is developed from the retro-molar part of the alveolus, participates in this articulation.

The dorsal part of the maxilla is large and projects dorsally towards the infraorbital fossa. Its external surface is smooth. Medially the dorsal part articulates with the nasal processes of the palatine bone. Cranial to the ventral process of the maxilla is a concavity in which the maxillary sinus lies (Figure 29B & 32C). The bony walls of the sinus are formed by - i) the maxillae laterally, ii) the lacrimal bone and orbital plate of the vomer cranially, iii) the ventral process of the palatine bone and the maxilla dorsally, and iv) the dorsal curvature of the inferior concha ventrally. The medial wall of the sinus is a double layer of mucous membrane. A circular plate of bone occasionally reinforces the medial wall. The nasolacrimal duct lies in a bony canal ventrocranial to the sinus and enters the inferior meatus ventral to the dorsal curvature of the inferior concha. The accessory nasolacrimal ducts emerge lateral to the main duct.

The palatine process is concave dorsally in both the sagittal and transverse directions. It projects medially to unite with the opposite palatine process in the midline. The nasal surface of the palatine process is smooth whereas the lingual surface is pitted by numerous vascular foramina and grooved by branches of the nasopalatine and middle palatine nerves. The nasal surface of the maxilla is concave but presents a ridge to which the inferior concha is attached. This ridge lies on a larger eminence which is formed over the alveolus of the canine.

The premaxillary process has a deep pit into which the premaxilla articulates. The floor of the pit is smooth and covers the canine. The alveolar and nasal edges have deep mortise and tenon like serrations. The palatine portion of the pit is prolonged dorsally. The whole premaxillomaxillary articulation is thus a combination of mortise and tenon together with a peg and socket type of joint. (Figure 45A).

#### The premaxilla (Figure 30) :

Even in young specimens the premaxillae are fused to form a single bone. The premaxilla carries the incisors and is separated externally into right and left halves by a median groove.

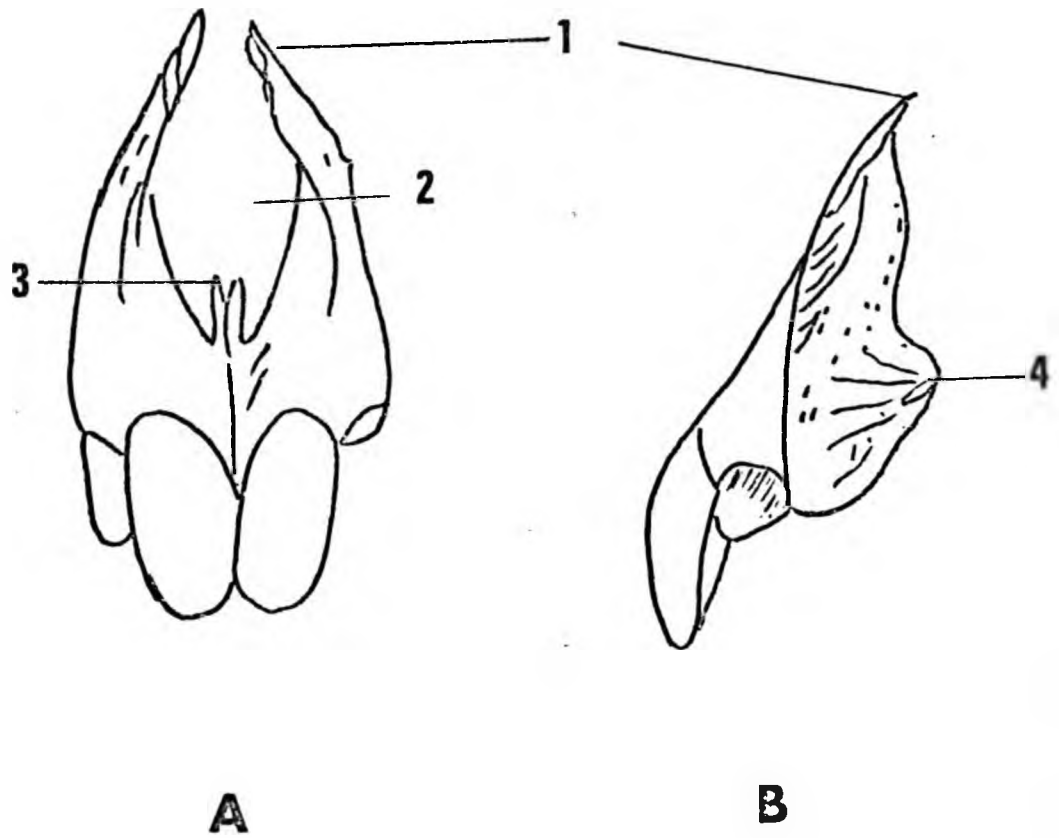


Figure 30.



Figure 30. The premaxilla.

A. Ventral aspect.

B. Lateral aspect.

1. Nasal process.
2. Nasal aperture.
3. Palatine processes.
4. Peg for maxillary socket.

The nasal aperture is formed ventrally and laterally by the premaxillae and its nasal processes. Cranially the fused nasal bones complete the nasal aperture. The external and nasal surfaces are smooth. The nasal processes curve medially and cranially as two narrow spikes.

The palatal surface is concave in all directions and in the midline two slender lamellae extend dorsally to lie on the cranial aspect of the vomer. The cartilaginous part of the nasal septum articulates with these lamellae. The lamellae remain separate throughout life and on either side the premaxilla is widened to form the bony walls of the vestibule of the palato-nasal canal.

#### Nasal bones (Figure 31) :

The nasal bones fuse in early postnatal life but a short internasal suture may persist in the interorbital region. From a wide ventral base the fused nasal bones extend dorsally wedge-like between premaxillae, the maxillae and lacrimal bones to the frontal bone. The external surface is smooth whereas only the ventral  $\frac{1}{5}$  of the nasal surface is smooth. The lateral and nasal surfaces are covered by deep lamina for a mortise and tenon type of articulation with the adjoining bones.

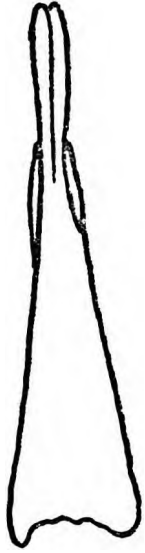#### Caudal concha (Figure 32) :

The caudal conchae are thin leaf-like bones attached to crests on the medial side of each maxilla. The dorsal ends curve medially to articulate with the vomer and the lacrimal bones, so that concave recesses are formed into which the nasolacrimal ducts discharge.

#### The nasal septum and medial aspect of the nasal cavity (Figure 32 A.B.& C) :

The bony part of the nasal septum consists of the septal part of the ethmoid cranially and the septal part of the vomer caudally (Figure 32A is a sagittal view of a cranium of a young adult male baboon). Apart from the formation of the bony septum Figure 32 also illustrates the deep olfactory pit, the nearly obliterated intersphenoidal synchondrosis and the occipito-sphenoidal synchondrosis. The latter synchondrosis shows a distinct bony plate between the occipital and sphenoidal parts.

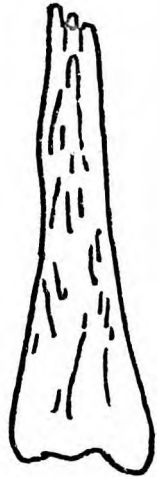
In Figure 32B the septal parts of the ethmoid and vomer have been removed to show the relationship of the caudal, middle and cranial nasal conchae. This figure also illustrates how the ventral and dorsal processes of the palatine bone surround the dorsal part of the maxilla. The sphenomaxillary fissure is seen from the medial aspect.



**A**



**B**

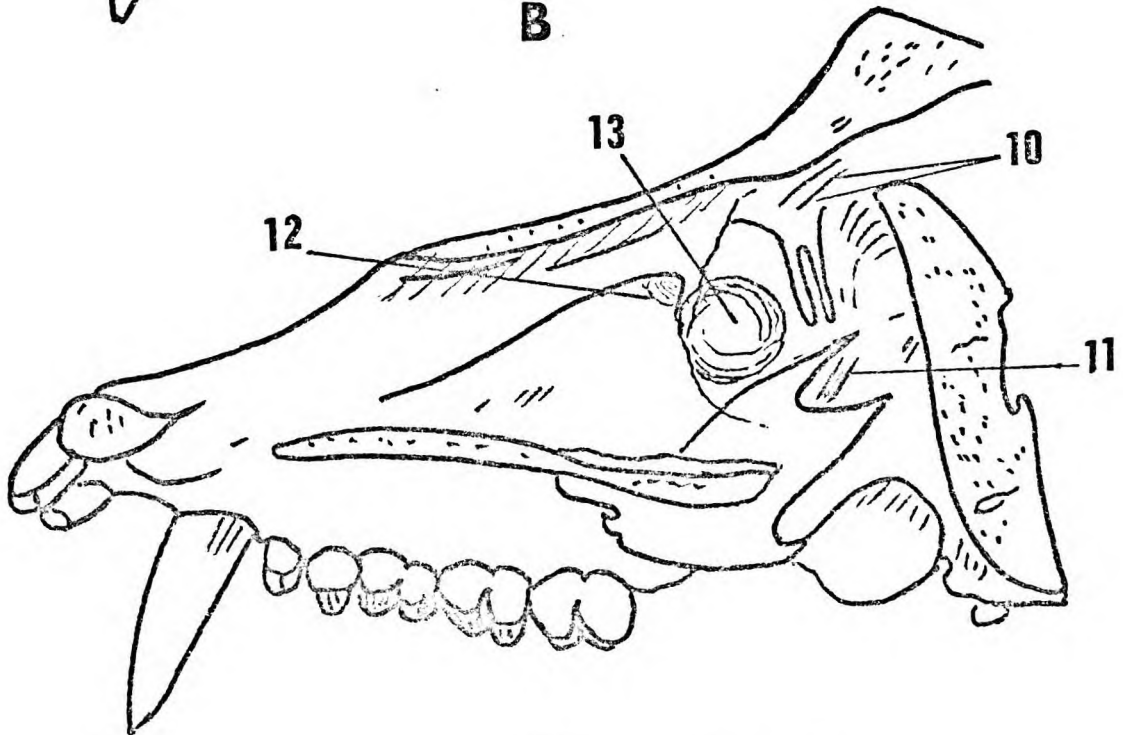
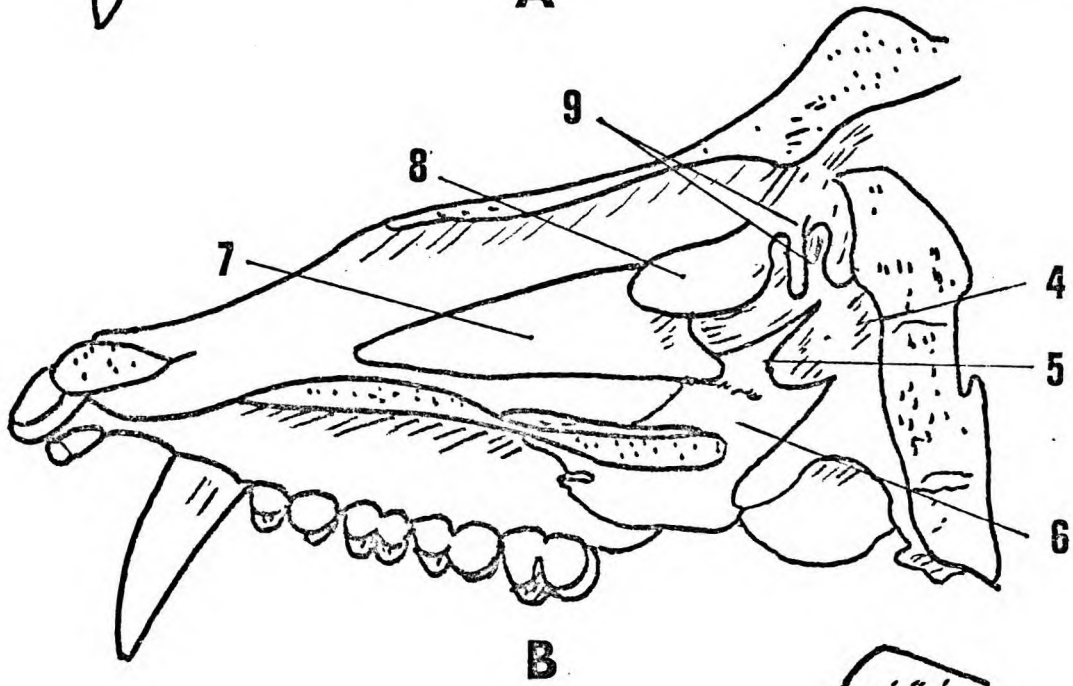
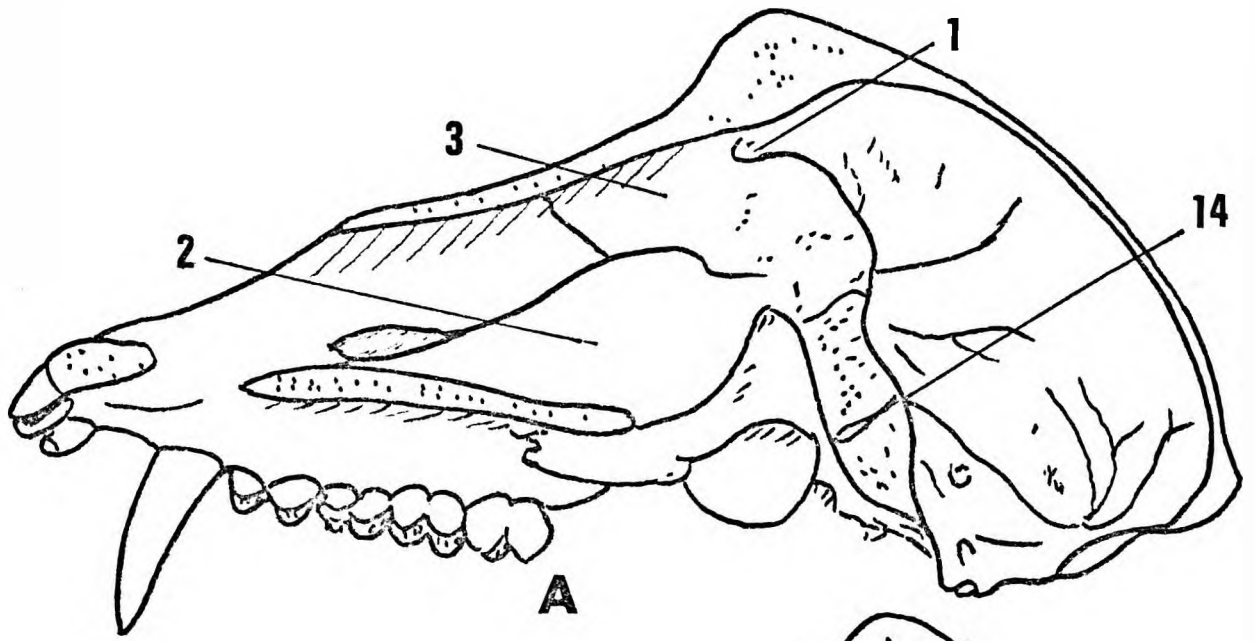


**C**

Figure 31.

Figure 31. The nasal bone.

- A. Ventral aspect.
- B. Lateral aspect.
- C. Nasal aspect.



**C**

Figure 32.

Figure 32.      A. A sagittal section of young adult  
                    B. Nasal septum removed.  
                    C. Nasal conchae removed.

---

1.           Olfactory pit.
2.           Septal part of vomer.
3.           Septal part of ethmoid.
4.           Foramen rotundum.
5.           Maxilla.
6.           Palatine bone.
7.           Caudal nasal concha.
8.           Middle nasal concha.
9.           Cranial nasal conchae.
10.          Sulci for olfactory nerve fibres.
11.          Sphenomaxillary fissure.
12.          Nasolacrimal duct.
13.          Maxillary sinus.

After removal of the conchae, the nasal opening of the nasolacrimal duct and maxillary sinus are clearly seen (Figure 32C). In this figure portion of the nasofrontal process of the frontal bone has been removed to demonstrate the sulci for the olfactory nerve fibres.

## THE MANDIBLE OF THE MALE BABOON

The mandible consists of a stout body and relatively short but stout ramus, and will be described from the lateral, medial, ventral, dorsal, cranial and caudal aspects.

### The lateral aspect (Figure 33B & 34A) :

The body projects ventrally from the ramus. The symphyseal region is well developed, convex ventrally and rugose for the attachment of the platysma colli and mentalis muscles. The mental nerve emerges through four or five foramina situated near the convex symphyseal border. The symphyseal region carries the incisors, canine and the ventral root of the first premolar. A large deep mandibular fossa separates the molar premolar alveolar region from the lower border of the body. This fossa produces an apparent thinning of the external bony plate of the mandible but is not apparent on the medial wall of the mandible. In some specimens the floor of the fossa is covered by a thin muscular sheet from the buccinator. In old specimens the fossa becomes translucent.

Below the molars the fossa is continued onto a slight concavity on which the dorsal part of the buccal pouch rests. The alveolus and lower border of the body are robust. The canine and medial incisor teeth are the only teeth which develop alveolar sockets visible on the exterior. The lower border of the mandible may be straight or slightly curved. The muscle platysma colli is attached to the lower border of the mandible from the symphyseal region to just ventral to the masseter muscle.

The mandibular angle describes a gentle dorsal curvature. There is a slight ridge on its lateral surface. The ramus is set obliquely on the body.

The lateral surface is slightly roughened for the attachment of the masseter muscle. The masseter muscle consists of ventral, dorsal and deep portions.

The ventral and dorsal parts insert onto the caudal  $\frac{3}{4}$  of the ramus whereas the deep part is inserted into a 'V'-shaped fossa extending ventrally from the condyle of the mandible. The condyle is set on a short strong pedicle. Its articular surface is convex and faces craniodorsally.

A stout bony bar, for the attachment of the lateral ligament of the temporomandibular joint, passes caudally from the condyle to the dorsal margin of the ramus. The coronoid process is large and reaches a higher level than the condylar processes. Its cranial surface is gently curved or forms a sharp spike.



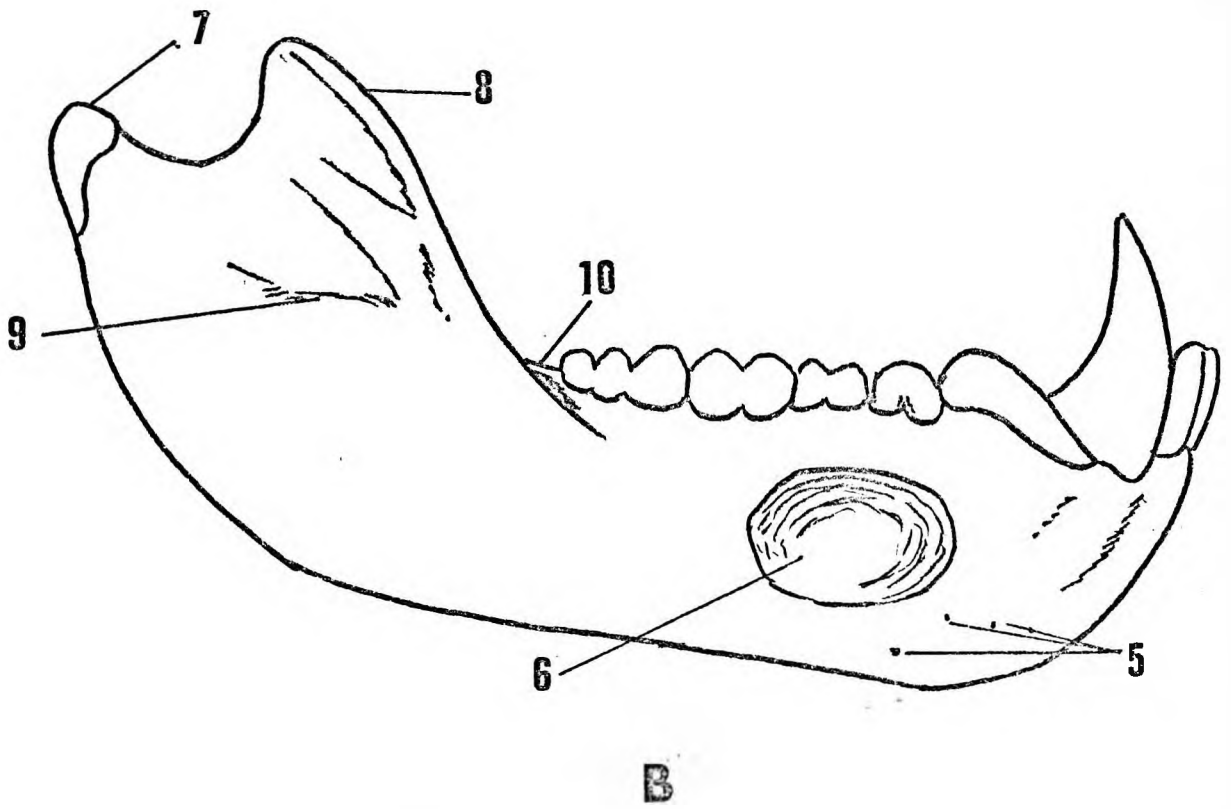
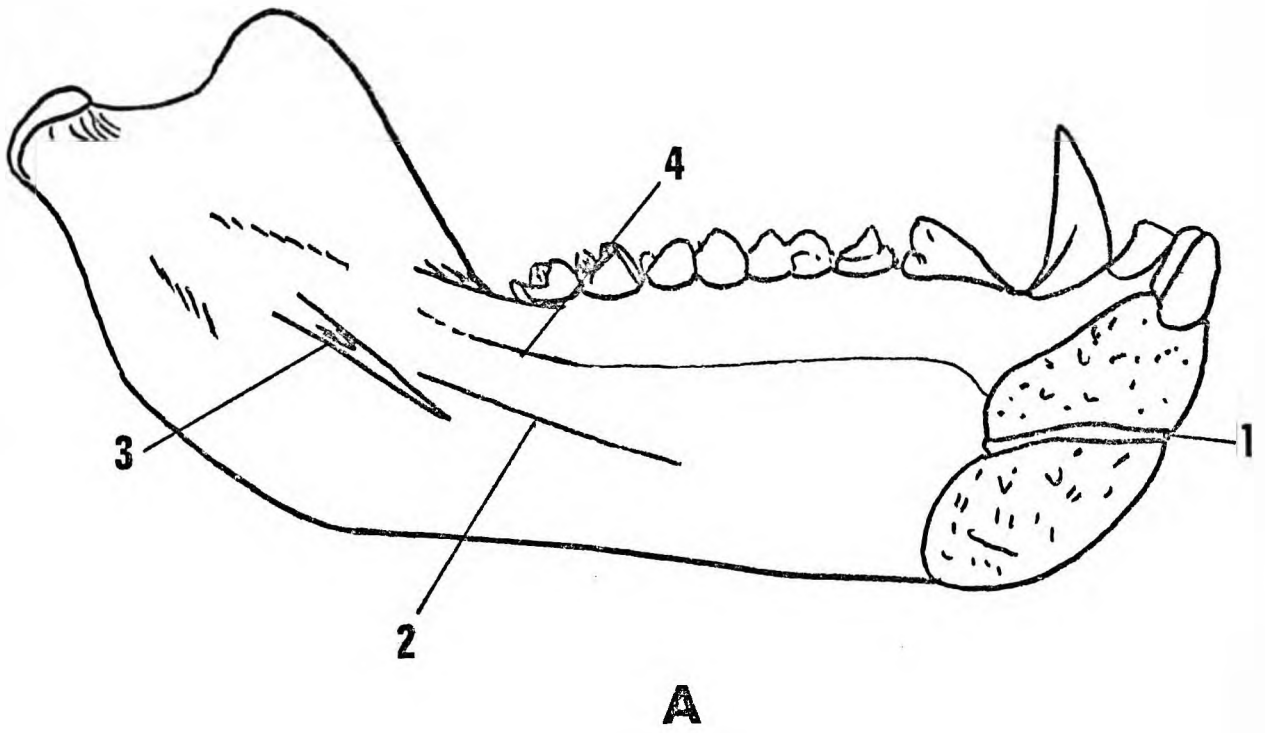


Figure 33.

Figure 33. The Mandible.  
A. Medial aspect.  
B. Lateral aspect.

---

1. Symphyseal canal.
2. Mylohyoid line.
3. Mandibular foramen.
4. Mucous membrane attachment.
5. Mental foramina.
6. Mandibular fossa.
7. Condyle.
8. Coronoid process.
9. Masseteric crest.
10. Retromolar recess.

The mandibular attachment of the temporal muscle has tendinous and fleshy portions. The fleshy part of the temporal muscle bulges ventrally to insert onto the coronoid process, while the tendinous ventral portion inserts along the ventral edge of the ramus, and continues onwards to insert into the dorsolateral aspect of the buccinator muscle.

The sigmoid notch may be shallow or deep and varies in shape from a nearly half circle to a shallow comma shape.

The medial aspect (Figure 33A & 34B) :

The section through the symphyseal region reveals its massive structure as well as the symphyseal canal. The root of each lower canine extends caudally to near the inferior border of the symphyseal region. The body of the mandible is convex medially. The mylohyoid line commences on the medial sharp edge of the postmolar gutter, and continues ventrally and obliquely across the body to the lateral wall of the caudal symphyseal fossa. The ventrocranial portion is related to the sublingual gland and is covered by mucous membrane at the caudal border of the alveolus. Caudal to the mylohyoid line is a slight groove related to the submandibular gland. The anterior belly of the digastric muscle is attached to a bony elevation on the medial ventral border of the body below the groove for the submandibular gland.

Dorsal to this is a slight depression for the masseter muscle which encroaches on the medial surface of the mandible ventral to the attachment of the medial pterygoid muscle. The medial pterygoid muscle covers nearly the whole of the medial surface of the ramus of the mandible caudal to the mandibular foramen. Numerous bony elevations are found on the dorsal part of the medial surface of the angle of the mandible. These are formed by fibrous elements in the attachment of the medial pterygoid muscle.

The mandibular foramen is a large 'V'-shaped depression. Cranially a small spike represents the lingula. The sphenomandibular ligament is attached around the margins of the 'V' and has a thickened portion attaching to the lingula. The groove for the nerve to the mylohyoid muscle is not always present and extends ventrally from the apex of the 'V'. The lateral pterygoid muscle is attached to the concavity on the medial side of the neck of the condyle.

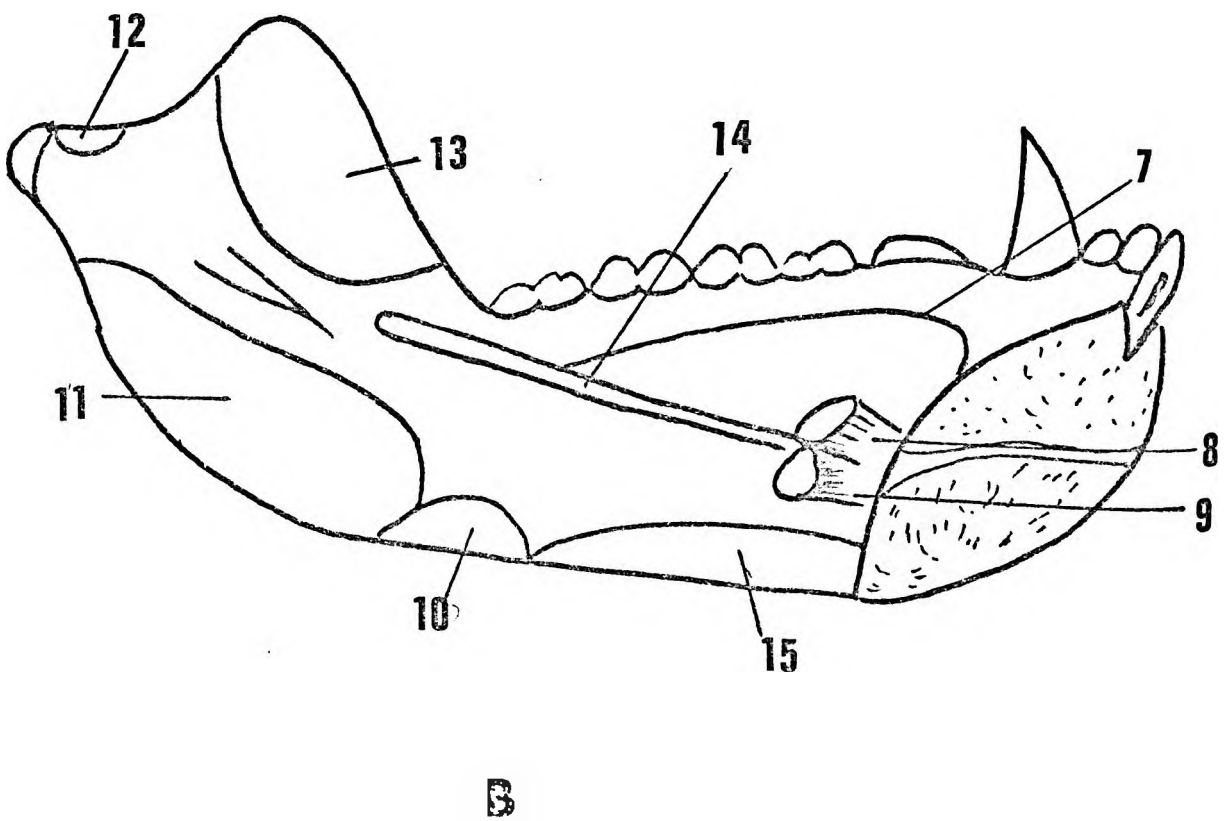
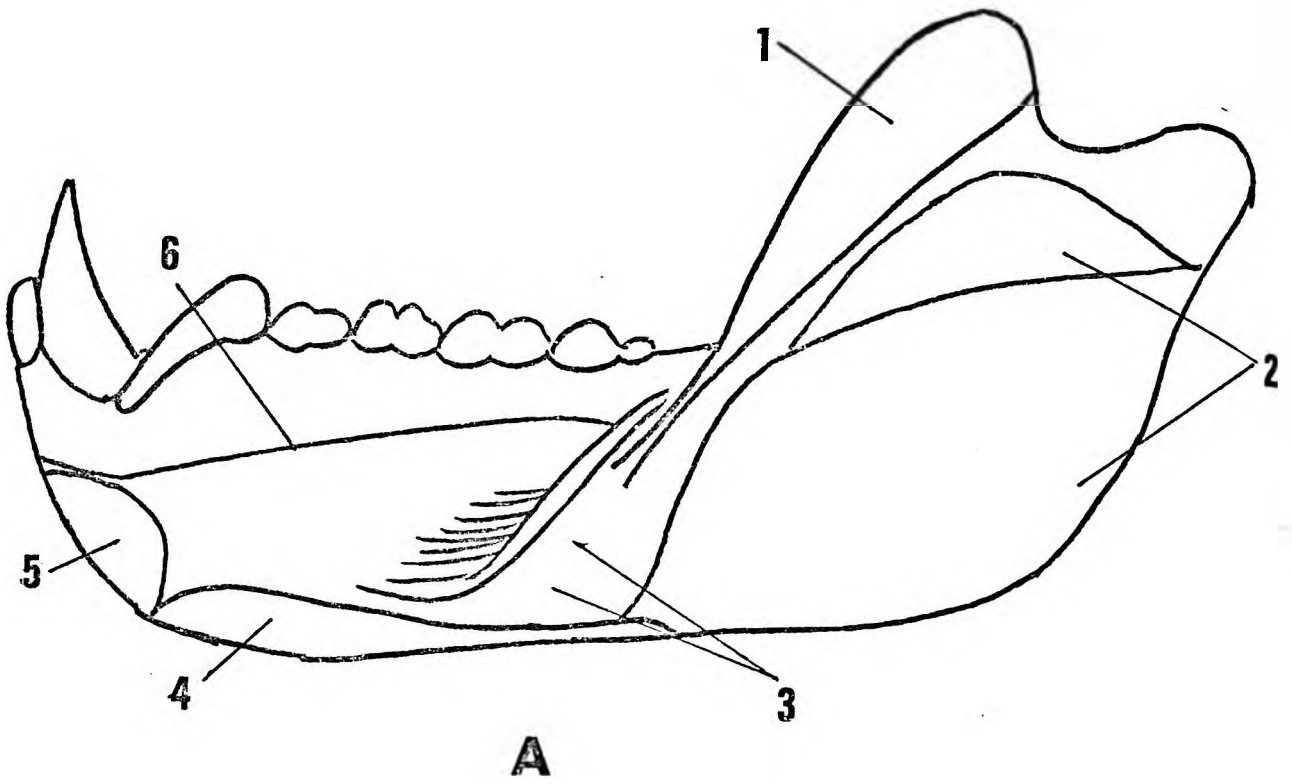


Figure 34.

Figure 34. The Mandible - muscle attachments.  
A. Lateral aspect.  
B. Medial aspect.

---

- 1 & 13 Temporal.
- 2 & 10 Masseter.
- 3. Buccinator and buccal pouch.
- 4. Platysma.
- 5. Mentalis.
- 6 & 7 Mucous membrane.
- 8. Genioglossus.
- 9. Geniohyoid.
- 11. Medial pterygoid.
- 12. Lateral pterygoid.
- 13. Temporal.
- 14. Myloheid.
- 15. Digastric.

The ventral aspect (Figure 35) :

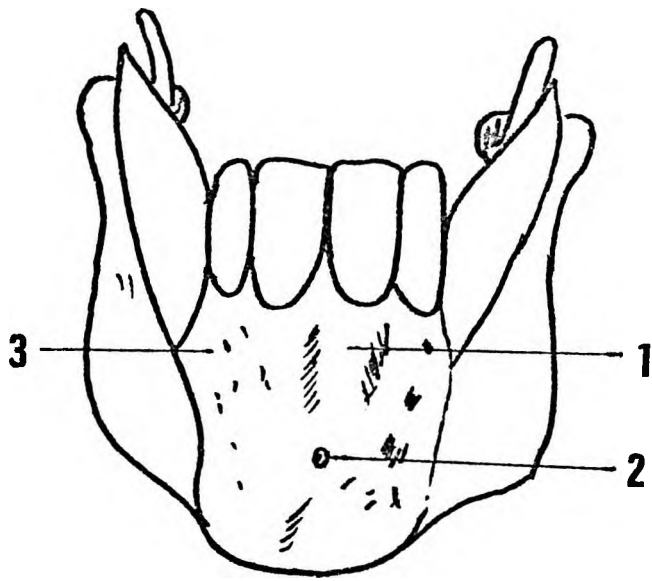
The symphyseal region is roughly rhomboidal in shape with a variable degree of constriction caudally at the bases of the canine alveoli. The constriction is produced by the ventral extensions of the mandibular fossae and from it the bodies and rami diverge markedly. Vertical buttresses extend caudally from the alveoli of the medial incisors to the symphyseal region. 'V' shaped recesses separate these buttresses from the large alveolar ridges of the canines. The union of the symphysis is indicated by a well defined vertical midline groove. A symphyseal canal connecting ventral and dorsal surfaces of the mandible interrupts this groove at about its middle. The symphyseal canal contains a branch of the lingual artery. Foramina for the mental nerves occur on the lateral and inferior part of the symphyseal region. This region is markedly rugose for the attachment of the muscles, platysma colli, the orbicularis oris and the mentalis. In this view the bodies and rami of the mandible diverge laterally and dorsally. There is slight eversion of the angles of the mandible and the ventral border of the rami.

The dorsal aspect (Figure 35) :

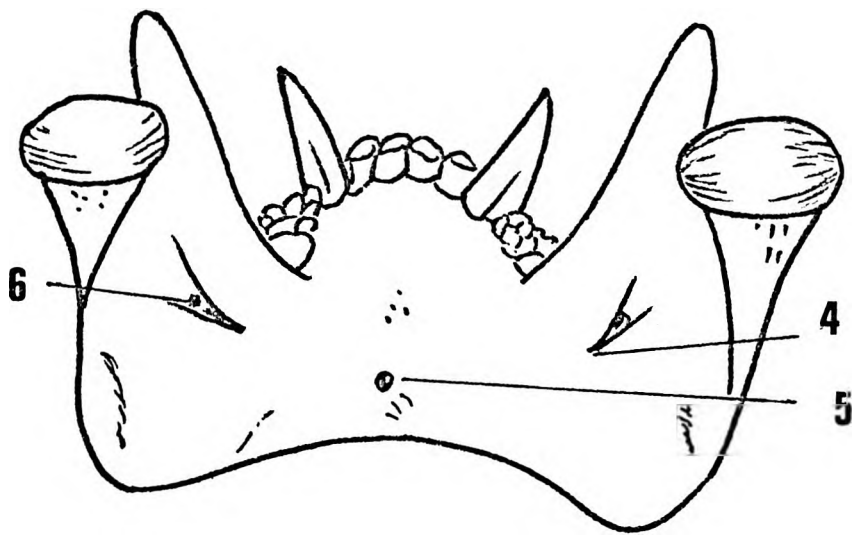
The massive nature of the symphyseal region is obvious. Inferior to the symphysis the deep symphyseal fossa, with scattered vascular foramina, and the opening of the symphyseal canal can be seen. In this view the well developed medial buttressing of the premolar and molar regions is also apparent. The dorsal margin of each ramus is slightly sinuous and ends in a triangular area below the condyle which is pitted by numerous vascular foramina. The articular surface on each condyle is continued well onto the dorsal surface.

The cranial aspect (Figure 36) :

The dental arcade and bodies of the mandible form a 'U'. The symphyseal region is thickened and forms a concave shelf extending dorsally to the level of the second premolar. This shelf supports the alveoli for the incisors, canines and first premolars. A deep fossa for the attachments of the muscles genioglossus, hyoglossus and the anterior bellies of the digastric is formed below this concave shelf. The alveoli for the premolars and first two molars slope craniolaterally while those for the



**A**



**B**

Figure 35.

Figure 35. The mandible.

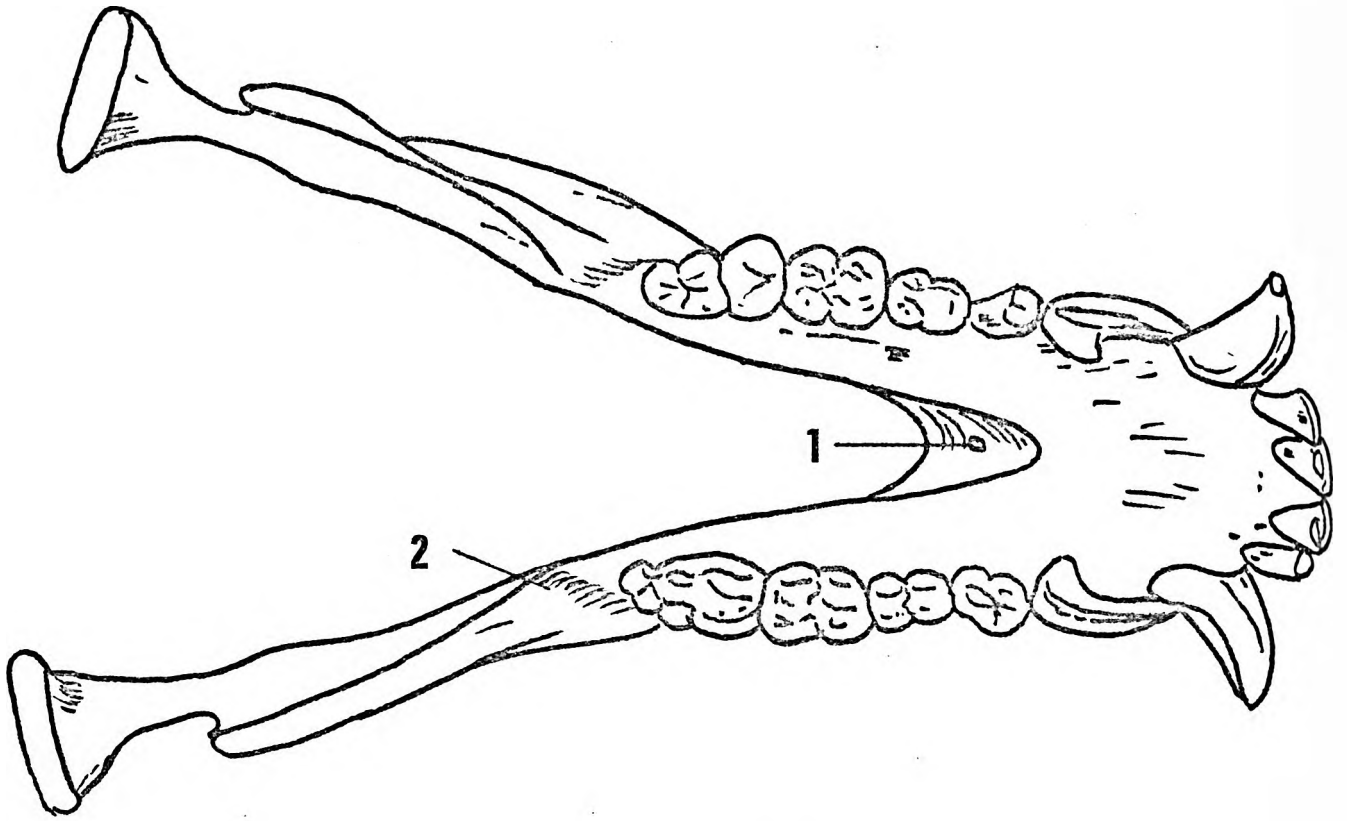
A. Ventral aspect.

B. Dorsal aspect.

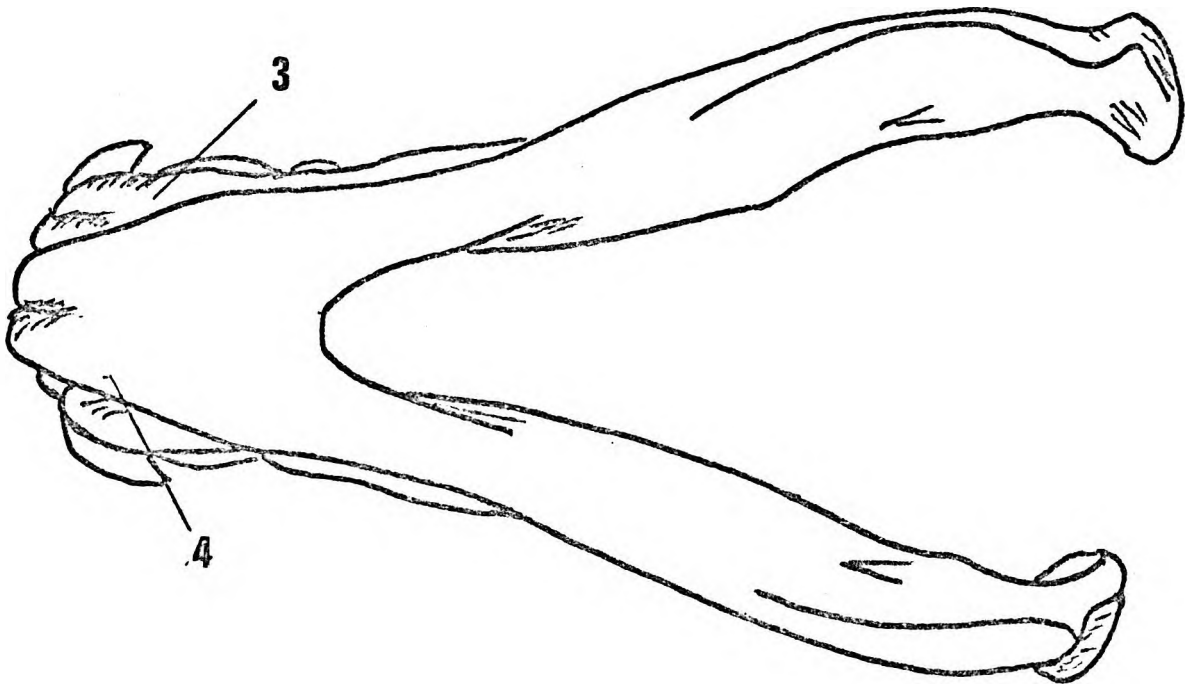
---

1. Incisor buttress.
2. Symphyseal canal.
3. Canine buttress.
4. Mylohyoid groove.
5. Symphyseal canal.
6. Mandibular foramen.





A



B

Figure 36.

Figure 36. The mandible.  
A. Cranial aspect.  
B. Caudal aspect.

---

1. Symphyseal canal.
2. Retromolar gutter.
3. Canine buttress.
4. Incisor buttress.

third molars are more vertically directed. This divergence in the direction of the alveoli is produced by a bony buttress on the medial aspect of the body of the mandible extending dorsally from the symphyseal region to the ventral border of the ramus. An obliquely placed postmolar gutter separates the molar region from the ramus. The temporal muscle inserts into the floor of the gutter. The sharp ventromedial border of the gutter gives attachment to the buccinator muscle.

In the cranial profile each ramus presents two eversions - i) at the caudal angle of the mandible and, ii) a cranial eversion of the coronoid and condylar processes. The angle of eversion corresponds with the bony buttress extending dorsally from the ramus to the neck of the condylar process. The ventral border of the ramus is thickened dorsal to the postmolar gutters and thins out to end in the sharply pointed coronoid processes. The temporal muscle is attached to the ventral, medial and lateral surfaces of the ramus.

The axes of the condyles are directed dorsomedially. A stout short neck supports each condyle. The lateral surface of the neck is convex and the medial surface concave. Three bony processes extend into the neck. These are derived respectively from the coronoid process, the postmolar buttress and the angle of the mandible. The ventral aspect of the neck of the condyle is triangular and separated from the lateral surface by a sharp border continuous with the sharp cranial border of sigmoid notch.

The caudal aspect (Figure 36) :

The mandible is roughly 'V'-shaped. The symphyseal region forms a rounded relatively large apex, from which the bodies and rami diverge. Two large bony buttresses develop dorsally from the medial incisors and the canines to fuse over the lower part of the symphysis and then to continue dorsally into the lower borders of the bodies of the mandible. In this view the eversion of the angles of the mandible and the obliquity of the mandibular condyles are apparent. The dorsal part of the body is thickened to support the molar region.


Individual differences of the mandibles of adult male baboons :

There are considerable morphological differences between the mandibles of the different specimens. Such differences concern the symphyseal region and the body of the mandible (Figures 37 A & B). Crania with large orbital margins are usually associated with sinuous caudal borders of the body of the mandible. This sinuosity results in a lack of depth of the body at the level of the third molar. Again these mandibles have comparatively deep mandibular fossae. A deep mandibular fossa also extends ventrally to produce a more constricted symphyseal region when viewed from the ventral aspect. The symphyseal region in such mandibles is more pointed than in crania with small orbital fossae. A more robust type of mandible is associated with crania that have small orbital margins. These mandibles have straight caudal borders of the bodies of the mandible, shallower mandibular fossae and stouter symphyseal regions. The convexity of the symphyseal region as seen from the lateral aspect varies considerably in both cranial types.


THE MANDIBLE OF THE ADULT FEMALE BABOON

Lateral aspects (Figure 38) :

In the females this bone is lighter, smaller and less robust. The ramus is set less obliquely on the body than in the male mandible. Muscular markings, although prominent are not nearly as well developed as in the male. The mandibular fossae, as in the male vary in depth but on the whole are smaller and in many specimens are only represented by slight concavities on the lateral sides of the body. The condyles occupy a nearly transverse plane and their articular facets extend ventrally to cover more of the cranial condylar surface than in the male. The ventral convexity of the symphyseal region as seen from the lateral aspect varies considerably. In some (Figure 38 A & D & F) it is an abrupt convexity whereas in others (B & C) it describes a gentle ventral slope. Such variations are not as obvious in male mandibles. The lower border of the body of the mandible may be sinuous or straight.



A



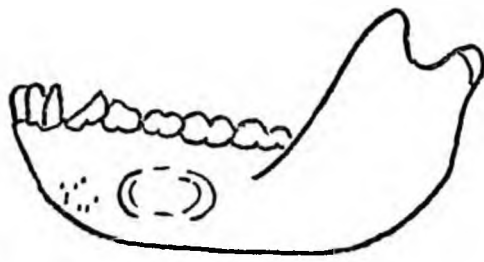
B

Figure 37.

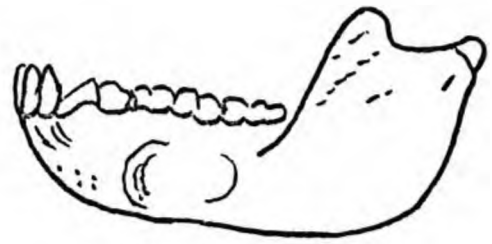
Figure 37. Lateral and ventral aspects of the mandibles  
of 2 adult male baboons. ( $\frac{1}{2}$  Normal size).

- A. Murahwas Kraal, Umtali.
- B. Chipinga, Rhodesia.

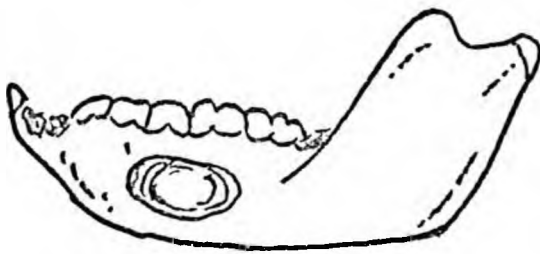
---



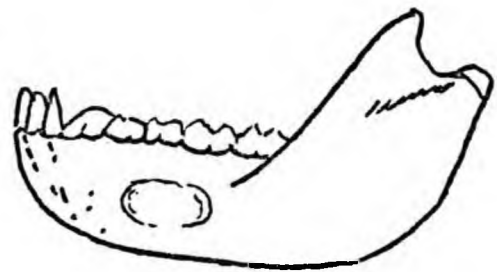
**A**



**B**



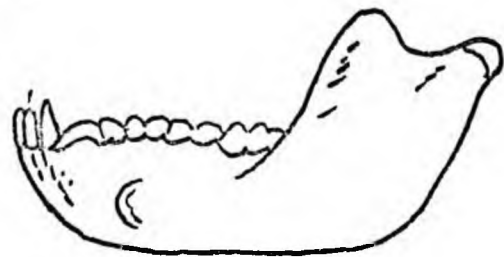
**C**



**D**



**E**



**F**

Figure 38.

Figure 38. The lateral aspects of mandibles of  
6 adult female baboons from the same  
troop. . . . .

---



The ventral aspect (Figure 39) :

The symphyseal region presents bony buttresses for the canines and medial incisors but these are less marked than in the male specimens. The outline varies from rectangular to almost square. The caudal margin may be straight or cranially concave as in A, C and D. The ramus deviates laterally and dorsally from the body. There is hardly any eversion of the angles of the mandible.

The cranial aspect (Figure 40) :

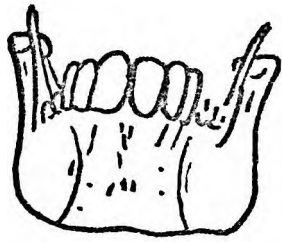
The dental arcade is 'U'-shaped with a more rounded incisor region than in the male. The symphyseal region is thickened but the shelf ends at the level of the first or second premolar. The shelf is more concave than in the male and the fossae for the attachment of muscles not as deep. The alveoli for all the teeth are more vertical than in the male. The postmolar gutter is well developed. In this profile the ramus is nearly vertical with only a slight eversion of the coronoid process. The ventral border of the ramus is slightly thickened. The condyles are much smaller than in the male with their axes directed dorsomedially. Similar bony buttresses pass to the neck of the condyle but are more delicate than in the male.

The caudal aspect (Figure 41) :

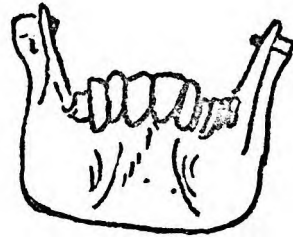
The outline of the mandible is approximately 'V'-shaped with the symphyseal region forming a rounded apex. The large bony buttress, passing from the symphyseal region to the lower border of the mandible, develops from the alveolus of the medial incisors without any apparent contribution from the canine as in the male. The molar region is thickened as in the male but there is hardly any eversion of the angle of the mandible.

The dorsal aspect (Figure 42) :


The symphyseal region is less massive than in the male and the genial pit much shallower. The bony buttress on the medial aspect of the body of the mandible is much less marked than in the male. The dorsal margin of the ramus of the mandible is nearly vertical. The articular cartilage of the condyle does not extend as far caudally as in the male.



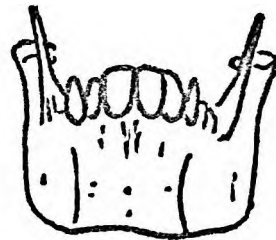
**A**



**B**



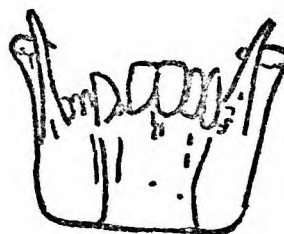**C**



**D**



**E**

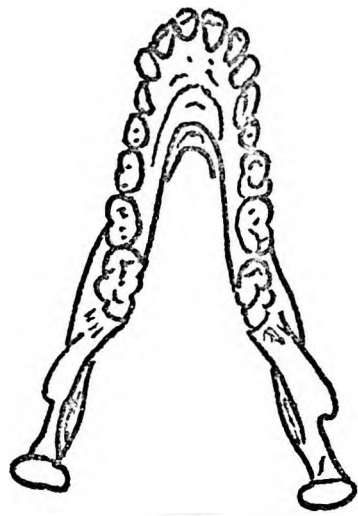


**F**

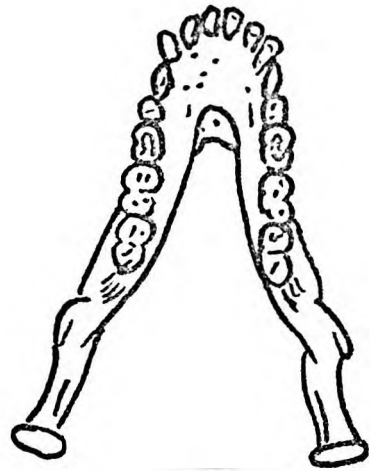
Figure 39.

Figure 39. The ventral aspects of the mandibles of  
6 adult female baboons from the same troop.

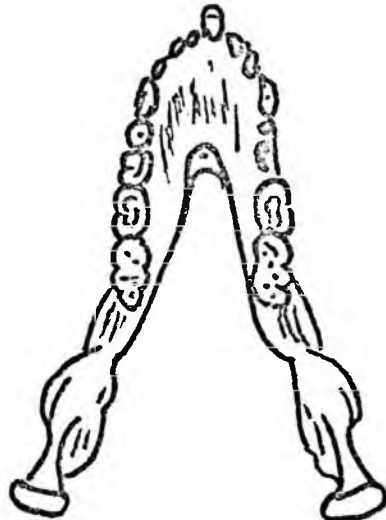
---



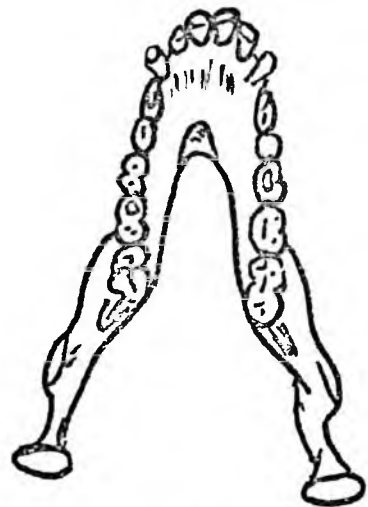
**A**



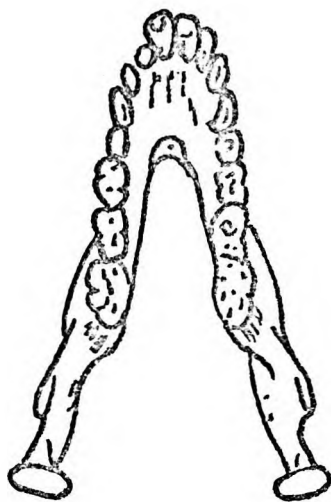
**B**



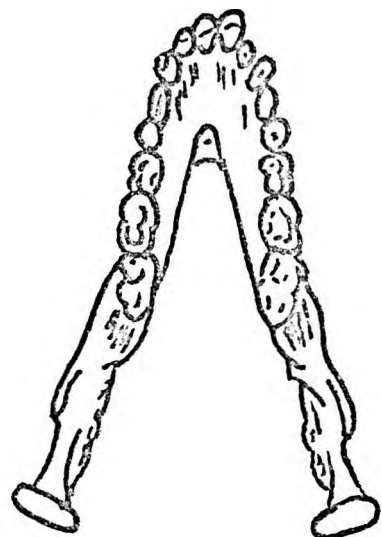
**C**



**D**



**E**

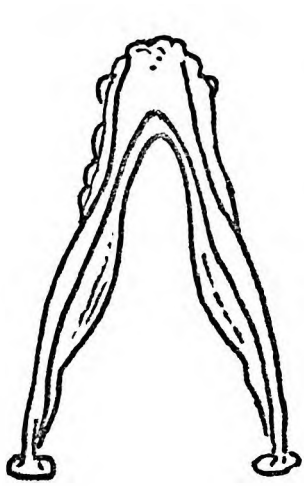


**F**

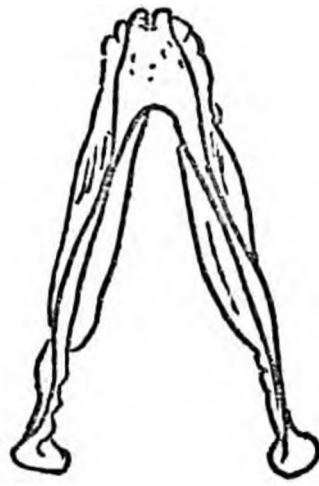Figure 40.

Figure 40. The cranial aspects of the mandibles of  
6 adult female baboons from the same  
troop.

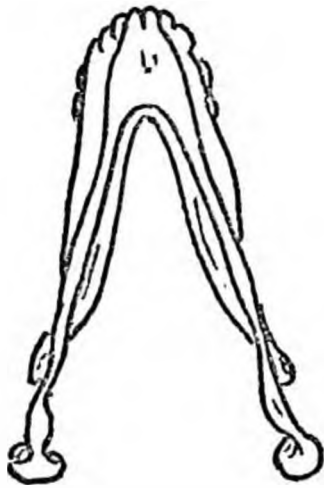
---



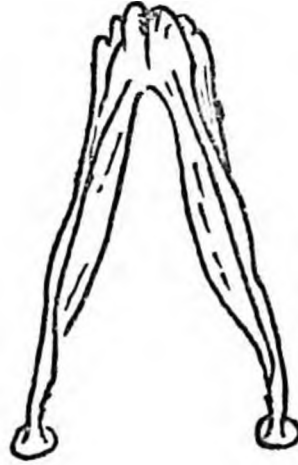
**A**



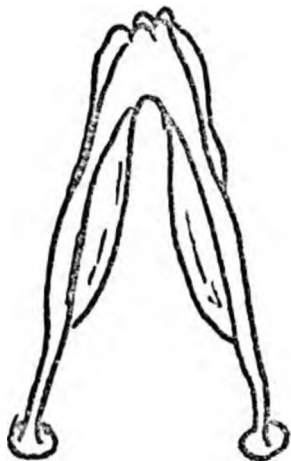
**B**



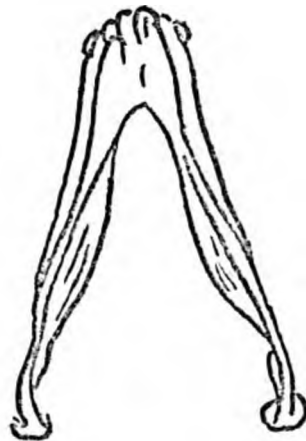**C**



**D**



**E**

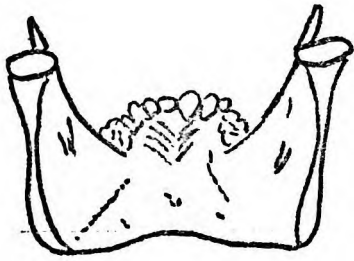


**F**

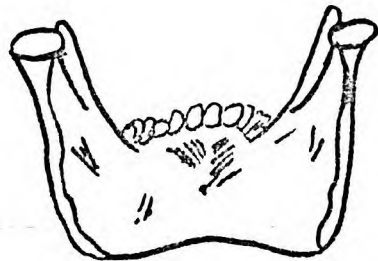Figure 41.

Figure 41. The caudal aspects of the mandibles of  
6 adult female baboons from the same  
troop. ....

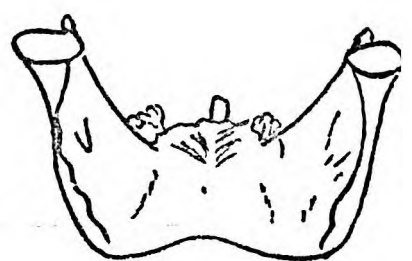---



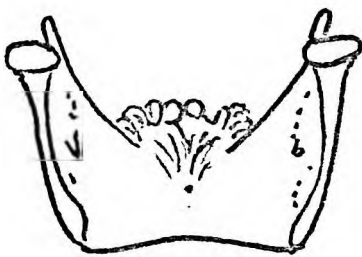
**A**



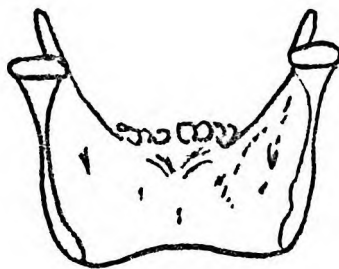
**B**



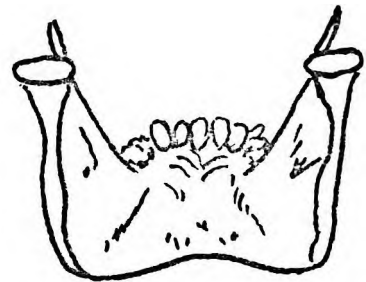
**C**



**D**



**E**



**F**

Figure 42.



Figure 42. The dorsal aspects of the mandibles of  
6 adult female baboons from the same  
troop.

---

The medial aspect (Figure 43) :

The symphyseal region is less massive than in the male and the roots of the canines are only a little larger than those of the incisors. The mylohyoid line is a distinct ridge. The glandular and muscular impressions are similar to those of the male. Below the mandibular foramen the ramus is slightly concave with prominent body markings for the attachment of the medial pterygoid muscle. The attachment of the lateral pterygoid muscle is marked by a shallow depression on the medial aspect of the neck of the mandible.

Individual differences among female mandibles :

Individual differences among female baboon mandibles are less marked than among the mandibles of the males. It is not possible to associate any mandible with a particular type of cranium as in the male specimens. The obvious differences that do occur affect the symphyseal regions which may be blunt or pointed and the mandibular fossae which vary in depth and extent. The lower border of the body of the mandible is generally straight although in some specimens it may be sinous.

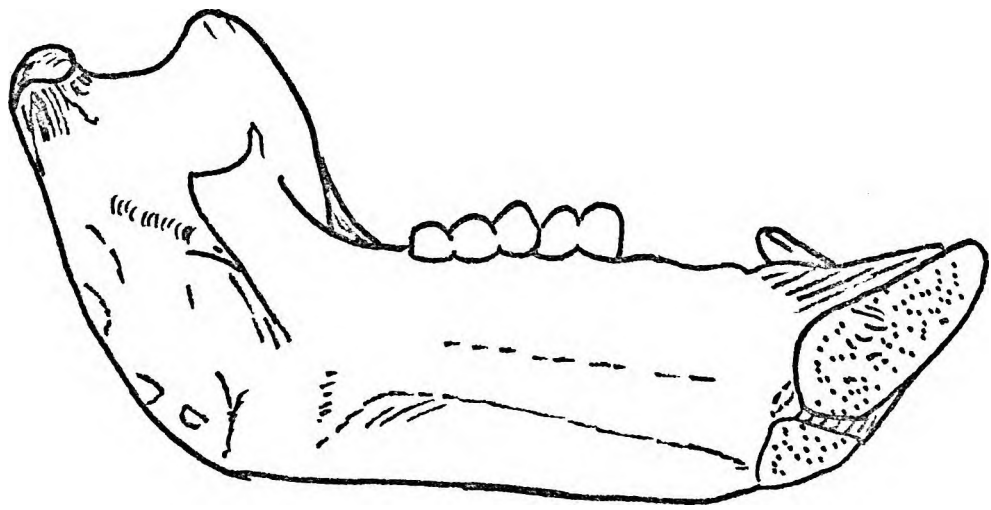


Figure 43.

Figure 43. The medial aspect of the mandible of  
.....an adult female baboon.

---

## DISCUSSION

The cranium of the adult male baboon The massive jaws of the adult male baboon have been commented on by many observers. The size of the jaws is not dependent on the type of diet but rather on the role the adult male plays in protecting juveniles and females. De Vore and Hall (1965) draw attention to this fact when they state -

'The fact that baboon and macaque males are aggressive and dominance orientated, by comparison to other primates, is presumably a correlate of the special function as group defenders, has important consequences on social behaviour and organisation'.

On the otherhand, Scott (1963) believes that dental and olfactory factors account for the prominence of the muzzle in baboons. But, as pointed out by Napier and Napier (1967) a massive muzzle for a massive canine is acceptable but the baboon sense of smell is greatly reduced and cannot have a profound effect on muzzle growth.

It has been shown that there are two main craniofacial types with intermediate types among the crania of adult male baboons -

Type 1. has characteristically small maxillary ridges, shallow maxillary fossae, ventrally directed zygomatic bones, large ventral orbital margins, well developed superciliary ridges, high temporal lines and a sagittal crest.

Type 11. has characteristically large scrolled maxillary ridges, deep maxillary fossae, ventrolaterally directed zygomatic bones, small ventral orbital margins, large supraorbital tori, low temporal lines and no sagittal crest.

Extremes of Type 1. could cause a 'langkop' (longhead) appearance whereas the extremes of Type 11. could give the appearance of a 'perdekop' (horsehead)

The intermediate facial types correspond with other appellations both scientific and colloquial.

Napier and Napier (1967) claims that the position of the sagittal crests on the cranium depends on the degree of prognathism of the face and the arrangement of the fibres of the temporal muscle. They also state that in Papio the posterior oblique element of the fan-shaped temporal muscle is much larger than the anterior components.

It is apparent that the different facial types are associated with different types of temporal muscles. Thus in Type 1, the dorsal elements of the temporal muscles are larger than the ventral components whereas in Type 11, the ventral components are larger.

The disposition of the various components of the temporal muscle not only affect the height of the temporal lines and the development of a sagittal crest but also influence other facial features.

Medial and lateral buttresses attach the muzzle to the neurocranium (Figure 44). The medial buttress commences at the premaxillae and canine alveoli. The premaxillary element extends dorsally through the nasal bones to the frontonasal region while the canine element on reaching the zygomaticomaxillary suture divides into medial and lateral portions. The medial portion passing to the frontonasal region and the lateral to the zygomatic bone.

The lateral buttress arises from the palatal plate of the premolar and molar regions to form the large zygomatic process of the maxilla. From the zygomatic bone stress elements pass medially to the maxilla, cranially to the frontal bone and dorsolaterally to the zygomatic arch. The sutures between the individual facial bones are elaborate interlocking devices designed not only to transmit stresses but to prevent disruption. Thus, the suture between the premaxilla and maxilla is an interlocking mortice and tenon, peg and socket arrangement where stress is transmitted directly to the maxillary ridge (Figure 45A).

The zygomaticomaxillary suture is an extremely strong mortice and tenon arrangement (Figure 45). At this suture a zygomatic strut receives the maxillary ridge whereas the lateral buttress from the maxillae forms a ledge into which the zygomatic bone fits. The maxillary ridge is thus a stress bar for the premaxillae and canines and the maxillary fossa is related to the degree of its development. Scott (1969) has shown that the zygomaticomaxillary suture in the human permits lateral growth of the face. In the baboon this suture permits mainly ventral growth.

From the zygomatic bone forces are transmitted cranially to the frontal bone and dorsally to the temporal bone. Both the frontozygomatic and zygomaticotemporal sutures are interlocking mortice and tenon devices. The frontozygomatic suture is designed to prevent ventrodorsal movement

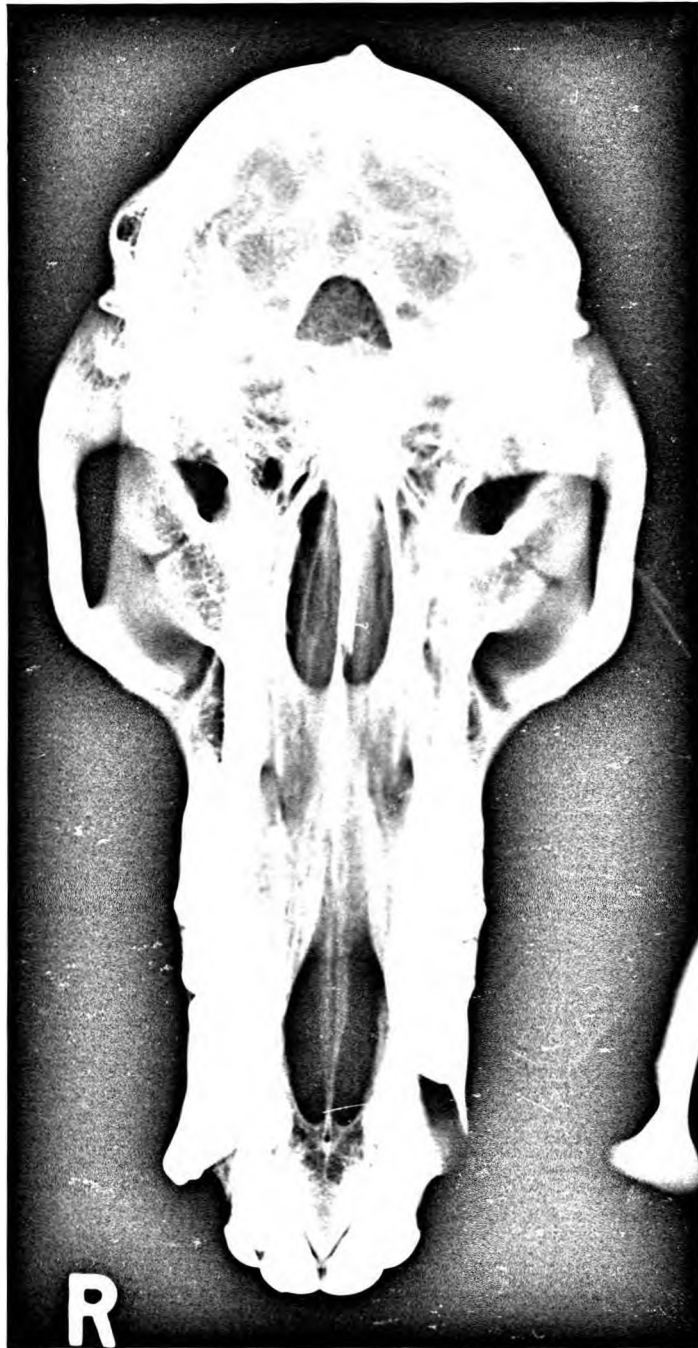

Figure 44B.

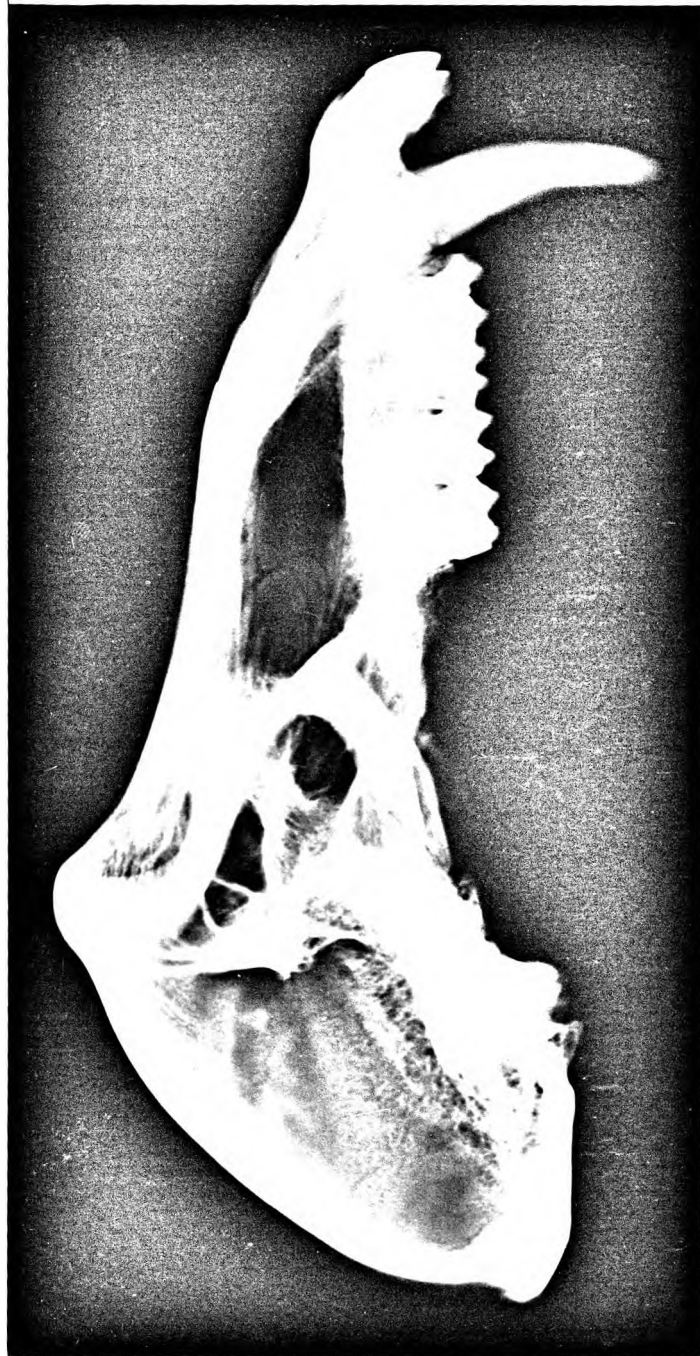

Figure 44A.

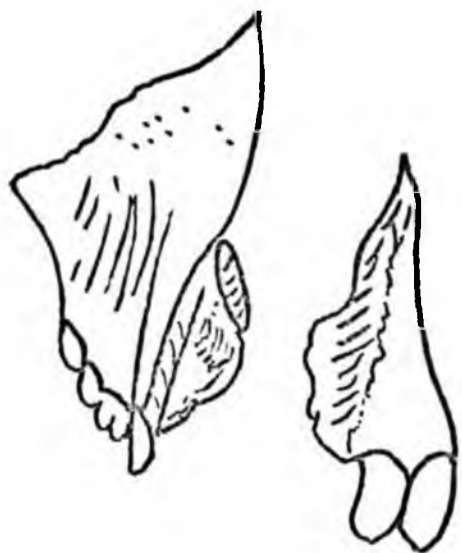

Figure 44. Radiographs of the skull of an adult male baboon.

---

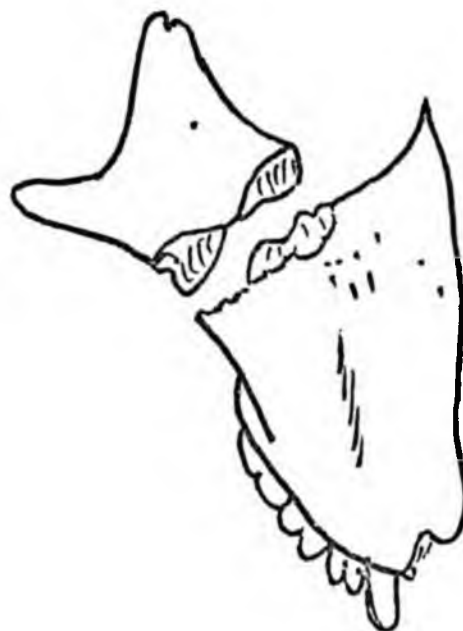A. Lateral aspect.

B. Basal aspect.



**A**

Figure 45A



**B**

Figure 45B.

Figure 45 A. The peg and socket articulation between the maxilla and premaxilla.

---

Figure 45 B. The zygomaticomaxillary suture.

---

while the zygomaticotemporal suture is obliquely placed and transmits forces dorsocranially to the robust zygomatic process of the temporal bone.

The frontonasal region consists of the nasal process of the frontal bone cranially; the nasal and frontal processes of the maxilla ventrally. The frontal bone is thick and cancellous and there is no frontal sinus. The maxilla and nasal bones are united by deep serrated sutures and join the frontal bone with a deep mortice and tenon type of suture. Radiographs of the frontal bones of adolescent and adult baboons are shown in Figure 46. The adolescent frontal bone illustrates the suture pattern at the frontonasal and zygomaticofrontal regions. In both radiographs stress lines can be seen extending laterally from the frontonasal region into the superciliary ridges and medially from the zygomaticofrontal region into the frontal bone.

Dorsocaudally the maxilla is linked to the sphenoid laterally by the palatine bones and medially by the vomer. The medial link is relatively weak and forms a scaffold for the nasal septum. The palatosphenoidal link is much stronger and has a serratosquamous type of suture.

Radiographs of the crania of Papio rhodesiae and a Papio hamadryas (Figure 47) are instructive. Both animals had been kept in captivity in the Pretoria Zoo for many years. In both there is a general osteoporosis with atrophy of the craniofacial stress bars. The osteoporosis is associated with other changes. The nasal septa are deviated. The bony attachments for the muscles of mastication, especially the temporal, are very prominent and radiographically resemble cases of myositis ossificans rather than bony crests formed as the result of muscular activity.

The shape of the ventral margin of the orbital cavities depends on the integrity of the bones and sutures forming these margins. In these captive animals the temporal muscles caused a collapse of the ventral orbital margins in a craniocaudal direction. Crania of other zoological animals show similar radiographic appearances.

de Klerk, et al (1973) of the Nutritional Unit at the C.S.I.R. Pretoria have drawn attention to the dramatic fall of the Vitamin C blood level of captive baboons as compared with animals in the wild state. This and factors as yet unknown could account for these bony changes.

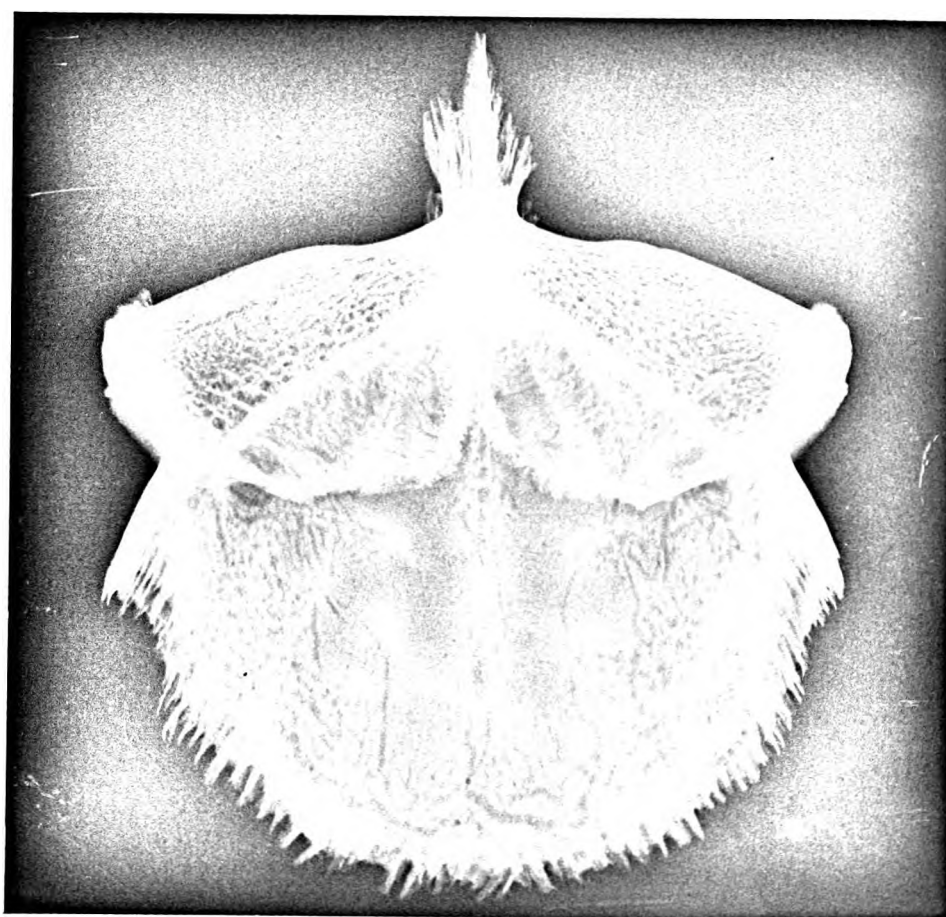


Figure 46B.

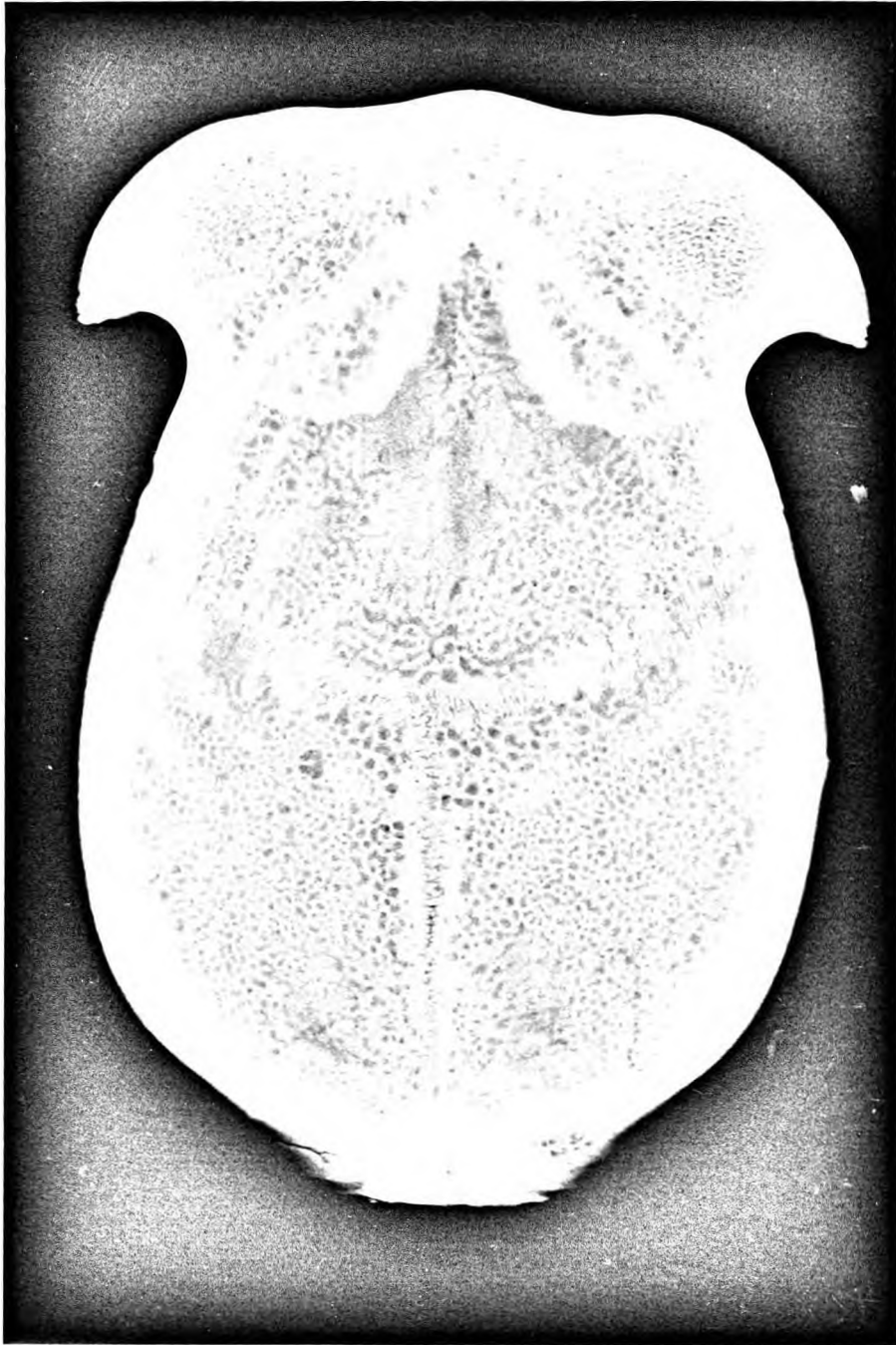

Figure 46A

Figure 46. Radiographs of the frontal bones of adult  
and adolescent baboons.

---

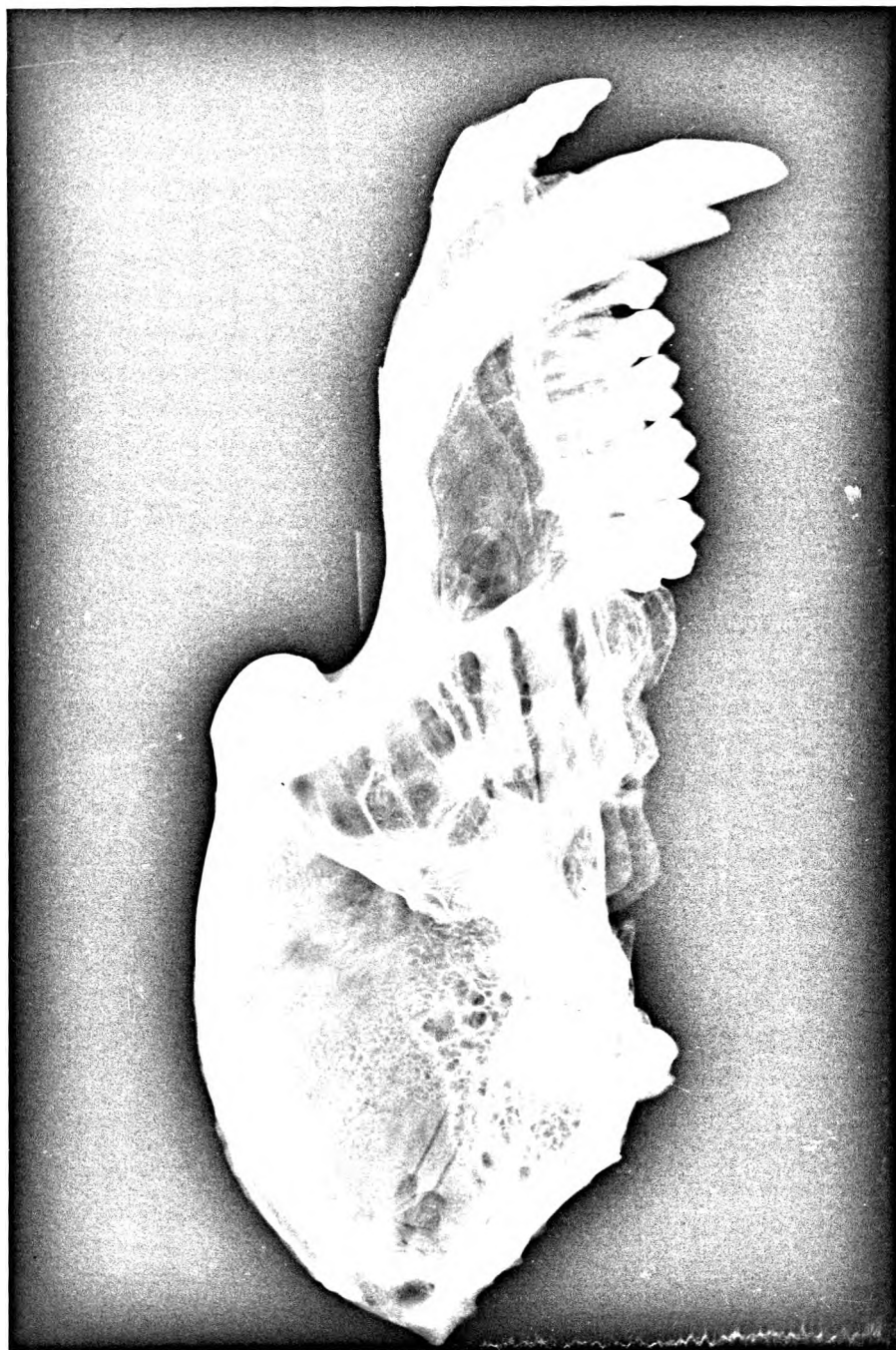


Figure 47B.



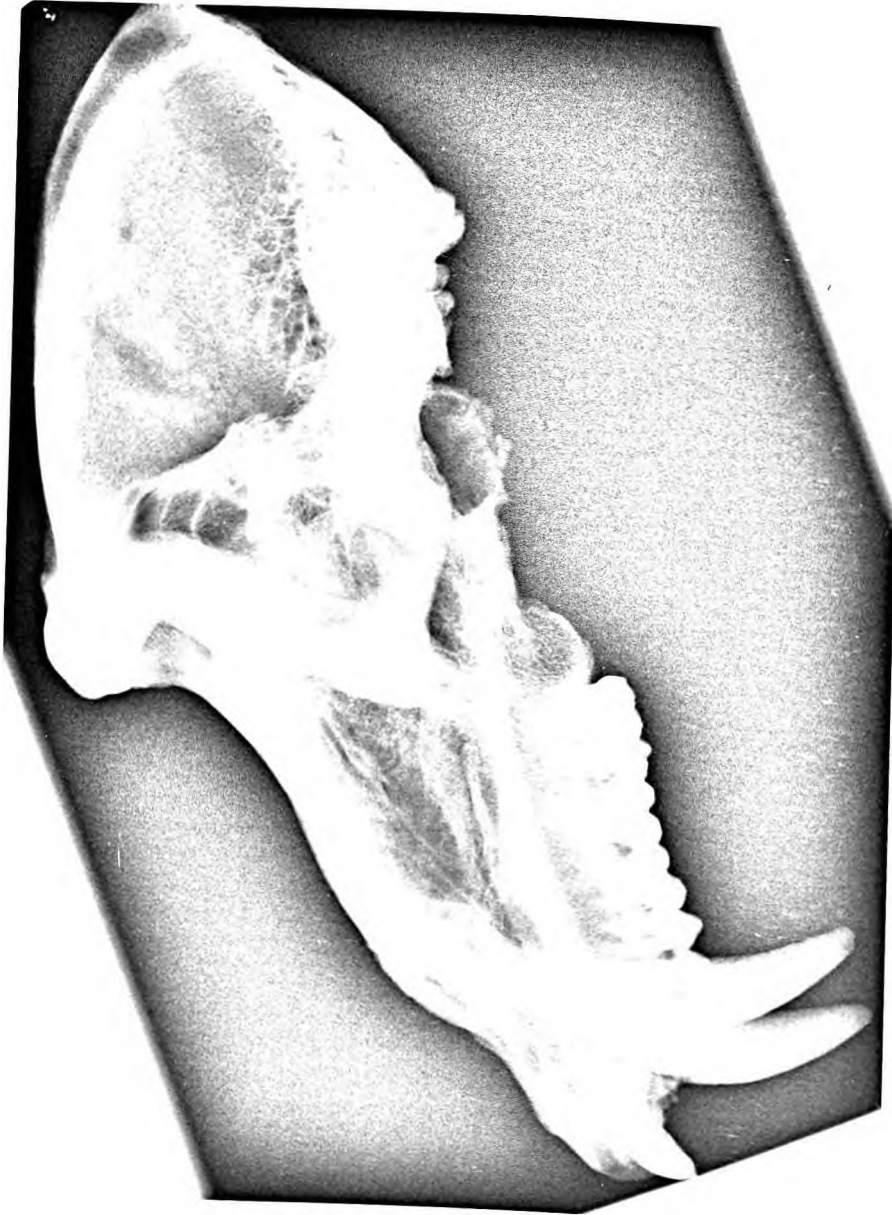

Figure 47A.

Figure 47. Radiographs of the crania of captive adult male baboons from the Pretoria Zoo.

---


A. *Papio rhodesiae*.

B. *Papio hamadryas*.

The craniofacial sutures of the baboon in general permit more ventral than lateral growth of the face as in man. Washburn, (1949) has shown that in the absence of the appropriate muscles, temporal lines, nuchal crests, mastoid areas of the cranium and the coronoid processes of the mandible do not develop in rats. In addition he also claims that the absence of muscles has no effect on the interior of the cranium although the sutures are less elaborate.

The temporal muscle of the baboon is a large globular fan-shaped structure obscuring the lateral aspect of the neurocranium. It is covered by dense temporal fascia which is attached to the zygomatic process of the frontal bone and the superior temporal lines. Dissections reveal two varieties of temporal muscles. In one variety associated with the Type 1. cranium, the dorsal element is larger while in the Type 11. cranium, the ventral element is larger. The temporal muscle not only influences the degree of development of the sagittal crest but also has an effect on the robustness of the zygomatic bone, zygomatic arch and the zygomatic process of the frontal bone. These influences are not unexpected since both muscle and bone are genetically self determining tissues Detwiller, (1936).

In man the superciliary arches (supraorbital torus) extend laterally from glabella and overlie the frontal sinuses Inkster, (1964). Frazer (1965) believes that the superciliary eminences of man develop because of the frontal sinuses. This is not the case in the baboons where the frontal sinuses do not develop. Scott (1963) has shown that a prominent supraorbital torus consists of the lateral orbital margins and the frontomaxillary junction, both of which form part of the facial buttress system, and that their development is correlated with the masticatory system. Clark (1971) can find no practical or theoretical reason why the development and subsequent disappearance of prominent supraorbital ridges should not be correlated with changing proportion of jaw and brain case.

 In the baboon the morphology of the supraorbital region appears to be dependent on the medial (frontonasal) buttress and the lateral (zygomatic) buttress. The development of the supraorbital torus (Schultz 1944 and Scott 1963) is well demonstrated in the baboon and is largely the result of bone deposition, producing a change in the relationship between the orbital margin and the brain case and a thickening of the upper rim of the orbital margin.

In the baboon the medial buttress results in the formation of the superciliary ridges, while the lateral buttress accounts for the development of the zygomatic process of the frontal bone. Both buttresses are dependent on the development of the masticatory system. The muscles of mastication, especially the temporalis, thus determine the facial types encountered. In the osteoporotic crania of captive animals these powerful muscles of mastication account for the distorted craniofacial crania and mandibles.

The nuchal crest : It is generally accepted (Washburn, 1949, Clark, 1971) that a nuchal crest develops to provide additional attachment for neck muscles on a relatively small occipital area; Figure 15 illustrates the attachments of the neck muscles to the occipital and temporal bones. Attached to the nuchal crest are, cranially the temporal muscle, the temporal fascia and the deep part of the occipitofrontalis muscle and caudally the muscles trapezius, sternocleidomastoid, splenius capitis and rhomboideus capitis. The nuchal crest is concave on its caudal surface indicating that in the male baboon it develops to give additional attachment for the neck muscles. The different patterns ofinion are entirely due to the presence or absence of a sagittal crest.

The sternocleidomastoid muscle of the rhesus monkey consists of three parts (Howell and Strauss, 1933). This is not the case in the baboon where the muscle has a wide comma shaped attachment to the nuchal crest and mastoid area. The ventral portion corresponds with the sternomastoideus and cleidomastoideus portions of the rhesus and is responsible for the two prominences of the mastoid area. The action of the sternocleidomastoid is that of rotation and extension of the head on the axial skeleton. The semispinalis capitis muscle is attached to a large rough area on the nuchal plane and acts as a powerful extensor of the head. The atlantooccipital muscles are attached to a large area of nuchal surface and obviously are powerful extensors as well as rotators of the head.

The posterior belly of the digastric muscle is covered by dense fascia and is attached to a large oval area overlapping the temporooccipital suture. This muscle together with the cervical portion of the platysma depress the mandible.

The cervical fascia is a dense investing layer surrounding the nuchal muscles and binding them into a tight mass. This musculofascial system

probably accounts for the simplicity of the sutures around the occipital bone. A surgical approach to the facial nerve, internal carotid artery and the internal jugular vein is possible if the dense layer of cervical fascia surrounding the sternocleidomastoid muscle is retained dorsally.

The mandibular fossa is shallow and large as compared with the condyle of the mandible, and is slightly concave mediolaterally and concavoconvex to nearly flat ventrodorsally. There are numerous slight differences between the fossae of different male crania but the female mandibular fossa is deeper and presents a definite articular eminence.

The postglenoid tubercle is large and appears to serve as a dorsal buttress when the jaws are opened. The articular cartilage does not cover its ventral surface as extensively in the female as in the male. The articular tubercle, situated laterally, is a definite eminence and there are no appreciable differences among the specimens or sexes. The intraarticular disc is attached to the ridges and tip of the postglenoid tubercle.

A large intraarticular disc covers the whole mandibular fossa, and this disc receives the condyle of the mandible in a shallow concavity on its caudal aspect. The male baboon has a canine guided bite with no rotation of the jaws. This conclusion is supported by the fact that all the masticatory muscles except the lateral pterygoid are elevators of the jaws. The lateral pterygoid muscle appears to steady the condyle of the mandible during opening of the jaws. On the otherhand the female baboon, with smaller canines and an articular eminence appears to be capable of rotatory jaw movement.

Pterygospinous and pterygoalar bars (Figure 14 A & B). These structures are frequently seen in baboon crania of all ages and both sexes. The fact that they occur in juvenile specimens implies that these bony structures are not ossified ligaments.

The pterygoalar ossification occurs in three forms :

- (i) A small bridge of bone from the lateral pterygoid plate to the alisphenoid forming a pterygoalar foramen.
- (ii) A large flange of bone which forms a pterygoalar canal.
- (iii) A still larger process which not only forms a pterygoalar canal but extends dorsally to articulate with the petrous temporal

bone, and it is this process which converts the foramen lacerum into a foramen ovale portion and a foramen spinosum portion.

This phenomenon possibly provides evidence for the extreme plasticity of the primate sphenoid and may also provide evidence of an attempt to develop separate foramina ovalia and spinosa.

The petrotympanic fissure of the baboon is a lateral extension of the foramen lacerum. The sphenomandibular ligament is not attached to the sphenoid but to a definite spine arising from the tympanic bone thus providing confirmatory evidence of the embryological origin of the 'spheno' mandibular ligament and the tympanic cavity. In contrast the styloid process is usually just a small bony elevation. In only a few cases does it consist of a proximal process, the tympanohyal, surrounded by a bony sheath - the vagina processus styloidei (Tobias, 1967) and a distal process, the stylohyal. Variation in this region is encountered in all primate crania, other than man. No adequate explanation for this variation can be offered but that the development of the stylohyal portion may be related to the assumption of an erect posture.

The dental arcade of the upper and lower jaws of Papio anubis have been described by Swindler, Mc Coy and Hornbeck (1966 to 1967). Their description does not differ in any marked detail from the findings in the present series. The arcades are 'U' shaped with variations affecting the incisor, canine and third molar regions. In Type 1. specimens, the canine incisor region is rounded whereas in Type 11. specimens this region is more squared off. In all specimens the alveoli in the region of the third molars curve medially so that the limbs of the 'U' approximate each other. This feature is more apparent in some specimens than in others. Type 1. specimens usually have narrower 'U's than Type 11. specimens. The bony palate is arched in transverse and sagittal direction. The alveoli are large and with a domed palate form a strong structural unit. James (1960) has pointed out that 'the exact position and spread of the roots of the teeth, with their compact encasing sockets, transmit pressures to the bony walls and buttresses of the upper jaw'. Observations made in the present study of the bony palate of the baboon, and of the origins of the medial and lateral buttresses confirm James' observations. He also pointed out that the forces of dental occlusion on the face and

cranium have not received much attention. This occlusal pressure would appear to be the factor producing the distorted facial features of Papio rhodesia, already referred to.

The medial walls of the incisive foramina are formed by the thin nasal processes of the premaxilla. Sullivan (1933) could not determine the origin of these processes in the rhesus monkey.

#### INTERIOR OF THE CRANIUM

Endocranial markings of the brain, the *impressiones gyrorum* occur on the floors of the ventral and middle cranial fossae and on the ventral aspect of the roof of the cranial vault. Such markings are associated with quadripedal animals.

The ventral cranial fossa : A deep olfactory pit occurs in many nonhuman primates but in the baboon this seems to be relatively deeper and smaller and is almost 'sheared off' from the ventral cranial fossa by the adjacent orbital plates of the frontal bone. The acute angulation of the olfactory nerves from the ventral cranial fossa to the olfactory pit suggests considerable reduction of olfaction in the baboon. The frontal crest is replaced by a low ridge which starts 1 or 2 cms. dorsal to the olfactory pit. The groove for the superior sagittal sinus may lie on this ridge or to the right or left of it. The ventral part of the falx cerebri is attached to this crest and more ventrally to a small crista galli. The attachment then extends dorsocaudally onto a bony ridge between the frontal bones and the presphenoid. This arrangement suggests that these ridges are related to the attachment of the falx cerebri and are not reinforcing structures as suggested by Weidenreich (1943).

The middle cranial fossa : The lateral compartments support the temporal lobes of the brain. The apex of the petrous temporal bone separates the fossa ovalis part of the foramen lacerum from petro-occipital fissure and thereby separates the mandibular division of the trigeminal nerve from the internal carotid artery. A distinct bony ridge bounds the lateral border of the carotid sulcus. The lateral wall of the cavernous sinus is attached to this ridge.

A similar ridge but more laterally placed bounds the groove for the maxillary division of the trigeminal nerve. The lateral wall of the cavernous sinus splits to enclose this nerve.

The fibrous layer of the dura mater becomes continuous with fibrous tissue between the sutures of the cranial bones while the meningeal layer provides tubular sheaths for the nerves as they pass through the foramina at the base of the cranium. . Thus, in the baboon the foramen lacerum is converted into separate fibro-osseous compartments for the structures passing through it.

In similar fashion fibro-osseous canals are formed for the maxillary nerve and internal carotid artery. In some specimens the fibrous coverings of these canals are ossified. This feature emphasises the osteogenic properties of the fibrous layer of the dura mater and accounts for the bony ridges and spurs seen in this region of the cranium. The fact that these ridges and spurs are prominent even in young specimens suggests that the dural processes also have a steadying influence on brain movement.

After a very short intracranial course the middle meningeal artery divides into ventral and dorsal branches. The ventral branches extend forward to internal aspect of pterion. In the rhesus monkey branches extend into the lateral side of the orbital cavity (Hartman and Strauss, 1933). This is not the case in the baboon where these vessels appear to be entirely diploic in character.

The dorsal division of the middle meningeal artery shares the internal aspect of the petrosquamous fissure with the prootic sinus. The sinus extends dorsally over the lateral boundary of the petrous temporal bone. Padget (1957) believes that the prootic sinus is the remains of the primitive middle dural plexus.

The central part of the middle cranial fossa is related to the optic chiasma, the termination of the internal carotid artery and the hypophyseal fossa. The clinoid processes are well developed and frequently connected to each other by ossifications. In similar fashion the endocranial termination of the carotid artery may also be surrounded by a bony ring.

The hypophysis cerebri is surrounded by a subarachnoid space containing cerebro spinal fluid. This observation is not in agreement with Wislocki's (1937) findings nor is it possible to offer any explanation for the frequent occurrence of the foramen in the dorsum sellae which connects the



hypophyseal fossa with the extra dural space over the dorsum sellae.

The dorsum sellae of the baboon is a beautifully designed plate of bone resembling that of man. It is attached to the sphenoccipital synchondrosis like a postage stamp. A small foramen in the midline connects the hypophyseal fossa and posterior cranial fossa. This foramen occurs in other primates, man included. In the baboon the dorsum sellae covers the hypophyseal fossa so that most of the hypophysis cerebri is not apparent from the endocranial aspect.

The cranial surface of the petrous temporal bone is separated from the dorsal surface by a sharp margin which maybe interrupted by a cleft over the subarcuate fossa. This margin corresponds with the cranial attachment of the superior petrosal sinus. There is a definite groove for the greater superficial petrosal nerve but no hiatus canalis facialis as occurs in the rhesus or vervet monkey.

The dorsal border of the petrous temporal bone faces dorsomedially. Definite grooves for the acousticovestibular nerve and the stem of the paraflocculus lead to the internal acoustic meatus and subarcuate fossa respectively. These grooves are not seen in the crania of rhesus or vervet monkeys.

The endocranial aspect of the occipital squame presents five fossae. The occipital poles of the cerebrum lie cranial to the bony ridges on which the transverse sinuses lie. In adolescent specimens these fossae show impressiones gyrorum but these disappear in the adult. In the midline, caudal to the internal occipital protuberance, is a deep median fossa. This is flanked by the strong dorsal buttresses of the foramen magnum. Lateral to these buttresses are the cerebellar fossae. These buttresses are obviously bony struts to preserve the bony integrity around the foramen magnum and of the occipital bone. The osteoporotic cranium of Papio rhodesiae has become platybasic because of a weakening of these buttresses.

The internal occipital protuberance is grooved by the sagittal sinus cranially and the transverse sinuses laterally. The sagittal sinus passes to the left or right transverse sinus in approximately an equal number of cases. Grooves for marginal venous sinuses were not found. The angle made by the junction of the transverse

and sigmoid sinuses is nearly a right angle but the outline is obscured by the posterior division of the middle meningeal vessels which divide at this point and separate the sinuses from the bone. The meningeal vessels then divide into parietooccipital branches and large occipital branches to the cerebellar fossa.

In adult crania the attachment of the dura to the cranial walls in relation to the venous sinuses has resulted in ossifications partly obscuring the grooves for these sinuses. This observation confirms Klintworth's (1968) claim that the ectomeninx of the duramater retains osteogenic properties - reference to these properties of the dura have already been made.

#### SEXUAL DIMORPHISM AND TAXONOMY

Freedman (1957) lists ten features characteristic of the female baboon skull. The description of the skulls of six adult female baboons from the same troop at Bindura confirms his views. Less well recognised dimorphic differences are noted in the description of the female skull but these are not of appreciable importance. However, the morphological differences between these skulls have an important bearing on the taxonomic status of baboons.

It has been shown that among the male skulls there are two main types with numerous intermediate variations. When allowance is made for sexual dimorphic changes similar craniofacial types can be identified among the female skulls from Bindura. Indeed, the crania of adult female baboons from other known localities - Kariba 3, Waterberg 1, Transvaal 4, Riversdale 5, South West Africa 1 and South Eastern Rhodesia 1 - correspond with the male counterparts from these areas. Starch, (1967) found similar craniofacial differences among adult male specimens of Papio doguera, Papio hamadryas and Papio cynocephalus. A personal examination of the collection of Papio cynocephalus skulls at the National Museum, Bulawayo, confirms this observation.

The collection of adult male baboon skulls at the Transvaal Museum consists of skulls from all parts of the Republic of South Africa

South West Africa, Botswana and Rhodesia. These skulls correspond with the different craniofacial types observed in this study.

Freedman, (1957) concluded that Papio rhodesiae Transvaal Museum 4078, was an abnormal specimen but could be fitted into the species Papio ursinus. It has already been shown that this skull is that of an osteoporotic captive animal.

Goldblatt's (1926) type specimen of Papio ursinus occidentalis Transvaal Museum 11707, comes from Rustenburg and resembles the Magaliesberg specimens in this collection. The type specimen of Papio ursinus orientalis, Transvaal Museum 11705, used by Goldblatt in his study comes from Queenstown. Examination reveals a healed fracture of the left zygomatic bone involving the zygomaticomaxillary suture. This fracture has produced a distortion of the left side of the face and orbit. Consequently I am inclined to agree with Hill, (1957) who considers that the Southern African baboon constitutes a single species with geographical variants. The present study also indicates that a re-examination of the fossil Cercopithecoidea of South Africa should be undertaken.

#### THE INDIVIDUAL BONES OF THE CRANIUM

The bones of the cranium described here are those of an adolescent specimen. They do not reveal the bony markings of the adult animal but are more instructive as far as suture patterns and the synchondroses are concerned.

It has previously been pointed out, (revor-Jones, 1972) that the study of the separate bones of the skull of lower mammals has been neglected. Some findings of workers in this field based solely on the study of articulated crania may thus be questionable (Broom, 1930, Freedman, 1957, Clark, 1971, Neal and Rand, 1936, Hill, 1957 and Reynolds, 1913).

All the bones of the baboon cranium except the ethmoid, the vomer and the palatine bones, resemble those of other primate and mammalian crania. These bones contribute to the medial wall of the orbit and the lateral wall of the nasal cavity.

It has only been possible to compare the baboon ethmoid, vomer and palatine bones with those of three other primates, namely, man, the vervet monkey and the galago. These bones are similar in the baboon and vervet monkey but in the galago, they resemble those of man. Thus, although the medial wall of the orbit (Figure 5) consists of the lacrimal and frontal bones cranially; vomer and orbitosphenoid bones caudally in baboons and vervet monkeys, it is not possible to claim this as the standard pattern of all the primates.

The composition of the lateral wall of the nasal cavity (Figure 32) as seen in the baboon and vervet monkey is similar and differs from that of man and the galago. It is interesting that in the baboon and vervet monkey the vomer not only usurps the place of the ethmoid in the orbital cavity but also takes over the formation of the turbinate bones in the nasal cavity. Furthermore, the dorsal extensions of the lateral processes of the vomer suggest an attempt at the formation of a sphenoidal air sinus.

The existence of a maxillary sinus in baboons was not recognised by Negus (1958). As shown in Figure 32C a maxillary sinus is present and is frequently infested by a mite (O'Donovan, 1969). The medial wall of the maxillary sinus usually consists of a double layer of mucous membrane but in adult specimens the connective tissue layer between the mucous membranes contains a circular plate of bone. This type of sinus could well represent a stage in the pneumatization of bone preceding the development of a true sinus.

The sutures have already been discussed but some remarks on the synchondroses are relevant.

Figure 48 illustrates the synchondroses on the cranial and caudal aspects of the postphenoid. The synchondrosis between the presphenoid resembles a low serrated suture while in the case of the sphenoccipital synchondrosis the sphenoid and occipital bones are separated by a flake of bone. This arrangement is reminiscent of the triradiate ossification in the developing acetabulum.

The postphenoid is united to the alisphenoid by a synchondrosis that is united in early adolescence.

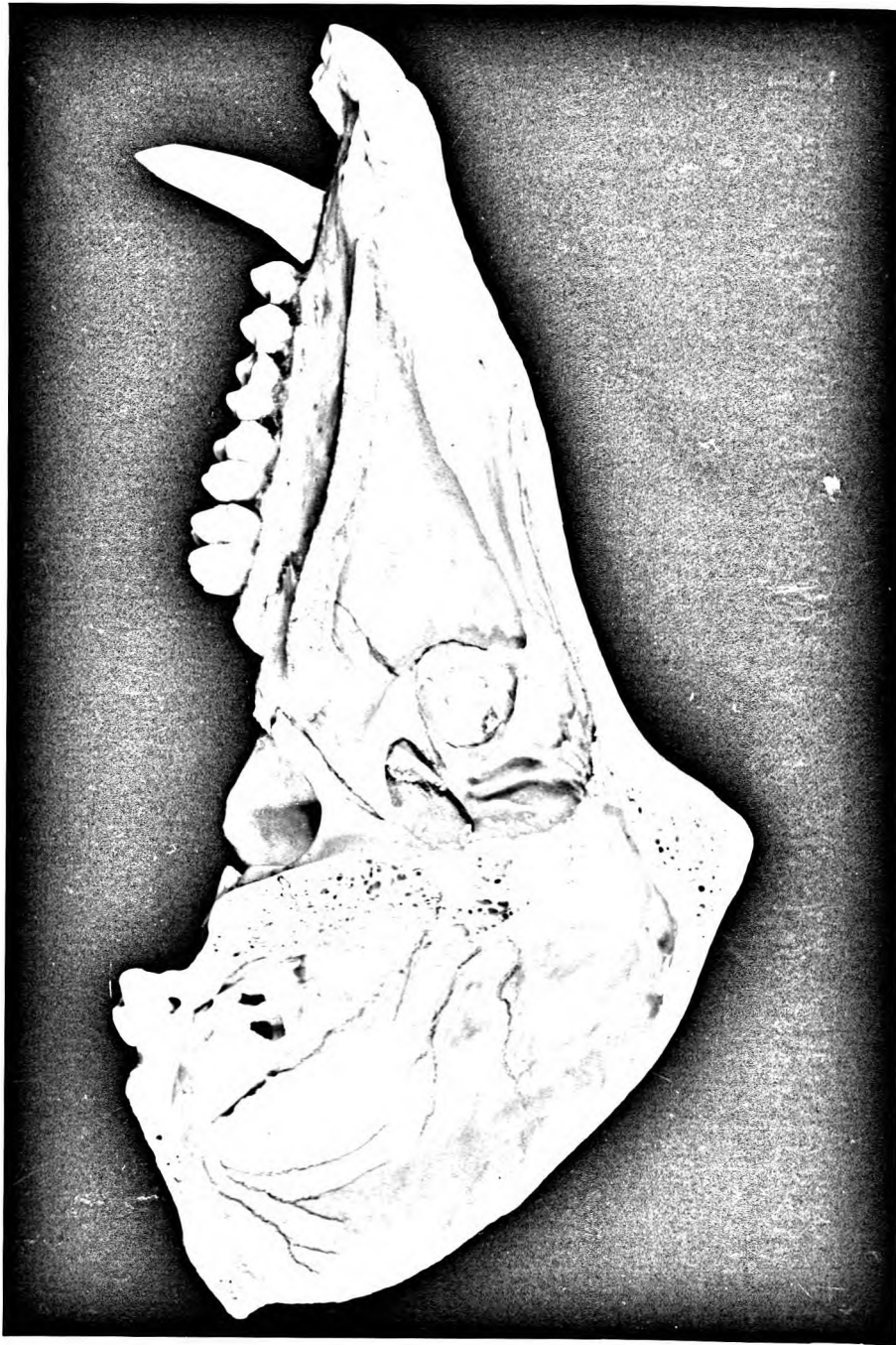


Figure 48.

Figure 48. Sphenoidal synchondroses.

## THE MANDIBLE

The mandible is the moving element of the temporomandibular joint. The baboon mandible corresponds in size with the upper jaw. A large simian shelf gives the symphyseal region a massive appearance as compared with the molar region. The symphyseal region bears the incisors, canines and sectorial first premolar (premolar 3). This premolar is characteristic of all baboons and other members of the Cercopithecoidea with large maxillary canines (James, 1960). The incisors and canines of the upper jaw and the incisors, canines and sectorial premolars of the lower jaw form an occlusal complex for crushing tough food and for biting. James has pointed out that the incisor region is an area of sensory perception. The upper canines and incisors are innervated by large branches of the infra-orbital nerves which occupy canals in the maxillary ridges. The lower incisors, canines and sectorial premolar are innervated by large terminal branches of the inferior dental nerves. Terminal branches of this nerve also supply the gums and lips. This observation not only supports James' thesis but explains the occlusal complex of the ventral aspect of the jaws. Furthermore, it accounts for the 'lip smacking display' and 'teeth chattering' communication behaviour of baboons (Marler, 1965).

The incisors, canines and premolars of the mandible are firmly fixed in the symphyseal region. On each side a bony buttress develops to form the caudal border of the body of the mandible. The trabeculae of this buttress continue dorsally to the dorsal aspect of the ramus (Figure 49). The simian shelf continues dorsally on either side to blend with the alveoli of the second premolars and molars. This region then gives rise to a bony strut which surrounds the postmolar gutter and extends into coronoid and condylar processes. Thus in the baboon the articular condyle is clearly the fulcrum of the lever. The mandibular fossa varies in depth and separates the premolar molar alveolus from the caudal border of the mandible, and is not evident on the medial aspect. The mandibular fossa is deeper in the less robust mandibles with sinuous lower borders, and does not appear to be related to the size of the buccal pouch but apparently reinforces the body of the mandible like a dome reinforces a building. The mylohyoid line

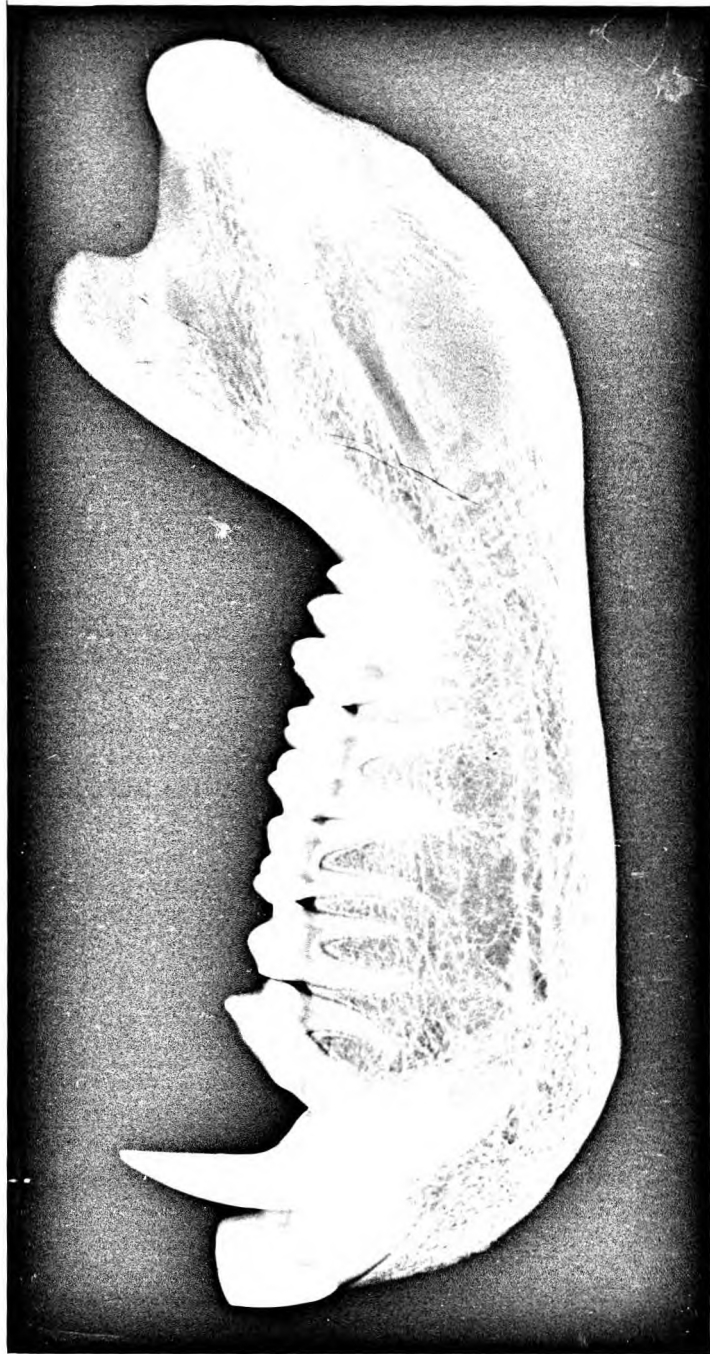

Figure 49.



Figure 49. Radiograph of the lateral aspect of  
the mandible.

---

reinforces the mandible on the medial aspect and blends with the molar buttress. Depression of the mandible is brought about by the combined action of the lateral pterygoid, digastric, suprahyoid and platysma colli muscles. This action of platysma has not been commented on before.

A symphyseal canal is found in many primates and occasionally in man (de Villiers, 1968). It contains terminal branches of the lingual artery which serve as additional nutrient arteries to the large symphyseal region.

The ramus is obliquely placed on the body of the mandible. The robustness of the rami and their obliquity vary considerably. Type 1 skulls are associated with slender more obliquely placed mandibular rami, whereas Type 11 skulls have broad robust rami set less obliquely. These differences can only be related to variations of the temporal muscles which also affect the shape of the coronoid processes.

The articular fossa found in animals with an omnivorous diet is wide and shallow (James, 1960). This type of articular fossa is found in baboons but the caudal compartment of the temporomandibular joint is a deep concavity to allow wide opening of jaws.

The mandible of the adult female baboon is smaller and less robust than that of the male. It resembles that of the male but there is not the same relationship between the mandibular and cranial types as in the male. The mandibular articular fossa of the female differs from that of the male in that it is more concave and shows a slight eminentia articularis. The presence of an eminentia articularis indicates that the incisors can be drawn forward into occlusion when the jaw is protracted (James, 1960), and renders the incisor area more sensitive. This is important to the female baboon when teaching baby baboons diet selection. An eminentia articularis also indicates that the cranial compartment of the temporomandibular joint is relatively larger in the female. This feature together with the rounded ventral part of the dental arcade and the small canines allows for slight rotatory movements during chewing.

## GENERAL CONCLUSIONS

Anatomical and taxonomic conclusions may be drawn from the present study.

### A. Anatomical.

- i. Structurally the cranium and mandible of the baboon is adapted to baboon ecology and social behaviour.
- ii. Maxillary and mandibular buttresses are similar to those described in other primates. These buttresses transmit the forces exerted by the powerful masticatory muscles to the cranium. Type 1 and Type 11 crania are associated with different temporal muscles resulting in different cranio-facial types.
- iii. An articular eminence occurs in the mandibular articular fossa of the female baboon but not in the male mandibular articular fossa. This signifies a difference of bite and occlusion.
- iv. The blood supply and the nerve supply to the ventral areas of upper and lower jaws emphasize the importance of these structures as sensory perceptors. The artery of the symphyseal canal is in fact a nutrient artery.
- v. The sutures and synchondroses are elaborated to counteract and transmit masticatory forces from the jaws to the neurocranium.
- vi. A maxillary sinus is present in the baboon. The medial wall of the sinus is covered by mucous membrane so that this becomes a maxillary recess in dried specimens.
- vii. The periosteal layer of the duramater has considerable osteogenic properties.

### B. Taxonomic.

- i. Two main types may be recognised among the numerous cranio-facial forms seen in this survey.  
Type 1 as exemplified by specimens from Chipinga, the Magaliesberge, South West Africa and the Zambezi Valley, exhibit small maxillary ridges, shallow maxillary fossae, ventrally directed zygomatic bones, large ventral orbital margins, well developed superciliary ridges, high temporal lines and a well developed sagittal crest.

Type 11 as exemplified by specimens from Eastern Cape, Murahwas Kraal and Umtali exhibit large flared maxillary ridges, deep maxillary fossae, ventrolaterally directed zygomatic bones, small ventral orbital margins, a large supraorbital torus, low temporal lines and no sagittal crest.

In a Type 1 skull the greater element of the temporal muscle lies dorsally while in a Type 11 skull the greater element of the muscle is ventral.

- ii. A Type 1 skull has a relatively slender mandible, with a deep mandibular fossa and a sinuous caudal border. A Type 11 skull has a more robust mandible, a shallow mandibular fossa and a straight caudal border.
- iii. The skulls of the six adult female baboons from the same troop illustrate that numerous craniofacial types may occur in a single troop. This observation casts some doubts on the validity of the present classification of fossil Cercopithecoidea.
- iv. The present study has shown that there is no justification for a specific or subspecific classification of baboons south of the Zambezi. It is clear that the Southern African baboons belong to one species with troop and intertroop variations. Furthermore, the skeletal remains of animals kept in captivity for long periods should not be used for taxonomic studies.
- v. The observations on the individual bones of the skull emphasize the need for similar studies on the skulls of all primates and mammals.

## REFERENCES.

1. Hartman, L.G. & Strauss, W.L.Jnr. 1933. The Anatomy of the Rhesus Monkey. New York. Hafner Publishing Co.
2. Freedman, L. 1957. The Fossil Cercopithecoidea of South Africa. Annals of the Transvaal Museum. Vol.23, Part. 2. 124-131.
3. Roberts, A. 1951. The Mammals of South Africa. 1st ed. Johannesburg. 'The Mammals of South Africa' Book Fund. 6-14.
4. Goldblatt, I. 1926. The Cranial Characters of some South African Baboons. S. Afr. J. Sci. 23. 764-83.
5. Neal, H. & Rand, H. 1936. Comparative Anatomy, London. H.K.Lewis & Co. 223.
6. Broom, R. 1930. The Origin of the Human Skeleton, London. H. & F.Witherby. 89.
7. Reynolds, B.H. 1913. The Vertebrate Skeleton, Cambridge at the University Press. 19.
8. Hill, W.C.O. 1957. Primates. Comparative Anatomy and Taxonomy 111, Pithecoidea Platyrrhine, Edinburgh : at the University Press.
9. Clark, W.E.Le Gros. 1971. The Antecedents of Man. Edinburgh : at the University Press. 131-132, 161.
10. Trevor-Jones, T.R. 1972. The Ethmoid, the Vomer and the Palatine Bones from the Baboon Skull. S. Afr. J. Sci. 68. 156-61.
11. Dart, R.A. 1972. Personal communication.
12. Zuckerman, S. 1962. Growth changes in the Skull of the Baboon, *Papio porcarius*. Proc. Zool. Soc. Lond. 55. 843-73.
13. Marais, E.N. 1939. My Friends the Baboons. Methuen & Co.Ltd. London. 19-21.

14. Napier, J.R. & Napier, P.H. 1967. A Handbook of Living Primates. London, New York. Academic Press. 247.
15. Trevor, J.C. 1959. 'Anthropometry' in Chambers Encyclopaedia, London Newnes. 458-62.
16. De Klerk, W.A., Kotze, P.J., Weight, N.J., Menn, I.V., Matthews, M.J.A., McDonald, T., 1973. The influence of various dietary ascorbic acid levels on Serum Ascorbic Acid and Serum Cholesterol values of the Baboon (*papio ursinus*) during captivity. S.A. Med. J. 47. 1503-1506.
17. Jones, T.R. 1937. A new fossil primate from Sterkfontein, Krugersdorp. Transvaal. S. Afr. J. Sci. 33. 709-28.
18. DeVore, I. & Hall, K.R.L. 1965. In: In Primate Behaviour. Ed. Irven DeVore, New York, Chicago, San Francisco, Toronto, London. Holt, Rinehart and Winston. 49.
19. Scott, J.H. 1963. Factors determining the skull form in Primates. Sym. Zool. Soc. Lond. No.10. 127-133.
20. Schultz A.H. 1944. Age changes and variability in Gibbons. Amer. J. Phys. Anthropol. N.S.2 : 1-129.
21. Scott, J.H. 1969. Dento-facial development and growth. Oxford. London. Pergamon Press. 108.
22. Washburn, S.L. 1949. The relation of the temporal muscle to the form of the skull. Anat. Rec., 99, 239.
23. Detwiller, S.R. 1936. Neuro-embryology. MacMillan, New York.
24. Inkster, R G. 1964. In Cunninghams Textbook of Anatomy. Ed. Romanes G.R. London, Oxford University Press. 104-146.
25. Frazer, J.E. 1965. Frazer's the Anatomy of the Human Skeleton. Ed. Breathnach, London. J & A Churchill Ltd. 182.
26. Clark, W.E.Le Gros. 1971. The Antecedents of Man. Ediburgh. at the University Press. 131.

27. Howell, A.B. & Strauss, W.L. 1969. In The Anatomy of the Rhesus Monkey. New York. Hafner Publishing Co. 97.
28. Tobias, P.V. 1967. Olduvai Gorge. The cranium and maxillary dentition of Australopithecus (Zinjanthropus boisei) Ed. Leakey, L.S.B., Cambridge. at the University Press. Vol.2. 33.
29. Swindler, D. McCoy, H.A., Hornbeck, P.V., 1966-67. The Baboon in Medical Research. Austin, University of Texas Press. Vol.2. 133-150.
30. James, W.W. 1960. The Jaws and Teeth of Primates. London, Medical Publishing Co.Ltd. 11.
31. Sullivan, W.E. 1933. In The Anatomy of the Rhesus Monkey, New York. Hafner Publishing Co. 52.
32. Weidenreich, F. 1943. The skull of *Sinanthropus pekinensis*, Palaeont. sin 127. 1-486.
33. Padget, D.H. 1957. The development of the cranial venous system in man from the viewpoint of comparative anatomy. Contributions to Embryology No.247. 81-139.
34. Wislocki, G.B. 1937. The meningeal relations of the hypophysis cerebri.ii. An embryological study of the meninges and blood vessels of the human hypophysis. Amer. J. Anat. 61. 95-130.
35. Klintworth, G.K. 1968. The comparative anatomy and phylogeny of the Tentorium cerebelli. Anat. Rec., 160 635-42.
36. Starch, D. 1967. Some remarks on morphological problems of the baboon skull. Anatomisches Institut Frankfurt am Main 184-187.
37. Reynolds, S.H. 1913. The vertebrate skeleton. Cambridge. at the University Press.
38. Negus, Sir Victor. 1958. The comparative anatomy and physiology of the nose and paranasal sinuses. E & S Livingstone Edinburgh and London. 293-295.

39. O'Donovan, W. 1969. Personal communication.
40. James, W.W. 1957. A further study of dentine.  
Trans. Zool. Soc. Lond. 29 Pt.1 2-48.
41. Marler, P. 1965. In: In Primate Behaviour. ed. DeVore  
Irven. New York, Chicago, San Francisco, Toronto,  
London. Holt, Rinehardt and Winston. 571.
42. De Villiers, H. 1968. The skull of the S.A.Negro.  
Johannesburg. Witwatersrand University Press. 148.