

The Response of the Exposed Dental Pulp to a Calcium Hydroxide-Corticosteroid Mixture

W W Bloch and J C Austin

Dental Research Unit of the South African Medical Research Council and the University of the Witwatersrand, Jan Smuts Avenue, Johannesburg

SUMMARY

*A total of 77 tooth pulps in 4 adult vervet monkeys were exposed. Half were capped with calcium hydroxide and half with a mixture of calcium hydroxide and a corticosteroid paste (Pulpomyxine**). Histological evaluation of the pulpal responses to these materials revealed no statistically significant differences between them.*

OPSOMMING

*'n Totaal van 77 tandpulpa is in 4 volwasse blou-apies ontbloot. Helfte van die tandpulpas is met kalsiumhidroksied, en die ander helfte met 'n mengsel van kalsiumhidroksied en 'n kortikosteroïede paste (Pulpomyxine**) bedek. 'n Histologiese ondersoek van die reaksies van die pulpa teenoor hierdie materiale het geen statisties noemenswaardige verskille tussen die twee groepe getoon nie.*

INTRODUCTION

In recent years there has been a renewed interest in the local use of corticosteroids in the pulp capping of exposed pulps, although this use is still controversial (Seltzer 1968). Much of the controversy results from the fact that in clinical practice it is difficult to assess accurately the pulpal effects of a dental material. Thus an apparently satisfactory clinical result may be obtained which might not be so histologically (Fiore-Donno and Baume 1962, and Mosteller 1968).

This study was undertaken to compare the histological response to pulp capping with calcium hydroxide (Dycal), to that obtained with a mixture of calcium hydroxide and a corticosteroid paste (Pulpomyxine) in exposed vital pulps in the vervet monkey.

MATERIALS AND METHODS

Four adult vervet monkeys (*Cercopithecus aethiops*) in which the third molar teeth had erupted were used. Labial class V cavities were prepared in all the teeth of the anaesthetised animals, with the exception of the upper and lower canines which are difficult to extract and the lower first premolars which have a morphology different to that of man (Ockerse 1959). The cavities were cut using a water-cooled No. 2 inverted cone bur run at a speed of approximately 5000 rpm.

Once the cavities had been cut, the teeth were isolated with cotton wool rolls and their pulps carefully exposed using a sterile No. 3 round bur. After the bleeding had stopped, each exposed pulp in one upper quadrant was capped with a mixture of Dy-

cal*, a calcium hydroxide paste, and Pulpomyxine** in the proportions of approximately four parts to one.

All the cavities were sealed with Nobotec***, a modified zinc oxide-eugenol cement containing resins and Terylene fibres.

As a control, the exposed pulps in the contralateral quadrant in the upper jaw were capped with Dycal alone. The procedure was reversed in the contralateral quadrants of the lower jaw.

The animals were killed at intervals of 1, 2, 4 and 8 weeks after the pulp exposures, with an intravenous overdose of pentobarbitone sodium. Prior to fixation the jaws were wedged open with a clamp to facilitate extraction. Their thoracic aortas were then sectioned at the proximal end and cannulated. The animals were perfused with one litre of physiological saline followed by 10 per cent neutral buffered formol-saline (Retief and Austin 1973).

After fixation, the buccal and lingual alveolar plates were removed with an osteotome and the teeth gently extracted in order to avoid damage to the fixed pulpal tissues. Each extracted tooth was coded with a random number (Scientific Tables-Documenta Geigy 1962). The teeth were decalcified in 5 per cent nitric acid under radiographic control followed by dehydration in serial ethanols and embedded in Paraplast**** under vacuum. Longitudinal serial sections were cut at 7 μ m and stained with haematoxylin and eosin. The pulpal reactions were then evaluated and graded into mild, moderate or severe based on the criteria used by Mjör and Tronstad (1972), and the evaluation was modified to take into account the fact that in

* The L.D. Caulk Company, Milford, Delaware, U.S.A.

** Spécialites Septodont, 29, Rue des Pettites-Ecuries, Paris, France.

*** Bofors, Nobel-Pharma, Sweden.

**** Sherwood Medical Industries, St Louis, Missouri 63103, U.S.A.

this study the pulps of the teeth were exposed. The pulpal responses were graded as follows:

Mild reaction:

A dentine bridge may or may not be present. Characteristically very few inflammatory cells are found beneath the dentine bridge when a bridge is present. There is no abscess formation and an otherwise normal pulp is present.

Moderate reaction:

A dentine bridge may or may not be present. There is a larger number of inflammatory cells beneath the dentine bridge when a bridge is present. There is no abscess formation and the remaining pulpal tissue is normal.

Severe reaction:

This is characterised by a marked cellular infiltration with localised or general abscess formation with or without the formation of a dentine bridge.

The reactions were given a score as follows: a mild response was given a value of 1, a moderate response a value of 2 and a severe response a value of 5.

Once the evaluation was completed, the code was broken and the results organised into the three experimental groups. A mean score of the pulpal responses of the control and experimental teeth at each time interval was calculated using the following formula.

$$\text{Mean Score Value} = \frac{n \times 1 + n \times 3 + n \times 5}{N}$$

n = Number of teeth

N = Total number of teeth

A statistical analysis of the results was carried out using the Chi-squared test.

RESULTS

Fifty-three of the 77 teeth prepared were found suitable for evaluation. The remaining 17 were discarded owing to fracture during extraction or unsatisfactory sectioning.

Of the teeth used in this experiment, 35.8 per cent showed a dentine bridge when examined histologically (Fig. 1). A dentine bridge was found under all three kinds of reactions. The dentine bridge formed below the pulp capping material and in many instances completely sealed the exposure site. In some studies the dentine bridge was incomplete and in some, pulpal tissue or chronic inflammatory cells were included in the bridge. The dentine bridge tissues were composed of osteodentine. After one week 60 per cent of the teeth capped with Dycal showed a mild response, and 0 per cent had a moderate response, while 40 per cent had a severe response. For Dycal and Pulpomyxine 37.5 per cent had a mild, 37.5 per cent a moderate and 25 per cent a severe response.

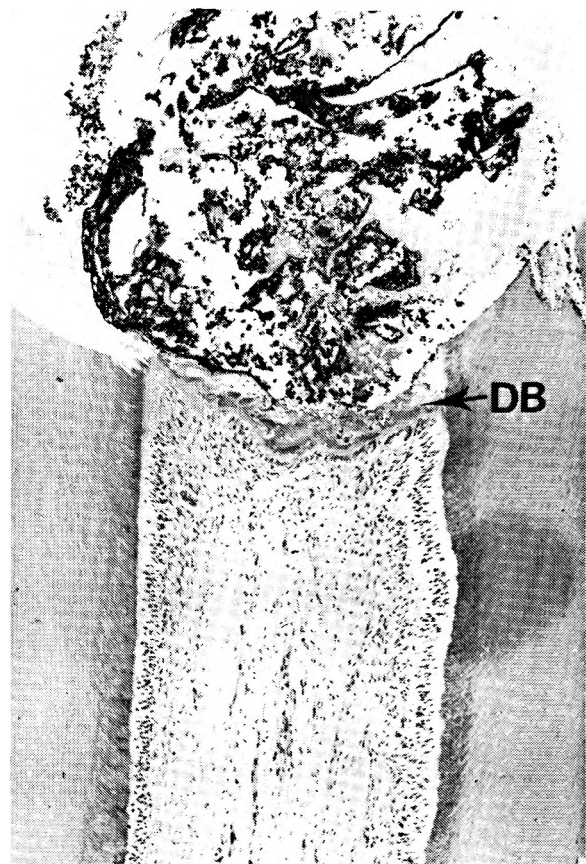


Fig. 1. Exposed dental pulp showing a dentine bridge (DB), mild pulpal response, and the remains of the dycal capping material. Haematoxylin and eosin. X 200.

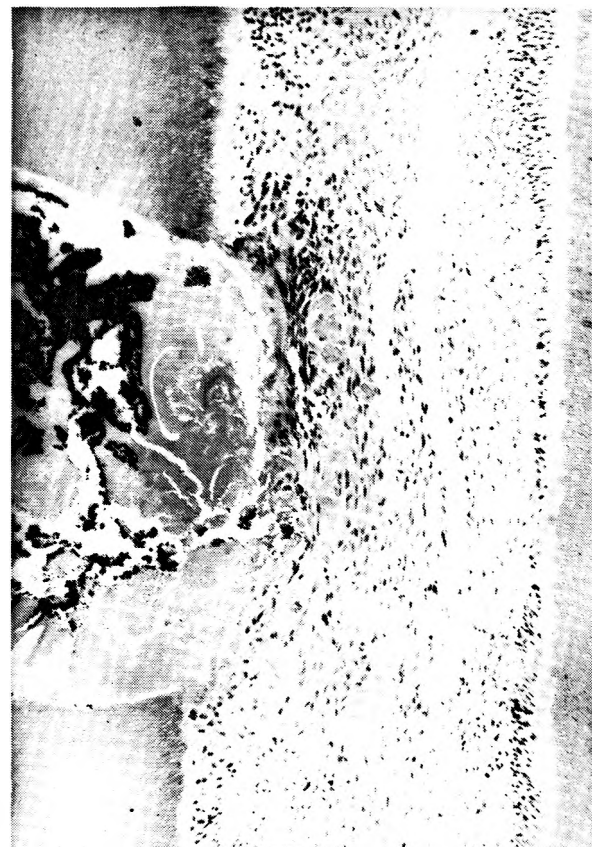

Fig. 2. In this exposed pulp there is no dentine bridge. A mild pulpal inflammatory response is present. Haematoxylin and eosin. X 300.

After two weeks 60 per cent of the teeth capped with Dycal had a mild response, 0 per cent a moderate and 40 per cent a severe response. For Dycal and Pulpomyxine 75 per cent had a mild, 12.5 per cent a moderate and 12.5 per cent a severe response. After four weeks the results for Dycal showed that 33.3 per cent had a mild response, 0 per cent a moderate and 66.6 per cent a severe response, whereas for pulps capped with Dycal and Pulpomyxine 14.3 per cent had a mild, 28.6 per cent moderate and 57.2 per cent a severe response.

After 8 weeks, for Dycal the mild response was 81 per cent, the moderate (Fig. 2) 9.1 per cent and the severe response 9.1 per cent. For Dycal and Pulpomyxine the mild response was 83.3 per cent, the moderate response 0 per cent and the severe response (Fig. 3) 16.7 per cent.

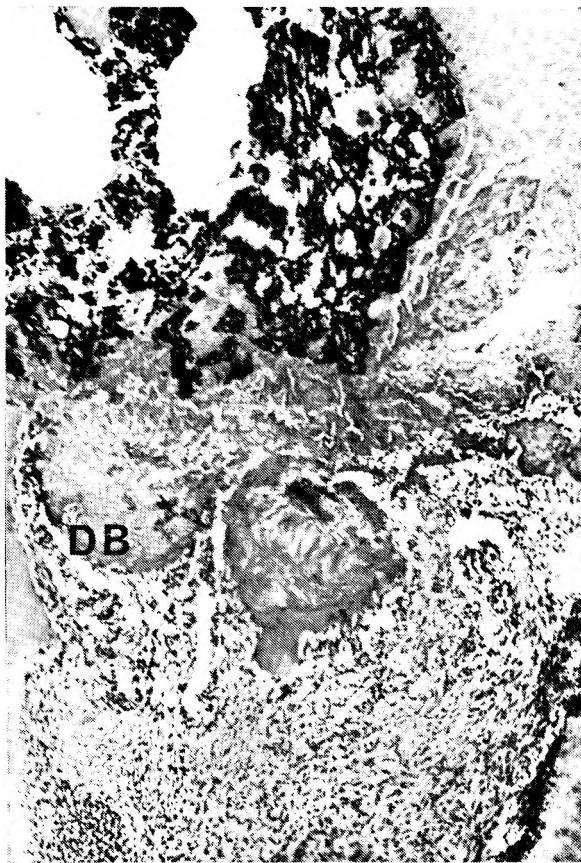


Fig. 3. The severe pulpal reaction may be seen even in presence of a dentine bridge (DB). Haematoxylin and eosin. X 300.

The mean score values are listed in Table I. At one week the mean score values of Dycal and the Dycal and Pulpomyxine mixtures were almost the same, while at 2 weeks, Dycal had a slightly higher value than Dycal plus Pulpomyxine. At 4 weeks the mean scores for Dycal and Dycal and Pulpomyxine are very similar. The mean score values for Dycal and Dycal and Pulpomyxine at 8 weeks are the same. The lower the score, the milder the reactions.

The Chi-squared test showed no statistically significant differences in any of the groups.

Table 1: Average pulpal response scores at the various time intervals

Post-exposure time (weeks)	Dycal	Material Dycal + Pulpomyxine	X ²
1	2,6	2,8	2,42*
2	2,6	1,8	1,73*
4	3,7	3,9	1,60*
8	1,6	1,6	0,72*

* = not statistically significant

DISCUSSION

The vervet monkey has been shown to be a good model for testing pulpal reactions (Retief and Austin 1973) as their teeth are very similar morphologically and histologically to that of man (Ockerse 1959, 1963).

Although one would have expected that a successful clinical result would have given a similar histological result, this was shown not to be so. This study has shown that the dentine bridge so often seen clinically is not the sole criterion for success. The criteria for success initially were the formation of a complete or incomplete dentine bridge, with a minimum amount of inflammation below the bridge and the remainder of the pulp appearing more or less normal.

There is disagreement concerning the histological criteria for a successful pulp capping. Most researchers are in agreement that for a pulp capping to be successful, there must be no degenerative or inflammatory changes and that dentinal bridging or reactions of the exposed area should indicate an obliterating process (Anneroth and Bang 1972).

When assessing a dentine bridge, the complete series of serial sections should be assessed, as one section may show a complete bridge, whereas other sections in the series may show an incomplete bridge. In this study a hard dentine barrier formed under the corticosteroid-calcium hydroxide pulp capping mixture and this observation is in accordance with that of Schroeder and Asal (1971).

From the results of this study it would appear that pulpomyxine had no influence on the inflammatory response of the pulp, which confirms the finding of Langeland, Tobon and Langeland (1968). This finding is not in agreement with other workers such as Schroeder and Schroeder (1960), and Dachi, Ross and Stigers (1964) who found that the corticosteroids have an influence on the inflammatory response of the pulp.

ACKNOWLEDGEMENTS

We would like to thank Dr. P. Cleaton-Jones and also Mrs. D. Banks, Mrs. R. Ichilcik, Miss B. Slack, Miss E. Vieira and Mrs. H. Wilton-Cox for their assistance.

REFERENCES

- Anneroth, G. & Bang, G. (1972) The effect of allogenic demineralized dentin as a pulp capping agent in Java monkeys. *Odontogisk Revy*, **23**, 315-328.
- Dachi, S.F., Ross, A & Stigers, R.W. (1964) Effects of prednisolone on the thermal sensitivity and pulpal reactions of silicate restored teeth. *Journal of Prosthetic Dentistry*, **14**, 1124-1132.
- Fiore-Donno, G. & Baume, L.J. (1962) Effects of capping compounds containing corticosteroids on the human dental pulp. *Helvetica Odontologica Acta*, **6**, 23-32.
- Langeland, K., Tobon, G. & Langeland, L.K. (1968) The effect of corticosteroids on the dental pulp. *Transactions of the Fourth International Conference on Endodontics*, 15-25.
- Mjör, I.A. & Tronstad, L. (1972) Experimentally induced pulpitis. *Oral Surgery, Oral Medicine and Oral Pathology*, **34**, 102-108.
- Mosteller, J.H. (1968) Discussion of: Conservative pulp therapy. *Transactions of the Fourth International Conference on Endodontics*, 58-61.
- Ockerse, T. (1959) The anatomy of the teeth of the vervet monkey. *Journal of the Dental Association of South Africa*, **14**, 209-226.
- Ockerse, T. (1963) The histology of the teeth of the vervet monkey. *Journal of the Dental Association of South Africa*, **18**, 35-40.
- Retief, D.H. & Austin, J.C. (1973) The vervet monkey (*Cercopithecus aethiops*) as an experimental model for pulpal studies. *Journal of the Dental Association of South Africa*, **28**, 98-103.
- Schroeder, A. & Asal, E. (1971) Application of corticosteroids and formation of hard substances under calcium hydroxide. *Deutsche Zahnarzt*, **26**, 449-455.
- Schroeder, T. & Schroeder, A. (1972) Possibilities and limits of preserving vitality of the pulp. *Zahnaertliche Praxis*, **23** (b), 147-148.
- Scientific tables*. (1962) *Documenta Geigy*, ed. Diem, K., 6th ed., p 131. Basle, J.R. Geigy S.A.
- Seltzer, S. (1968) Discussion of: The effect of corticosteroids on the dental pulp. *Transactions of the Fourth International Conference on Endodontics*, 45-48.