THE STRUCTURE OF THE DIENCEPHALON IN THE INSECTIVORA (ESPECIALLY ELEPHANTULUS MYURUS), THE TUPAIOIDEA AND THE PROSIMIAN PRIMATES, WITH SPECIAL REFERENCE TO THE EVOLUTION OF THE PRIMATE DIENCEPHALON

Robert Michael Thomas Simmons, M.Sc. (Witwatersrand)

Volume I

To Professor Proctor,
with my best wishes and
thanks for everything,
Robert Simmons.

THE STRUCTURE OF THE DIENCEPHALON IN THE INSECTIVORA (ESPECIALLY ELEPHANTULUS MYURUS), THE TUPAIOIDEA AND THE PROSIMIAN PRIMATES, WITH SPECIAL REFERENCE TO THE EVOLUTION OF THE PRIMATE DIENCEPHALON

Robert Michael Thomas Simmons, M.Sc. (Witwatersrand)

A Thesis submitted to the Faculty of Science, University of the Witwatersrand, Johannesburg, for the degree of Doctor of Philosophy

Johannesburg, 1974

DECLARATION

This is to certify that the thesis entitled "The Structure of the Diencephalon in the Insectivora (especially *Elephantulus myurus*), the Tupaioidea and the prosimian primates, with special reference to the evolution of the primate diencephalon" is my own unaided work, and that it has not been previously accepted for any degree in any university.

Date: September 16th, 1974

ABSTRACT

The comparative structure of the diencephalon was investigated in the elephant shrew, the tree-shrew and several of the prosimian and anthropoid primates, including man. The brains were perfused with and fixed in formol saline. Most of those brains were sectioned transversely; others horizontally and sagitally. Sections of the diencephalon were stained with the cresyl-echt violet method for cytology and the study of cytoarchitectonics, and with the Klüver and Barrera, and Simmons techniques for myeloarchitectonics. [illegible]

Various nomenclatures devised by workers over the past fifty years are critically reviewed and compared. The terminology used in this study is a modification of those of Walker (1937), Le Gros Clark (1929 - 1938) and Krieg (1948).

In the study of the morphology and development of the primate diencephalon, it has been observed that several diencephalic structures such as nn. pregeniculatus, reticularis, and zonae incertae have dual ontogenetic and phylogenetic development. These nuclei have two parts, one of which originated from the subthalamic region, and the other from the dorsal thalamic region.

The nuclear configuration and fibre connections of the diencephalon of *Elephantulus myurus*, *Tupaia*, *Microcebus*, *Lepilemur*, *Lemur*, *Galago*, *Perodicticus potto*, *Cercopithecus aethiops* and *Homo* are described, compared and discussed with reference to their evolution. In these species, the thalamic and hypothalamic

nuclei which show more advanced development than others, are nn. anteroventralis, mediodorsalis, centrum medianum, lateralis posterior, pulvinaris, ventrales lateralis and posterior, geniculati lateralis and medialis, subthalamicus and mamillaris medialis. Other diencephalic structures show either regression or stable development throughout the Insectivore-Primate lineage. In two of the prosimian species, Lepilemur and Galago demidovii, an accessory neurosecretory hypothalamic nucleus has been observed; it is more closely related to the paraventricular nucleus than to the supraoptic nucleus, and there is a tenuous cellular connection between these hypothalamic nuclei. N. mediodorsalis shows a clear development from a small and undifferentiated structure in Elephantulus and Tupaia, to one of the largest and most highly complicated structures in higher primates. There is gradual fusion of nn. anteroventralis and anteromedialis into one nucleus, n. anterior principalis, whereas n. anterodorsalis becomes more rudimentary as one ascends the primate scale to man. The ventral posterior nucleus becomes differentiated not only into lateral, medial and inferior parts, but also cytoarchitectonically into discrete portions within the lateral and medial parts of n. ventralis posterior. The lateral geniculate body is clearly divided into two parts, nn. pregeniculatus and geniculatus lateralis; the latter nucleus is well differentiated into cellular and fibrous layers, mostly six; it shows a lateral rotation along the rostrocaudal axis, a change from the inverted to the everted form and a shift from the dorsal position, as in Tupaia, to the ventral position as in anthropoid apes and man. The medial geniculate body shows also some evolutionary changes, i.e., a division into two parts that show different cytoarchitectonics and fibre connections with the adjoining thalamic structures. The mamillary region is better developed and differentiated into various nuclei in higher prosimian and anthropoid primates than in the tupaiids and lower prosimians.

An attempt has been made to throw some light on the taxonomic status of the Tupaioidea, the position of which is still unsettled. It has been classified with the Primates and with the Insectivora, either in the Macroscelidoidea, or as an infraorder, the Tupaiiformes, between the Macroscelidoidea and the Lemuroidea. It has been found, not only from my investigations on the diencephalon of the Tupaiidae, but also from results of other workers on extradiencephalic and non-neuroanatomical structures that the phylogenetic development of the Tupaiidae shows more affinities with primates than with the insectivores. Thus, the Tupaiidae may be classified either with the primates, or in a separate order of their own. The diencephalic structures of the Lemuroidea and Lorisoidea are compared and discussed with regard to the relationship of these prosimian superfamilies with each other and with the Tupaioidea.

ACKNOWLEDGEMENTS

The author wishes to express his deep gratitude to:

Professor P.V. Tobias, Head of the Department of Anatomy, University of the Witwatersrand, for his excellent supervision and advice concerning the execution of research work and preparation of the thesis;

Professors Ann Andrew, J.C. Allan, Hertha de Villiers, and Dr.C.Wallace and all his colleagues and the staff members of the Department of Anatomy for their keen interest and encouragement in carrying out this exhaustive work;

Professor N.P.S. Proctor, Head of the Department of Pathology, University of the Witwatersrand, and the South African Institute for Medical Research, for having provided access to his laboratories during the early years of the work on this topic;

Professor G.A. Doyle, Head of the Department of Psychology, University of the Witwatersrand, for the Galago specimens;

Dr. Alan Walker, formerly of the Department of Anatomy, Makerere University College, Kampale, Uganda, for the brains of many prosimian species, particularly of the bushbaby, lemur and potto;

the United States Army Medical Research Unit, Kuala Lumpur, Malaysia, and Professor C.H. Conaway of the Department of Anatomy, University of Missouri, Columbia, Mo., for the tree-shrew specimens and brains;

Dr. J.-J. Petter, of the Museum of Natural History, Paris France, for the mouse lemur brains;

Dr. Y. Rumpler, of the Pasteur Institute, Tananarive, Madagascar, for the lemur brains;

the Ecology Unit, South African Institute for Medical Research, Johannesburg, for the elephant shrew specimens;

the Poliomyelitis Research Unit, Rietfontein, for the vervet monkey specimens;

Dr. R. van Hoogstraten, a former colleague in the Department of Anatomy, University of the Witwatersrand, for assistance with the perfusion of prosimian brains, and for the human brains;

Mrs. K. Copley - for her generous assistance in typing the corrective notes and advice in carrying out the method of rapid correction work;

Mrs. M. Campbell, Miss. M. Claassen, Mr. and Mrs. R.H. Voss, Mrs. A. Levine, Mr. C.K.E. Burm, Mr. C.L. Burm, Mr. A.S, Shevel and Mrs. M. Lourens - for forming such a wonderful and indefatigable team in mounting of the illustrations, and in carrying out the operation of clearing the manuscripts of typographical, spelling and grammatical errors;

Mr. and Mrs. V.H. Simmons, my parents and the Trustees of the Glanville Scholarship Fund (St. Vincent's School for the Deaf, Johannesburg) for their sponsorship and financial assistance without which the final production of this thesis would not have been possible;

Very special thanks must go to May, my beloved wife, for her wonderful love, encouragement, and also for her sacrifice in giving me much-needed assistance and for her leadership of the team in the final completion of this mammoth task. To her and our children, to our parents and families, this thesis is dedicated.

And finally, thanks and praise to GOD, for His wonderful care and continual help in fulfilling this thesis which, at times, seemed impossible.

Professor R. Bauchot, Head of the Comparative Anatomy Laboratories, University of Paris, France; Professor K. Fermutsch, Department of Anatomy, University of Berne, Switzerland; Professor H. Stephan, Department of Neuroanatomy, Max-Planck Institute for Brain Research, Frankfurt, Germany; and Dr. R.D. Martin, Department of Anthropology, University College of London, England, for their valuable advice and research material, and also for their keen interest in the progress of this study;

Mr. Alun R. Hughes, Supervisor of Laboratory Services, Department of Anatomy, University of the Witwatersrand, for technical advice on photographic techniques;

Mr. R. Klomfass, Department of Anatomy, University of the Witwatersrand, for his kind assistance in removing brains from primate specimens, and advice concerning preservation of research material;

Mr. Peter Faugust, Mr. R. Herman and Miss Dawn Croft for technical assistance in preparing photomicrographs and photographic prints;

Mr. Max Ulrich, Photography Unit, South African Institute for Medical Research, Johannesburg, for his kind assistance in photographing the myelin-stained sections of the diencephalon;

Misses J. Walker and F. Wadvalla, medical illustrators for the University of the Witwatersrand Medical School, for executing beautiful drawings of the sections of the diencephalon and other diagrams;

Miss M. Lucas and her able staff of the Medical School Library for their patience and kind co-operation;

Mrs. Elaine Towsey of the University Typing Pool for her excellent typing and preparation of the manuscripts;

Mrs. Margaret Wallace and Mrs Pat Hadoway - for their kind co-operation in making Xerox copies of this thesis so very promptly;

CONTENTS

PART I

PAGE

PART II

CHAPTER 3 (contd.) PAGE

PAGE

PART III

PAGE

CHAPTER 6 (contd.)

CHAPTER 7 (contd.) PAGE

5. Nucleus tractus optici

PART IV

PAGE

CHAPTER 13 (contd.)

CHAPTER 13 (contd.)

PAGE

PAGE

CHAPTER 15 (contd.)

CHAPTER 16 (contd.)

CHAPTER 17 - THE HYPOTHALAMUS: POSTCHIASMATIC PART

PAGE

CHAPTER 17 (contd.)

PART V

LIST OF TABLES

PAGE

PAGE

LIST OF TABLES (contd.)

ILLUSTRATIONS:

PART I -

INTRODUCTION, MATERIAL AND METHODS

CHAPTER I

INTRODUCTION

1. SCOPE OF RESEARCH WORK ON THE PROSIMIAN DIENCEPHALON IN THIS STUDY

The purpose of this thesis is to study the topography and architectonics of the diencephalon of lower primates (Prosimii), and to compare it with those of higher primates (Anthropoidea) and insectivores. Since the tree Shrew (*Tupaia*) is still regarded by many primatologists and zoologists as a "borderline" species between Insectivora and Primates, comparisons of its diencephalon are made with those of the elephant shrew (*Elephantulus myurus*) and of the mouse lemur (*Microcebus murinus*), its closest relatives, in order to assess possible evolutionary changes in the prosimian diencephalon.

In this thesis, I have carried out only qualitative studies of the diencephalic structures, although some quantitative work of subjective value had been done on cellular sizes without attempting to make comparisons of absolute sizes to the absolute size of the brain as a whole. The results of any qualitative study of the brain or any part of the brain do not give adequate reasons for separating the Tupaiidae from the Macroscelididae, or placing the Lorisidae on a taxonomic rank higher than that of the Lemuridae, e.g., the lamination of the lateral geniculate nucleus or enlargement of the pulvinar are not good criteria for making objective judgements of its phylogenetic development in Primates. To achieve really satisfactory results in evaluating the evolutionary progress of the diencephalon in any primate species, it is essential to bear in mind the relationships of body and brain sizes or weights, without which one cannot estimate the indices of progression or regression of the diencephalic structures in primates or any of the non-primate mammalian groups. As there was not a sufficient number of research specimens to carry out quantitative comparisons of the diencephalic structures (many of the research materials were obtained without information on body and brain weights or sizes), I had to resort to the qualitative methods in studying the nuclear configuration and topography of the diencephalon in *Elephantulus*, the Tupaiidae and Primates.

The quantitative work in this study was done only on the measurements of cells in the diencephalic structures without basing it on the methods of Bauchot, Stephan and their associates on brain structures (1964-1970).

Le Gros Clark (1929) mentioned in the opening paragraph of his article on the thalamus of Tupaia minor that comparative study of the mammalian "optic" thalamus had reached a much less advanced stage than that of other parts of the brain. In the past forty-five years, much literature has accumulated on the mammalian thalamus, thus, improving our knowledge of its anatomy and histology quite tremendously, but its evolution in relation to the rapid development of the cerebral cortex throughout the Primate scale is still not fully understood. Le Gros Clark pointed out also that the homologies of various thalamic nuclei of mammals are far from settled. Attempts to determine them are blocked up partly because the definition of certain elements of the thalamus requires detailed attention to the cyto- and myelo-architecture of thalamic structures, partly because of the confusing nomenclature used by various authors, and partly, too, because at the time of Le Gros Clark's work on Tupaia minor and Tarsius (1929, 1930) the literature on the primate thalamus was inadequate. Le Gros Clark was convinced that our knowledge would improve greatly if the thalamus of primates were compared with that of non-primate mammals. Therefore, Le Gros Clark thought that the tree-shrew might provide suitable material for this sort of study, since at that time, the tree-shrew was regarded as an insectivore of the most advanced type. Furthermore, its thalamus offers a fair comparison with those of *Elephantulus* and *Erinaceus* (insectivores), and of less advanced prosimian species, e.g., *Microcebus* and *Galago demidovii*, whose brains are of comparable size, but exhibit considerable differences in the development of various elements of the cerebrum. Such a differential development is, to a large extent, reflected in the structure of the thalamus.

The thalamus of higher mammals has become such a complicated structure that it is virtually impossible to analyze by direct methods. It is, therefore, essential to define the composition of the thalamus by studying it in a simpler form as found in any small generalized mammal. Then a closely graded series of mammalian and primate brains can be arranged, to correspond as nearly as may be to a *true* phylogenetic series so that it will be possible to trace, by direct comparison, the changes which occur in the development of the more complex from the more simple type of thalamus, and to establish satisfactory homologues of its components. Otherwise, if a comparison is made between the thalamus of man and the thalamus of dog or rat without reference to the intermediate forms, erroneous interpretations may arise. Studies of comparative anatomy of the central nervous system, particularly in primates, is of immense value in establishing a better understanding of phylogenetic relationships among primates, between prosimians and simians, and between primates and non-primates. By the very nature of cortical activity, it would be expected that regressive changes have been undergone in subcortical structures during the course of evolution. In other words, the general concept of irreversibility of evolution might be shown to have considerable validity, i.e. the evolution of the neocortex cannot be expected to reverse its course of development, or in the thalamus, one may expect some nuclei to develop concomitantly with certain parts of the cerebral cortex where there is a progressive elaboration of higher functions of the brain, e.g., development of speech, dexterous use of limbs.

The neuro-anatomical term 'nucleus' has particular meanings outside its significance in the sense of classification. Originally, it was used to designate large masses of grey substance which do not reach the surface. Now, the term nucleus is used more systematically to define a delimited region of grey substance which can be distinguished from adjacent regions by 'local differences of number, arrangement and morphology of the tissue elements as they appear with selective histological methods' (Vogt 1941). The other term 'subnucleus' is to define a subunit which is delimited according to criteria of its connections, of somatotopic arrangement or of finer cytological differences. The term 'area' is applied to a sheet of grey substance, e.g. cerebral cortex, hypothalamic areas, where dividing lines are drawn across a region that is to be delimited into areas.

The interior of the diencephalon is constituted of complex structures of grey matter which are diffusely permeated by isomorphous layers of different types of cells or neurones. These layers form zones as they increase and decrease in density. Some of the zones are clearly circumscribed and well-rounded, that is, they form nuclei in the true sense, and their boundaries are easily defined by cyto- and myelo- architectonical methods. But this is not so with dispersive cellular areas, and in connection with this, there have been differing opinions among neuro-anatomists as to how the areas should be subdivided and defined. What the workers all have agreed, is that the brain is composed of units of varying functional importance. Therefore, the morphological classification of any nervous structure, e.g., thalamus, attempts to make the subdivision in such a way as to be meaningful also from a functional standpoint. Different methods or principles of classification have been applied such as topographic, quantitative, qualitative (cytological), cytoarchitectonic and myeloarchitectonic methods.

In regard to the present method of studying the neurones in the diencephalon, only the qualitative and cytoarchitectonic methods have been used. The qualitative or cytological principle is founded on the concept that the neurone constitutes the basic element of the central nervous system. It rests also on the assumption that structural differences between neurones, single or in groups, are expressions of differences in function. These neuronal differences, which are particularly evident in cresyl echt-violet sections, can be worked in more detail through histological and histochemical procedures. The qualitative method is, therefore, concerned with structural differences between neuronal types. Neurones of similar types and origins are found usually together in a cortical layer or a subcortical grey substance, thereby, demonstrating a close relationship between cell type and function. Thus, the cytological type is more important than other types, and should be also the most acceptable principle for functional classification of a subcortical grey mass, provided that there are no irregularities arising from unknown synaptological and morphogenetic conditions which might appear in the form of indistinct boundaries between nuclei containing different types of neurones. There are different types of cells that may depart from their isomorphous characteristics by changing in structure and intermingling in varying extents in different areas, and in different individuals, e.g., nuclei centrum medianum and parafascicularis; nuclei reticularis, pregeniculatus and zonae incertae; hypothalamic areas. At this juncture, the terms 'isomorphism', 'allomorphism', 'heteromorphous' and 'dimorphism' are employed by neuro-anatomists to define the cellular nature of a grey substance or mass in the central nervous system as follows:

(a) Isomorphism - where there is usually one type of nerve cell that is uniformly distributed in an area or a nucleus which is neatly demarcated from other nuclei, e.g., almost all thalamic and subthalamic nuclei, and some of the hypothalamic nuclei such as nn. supraopticus, paraventricularis, mamillaris lateralis.

(b) Allomorphism - occurs where there is a notable change in size and shape of cells, presumably due to biological factors, or to a combination of two or three different types of nerve cells in a single area or nucleus. Examples - all hypothalamic areas, ventrolateral, medial and posterior thalamic nuclear groups.

(c) Heteromorphism - variation from the normal in form, i.e., either a deviation from the type or standard of nerve cell or taking on of a different form at different stages in cellular morphogenesis. Heteromorphism occurs fairly frequently among the diencephalic structures, particularly in n. mediodorsalis where there is an appreciable difference in size and shape of cells between two parts of a nucleus or an area. The different cells intermingle with one another to such an extent that it is not possible to define the boundaries of one nucleus from another nucleus.

(d) Dimorphism - the existence of two completely separable forms within a particular nucleus or area, e.g., lateral and medial geniculate bodies.

The allomorphous mixed regions, e.g., hypothalamus, are divided into nuclei on the basis of their degree of neuronal permeation, and these 'nuclei' are regarded as static units with fixed boundaries and of constant occurrence, whereas 'areas' retain the definition of large, undefined regions of grey matter containing various types of cells that are scattered throughout the area. Based on this cytoarchitectonic principle, Feremutsch (1952) introduced his concept of 'scatter-cells', taking only individual factors into consideration. At the same time, he paid particular attention to the distinction between the central grey matter and large-celled nuclei; this method was, however, based largely upon that of Grünthal (1934). After an extensive analysis of the human hypothalamus, Feremutsch was able to define two central grey formations, one periventricular or medial, and one lateral. These formations are made up of nine areas in which nine large-celled nuclei are embedded. These nine nuclei are, in turn, allotted to three basic groups - a rostral (prothalamic or preoptico-supraoptic), a tuberal and a mamillary. This type of differentiation between the central grey matter and large-celled nuclei may sometimes prove a good aid in clarifying the architectonic principle, but it can often lead to contradictions. For instance, from the cytological viewpoint, n. ventromedialis is referred by Feremutsch as a part of the hypothalamic central grey matter, but it has more definite characteristics of a nucleus than of an area and therefore, it should be regarded as a true nucleus. Conversely, the 'nucleus' tuberomamillaris is really an area, because it has a diffuse nature and poorly defined boundaries as characterised by an area rather than a true nucleus. At best, it is regarded as a part of the posterior hypothalamic area which contains many different types of cells.

The question arises whether a nucleus possessing large cells should be regarded as more primitive in structure and function than one containing small cells or not. In the brains of lower mammals, and to some extent, in submammalian forms, large-celled nuclei or areas are more predominant than small-celled formations. In the phylogeny of the diencephalon, it could be inferred that nn. ventralis posterior, pretectalis, tractus opticus, reticularis, mamillaris and the geniculate bodies have been once almost entirely composed of large cells, but on ascending the mammalian scale towards the Primates, more and more small cells come into prominence in these same nuclei. This may signify the increasing importance of the rôle of small-celled elements in specific and non-specific projections of special and general sensory impulses to the cerebral cortex. In Primates, small-celled elements have been observed to appear among the large cells in isolated places, but mostly ventral to the magnocellular portions of the abovementioned nuclei, or even in scattered clusters throughout the particular nucleus. As one ascends the primate scale, the ratio of small cells to large cells changes, until in higher forms, the parvocellular areas become larger than the magnocellular areas. To such an extent, this process has occurred that the large cells appear to have been confined to a smaller, circumscribed area which is often seen to lie dorsally and medially to the small-celled portion of such nuclei as nn. geniculatus medialis and ventralis posteromedialis. Other nuclei, belonging mostly to the posterior thalamic group, have undergone regressive changes; large cells are seen only in scattered small groups lying in a linear fashion between two regions, e.g., nn. limitans and tractus opticus lying between the posterior part of the thalamus and the midbrain. There are still other nuclei, which are found in reduced sizes lying among the phylogenetically younger structures, e.g., n. reticularis pars lateralis. But there are large cells that are bigger in all dimensions than those of the phylogenetically older nuclei, and these are found in nn. ventralis posterolateralis, mediodorsalis, pulvinaris inferior and geniculatus lateralis.

It is hoped that the present investigation on diencephalic structures that show changes in cellular proportions, e.g., ratio of small cells to large cells, will rectify this phylogenetic trend towards larger parvocellular and smaller magnocellular divisions.

In the last fifty years, there has been much research work done on the structure and functions of the diencephalon. Progress has already been made, largely by means of systematic comparative and experimental studies, and providing that not too much is expected in the way of exact structural correspondence, the comparative method will continue in the coming years to be one of the most effective tools of neurological investigations in achieving an understanding of the structure and function of the mammalian diencephalon.

2. HISTORICAL SURVEY OF COMPARATIVE STUDIES ON THE PRIMATE DIENCEPHALON

Descriptive accounts of scientific investigations, which have been carried out on the anatomy and physiology of the diencephalon from the time of Galen 129-199 A.D. up to the present time, have been done by Clarke and O'Malley (1968) and Meyer (1971). In addition, references can be made to summaries by Le Gros Clark (1929, 1932), Walker (1937), Fulton (1938), Dekaban (1953) and Simmons (1965) mainly on the human thalamus, and by Krieg (1932), Fulton (1940) and Bauchot (1959, 1963) on the hypothalamus Therefore, a short historical survey will be attempted here only on comparative studies of the primate diencephalon.

Stein (1834) was quoted by Fulton (1938) as probably the first neuro-anatomist to have conducted a comparative survey of the mammalian thalamus. Stein concluded that in higher mammals, particularly primates, the optic nerves originated from the thalami, the fibres from which connected the entire cortex with the primary visual centre in the superior colliculus. However, Stein did not suggest that the thalamus subserved sensory functions.

During the 1830's, a revolution took place in the development of neurohistology which led to the invention of staining techniques for demonstrating nerve cells and myelin sheaths of nerve fibres - among those workers are Ehrenberg (1836), Valentin (1836) Remak (1838), Purkinje (1838), Schwann (1839), Helmholtz (1842) and Kolliker (1842). However, a considerable number of years had to elapse before methods of hardening, embedding, sectioning and staining nervous tissues were greatly improved. Waller's (1850) demonstration of secondary degeneration, Flechsig's myelogenetic method, fully developed in 1878, and the experimental methods of Gudden in determining the retrograde (or secondary) degeneration which ensued during the survival periods after selective ablations, were important milestones in the growth of neurohistological techniques. These lent a great impetus to the introduction of specific staining procedures by Marchi (1886) and Weigert (1882) for myelin sheath degeneration (myelo-architectonic techniques), by Nissl (1885, 1894) for nerve cell changes (cytological and cyto-architectonic techniques); and by Weigert (1895), Golgi (1873) and Cajal (1900) for neuroglia: Kolliker (1896), Cajal (1904), Bielschowsky (1919) and C. and O. Vogt (1920) among themselves developed techniques for finer histological features of the neurone and its cellular and fibrous composition.

These staining techniques helped to open an immense vista of microscopical investigations on the diencephalon, and led to an extensive study of its phylogeny, particularly in primates. Today, neurohistology is of primary importance in all comparative studies, whereby different diencephalic nuclei and definition of their relationship with one another and other structures of the brain can be localized with certainty and efficiency.

Meynert, Forel, Ganser and Edinger, by carrying out experimental investigations on thalamocortical connections during the latter part of the 19th century, initiated the era of comparative studies of the central nervous system. But they did not describe fully the structural changes in thalamic nuclei related to increasing functional importance of visual, auditory and somaesthetic sensory senses during the phylogeny of the primate brain. However, during the first three decades of the 20th century, there was intensive research work on the diencephalon in a wide range of vertebrates.

The principal studies of the submammalian and mammalian thalamus up to 1925 were the works on rodents, lagomorphs and carnivores by Munzer and Wiener (1902), Bianchi (1909), Cajal (1904, 1911), Neiding (1911), Winkler and Potter (1911, 1914), d'Hollander (1913) and Nissl (1913). Concerning the lower vertebrates such as fishes, amphibians, reptiles and birds, the Herrick brothers, Ariens Kappers, Huber, Crosby, Woodburne and Brouwer made major contributions to the present knowledge of the phylogeny of the diencephalon in these non-mammalian species. Since this thesis is primarily concerned with primates, particularly the prosimians, no further historical accounts will be attempted on these subprimate forms.

Forel (1907) wrote a short paper discussing the major differences in the structure of the diencephalon among several mammals, including primates. Suchs (1909), the Vogts (1909) and Friedemann (1912) gave the first complete topographical description of the primate thalamus; they used the Weigert and Marchi techniques. Malone (1910, 1913) employed the Nissl technique but used the structure of the single cell as a criterion in dividing the thalamus into sensory and motor regions rather than into cytoarchitectonical areas. This was a deviation from the customary architectonic methods, but his results did not correspond well with those of other authors.

Ariens Kappers (1921) published a very detailed account on the phylogeny of the diencephalon. It was much later elaborated and published in three volumes in collaboration with Huber and Crosby in 1936. Mussen (1923) described the cytoarchitecture of the brainstem in the macaque that formed the basis of investigations by other workers in the following decade. Foix and Nicolesco (1925) illustrated their study of thalamic structure with cytoarchitectonic diagrams and photographs of myelin-stained sections, but they were so concerned with the clinicopathological side of the thalamic picture that they did not contribute much to the anatomical side of investigation. Papez (1929) gave a brief account of the thalamus in his textbook of comparative neurology. Le Gros Clark must be regarded as the best authority of his time on the primate diencephalon. He published several articles between 1925 and 1962, not only on the nervous system but also on the evolutionary development of the morphology of the body in relation to the phylogeny of the Primates. His works on the diencephalon of prosimian and simian species have contributed much to the present investigation of thalamic and hypothalamic structures in the Prosimii.

Crouch (1934), Grünthal (1934), Aronson and Papez (1934) and Walker (1937, 1938) made careful and excellent studies of the diencephalon of Macacus rhesus. However, their description caused much confusion in terminology because there were too many divisions within the thalamic mass. This was remedied by Walker in 1937, when he introduced a much simpler nomenclature of thalamic nuclei in his book "The Primate Thalamus". He not only gave cyto- and myelo-architectonic patterns of the thalamus, but also carried out experiments on afferent thalamic connections. He gave a short account on the thalamus of the chimpanzee, but did not compare it with the thalamus of the macaque.

Sheps (1945), Toncray and Krieg (1946) and Dekaban (1953) all concentrated their investigations on the thalamic nuclei of man, but with different methods and results. Sheps studied serial sections of two normal human thalami stained by the Nissl technique, but the annotations to his photomicrographs were not clear enough to permit identification of thalamic nuclei. Toncray and Krieg used slice reconstruction methods to illustrate the morphology of individual thalamic nuclei, but it is not easy to correlate their diagrams with the photomicrographs of the nuclei cut at the same level, and there were too many subdivisions of less important thalamic nuclei to bring out the exact borders of the major divisions of the thalamus. Krieg in 1948 applied those methods to the thalamus of Macaca mulatta, but the same problems were encountered. However, in the latter two cases, the extents of the nuclei were beautifully shown in a tridimensional-like manner, so that one could follow the divisions or merging of the nuclei in anteroposterior and mediolateral extensions.

Olszewski (1952) was probably the first to attempt a stereotactic atlas of the brain of the macaque, based on the Horsley-Clarke apparatus. The serial sections of the thalamus were clearly illustrated both topographically and cytologically; therefore, they were easy to correlate with those of other primates.

Hassler (1959) studied the anatomy of the human thalamus with emphasis on functions of different nuclei, but the terminology is overcomplicated and his recognition of minute, fragmented subdivisions of nuclei is too meticulous and tedious.

There had also been extensive research work carried out on the comparative anatomy and physiology of the hypothalamus during the years of 1938 and 1940. One study was done by Le Gros Clark who published a book that gave a very wide review of research work on the anatomical, embryological, physiological and clinicopathological aspects of the human hypothalamus. His own contributions to the phylogeny of the mammalian hypothalamus were tremendous, particularly that he presented a much clarified and simpler picture of the evolutionary changes in the hypothalamus. His terminology of hypothalamic nuclei was more direct and uncomplicated. However, he did not solve the riddle of the true identity of the lateral mamillary nucleus which is still confused with the intercalated mamillary nucleus or with n. interstitialis of the mamillary peduncle. Crosby and Woodburne (1940) gave a brilliant survey on the comparative anatomy of the hypothalamus while Ingram, in the same year, dealt exclusively with its nuclear organization and chief fibre connections in primates. Rioch et al (1940) drew up a precis on the terminology, and included a well-illustrated atlas of the mammalian hypothalamus. Almost 30 years later, another series of research work was done on the hypothalamus, not only of mammals, but also of other vertebrate classes (Crosby and Showers, 1969). There is also an excellent treatise on the ontogeny of the diencephalon by J.F. Christ (1969) in collaboration with Kuhlenbeck, and another one on the nuclear configuration and fibre connections by Nauta and Haymaker (1969).

During the last twelve years, much progress has been made in the study of the prosimian diencephalon, thanks to Feremutsch (1957 to 1963) and Bauchot (1959 to 1967). Heiner (1960) based his observations on the thalamus of the chimpanzee on the slice reconstruction method of Krieg, and made some changes in Krieg's nomenclature of the thalamus. Bauchot (1963) and Feremutsch (1963) made very important contributions to the elucidation of the evolution of the thalamus and hypothalamus in the Insectivore/Primate lineage. Bauchot used quantitative methods to measure the volume and cellular density of all diencephalic structures, which are quite outside the scope of this study, but they gave some useful indications of the phylogeny of these structures. Bauchot was able to show that the Tupaioidea were of a more advanced group than the Macroscelidoidea but they were classified beneath the Lemuroidea. He was particular in giving all the existing homologous terms for almost every diencephalic nucleus, as well as in evaluating the phylogenetic trends in the Insectivora and Prosimii. He collaborated with Spatz, Andy and Stephan during the 'sixties in analysing quantitatively all brain structures of both insectivore and primate groups; those authors were able to show a closer phyletic and taxonomic relationship of the insectivores to the primates than any other mammalian order. Feremutsch, on the contrary, concentrated on the qualitative features of the evolution of the primate thalamus and hypothalamus. With Simma, he wrote several articles on the diencephalon of the Anthropoidea (1953-1961) culminating in his brilliant edition of the thalamus in the Primatologia Series (1963).

Between 1963 and 1972, there was a dearth of relevant literature on the prosimian diencephalon, except for a detailed description of the hypothalamus and subthalamus of Perodicticus potto Bauchot (1966, 1967), and Kanagasuntheram et al's comprehensive articles on the diencephalon of certain lorisoids and of the Hylobatidae (1968, 1969). During the same period of time, there was a minor flood of stereotactic atlases of mammalian and primate brains. Among these stereotactic atlases is a book on the brain of Tupaia glis by Tigges and Shantha (1969) which was a boon to this study. An article dealing with fibre projections of dorsal column nuclei in the spinal cord to the brain-stem and thalamus in the tree-shrew by Schroeder and Jane (1971) lent some aid in sorting out the topographic positions of the ventral, lateral and posterior thalamic nuclei, but the hypothalamus, and the anterior and medial thalamic regions were not illustrated. A comprehensive list of works, which have been carried out exclusively on all primate species from the beginning of this century to the present day, will be given in the Appendix which follows the reference list of authors (Bibliography).

Physiological, immunological and pathological experiments on tree-shrews, galagos and certain lemuroids are now in vogue, while anatomical and histological investigations are taking a back seat. A new challenge is now developing, to expand the many facets of knowledge of neurology and other anatomical subjects so that a clearer picture of the evolutionary processes in Primates can be achieved.

3. OUTLINE OF RESEARCH WORK ON THE PRIMATE DIENCEPHALON

This research work is, therefore, an attempt to compare the diencephalon of lower primates with those of non-primate mammals, e.g. Insectivora, and of higher primates, e.g., monkey and man. It is designed also to study the comparative structure, and to infer the possible evolution of the diencephalon of the Prosimii with particular reference to increasing importance of visual, auditory and somaesthetic senses in Primates. Furthermore, connections are sought among the pulvinar, lateral and ventral thalamic nuclear groups, and geniculate bodies which may be associated with phylogenetic development of speech and language in man. In regard to the hypothalamus, an attempt is made to trace any possible connection between the two neurosecretory hypothalamic nuclei (nn. supraoptic and paraventricularis) in primates, as well as to ascertain their origin from the magnocellular elements in the preoptic region in lower vertebrates.

Other purposes of this study are:

(1) to observe structural changes in the lateral geniculate body in relation to visual function in primates;

(2) to provide some neuro-anatomical evidence which may throw some light upon the phyletic relationships of the Tupaioidea with the Primates.

(3) to propose a more readily acceptable nomenclature for thalamic and hypothalamic nuclei.

It is hoped that this thesis may contribute some help to students of neurosciences in the identification and comparison of diencephalic structures, and also to stimulate future work on a detailed atlas, and possibly a textbook, on the comparative structure of the primate diencephalon, and even on the anatomy of the primate nervous system. Such work would have to be based on much more extensive material and on further experimental evidence of thalamic and hypothalamic connections with parts of the brain which are not very well known or still controversial.

CHAPTER 2

MATERIAL AND METHODS

A. MATERIAL

1. PRIMATE CLASSIFICATION

There is still a question of what the best procedure is to classify the primates. There was previously a tendency among the early zoologists to place primates in a series of stages successively closer to man, the latest product of evolution. It was, however, discarded because many of the surviving primate groups have been kept apart for such long periods of time that distinctions between them became more emphatically sharp. For instance, the lemurs which were once regarded as rather primitive monkeys, are now placed in an infraorder of their own, sharing with other primates only 'the retention of certain primitive characters and an adaptation to arboreal life' (Wood Jones 1929). At present, there is no general agreement about the best means of classification. The one based on 'more natural or phyletic lines could be devised which would necessitate the postulation of a large number of distinct categories unless these were simplified by admitting speculations about the affinities of the lines (Young 1962).

Therefore, Le Gros Clark and Young advise the use of Simpson's classification of the Primates (1945), not because it is the only possible classification, but because it is based on recognized authority and a long practical experience of taxonomic methods. It has also the merit of comparative simplicity, and phylogenetic relationships can be inferred from the evidence at hand. Simpson's classification has been, up to the present time, provisionally accepted and recognized by other authoritive workers in the same field.

The Order Primates is divided into two great suborders - PROSIMII and ANTHROPOIDEA as follows:

- Order: PRIMATES
  - Suborder: PROSIMII
    - Infraorder: LEMURIFORMES
      - Superfamily: TUPAIOIDEA
        LEMUROIDEA
        DAUBENTONIOIDEA
    - Infraorder: LORISIFORMES
      - Superfamily: Lorisoidea
    - Infraorder: TARSIIFORMES
      - Superfamily: Tarsioidea
  - Suborder: ANTHROPOIDEA
    - Infraorder: PLATYRRHINI
      - Superfamily: Ceboidea
    - Infraorder: CATARRHINI
      - Superfamily: Cercopithecoidea
        Hominoidea

It can be seen from this nutshell of classification that the *PROSIMII* are composed of three different types of primates which are all primitive in the sense of retaining insectivoran characters, such as an elongated snout, laterally situated eyes and small brain. They are grouped here as three infraorders - *Lemuriformes* for the lemurs of Madagascar and their allied fossils; *Lorisiformes* for the rather similar animals outside Madagascar, but chiefly confined to Africa and South-East Asia, and *Tarsiiformes* for the living tarsiers of the Phillipines and their numerous extinct relatives.

he tree-shrews have been included for a long time with the lemuriformes y several authors, notably Le Gros Clark (1962) and Simons (1944), but his is not taxonomically correct, since they have no geographical connection with the lemurs, and they have their own distinct evolutionary characters. For this reason, the tree-shrews, which are widely spread over the southern parts of the Asian continent, should be classified as a separate infraorder - *Tupaiiformes*, hereby following the classification systems of Straus (1949) and of Fielder and Remane (1961). Modifications are made to the

TABLE 1: CLASSIFICATION OF PRIMATES AND TUPAIOIDEA

Order	Suborder	Infraorder	Superfamily	Family	Subfamily	Genus	Common Name
Primates	? Prosimii	Tupaiiformes	Tupaioidea	Tupaiidae	Tupaiinae	Tupaia Dendrogale Urogale Lyonogale Anathana	Common Tree Shrew Smooth Tailed Tree Shrew Philippine Tree Shrew Terrestrial Tree Shrew Madras Tree Shrew
					Ptilocercinae	Ptilocercus	Pen Tailed Tree Shrew
	Prosimii	Lemuriformes	Lemuroidea	Lemuridae	Lemurinae	Lemur Hapalemur Lepilemur	Common Lemur Gentle Lemur Sportive Lemur
					Cheirogaleinae	Cheirogaleus Microcebus	Mouse Lemur Dwarf Lemur
				Indridae		Indri Lichanotus Propithecus	Indris Avahi Sifaka
				Daubentoniidae		Daubentonia	Aye-Aye
		Lorisiformes	Lorisoidea	Lorisidae		Loris Nycticebus Arctocebus Perodicticus	Slender Loris Slow Loris Angwantibo Potto
				Galagidae		Galago	Bush Baby
		Tarsiiformes	Tarsioidea	Tarsiidae		Tarsius	Tarsier
	Anthropoidea	Platyrrhini	Ceboidea	Callithricidae		Callithrix Leontocebus	Plumed and Pygmy Marmosets Tamarin
				Cebidae	Callimiconinae	Callimico	Goeldi's Marmoset
					Aotinae	Aotes Callicebus	Douroucouli Titi
					Pithecinae	Pithecia Chiropotes Cacajao	Saki Saki Uakari
					Alouattinae	Alouatta	Howler
					Cebinae	Cebus Saimiri	Capuchin Squirrel Monkey
					Atelinae	Ateles Brachyteles Lagothrix	Spider Monkey Woolly Spider Monkey Woolly Monkey
Primates		Catarrhini	Cercopithecoidea	Cerropithecidae	Cercopithecinae	Macaca Cynopithecus Cercocebus Papio Theropithecus Cercopithecus Erythrocebus	Macaque Black Ape Mangabey Baboon Drill Gelada Guenon Patas Monkey
					Colobinae	Presbytis Pygathrix Rhinopithecus Simias Nasalis Colobus	Common Langur Douc Langur Snub Nosed Langur Pagi Island Langur Proboscis Monkey Guereza
			Hominoidea	Hylobatidae		Hylobates Symphalangus	Gibbon Siamang
				Pongidae		Pongo Pan Gorilla	Orangutan Chimpanzee Gorilla
				Hominidae		Homo	Man

classification system devised by Elwyn Simons (1964) to illustrate the suggested separation of the tree-shrews into their own infraorder in the suborder Prosimii (Table 1). In this table, species which are used in this study are underlined by solid black lines, and those which have been studied in the literature by broken lines. In the section dealing with the suborder Anthropoidea, the gibbon and siamang occupy an intermediate taxonomic position between the Cercopithecidae and Pongidae, because these primates are suggested by several workers, notably Le Gros Clark (1962), and Napier and Napier (1967) to have several morphological characters that distinguish them from both families. These genera are classified as the Hylobatidae. Previously, the Hylobatidae were grouped with Pongo (orang-utan) within the family Pongidae, because the gibbon and siamang share with the orang-utan several common anatomical features, even certain neuro-anatomical ones, such as the lateral geniculate nucleus.

Several species belonging to the Prosimii, and two species of the Anthropoidea have been obtained for this research. Only one non-primate mammalian species - Elephantulus myurus - belonging to the family Macroscelididae in the Order Insectivora is included in this study for purposes of comparison with the Tupaioidea and Prosimii. Other prosimian families such as the Daubentoniidae, Indridae and Tarsiidae will not be included, because the species belonging to these families have been unavailable for this study, although references will be made quite frequently to Tarsius which was studied by Le Gros Clark (1930). The Lorisoidea will be split into families Lorisidae and Galagidae for descriptive purposes, but wherever there are similar features in their diencephala, these families will be grouped together under their superfamily.

2. RESEARCH MATERIAL

The brains of a number of prosimian and anthropoid primates have been made available for this study; many of these brains, particularly those of the Galagidae and *Cercopithecus aethiops* and *Homo sapiens* were received in the fresh state, while others were already fixed for an indefinite period of time in formalin or alcohol fixatives, before being studied. In other cases, whole specimens were sent with brains still in the skulls (e.g., *Tupaia alis*). During those five years (1966-1971), this author encountered difficulties in obtaining material from research institutes and zoological gardens in Europe, the United States of America and even right here in South Africa. However, more material is badly needed to approach anything like a complete series of lower primates from *Tupaia* to *Tarsius*. Many prosimian species such as *Cheirogaleus*, *Indri*, *Daubentonia*, *Propithecus*, *Nycticebus*, *Ptilocercus*, *Urogale*, *Dendrogale*, *Avahi*, *Tarsius* are virtually impossible to obtain from their indigenous habitats where they are protected to avoid the danger of extinction.

The material which has been made available for this study, is listed systematically, even the species already studied by other workers (indirect references) as below:

1. MACROSCELIDIDAE - 2 specimens

Elephantulus myurus - the two specimens were donated by the Medical Ecology Unit, South African Institute for Medical Research towards my research work on the diencephalon. Both brains were histologically prepared.

This macroscelidoid species was studied by:

(i) Le Gros Clark in 1926
(ii) Allison in 1947
(iii) Bauchot in 1963.

2. TUPAIIDAE - 18 specimens

(a) Tupaia glis - eleven specimens all received from Kuala Lumpur, Malaysia. Five of these specimens were histologically prepared; two donated to the Anatomy Department and four retained for further study.

(b) Other Tupaia species - seven specimens all received from the University of Missouri, United States. Two of them are Tupaia minor, two Tupaia longipes, one Tupaia gracilis, and two Lyonogale (formerly Tupaia tana) - all histologically prepared.

(c) Tupaia species studied by other authors - two species

(i) Tupaia minor by Le Gros Clark (1929)
(ii) Tupaia glis by Bauchot (1963) and Feremutsch (1963)

3. LEMURIDAE - 12 specimens

(a) Microcebus murinus - five specimens sent from the National Museum of Natural History, Paris, France and from Madagascar. One was histologically unsuitable and discarded; two were prepared for microscopical study and two retained for future research work.

(b) Lepilemur - one specimen received from Madagascar via East Africa - prepared for microscopical study.

(c) Lemur species - three species (six specimens); four of them were donated by the Pretoria Zoo, and two came from Madagascar. Four Lemur catta - one histologically unsuitable, one retained for further study and two used for this study; one Lemur fulvus and one Lemur macaco both microscopically studied.

(d) Other Lemur species studied elsewhere - four species

(i) Lemur catta by Pines (1927)
(ii) Lemur macaco by Feremutsch (1963)
(iii) Lepilemur and Microcebus murinus by Feremutsch (1957, 1963)
(iv) Microcebus murinus by Le Gros Clark (1931)

4. INDRIIDAE - no specimen

Only Propithecus verrauxi has been studied by Feremutsch(1957, 1963)

5. DAUBENTONIIDAE - no specimen

This family, apart from Osman Hill (1953),has never been studied before.

6. LORISIDAE - 5 specimens (all obtained from East Africa)

(a) Arctocebus - one specimen, histologically unsuitable.

(b) Perodicticus potto - four specimens, one histologically unsuitable and other three prepared for microscopical study.

(c) Other species studied - Nycticebus coucang by Kanagasuntheram et al (1968)

- Loris tardigradus by Feremutsch (1957, 1963)

- Perodicticus potto by Bauchot (1967)

7. GALAGIDAE - 14 specimens

(a) Galago demidovii - obtained from East Africa. Three specimens - all microscopically prepared.

(b) Galago senegalensis - eight specimens, obtained from the Department of Psychology, Witwatersrand University. Six of them were prepared for microscopical study and two retained for future study.

(c) Galago crassicaudatus - three specimens, two of which were donated by the Psychology Department, Witwatersrand University, and one which was histologically unsuitable, came from Malawi.

(d) Other species studied elsewhere - two species

(i) Galago demidovii by Bauchot (1963).
(ii) Galago senegalensis by Kanagasuntheram et al (1968).

8. TARSIIDAE - no specimen

Only *Tarsius* has been studied by Le Gros Clark (1930).

Cercopithecus aethiops

9. CERCOPITHECIDAE -/11 specimens, all of which had been used for the M.Sc. thesis in 1965. Five of those specimens were obtained from the Department of Anatomy, Witwatersrand University, and the other six from the Poliomyelitis Research Institute, Rietfontein, Transvaal. All those brains were histologically prepared. Two of them were used in this study for comparative purposes.

10. HOMINIDAE

Homo sapiens - five brains which had been previously perfused and fixed in 10% formol saline, were generously donated by Dr. R. van Hoogstraten who was then an anatomy assistant in the Department of Anatomy, University of the Witwatersrand Medical School, in 1966 for research work on the human nervous system.

B. METHODS

1. PERFUSION METHOD

The Galagidae were the only prosimians that were live specimens obtained for this study. Their brains had to be perfused and fixed *in situ* before they could be removed from the skulls. Those animals were first killed with chloroform and the perfusion method was carried out immediately.

The perfusion method differs according to the size of the animal. If the animal is small, e.g., *Galago senegalensis*, the perfusion is performed through the heart, and if the animal is large, e.g., Galago crassicaudatus, the internal carotid artery is used. The cardiac method is preferable, because it is not only the easier route for the perfusing fluid, but also the chance of fixing the brain in situ is definitely better. A cannula is inserted into the left ventricle and normal saline is allowed to flow from an upturned sterile bottle which is suspended above the operating table. The brain is perfused for five or ten minutes, and in the meantime, the jugular vein of either side is severed to allow the normal saline to escape, until the fluid shows no signs of being red-stained, i.e., the brain is cleared of all blood. Then the perfusing fluid is changed to 5% formol saline by removing the tube from the normal saline bottle, and inserting it into the bottle which contains 5% formol saline. Then the latter fluid is released into the body, and left running until the limbs show signs of rigidity. Then the brain is properly fixed in situ.

The cranium, especially of large animals, is sawn in a horizontal plane just above the supra-orbital ridges and the occipital protuberance. The vault is carefully removed with a minimum of damage to the underlying meninges and brain tissue. Then the dura mater which is attached to the brain, is cut open, along the superior sagittal sinus and around the brain above the sawn edge of the cranium, with a pair of sharp scissors. Then the brain is slowly elevated from the front, and the underlying attachments (nerves, strands of arachnoid and pia mater, bloodvessels, etc.) are snipped. This allows the brain to fall backwards to expose the foramen magnum. The hind-brain is the most difficult part to release from its bony and membranous vault; therefore, the first few cervical vertebrae are prised open to expose the lower part of the medulla oblongata, and the upper part of the spinal cord. At this level, the brain is disconnected by transection from the spinal cord. The brain is now freed from the remaining strands of dura mater, and is then placed immediately into a jar containing 10% formol saline.

With small specimens, it is necessary to use fine-pointed scissors and cut the cranium along the same plane as mentioned above, otherwise, it has to be chipped off bit by bit, so as not to damage the soft brain beneath.

3. FIXATION AND PRESERVATION METHODS

Since the methods of fixation and preservation of brains varied greatly among the prosimian species, they will be described under each family.

(a) Tupaiidae

In December 1966/January 1967, the first three Tupaia glis specimens (Tu 1, 2 and 3) were received by air freight from the United States Army Research Institute in Kuala Lumpur, Malaysia. Those animals had been anaesthetised with chloroform and their brains were immediately fixed by means of the perfusion method. The brains were then removed and placed in cold 10% formalin for a few hours, and then this fluid was changed and left for a few days. They were wrapped in cotton-wool soaked in 10% formalin and placed in separate, sealed plastic bags which were disposed in a refrigerator at 5°C, until shipment to South Africa. The brains were received in an excellent condition but upon closer examination, it was discovered that there were horizontal and transverse sections or "cracks" running through the base of the brain (Tu 2 and 3), thus ruining the regions essential for the study of the diencephalon. However, they were not too badly damaged for histological work, and the sections were excellent in spite of horizontal creases in the region of the hypothalamus. Those sections were used for preliminary studies until a further supply could be obtained from Kuala Lumpur. Eventually in May 1967, four whole specimens (all Tupaia glis - Tu 4, 5, 6 and 7) arrived in a good condition, each specimen in its own plastic container which was filled with 10% formalin. The skulls were not opened, but one of them was detached from the body. All the brains were, nevertheless, well preserved. Two of all these specimens (Tu 1 and Tu 7) were donated to the Anatomy Department of the Witwatersrand University for research purposes. In November 1971, four whole Tupaia glis specimens - body and head together, and brains neither removed nor exposed to the fixative - were received from Kuala Lumpur but they are reserved for future work on the anatomy of the tree-shrew. Seven specimens belonging to four different tupaiid species (Tupaia minor, Tupaia gracilis, Tupaia longipes and Lyonogale) - Tu 8 to 14 - were sent from the University of Missouri, U.S.A. in April 1970. These species - heads only - were received in an excellent condition, and the brains were removed with as little damage as possible in order to preserve the skulls for teaching and demonstrative purposes.

(b) Lemuridae

The first species belonging to the Lemuridae received for this study was Microcebus murinus - two specimens of undetermined sex (Mi 1 and Mi 2). They were kindly donated to this research work by Dr. J.J. Petter of the National Museum of Natural History in Paris, France. One of them (Mi 1) was fixed in formalin, and the other (Mi 2) in alcohol for a very long time. Mi 1 showed some necrosis on the base of its brain, signifying poor penetration of the fluid, and the medulla was torn completely from the rest of the brain. That brain was re-fixed in 10% buffered formalin (acid monohydrate sodium phosphate ($Na_2H_2PO_4.H_2O$) and anhydrous disodium phosphate (Na_2HPO_4) were added to the fixative) in order to induce better penetration into the tissues as well as to neutralize the corrosive effect of the old formalin fluid. On sectioning and staining that brain, it was found that only the anterior part of the diencephalon, particularly in the region of the preoptic and supraoptic areas, was damaged, but not seriously enough to preclude microscopical examination. Mi 2 which was alcohol-fixed, was placed also in the buffered formalin solution, but did not yield any satisfactory results; the sections did not stain well, due to possible post-mortem autolysis in its cells. In April 1970, a third Microcebus murinus brain (Mi 3) was received from Madagascar, including a whole deviscerated specimen (the thoracic and abdominal viscera had already been removed before the specimen was sent to South Africa). That brain was well preserved and adequately processed, but during embedding, it might have leaned towards one side, and on its superior surface, so that a deep oblique plane resulted during sectioning of the block. As it was not very suitable for topographical localization of the diencephalic structures, it was retained for cytological studies. The lemur specimens were obtained not only from the Pretoria Zoological Gardens, but also from Madagascar and through contacts in East Africa. In 1969, the Pretoria Zoological Gardens donated two lemurid species, one Lemur catta (Le 1) and the other, Lemur fulvus (Le 3). Those animals had been dead only for a few hours, and placed in a refrigerator prior to their collection. The brains were not perfused, and had to be removed immediately from the skulls and placed in 10% formol saline for two weeks. Another Lemur catta specimen (Le 2) was received, at the same time as those two specimens, from Dr. Walker in Uganda, East Africa. It was found to be in such an excellent condition, both microscopically and macroscopically, that it was selected to be the pilot brain of the whole study, and all the brains were compared with, and qualititatively evaluated against it. Some weeks later, two more brains belonging to Lemur macaco (Le 4) and Lemur catta (Le 5) were sent to South Africa from the Zoological Institute in Tanarive , Madagascar. These brains were received with their skulls, the tops of which were removed for fluid permeation. In November 1970, Dr. Rumpler, on his short visit to the South African Institute for Medical Research, brought some live Lemur catta specimens for research purposes there, and also another Lemur catta brain for this study. This brain (Le 6) has not been used for microscopical study, but is kept for further research work.

In 1971, a *Lepilemur* brain (Le7) was received from Dr. Walker and in spite of the advanced stage of histological work on other lemurid species, it was immediately prepared for comparative work.

(c) *Lorisidae*

The lorisid specimens - one Arctocebus and four *Perodicticus potto* - were received in 1968 from Dr. Walker in East Africa. The *Arctocebus* brain was found not to be in a satisfactory state, because a large piece of brain tissue was missing from the left frontotemporal region; most of the brainstem was cut away, and the cerebellum was nicked badly in some places. Owing to overfixation or an accident in the laboratory, this one and only Arctocebus specimen was ruined beyond salvation even for the crudest anatomical examination. But in compensation for that irrecoverable loss, the four *Perodicticus potto* specimens gave satisfactory results, both macroscopically and microscopically. Two of them (Po 1 and Po 2) were used for transverse sections; Po 4 for sagittal sections and Po 4 for horizontal sections. However, upon microscopical examination, three of them (Po 1, 2 and 3) were quite heavily infested with a parasite, which was diagnosed by Drs. J.C.E. Kaufmann and I.Fripp of the South African Institute for Medical Research as a nematode worm. But this parasite did not penetrate far enough to affect the diencephalon, and there is only a very slight histological distortion in the anterior part of the diencephalon (preoptic region), particularly in Po 2. As these brains were well perfused prior to their shipment to South Africa, the sections stained beautifully with all the staining techniques and gave good photographic results.

(d) *Galagidae*

The Galagidae were the first species to be used at the beginning of this work on the prosimian diencephalon. In 1966, six *Galago senegalensis* (Ga 1 to 6) specimens were donated by the Department of Psychology, Witwatersrand University. All those brains were in an excellent condition after being perfused with 5% formalin and immersed in 10% formol saline for seven to ten days. Two *Galago crassicaudatus* (Gc 1 and Gc 2) specimens were received from the same source as the other *Galago* specimens in 1967. The perfusion method (see supravide) was performed on them through the heart. Since a third brain was needed for either horizontal or sagittal sections, it was obtained from Malawi in 1969. Unfortunately, it was ruined by a huge subdural haemorrhage on the left side, and upon close examination, an air pellet was discovered to be deeply embedded in the cerebral hemisphere. That haemorrhage extended even to the diencephalon, and caused so much histological distortion that the brain (Gc 3) had to be discarded as unsuitable for any research work. In 1970, two more *Galago senegalensis* specimens were received from the same department. One of them (Ga 7) had a cataract in his right eye, and the other specimen (Ga 8) was blind in both eyes. These specimens are, however, retained for future investigations on the visual system affected by the cataracts and other forms of induced blindness.

The first *Galago demidovii* brain (Gd 1) was sent from Uganda in 1967. It was found to be poorly preserved, and most of the hind-brain including the cerebellum was badly nicked, but the forebrain was comparatively free of damage. However, after sectioning and staining, a preliminary microscopical examination revealed a "worm-eaten" or "furrowed" appearance, and that specimen had to be abandoned as useless for research work. The other two *Galago demidovii* specimens (Gd 2 and 3) were sent by Dr. Walker to South Africa in 1969, together with the other prosimian specimens. The *Galago demidovii* specimens were received in an excellent condition, and gave satisfactory histological results; Gd 2 for the thalamus and epithalamus, and Gd 3 for the subthalamus and hypothalamus.

4. PROCESSING AND SECTIONING TECHNIQUES

The brains are placed first in 30% alcohol for 12 hours, and then transferred to 50% alcohol for 12 hours. Thereafter, the brains are passed through a graded series of alcohol as follows:

(a) Two changes of 70% alcohol, each change for six hours,

(b) Two changes of 95% alcohol or rectified spirits, each change every six to twelve hours,

(c) Three changes of absolute alcohol, each change every twelve hours.

Then the brains are cleared in chloroform, two changes made each in three to six hours.

In prior to embedding, the brains are placed in molten paraffin wax, and left in the 56-60°C for four to six hours.

The wax is changed every three or four hours, but if the brains, belonging to large prosimian and anthropoid specimens, take a longer time for a thorough impregnation, they can be left overnight in the embedding wax jars.

Then embedding is done in stainless steel boxes, the size and depth of which depend on the size of the brain. Each brain is placed with its rostral end (olfactory bulbs or frontal poles of the cerebral hemispheres) pointing towards the base of the box, and with the ventral surface of the brain as near as possible to the side of the embedding box, to prevent it from toppling over. When the brain blocks have been hardened sufficiently by immersion in cold water, the wax is trimmed away as much as possible to obtain the maximum area of section of the brain for mounting on glass slides measuring 7,5 x 2,5 cms.

The majority of prosimian brains were sectioned in the coronal plane. In addition, one set of horizontal and one of sagittal sections were obtained from each of two Tupaia glis, one Galago senegalensis and one Perodicticus potto specimens. One Lemur catta brain was divided into two halves, which were sectioned horizontally and sagittally respectively. All brains were cut at 10 to 15 micra. In regard to small brains belonging to the Tupaia species, Microcebus murinus, Galago demidovii and Elephantulus myurus, every section was preserved and mounted on glass slides. Of brains belonging to large prosimian specimens, six in every ten sections were mounted and the remaining four sections were stored.

One set of mounted brain sections from each of the prosimian specimens was stained with the Cresyl-echt violet method for cytoarchitectonic and cytological studies; another two sets with the Luxol fast blue method (Klüver and Barrera 1953) and with the lithium carbonate-haematoxylin method (Simmons 1968) for myeloarchitectonics, fibre patterns and topographical relations of the diencephalon with the adjoining telencephalic and mesencephalic structures. The other two or three sets of mounted sections were stored for future use.

The brains of two Elephantulus myurus specimens were immediately removed upon their receipt, and fixed in 10% formol saline for 10 days, then processed and embedded in paraffin wax. One of those brains, Mc 1, was sectioned in the transverse plane, and the other one, Mc 2, in the horizontal plane. Every section from both brains was preserved and mounted. One set of sections was used for cytoarchitectonics, and the other set for myeloarchitectonics.

Two Cercopithecus aethiops brains, labelled in my M.Sc. thesis as Th VIII and M I, were relabelled Ce 8 and Ce 10.

respectively. Both brains had been sectioned in the transverse plane, and were stained for both cyto- and myelo-architectural studies.

In regard to the human brains, two of them, Hu 1 and Hu 3, were sectioned in the transverse plane, while Hu 2 was sectioned in the horizontal plane: Hu 4 in the sagittal plane, and Hu 5 was used only for sagittal sections of the hypothalamus. All of those brains were stained for cyto- and myeloarchitectonics.

5. STAINING TECHNIQUES

The staining techniques, except for this author's own technique (1968), are similar to those which are generally used in routine laboratory work, although modifications have been made in these techniques to suit the particular requirements for microscopical work in this study. These techniques are given in detail as follows:

(1) Staining technique for cyto-architectonic and cytological details

Cytological stains concerned with special inclusions in the cytoplasm of neurones such as Nissl granules are cresyl-echt violet, toluidine blue, methylene blue, thionine and gallocyanin. The cresyl-echt violet gives not only a metachromatic contrast in the cell-body, but also shows a greater degree of affinity for the chromophile substance of the neurone than do the other dyes. It has, therefore, been selected to demonstrate the cyto-architectonical pattern of diencephalic nuclei, as well as to show up the cytoplasmic details of cells in individual thalamic and hypothalamic nuclei.

The cresyl-echt violet was based on a modification of the Vogt method (1957). The concentration of the staining solution was reduced from 1,00 as recommended by Vogt to 0,25 gram per 100 ccs. distilled water, because the dye obtained from Messrs. Coleman and Bell, (U.S.A.), produced so intense a staining reaction that it could not bring out the desired differentiation of the Nissl granules. In the techniques of Vogt (1960) and Klüver and Barrera (1953), sodium acetate was not included in the formula, since cresyl-echt violet was used only as a counterstain and was not substituted by any other substance. However, 0,25 grams. sodium acetate was added to the 0,25% cresyl echt violet solution for cytological purposes in this study, and the solution was adjusted to a pH of 3,0 - 4,0 every time before use. As a mounting medium, neutral Canada balsam was preferred to DePeX, because it prevented the sections from fading too quickly. The result of this modified staining technique proved gratifying, for the Nissl substance appeared royal purple, the cell nuclei deeper purple and the background almost colourless (a slight bluish tint). (Fig.1)

Modified Cresyl-Echt Violet Method

Fixation and Embedding - 10% formal saline preferably. Paraffin wax sections at 10-15 micra. If celloidin sections are used, they should be cut at 20-30 micra.

Staining procedure

(a) Bring the sections down to distilled water, through graded alcohols.

(b) Stain with 0,25 cresyl-echt violet solution for 5-10 minutes at room temperature.

(c) Rinse in two changes of distilled water to get rid of excess stain.

(d) Differentiate in 95% alcohol, to which 1-2 drops of concentrated glacial acetic acid is added, until the sections appear pinkish-violet (examine microscopically to see if the cells stand out distinctly in a colourless background - the Nissl granules should be of a deeper shade than the cytoplasm of the neurone).

(e) Rinse in one change of 95% alcohol followed by two changes of 100% alcohol.

(f) Rinse in xylol for 1 minute.
(g) Leave in the balsam-xylol mixture for two minutes.
(h) Absolute alcohol - two changes.
(i) Clear in xylene - two changes.
(j) Mount in Canada balsam.

(2) Staining Techniques for topography and myeloarchitectonics

Two staining techniques - the Klüver and Barrera (1953) and Simmons (1968) techniques - were employed for myeloarchitectonic studies and for photography. Ideally, the myelin fibre patterns stand out distinctively against a pale, colourless background. When cellular relationships to the myelin patterns are to be studied, counterstains such as cresyl echt violet and neutral red are used to provide a brilliant contrast between cells and fibres. (see Figs. 2, 3, & 4.)

(i) The modified Klüver and Barrera technique

This method has proved by far the most successful, and has, therefore, been used in this study for illustrating the topography and architectonics of the primate diencephalon. This technique is a combination of Luxol Fast Blue MBS and cresyl-echt violet dyes which stain the myelin sheaths and Nissl granules in the cell-bodies simultaneously. The Luxol Fast Blue MBS was introduced by Klüver and Barrera in 1953, and in many laboratories, has now almost superseded the haematoxylin-lake stains of Weigert, Weil and Loyez. This stain has the advantage of allowing combinations, not only with cresyl echt violet, but also with PAS, PTAH, Oil Red O and Neutral red methods.

In order to achieve optimal staining efficiency, modifications were made in the Klüver and Barrera technique. The concentrations of the Luxol Fast Blue MBS and of the cresyl echt violet solutions were increased from 0,1 to 0,2 gram per 100 ccs, of solute. This was found to be more effective with sections which were cut at 10 micra and over. In the Klüver and Barrera method, the sections were differentiated in several changes of 95% alcohol after being counterstained with 0,1% cresyl echt violet. The sections appeared to be insufficiently decoloured, and the Nissl substance could not be distinguished clearly from the cytoplasm and nucleus. In the first of the two changes of 95% alcohol, 2-3 drops of concentrated glacial acetic acid were added, so that the differentiating process would be hastened without fear of having the Luxol Fast Blue removed, since the latter dye is bounded by the Cresyl echt violet. Differentiation was allowed to proceed until the cresyl echt violet coloured the cytoplasm slightly blue and the Nissl substance purplish-blue. The modified counterstaining enhanced the metachromatic appearance of the Nissl substance, which stood out so distinctly that cytological comparison of cells of various diencephalic nuclei was facilitated.

This modified technique is given below:

Fixation and Embedding - same as for the cresyl echt violet method.

Staining procedure

(a) Deparaffinize in benzol, then hydrate through two changes of absolute alcohol followed by three changes of 95% alcohol.

(b) Stain overnight (16-48 hours) in Luxol Fast Blue solution in a 56-60°C incubator, using sealed Coplin jars or large staining dishes.

(c) Wash in two changes of 95% alcohol followed by a rinse in distilled water to remove excess stain.

(d) Differentiate in 0,05% lithium carbonate until the grey and white matters are just discernible.

(e) Wash in distilled water.

(f) Continue differentiation in 70% alcohol until the distinction between grey and white matters is clear. Differentiation proceeds fast within one minute. The grey matter should be almost colourless and contrast sharply with the white matter, which assumes a shade between blue and aquamarine.

(g) Should the grey matter possess a bluish tint after differentiation in 70% alcohol, then the sections should be washed briefly in distilled water and dipped quickly in the lithium carbonate solution diluted by 1 in 5.

(h) Wash well in distilled water.

(i) Place in warmed cresyl echt violet solution for about 30 minutes or stain in a 56-60°C incubator for 1-2 hours.

(j) Wash in two changes of distilled water to remove excess stain.

(k) Differentiate in two changes of 95% alcohol, into the first of which 3-4 drops of concentrated acetic acid per 100 ccs. of alcohol are placed. The purpose of the glacial acetic acid is merely to hasten the differentiation process. Allow the differentiation of cresyl echt violet staining to proceed until it colours only the cytoplasm of neurones and the Nissl granules stand out distinctly.

(l) Rinse in two changes of absolute alcohol and xylol.

(m) Place in the balsam-xylene mixture for two minutes.

(n) Rinse and clear in two changes of xylol.

(o) Mount in neutral Canada balsam.

In case of celloidin sections, according to Klüver and Barrera, these sections are transferred to 75% alcohol, and follow the procedure as outlined in Steps (b) to (o), except that the sections can be left in the cresyl echt violet solution indefinitely.

Solutions

(1) Luxol Fast Blue MBS

Luxol Fast Blue	0,2 gm.
95% Ethyl alcohol	100 cc.

Dissolve the dye in ethyl alcohol, filter and add 3,0 cc. of 10% glacial acetic acid to every 500 cc. of solution, which will remain stable indefinitely.

EXPLANATION OF FIGURES

Figure 1

Photomicrograph of a thalamic neurone to illustrate the cresyl-echt violet staining technique for cytology and cytoarchitectonics

x400

Figure 2

Photomicrograph of a thalamic neurone and myelinated fibres to illustrate the Klüver and Barrera staining technique for myelin sheaths and myelo-architecture.

x400

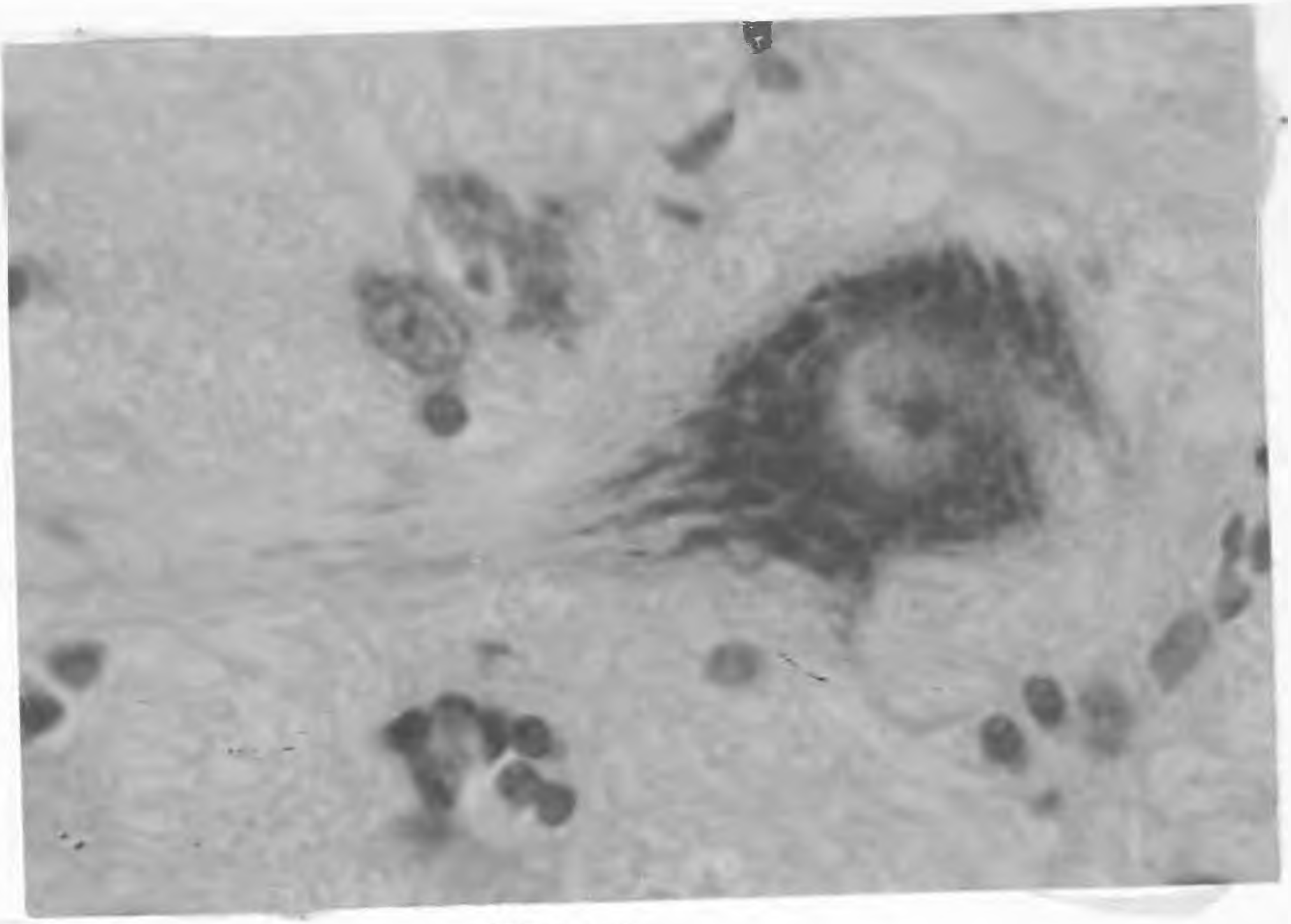

Figure 1.

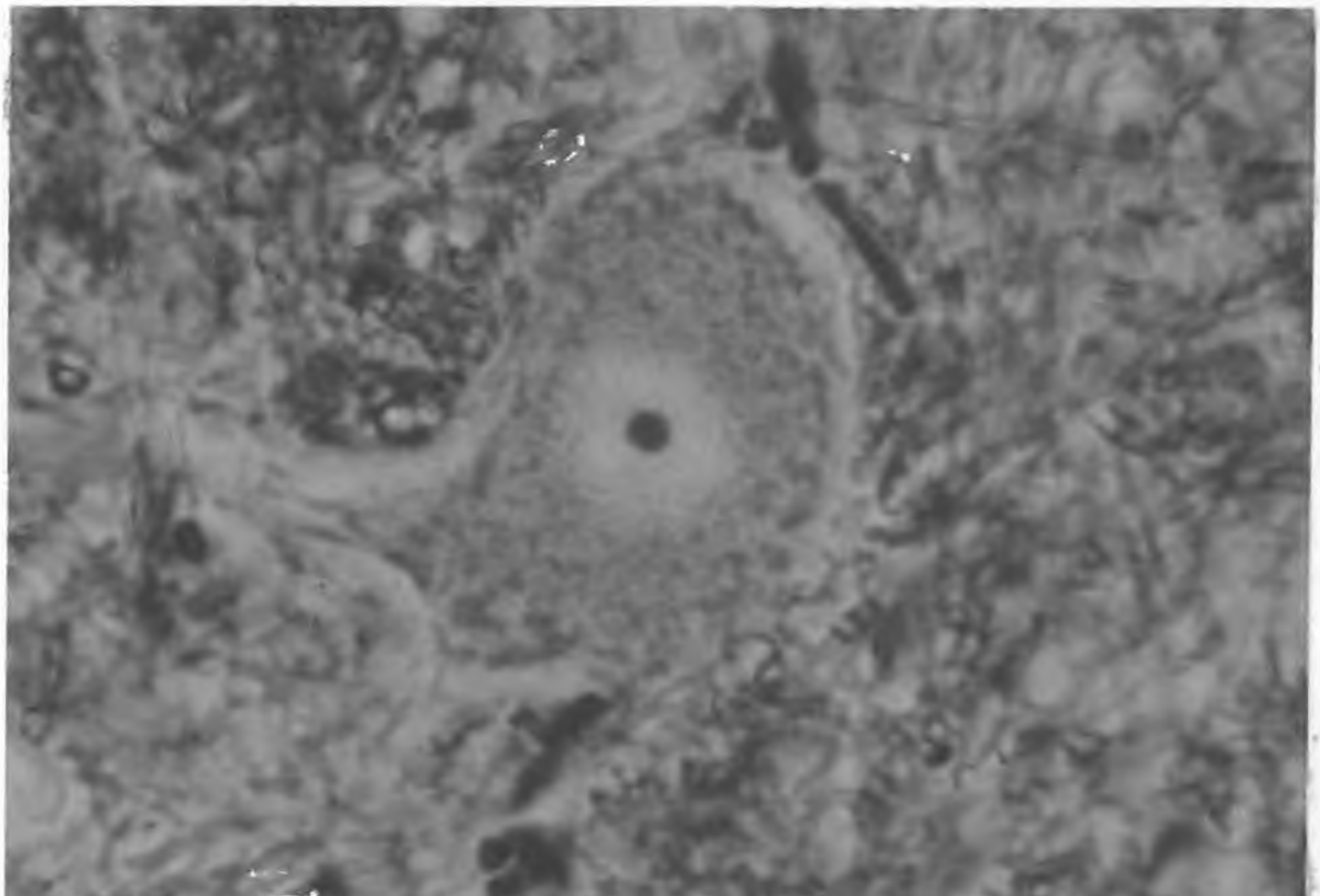

Figure 2.

Figure 1.

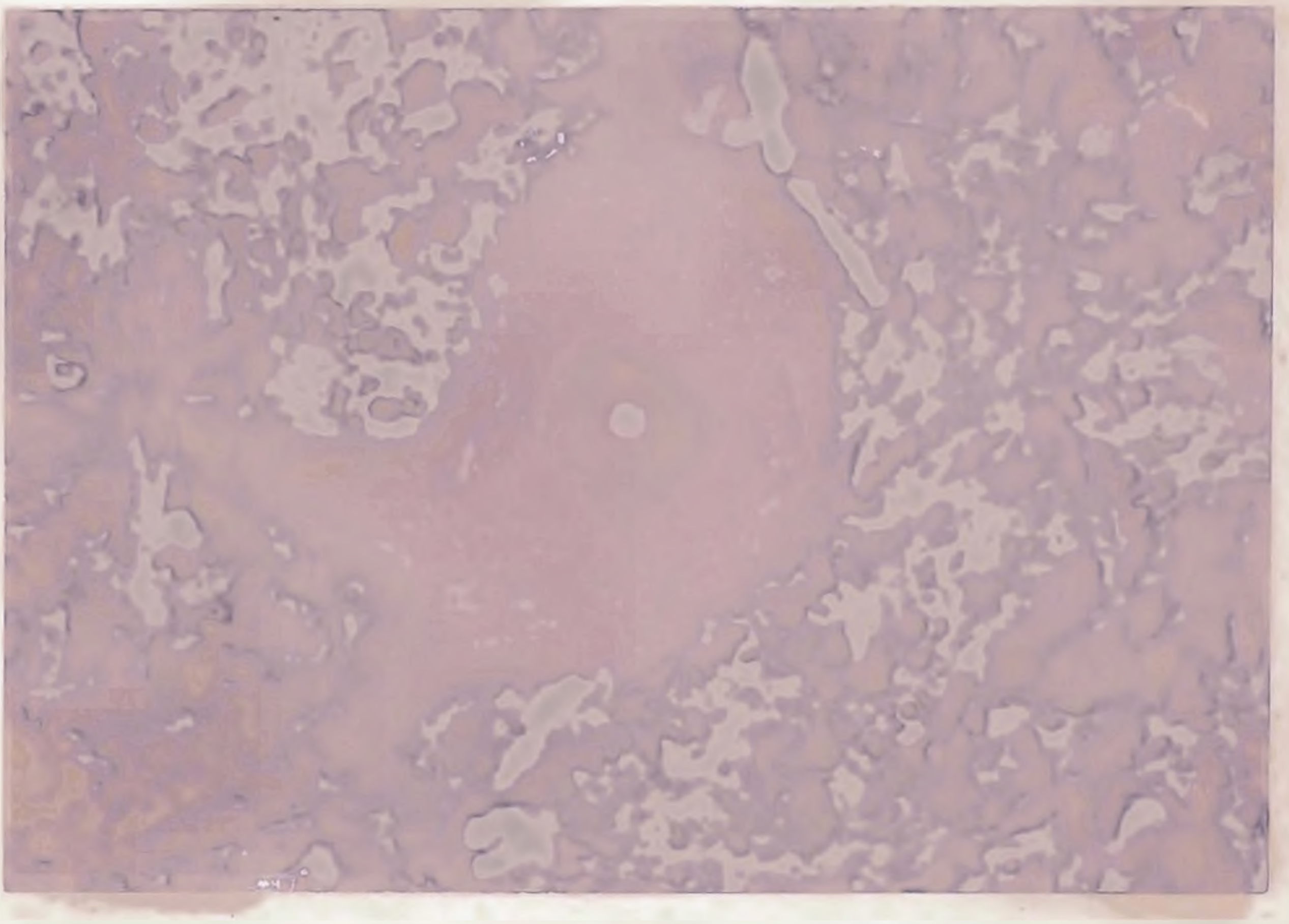

Figure 2.

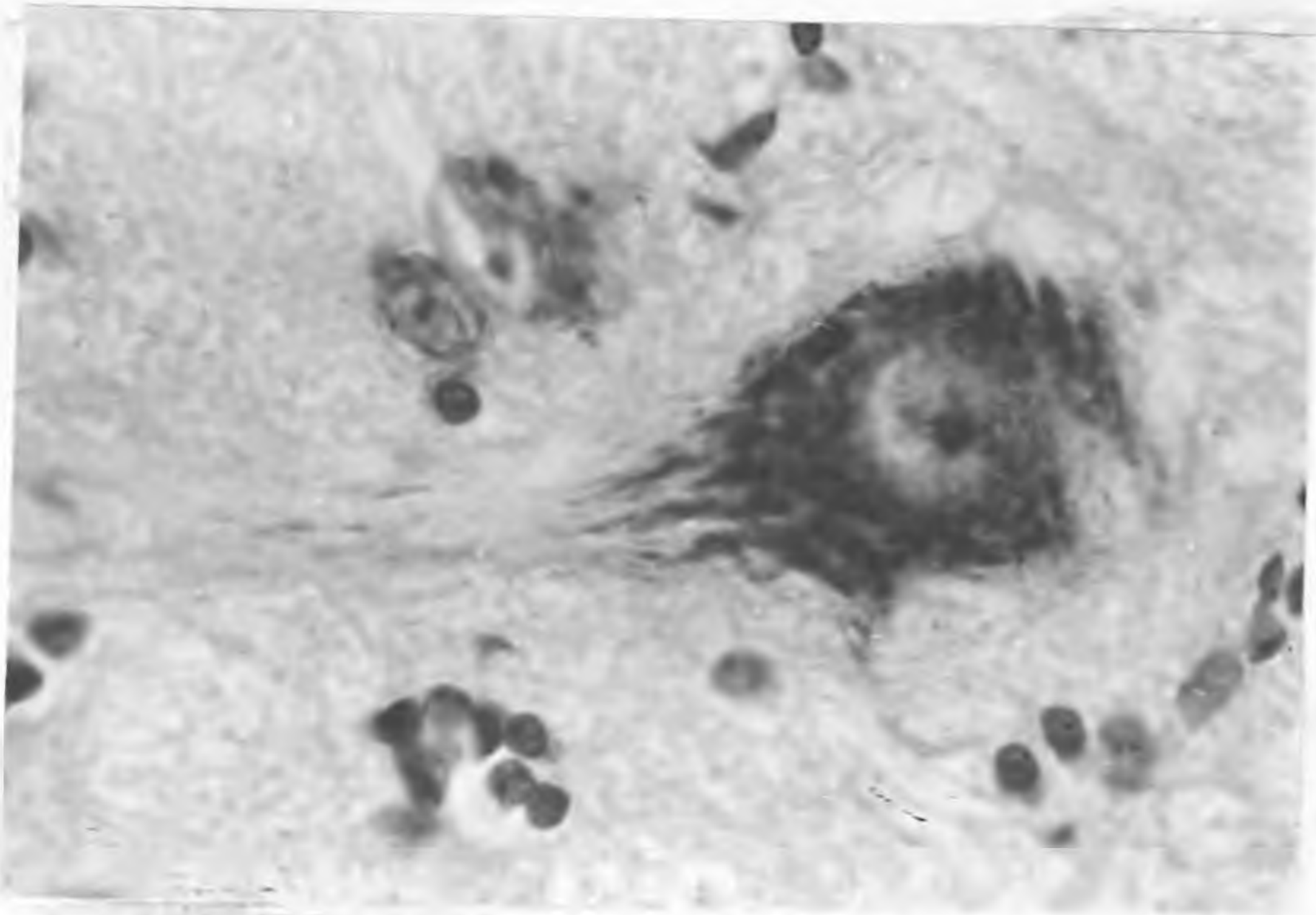

Figure 1.

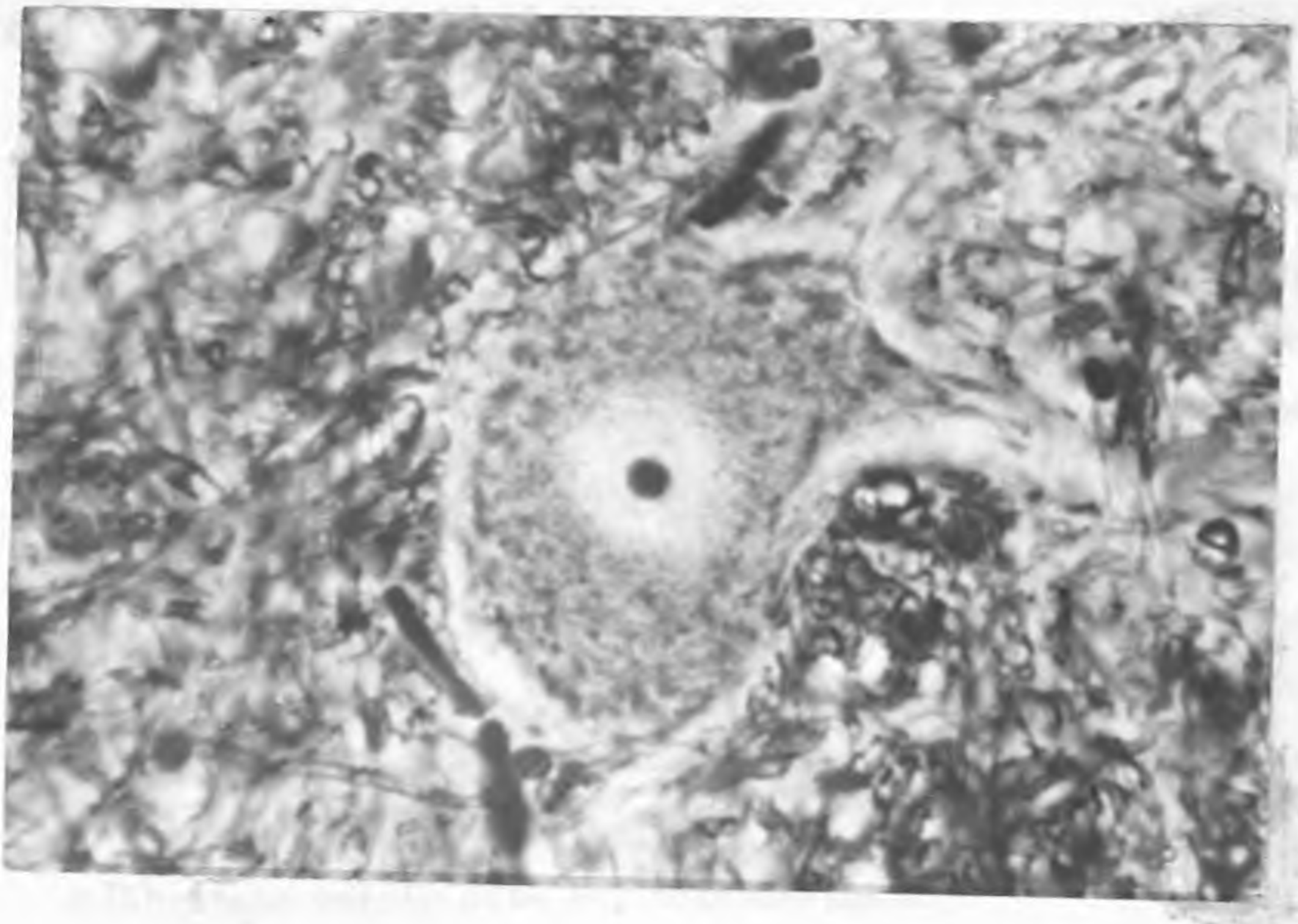

Figure 2.

(2) Lithium Carbonate

Lithium carbonate	0,25 gm.
Distilled water	500 ccs.

(3) Cresyl echt violet

Cresyl echt violet	0,2 gm.
Distilled water	100 ccs.

Dissolve the dye thoroughly in distilled water, and add 1,0 cc. of 10% glacial acetic acid to every 50 ccs. of solution. Filter if necessary.

Results

Myelin sheaths stain from midnight blue to deep aquamarine, while neurones contain pinkish-violet Nissl granules against a background of a much more lightly stained cytoplasm. (Fig.2)

(ii) Simmons's technique

This technique is a modification of the Woelcke-Weil technique for myelin in paraffin wax and freeze-drying sections. It is based also on other myelin-staining methods, e.g., the Loyez and Weigert-Pal techniques (Anderson 1929, Russel 1939, Gasser 1961), but lithium carbonate is substituted for iron haematoxylin in making up the working haematoxylin solution for staining myelin sheaths. Because this method leaves the grey matter partially colourless, either cresyl echt violet or neutral red can be used as a counterstain, not only to bring out cellular details, but also for a better and sharper colour contrast between myelin sheaths and nerve cells. It offers a rapid staining procedure for neuropathological examination, and is very useful in staining serial sections for neuro-anatomical studies. Furthermore, this technique does not require differentiation, as do other myelin stain techniques, since it can be used on any thickness of sections which stain easily with any counterstain.

Methods

Fixation and Sectioning - 10% formol saline or 5% formalin for 1 to 14 days, depending on the size of the brain or brain blocks, and whether the brain had been previously perfused with normal saline and/or 10% formol acetate. Sections are cut at 10 - 15 micra.

Staining procedure

(a) Bring sections down to distilled water. (Before bringing them down to distilled water, cover slides with 1% celloidin, air-dry and place them in 80% alcohol).

(b) Mordant in 2,5 ferric alum for one hour (can be left overnight if desired).

(c) Wash thoroughly with distilled water.

(d) Place sections in the working haematoxylin solution and leave in a 37°C incubator for 2 to 3 hours. The grey matter should appear almost colourless.

(e) Wash quickly in distilled water.

(f) Clear in 80% alcohol.

(g) Bring sections back to distilled water for counterstaining with either neutral red or cresyl echt violet.

Neutral Red Counterstaining

(a) Place in 0.1 N-acetate buffer, pH 5,6. Prepare fresh buffer by combining 1 part 0,1 N-acetic acid and 9 parts 0,1 N-sodium acetate.

(b) Stain 5 to 10 minutes with 0,05% neutral red solution which is diluted with the acetate buffer in equal parts.

(c) Rinse rapidly in distilled water.

(d) Treat for 30 seconds with the copper sulphate-chrome solution.

(e) Dehydrate, clear and mount in DePeX.

OR Cresyl Echt Violet Counterstaining

(a) Place sections in 0,5 cresyl echt violet solution for 10 minutes.

(b) Wash well in distilled water.

(c) Differentiate in 95% alcohol (add 1-3 drops of 10% glacial acetic acid to facilitate the differentiating process).

(d) Dehydrate, clear and mount in DePeX.

Solutions

2,5% ferric ammonium sulphate.

10% alcohol haematoxylin - 10 gms, haematoxylin is dissolved in 100 ccs. absolute alcohol, and the stock solution is left to ripen at room temperature for 4 to 6 weeks (this solution should be prepared long beforehand, and replenished continuously).

Saturated lithium carbonate solution - 1,60 gms. lithium carbonate is added to 100 ccs. distilled water.

Working haematoxylin solution - To 10 ccs. stock 10% haematoxylin, 90 ccs. distilled water, and then 8,0 ccs. saturated lithium carbonate solution are added, and the mixture is shaken well before using.

0,05% aqueous neutral red.

0,5% cresyl echt violet solution - a few drops of 10% acetic acid is added before using.

Copper sulphate-chrome alum solution - To 500 ccs. distilled water, 1,0 gms. copper sulphate ($CuSO_4.5H_2O$), 1,0 gms. chrome alum ($CrK(SO_4)_2.12H_2O$ and 6,0 ccs. 10% glacial acetic acid are added in that order and stirred well until the mixture is completely dissolved. Then it is ready for use. This solution enhances the colouring of nerve cells and other elements for photography and microscopical contrast.

Results

With neutral red counterstaining, myelin sheaths stain purplish-black, the Nissl substance brilliant red, nuclei reddish-black, red blood cells black and boutons terminaux blackish or deep purple. With cresyl violet counterstaining, myelin sheaths stain blue-black, the Nissl granules violet, nuclei black, cytoplasm of nerve-cells and of neuroglia pink to violet, and boutons terminaux blue-black. Ependyma, media and endothelium of bloodvessels stain in varying tints of mauve, and red blood cells stain blue-black. (Figs. 3 and 4).

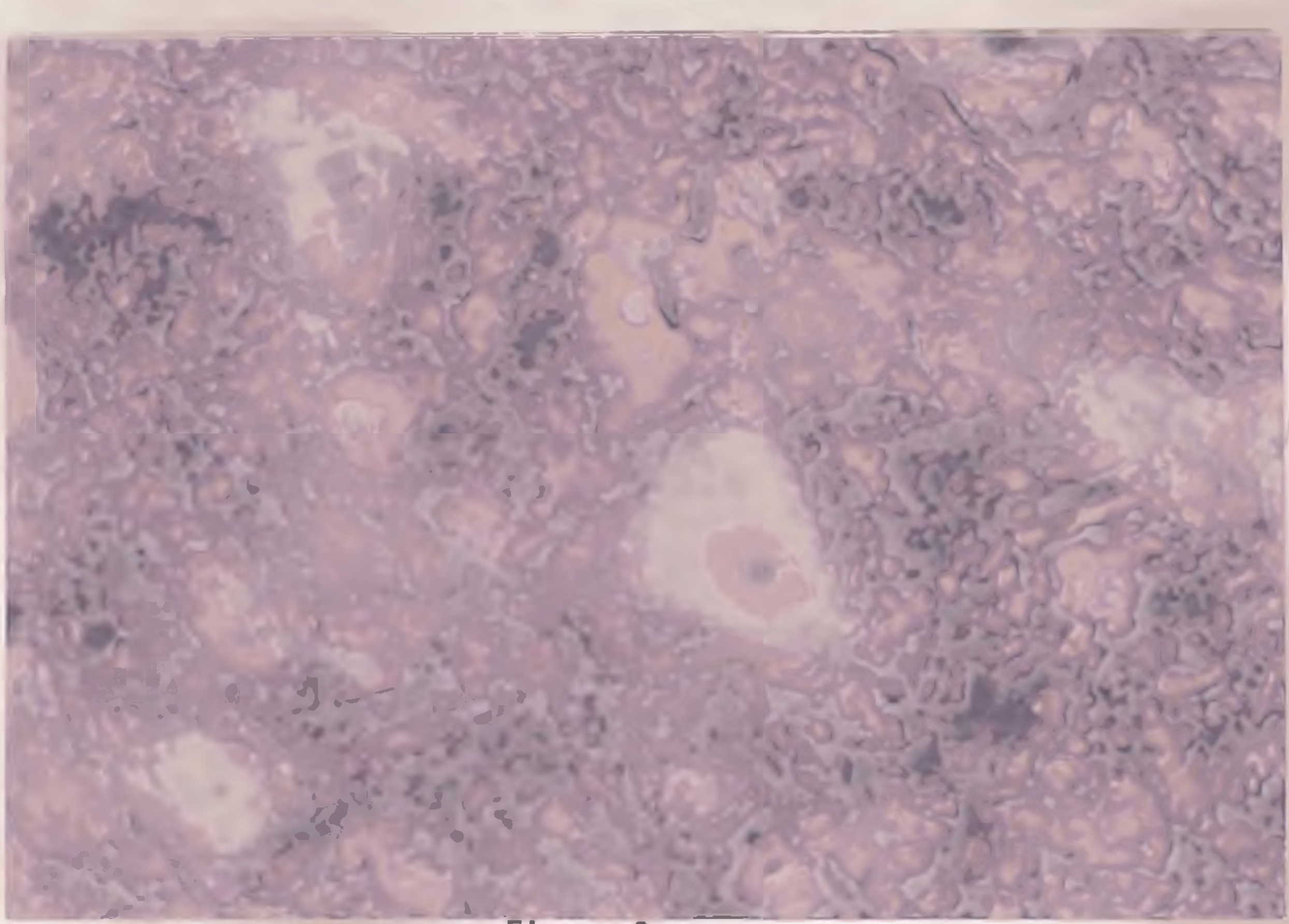

Figure 3

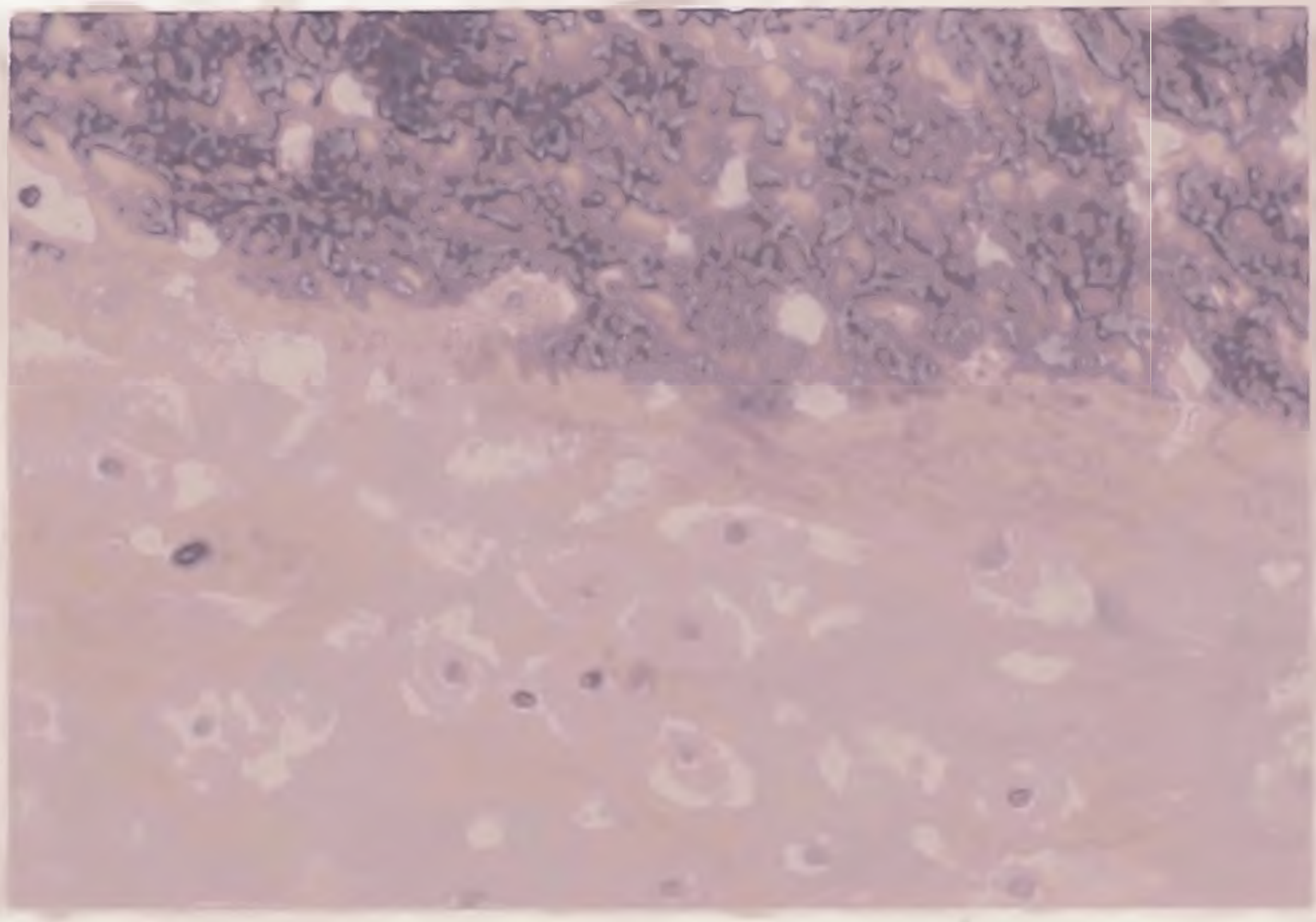

Figure 4

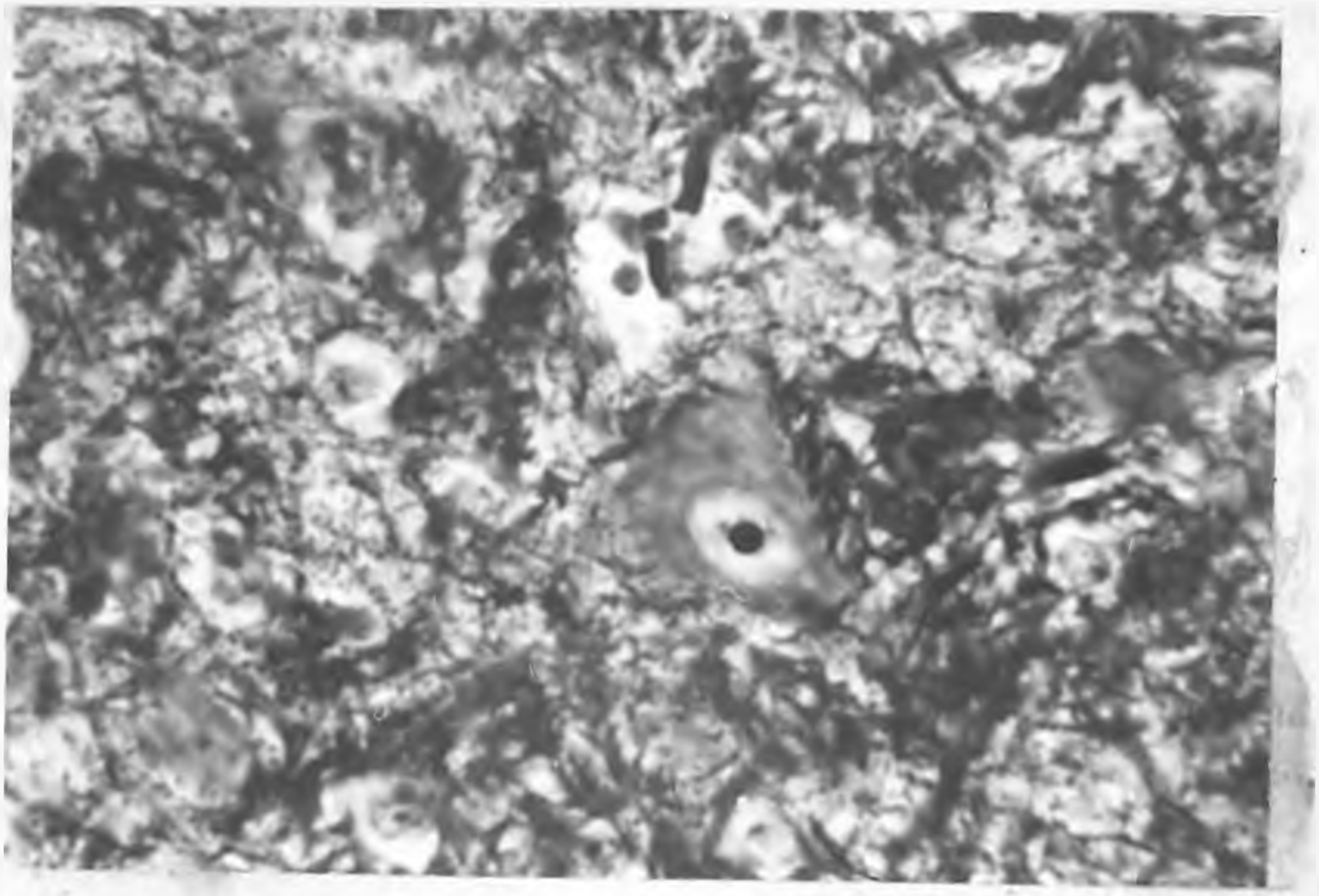

Figure 3

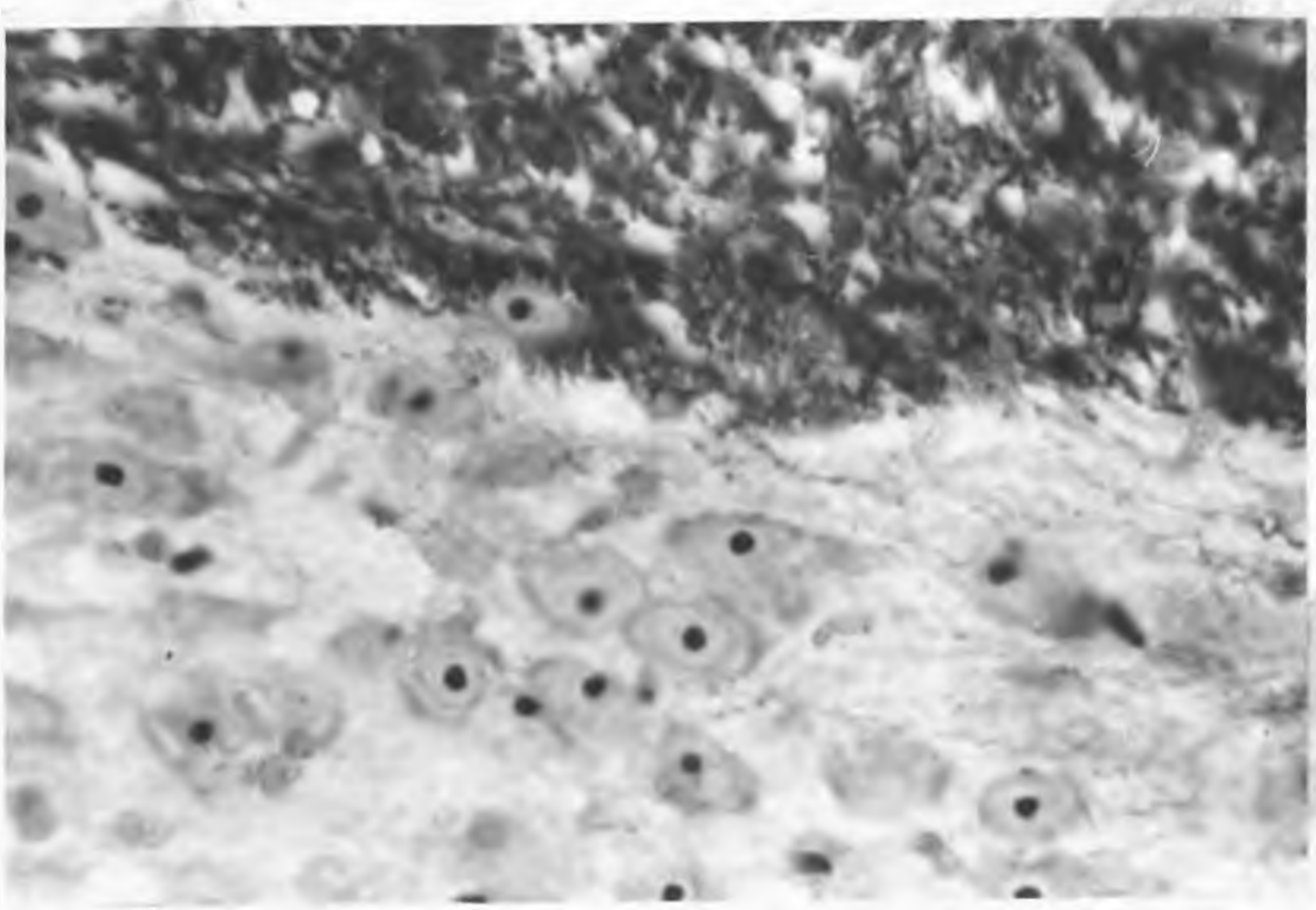

Figure 4

6. METHOD OF MICROMETRY

There are considerable difficulties in selecting the axes of any nerve cell body for measurements with a conventional eyepiece micrometer. Very often, the boundary between the cell body and the dendrite is an arbitrary one; the elongated bipolar neurone, commonly found in the epithelia of special sensory organs, such as the eye and ear, gives a good example of this problem. In measuring pyramidal, stellate, round or oval cells of the diencephalic structures, a cytological landmark can be made on the first dendritic bifurcation, but no such agreement can be reached on the thalamus whose cells vary widely in size and shape. DeWulf and his associates (1971) have designated an eyepiece micrometer which is furnished with a row of circles; the diameter of each circle is 5% larger than that of the preceding circle. The size of a nerve cell body is indicated by the diameter of the circle which encompasses it without masking any part of its contours. DeWulf found that the circle no. 18 corresponded with the smallest thalamic neurone, and the circle no. 64 with the largest thalamic neurone, thus achieving a range of 45 different sizes! The microscope is adjusted so that 0,01 mm. of its <u>objective</u> micrometer corresponds with the diameter of circle no. 42 of DeWulf's eyepiece micrometer. For sizes below circle no. 30, the difference may become more marked, as the elements become less readily discernible because of their smallness. But this difference does not, at all, mar the final appearance of the graph depicting the differentiation of size among the thalamic neurones.

DeWulf's method appears to be a very simple one, and its results can be read directly and interpreted quite easily. Unfortunately, at the time of writing this thesis, DeWulf's eyepiece micrometer has been only realized, and is not available anywhere in this country. It would have made the measurements of diencephalic nuclei more easily and accurately than the conventional eyepiece microtome; DeWulf's method of micrometry would provide better results for both quantitative and qualitative studies of the diencephalic structures in this study than any other means of measuring the cells.

In this study, the neurones are measured with the conventional eyepiece micrometer. The axes (length and breadth) on the nerve cell body show more or less fully the entire nucleus and nucleolus, and they do not extend beyond the distribution of the Nissl granules in the processes. These axes must run through the centre of the nucleus, but not necessarily through the nucleolus, since it may not occupy the centre of the nucleus.

Only by visual inspection, I compared <u>absolute cell sizes</u> without attempting to relate such subjectively determined absolute sizes to the absolute size of the brain as a whole.

The method of making such micrometric measurements is illustrated as follows:-

FIGURE 5.

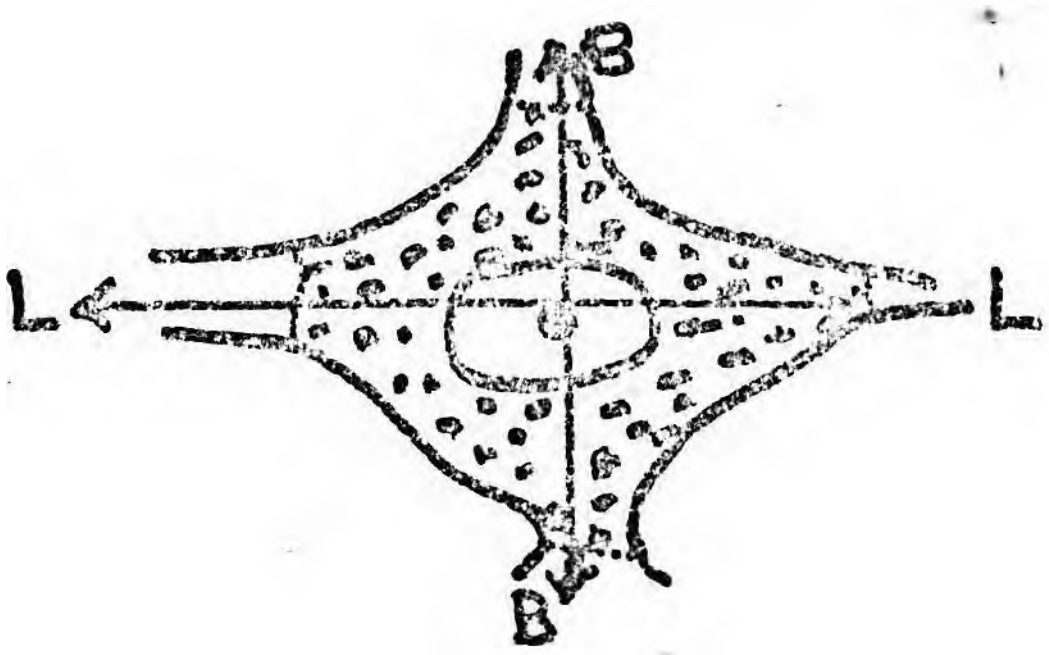

In each diencephalic nucleus, ten to twelve, sometimes twenty, cells are measured and recorded. The measurements of these cells are then analyzed on the IBC computer which calculates not only the sizes of smallest and largest cells, but also the average cellular size in the nucleus studied. Measurements of the neurones of the diencephalon range generally from 4 to 30 $/^u$, sometimes extending to 45 $/^u$, in case of nn. tractus optici and commissuralis posterior (Figure 6). The sizes of all neurones are arranged into five groups from the smallest sizes (1 to 9 $/^u$) to the largest sizes (25 to 30 $/^u$ and over); the intermediate sized cells are rearranged into three groups, each within limits of 5 $/^u$, i.e., 10 to 14 $/^u$; 15 to 19$/^u$; 20 to 24 $/^u$. A set of cells, each from the thalamus and hypothalamus, have been selected from the prosimian and simian specimens listed below:

PROSIMII

(a) Tupaiidae - Tupaia glis - whole diencephalon.
(b) Lemuridae - Lemur catta - whole diencephalon.
(c) Galagidae - (i) Galago crassicaudatus - thalamus, metathalamus and epithalamus.
    (ii) Galago demidovii - subthalamus and hypothalamus.

ANTHROPOIDEA

(d) Cercopithecidae - Cercopithecus aethiops - whole diencephalon.

Two separate montages, one for the thalamus and the other for the hypothalamus, have been set up (Figures 6 and 7); the magnification of these neurones was taken at between 600 and 640x. Tables 2a and 2b are drawn up to list the measurements of neurones in the four different specimens mentioned above. These cell sizes should not be taken as relative cell sizes among those tupaioid and primate species, because I did not make a proper quantitative study, like those of Stephan, Bauchot and their associates (1964 - 1970).

7. ILLUSTRATIONS

Selected sections of the diencephalon cut in the coronal or transverse plane and stained with the Klüver-Barrera method or Simmons's technique are photographed at a magnification of 50 to 60x to illustrate the topography and myeloarchitecture of the diencephalic structures. These photomicrographs are taken only at 4 to 6 different levels, for example, one through the anterior region, two or more through the middle region, and one through the posterior region of the diencephalon of each specimen. In these photomicrographs, the hypothalamus is inadequately illustrated for proper identification of nuclei, particularly the smaller ones or subdivisions of larger nuclei. Among all primate specimens, *Galago demidovii* was selected for a more detailed scrutiny of the hypothalamus; the hypothalamic sections have been photographed at a higher magnification of 70 to 80x. Particular hypothalamic features, such as accessory neurosecretory nuclei and supraoptic decussations found in other specimens, are photographed at the same magnification as the hypothalamic sections. In addition, *camera lucida drawings* of the hypothalamus of *G. demidovii* have been also photographed at more or less the same magnification as the photomicrographs of the same hypothalamic sections.

In respect to the camera lucida drawings, the conventional camera lucida apparatus was found to be unsuitable for making cytoarchitectonic drawings of diencephalic structures cut at the same level as those stained for myeloarchitectonics, because the areas covered by that apparatus were too large for tracing work. A photographic enlarger was set at such a magnification that the outlines of the diencephalic sections as well as the boundaries of diencephalic nuclei could be adequately traced and delineated. Those sections were then studied under a dissecting microscope for cellular density and composition, and were depicted on Bristol board paper plates with India ink. Then those plates were photographed at the same magnification as that of the photomicrographs of the diencephalic sections.

Black and white plates of sections of *Lemur catta* and *Galago demidovii* diencephala were taken at a magnification of 400x using a blue filter to illustrate the three different staining techniques - the Kluver and Barrera, and Simmons techniques for myeloarchitectonics, and the cresyl echt violet technique for cytology and cytoarchitectonics.

Photomicrographs and camera lucida drawings of the lateral geniculate nucleus of all the research specimens have been taken at a much higher magnification than those of the hypothalamus, i.e., between 90 and 120x. The illustrations of the lateral geniculate nucleus of other primates which were not available for this study,

* Table 2 dealing with neuronal types has been eliminated with the old chapter dealing on the types of neurones in the diencephalon.

TABLE 3 (a) COMPARISONS OF CELL SIZES AMONG THE PRIMATE SPECIES

NUCLEUS	TUPAIA GLIS			LEMUR CATTA			GALAGO SPP.			CERCOPITHECUS AETHIOPS		
	SMALLEST SIZE (/μ)	LARGEST SIZE (/μ)	AVERAGE SIZE (/μ)	SMALLEST SIZE (/μ)	LARGEST SIZE (/μ)	AVERAGE SIZE (/μ)	SMALLEST SIZE (/μ)	LARGEST SIZE (/μ)	AVERAGE SIZE (/μ)	SMALLEST SIZE (/μ)	LARGEST SIZE (/μ)	AVERAGE SIZE (/μ)
1. HABENULA (EPITHALAMUS)												
HAbm	5 x 4	8 x 6	7 x 5	7 x 6	12 x 10	10 x 7	4 x 3	8 x 5	6 x 4	10 x 4	12 x 7	11 x 5
HABL	8 x 6	12 x 6	10 x 6	10 x 7	17 x 10	12 x 9	7 x 5	12 x 7	12 x 9	10 x 9	18 x 10	14 x 9
2. THALAMUS												
(a) ANTERIOR NUCLEAR GROUP												
AD	11 x 9	17 x 11	15 x 10	13 x 8	16 x 10	14 x 9	15 x 12	13 x 6	14 x 9	9 x 7	21 x 11	15 x 9
IAD	11 x 5	15 x 9	12 x 7	12 x 5	17 x 6	14 x 6	10 x 6	12 x 12	12 x 9	-	-	-
AM	12 x 9	17 x 10	13 x 10	14 x 10	17 x 15	16 x 12	14 x 9	16 x 13	14 x 11	15 x 10	17 x 12	16 x 11
IAM	10 x 9	15 x 11	12 x 9	14 x 10	20 x 12	16 x 11	9 x 7	14 x 13	12 x 10	14 x 10	16 x 11	15 x 10
AV	12 x 10	15 x 12	15 x 10	16 x 11	20 x 12	17 x 12	12 x 7	16 x 8	13 x 8	15 x 13	32 x 16	23 x 10
(b) MIDLINE NUCLEAR GROUP												
PV	6 x 6	14 x 8	11 x 7	12 x 5	20 x 8	14 x 6	9 x 3	14 x 4	11 x 4	10 x 5	12 x 5	10 x 6
PT	11 x 10	15 x 10	14 x 10	12 x 9	17 x 10	14 x 10	9 x 6	17 x 12	12 x 9	9 x 4	16 x 3	12 x 4
RHOM	11 x 6	14 x 7	11 x 7	10 x 6	12 x 8	11 x 8	11 x 8	13 x 10	13 x 9	12 x 10	20 x 10	15 x 10
CM	6 x [illegible]	10 x 7	9 x 6	9 x 7	12 x 10	10 x 3	10 x 10	15 x 12	13 x 11	10 x 10	18 x 13	15 x 11
REUN	9 x 5	15 x 10	12 x 8	8 x 6	15 x 9	12 x 8	8 x 5	10 x 10	10 x 7	10 x 10	16 x 10	13 x 12
(c) MEDIAL AND INTRALAMINAR NUCLEAR GROUP												
MDdm	15 x 8	20 x 11	16 x 10	14 x 10	20 x 14	17 x 11	13 x 9	16 x 10	14 x 9	16 x 14	26 x 16	22 x 15
MDvl	10 x 8	15 x 15	11 x 9	11 x 10	17 x 12	14 x 11	11 x 7	20 x 10	14 x 8	16 x 12	22 x 17	20 x 14
PC	15 x 8	20 x 10	16 x 10	12 x 10	20 x 10	15 x 10	13 x 10	19 x 11	17 x 11	16 x 13	24 x 14	19 x 14
CL	15 x 10	19 x 11	17 x 11	16 x 15	25 x 20	21 x 16	15 x 10	21 x 8	16 x 10	15 x 13	25 x 14	19 x 12
CEM	10 x 8	15 x 10	12 x 10	11 x 8	19 x 9	15 x 8	10 x 7	12 x 10	11 x 9	12 x 8	30 x 13	16 x 10
PF	13 x 8	20 x 12	16 x 10	15 x 10	20 x 15	18 x 12	10 x 6	16 x 12	17 x 9	12 x 10	20 x 11	16 x 11
[illegible]	13 x [illegible]	20 x 10	15 x 11	————	NOT MEASURED	————	10 x 8	15 x 10	12 x [illegible]	12 x 10	18 x [illegible]	14 x 10
(d) DORSOLATERAL NUCLEAR GROUP												
LD	10 x 7	16 x 7	12 x 9	17 x 8	25 x 15	19 x 12	12 x 10	20 x 11	13 x 5	10 x 10	20 x 10	13 x 9
LI	10 x 7	15 x 9	13 x 9	15 x 5	26 x 15	16 x 12	10 x 9	18 x 10	13 x 10	12 x 9	19 x 13	15 x 10
LP	13 x 8	24 x 10	17 x 10	16 x 12	21 x 15	17 x 14	13 x 8	18 x 9	15 x 10	15 x 11	22 x 12	17 x 11
PULS	10 x 8	15 x 10	12 x 9	12 x 10	20 x 13	17 x 12	14 x 9	18 x 10	15 x 11	15 x 12	24 x 12	19 x 12
PULM	10 x 8	14 x 12	13 x 10	15 x 10	20 x 12	17 x 11	15 x 10	20 x 10	17 x 12	11 x 10	18 x 13	15 x 12
(e) VENTROLATERAL NUCLEAR GROUP												
VA	14 x 12	17 x 10	15 x 10	15 x 13	20 x 16	19 x 15	13 x 10	25 x 11	20 x 11	18 x 12	22 x 13	19 x 13
VM	14 x 10	20 x 14	16 x 11	15 x 10	22 x 15	17 x 13	15 x 12	25 x 11	17 x 12	14 x 9	20 x 12	16 x 8
VL	13 x 10	25 x 14	16 x 11	14 x 12	21 x 14	20 x 13	15 x 10	25 x 11	17 x 12	16 x 10	30 x 16	21 x 15
VT	————	————	————	————	NOT MEASURED	————	————	————	————	15 x [illegible]	28 x 20	[illegible]
VPL	15 x 10	20 x 14	17 x 11	16 x 14	34 x 15	23 x 16	1[illegible] x 10	20 x 16	17 x 13	20 x 12	54 x 20	27 x [illegible]
VPM	12 x [illegible]	18 x 10	15 x 9	14 x 9	27 x 16	17 x 11	12 x 10	15 x 16	15 x 12	13 x 10	30 x 18	24 x 15
VPI	12 x 10	16 x 13	15 x 11	13 x 10	16 x 12	15 x 11	14 x 10	20 x 12	15 x 11	12 x 8	23 x 15	17 x 12

Table 3(b) COMPARISONS OF CELL SIZES AMONG THE PRIMATE SPECIES

NUCLEUS	TUPAIA GLIS			LEMUR CATTA			GALAGO SPP.			CERCOPITHECUS AETHIOPS			"FINAL" NEURONAL TYPES
	SMALLEST SIZE (μ)	LARGEST SIZE (μ)	AVERAGE SIZE (μ)	SMALLEST SIZE (μ)	LARGEST SIZE (μ)	AVERAGE SIZE (μ)	SMALLEST SIZE (μ)	LARGEST SIZE (μ)	AVERAGE SIZE (μ)	SMALLEST SIZE (μ)	LARGEST SIZE (μ)	AVERAGE SIZE (μ)	
(f) POSTERIOR NUCLEAR GROUP													
PRETm	10 x 5	16 x 8	12 x 8	10 x 7	19 x 5	13 x 9	8 x 8	12 x 10	11 x 8	(9 x 6)	(15 x 10)	11 x 8	III
PRETl	15 x 12	23 x 12	18 x 13	14 x 10	20 x 12	17 x 11	15 x 10	30 x 12	16 x 16	-	-		III
NPC	12 x 10	22 x 14	17 x 12	15 x 11	45 x 26	25 x 20	10 x 7	19 x 14	15 x 10	11 x 8	20 x 6	15 x 7	IX,X,XII
SG	14 x 9	20 x 13	18 x 11	10 x 8	16 x 14	22 x 14	13 x 8	21 x 18	19 x 13	21 x 12	30 x 27	26 x 17	VII,IX
NL	11 x 6	18 x 10	14 x 8	18 x 13	28 x 23	22 x 17	15 x 12	20 x 13	18 x 13	12 x 9	20 x 12	18 x 10	V,VI,X
NOT	14 x 9	25 x 15	20 x 13	20 x 13	28 x 25	25 x 18	18 x 15	30 x 15	25 x 14	10 x 7	18 x 11	14 x 9	VII,XI
RETd	11 x 10	21 x 13	16 x 11	15 x 8	15 x 14	15 x 11	15 x 10	23 x 8	20 x 11	(15 x 10)	(30 x 15)	22 x 14	XII,VI,VII
RETv	10 x 7	19 x 13	15 x 9	15 x 10	20 x 15	19 x 11	13 x 7	25 x 11	18 x 11				
3. METATHALAMUS													
MGNdm	17 x 7	23 x 12	19 x 11	12 x 10	17 x 11	16 x 11	15 x 11	23 x 12	19 x 12	20 x 11	30 x 11	25 x 11	V,VI,VII
MGNvl	11 x 10	18 x 10	15 x 9	10 x 8	16 x 14	14 x 10	10 x 8	20 x 8	14 x 9	10 x 10	19 x 13	14 x 11	III,IV,V,VI
PGN	11 x 10	18 x 10	14 x 10	12 x 6	23 x 13	17 x 12	13 x 8	19 x 10	14 x 8	8 x 9	11 x 8	9 x 8	V,VII,VIII
LGN1	15 x 10	20 x 15	17 x 12	15 x 15	27 x 15	20 x 15	15 x 9	18 x 9	18 x 10	16 x 9	20 x 10	18 x 8	VII,IX
LGN2	14 x 10	20 x 13	16 x 12	16 x 11	29 x 17	20 x 15	12 x 8	16 x 10	14 x 9	16 x 10	22 x 12	19 x 11	VII,IX
LGN3	15 x 10	17 x 14	17 x 12	13 x 8	19 x 15	15 x 12	11 x 8	16 x 10	13 x 10	11 x 10	20 x 9	15 x 9	III,IV,V
LGN4	12 x 11	20 x 13	16 x 11	10 x 9	16 x 13	14 x 11	10 x 8	18 x 10	14 x 10	12 x 8	19 x 9	15 x 8	III,V
LGN5	14 x 8	20 x 13	15 x 10	11 x 10	20 x 14	15 x 11	12 x 10	20 x 14	15 x 11	10 x 8	16 x 7	13 x 7	V,VI
4. SUBTHALAMUS													
SP	15 x 11	18 x 13	18 x 13	20 x 10	30 x 20	23 x 16	12 x 8	18 x 10	14 x 9	20 x 10	25 x 11	22 x 10	VII
PP	12 x 8	18 x 10	13 x 9	15 x 44	17 x 8	15 x 7	15 x 7	20 x 9	16 x 8	-	-	-	V,VI
ZI	18 x 11	20 x 15	18 x 13	15 x 7	21 x 13	20 x 9	15 x 8	20 x 10	15 x 9	12 x 8	22 x 9	17 x 8	V,VI
FH1	15 x 9	18 x 13	16 x 11	16 x 7	25 x 10	21 x 9	10 x 7	16 x 10	12 x 8	17 x 9	20 x 12	19 x 10	III,V
FH2	15 x 10	20 x 16	19 x 12	14 x 4	20 x 10	17 x 9	13 x 9	20 x 15	17 x 10	15 x 9	18 x 10	16 x 10	IV,VI
STH	14 x 10	20 x 9	16 x 10	16 x 8	18 x 13	17 x 10	13 x 10	23 x 8	16 x 9	15 x 9	20 x 12	17 x 10	V,VI
5. HYPOTHALAMUS													
POH	7 x 5	10 x 5	8 x 5	8 x 5	12 x 9	9 x 6	7 x 6	11 x 6	9 x 6	7 x 4	11 x 8	9 x 6	I,II,III
POL	7 x 5	12 x 10	10 x 7	10 x 7	19 x 10	13 x 10	10 x 10	15 x 11	14 x 10	10 x 6	15 x 12	14 x 9	II,III,V
SO	18 x 8	24 x 11	21 x 10	13 x 33	20 x 10	15 x 8	10 x 9	20 x 14	16 x 11	15 x 9	23 x 12	19 x 10	VI
PAV	12 x 8	18 x 18	16 x 13	8 x 5	17 x 14	14 x 10	13 x 8	17 x 10	15 x 9	10 x 7	18 x 9	14 x 9	VI
SCH	8 x 5	8 x 7	8 x 6	5 x 3	9 x 6	7 x 4	5 x 5	10 x 8	9 x 5	5 x 5	7 x 6	9 x 6	I
PEV	8 x 4	9 x 7	6 x 5	8 x 5	13 x 7	10 x 6	7 x 5	10 x 8	7 x 6	6 x 5	9 x 5	7 x 5	I,II
VMH	8 x 7	15 x 10	12 x 8	10 x 8	14 x 8	12 x 9	10 x 5	15 x 8	12 x 6	10 x 6	15 x 8	13 x 7	III
DMH	10 x 7	13 x 11	10 x 7	8 x 6	17 x 8	12 x 8	10 x 5	16 x 8	14 x 8	10 x 8	21 x 10	16 x 9	III,V,VIII
TM	10 x 6	15 x 9	12 x 8	14 x 10	20 x 14	15 x 9	12 x 6	20 x 7	14 x 7	10 x 9	22 x 10	16 x 9	V,VII
TL	11 x 6	14 x 9	13 x 8	12 x 10	20 x 14	17 x 11	10 x 6	19 x 7	13 x 6	10 x 8	15 x 12	13 x 10	III,IV,V
PRF	14 x 7	17 x 9	15 x 9	15 x 8	33 x 15	19 x 12	13 x 5	17 x 11	15 x 9	10 x 8	18 x 10	14 x 9	V,VI,VII
PRM	10 x 6	10 x 8	10 x 7	14 x 8	16 x 5	14 x 7	12 x 6	15 x 11	13 x 8	13 x 10	15 x 12	14 x 11	V
PM	10 x 6	17 x 10	11 x 8	10 x 7	19 x 12	13 x 9	10 x 7	15 x 10	13 x 9	10 x 8	20 x 10	15 x 9	V,VII
ML	16 x 9	15 x 13	13 x 9	11 x 10	20 x 14	16 x 11	12 x 10	15 x 15	13 x 10	12 x 10	18 x 10	15 x 10	V,VI,VII
MIC	10 x 9	19 x 10	13 x 9	19 x 10	24 x 15	20 x 12	15 x 8	20 x 12	16 x 12	12 x 11	25 x 10	18 x 10	VII,IX
SC (Standard cell)	-	-	27 x 12	-	-	34 x 22	-	-	26 x 20	-	-	16 x 12	XII

EXPLANATION OF FIGURE

Figure 6

A photomicrographic montage of neurones to illustrate the Simmons classification of *twelve* types of neurones in the tupaiid and primate thalamus.

Note: Type XII is a magnocellular neurone from the red nucleus of *Tupaia glis* that is used as a standard cell type in this classification.

Abbreviations:

I. HAB - n. habenularis medialis
II. PVa - n. paraventricularis anterior
III. RH - n. rhomboidalis
IV. PT - n. parataenialis
V. PC - n. paracentralis
VI. CEM - n. centrum medianum
VII. VA - n. ventralis anterior
VIII. VPM - n. ventralis posteromedialis
IX. VL - n. ventralis lateralis
X. NL - n. limitans
XI. NOT - n. tractus opticus
XII. RN - n. ruber mesencephali

Cresyl-echt violet stain x600-640

THALAMIC NEURONES

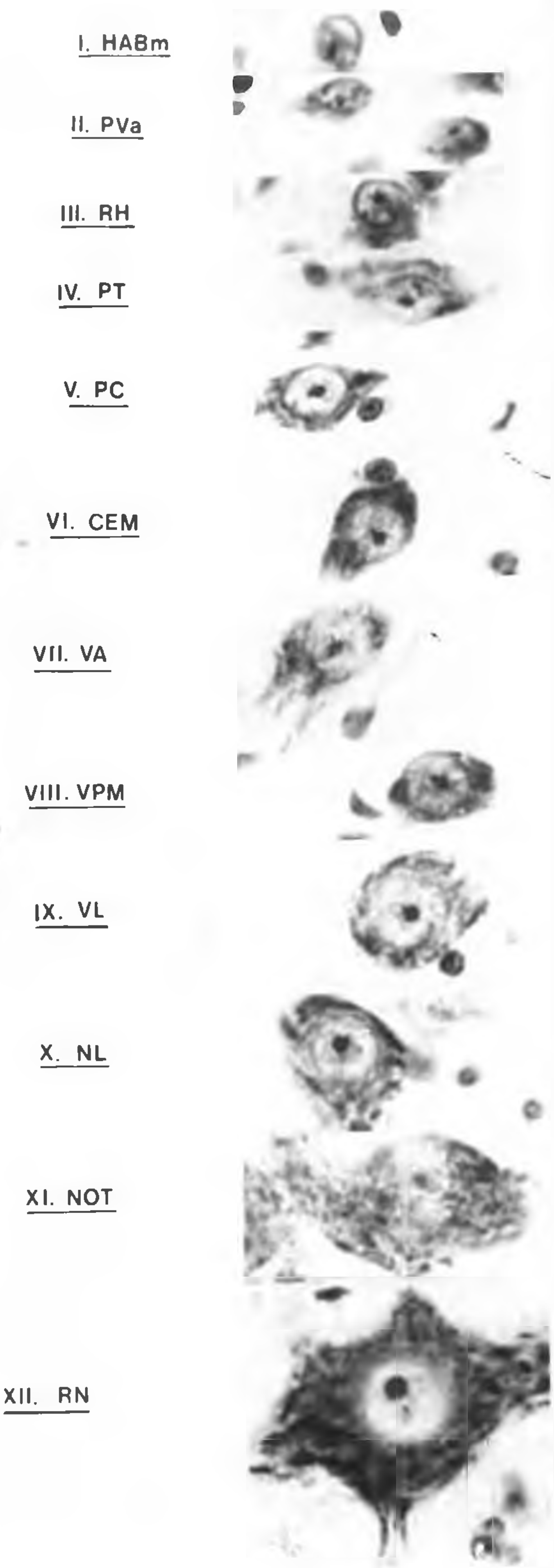

Figure 6

EXPLANATIONS OF FIGURES

Figure 7.

A photomicrographic montage to illustrate the Simmons classification of nine types of neurones in the tupaiid and primate hypothalamus, and also to compare with those in Wahren's classification (Figure 8).

Abbreviations:

I. SCH - n. suprachiasmaticus
II. PEV - n. periventricularis hypothalami
III. VMH - n. ventromedialis hypothalami
IV. PRF - n. perifornicalis
V. ML - n. mamillaris lateralis
VI. SO - n. supraopticus
VII. TUB - n. tuberalis (lateralis)
VIII. DMH - n. dorsomedialis hypothalami
IX. MIC - n. mamillaris intercalatus

Cresyl echt-violet stain x600-640

* Figure 8 illustrating neurone types in the hypothalamus according to Wahren's classification has been eliminated with the notes of the old chapter (Chapter 3)

HYPOTHALAMIC NEURONES

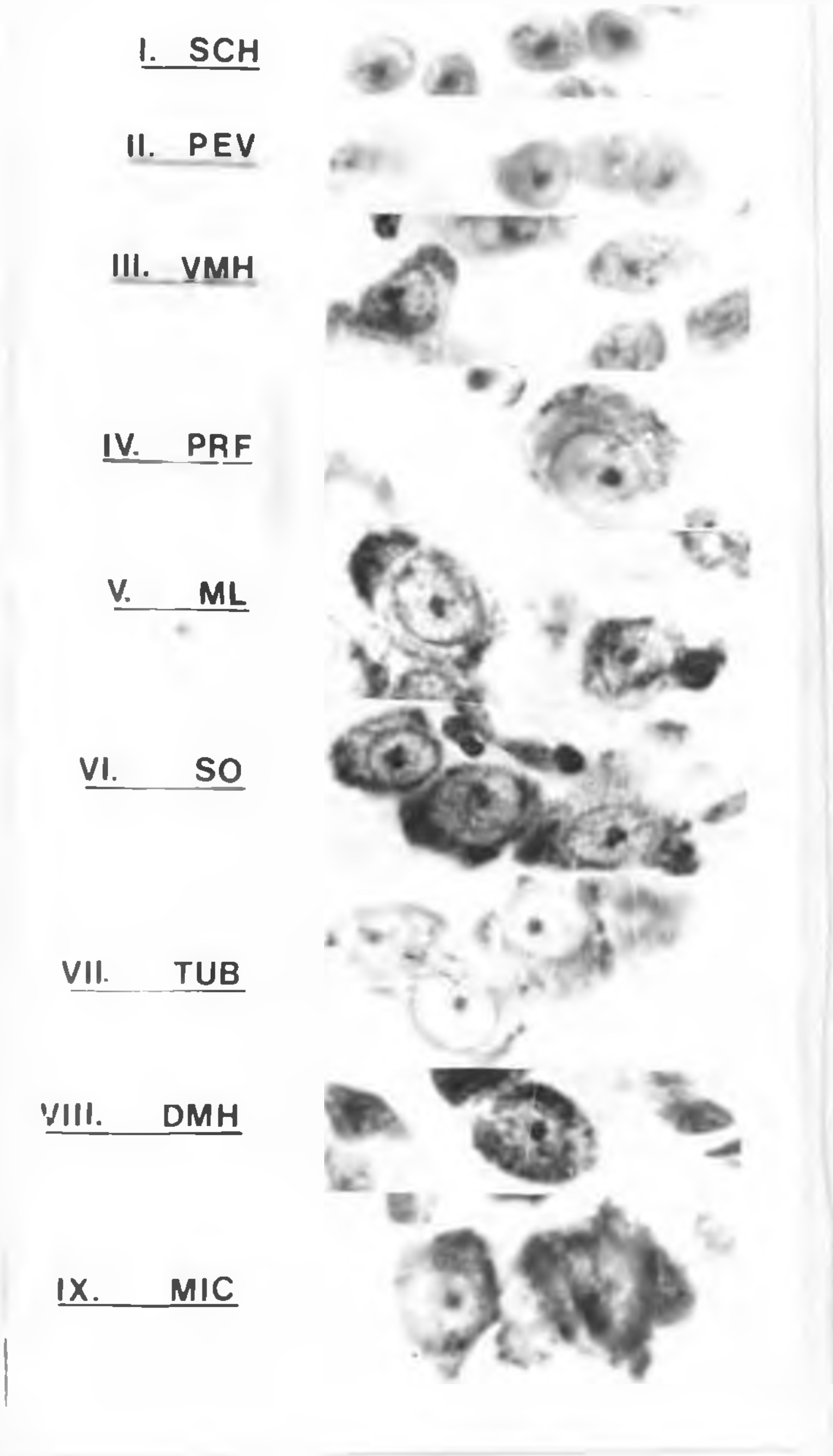

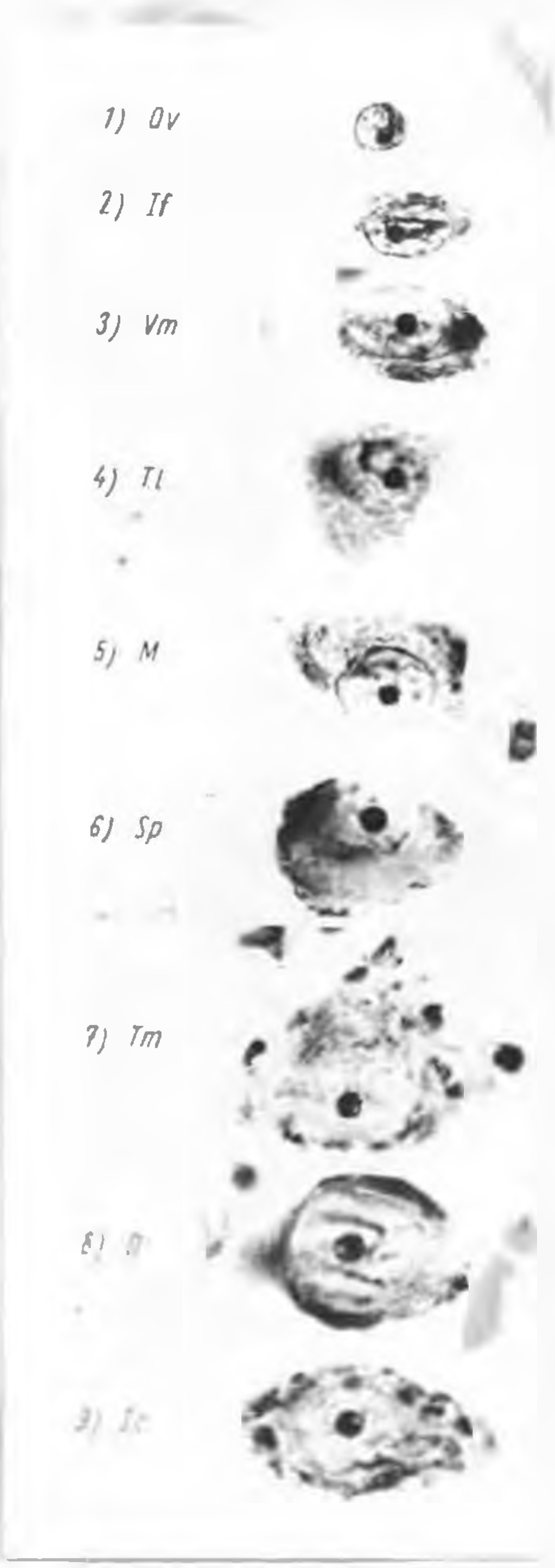

Figure 7

Figure 8.

were adapted from the literature, and then modified to conform with the other illustrations.

Sagittal sections of brains of elephant shrew, tree-shrew, lemur, galago, monkey and man have been constructed diagrammatically to show the relative growths of diencephalon and cerebral hemispheres during the evolution of the primate brain. One graph based on those of Stephan (1964) is included with these diagrams. Other diagrams, modified and relabelled from several articles for comparisons of the certain structures in the ontogeny of the primate diencephalon, as well as the phylogenetic "trees" based on those of Martin (1968), and Charles-Dominique and Martin (1970) are included in this thesis.

PART II

TERMINOLOGY; MORPHOLOGY AND DEVELOPMENT OF THE DIENCEPHALON

CHAPTER 3

TERMINOLOGICAL PROBLEMS IN THE PRIMATE DIENCEPHALON

In order to decide upon a suitable and, perhaps, generally acceptable terminology for nuclear structures of the prosimian diencephalon, various systems of nomenclature will be reviewed and compared with one another. The rapidly changing literature on the diencephalon has sharply accentuated the problem of nomenclature. A complete and rational standardization of terminology is virtually impossible without sufficient structural and functional data upon which to base reasonably accurate homologies. Indeed, an accurate topographical description of nuclear groups of the diencephalon, coupled with and, controlled by studies of fibre connections of these structures with all available methods, are quite essential. However, criteria for the identification of nuclei are variable. In some situations, there is a clear boundary line between two regions containing identical cell types; in others, within an apparently undivided region, there are differences in cell type, density or composition, and these variations may be associated with differences in staining intensity. From the trend of recent histological investigations, it is probably safe to say that the cell type remains the most important single criterion in the morphological delimitation of diencephalic nuclei. Since the mammalian thalamus has been studied by a multitude of investigators adhering to numerous schools, a complex nomenclature with many confusing synonyms has been evolved; discrepancies and contradictions have become more and more evident in the subdivision of thalamic masses. Concerning the hypothalamus, too, there have been also difficulties in homologizing the various structures, partly because many names have been used for the same hypothalamic structures, and partly because of specific differences among various mammals. Comparative studies of the hypothalamus in the present century have

I have used throughout "n." and "nn." as abbreviations for "nucleus" and "nuclei" respectively; although strictly speaking in terms of the Paris Nomina Anatomica, the correct abbreviations should be "nucl." and its plural, "n." and "nn." as abbreviations for "nerve" and "nerves" not entirely succeeded in eliminating the confusion; there has been a tendency, among several workers, towards overly detailed and minute subdividing of hypothalamic structures. Grünthal (1934) stated that the hypothalamus of non-mammalian vertebrates and mammals is more differentiated than that of higher mammals, but his view aroused much criticism, particularly from Crosby and Woodburne (1940), Kuhlenbeck (1949, 1954) and Spatz (1959). These workers maintain that the hypothalamus has not changed much during its phylogeny; structures have been either eliminated through development of other structures or merged with newer nuclei, but the fundamental pattern of hypothalamic nuclear arrangement remains more or less unchanged from fish through the vertebrate classes to mammals, and finally to primates.

THE SCHOOLS OF NOMENCLATURE

The terminologies, based on cyto- and myelo-architectural, as well as topographical, grounds, were formulated by various 'schools of nomenclature', particularly the Continental and Anglo-American Schools. Those schools have attempted to designate thalamic components delineated morphologically by topographical or descriptive adjectives, numbers, or even letters, either Greek or Arabic, thus, causing great confusion. Clinical neurologists, in particular, have despaired over such terms as 'Nucleus postopticus pars inferior' or 'nucleus hypothalamus magnocellularis'. Simple descriptive terms like 'n. ventralis posterior', 'n. hypothalamicus ventromedialis' or 'n. subthalamicus', etc. have more appeal to students of neurological subjects.

1. The Continental School of Nomenclature

To this school belong the French and German workers such as principally Friedemann (1912), d'Hollander (1913), Spiegel and Zweig (1919), Müssen (1923), Foix and Nicolesco (1925), Greving (1925), Grünthal (1930, 1934), Koikegami (1938), C. & O. Vogt (1941), Brockhaus (1942), Feremutsch and Simma (1955 - 1963), Hassler (1959), Wahren (1959) and Bauchot (1956 - 1967). The terminologies of these latter authors whose names are underlined here will be described briefly with reference to the terminology devised for this present study. Even here, there are different terminologies, some very confusing and others bleak and meaningless, which appear to be centred on the lateral and ventral thalamic nuclear groups, and to a lesser extent, on the medial thalamic mass. As far as the other diencephalic regions are concerned, only the preoptico-supraoptic area of the hypothalamus, and the proper categorization of nuclei belonging to the ventral thalamus and subthalamus, need particular attention.

(a) The nomenclatural method of Feremutsch and Simma (1955 - 1963) (Table 5 - Column 2).

Those authors group together individual nuclei into larger formations. At the same time, they disregard the standard terminology of thalamic and metathalamic nuclear elements in the Paris Nomina Anatomica (P.N.A. 1955), and have made many variations within the thalamencephalon, in which they include the subthalamic part of the ventral thalamus and habenular nuclei of the epithalamus. Their classification is based only on cellular and topographical forms of the human brain, as they believe that they facilitate the description of individual nuclei, and comparative work on the primate brain. Such structures of their classification are distinguished as follows:

(1) Paramedian structures which are situated close to the wall of the third ventricle such as n. habenularis of the epithalamus, nn. parataenialis and periventricularis which are equivalent to the midline nuclear group of the Anglo-American School;

(2) Medial formations which consist of the anterior thalamic group and n. mediodorsalis;

(3) Intercalated formations which are identical to the intra-laminar nuclei of other authors, viz., nn. paracentralis and centralis lateralis (termed by Feremutsch nucleus circularis), nn. centrum medianum, parafascicularis, centralis medialis and limitans;

(4) Lateral formations which contain the whole ventrolateral thalamic mass and include nn. pulvinaris and reticularis;

(5) Metathalamic structures which denote the lateral and medial geniculate bodies;

(6) Subthalamic formations which consist only of n. subthalamicus and the zona incerta, excluding the fields of Forel, nn. entopeduncularis and peripeduncularis.

In this way, Feremutsch recognizes six broad subdivisions of the diencephalic structures, but they are largely situated in the thalamic region. For instance, the medial and lateral thalamic formations are merely delimited from each other by the intercalated formations (intralaminar nuclei), in the anterior regions, and nn. centrum medianum, parafascicularis and limitans, in the posterior regions of the thalamus. The latter nuclei demarcate also the polar region of the pulvinar from the midbrain. The subthalamus is split up into two parts, based on ontogeny; nn. subthalamicus and zonae incertae are presumed to be entirely diencephalic in character while the fields of Forel and n. peripeduncularis belong to the rostral mesencephalic area. N. entopeduncularis is the most rostrally situated of all subthalamic structures, therefore, it cannot belong to the mesencephalon, but is more closely related to the basal telencephalic areas, particularly the globus pallidus of the corpus striatum. Feremutsch feels that the division between the subthalamus and the rostral hypothalamic region is not properly defined, because the zona incerta often gets lost medially in the dorsal hypothalamic area. The paramedian formations are altered to such an extent that they are displaced or replaced by the medial formations, except nn. habenularis and parataenialis in the dorsal, and n. reuniens, in the ventral parts of the griseum periventriculare (central grey substance of the interthalamic adhesion).

But the crux of this nomenclature revolves around the method of terming the nuclei lying between the internal and external medullary laminae, i.e., the lateral, ventral and pulvinar (posterior) nuclear elements. From the topographical point of view, such an arrangement of the nuclei would be acceptable, since it covers a very large area of heteromorphic nuclei, each of which possesses a distinct cyto- and myelo-architectural identity denoting a different functional character. Even though the borders among these laterally situated nuclear areas remain arbitrary and indistinct, they are not difficult to distinguish from one another cytologically and cytoarchitectonically.

Feremutsch, however, has an entirely different terminology for the hypothalamic nuclei that has been apparently modified from those of Pines (1927), Le Gros Clark (1929, 1930) and Grünthal (1930, 1934). Feremutsch divided the periventricular areas into several parts which extend throughout the entire hypothalamic regions, although he retains the term 'nucleus' for nn. supraopticus, paraventricularis and mamillo-infundibularis. No mention has been made of the divisions within the mamillary region which Feremutsch simply terms 'corpus mamillare', as he does not believe that the mamillary nucleus should be divided into medial and lateral parts, owing to the confusion of the latter part with n. intercalatus. His terminology (see Table 6:3), seems to be more confusing than those of other workers, because his 'areas' and 'zones' cover large regions, irrespective of boundaries and nuclear definitions, and these cannot be homologized easily with any part of the hypothalamus.

(b) The nomenclatural method of Hassler (1959) (Table 5 - Column 1).

Hassler bases his terminology on specific and unspecific functional systems, because he believes that the cellular and fibrous structure of the thalamus is far more differentiated than has been assumed before, and that there are more afferent and efferent fibre connections than can be anticipated. One can, thus, delimit as many as 150 subdivisions of the thalamus alone, based on cyto- and myelo-architectonic differences. Any subdivision of the thalamus which may provide useful stereotactic localizations of the brain, must be based on functional differentiations, but particular difficulties are caused by the nomenclatural confusion in classifying these subdivisions. Hassler uses the nomenclature set up by C. and O Vogt (1941), but with extensions, and he tries to equate his terms only to a moderate degree with those used by the Anglo-American School.

If the thalamus is subdivided according to function, its nuclei belong either to the truncothalamic (unspecific) or to the thalamocortical (specific) systems, by virtue of their relationship to the cerebral cortex. Those nuclei, which do not project directly to the cerebral cortex or are independent of the cortex, are the midline, intralaminar, habenular, dorsolateral nuclei and small isolated groups of cells in both geniculate bodies. These truncothalamic nuclei, except the habenular nuclei, form the unspecific projection system to the cerebral cortex since they influence the electrical activity of the cortical fields, although they do not send their fibres directly to the cerebral cortex (Morison and Dempsey 1942).

According to Hassler, the thalamic nuclei which have specific projections to the cerebral cortex, have such characteristi cellular and fibrous structure that each thalamic nucleus is an intimate two-directional relationship with its corresponding cortical area. This relationship constitutes a functional unit - the *thalamico-areal neuronal circuit*. Furthermore, these cortical areas receive secondary, smaller afferent fibres from internuncial cells in their corresponding thalamic nuclei. The larger groups of thalamic nuclei or *territories* which generally have a specific fibre system, project their fibres to special areas in the cerebral hemispheres, so that there is not question that their delimitation is justified. Such structures are the anterior and medial thalamic nuclei, ventrolateral thalamic mass, lateral and medial geniculate bodies.

It is not intended here to give a detailed criticism of Hassler's nomenclature. Indeed, his terminological differences are tabulated along with the terminologies of other workers. (Tables 4 and 5). However, his method of subdividing the lateral thalamic mass needs particular attention, since in this area the terminological controversy is apparently most acute. Within the lateral nuclear mass, are *ventral* nuclei which receive extrathalamic fibres, and *dorsal* nuclei, which are integrative or associational nuclei. Each of these nuclei is split further into oral, intermediate and caudal segments, viz., nn. *ventralis* oralis, intermedius and caudalis; nn. *dorsalis* oralis, intermedius and caudalis. Each of these six nuclear masses is further broken up into anterior, posterior, medial and lateral parts. Two further subdivisions are recognized within the lateral nuclear mass: between each dorsal and ventral nucleus, in their oral, intermediate and caudal segments, there is a nucleus which has an intermediate position both topographically and structurally. It is called *intermediate* or *centrolateral* ('zentrolateral') nucleus, e.g., nn. centrolateralis oralis, intermedius and caudalis. The *rostral* pole of the lateral nuclear mass is not divided clearly into a dorsal and ventral mass, and since the sensory fibre pathways do not extend farther there, the nuclei occupying this

The terms *nuclei laterales* used by the proponents of the Anglo-American School to designate the nuclei lying dorsal to the ventrolateral thalamic mass, appear to be erroneous, and according to the proponents of the Continental School, should be replaced by the terms *nuclei dorsales*. The dorsal and ventral nuclei have been subjected to such an extensive delimiation into smaller divisions or parts that the terms for these smaller units are too complicated for the layman or students of neurological sciences to understand them. Therefore, the terminology for the dorsal nuclei would require careful investigation before the terms for the lateral nuclei are to be replaced by the terms '*nuclei dorsales*', which can conform well with those used for the ventral nuclei. Such terms like 'n. dorsalis superficialis', 'n. dorsalis caudalis', etc., would be out of place with the terms used for the ventral nuclei. Even though the Hasslerian terminology may be better from a historical and logical point of view for those who adhere to the Continental School, a simpler and clearer terminology,and fewer divisions for larger thalamic masses is still much to be desired. The terms *dorsolateral* and *ventrolateral* nuclei are, therefore, used in this study to designate the thalamic nuclei lying medial to n. reticularis, lateral to the medial thalamic mass and dorsal to the subthalamic and hypothalamic regions. By comparison with Hassler's terminology, Feremutsch's and Simma's terminology is a broader and uncomplicated system of classifying various thalamic nuclei based on structure and function.

region are collectively n. lateropolaris.

(c) The nomenclatural method of Wahren (1959) (Table 6, Column 4).

Wahren has given different names to all hypothalamic nuclei and areas lying *rostral* to the mamillary region, and it is not easy to correspond these names to those of other terminologies. Wahren unites the preoptic and supraoptic areas into one continuous cellular mass, including the cytologically different hypothalamic nuclei, nn. supraopticus, paraventricularis and suprachiasmaticus which are, however, classified as separate entities. This new topographical area is termed the *prothalamus*, not only by virtue of its suprathalamic relationships with the telencephalic structures but also because there is no actual distinction between these two regions. The term prothalamus has, however, been designated by Brockhaus (1942) upon whose terminology Wahren appears to have partly based his terminology. The prothalamus is divided into a periventricular and a principal part; the first consists of areas closely associated with the third ventricle, whereas the second is spread over a wide area laterally towards the striatal regions and basal telencephalic regions. In other words, these parts are merely homologous with the medial and lateral preoptic areas, and with the anterior hypothalamic area without nn. supraopticus, paraventricularis and suprachiasmaticus. In the tuberal region of the hypothalamus, Wahren classifies lateral and dorsal hypothalamic areas as 'nuclei' because he insists that the term 'nucleus' should be used more systematically to define a delimited grey substance that can be distinguished from neighbouring regions by 'local differences of number, arrangement and morphology of the tissue elements as they appear with the selective histological methods' (C. and O. Vogt 1941). Wahren does not mention the presence of the posterior hypothalamic area, but apparently includes it in his n. dorsalis. Surprisingly enough, he retains *n. tuberomamillaris* as a separate entity, even in the human hypothalamus, whereas it is either non-existent or merely a ventrolateral extension of the posterior hypothalamic area. Also *n. pallidohypothalamicus* is included in the lateral hypothalamic area; it may be homologous with *n. entopeduncularis* (Kuhlenbeck and Haymaker 1949, 1954) or with *n. ansae lenticularis* of Mosinger (1950). In the mamillary region (corpus mamillare), there are only three mamillary nuclei, medialis, lateralis and intercalatus. Comparisons with other terminologies of hypothalamic nuclei can be found in Table 6, as well as in Wahren's own article.

(d) The nomenclatural method of Bouchot (1963 - 1967) Table 5, Column 3; Table 6, Column 5)

Bouchot classifies the diencephalic structures entirely according to their embryonic origin. He retains nn. pretectalis and thalamicus posterior which are placed together with the geniculate bodies and pulvinar, in the posterior thalamic nuclear group. This posterior thalamic region forms a sort of transitional zone between diencephalon and mesencephalon. Bouchot maintains the ontogenetic division between the subthalamic components of the dorsal and ventral thalamic parts, but excludes only the fields of Forel, which he believes, belong to the mesencephalon. The thalamus is composed of *seven* nuclear groups, among which the ventral and lateral thalamic nuclei are separated from one another and reclassified in the Continental style - dorsal and ventral nuclei which are, like those of Hassler, further subdivided into oral, intermediate and caudal parts. There is an additional nucleus to the dorsal group, *n. dorsalis superficialis*. Among the nuclei belonging to the medial division, is *n. parataenialis* which is usually classified as a midline structure, but Bauchot maintains it in this situation because of its paramedian position. This can be contrasted with *n. submedius*, which is placed with the median or midline nuclear group because of its closer relationship to the ventrally situated nn. centralis medialis, reuniens and interventralis.

Bauchot bases his classification of the hypothalamus and subthalamus of *Perodicticus potto* upon that of Diepen (1962), and it is different from those encountered in the present systems of nomenclature. The preoptic and supraoptic areas are grouped together into a large region that should be possible, particularly in the prosimians, where the structures extend anteriorly and posteriorly without any distinguishable delimitations. This unified region corresponds obviously with the prothalamus of Wahren. Bauchot includes several structures which are truly telencephalic in the morphological and developmental sense in his 'prothalamic' region, *n.commissuralis anterior* and *n.interstitialis*. He maintains that of the stria medullaris the *n.filiformis* is a separate part of n. paraventricularis. In the mamillary region, the mamillary nuclei are divided into several parts; most of these parts can be distinguished topographically and cytologically in the prosimians. Bauchot retains also all the terms for the subthalamic region, except *n. entopeduncularis* which he regards as a telencephalic or striatal structure. He substitutes the term '*area commissuralis postopticus*' for n. supraopticus diffusus, because he maintains that the former nucleus lies clearly posterodorsal, not dorsal, to the optic chiasma, and is, therefore, postoptic and not supraoptic. The cellular density of n. supraopticus diffusus is, in fact, too diffuse and ill-defined for it to be termed a nucleus, and it does not exhibit neurosecretory characteristics like those of nn. supraopticus and paraventricularis. These observations of Bauchot are quite correct, and n. commissuralis postopticus should be included in the standardized nomenclature for the hypothalamic nuclei. (Table 6, Column 5.) But the division of the anterior hypothalamic area into medial and lateral parts is rather vague, and these parts are not well defined in other prosimians. Therefore, the term *anterior hypothalamic area* (area hypothalamica anterior) is retained. Bauchot has made such an impressive array of synonymous terms for each diencephalic nucleus that there is no need to discuss terminological differences of other authors. Otherwise, Bauchot's terminology corresponds quite well with those of Le Gros Clark and Kuhlenbeck, and will be accepted with a few modifications in this study.

2. The Anglo-American School of Nomenclature

(1) The subschool of Le Gros Clark and Walker

(a) Le Gros Clark (1925 - 1938) (Table 4, Column 1; Table 6, Column 1)

Le Gros Clark worked on the primate thalamus (*Tupaia minor* 1929, *Tarsius* 1930, and *Microcebus* 1931) for several years before Walker and other American neurologists evolved a better and simpler nomenclature for thalamic nuclei of *Macacus* species. Since Le Gros Clark's nomenclature was apparently based on those of the Vogts (1909) and of Friedemann (1912), it could be aligned more conveniently with the Continental School. He differed from this school in his classification of the ventral and posterior thalamic nuclei. However, he retained the terminology of older workers by placing some nuclei in other thalamic groups, for example, n. parataenialis with the medial nuclear group and n. suprageniculatus with the lateral nuclear group. The diencephalic nuclei of *Tupaia minor* were not classified into morphological or cytological units, and they were merely described in a graphic manner. However, the thalamic nuclei of Tarsius were arranged in topographical units, and their names were different from those given to T. minor. For instance, n. rhomboidalis of T. minor was retermed n. rhomboideus in the thalamus of Tarsius, and in subsequent primate species; n. dorsalis raphae as n. paraventralis. The ventral group of both T. minor and Tarsius were not classified although they were given terms based on their topographical positions. The terms of both species can be compared with each other as well as with those of other authors. (Table 4, Column 1.) Le Gros Clark paid little attention to the classification of nuclei belonging to other diencephalic regions in both of his prosimian specimens.

In 1938, Le Gros Clark, in collaboration with Beattie, Riddoch and Dott, published a book on the morphological, functional, clinical and surgical aspects of the hypothalamus. In that book, Le Gros Clark devised an even simpler classification of the hypothalamus which is now preferable to that of the Continental School. For convenience, Le Gros Clark classified three regions in the mammalian hypothalamus from before backwards - the pars supraoptica (in relation to the optic chiasma), the tuber cinereum (to which is attached the stalk of the hypophysis) and the pars mamillaris. He kept the preoptic region separate, as he believed it to be a telencephalic area, and not a part of the hypothalamus. His classification is included in Table 6:1. In this table, it is apparent that Le Gros Clark regards the anterior, lateral and posterior areas as 'nuclei'. According to his own definition, the delimitation of these 'nuclei' is determined entirely by their topographical position, their relation to fibre tracts, and the fact that they form spatial units separated off more or less distinctly from surrounding groups by relatively acellular zones Other workers consider that these so-called hypothalamic nuclei are too diffuse and poorly demarcated to be classified properly as 'nuclei' (Ingram 1940, Rioch et al 1940). Therefore, the present terms for hypothalamic nuclei will be retained in this study (see Table 6:1).

(b) Walker (1937, 1938) (Table 4, Column 2)

He used the retrograde cell degeneration technique of Marchi, in determining the boundaries of thalamic nuclei, and the Nissl technique to illustrate different cytoarchitectonic patterns of those nuclei. He believed that anatomical descriptive terms for nuclei were more informative than Greek letters or Arabic numerals. Hence, he followed the terminologies of Rioch (1929) in carnivores, and Crouch (1934) in the macaque more closely than that of Le Gros Clark, but he made several modifications based on his observations of fibre connections of the thalamic nuclei in the macaque. According to Walker, the thalamus is divided into five principal nuclear groups, the metathalamus being included with the posterior thalamic nuclear group . His simplified terminology is used in general descriptions of the thalamus in textbooks of neuro-anatomy, but modifications and additions have been made to Walker's terminology periodically (e.g., by Rose 1942, Krieg 1944, 1948; Olszweski 1952, Kuhlenbeck 1954, Russell 1955, Kruger 1959, Heiner 1960, Bauchot 1963, Kanagasuntheram et al 1968).

(2) The subschool of Kuhlenbeck (1948 - 1954)
(Table 5, Column 4; Table 6, Column 2)

Kuhlenbeck bases his terminology of the dorsal thalamic nuclei on that of Walker, but the thalamus is divided on grounds of its embryonic development into seven groups. He separates the pretectal area from the posterior thalamic group because it is a transitional zone between diencephalon and mesencephalon. The ventral and lateral groups are not separated from each other, and the intralaminar nuclei are set up as a group apart from the medial or lateral nuclear groups. This sort of nomenclature is patterned more strongly on the embryological, rather than anatomical or cytological, approach. Kuhlenbeck represents the structures of his ventral thalamic cell zone; he regards the term subthalamus as a synonym for ventral thalamus, although the subthalamus includes also the structures which are ontogenetically derived from the hypothalamic cell column as well as the mesencephalic tegmental derivatives, e.g., fields of Forel. Whether n. entopeduncularis and the substantia nigra should be included in the subthalamus, is a matter of preference, though it would be expedient to exclude the substantia nigra, because it is entirely a mesencephalic structure, having fibre connections only with the caudal regions of the diencephalon.

Kuhlenbeck (1949) bases his terminology of hypothalamic nuclei almost entirely on that of Rioch (1940). He includes n. subthalamicus and globus pallidus in his hypothalamic classification, because they are derivatives of the primordial hypothalamic longitudinal zone, in spite of the fact that these structures belong functionally to the extrapyramidal system. The hypothalamus is divided into four main groups -- dorsal or entopeduncular, anterior, middle and posterior; these divisions are, however, similar to those of Le Gros Clark (1936), but the dorsal group is omitted. Again, the preoptic and supraoptic regions are grouped together as one region, the anterior hypothalamic region, which corresponds well with Wehren's 'Prothalamus'.

(3) The subschool of Krieg (1944 - 1960)
(Table 4, Column3)

This subschool under Krieg, Toncray and Heiner has the thalamus partitioned into six main nuclear groups. The ventral and lateral nuclear groups are fused into one larger ventrolateral mass that is divided into anterior, middle and posterior thirds. Krieg designated n. medialis dorsalis as n. medialis, and this was divided into three cellular parts. He did not recognize n. medialis ventralis which was re-designated merely as n. submedius. He divided n. paraventricularis into stellato- and rotundo-cellular parts, but these cellular distinctions are not very well developed in the nucleus of the same name in the prosimian thalamus. Krieg described two new elements in the ventral thalamic nuclear group, nn. ventralis ventralis and ventralis dorsomedialis. The existence of these nuclei has been confirmed by Krieg and Toncray (1946) in the human thalamus, Heiner (1960) in the chimpanzee and by Simmons (1965) in the vervet monkey. However, most authors working on the primate diencephalon have either denied or ignored their presence.

(4) The subschool of Olszewski (1952)
(Table 4, Column 5)

Olszewski based his terminology on that of Walker's, but preferred to use Latin names, maintaining that the English names cause more misunderstanding or further confusion of terms. The main difference between the terminologies of these two authors is found in the midline and intralaminar nuclear groups. Olszewski introduced new names to different cellular areas which had been delineated by him on structural and topographical grounds. However, these terms have not been accepted by most authors, with the exception of the parts belonging to n. centralis lateralis, because they are not well developed in higher primates, particularly man.

(5) Other Terminologies up to the present time (19[illegible])

In the past fifteen years there have not been any significant changes in the classification of the primate diencephalon.

In 1963, at a symposium on the normal thalamus in Louvain, Belgium, leading neuroanatomists such as Hopf, Krieg, Simma, Feremutsch, Bauchot and DeWulf, attempted to standardize the nomenclature of thalamic nuclei. In 1971 the results of that symposium were published by DeWulf in a book "Anatomy of the Normal Human Thalamus"; that book became available to me only at the time when most of the thesis had already been written, in 1973.

Kanagasuntheram et al (1968) based their terminology of the lorisoid diencephalon, for the most part, on that of Kaelber (1966) who used the terminologies of Rioch (1929) and Le Gros Clark (1930), the latter being in connection with the ventral thalamic nuclei and preoptic region of *Tamandua tetradactyla* and *Myrmedophaga jubata* (anteaters). All those authors maintained the anterior and lateral divisions of the rostral region of the ventral nucleus, and substituted the term n. paraventricularis for n. filiformis of older workers.

Kanagasuntheram's terminology can be found in Table 4, Column 4, and Table 5, Column 6 mainly for purposes of comparison with the terminology of diencephalic nuclei of prosimians used in this study. Shantha's (1969) classification of nuclei of the chimpanzee thalamus, subthalamus, metathalamus and epithalamus, was based largely on Olszewski's nomenclature with a good measure from the terminologies of Papez and Aronson (1934), Crouch (1934) and Walker (1937), 1938). The latest addition to the terminology of the human diencephalon is by van Buren and Borke (1972). These authors appear to use Hassler's terms to a very large extent, particularly for the ventrolateral thalamic nuclei, but they have made their terminology much clearer by comparing their terms with those of Walker (1938) and Olszewski (1952).

TERMINOLOGY EMPLOYED IN THE PRESENT INVESTIGATION
(Table 5, Column 5; Table 6, Column 7)

The terminology applied to this study is based mostly on those of Le Gros Clark (1930, 1932), Walker (1937, 1938), Krieg (1948), Olszewski (1952), Russell (1955) and Bauchot (1963), with some modifications. The thalamus is divided into six groups as follows:

A. Anterior nuclear group
B. Midline nuclear group
C. Medial and Intralaminar nuclear groups
D. Dorsolateral nuclear group
E. Ventrolateral nuclear group
F. Posterior nuclear group

A. Anterior Nuclear Group

(a) N. anterodorsalis and n. commissuralis interanterodorsalis
(b) N. anteromedialis and n. commissuralis interanteromedialis
(c) N. anteroventralis

Most of the terminologies of human, and to some extent, primate thalamic nuclei have included nn. interanterodorsalis and interanteromedialis either with the anterior thalamic or with the midline thalamic group. In this study, the interanterior nuclei or commissures are retained in the anterior nuclear group mainly on grounds of relationship with the anterior nuclei. However, a reasonable case could be made out for including the commissural parts of the anterior thalamic nuclei with the midline nuclear group, because they are topographically, if not cytoarchitectonically, related to the midline nuclei.

B. Midline Nuclear Group

(a) N. parataenialis
(b) N. paraventricularis
(c) N. rhomboidalis
(d) N. centralis medialis
(e) N. reuniens
(f) N. interventralis

The terminology of these midline nuclei remains the same as in other terminologies, except that n. interventralis is included with the midline nuclear group, because it has a midline position, even though it connects n. ventralis medialis on both sides of the median plane.

C. Medial and Intralaminar Nuclear Groups

(a) N. mediodorsalis }
(b) N. medioventralis } medial thalamic nuclei
(c) N. submedius }

(d) N. paracentralis
(e) N. centralis lateralis } anterior intralaminar
(f) N. subparacentralis } nuclei
(g) N. centrum medianum
(h) N. parafascicularis } posterior intralaminar
(i) N. subparafascicularis } nuclei

The terms nn. *mediodorsalis* and *medioventralis* are preferred to the other names (nn. medialis dorsalis and medialis ventralis) because the former terms are easier to recognize verbally and will not be confused with the terms ventralis dorsomedialis and ventralis medialis. However, in higher primates, the term *n. medialis* can be substituted for n. mediodorsalis, for n. medioventralis is no longer present in these forms. The intralaminar nuclei have long been included with the medial or posterior nuclear groups, but are now commonly treated as a separate group (Hassler 1959, Feremutsch 1963, Bauchot 1963, Schroeder and Jane 1971). That is certainly justifiable, because these nuclei have not only a very distinct topography separating the medial from the lateral thalamic mass, but they also have distinct functional characters. Some workers like Feremutsch and Simma (1955, 1957, 1963) maintain that the centralis lateralis/paracentralis/centralis medialis complex should be termed one intralaminar or intralamellar nucleus surrounding the entire lateral surface of n. mediodorsalis, and thereby, their term nucleus *circularis*. Such an usage would be acceptable, but for easier identification of the constituent nuclei, the old terms are retained in this study.

D. *Dorsolateral Nuclear Group*

(a) N. lateralis dorsalis
(b) N. lateralis intermedius
(c) N. lateralis posterior
(d) N. pulvinaris superior
(e) N. pulvinaris inferior

The lateral thalamic nuclear mass has been divided arbitrarily into dorsal and ventral nuclear groups. Based partially on the Continental School of nomenclature, the lateral thalamic regions are re-classified as dorso- and ventro-lateral thalamic nuclear groups. The latter group should not be confused with the term 'ventral thalamus' which is sometimes used to denote the subthalamic region. For sake of simplicity, the old terms nn. laterales dorsalis, intermedius and posterior will be retained, even though they are not precise definitions of nuclear elements lying dorsally to the ventral nuclear group. The pulvinar is included with the lateral nuclear group because it is actually a posterior extension of this group, and does not form any part of the posterior thalamic group in spite of its topographical position.

E. Ventrolateral Thalamic Group

(a) N. ventralis anterior
(b) N. ventralis lateralis
(c) N. ventralis medialis
(d) N. ventralis intermedius
(e) N. ventralis dorsomedialis
(f) N. ventralis posterior
    (i) pars lateralis
    (ii) pars medialis
    (iii) pars inferioris

The divisions of the ventrolateral thalamic group are based mainly on those of Walker (1937) and Krieg (1948). It has been noted in the third edition of Nomina Anatomica (Wiesbaden 1965) that nn. ventralis anterior and lateralis have been termed together as *n. ventralis anterolateralis*. However, these nuclei are maintained in this study as separate entities, not only for purposes of identification, but also they receive fibre systems from different parts of the brain, and project fibres to different areas in the frontal lobe of the cerebral hemisphere. Some nuclei of dubious identity, such as nn. ventrales medialis, dorsomedialis and intermedius, are included because there is some evidence of their presence and functional differentiation in the primate thalamus. *N. ventralis postero-inferioris* is included with n. ventralis posterior, because in lower primates, it is distinctly formed and has its own architectural and cytological characteristics.

F. *Posterior Nuclear Group*

(a) N. pretectalis
(b) N. suprageniculatus
(c) N. limitans
(d) N. tractus opticus
(e) N. thalamicus posterior
(f) N. commisuralis posterior
(g) N. olivaris superior
(h) N. reticularis

The posterior thalamic group has not been classified by some neuro-anatomists in higher primates, particularly man, because its constituents are too fragmentary for identification and homologizing. However, these nuclei are better developed and individually identifiable in lower primates, and are retained in this study, even though some nuclei have a doubtful separate existence, such as nn. thalamicus posterior and olivaris superior. Although n. reticularis has a different ontogeny from that of the lateral or posterior thalamic group, it is included with the latter group for purely descriptive reasons.

The other components of the diencephalon are classified more or less as in other nomenclatures, but the hypothalamus is classified largely according to Le Gros Clark (1938) and Bauchot (1963).

The Epithalamus

(a) N. habenularis medialis
(b) N. habenularis lateralis

(c) Commissura habenularis
(d) Corpus pineale

The Metathalamus

(a) N. geniculatus lateralis
(b) N. pregeniculatus
(c) N. geniculatus medialis

The lateral geniculate body is very clearly divided on grounds of ontogeny and morphology into dorsal and ventral parts. It would, therefore, be appropriate to classify it into 'n. geniculatus lateralis pars dorsalis' and n. geniculatus lateralis pars ventralis'. Such an extravagance of words is unnecessary. Instead, the ventral part of the lateral geniculate body is accordingly re-termed n. pregeniculatus, while the dorsal part of the same nucleus is known as n. geniculatus lateralis. The medial geniculate body is also divided on similar grounds as the lateral geniculate body, but to a lesser extent, into ~~a~~ dorsomedial and ventrolateral parts; it will be subsequently termed n. geniculatus medialis.

The Subthalamus

(a) N. subthalamicus
(b) N. zonae incertae
(c) N. entopeduncularis
(d) N. peripeduncularis
(e) Fields of Forel

In spite of the fact that the subthalamus is subdivided into two parts - 'subthalamic' and 'ventral thalamic' parts - on grounds of embryonic development or different morphological features, it would be convenient to retain all the abovementioned nuclei in the subthalamus, so as not to confuse with the ventral thalamic region.

The Hypothalamus

The hypothalamus is divided into four regions as follows:

1. Preoptic Region
   - (a) N. preopticus medialis
   - (b) N. preopticus lateralis
2. Supraoptic Region
   - (a) Area hypothalamica anterior
   - (b) N. supraopticus
   - (c) N. commissuralis postopticus (n. supraopticus diffusus)
   - (d) N. hypothalamicus paraventricularis
   - (e) N. suprachiasmaticus
   - (f) N. hypothalamicus periventricularis pars anterior
   - (g) Area hypothalamica dorsalis
3. Infundibular or Tuberal Region
   - (a) N. hypothalamicus ventromedialis
   - (b) N. hypothalamicus dorsomedialis
   - (c) N. hypothalamicus arcuatus or periventricularis posterior
   - (d) N. tuberalis lateralis
   - (e) N. tuberomamillaris
   - (f) Area hypothalamica lateralis
   - (g) Area hypothalamica posterior
   - (h) N. periforniculis
4. Mamillary Region
   - (a) N. mamillaris medialis
   - (b) N. mamillaris lateralis
   - (c) N. mamillaris intercalatus
   - (d) N. supramamillaris
   - (e) N. premamillaris

The hypothalamic structures that bear the term 'area' are so designated, because they do not possess distinct borders, nor do they have definite architectural and cytological characteristics that would qualify them to be called 'nuclei'. These structures are so diffuse that they cannot be delineated from one another.

There are five distinct mamillary nuclei, although more nuclei belonging to the mamillary nuclei have been described in the literature. Such nuclei are actually parts of n. mamillaris medialis, and will be described together with this nucleus.

TABLE 4: TABLE OF NOMENCLATURES OF THE [illegible]

1. LE GROS CLARK (1929-1931)	2. WALKER (1937,1938)	3. KRIEG (1944-1948)	4. KUHLENBECK (1948-1951)	5. OLSZEWSKI (1952)
		1. E P I T H A L A M U S		
N. habenulare	medial habenular nucleus	habenula medialis	N. habenularis medialis	N. habenularis medialis
	lateral habenular nucleus	habenula lateralis	N. habenularis lateralis	N. habenularis lateralis
Commissura habenularis	habenular commissure	- - - - -	habenular commissure	- - - - -
- - - - -	pineal body	- - - - -	epiphysis	- - - - -
		2. T H A L A M U S		
		(i) Anterior nuclear group		
N. anterodorsalis	N. anterodorsalis	N. anterodorsalis	N. anterodorsalis	N. anterior dorsalis
N. anteromedialis	N. anteromedialis	N. anterior medioventralis	N. anteromedialis	N. anterior medialis
N. anteroventralis	N. anteroventralis		N. anteroventralis	N. anterior ventralis
- - - - -	- - - - -	- - - - -	- - - - -	(N. alaris)
(? N. interdorsalis of Cajal) N. commissuralis interanterodorsalis	Interanterodorsal commissure Interanterodorsal nucleus	- - - - -	- - - - -	- - - - -
- - - - -	Interanteromedial commissure and nucleus	- - - - -	- - - - -	- - - - -
		(ii) Midline nuclear group		
N. paraventricularis or dorsalis raphé	N. paraventricularis anterior N. paraventricularis posterior	N. paraventriculares stellato- and rotundocellularis	N. paraventricularis anterior N. paraventricularis posterior	N. paraventricularis
N. parataenialis (in medial group)	N. parataenialis	N. parataenialis	N. parataenialis (in anterior group	(N. parataenialis (N. centralis densocellularis
N. rhomboidalis	N. rhomboideus	N. rhomboideus	N. rhomboidalis	? N. centralis densocellularis
N. centralis medius (N. centralis)	N. centralis medialis	N. centralis medialis	N. centralis medialis	?{N. rotundus (N. centralis latocellularis
N. reuniens	N. reuniens	N. reuniens	N. reuniens	N. reuniens
N. interventralis	N. interventralis	N. reuniens (pro parte)	- - - - -	- - - - -
		(iii) Medial and intra-laminar nuclear groups		
N. dorsomedialis	N. medialis dorsalis	N. medialis	N. medialis	N. medialis dorsalis
N. ventromedialis	N. medialis ventralis	- - - - -	N. medialis ventralis (in ventro-lateral group	- - - - -
N. submedius	N. submedius	N. submedius (in midline group)	N. submedius (in ventral group)	- - - - -
N. paracentralis	N. paracentralis	N. paracentralis (in separate group	N. paracentralis	N. paracentralis
N. centralis lateralis	N. centralis lateralis	N. centralis lateralis	N. centralis lateralis	?{N. centralis lateralis} (N. centralis superolateralis}
		N. glomus [illegible]		
Centre median nucleus	N. centrum medianum (of Luys)	N. centrum medianum (in posterior group	N. centrum medianum	N. centrum medianum
N. parafascicularis	N. parafascicularis	N. parafascicularis	N. parafascicularis	N. parafascicularis
- - - - -	- - - - -	- - - - -	N. subparafascicularis (in ventral group	- - - - -
		(iv) Dorsolateral Nuclear Group		
N. lateralis A (La)	N. lateralis dorsalis	N. lateralis dorsalis	N. lateralis dorsalis	N. lateralis dorsalis
- - - - -	? N. lateralis posterior (angularis)	N. lateralis anterior	- - - - -	- - - - -
N. lateralis B (Lb)	N. lateralis posterior (pro parte)	- - - - -	N. lateralis posterior (part of)	N. lateralis posterior (part of)
N. lateralis pars posterior	N. lateralis posterior	N. lateralis posterior	N. lateralis posterior	N. lateralis posterior
N. lateralis pars posterior	N. pulvinaris lateralis	N. pulvinaris lateralis superior	N. pulvinaris lateralis	N. pulvinaris lateralis
	N. pulvinaris medialis	N. pulvinaris medialis	N. pulvinaris medialis	N. pulvinaris medialis
	N. pulvinaris oralis	N. pulvinaris dorsalis	N. pulvinaris oralis	N. pulvinaris oralis
	N. pulvinaris inferior	N. pulvinaris lateralis inferior (all pulvinar subnuclei in posterior group)	N. pulvinaris inferior	N. pulvinaris inferior

TABLE 4: (contd.) TABLE OF NOMENCLATURES OF THE PRIMATE DIENCEPHALON - (a) EPITHALAMUS, THALAMUS, METATHALAMUS AND SUBTHALAMUS

1. LE GROS CLARK (1929-1931)	2. WALKER (1937,1938)	3. KRIEG (1944-1948)	4. KUHLENBECK (1946-1951)	5. OLSZEWSKI (1952)
		THALAMUS (v) Ventrolateral Nuclear Group	(contd.)	
Anterolateral ventral nucleus	N. ventralis anterior	N. ventralis anterior	N. ventralis anterior	N. ventralis anterior
	N. ventralis lateralis	? N. ventralis ventralis	N. ventralis lateralis	N. ventralis lateralis
Anteromedial ventral nucleus	N. ventralis medialis	N. ventralis medialis	- - - - -	N. ventralis pars medialis
	? N. ventralis ventralis	- - - - -	- - - - -	? "Area X"
	N. ventralis intermedius	- - - - -	- - - - -	N. ventralis pars caudalis
? N. ventralis pars dorsomedialis	- - - - -	N. ventralis dorsomedialis	- - - - -	"Area X"
Posteromedial ventral nucleus	N. ventralis posteromedialis pars magnocellularis	N. ventralis posteromedialis pars magnocellularis	N. ventralis posteromedialis	N. ventralis posteromedialis
	pars parvocellularis	pars parvocellularis	- - - - -	pars parvocellularis
Posterolateral ventral nucleus	N. ventralis posterolateralis	N. ventralis posterolateralis	N. ventralis posterolateralis	N. ventralis posterolateralis pars oralis et caudalis
- - - - -	N. ventralis posteroinferioris	N. ventralis posteroinferioris	N. ventralis posteroinferioris	N. ventralis posteroinferioris
		(vi) Posterior Nuclear Group		
N. pretectalis	- - - - -	- - - - -	Area and n. pretectalis	Regio pretectalis
N. suprageniculatus	N. suprageniculatus	N. suprageniculatus	N. suprageniculatus	N. suprageniculatus
- - - - -	N. limitans	N. limitans	N. lentiformis mesencephalicus	N. limitans
Large celled nucleus of the optic tract	? N. parageniculatus	- - - - -	N. lentiformis mesencephalicus pars magnocellularis	- - - - -
N. opticus tegmenti	- - - - -	- - - - -	N. posterior thalami	Part of regio pretectalis
- - - - -	- - - - -	- - - - -	N. commissuralis posterior	N. interstitialis of the posterior commissure
- - - - -	- - - - -	- - - - -	N. olivaris of the superior collicularis	N. pretectalis anterior
N. reticularis	N. reticularis (in ventral group)	N. reticularis	N. reticularis (in ventral thalamus)	N. reticularis
		3. METATHALAMUS		
Lateral geniculate body (dorsal part)	Corpus geniculatus lateralis pars dorsalis	Lateral geniculate body (pars magnocellularis)	Corpus geniculatus lateralis pars dorsalis	N. geniculatus lateralis pars dorsalis
Lateral geniculate body (ventral part)	Corpus geniculatus lateralis pars ventralis (? N.parageniculatus)	Lateral geniculate body (pars parvocellularis)	Corpus geniculatus lateralis pars ventralis (in ventral thalamus)	N. geniculatus lateralis pars ventralis
Medial geniculate body	Corpus geniculatus medialis	Medial geniculate body (pars parvocellularis)	Corpus geniculatus medialis (pars dorsalis)	N. geniculatus medialis (pars magnocellularis)
		Medial geniculate body (Pars magnocellularis)	Corpus geniculatus medialis (pars ventralis - in ventral thalamus)	N. geniculatus medialis (pars parvocellularis)
		4. SUBTHALAMUS		
N. subthalamicus	- - - - -	Subthalamic nucleus	(Ventral thalamus) N. subthalamicus (of Luys)	N. subthalamicus
N. zona incerta	- - - - -	Zona incerta	Zona incerta	Zona incerta
N. entopeduncularis	- - - - -	- - - - -	- - - - -	- - - - -
- - - - -	- - - - -	- - - - -	Zona incerta pars peripeduncularis	N. peripeduncularis
- - - - -	- - - - -	Nuclei of fields of Forel H_1 and H_2	Fields of Forel H_1 and H_2	Fields of Forel H_1 and H_2

TABLE 5: TABLE OF COMPARISONS OF THE PRIMATE DIENCEPHALON - (a) EPITHALAMUS, THALAMUS, METATHALAMUS AND SUBTHALAMUS

1. HASSLER (1959)	2. FEREMUTSCH (1957-1963)	3. [illegible] (1959, 1963)	4. KANAGASUNTHERAM et al (1965)	5. PRESENT STUDY (1974)
		(1) E P I T H A L A M U S		
N. habenularis medialis } N. habenularis interstitialis }	Habenula (part of paramedian formation)	N. habenularis medialis	N. habenularis medialis	N. habenularis medialis
N. habenularis lateralis } N. habenularis mixtocellularis }		N. habenularis lateralis	N. habenularis lateralis	N. habenularis lateralis
Habenular commissure N. subhabenularis)		- - - - -	- - - - -	Commissura habenularis
Epiphysis	Epiphysis	Epiphysis	- - - - -	Corpus pineale
		(2) T H A L A M U S		
		(i) Anterior thalamic group		
N. anterodorsalis	Nucleus anterior (part of median formation)	N. anterodorsalis	N. anterior dorsalis	N. anterodorsalis
N. anteromedialis		N. anteromedialis	N. anterior medialis	N. anteromedialis
N. anterior principalis } N. [illegible] }		N. anteroventralis	N. anterior ventralis	N. anteroventralis
N. [illegible] }		N. anterodorsalis [illegible] N. anteromedialis [illegible]	- - - - - - - - - -	N.(commissuralis)interanterodorsalis N.(commissuralis)interanteromedialis
		(ii) Midline thalamic group		
N. paramedianus (nucl. gracilis, principalis	} Part of griseum periventriculare in paramedian formation	N. paraventricularis	N. paraventricularis	N. paraventricularis pars anterior et posterior
N. paratenialis	N. paratenialis	N. paratenialis	N. paratenialis (in medial group)	N. paratenialis
N. commissuralis	{ Part of griseum periventricularis in paramedian formation	{ N. [illegible] N. centralis medianus	N. rhomboidalis N. centralis medialis	N. rhomboideus N. centralis medialis
N. endymalis	N. reuniens	N. reuniens	N. reuniens	N. reuniens
- - - - -	- - - - -	N. [illegible]	- - - - -	N. interventralis
		(iii) Midline and intralaminar nuclear groups		
[illegible] medialis	N. mediodorsalis	N. medialis	N. medialis dorsalis	N. mediodorsalis
N. [illegible]	- - - - -	- - - - -	- - - - -	N. [illegible]
? N. [illegible]	(Nn. paracentralis and centralis lateralis) anterior part of N. circularis	N. submedius	N. submedius	N. submedius
N. [illegible]		N. paracentralis	N. paracentralis	N. paracentralis
N. [illegible]		N. centralis lateralis	N. centralis lateralis	N. centralis lateralis
- - - - -	- - - - -	- - - - -	N. subparacentralis	N. subparacentralis
N. [illegible]	Centrum medianum	Centrum medianum	Centrum medianum	N. centrum medianum
N. parafascicularis	N. parafascicularis	N. parafascicularis	N. parafascicularis	N. parafascicularis
- - - - -	- - - - -	N. subparafascicularis	N. [illegible]	N. subparafascicularis
- - - - -	- - - - -	- - - - -	N. [illegible]	- - - - -
		(iv) Dorsolateral Nuclear group		
N. dorsalis superficialis	} Dorsal part of the lateral complex (LD)	N. dorsalis superficialis } N. dorsalis oralis }	N. lateralis pars dorsalis	N. lateralis dorsalis
N. [illegible]		N. dorsalis intermedius	N. lateralis pars intermedius	N. lateralis intermedius
N. dorsalis caudalis		N. dorsalis caudalis	N. lateralis pars posterior	N. lateralis posterior
N. pulvinaris lateralis N. pulvinaris medialis	} N. pulvinaris	N. dorsalis caudalis	Pulvinar	N. pulvinaris superior pars lateralis et medialis
N. pulvinaris [illegible] N. pulvinaris [illegible]				N. pulvinaris medialis
N. pulvinaris ventralis et intergeniculatus				N. pulvinaris inferior

TABLE 5: (contd.) TABLE OF NOMENCLATURES OF THE PRIMATE DIENCEPHALON - (a) EPITHALAMUS, THALAMUS, METATHALAMUS AND SUBTHALAMUS

1. HASSLER (1959)	2. FEREMUTSCH (1957-1962)	3. BAUCHOT (1959, 1963)	4. KANAGASUNTHERAM et al (1965)	5. PRESENT STUDY (1974)
		(v) Ventrolateral Nuclear Group		
N. lateropolaris N. ventro-oralis	Ventral part of the lateral nuclear complex (LV)	N. ventralis oralis	N. ventralis anterior	N. ventralis anterior
N. ventro oralis internus		N. ventralis oralis pars lateralis	N. ventralis lateralis	N. ventralis lateralis
N. ventro-intermedius		N. ventralis oralis pars intermedia	- - - - -	N. ventralis intermedius N. ventralis dorsomedialis
N. ventro-oralis medialis		N. ventralis oralis pars medialis	- - - - -	N. ventralis medialis
N. ventro-caudalis posterior pars internus	Ventroposterior part of the lateral nuclear complex (LVP)	N. ventralis caudalis pars medialis	medial component of n. ventralis posterior	N. ventralis posteromedialis
N. ventro-caudalis posterior pars externus		N. ventralis caudalis pars lateralis	lateral component of n. ventralis posterior	N. ventralis posterolateralis
N. ventrocaudalis parvocellularis (N. ventrocaudalis portae)		N. ventralis caudalis pars inferior	- - - - -	N. ventralis posteroinferioris
		(vi) Posterior Nuclear Group		
? Area pretectalis	N. praetectalis (caudal part of n. medialis?)	Area (N.) pretectalis (Pretectum)	- - - - -	N. pretectalis
	N. suprageniculatus (part of n. lateralis caudalis)	N. suprageniculatus	N. suprageniculatus (in dorsolateral group)	N. suprageniculatus
N. limitans (in medial group)	Nn. limitans cum tractus opticus - posterior part of n. circularis	N. limitans	N. limitans (in dorsolateral group)	N. limitans
- - - - -		- - - - -	Large-celled nucleus of the optic tract	N. tractus opticus
- - - - -	- - - - -	N. posterior (also part of (the pretectum)	- - - - -	N. thalamicus posterior
- - - - -	- - - - -		N. commissuralis posterior	N. commissuralis posterior
- - - - -	- - - - -	- - - - -	N. olivaris of the superior colliculus	N. olivaris of the superior colliculus
N. reticularis parsi oralis et polaris N. reticularis parsi intermedia et caudalis	N. lateralis pars reticularis	N. reticularis (in ventral thalamus group)	N. reticularis pars ventralis (in subthalamus group	N. reticularis pars ventralis
		(3) METATHALAMUS		
Lateral geniculate body parsi parvocellularis et magnocellularis	Corpus geniculatum laterale	N. geniculatus lateralis pars dorsalis	N. geniculatus lateralis pars dorsalis	N. geniculatus lateralis
N. pregeniculatus pars griseum		N. geniculatus lateralis pars ventralis	N. geniculatus lateralis pars ventralis	N. pregeniculatus
N. [illegible]		- - - - -	- - - - -	(N. parageniculatus)
Medial geniculate body	Corpus geniculatum mediale	N. geniculatus medialis	N. geniculatus medialis	N. geniculatus medialis
		(4) SUBTHALAMUS		
Not mentioned	N. subthalamicus	N. subthalamicus	N. subthalamicus	N. subthalamicus
	Zona incerta	Zona incerta	Zona incerta	N. zonae incertae
	- - - - -	N. entopeduncularis	N. entopeduncularis	N. entopeduncularis
	- - - - -	N. peripeduncularis	- - - - -	N. peripeduncularis
	- - - - -	- - - - -	Fields of Forel H_1 and H_2	Fields of forel H_1 and H_2

TABLE 6: TABLE OF NOMENCLATURES OF THE PRIMATE DIENCEPHALON - (5) HYPOTHALAMUS

1. LE GROS CLARK (1938)	2. KUHLENBECK & HAYMAKER (1949)	3. FEREMUTSCH (1955-1957)	4. WAHREN (1959)
	PREOPTIC		REGION
Medial preoptic area	N. preopticus medialis	Area periventricularis	N. prothalamicus ventralis
	N. preopticus periventricularis	hypothalamicus dorsalis	N. prothalamicus periventricularis dorsalis
Lateral preoptic area	N. preopticus lateralis	Area periventricularis hypothalamicus anterior	N. prothalamicus principalis lateralis
	N. interstitialis of the lateral forebrain bundle	Area periventriculare hypothalamica [illegible]	N. [illegible] oralis
	SUPRAOPTIC		REGION
N. supraopticus (N. tangentialis)	N. supraopticus	N. hypothalamicus supraopticus	N. supraopticus
—	N. supraopticus diffusus	—	—
N. paraventricularis (N. magnocellularis hypothalami)	N. paraventricularis —	N. hypothalamicus paraventricularis —	N. paraventricularis —
N. suprachiasmaticus (ovoideus)	N. suprachiasmaticus	Area periventricularis ant.	N. ovoideus
—	N. lineae mediane (?)	Area periventriculare hypothalamica anterior	N. prothalamicus periventricularis
N. hypothalamicus anterior	N. hypothalamicus anterior	Area lateralis hypothalamica anterior	N. hypothalamicus lateralis
—	N. hypothalamicus dorsalis	Area lateralis hypothalamica posterior pars dorsalis	N. hypothalamicus dorsalis
	TUBERAL		REGION
N. hypothalamicus ventromedialis	N. hypothalamicus ventromedialis	Area laterale hypothalamica ventromedialis	N. ventromedialis
N. hypothalamicus dorsomedialis	N. hypothalamicus dorsomedialis	Area medioperiventricolaris	N. dorsomedialis
- - - - -	- - - - -	- - - - -	- - - - -
N. hypothalamicus arcuatus	N. periventricularis posterior N. periventricularis arcuatus	Area periventricularis posterior	N. (tuberis) infundibularis
Part of n. hypothalamicus lateralis	Parts of nn. hypothalamicus lateralis and posterior	N. mamillo-infundibularis	N. tuberomamillaris
N. tuberi.	N. tuberis lateralis	N. tuberis lateralis hypothalamicus	N. tuberis lateralis
- - - - -	N. perifornicalis	Area lateralis hypothalamica posterior (parafornicalis)	N. perifornicalis
N. hypothalamicus lateralis	N. hypothal. lateralis	Area lateralis hypothalamicus reticularis pars principalis	N. hypothalamicus lateralis
N. hypothalamicus posterior	N. hypothal. posterior	- - - - -	- - - - -
	MAMILLARY		REGION
[illegible]	N. mamillaris medialis	N. corporis mamillaris	N. mamillaris medialis
N. mamillaris lateralis	N. mamillaris lateralis		N. mamillaris lateralis
N. intercalatus	N. intercalatus	N. intercalatus hypothalami	N. intercalatus
N. [illegible]	N. premamillaris	- - - - -	- - - - -
(N. [illegible])	N. supramamillaris	- - - - -	- - - - -

TABLE 6: (contd.) TABLE OF NOMENCLATURE OF THE PRIMATE DIENCEPHALON - (b) HYPOTHALAMUS

5. BAUCHOT (1963, 1967)	6. KANAGASUNTHERAM ET AL (1968)	7. PRESENT STUDY (1976)
PREOPTIC		REGION
	N. preopticus principalis N. preopticus medianus	N. preopticus medialis
N. (Area) preopticus medianus	N. preopticus magnocellularis N. preopticus interstitialis	N. preopticus lateralis
N. (Area) preopticus lateralis	N. preopticus periventricularis	N. preopticus periventricularis
Area preoptica periventriculare	N. interstitialis of the inferiorthalamic peduncle	- - - - -
N. interstitialis of the stria terminalis		
SUPRAOPTIC		REGION
N. supraopticus	N. supraopticus	N. supraopticus
Area commissurale postopticus	- - - - -	(N. supraopticus diffusus) N. commissuralis postopticus
(Area paraventriculare) N. paraventricularis	N. paraventricularis	N. paraventricularis
N. suprachiasmaticus	N. suprachiasmaticus	N. suprachiasmaticus
	N. hypothalamicus periventricularis	N. hypothalamicus periventricularis posterior
Area hypothalamicae anteromedialis	Anterior hypothalamic area	Area hypothalamica anterior
Area hypothalamica dorsalis	Dorsal hypothalamic area	Area hypothalamica dorsalis
TUBERAL		REGION
N. ventromedialis	N. hypothalamicus ventromedialis	N. hypothalamicus ventromedialis
N. dorsomedialis	N. hypothalamicus dorsomedialis	N. hypothalamicus dorsomedialis
Supraoptic region N. paraventricularis filiformis	N. hypothalamicus dorsolateralis N. hypothalamicus parvocellularis	N. hypothalamicus dorsolateralis (N. filiformis or hypothalamicus parvocellularis)
N. infundibularis	N. hypothalamicus periventricularis	N. hypothalamicus arcuatus or periventricularis posterior
N. tuberomamillaris	- - - - -	N. tuberomamillaris
- - - - -	N. hypothalamicus tuberis	N. tuberis lateralis
N. (Area) perifornicalis	- - - - -	N. perifornicalis
Area hypothalamicus anterolateralis	N. hypothalamicus lateralis	Area hypothalamica lateralis
Area hypothalamica dorsocaudalis	N. hypothalamicus posterior	Area hypothalamica posterior
MAMILLARY		REGION
N. mamillaris medialis	N. mamillaris medialis	N. mamillaris medialis
N. mamillaris lateralis	N. mamillaris lateralis	N. mamillaris lateralis
N. paramamillaris	N. intercalatus	N. mamillaris intercalatus or paramamillaris
N. (Area premamillaris)	- - - - -	N. premamillaris
? N. perimamillaris	N. supramamillaris N. interstitialis supramamillaris	N. supramamillaris N. mamillaris interstitialis

CHAPTER 4

DEVELOPMENT AND MORPHOLOGY OF THE PRIMATE (AND TUPAIOID) DIENCEPHALON

1. The Development of the Primate Diencephalon

(I) Ontogeny

In the phylogeny of the vertebrate diencephalon, there is a progressive elaboration of its dorsal part (the thalamus and epithalamus), an increasing number of direct and indirect sensory pathways terminate in it and, later, reciprocal relations develop between the thalamus and the superposed neocortex. Thus, when the diencephalon is followed through an ascending series of vertebrates, the thalamus increases in size, while the hypothalamus becomes relatively smaller.

The boundaries of the diencephalic regions may be determined primarily on the basis of topographical relationships of cellular masses within the neural tube, and secondarily by the position of certain sulci, which are landmarks for the boundaries of zones. Both approaches are used in this study.

His (1893, 1904) recognized, in the human diencephalon, three main divisions based on embryonic development - epithalamus, thalamus and hypothalamus. Subsequently, in numerous studies on the adult amphibian forebrain, Herrick (1910, 1917, 1933), found four distinct subdivisions - epithalamus, dorsal thalamus, ventral thalamus and hypothalamus, the boundaries of which were represented fairly constantly by sulci in the wall of the third ventricle. He distinguished also in the mammalian dorsal thalamus, the medial nuclear groups and the lateral groups. He interpreted the corpus Luysii, Forel's fields H_1 and H_2 and the adjacent subthalamic nuclei as components of the ventral thalamus. Other investigators such as Fortuyn (1912), and Herrick and Obenchain (1913) suggested that a similar arrangement could be found in cyclostomes, reptiles and mammals.

Streeter (1912) studied the three main regions of the developing human diencephalon - the dorsal thalamus, the hypothalamus and the epithalamus. Hochsetter (1919) gave a morphological description of the diencephalon in human embryos up to 102 mm. crown-rump length, but he did not study the differentiation of the diencephalic nuclei. Hines (1922) examined the forebrain only during the first four intrauterine months in man. Gilbert (1935) made a detailed study of the development of the human thalamus up to 14 weeks of gestation time, but was concerned only with the fibre tracts of the diencephalon.

Dekaban (1954) studied the ontogeny of the thalamic nuclei in human embryos from 25 mm. to over 150 mm. crown-rump length. Cooper (1945, 1948) studied the development of the metathalamus in the human foetus. In 1950, he carried out an extensive investigation on the ontogeny of the thalamus in human embryos from 3 weeks to full term. He based his observations on the stages of development of four medullary laminae, between which the thalamic nuclei could be identified at their earliest appearance. Kuhlenbeck and his collaborators (1930 - 1947) analysed further the patterns of the vertebrate diencephalon, and concluded that the subdivision of the diencephalon into four zones could be detected not only in amphibians, but also in fish, reptiles, birds and mammals. This morphological subdivision, thus, appears to be a feature of the vertebrate diencephalon, and to be independent of the functional subdivision of brainstem and spinal cord into somatic and visceral columns.

In reptiles, birds and mammals, the longitudinal zonal arrangement of the diencephalon is distinct only at certain ontogenetic stages, because in these forms and not in fish and amphibians, the original pattern breaks up during subsequent ontogeny into many separate diencephalic areas. These areas become progressively blurred by a complex sequence of transformations. But in these forms, an early and transitory stage of embryonic development always reveals the zones of the diencephalon as distinctly as in fish and amphibians.

In tailed amphibians (Urodela), the cellular masses comprising the four longitudinal zones form a periventricular matrix, together with the separating sulci, subthalamus, ventral diencephalic sulcus and hypothalamus. This pattern is better differentiated in a tail-less amphibian (Anura)(Fig.9). Here, the periventricular cellular masses are less dense, and the primordia of some individual nuclei, e.g. the dorsal and ventral parts of the lateral geniculate body, have emerged. Scattered cells derived from the hypothalamus are found in the path of the medial and lateral forebrain bundles that form later the basal forebrain bundle or internal capsule. These cells are the forerunners of the entopeduncular nucleus, a constituent of the rostral subthalamic region.

In the diencephalon of a 70 mm. pig embryo, the four cellular columns are more clearly evident. They have different cell densities and are separated by cell-poor limiting zones. Of the three sulci of the fundamental plan, only the ventral diencephalic sulcus (hypothalamic sulcus) is visible. Miura (1933) demonstrated a zonal system in the key stage of development in a 15 mm. rabbit embryo, where the four fundamental zones and the dorsal, middle and ventral diencephalic sulci, together with some accessory sulci, can be clearly recognized (Fig.10).

The early embryonic pattern of the primate diencephalon is similar to that just described for other mammalian brains. In the brain of an eight week old human embryo, the middle and ventral diencephalic sulci are visible (Fig 11 and 12). In the 11th

EXPLANATIONS OF FIGURES

Figure 9.

Diencephalon of a tail-less amphibian (Anura)

(drawn and modified from Kuhlenbeck 1948 - Figure 1B, p.434.)

Figure 10.

Diencephalon of a rabbit embryo of 15 mm.

(drawn and modified from Kuhlenbeck 1948 - Figure 2, p.434)

Abbreviations in Figures 9 and 10

et - epithalamus
hy - hypothalamus
ld - primordium of the *dorsal* part of the lateral geniculate body
lv - primordium of the *ventral* part of the lateral geniculate body
sd - dorsal diencephalic sulcus
sf - lateral infundibular sulcus
si - infundibular sulcus
sl - sulcus limitans
sm - medial diencephalic sulcus
sv - ventral diencephalic sulcus
td - dorsal thalamus
tm - rostral end of the mesencephalic tegmentum
tv - ventral thalamus

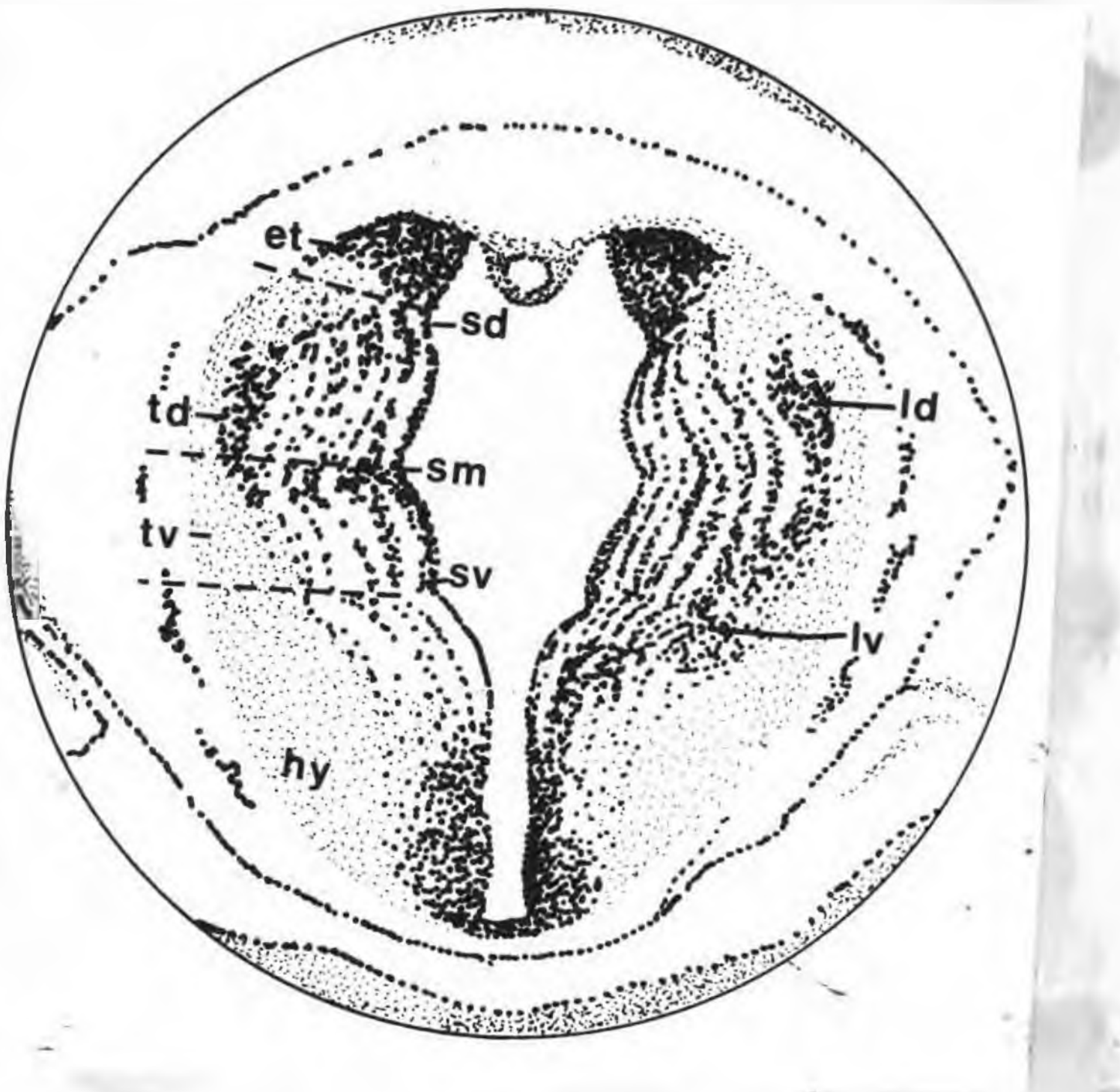

Figure 9.

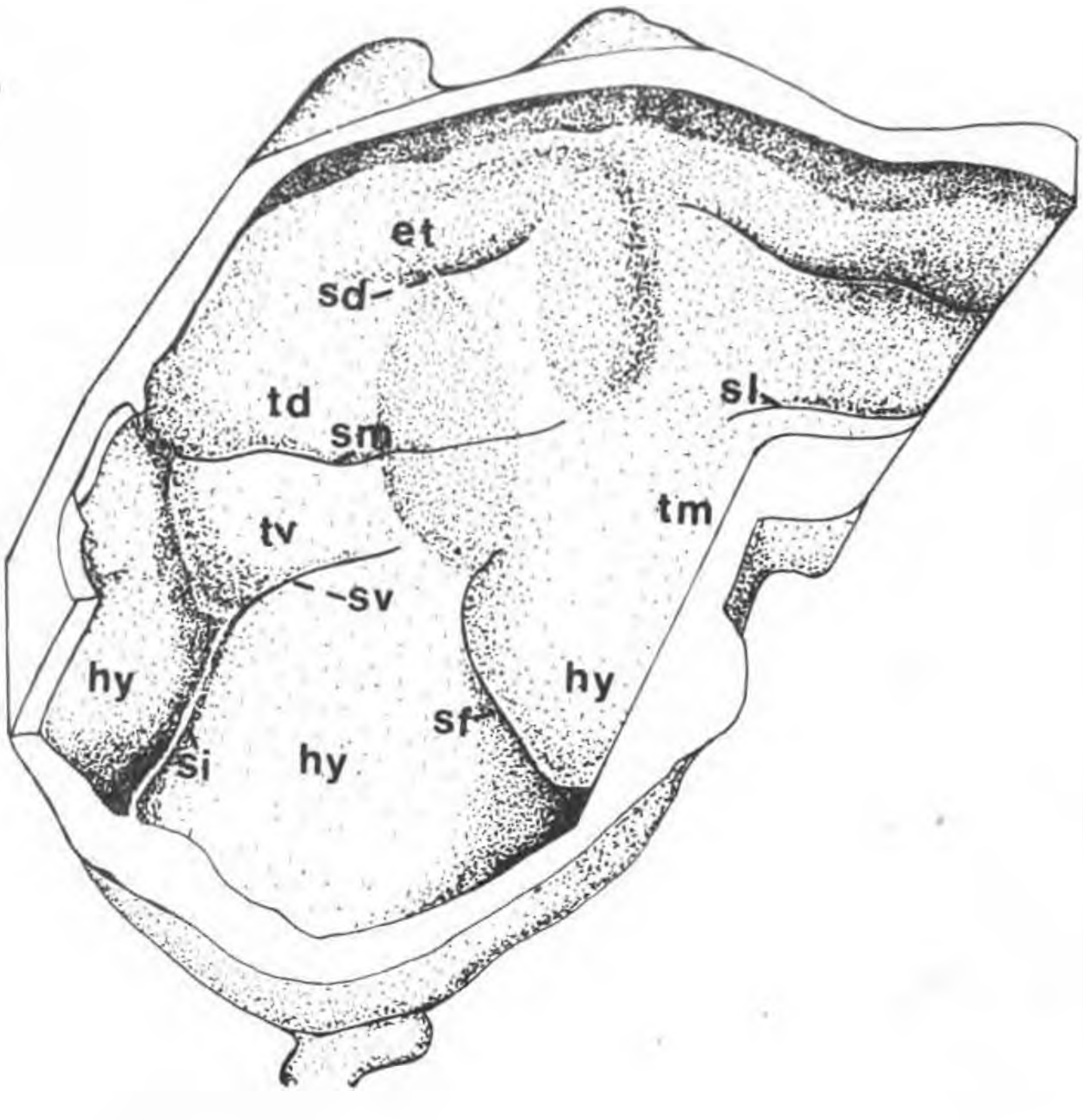

Figure 10.

EXPLANATIONS OF FIGURES

Figure 11

Diagram of the diencephalic zones as seen in a cross section of the diencephalon in a human embryo of about 25 mm. (8 weeks)

(after Kuhlenbeck 1948, Text-figure 2a, p.439)

Figure 12.

Diagram of the diencephalic zones as seen in a cross section of the diencephalon in a human embryo of about 47 mm. (11 weeks)

(after Kuhlenbeck 1948, Text-figure 2b, p.439)

Abbreviations in Figures 11 und 12

et - epithalamus
hy - hypothalamus
cl - primordium of subthalamic nucleus (corpus Luysii)
ld - primordium of the dorsal part of the lateral geniculate body
lv - primordium of the ventral part of the lateral geniculate body
ma - primordium of mamillary body
sd - dorsal diencephalic sulcus
sm - medial diencephalic sulcus
sv - ventral diencephalic sulcus

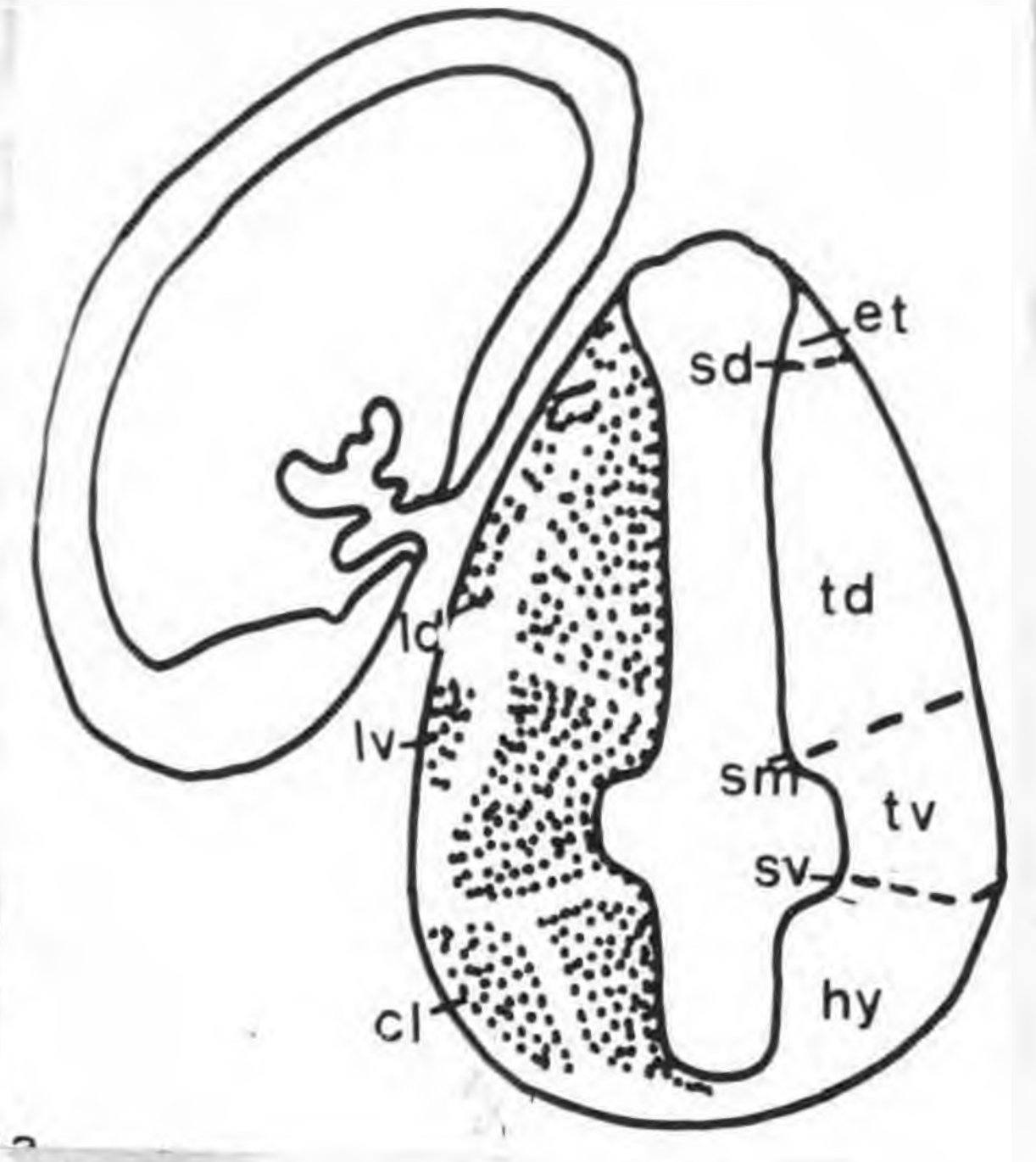

Figure 11.

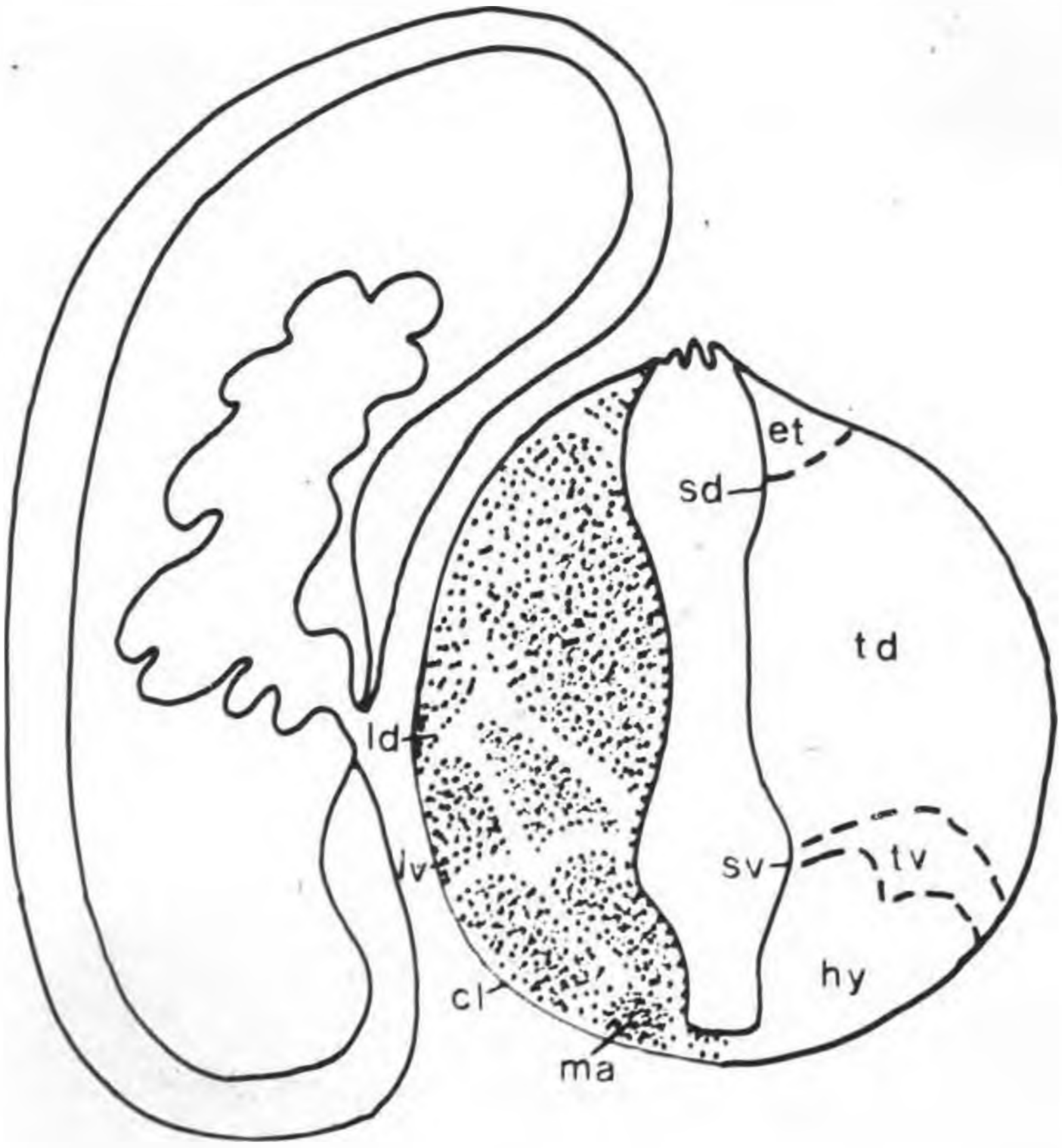

Figure 12.

EXPLANATIONS OF FIGURES

Figure 13.

Diagram of human diencephalon at an early embryonic stage (18 mm - about 7 weeks)

(drawn and modified from Christ 1969, Fig.2-6 A)

Figure 14.

Diagram of human diencephalon at a later embryonic stage (33 mm - about 9 weeks)

Note: the ventral thalamic region becomes differentiated into the reticular nucleus and zona incerta; another portion of the ventral thalamus (gv) migrates lateralwards to become ventral parts of the lateral and medial geniculate bodies; the subthalamic nucleus (s) moves also lateralwards to become a component of the subthalamus; the entopeduncular nucleus migrates lateralwards and rostralwards to become closely related to the internal (medial) segment of the globus pallidus: the intraencephalic sulcus becomes the preoptic recess (rp) which poorly marks the boundary between the preoptic and anterior hypothalamic regions

(drawn and modified from Christ 1969, Fig. 2-6 B)

Abbreviations in Figures 13 and 14

ET - epithalamus
GP - globus pallidus
HY - hypothalamus
M - mamillary body
PRE - preoptic region
TD - dorsal thalamus
TEG - tegmentum of midbrain
TV - ventral thalamus

ac - anterior commissure
ah - adenohypophysis
en - entopeduncular nucleus
fi - interventricular foramen
gv - ventral parts of lateral and medial geniculate bodies
hab - habenular region
is - intraencephalic sulcus which separates the preoptic region from the hypothalamic region
ls - lateral infundibular sulcus
nn - neurohypophysis
pr - pretectal region
r - reticular nucleus
rd - dorsal part of reticular nucleus
rv - ventral part of reticular nucleus
s - subthalamic nucleus
sd - dorsal diencephalic sulcus
sep - septum
sh - sulcus hypothalamicus
sl - sulcus limitans
sm - medial diencephalic sulcus
str - striatum
sv - ventral diencephalic sulcus
zi - zona incerta

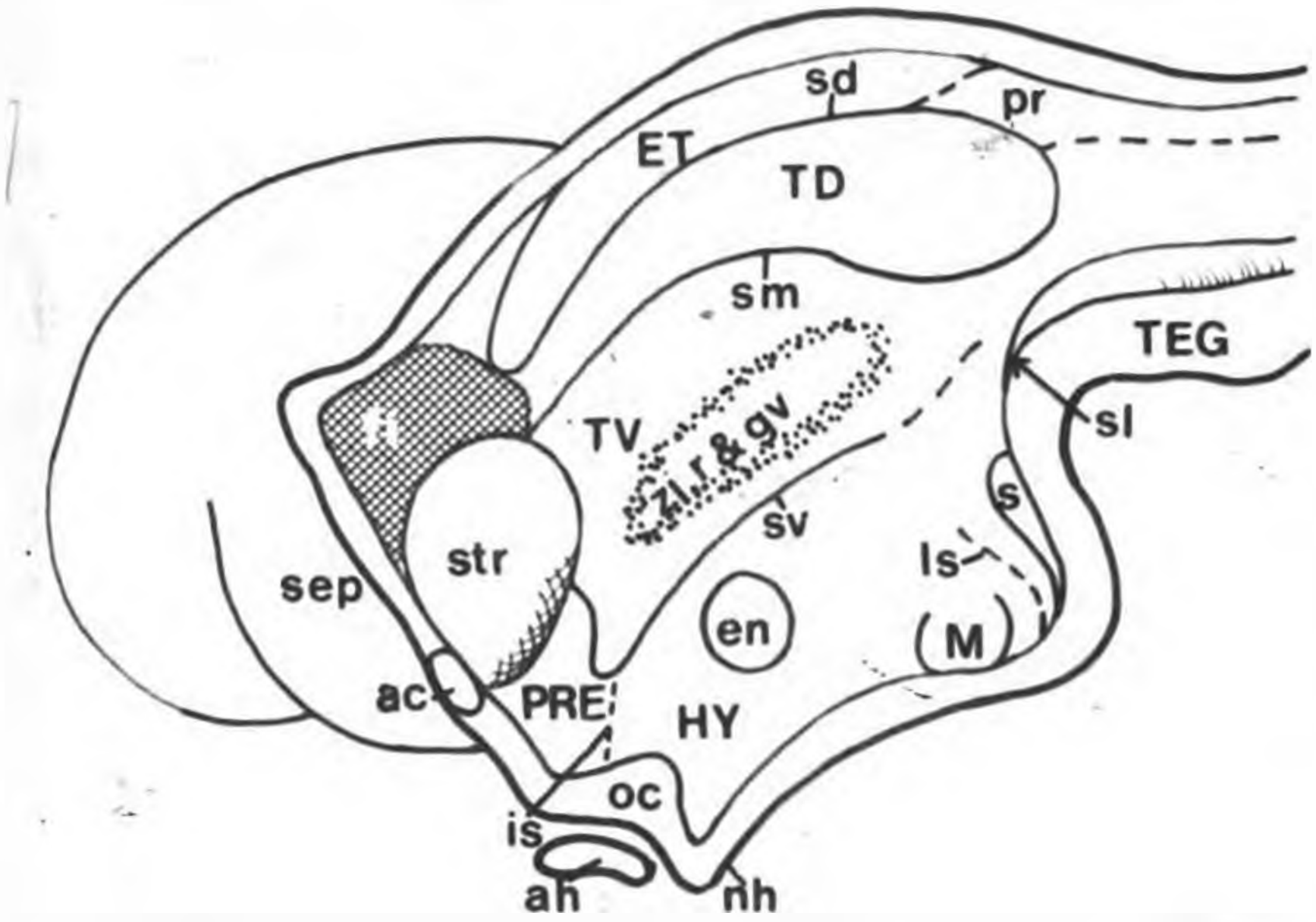

Figure 13.

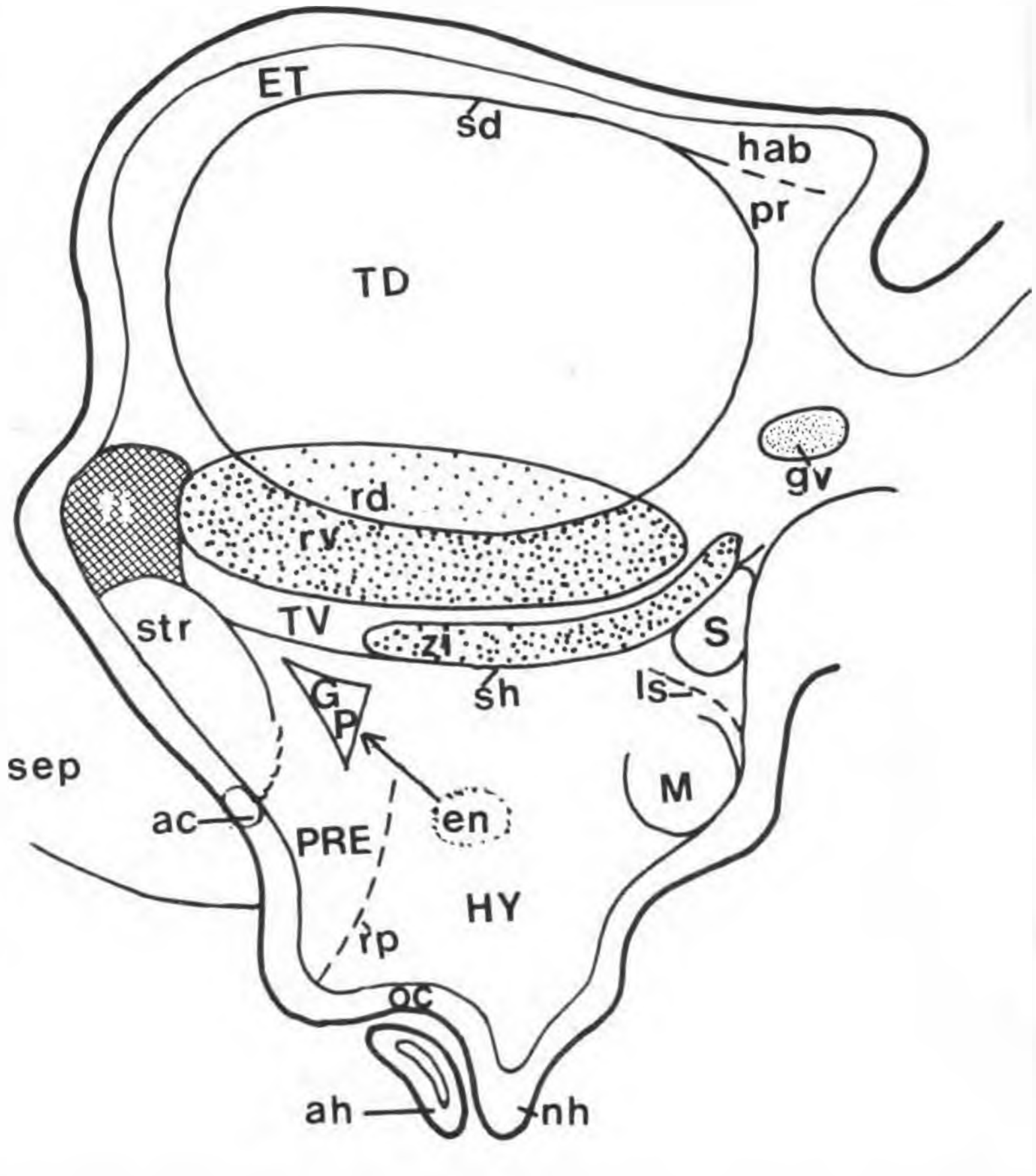

Figure 14.

week, the middle diencephalic sulcus has disappeared, while the ventral diencephalic sulcus is retained, and the dorsal diencephalic sulcus has just appeared. Between the 8th and 11th weeks of human foetal development, in the region of the ventral diencephalic sulcus, the thalamus and hypothalamus are drawn close together, and the subthalamus is displaced laterally (Figs. 13 and 14). The subthalamus becomes flattened in its medial part in the 11th week, a very important feature in the ontogeny of the vertebrate diencephalon. The further development of the primate diencephalon is characterized by increasing predominance of the thalamus, and continued lateral displacement of the subthalamus.

The thalamus retains its identity throughout the ontogeny of the diencephalon. It is separated from the epithalamus by the dorsal diencephalic sulcus, and from the subthalamus by the middle diencephalic sulcus. The embryonic thalamus and epithalamus are laid down as longitudinal primordial cellular zones that extend rostrocaudally within the dorsal part of the diencephalon. The epithalamus is the most dorsal longitudinal zone, lying adjacent to the epithelial roof-plate, and running from the region dorsocaudal to the velum transversum to the caudal end of the epiphysis. The thalamus is a more voluminous cell zone extending from the velum transversum at the level of the interventricular foramen (of Monro) to the diencephalico-mesencephalic border. During foetal development, the thalamus becomes the most massive constituent of the diencephalon through increase both in wall thickness and in dorsoventral extent. Simultaneously with these growth processes, the original tubular pattern of the prosencephalon undergoes marked changes: this results in a broad zone of contiguity between the diencephalon and the telencephalon, characterized by a groove, the sulcus terminalis. Through this zone of contact, pass numerous fibre systems, for example, the internal capsule and various thalamic radiations.

TABLE 7

	TELENCEPHALON	THALAMUS
1. Median zone	rhinencephalon, comprising the septal area and olfactory lobes, including some parts of the hippocampus (Ammon's horn and indiseum griseum)	massa intermedia and periventricular grey of the third ventricle
2. Paramedian zone	limbic lobes, excluding the hippocampus, and including the insula of Reil and the orbital area of the frontal lobe joining the insula with the parolfactory area of Broca	a) n. centrum medianum and the crescentic complex of arcuate nuclei, e.g., nn. ventrales postero-medialis and postero-lateralis, and including the geniculate bodies b) nn. medialis dorsalis, paracentralis and centralis lateralis
3. Dorsolateral -posterior zone	main mass of the cerebral hemisphere, opercula and white matter of the corona radiata	lateral, lateral-posterior and pulvinar nuclei

These three zones are first clearly recognized in the thalamus of a human foetus of seven months, and become further differentiated into six nuclear groups up to the seventh postnatal month when there is a gradual gain in the caudal growth of the pulvinar, and an increase in the rostrocaudal diameter of the thalamus. Coincidentally, there is a gradual shift in relative position of n. geniculatus lateralis from a position dorsal to the plane of greatest transverse diameter at 13 weeks (80 mm.) into the ultimate position ventral to the greatest transverse diameter at 28 weeks (240 mm.), Fig. 12b. The displacement of n. geniculatus lateralis indicates not only the growth and caudal expansion of the lateral thalamic regions concomitant with the development of the parieto-occipital region of the cerebral hemispheres, but its phylogenetic development is also recapitulated in the ontogeny of the human thalamus.

In the fully developed brain, the definitive dorsal surface of the thalamus and epithalamus become hidden in the depths of the transverse cerebral fissure which lies ventral to the corpus callosum (Fig.13). The rostral part of this dorsal surface protrudes slightly into the transverse cerebral fissure as the anterior tubercle containing the anterior thalamic nuclei. The embryonic lateral surface of the thalamus lying caudally to the stalk of the cerebral hemispheres has become caudally situated, and displays the prominences of the pulvinar, and lateral and medial geniculate bodies.

In the embryonic development of nuclear masses in the thalamus and epithalamus, an external and an internal cellular plate or area are visible. In the epithalamus, the external cellular area becomes the lateral habenular nucleus, while the internal becomes the medial habenular plate. In the thalamus, the external cellular plate is the dorsal part of the lateral geniculate body, while its remnants merge with the internal cellular plate to form a diffuse matrix. Within this matrix, the nuclear masses of the thalamus are formed by growth, differentiation and condensation of cells, as well as of the neuropil in situ.

Yakovlev (1969) states that the thalamus conforms in its general configurations to those of the cerebral hemispheres and rhinencephalon (telencephalon) in having the same three cardinal zones of embryonic development: a median zone, a paramedian zone and a dorso-lateral/posterior zone. The relationship of these zones between the thalamus and telencephalon can be demonstrated as follows:

←

Further details of the embryology and cytoarchitectonic differentiation of the thalamic nuclei can be studied in Yakovlev's monograph (1969), and therefore, there is no need to describe the ontogeny of the primate thalamus in this study. However, it would be interesting to note that the ontogenetic development of the thalamus into three morphological zones which differentiate later into six distinct nuclear groups, is recapitulated phylogenetically in mammals, particularly in primates.

> The medial and paramedian zones, of the thalamus, together with the epithalamus and hypothalamus, which show full maturity in a human foetus of 13 to 16 weeks, appear to have a more advanced cytoarchitecture than the lateral and ventral regions of the thalamus in the Insectivora, Tupaioidea and lower prosimians. In these species, the midline and medial thalamic nuclei have already differentiated cyto- and myelo-architectonically further than the nuclei comprising the lateral thalamic regions. The thalamus of a newborn infant, and also during the first few years of postnatal life, compares quite favourably with the thalamus of higher prosimians, in which the lateral thalamic region has already been demarcated into dorsolateral, ventrolateral and posterior nuclear groups. The only exceptions in this phylogenetic recapitulation are:
>
> (a) the lateral and medial geniculate bodies attain their peak of embryonic development *before* the lateral thalamic region, e.g., in the eighth foetal month, although the lamination of n. geniculatus lateralis is contined further well into the first decade of postnatal life;
>
> (b) n. centrum medianum appears *earlier* in the ontogeny of the human thalamus, that is, it becomes better definable as a nucleus than nn. mediodorsalis and ventralis posterior.
>
> The reason for this earlier appearance of n. centrum medianum is not known, but it is possible that it arises from the migration of neuroblasts from the deeper layer to the superficial layer of the mantle zone in the diencephalic vesicle as observed in a six weeks' human embryo.

2. Phylogeny

(a) Phylogenetic Classification of the Thalamus

The terms 'phylogeny' and 'phylogenetic' are so extensively used in the literature on the comparative anatomy of the central nervous system that their true meaning is often confused and blurred. Therefore, the following discussion will attempt to clarify this comparison of terms. Comparative studies of tissues, organs and systems of primates used as common laboratory specimens, such as tree-shrew, bushbaby, monkey and chimpanzee, do not reveal any direct line of evolution from tree-shrew to man, although the monkey and chimpanzee do share a common ancestry with man. The structure and functions of the central nervous system of various living non-human primates today may be comparable with those of various ancestors in the direct lineage of man (? fossil hominids).

Until only recently, it has been generally accepted that the thalamus was divided phylogenetically into two main nuclear groups based on their accreted development in different periods of time. Such an understanding of that evolutionary process would make simpler an otherwise confusing complexity of thalamic classification. Thus, the thalamic nuclei are grouped under either paleothalamus or neothalamus. The paleothalamus consists of groups of nuclei that extend from the dorsal limit of the third ventricle to the subthalamus ventrally, and from the anterior thalamic nuclei to the habenula posteriorly, but they are, throughout these extensions, closely situated to the walls of the third ventricle. Such nuclear groups are as follows:

a. the anterior thalamic group - nn. anterodorsalis, anteromedialis and anteroventralis;

b. the midline thalamic group - nn, parataenialis, paraventricularis, rhomboidalis, reuniens and ventralis medialis, as well as the interanterior commissures;

c. the medial thalamic group - nn. mediodorsalis, centrum medianum, parafascicularis, paracentralis and centralis lateralis;

d. the habenular complex - nn. habenulares medialis and lateralis;

e. the posterior thalamic group - nn. limitans, suprageniculatus, tractus opticus, pretectalis, thalamicus posterior, commissuralis posterior and olivaris superior.

The neothalamus forms the greater part of the lateral region of the thalamus, and presents the maximal expansion of the more recently developed nuclei. This lateral thalamic region is more or less recently demarcated myeloarchitectonically from the medial nuclear groups of the thalamus. Such nuclei comprising the neothalamus are:

a. the dorsolateral thalamic group - nn. laterales dorsalis, intermedius and posterior, and the pulvinar;

b. the ventrolateral thalamic group - nn. ventrales anterior, lateralis, and posterior, and their subdivisions;

c. the metathalamus - n. geniculatus lateralis and n. geniculatus medialis.

There is yet another term for classifying thalamic nuclei - archithalamus; this term has been introduced by Chandler Elliott (1969). He maintains that the thalamus underwent three, not two, stages of phylogenetic development, like the cerebral cortex, striatum and cerebellum, that is, archi- —— paleo- —— neo-neural stages. However, these stages may represent only rough approximations as the corresponding stages may overlap or merge into one another to a considerable degree. Chandler Elliott appears to base his classification on that of Kuhlenbeck (1954) who puts this viewpoint forward more rigorously:

> "On the basis of my observations, I have reached the conclusions that, in the diencephalon the phylogenetically 'new' and 'old' connections as well as structural developments are inextricably commingled or amalgated in topographically identical neighbourhoods, so that it is not legitimate, in my opinion, to designate any griseum as 'new' or 'old', but at most as more or less differentiated."

This phylogenetic classification of thalamic nuclei should be first considered as to whether it can be more acceptable than the older classifications or not. The thalamic nuclei which have been previously classified as belonging either to the paleothalamus or to the neothalamus, are re-arranged on the basis of their primary, secondary or tertiary appearances in the vertebrate brain.

The archithalamus is defined by Chandler Elliott (1969) as the part of the thalamus which developed first in animals possessing a rudimentary or very primitive cortex, rudimentary limbs and a very highly developed olfactory system, e.g., fish of all classes, extinct or living. The archithalamus still persists in primates only as a small, diffuse collection of ill-defined nuclei, but there are some well developed and phylogenetically progressive nuclei scattered among the more recently developed or 'modern' nuclei. Such nuclei constituting the archithalamus are:

a. Midline thalamic nuclei,
b. Intralaminar nuclei,
c. Nn. centrum medianum and parafascicularis,
d. N. reticularis,
e. N. anteroventralis.

Of these five groupings, only the midline thalamic nuclei can be correctly classified as archithalamic components, because they have retained strong connections with the ancient parts of the brain, particularly the archipallium (hippocampus) that deals with visceral control, with the archistriatum (part of the basal ganglia) for primitive motor control, with the paleocortex for somatovisceral or somato-olfactory functions, and with the rhinencephalon for olfactovisceral connections. The midline nuclei have also connections with the orbital gyri of the frontal lobe and the diffuse reticular formation (Starzl and Magoun, 1951).. Kuhlenbeck (1954) believes that the midline nuclei found in their present form are only comparatively recent derivations of a more primitive median nuclear mass which evolved in gradual gradations into true medial nuclei. But, ~~as~~ their functions are still obscure, and their structures become more and more poorly ~~ill~~-defined as one ascends the mammalian scale through primates to man.

The intralaminar nuclei cannot be archithalamic in the true sense, since they form a sort of delimitation between the medial and lateral nuclear masses. Furthermore, they are not regressive, but remain more or less stable throughout the mammalian orders, e.g., nn. paracentralis and centralis lateralis, or undergo such a progressive increase in size and complexity in fibre connections with other parts of the thalamus and other subcortical areas, e.g., nn. centrum medianum and parafascicularis.

Since n. centrum medianum makes its appearance much later in the phylogenetic history of the thalamus than the intralaminar nuclei and n. parafascicularis, it cannot be accepted as an archithalamic structure. Therefore, it may belong to the class of neothalamic structures.

N. reticularis cannot either be classified as an archithalamic nucleus because it belongs ontogenetically to the subthalamus. It has been found to have no cortical connections, but it is involved with the ascending reticular system, non-specific and specific thalamocortical projections. N.reticularis is, at least, a palaeothalamic structure, as it has connections with other palaeothalamic nuclei.

N. anteroventralis has strong connections with the mamillary region which itself is a more recent development in the phylogeny of the vertebrate hypothalamus. Therefore, it does not fit in the description for the archithalamus. Its 'partners', nn. anteromedialis and anterodorsalis which have closer connections with the olfactory system, appear to be more suited as archithalamic components, while n. anteroventralis is essentially a paleothalamic nucleus having discrete fibre projections to the cingular cortex and other parts of the limbic system.

The appearance of well-developed limbs and senses requiring more complicated co-ordination and correlation in amphibians and reptiles, served as a prerequisite for the development of a secondary phylogenetic character of the thalamus - the paleothalamus. In that newly developed region, each of the special senses other than olfaction, i.e., vision, audition and somesthetic sensory senses, acquired a 'special' nucleus of its own where information from the periphery of the organism could be integrated into concepts. As a result of evolutionary domination by the cerebral cortex, these nuclei have become relay stations for the sensory pathways to the cerebral cortex, though they organize beforehand the incoming impulses in a spatial fashion to their destinations. Such nuclei are nn. ventrales posterolateralis, posteromedialis and posteroinferioris, and the geniculate bodies, which serve cranial and somatic sensory modalities; n. ventralis lateralis, a cerebellar relay nucleus, and doubtfully, the anterior nuclei as put forward by Chandler Elliott.

None of these thalamic nuclei should be classified as paleothalamic structures, except n. anteroventralis as already discussed above, although it is acknowledged that they developed much earlier than other so-called neothalamic nuclei.
These nuclei should be called earlier neothalamic nuclei, because they developed concomitantly with the increasing use of limbs, and with the growing functional importance of visual and

auditory senses in terrestrial animals. In reptiles and birds, where the cerebellum shows a higher degree of differentiation, such a connection with the thalamus is still rudimentary or of a minor importance, because the neoneural components of the cerebello-cerebral system have not been fully developed. Moreover, n. ventralis lateralis is not entirely a separate entity in these animals, being a part of the ventrolateral thalamic mass lying lateral to n. dorsolateralis anterior. In respect to nn. ventrales posterolateralis and posteromedialis, there may be homologous structures in reptilian and avian thalami, i.e., nn. rotundus and dorsolateralis anterior, that subserve gustatory and somatic sensations. The ventroposterior nucleus itself is a relatively small and underdeveloped structure even in lower mammals. The geniculate bodies are also simple and undifferentiated, but the lateral geniculate body is divided into dorsal and ventral parts, each part having different visual functions.

To the 'neothalamus' of Chandler Elliott belong nn. mediodorsalis, laterales dorsalis and posterior, pulvinaris and ventralis anterior; these nuclei are associational nuclei in the physiological sense. N. mediodorsalis is essentially a neothalamic nucleus, because it is an integrative centre for somatic and visceral impulses from the hypothalamus and limbic system, and it projects to the prefrontal areas of the cerebral cortex. Therefore, n. mediodorsalis is considered by many workers as a relay nucleus of primary importance, not one of the thalamic nuclei which are actually connected with association areas of the cerebral cortex. Moreover, it has such features that qualify it as a neothalamic, not paleothalamic, nucleus, e.g., a progressive increase in size and nuclear differentiation in primates. N. ventralis anterior, though correctly classified as neothalamic, is not entirely an associational nucleus, because it has yet to be proved experimentally that it has a cortical projection, although its magnocellular portion has been found to project to the anterior insular cortex that lies inferior to Area 4 in the frontal lobe (Carpenter 1967). The dorsolateral thalamic nuclei, and their posterior extension, the pulvinar, are to be considered as later neothalamic structures, as these nuclei developed comparatively late in the evolution of the primate diencephalon. They have fibre projections to the association areas of the parieto-temporo-occipital regions. N. ventralis lateralis is a phyogenetically younger, or a later phylogenetically differentiated thalamic structure as Kuhlenbeck calls it, than either n. ventralis anterior or n. ventralis posterior, because of the appearance of the dentate nucleus in the neocerebellum and of the small-celled element in the red nucleus in primates.

The posterior thalamic nuclei are difficult to classify either as paleothalamic or archithalamic structures, although they are more prominent and well-formed in submammalian forms, in which nn. pretectalis and thalamicus posterior are the most conspicuous features of the posterior thalamic region. As these nuclei do not have cortical projections, they are essentially archithalamic or earlier paleothalamic in character.

Finally, the concept of classifying the thalamic nuclei, according to their developmental periods, should not be based rigidly on the phylogenetic differentiation of the thalamus throughout the vertebrate scale. The thalamic nuclei can still be grouped as paleothalamic or neothalamic structures based on the eventual development of the special sensory organs, but the idea of using the term archithalamus cannot be disregarded at all. A table giving the phylogenetic 'ages' of the thalamic nuclei is given as follows:

TABLE 8

Archithalamus	Paleothalamus	Neothalamus
n. anterodorsalis	n. anteroventralis	
n. anteromedialis		
n. paraventricularis	? n. centralis medialis	n. mediodorsalis
n. parataenialis	? n. medioventralis	n. centrum medianum
n. rhomboideus	n. parafascicularis	
n. reuniens	n. paracentralis	
n. submedius	n. centralis lateralis	
n. limitans	? n. suprageniculatus	n. lateralis dorsalis
n. pretectalis	? n. tractus opticus	n. lateralis posterior
n. thalamicus posterior		n. pulvinaris
n. commisuralis posterior		
? n. olivaris superior		
	n. ventralis anterior	n. ventralis anterior
	n. ventralis posterior (lateral and medial)	n. ventralis lateralis
		n. ventralis postero-inferioris
	n. geniculatus lateralis	n. geniculatus lateralis (both dorsal and ventral parts)
	n. geniculatus medialis	n. geniculatus medialis (both magnocellular and parvocellular parts)

(b) Morphological Differentiation of the Diencephon

(i) Epithalamus and Thalamus

While the pattern of the epithalamus remains essentially the same throughout phylogeny, the thalamus undergoes profound changes. The tracing of thalamic homologues throughout the vertebrate series is, thus, a difficult problem.

In most primitive vertebrates, e.g., cyclostomes, the thalamus is little more than a slender band of nervous tissue running dorsoventrally and linking up the epithalamus above with the hypothalamus below. The epithalamus is comprised of the habenula and pineal gland. The hypothalamus forms a conspicuous swelling in the floor and lower part of the lateral wall of the third ventricle. It receives rich contributions of fibres from the telencephalon which are olfactory in function.

In fish, an increasing proportion of somatic impulses enter the dorsal diencephalic part which shows some differentiation. Thus, there develops a part of the diencephalon, the thalamus, which has no direct connection with the olfactory system. It receives somatic impulses mainly through the mesencephalic tectum, but a forerunner of the lemniscal system of sensory tracts from lower levels is present. The thalamus starts to extend its influence rostrad into the sphere of the telencephalon, invading a territory which was once the domain of the olfactory system alone. A somatic area arises in the telencephalon, and is continuous rostrally with the lateral olfactory area of the forebrain. This somatic area is the precursor of the somatic part of the corpus striatum of higher forms. The fiber connections between the thalamus and somatic area of the telencephalon are the forerunners of the striothalamic and thalamostriate connections. The thalamus of more specialized fish, e.g. teleosts (bony fish), shows a far more advanced degree of differentiation.

At the amphibian stage, the thalamus ought more properly to be called the dorsal thalamus to distinguish it from the ventral thalamus. The dorsal thalamus is greatly increased in size in amphibians. Medial to the lateral geniculate body lies a mass of cells which may represent the beginning of a differentiated portion of the dorsal thalamus. This differentiated portion is the forerunner of the ventrolateral thalamic mass of higher forms;

it receives fibres from lower centres, probably ascending secondary trigeminal fibres. Further it sends fibres to the dorsolateral wall of the telencephalon, thus initiating the earliest direct fibre projection from thalamus to telencephalon. The central thalamus is smaller, and the hypothalamus is not nearly as well developed as the dorsal thalamus. The epithalamus is still prominent and shows more or less the same features as in lower forms.

In *reptiles*, the thalamus is further elaborated and has increased considerably in size and nuclear complexity. It is differentiated into fairly well defined nuclear masses, among which are *nuclei dorsolateralis anterior* and *rotundus* that make up the bulk of the dorsal thalamus. Both nuclei are composed of similar cell types, and are not clearly separated from each other; both are connected with somatic areas in the lateral part of the telencephalon. They receive afferent impulses from the mesencephalic tectum, from n. rotundus, and from the lemniscal system. N. rotundus is a distinctive element in the reptilian thalamus. It certainly may be homologized with a part of the ventral nuclear group in the mammalian thalamus, possibly n. mediodorsalis, n. medioventralis or n. submedius. In reptiles, n. rotundus appears to occupy the centre of the thalamus, but in birds, it undergoes a ventrolateral displacement. N. mediodorsalis of mammals seems to arise in the same locus within the thalamic primordium, and therefore, may be regarded as a homologue of the reptilian n. rotundus rather than of the other nuclei. But the large size and marked differentiation of n. rotundus are intimately associated with the relatively immense size of the striatum in reptiles and birds. Therefore, it would not be justified to expect its homologue in the mammalian thalamus to bear any resemblance to it in shape and proportions, since the relative development of the striatum is very different in reptiles and mammals.

N. dorsolateralis anterior of reptiles represents probably n. anteroventralis of the mammalian thalamus. The relationship of this nucleus to the hypothalamus is not clear as it is in higher vertebrates via the mamillo-thalamic system. At the tectothalamic junction near the dorsal surface of the thalamus, a pretectal nucleus is found; it is related closely to the optic system, and from it afferent fibres descend to the mesencephalic tegmentum. It is apparently the homologue of the pretectal area of the mammalian thalamus.

All the major nuclear masses found in the thalamus of reptiles can be demonstrated in birds, but there is an increase in the number of nuclei and their associated fibre systems. The positions of specific nuclei differ also from those of their homologues in reptiles; thus there is a noticeable ventral shifting of tectal regions, and corresponding changes in position of tectothalamic fibre bundles. Optic, auditory and somesthetic sensory impulses reach the thalamus by way of the tectum through the well developed tectothalamic fibre bundles. The other dorsal thalamic nuclei may be interpreted as differentiations of the cellular masses surrounding n. rotundus in a capsule-like fashion.

The following is a summary of diencephalic homologies between reptiles and birds on the one hand, and mammals on the other hand:

TABLE 9:

Reptiles and Birds	Mammals
n. dorsolateralis anterior	n. anteroventralis
n. rotundus	n. mediodorsalis or n. medioventralis or n. submedius
cells surrounding n. rotundus on the ventromedial, lateral and ventral sides	nn. ventralis medialis, lateralis and geniculatus medialis
n. geniculatus lateralis	n. geniculatus lateralis, pars dorsalis

In mammals, the main sensory nucleus is the ventral nucleus which forms the terminus for medial, spinal and trigeminal lemniscal systems. As the ventral nucleus becomes differentiated into many functionally distinct areas, these parts comprise lower functional levels of the thalamus concerned mainly with the reception of sensory impulses from the hypothalamus. The mamillothalamic tract is a very well formed bundle in mammals, and attains its most complete definition in these forms. The less specialized part of the periventricular system persists as a more diffuse tract of fibres and cells, linking up the hypothalamus with the midline nuclear group of the thalamus. The pretectal area is best developed only in primitive mammals.

A distinctive feature of the mammalian thalamus is the development of an upper level (topographically and functionally speaking) which is not found in lower vertebrates. This occupies the dorsal part of the thalamus above the ventral thalamic nucleus, from which it is more or less separated by the intralaminar nuclei. The upper level of the thalamus comprises the lateral nuclear group and n. mediodorsalis. These structures receive no significant afferent connections from lower sensory centres, except by relays through the lower levels of the thalamus. They are related rather to the 'association areas' of the cerebral cortex, whereas the nuclei of lower thalamic levels are connected with the sensory projection areas. The nuclei of the upper thalamic level show a progressive increase in relative size and elaboration in higher mammals, particularly in the primates.

(ii.) Subthalamus

The longitudinal cellular zones of the subthalamus and hypothalamus extend from the telencephalico-diencephalic boundary at the interventricular foramen to the rostral convexity of the mesencephalon. Ventrally, the subthalamus is bounded by the ventral diencephalic sulcus and dorsally by the middle diencephalic sulcus. It is comparatively large during early phylogenetic stages, but in time, suffers great reduction, coincident with the expansion of the thalamus. The cellular masses of the subthalamus develop into a thin sheet which covers the inferolateral aspect of the thalamus. A medial portion of this cellular layer becomes the zona incerta while the lateral portion develops into n. reticularis. Another portion of the subthalamus migrates caudally to become the pregeniculate nucleus (ventral part of the lateral geniculate body). N. entopeduncularis migrates laterally and dorsally from the dorsolateral hypothalamic anlage to lie in the dorsal part of the diencephalon. N. subthalamicus, also a derivative of the primitive dorsolateral hypothalamic region, eventually moves laterally to become the chief component of the subthalamus. (Figs. 13 and 14.)

(iii) Hypothalamus

The rostral boundary of the hypothalamus is the hypothalamic or ventral diencephalic sulcus, while its caudal boundary is formed by the upper end of the midbrain. An inconstant branch of the lateral infundibular sulcus divides the hypothalamic region into dorsal and ventral parts. The preoptic region is separated from the rest of the hypothalamus by an intra-encephalic sulcus which later becomes the preoptic recess.

In some bony fish and amphibians, vague anlagen of individual nuclei corresponding to those of higher vertebrates can be detected. But generally speaking, in these lower forms, the entire hypothalamus is a relatively undifferentiated primordium. In mammals, this primordial region gives rise to n. subthalamicus and a part of the globus pallidus, as well as to the preoptic, paraventricular and other hypothalamic nuclei, including the mamillary bodies. Spatz (1921, 1925) was the first to provide evidence that the entire globus pallidus is an ontogenetic derivative of the hypothalamus, in spite of the conventional view that the globus pallidus is a telencephalic structure, developing as a part of the striatum. Kuhlenbeck (1949) supports this view of Spatz. In lower vertebrates, cells from the ventral thalamic region and hypothalamus migrate into the stalk of the hemispheres; they merge with the basal cell masses of the telencephalon to form a single cellular mass, the massa cellularis reuniens, which is divided into a superior and an inferior part. The superior part, originating from the ventral thalamus, becomes the nucleus reticularis (pars dorsalis). The inferior part, of hypothalamic origin, gives rise to the bed nucleus of the stria terminalis, and to the anterior entopeduncular stalk in reptiles (Crosby and Woodburne 1940). In mammals, the stalk of the hemispheres is enlarged, and the inferior part of the massa cellularis reuniens becomes extensive, thus contributing to the formation of the globus pallidus. Hence n. entopeduncularis may have split off from the globus pallidus during the phylogenesis of the subthalamus, and therefore, these two structures are essentially dorsolateral hypothalamic derivatives (Kuhlenbeck 1949).

The reptilian hypothalamus displays a stage of differentiation intermediate between those of amphibians and of mammals. The fairly advanced differentiation of the avian hypothalamus is somewhat aberrant in type, but is related closely to the reptilian pattern.

The concept of the telencephalo-diencephalon is emphasized by Kuhlenbeck (1949) as the relationship of the preoptic region to the other parts of the hypothalamus can be clearly shown. In the conventional subdivision employed by the Basel Nomina Anatomica (B.N.A.), the telencephalo-diencephalic boundary is drawn from the velum transversum to the chiasmatic ridge, and the preoptic region is included in the telencephalon medium. It will be seen that the unevaginated part of the cerebral hemispheres, that is especially well developed in fish and amphibians, but remains rudimentary in cyclostomes and in higher vertebrates, does not include the preoptic area, and lies only dorsal and rostral to the anterior commissure. Most investigators, particularly Le Gros Clark (1940), agree that from the morphological standpoint, the preoptic region cannot be separated from the hypothalamus. This is obvious if the development of the fundamental longitudinal zones is considered. In this regard, the B.N.A. terminology is obsolete.

SUMMARY

As was stated above, a clear-cut diencephalic zonal pattern is a conspicuous but transitory feature during the ontogeny of higher vertebrates. The limiting sulci may show certain variations and distortions. The accessory sulci which extend from the mesencephalon to the diencephalon, and a furrow which originates in the region of the developing posterior commissure, may place obstacles to ontogenetic and phylogenetic classifications of the vertebrate diencephalon. The diencephalon of mammals, particularly of man and non-human primates, differs so greatly from the diencephalon of other vertebrates that a comparison based on adult stages alone presents insurmountable difficulties. During early ontogeny, the mammalian diencephalon passes through developmental stages, some of which bear close comparison with the structure of the diencephalon of adult fish and amphibians. Such ontogenetic events may be regarded as examples of recapitulative phenomena.

2. Gross Anatomy of the Prosimian and Tupaioid Diencephalon

The following is a summary of external features of the thalamus and other constituents of the diencephalon.

(a) Epithalamus

The epithalamus forms the most dorsal part of the diencephalon. It includes the pineal body, the habenular trigone, the stria medullaris and the posterior commissure.

The pineal body (corpus pineale) in all prosimians, and in tree-shrews, is an unpaired cone-shaped structure which projects over the midbrain and lies in a groove, the intercollicular sulcus, between the two superior colliculi. The pineal body is attached by a median stalk whose base is divided by the pineal recess, so that its dorsal portion is attached to the habenular commissure, and its ventral portion to the posterior commissure. The habenular trigone as seen from above, is a rather depressed triangular area rostral to the superior colliculus on each side. It contains a fusiform mass of cells, the habenular nuclei, that are connected from one side to the other by the habenular commissure. The stria medullaris can be identified as a white fibrous strand passing caudally to the region of the epiphysis. In higher primates, it is relatively narrow, in keeping with a reduction of the habenular region.

(b) The Thalamus

The thalamus is generally an ovoid mass of grey matter forming the largest subdivision of the diencephalon. In all primates, as well as the tree shrews, the thalamus is completely obscured from view by the cerebral hemispheres and cerebellum. In order to expose the dorsal aspect of the thalamus, the overhanging cortex has to be removed, followed by the corpus callosum, the columns of the fornix and tela chorioidea with the choroid plexuses of the lateral ventricle. The two thalami appear as relatively large, rather oval structures whose caudal ends diverge from each other. Between these ends, is the narrow cavity of the dorsal part of the third ventricle. Demarcating the medial from the dorsal surface of the thalamus is the taenia thalami, to which is attached the ependymal roof of the third ventricle. The sloping dorsal surface of the thalamus is divided into two parts, a medial and a lateral, by a shallow, diagonal groove, which contains the stria terminalis and thalamostriate vein. This groove lies between the thalamus and caudate nucleus dorso-lateral to it. The medial part of the dorsal surface of the thalamus forms part of the floor of the transverse cerebral fissure. Both columns of the fornix which form the rostral margin of the interventricular foramen, mark rostrally the boundary of the lateral ventricles. At the rostral end of the lateral portion of the thalamus and projecting into the body of the lateral ventricle lateral to the fornix, is a small rostrocaudal protuberance, the *anterior tubercle* of the thalamus which is not very prominent in lower primates. In larger prosimians, e.g. lemurs and galagos, at the caudal end of the thalamus, a rather conspicuous protrusion, the pulvinar, projects above and laterally to the superior colliculus. Immediately beneath the pulvinar, on the ventral surface of the thalamus, between the cerebral peduncle and superior colliculus, is the medial geniculate body. The lateral geniculate body is a more or less flattened eminence lying dorsolaterally to the latter structure. The extent to which the pulvinar conceals lateral geniculate body from view varies among the prosimians, but it progresses as the primate scale is ascended, owing to the gradual posterior expansion of the thalamus.

The *medial* surface of the thalamus is covered with the ependyma of the third ventricle except where the large interthalamic adhesion unites the two thalami across the median plane. In all primates except man, the interthalamic adhesion extends through the whole length of the thalamus. Lying below it is the shallow hypothalamic sulcus which separates the thalamus from the hypothalamus.

The *lateral* surface of the thalamus is entirely covered by the external medullary lamina, a sheet of myelinated fibres lying parallel to the internal capsule.

The thalamus of the Lemuroidea and Lorisoidea appears to be much larger than that of the Tupaioidea. The interthalamic adhesion is massive and extensive. In *Microcebus murinus*, the pulvinar is seen only as a small development from the caudal part of the lateral thalamic area.

(c) The Metathalamus

In *Tupaia* species, the lateral geniculate body lies beneath the optic tract; therefore, little of it is seen from the external surface. The medial geniculate body is an oval tubercle which, unlike that of higher primates, lies immediately caudal to the ventral pole of the lateral geniculate body, and on the side of the midbrain rostrolateral to the inferior colliculus. Dorsomedially to the lateral geniculate body, the dorsal surface of the thalamus projects caudally to form a rather small and flattened convexity which corresponds topographically to the pulvinar of primates. Further rostrally is a faint protuberance, which may be regarded as the dorsal surface of n. lateralis dorsalis, but not as the anterior tubercle of higher forms, since the anterior nuclei of the Tupaioidea are situated more deeply in the thalamic substance. The dorsal surface of the tupaioid thalamus is generally broader in front than at its caudal extremity, because the pulvinar is only a very small and inconspicuous formation.

In the Lemuroidea and Lorisoidea, the lateral geniculate body is pushed farther towards the ventral surface of the thalamus by the expanding pulvinar which forms the posteromedial angle of the thalamus. The lateral geniculate body is overlapped by the temporal lobe of the cerebral hemisphere; therefore, it is not well observed from the ventral aspect. The medial geniculate body is better seen from this aspect, as it is displaced towards a more medial position by the lateral geniculate body, and as the medial border of the cerebral hemisphere here deviates more laterally. In *Microcebus murinus*, the outline of the lateral geniculate body is not strongly indicated, and the optic tract passes dorsad and caudad to reach its ventral pole. The medial geniculate body is conspicuous, more so even than in *Tupaia* spp. and *Galago demidovii*;

it forms a prominent and circumscribed tubercle projecting ventrad on the lateral aspect of the cerebral peduncle.

(d) The Subthalamus

This subdivision of the diencephalon is not visible from the exterior, since it lies deep in the brain substance between the mesencephalon caudally, the hypothalamus rostroventrally and the thalamus rostrodorsally.

(e) The Hypothalamus

In all primates, and in the Tupaioidea, the hypothalamus occupies the most ventral part of the diencephalon. In the median sagittal plane, the narrow slit-like third ventricle divides it into symmetrical halves. A shallow but well-defined hypothalamic sulcus demarcates it from the thalamus dorsal to it. Laterally, the subthalamus lies in relation to the hypothalamus. Rostrally, the hypothalamus overlaps the preoptic area; any separation between them is largely arbitrary. The hypothalamus is usually regarded as beginning rostral to the mesencephalic tegmentum at the caudal level behind the mamillary bodies. It stretches to the rostral pole of the region of the optic chiasma, where it extends bending the optic chiasma and optic tract to the free ventral surface of the brain. Medially, the hypothalamus lines the walls of the ventral part of the third ventricle, being separated from it only by a thin layer of ependyma.

Superficially, the position of the hypothalamus is roughly indicated on the base of the brain by a diamond-shaped area bounded rostrally by the optic chiasma and caudally by the converging cerebral peduncles. Within these limits lie the rounded, paired mamillary bodies caudally, and the club- or cone-shaped infundibulum rostrally, both being important parts of the hypothalamus itself. The infundibulum has very intimate relations, structurally and functionally, with the neurohypophysis. The optic chiasma marks the site where the supraoptic and preoptic regions are located.

In prosimians, the gross anatomy and relations of the hypothalamus differ slightly from those of higher primates. In Tupaia spp. and Microcebus murinus, the mamillary body appears to be a single downgrowth of the caudal hypothalamic region, and does not protrude much on the free surface of the brain. In large prosimians, the mamillary body is as large and clearly bilobed as that of higher primates. The preoptic region appears to be compressed between the basal telencephalic areas and the rostral hypothalamic region; it runs such a very short distance rostrocaudally that it seems often to merge insensibly with the supraoptic region. For this reason, it may be difficult to define where the preoptic region ends and the hypothalamus begins.

The vascular supply of the diencephalon will not be dealt with here. It is described in Feremutsch's monograph on the primate thalamus (1963, pp. 6/15-17). Generally, the blood supply of the diencephalon of primates does not differ much from what is described for the human brain.

The fibre connections of the primate diencephalon and thalamic radiations have been described so extensively in the literature that they will need scarcely any discussion here. Wherever there are deviations from the usual myeloarchitectural pattern, these will be mentioned in the following chapters.

CHAPTER 5

THE THALAMUS: ANTERIOR NUCLEAR GROUP

The anterior nuclear group in all the specimens studied is divided into three parts, namely, nn. anterodorsalis, anteromedialis and anteroventralis. In addition, there are two internuclear commissures, commissurae interanterodorsalis and interanteromedialis which are described with their respective connecting nuclei.

1. *Nucleus anterodorsalis (AD) and nucleus interanterodorsalis (IAD)* (Plates 1 - 49)

(1) *INSECTIVORA*

Macroscelidoidea

Elephantulus myurus

N. anterodorsalis (Figs. 33 & 34) is the largest of the three anterior nuclei in this species. It can be readily distinguished from the adjoining medial and lateral nuclei by its large, deep-staining cells and rich myelin content. In the rostral region of the thalamus, it is triangular in shape; caudally, it is at first wedge-shaped, and then rounded or ovoid. N. anterodorsalis extends caudally from the level of the caudal extremity of the anterior commissure to the level of the optic chiasma where it is represented by a few large cells scattered about the mamillothalamic tract. Unlike its homologue in primates, it does not reach the dorsal surface of the thalamus. N. anterodorsalis is connected with its fellow by an extensive, thick and well defined bundle of fibres, the commissure of n. anterodorsalis. Its bed nucleus, *n. interanterodorsalis*, is represented by smaller, spindle-shaped and very deeply staining cells that are disposed horizontally in the region of the commissure. At the level of this bed nucleus, n. anterodorsalis is pierced by numerous bundles of fibres from the mamillothalamic tract, the preoptic area and the lateral and the lateral corticohabenular tract. These fibres form a thick network of finely myelinated fibres throughout n. anterodorsalis.

(2) TUPAIOIDEA

N. anterodorsalis of *Tupaia* spp. (Figs. 43 & 44) is much smaller and more dorsally situated in the thalamic region, and is intermediate in size between those of Insectivora and Prosimii. It does not extend as far rostrally as in primates; its rostral extremity is caudal to n. anteroventralis. N. anterodorsalis is a thin band of medium-sized cells (15 x 10 μ) covering the dorsal aspect of n. anteroventralis beneath the fibrous area of the stria medullaris. Caudally, n. anterodorsalis is roughly ovoid in cross-section, and comes to lie more medially, on the dorsal surface of n. anteroventralis.

There, n. anterodorsalis is related medially to the dorsolateral nuclei of the thalamus, laterally to n. parataenialis rostrally, to n. paraventricularis caudally and to the oral part of n. mediodorsalis further caudally. There, n. anterodorsalis becomes reduced in size, and is replaced by n. lateralis dorsalis. N. interanterodorsalis (Figs. 43 and 44) is a small and well developed structure. It is identified in myelin-stained sections as a thin fibrous structure running medioventrally from n. anterodorsalis, along the dorsal border of n. anteromedialis, to cross the midline ventral to n. paraventricularis. The cells of n. interanterodorsalis are smaller (12 x 7 μ); ~~They are~~ and less darkly staining and more fusiform than those of n. anterodorsalis; they are packed closely together in two or three rows with their long axes directed obliquely to the dorsal surface of the thalamus.

Moreover n. interanterodorsalis has a longer rostrocaudal extent than n. interanteromedialis; it disappears just before n. anterodorsalis is replaced by n. lateralis dorsalis.

(3) PROSIMII

(a) Lemuroidea

N. anterodorsalis (Figs. 53 & 54; 61-64; 72-74) is the smallest of the three anterior nuclei, and shows features that distinguish it from the other two nuclei. In the lemuroids, n. anterodorsalis is a crescentic structure which covers the dorsomedial surface, of n. anteroventralis, and lies just beneath the lamina affixa. In *Lemur catta*, the medial point of n. anterodorsalis dips further ventrally into the midline nuclear region than in other lemuroids. In *Lepilemur* and *Microcebus murinus*, n. anterodorsalis is a very long, almost flattened crescent-shaped nucleus covering the whole surface of n. anteroventralis. In all lemurs, n. anterodorsalis is at its widest at the level of the rostral pole of n. mediodorsalis, then reduces in size and disappears slightly caudal to n. anteromedialis. The cells of n. anterodorsalis are generally small (14 x9/$^{\mu}$), stain darkly and are spindle-shaped with their long axes directed dorsoventrally. N. anterodorsalis is well connected with its fellow by a thick, fibrous commissure, commissura

eranterodorsalis, across the midline. The cells of n. interanterodorsalis gs. 53 & 54, 62, 73 & 74) are of the same size as those of n. anterodorsalis.

(b) Lorisoidea

(i) Lorisidae

Perodicticus potto

N. anterodorsalis (Figs. 87 & 88) remains comparatively small, being less conspicuous than in other prosimians. At its rostral pole, n. anterodorsalis is more ovoid than crescentic in shape, but caudalwards, it changes into a flattened, cap-like structure lying beneath the dorsal surface of the thalamus. There, it deviates from its usual relationships with nn. anteroventralis and anteromedialis by lying almost entirely on the dorsolateral, not dorsomedial, surface of the former nucleus with hardly any contact with n. anteromedialis. Moreover, N. anterodorsalis extends for a shorter distance rostrocaudally than it does in other prosimians; it disappears at the level of the rostral pole of n. mediodorsalis, where it is replaced by n. lateralis dorsalis. The cells of n. anterodorsalis are small, fusiform, deeply staining and rather compactly arranged, and not much different in these, as well as other, characteristics from those of the Tupaioidea and Galagidae. The interanterodorsal commissure extends ventromedially from n. anterodorsalis between nn. parataenialis and paraventricularis medially and n. anteromedialis laterally. The cells of n. interanterodorsalis (Figs.87 and 88) are smaller and more darkly staining than those of n. anterodorsalis; their long axes are aligned along the dorsolateral extension of the internal medullary lamina.

(ii) Galagidae

N. anterodorsalis (Figs. 97-100; 107 & 108) is again the smallest of the three anterior nuclei. It is further reduced than in other prosimians or in the Tupaioidea. It is also a crescent-shaped structure that lies on the dorsomedial surface of n. anteroventralis. N. anterodorsalis reaches its widest diameter at the level of the middle region of n. anteromedialis. Caudally it becomes gradually smaller until it ends slightly caudal to n. anteroventralis at the level of the rostral pole of n. ventralis lateralis.

N. anterodorsalis is more prominent in size in Galago crassicaudatus; it is a triangular shaped structure, wedged between n. anteroventralis dorsally and the stria medullaris medially. In Galago demidovii, n. anterodorsalis has more or less similar characteristics to those in Galago senegalensis, but it has a short, fat, comma-shaped form whose tail stretches over the dorsolateral surface of n. anteroventralis, whereas in Galago crassicaudatus, the whole nucleus forms a very thin layer of cells that covers completely the dorsal surface of n. anteroventralis. The cells of n. anterodorsalis in all *Galago* specimens are generally small (14 x 9 $/^{u}$), round or oval, and very in staining intensity, from very dark in *Galago senegalensis* to rather light in *Galago demidovii*.

In *Galago senegalensis*, n. anterodorsalis appears to consist of two distinctive groups of cells; one group is medially situated, and may be the main body of the nucleus. Its cells are more lightly staining and less compactly packed than those of the lateral group.

N. interanterodorsalis (Figs. 99 & 100; 107 & 108) is well formed in all *Galago* specimens. It is better developed than n. interanteromedialis, although the latter nucleus has a longer caudal extent. N. interanterodorsalis has cells with almost identical characteristics to those in other prosimians (12 x 9 $/^{u}$).

It is situated between n. paraventricularis dorsally and n. rhomboidalis ventrally, which replaces it when the latter nucleus expands ventrally towards n. centralis medialis.

(4) ANTHROPOIDEA

(a) Cercopithecidae
Cercopithecus aethiops

N. anterodorsalis (Figs. 129-131) is a small conspicuous structure lying on the dorsal surface of n. anteroventralis. **From the latter, it is demarcated clearly at the level of the rostral end of n. mediodorsalis. Caudally, it assumes a longish,** cap like form related ventrolaterally to n. anteromedialis. It extends caudally, as a tail-like projection, to the rostral pole of n. lateralis dorsalis. The cells of n. anterodorsalis are slightly larger than those in the prosimians (20 x 12 $/^{u}$), ovoid in shape and stain well, but a trifle more deeply than those of the other two anterior nuclei.

N. anterodorsalis is well surrounded by the fibres of the stratum zonale and by the dorsomedial component of the internal medullary lamina. Fine myelinated fibres traverse it dorsoventrally, and form the mamillothalamic tract. The interanterodorsal commissure apparently does not exist in the vervet monkey.

(b) Hominidae

Homo sapiens

N. anterodorsalis (Figs.129-130) is a very thin, indistinct band of large, deeply staining and fusiform cells that lie on the medial border of n. anteroventralis. It does not extend, like that of other primates, over the dorsomedial angle of the latter nucleus to participate in the formation of the anterior tubercle.

Discussion on n. anterodorsalis

Of all the Insectivora, Tupaioidea and Primates studied here, it is only in the family Macroscelididae that n. anterodorsalis is unusually large, its size exceeding those of nn. anteromedialis and anteroventralis put together. In other families of Insectivora, n. anterodorsalis is so insignificant that identification and demarcation from the other two anterior nuclei are difficult. Le Gros Clark (1929) pointed out that this remarkable macroscelidid development is not to be regarded as a primitive mammalian characteristic, because the poor definition or near absence of n. anterodorsalis in Erinaceus (hedgehog) and other lipotyphlan insectivores, as well as in reptiles, suggests rather that its development is a mammalian character, which becomes specialized in certain groups such as Rodentia and Macroscelididae. Moreover, the close and constant relations of n. anterodorsalis to striae medullaris and terminalis suggest the possibility of a functional relationship in the olfactory sphere. It has been found that the connection of n. anterodorsalis with the mamillothalamic tract, which is also a large and well developed structure, may have something to do with its unusual development in the Macroscelididae. In other insectivores, n. anterodorsalis is relatively small and inconspicuous, and its connections with the mamillothalamic tract cannot be easily detected by ordinary histological methods.

The anterior nuclei take a further step in differentiation in the Tupaioidea, e.g. *Tupaia glis*, so that they come to resemble those of most specialized mammals, particularly primates. Le Gros Clark (1928, 1962) found that the development of the anterior thalamic nuclei in *Ptilocercus* (a tupaioid) was somewhat intermediate between that in *Macroscelides* and in *Tupaia*. He noted that nn. anterodorsalis and anteroventralis of *Ptilocercus* are larger than those of *Tupaia*, but n. anterodorsalis is much smaller in relation to n. anteroventralis than in *Macroscelides*; its constituent cells are not as large as those of the latter species, yet they are relatively bigger and more darkly staining and closely packed than the cells of *Tupaia minor*. Bauchot (1963) states that the cells of n. anterodorsalis in *Tupaia glis* are relatively larger than those of *Tupaia minor*; that is different from what has been observed in the same species used in this study, where the cells of n. anterodorsalis are uniformly small in size and dark-staining.

My observations on structure, form, cellular size and neuronal type in *Elephantulus myurus* and *Tupaia spp.* conform to those of Le Gros Clark, Bauchot and other authors on the Macroscelididae and Tupaioidea. It is in the Tupaioidea that the first signs of regression become evident in n. anterodorsalis.

In *Galago* spp., used in this study, n. anterodorsalis covers not only the dorsomedial surface of n. anteroventralis, but also the dorsolateral surface of the same nucleus. This unusual feature has been described by Kanagasuntheram et al (1968) in *Nycticebus coucang* (a lorisoid), thus approaching the condition found in the Insectivora and Tupaioidea. The cellular differentiation of n. anterodorsalis into medial and lateral groups in *Galago senegalensis* has been reported previously by

Kanagasuntheram et al in the same species, but this subdivision is not present in *Nycticebus coucang*. It is doubtful whether this cellular differentiation represents a phylogenetic trend, since it is not present in all other primate species studied here. However, in the gibbon (Hylobatidae), Kanagasuntheram and Wong (1969) describe a poorly developed n. anterodorsalis which is separated on a cytological basis into medial and lateral portions. But in the gibbon, the medial parts of n. anterodorsalis on both sides of the median plane do not form an internuclear connection, as found in other lower primates.

As one ascends the primate scale from cercopithecoids to man, n. anterodorsalis becomes reduced in size until it comes to resemble a thin caplike structure aligned along the dorsomedial surface of n. anteroventralis. The cells of n. anterodorsalis remain more or less uniformly medium-sized, darkly stained and compactly arranged throughout the higher primates.

The *interanterodorsal commissure* is larger and better developed in menotyphlan than in lipotyphlan insectivores (Bauchot 1963). This has been confirmed here for *Elephantulus myurus*, in which n. anterodorsalis is unusually large. N. interanterodorsalis is, however, less well developed than n. interanteromedialis in all prosimians, becomes rudimentary in higher primates, and is absent in man.

2. *Nucleus anteromedialis (AM)* and *nucleus interanteromedialis (IAM)* (Plates 1-47)

(1) *INSECTIVORA*

Macroscelidoidea

Elephantulus myurus

N. anteromedialis (Figs. 33 & 34) is smaller than n. anterodorsali and slightly larger than n. anteroventralis from which it is demarcated rather clearly by an oblique band of myelinated fibres. At its rostral extremity, n. anteromedialis appears as a triangular mass of cells that lies beside the dorsal tip of the preoptic recess of the third ventricle, above the fornix and anterior commissure. It extends further laterally than n. anterodorsalis; its cells are larger, better staining and more oval-shaped than those of n. anteroventralis.

N. interanteranteromedialis is a large and well defined structure connecting the two nuclei anteromediales across the median plane. It is situated ventral to n. interanterodorsalis.

N. anteromedialis is pierced on its lateral side by fibre bundles of the lateral corticohabenular tract and superior thalamic radiations. Small fibre bundles converge at the ventrolateral extremity to form the main body of the mamillothalamic tract. N. anteromedialis itself is free of myelinated fibres. It receives fibres from the anterior part of the periventricular system and also from the thalamic radiations.

(2) TUPAIOIDEA

N. anteromedialis (Figs.43 & 44) appear at a slightly more caudal level than n. anteroventralis, and throughout its extent, lies ventromedial to the latter nucleus. It may readily be distinguished from n. anteroventralis, but the myeloarchitectonic differences between the two nuclei are not well defined. However, a "broken line" of fibre bundles running dorsoventrally gives an impression of demarcation between these two nuclei. This delimitation appears to be more pronounced in certain *Tupaia* species such as *Tupaia glis* and *Tupaia gracilis*, while in others, it is weakly developed.

N. anteromedialis lies ~~ventro~~medial to nn. anterodorsalis and parataenialis, ventromedial to n. anteroventralis, lateral to n. paraventralis and ~~medial~~ lateral to n. ventralis anterior. In its caudal extension, n. anteromedialis becomes related ventrally to nn. submedius and medioventralis, and dorsally to the rostral pole of n. mediodorsalis which eventually replaces it. The cells are 13 x 10 µ in size, round or oval, and are arranged more compactly than are those of n. anteroventralis.

N. interanteromedialis (Figs 43 and 44) is present, and contains fewer fibrous bundles than n. interanterodorsalis. In the rostral part of the midline region, it lies between nn. paraventricularis and interanterodorsalis, and in the caudal part of the same region, between nn. rhomboidalis dorsally, and nn. centralis medialis and reuniens ventrally. It runs for a short distance caudally when it is replaced by the expanding n. rhomboidalis. The cells of n. interanteromedialis are smaller than those of n. anteromedialis (12 x 9 µ).

(3) PROSIMII

(a) Lemuroidea

N. anteromedialis (Figs. 53 & 54; 61 & 64; 71-74) has a shorter rostro-caudal extent than n. anteroventralis, and it terminates at the level of the rostral part of n. mediodorsalis which replaces it. In all lemuroids, n. anteromedialis is not very well demarcated from n. anteroventralis, but can still be distinguished from the latter nucleus by differing myeloarchitectonics. The cells of the anteromedial nucleus are mostly medium-sized (16 x 12 µ), stain quite lightly. They are arranged less compactly than those of n. anteroventralis. Its topographical relations to adjoining nuclei are the same as described for the Tupaioidea. However, n. anteromedialis is more heavily myelinated than n. anteroventralis; fibre fascicles run ventromedially and join the fibres running along the dorsoventral surface of n. anteroventralis to form the mamillothalamic tract. In one of the *Lemur* species studied here, *Lemur fulvus*, n. anteromedialis is lightly myelinated probably because of the extreme youth of this animal in which myelinization may not have been completed. In all lemurs, nn. anteromedialis and anteroventralis are not completely separated from each other, although some fibre bundles are arranged almost parallel to the midline, running through the anterior nuclear mass. *N. interanteromedialis* (Figs. 53 & 54; 62; 72 - 74) has the same features as described in the Tupaioidea (16 x 11 $/^{u}$),

(b) *Lorisoidea*

(i) *Lorisidae Perodicticus potto*
Perodicticus potto

N. anteromedialis (Figs. 87 & 88) is not distinctly separated, and even not cytoarchitectonically distinguished, from n. anteroventralis, although the cells of the former are less intensely staining, and not as regularly arranged as those of the latter nucleus. However, a denser collection of fibre bundles runs horizontally from the external medullary lamina through the region of the anterior nuclei. This is the mamillothalamic tract which is a thick and prominent structure running dorsally, mainly through n. anteromedialis, towards the dorsal surface of the thalamus. On the basis of these differing myeloarchitectonics, n. anteromedialis is slightly smaller than n. anteroventralis in size, and is almost completely rounded off by a capsule of fibres from nn. anteroventralis and anterodorsalis. N. anteromedialis is replaced by the expanding n. mediodorsalis at the level of the rostral appearance of n. lateralis dorsalis. *N. interanteromedialis* (Figs.87 and 88) is well defined, and has the usual topographical relations as in other prosimions.

(ii) Galagidae

In all three Galago species, n. anteromedialis (Figs.97-100; 107-110) is not easily delimited topographically from n. anteroventralis. Myeloarchitectonically, n. anteromedialis is heavily stippled with myelinated fibre bundles, the mamillothalamic tract, that runs ventro-dorsally towards it. N. anteromedialis can be distinguished also cytologically from n. anteroventralis; the former has smaller, more rounded and lighter staining cells (14 x 11 μ) that are more loosely arranged than those of the latter nucleus. N. interanteromedialis (Figs. 99-100; 107 & 108) is a well formed structure lying in the median plane between nn. interanterodorsalis and rhomboidalis dorsally, and nn. centralis medialis and reuniens ventrally. The topographical relations of n. anteromedialis are not different from those of other prosimians (12 x 10 μ).

(4) ANTHROPOIDEA

(i) Cercopithecidae
Cercopithecus aethiops

N. anteromedialis (Figs. 119 & 120) has the same topographical features as in lower primates. However, it commences slightly caudal to n. anteroventralis, but rostral to the rostral end of n. anterodorsalis. N. anteromedialis reaches its greatest size at the level of the caudal end of n. paratuenialis, and becomes equal in cross-sectional area to that of n. anteroventralis. Then farther caudally, it decreases in size, and is replaced rapidly by the expanding dorsal part of n. mediodorsalis. The cells of n. anteromedialis are medium-sized (18 x 14 μ), but they are larger than those of the same nucleus in prosimians. They stain fairly well, are arranged rather loosely;

the Nissl granules are larger and better developed than in the cells of n. anteromedialis in prosimians. N. interanteromedialis (Figs 119 & 120) is well developed in this simian primate. The interanteromedial commissure is the only commissure of the anterior group since the interanterodorsal commissure has regressed to a vestigial structure in cercopithecoids. The cellular characteristics of n. interanteromedialis are the same as in other primates. (16 x 14 /").

(ii) Hominidae

Homo sapiens

N. anteromedialis (Figs. 125 & 126) appears at the level of the middle part of n. anteroventralis. It is surrounded by a distinct fibrous layer, except at its rostrodorsal border, where it is indistinctly separated from the latter nucleus. N. mediodorsalis replaces n. anteromedialis rostrally and the other anterior nuclei caudally.

Discussion on n. anteromedialis

Because n. anteromedialis shares more or less the same cytoarchitectonic characteristics, and also a common boundary, with n. anteroventralis, it will be discussed later in this chapter in connection with the latter nucleus.

3. N. anteroventralis (AV) (Plates 1 - 49)

(1) INSECTIVORA

Macroscelidoidea

Elephantulus myurus

N. anteroventralis (Figs. 33 & 34) is the smallest of the three anterior nuclei. It is seen as a rounded mass of medium-sized, moderately staining and multipolar cells lying in the angle between nn. anterodorsalis and anteromedialis. Further caudally, it is triangular in shape, and its medial angle fuses with the midline nuclei. It becomes progressively smaller, until it is replaced caudally by the intralaminar nuclei, particularly by n. centralis lateralis. N. anteroventralis is well connected with the telencephalic areas through the superior thalamic radiations.

(2) *TUPAIOIDEA*

Compared with n. anteroventralis of *Elephantulus*, (Figs. 43 & 44) It is much larger. In *Tupaia* specimens, *n. anteroventralis* is the largest of the three anterior nuclei, but is, nevertheless, relatively smaller than in higher primates. It is first of the three anterior nuclei to make its appearance at the rostral level of the diencephalon. This nucleus can be distinguished easily from n. anteromedialis by its larger, more deeply staining, polygonal cells (15 x 10 $/^{u}$), that are distributed more uniformly in the substance. They are arranged closely to the dorsal thalamic surface between the stria medullaris and the olfactohabenular tract. Caudally, n. anteroventralis enlarges and becomes isolated from the adjoining nuclei by a capsule of fibres. It lies ventral to n. anterodorsalis, lateral to n. reticularis, and medial to nn. paraventricularis and mediodorsalis pars oralis. Since nn. anteroventralis and anteromedialis are incompletely demarcated from each other, they are often regarded collectively as the *principal anterior nucleus*. In that event, n. anterodorsalis is the *accessory anterior nucleus*. These nuclear relations are more accentuated in higher primates, where the separation between nn. anteromedialis and anteroventralis is almost absent.

At the level of the rostral pole of n. mediodorsalis, n. anteroventralis is reduced progressively in size, and becomes further isolated by its fibrous capsule from the dorsolateral nuclei laterally and from n. mediodorsalis medially. At its caudal end, n. anteroventralis is replaced by the dorsolateral region of n. mediodorsalis.

Prosimii

(a) Lemuroidea

N. anteroventralis (Figs.53 & 54; 61-64; 71-74) is comparatively much larger than in other prosimian species. It is rather ovoid in cross-section and is circumscribed by a fibrous capsule, more particularly in *Lemur fulvus*. It shows a conspicuous elevation on the dorsal thalamic surface, thus marking the beginning of an anterior tubercle in primates. The cells of n. anteroventralis are large (17 x 12 μ), well staining, oval or polygonal, they are arranged more regularly than those of n. anteromedialis. There is no evidence that n. anteroventralis is divided into two cellularly distinct parts, as described in the Lorisidae by Kanagasuntheram et al (1968), nor that the cellular distinction between nn. anteroventralis and anteromedialis is definable. But the demarcation is better indicated at the level of the entrance of the mamillothalamic tract. N. anteroventralis is replaced by n. lateralis dorsalis at the level of the middle part of n. mediodorsalis (in *Lemur fulvus*); it disappears at the level of the rostral part of n. mediodorsalis.

(b) Lorisoidea

(i) *Perodicticus potto*

As in other prosimians, n.anteroventralis (Figs. 87 & 88) is the largest of the three anterior nuclei. On the dorsal surface of the thalamus, it has a prominent eminence, the anterior tubercle, that thrusts above the epithalamic structures. N. anteroventralis is not well demarcated from n. anterodorsalis which forms a thin layer on its dorsal surface. In its rostral region, n. anteroventralis is related ventrolaterally to n. reticularis, but this relationship changes towards the level of the rostral pole of n. lateralis dorsalis. There, n. reticularis is its direct lateral relation, and the midline nuclei form its medial relation. Caudally, n. anteroventralis disappears at the level of the rostral pole of n. mediodorsalis.

(ii) *Galagidae* (Figs.106-109; 116-123)

N.anteroventralis (Figs.97-100; 107-110) is a large structure consisting of medium-sized (13 x 3 μ), fairly well stained, polyhedral cells that are scattered throughout the nucleus. It is not very clearly separated from n. anteromedialis, thus giving an appearance of being fused into one uniform mass of medium-sized, well-stained polygonal cells (n. anterior principalis). N. anteroventralis commences at the caudal level of the anterior commissure. Its relationships to adjoining nuclei are slightly different from those in the Lemuroidea: ventral to n. anterodorsalis; ventrolateral to nn. paraventricularis and parataenialis, and the stria medullaris; ventromedial to n. reticularis and the dorsal part of n. ventralis anterior, and dorsolateral to nn. anteromedialis and paracentralis. At its caudal end, n. anteroventralis is replaced by the dorsolateral nuclei.

In all *Galago* specimens, n. anteroventralis appears to be differentiated cytoarchitectonically into a smaller medial magnocellular and a larger lateral parvocellular part. The former part resembles n. anterodorsalis in having dark-staining and polygonal cells which are, however, larger than these of the latter nucleus. The lateral part is, in fact, the main body of n. anteroventralis.

(4) ANTHROPOIDEA

(i) *Cercopithecidae*

Cercopithecus aethiops

Rostrally, n.anteroventralis (Figs.117-120) appears as a small, oval mass, situated ventromedial to the caudal end of the stria terminalis, and ventral to the taenia thalami. It has a longer anteroposterior extent than the other two anterior nuclei, and is replaced, at its caudal end, by n. lateralis dorsalis. Nn. anteroventralis and anteromedialis are indistinctly demarcated from each other by one incomplete band of fibres. The cells of n. anteroventralis are mostly medium-sized (20 x 12 μ), but they are distinctly larger than those of the prosimians. The cellular characteristics of n. anteroventralis are, however, similar to those of the same nucleus in prosimians (Type V). Many bundles of myelinated fibres traverse n. anteroventralis, but the myelin distribution is not as dense as that of n. anteromedialis. At its dorsolateral border, small, scattered fibre bundles are observed, separating n. anteroventralis from n. lateralis dorsalis. The internal medullary lamina surrounds n. anteroventralis almost entirely on all sides, except at its inferomedial border, where it is not clearly delimited from n. anteromedialis.

(ii) Hominidae

Homo sapiens

N. anteroventralis (Figs. 125-130) is not only the largest of the three anterior nuclei, but it is also one of the most conspicuous nuclei of the entire thalamus. N. anteroventralis makes up the bulk of the anterior tubercle, and if this tubercle is not present, n. anteroventralis commences at the level of the rostral pole of n. mediodorsalis. It extends to the level of the interthalamic adhesion, where it expands rapidly in size to form a large, ovoid structure, lying dorsoventrally along the wall of the third ventricle. N. anteroventralis terminates at the caudal pole of n. mediodorsalis which replaces it. This is significant, since n. mediodorsalis has expanded enormously in size and extent, and the caudal extent of n. anteroventralis is much longer than it is in other primate species.

The cells of n. anteroventralis are almost identical to these of n. anteromedialis; that is, they are mostly medium-sized, rather well staining and polygonal or oval, but they are distributed more compactly than those of the latter nucleus.

Discussion on nn. anteroventralis and anteromedialis

In all primates, the elements of the anterior nuclear group show much variation in relative size and differentiation, and in the character of their cells. In non-primate mammals, the three anterior nuclei are more or less distinctly separated from one another, e.g., in rodents (Gurdjian 1927, Holmes 1953, Hess 1955, Herbert 1962), in ungulates (Solnitzky 1938, Rose 1942), in carnivores (Rioch 1929, Ingram et al 1932), in cetaceans (Kruger 1959), in edentates (Kaelber 1966) and marsupials (Goldby 1941). The last mentioned author did not find any outstanding development of the three anterior nuclei that resemble one another in all important features. He concluded that the anterior nuclei should remain classified as an unit, nucleus anterior, and that n. anterodorsalis and its commissure should be included with the midline nuclei. Goldby's inference is partly correct, but n. interanterodorsalis, not n. anterodorsalis, is actually a midline structure; it has been described in this study, as well as by other authors, as an element of the anterior nuclear group by virtue of its connection with n. anterodorsalis.

In these non-primate mammals, n. anteroventralis is more distinctly demarcated from n. anteromedialis by a well-developed bundle of fibres, belonging possible to the superior thalamic peduncle. The cytoarchitectonic features of these two nuclei in size and extent are, however, not very distinctive. Le Gros Clark (1929), Allison (1947) and Bauchot (1963) found that in Macroscelides and Elephantulus, n. anteroventralis is smaller than nn. anteromedialis and anterodorsalis, but in Erinaceus (hedgehog), the former nucleus is relatively large and well-developed. Generally, n. anteroventralis of lipotyphlan insectivores is a large, rather irregularly shaped structure, extending dorsolaterally towards the dorsal surface of the thalamus, whereas it is more deeply situated in the thalamus of Elephantulus and other macroscelidids. However, in all insectivores, n. anteromedialis is large and well differentiated in comparison with n. anteroventralis; it is also well demarcated from the latter nucleus, not only by the fibres of the mamillothalamic tract, but also by differing cytological features.

The reversal in structural size and topographical relations of n. anteroventralis to the other two anterior nuclei, as well as in the cytological characteristics of n. anteromedialis in Elephantulus myurus conforms to those in the Macroscelididae described by the above-mentioned authors.

In the Tupaioidea, the size of n. anteroventralis, and also the degree of its separation from n. anteromedialis, vary from species to species. In Ptilocercus, n. anteroventralis is slightly smaller than n. anteromedialis, from which it is clearly demarcated. (Le Gros Clark 1929, 1962). The cells of n. anteroventralis are, however, smaller and less darkly staining than those of n. anterodorsalis, whereas in Tupaia spp. these cells have been observed to be larger and better staining than those of the other two anterior nuclei. In Ptilocercus, towards its caudal end at the level of the rostral pole of n. mediodorsalis, n. anteroventralis loses its individuality by merging with n. anteromedialis, whose cells give an appearance of being arranged in rows curving towards the median plane. In Tupaia glis, n. anteromedialis is the first anterior nucleus to undergo reduction in size; towards the rostral pole of n. mediodorsalis, it becomes indistinctly separated from n. anteroventralis. Thus, an evolutionary change has possibly taken place in n. anteroventralis, starting with the tupaioids and increasing steadily in structure and functional importance throughout the primate scale, until in man, it becomes such an important structure that it seems to take over virtually the whole anterior nuclear group.

The separation between nn. anteroventralis and anteromedialis is less complete in *Tarsius* (Le Gros Clark 1930) than in all other prosimians studied here and by other authors (Bauchot 1963, Feremutsch 1963, and Kanagasuntheram et al (1968, 1969). In *Tarsius*, nn. anteroventralis and anteromedialis appear to be more or less fused to form the main bulk of the anterior nucleus, while n. anterodorsalis is a small structure lying on the dorsomedial surface of the latter nucleus. The presence of a small-celled portion within the lateral part of n. anteroventralis, as found in *Galago crassicaudatus* and *Galago senegalensis*, has been reported previously by Le Gros Clark in *Tupaia* (1929) and by Rioch in carnivores (1929). The absence of this small-celled part, and, more especially, of the division of n. anteroventralis, cannot be accepted as a progressive feature in the prosimians, particularly in the Lorisoidea.

In *Lemur catta*, Pines divided the anterior nuclear region into a principal part, his nucleus "aa", which is double-sided, and joined in the midline, and an accessory part, his nucleus "ac". The nucleus "aa" is divided further into a dorsolateral portion, also termed "aa" and a ventromedial portion"ab". Le Gros Clark (1929, 1930) homologized Pines's n. "aa" and n. "ab" to the large-celled dorsal portion and the small-celled ventral portion of nn. anteroventralis (and of n. anteromedialis) respectively in *Tupaia minor*, and to n. anteroventralis in *Tarsius*. Pines's n. "ac" corresponds directly to n. anterodorsalis in both species. These topographical divisions are not different from those in *Lemur catta* and other lemur specimens used in this study, although Pines's descriptions of the anterior nuclei differ considerably from those of the prosimians studied here and by other authors.

Kanagasuntheram et al (1968) mention that n. anteroventralis is larger than n. anteromedialis in both Galago senegalensis and *Nycticebus coucang*, but separation between these two anterior nuclei is more distinct in the latter species. It may show that this is a primitive character, particularly in the lorisoids, because the trend towards fusion of nn. anteroventralis and anteromedialis becomes more and more pronounced as one goes up the primate scale.

Feremutsch (1963) does not believe that the anterior nucleus of primates should be divided into three separate parts, because there are no actual cytoarchitectonic distinctions among nn. anteroventralis, anteromedialis and anterodorsalis, and the former two nuclei are only a homogeneous mass of cells, which he terms the principal part of the anterior nucleus. In this event, n. anterodorsalis is the dorsomedial "cap" of the principal anterior nucleus. In all primate species studied by Feremutsch, the principal anterior nucleus is described as a very large and well developed structure, circumscribed by a fibrous capsule and sharply delimited on its lateral side. It is indistinctly divided into dorsolateral and ventromedial parts which represent nn. anteroventralis and anteromedialis respectively in the primate species used in this study.

The hypothesis that nn. anteroventralis and anteromedialis are different cytoarchitectonically from each other, has been previously maintained by several authors working on the primate diencephalon, namely Olszewski (1952), Simma (1957) and Heiner (1960). In the vervet monkey(Simmons 1965), nn. anteroventralis and anteromedialis are quite distinctly separable from each other by an incomplete band of fibres running dorsoventrally through the anterior nuclear region, and cytological differences between these two anterior nuclei are not great. N. anterodorsalis is a relatively well formed structure bordering on the dorsomedial surface of n. anteroventralis. These structural features have been reported also in _Macaca spp._ by Papez and Aronson (1934), Crouch (1934), Walker (1937) and Krieg (1948). Kanagasuntheram and Wong (1969) maintain, however, that nn. anteroventralis and anteromedialis are distinctly separated in the siamang, but not in the gibbon and other members of the Hylobatidae. In the human thalamus, Sheps (1945), Toncray and Krieg (1946), Dekaban (1953) and Kuhlenbeck (1954) treat the anterior nuclei as separate entities without mentioning the presence of a fibrous demarcation between nn. anteroventralis and anteromedialis. However, in the human thalamus studied here, n. anterodorsalis is still a separate structure which is very small in size, and shaped like a baton aligned along the dorsomedial surface of n. anteroventralis; n. anteromedialis is distinguishable by only slight cytological differences from n. anteroventralis.

SUMMARY OF THE ANTERIOR NUCLEAR GROUP

It is seen that throughout the Primates from *Tupaia* spp. to man, n. anterodorsalis becomes progressively smaller in size, until in man, it becomes only a narrow cap-like structure lying on the dorsomedial surface of n. anteroventralis. It shows evident signs of regression. Likewise, *n. anteromedialis* becomes less and less distinctly separated from n. anteroventralis, until in man, the former is indistinguishable cytoarchitectonically from n. anteroventralis anteroventralis. Of all the nuclei in the anterior group, n. anteroventralis shows the most progressive evolution from a very small and insignificant structure in *Elephantulus*, an insectivore, to one of the largest and most conspicuous structures in the primate thalamus in man. In some primate species, namely *Galago senegalensis*, n. anteroventralis exhibits a dimorphic character that cannot be regarded as a progressive trend, as it has not been observed in all other primates. The most significant features in the phylogeny of the anterior nuclear group of primates are the steady progression in changes of size and differentiation of the anterior nuclei. Structural features, cellular properties, myelin content, phylogenetic trends, etc., are summarized in Table 10.

Table 10 COMPARISONS IN THE ANTERIOR THALAMIC NUCLEAR GROUP

Features	N. anterodorsalis (AD)	N. interanterodorsalis (IAM)	N. anteromedialis (AM)	N. interanteromedialis (IAM)	N. anteroventralis (AM)
STRUCTURAL FEATURES	Largest in *Elephantulus*; intermediate in size in Tupaioidea; smallest in Prosimii and Anthropoidea. Covers dorsomedial surface of n. anteroventralis in most primate species, but dorsolateral in *Galago senegalensis*.	Present in *Elephantulus*, Tupaioidea and in all prosimians, but is either a vestigial structure or absent in Anthropoidea. Is seen crossing the median plane below n. paraventricularis.	Slightly larger than n. anteroventralis in *Tupaia* spp., but becomes smaller in size and extent than n. anteroventralis in higher primates. Is incompletely separated in prosimian and simian primates, but is fused with n. anteroventralis in anthropoid apes and man.	Is present in *Elephantulus*, in Tupaioidea and all prosimians. Is prominent in ceboid monkeys, but is not present in anthropoid apes and man. Is larger and more distinctly formed than n. interanterodorsalis.	Small in *Elephantulus* but becomes the largest nucleus in Tupaioidea, Prosimii and Anthropoidea, as well as one of the most conspicuous nuclei in primate thalamus. In many species, it is not well demarcated from n. anteromedialis.
CELLULAR PROPERTIES	Mostly small, dark-stained, fusiform. Average cell size is variable (14 x 9 /^{u} *Lemur* to 20 x 12 /^{u} *Cercopithecus*.) Type III; Nissl granules scanty and small. Cellular arrangement is rather compact.	Smaller, less darkly stained, mostly fusiform. Scanty Nissl substance. Type II. Cell size mostly medium (12 x 7 /^{u} *Tupaia* to 14 x 5 /^{u} *Cercopithecus*).	Mostly medium (13 x 10 /^{u} - *Tupaia* to 18 x 14 /^{u} - *Cercopithecus*); lightly stained loosely arranged. Nissl granules present but few ~~(Type V)~~.	Medium but smaller in size (12 x 9 /^{u} - *Cercopithecus*). Same cellular features but scantier Nissl material ~~(Type II)~~.	Medium to large (13 x 8 /^{u} - *Tupaia* to 20 x 10 /^{u} - *Cercopithecus*); round, better staining than n. anteromedialis, but less than n. anterodorsalis. Nissl substance more abundant - Type V. Cells are regularly arranged but more loosely than those of n. anteromedialis.
FIBRE CONTENT AND ARRANGEMENT	Dense myelin content; fibres arranged mediolaterally, and encapsulate the nucleus.	Fibrous strands crossing the midline - commissure of n. anterodorsalis. Absent in anthropoid apes and in man.	More densely myelinated than n. anteroventralis; medial part is traversed by incomplete fibrous band in Tupaioidea and Prosimii, but this band is absent in Anthropoidea.	Compactly arranged fibrous band lying below n. interanterodorsalis, but is not well formed in anthropoid apes and is absent in man.	Fine meshwork of fibres with occasional transverse bundles separating it from n. anterodorsalis on its dorsomedial border in all primate species.
EVOLUTIONARY TRENDS	Largest and most specialized in macroscelidids but shows signs of regression in Tupaioidea. Is the accessory anterior nucleus in all primates. Exhibits slight dimorphism in certain galago species.	Better developed in <u>lower</u> prosimian species, particularly Lemuroidea. Is a regressive structure in the primate thalamus.	Slight regressive trend; varies in degree of separation from or fusion with n. anteroventralis throughout the the primate scale. Indistinct cytoarchitectonic differences between nn. anteromedialis and anteroventralis.	At first stable in development up to the taxonomic level of anthropoid apes where it becomes rudimentary, and is absent in man.	Is the only anterior nucleus that shows progressive features; it takes over the whole anterior nuclear region in higher primates. Exhibits an occasional dimorphism, particularly in the Galagidae.

CHAPTER 6

THE THALAMUS: MIDLINE NUCLEAR GROUP

This nuclear group is the most difficult to trace and to divide into constituents throughout the mammalian order. However, it remains remarkably constant in its topographical distribution in the periventricular grey of the interthalamic connection. It is also the most conservative of all thalamic groups, and forms a part of the phylogenetically older thalamus. The midline nuclear group is composed of six recognizable nuclei as follows:

1. N. parataenialis (PT)
2. N. paraventricularis (PV)
3. N. rhomboideus (RH)
4. N. centralis medialis (CM)
5. N. reuniens (RE)
6. N. interventralis (IV)

1. *N. parataenialis* (PT) (Plates 1 - 49)

(1) INSECTIVORA

Macroscelidoidea

Elephantulus myurus

In the rostral part of the thalamus, n.parataenialis (Figs.33 & 34) consists of a column of mixed small and medium-sized cells lying immediately ventromedially to the stria medullaris. It is a rather large and well-defined structure with primitive cellular features. It can be clearly separated into medial and lateral parts: the *lateral part* has relatively large cells that are scattered just beneath the stria medullaris, and the *medial part* consists of compactly arranged small cells that are related closely to the anterior part of n. paraventricularis. N. parataenialis is, to some extent, connected with its fellow by a very small and barely discernible band of cells, *n. interparataenialis*, which lies ventral to n. paraventricularis. The cells of this bed nucleus are much smaller, more darkly staining and more spindle-shaped than those of n. parataenialis. N. parataenialis continues as far caudally as the level of the rostral pole of the habenular body where it is replaced by n. mediodorsalis.

(2) TUPAIOIDEA

The *interthalamic adhesion* in all *Tupaia* species (Figs.43-48) is well developed and very thick. In *Tupaia gracilis*, in which the thalamus appears to be shorter dorsoventrally and broader mediolaterally, the interthalamic adhesion is smaller; this may be due to an unusually large third ventricle. There, the midline nuclei seem to be packed closely to one another without their identities being obliterated or blurred. However, further caudally, where the third ventricle becomes shorter and is placed more ventrally, the interthalamic adhesion becomes thicker, and the midline nuclei can be better delimited from one another. In all tupaioids, the whole extent of the midline thalamic mass follows almost exactly that of n. paraventricularis.

N. parataenialis is a small, round mass of cells lying laterally to the anterior part of n. paraventricularis, and ventrally to the stria medullaris. N. parataenialis can easily be distinguished cytoarchitectonically from n. paraventricularis by the more scattered, larger and less darkly staining cells of the former nucleus (11 x 7 μ).

Medial and lateral divisions of n. parataenialis as described by Le Gros Clark (1929) in *Tupaia minor*, and by Allison (1947) and in this study in *Elephantulus*, cannot be observed in all tupaioids. However, the caudal part of n. parataenialis extends laterally to become related dorsally to n. mediodorsalis, and to the dorsal part of the internal medullary lamina. Thus, n. parataenialis comes into direct relationship with n. centralis lateralis which is lateral to it. N. parataenialis terminates at the level of the rostral pole of n. habenularis medialis.

The interparataenial commissure is well defined in all tupaioids, and is at its thickest when the caudal end of n. parataenialis is reached.

N. interparataenialis runs horizontally from one parataenial nucleus to the other across the median plane. In the median plane, it lies dorsally first to n. interanteromedialis, and then to nn. interanterodorsalis and rhomboideus. Its cells are smaller, less darkly staining and more fusiform than those of n. parataenialis. The cells of the latter nucleus are more loosely arranged and lie close to the dorsal surface of the thalamus. It is more densely myelinated than the other midline nuclei and it is closely related to the stria medullaris.

(3) PROSIMII

Lemuroidea and Lorisoidea (Figs.33-73; 86-110)

There are very few differences in the structure of the midline nuclear group among these prosimians, so that a general description will be given. Where there are topographical or cytological differences, these will be mentioned.

N. parataenialis commences at the most rostral region of the thalamus, at an even more anterior level than that of the Tupaioidea, as a well circumscribed area lying between n. paraventricularis anterior and the rostral part of n. anteroventralis. Caudad, n. parataenialis becomes larger, and its oval shape is longer mediolaterally than dorsoventrally. It is related almost entirely to the lateral border of n. paraventricularis pars anterior; at this level, it lies dorsal to n. anteromedialis, dorsomedial to n. anteroventralis and ventral to the stria medullaris. These relationships remain constant throughout its extent in all prosimians. N. parataenialis is replaced gradually by the lateral extension of

n. rhomboideus, until at the level of maximal size of n. mediodorsalis, it disappears, thus, being much shorter rostrocaudally than in the Tupaioidea.

N. interparataenialis (IPT) can be identified in *Galago demidovii* and *Galago senegalensis*, and to a lesser extent, in *Galago crassicaudatus*. It is a very thin band of dark-staining cells crossing the median plane ventral to the rostral pole of n. paraventricularis. However, it is barely distinguishable or even absent in lemuroids. It is entirely absent in *Perodicticus potto*.

The cells of n. parataenialis in all prosimians used in this study are generally small (12 x 9 μ in *Galago* and 14 x 10 μ in *Lemur*), stain rather well, are oval or round in shape, and are arranged rather loosely among the densely packed myelinated fibres of the stria medullaris.

(4) ANTHROPOIDEA

(i) *Cercopithecidae*

Cercopithecus aethiops (Figs.117-122)

N. parataenialis has a very long rostrocaudal extent. It appears at the level of the rostral pole of n. anteroventralis, and ends at the level of the rostral part of the habenular region. There is no evidence of its being divided into medial and lateral parts, nor of its having an internuclear commissure: it remains relatively simple and undifferentiated. The cells of n. parataenialis appear to be more concentrated beneath the stria medullaris than in the periventricular grey of the third ventricle. These cells are small (12 x 9 μ), stain darkly and are spindle-shaped or stellate, in contrast with the oval shape of the cells of the same nucleus in lower primates

(ii) Hominidae

Homo sapiens (Figs.125-130)

The topography and architectonics do not differ much from those of the vervet monkey. However, in man, n. parataenialis is a stable and more distinctly formed structure that lies close to the stria medullaris laterally, and to n. paraventricularis medially. It is scantily myelinated, and is well connected with the hypothalamus by the periventricular system, and also with nn. mediodorsalis, centrales medialis and lateralis.

Discussion on n. parataenialis

Most authors place n. parataenialis in the medial thalamic group largely because of its paramedian position, rather than because of its close relationship to the periventricular system, with which it shares the same functions. In rodents (Gurdjian 1929, Rose 1942, Krieg, 1944, and Hess 1955), n. parataenialis does not have medial and lateral divisions, but possesses a large internuclear commissure. However, Holmes (1953) did not find either the cellular parts or the interparataenial commissure in the mouse. In ungulates and carnivores, n. parataenialis remains undivided, but is fused with its bed nucleus (Rioch 1929, Ingram et al 1932, Solnitzky 1938 and Rose 1942). Kruger (1959) did not find n. interparataenialis in his cetacean species. N. interparataenialis has been found in this study to be present in Elephantulus, Tupaioidea and in certain prosimians; it regresses gradually through the primate scale until it disappears in anthropoid apes and man. N. parataenialis is divisible into medial and lateral parts in Elephantulus and the Tupaioidea, as was found by Le Gros Clark (1929) in the tree-shrew and by Bauchot (1963) in the Insectivora and Prosimii. The latter author could not find any trace of Le Gros Clark's "nucleus disseminatus", which corresponds most probably to nn. interparataenialis and intermediodorsalis of non-primate and lower primate forms. Bauchot mentions also the cellular divisions in his prosimian specimens, particularly *Galago demidovii*; these parts have not been observed in all the animal species used in this study.

It is difficult to analyse Feremutsch's (1963) paramedian formations into their homologies with the midline and medial nuclei of primates in this study. Feremutsch describes n. parataenialis as a well demarcated, monomorphous and isoformic nucleus lying laterally to his "pars dorsalis (Pd)" of the periventricular grey of the interthalamic adhesion; it is divided into medial and lateral parts, particularly in *Propithecus* and *Loris tardigradus*. Kanagasuntheram et al (1968) do not mention these features in *Galago senegalensis* and *Nycticebus coucang*. In *Tarsius*, Le Gros Clark (1930) describes n. parataenialis as a small group of cells lying along the fibres of the stria medullaris on the anterodorsal aspect of his nucleus anterior, and reaching back as far as the rostral extremity of n. habenularis pars medialis. He did not describe two cellular sub-divisions or an internuclear commissure. He was able to distinguish n. parataenialis from n. paraventricularis pars anterior by its larger and more scattered cells which were somewhat smaller and more lightly staining than the cells of s. anterior. In some cercopithecoids, n. parataenialis has a clear cellular division into medial and lateral parts (Crouch 1934, Papez and Aronson 1934, Walker 1937, Krieg 1948), but this feature is not found in the vervet monkey (Simmons 1965). My observations on n. parataenialis show that this nucleus is a rather stable structure in all primates, changing only in size from species to species. Its internuclear commissure, however, vanishes with the drastic reduction of the interthalamic adhesion, particularly in higher primates.

2. N. paraventricularis (PV) (Plates 1 - 50)

(1) INSECTIVORA

Macroscelidoidea

Elephantulus myurus

N. paraventricularis (Figs.33-38) can be divided, on the basis of both topography and cytology, into anterior and posterior parts. The anterior part (n. paraventricularis pars anterior) lies below the third ventricle in the rostral part of the thalamus, separated from the adjacent medial thalamic nuclei by the periventricular fibres; it extends as far caudally as the rostral pole of n. habenularis pars medialis, where it continues further as the posterior part (n. paraventricularis pars posterior).

The anterior part is relatively large and wing-shaped, particularly in its dorsal part; it appears to be differentiated cytoarchitectonically into stellato- and rotundo- cellular parts as described by Krieg (1948) in the macaque. The stellate cells are found along the dorsal surface of the thalamus while the rotund cells are more closely applied to the median plane. These cells, whether stellate or rotund, are mostly medium sized, stain moderately well, and are arranged rather compactly near the dorsal ventricular wall throughout the extent of the anterior part. The posterior part of n. paraventricularis consists mainly of round cells that are arranged along the wall of the third ventricle from the stria medullaris and the habenular region dorsally to n. parafascicularis ventrally. It has a short caudal extent, and is replaced by the posterior commissure. Both parts of n. paraventricularis have the same myelin content; fine fibres connect this nucleus with the periventricular system of the diencephalon. N. paraventricularis in Elephantulus myurus is heteromorphous and anisoformic because it exhibits more than one type of cell, and there is a mixture of cells of different shapes in this nucleus.

2. TUPAIIDAE

N. paraventricularis is the longest and most constant of all the midline nuclei. At the level of the caudal end of n. parataenialis, the nucleus can be divided easily into anterior and posterior parts, but this division is based rather more on cytological than topographical differences. The <u>anterior part</u> consists of small cells (11 x 7 μ) that are dark-staining and fusiform; they lie very close to the ventricular wall, and extend ventrally towards the hypothalamic sulcus. It is related laterally to nn. parataenialis and anterodorsalis, and ventrally to nn. rhomboideus, interanterodorsalis and interanteromedialis. N. paraventricularis pars anterior may be differentiated cytoarchitectonically into stellate and round cells, but intermingled with these cells are a few fusiform cells, so that they cannot be separated into dorsal and ventral parts as in *Elephantulus*. The round cells, however, constitute most of the dorsal part of the interthalamic adhesion.

The <u>posterior part</u> of n. paraventricularis is best seen at the level of the rostral part of n. habenularis pars medialis. It can be distinguished topographically from the anterior part of the same nucleus as a column of small, dark-staining and rather compactly packed cells lying beneath the habenular nucleus, lateral to the caudal part of n. mediodorsalis, and dorsal to n. parafascicularis. It is replaced abruptly by the bed nucleus of the posterior commissure.

3. PROSIMII

(a) *Lemuroidea*

The topographical and architectonic features of n. paraventricularis (Figs.53-58; 62-68; 71-78) are much the same as in the Tupaioidea. The topographical delimitation of this nucleus into anterior and posterior parts is more artificial than the differentiation into stellate and round cells which are still detected in the lemurs. Larger, dark-staining, fusiform or stellate cells tend to occupy the area close to the ependymal surface of the third ventricle, i.e., in the *dorsal* part of the midline nuclear region, while the round cells appear to occupy the *ventral* part. N. paraventricularis elongates dorsoventrally and remains in this position until it approaches the rostral part of n. habenularis pars medialis. There it becomes shorter and is applied very closely to the wall of the third ventricle until it is replaced by the posterior commissure. In *Microcebus murinus*, n. paraventricularis is better developed and possesses distinctive stellate and rotund celled portions, particularly in its anterior part.

(b) *Lorisoidea*

Perodicticus potto and *Galago species*

N. paraventricularis (Figs.86-96; 97-104; 107-112) is seemingly smaller than in the Lemuroidea, and is applied more closely to the ventricular wall and along the median plane ventrally. It is also arbitrarily divided into anterior and posterior parts, but this delimitation is less distinct in *Galago crassicaudatus* and *Perodicticus potto* than in other lorisoids. This may be due partly to the well defined individuality of the midline nuclei and the large size of the interthalamic adhesion and partly also to its confinement to the dorsomedial surface of the thalamus and to the ventricular wall throughout its extent. N. paraventricularis is very long rostrocaudally beginning at the level of the interventricular foramen and ending at the level of the rostral pole of n. habenularis pars medialis. It is a fairly thick mass of small, dark-staining, fusiform cells (11 x 4 μ); their axes lie parallel to the surface of the ventricular wall. The myelin content of n. paraventricularis is sparse; fine thread like-fibres traverse it, thus indicating its relationship to the periventricular system.

Unlike in the Tupaioidea, n. paraventricularis is mono-morphous and anisoform.

(3) ANTHROPOIDEA

(i) Cercopithecidae

Cercopithecus aethiops

The division of n. paraventricularis (Figs.117-122) into stellate and round cells is well observed in the vervet (Simmons 1965), while its division into anterior and posterior parts is better defined than in lower primates. N. paraventricularis pars anterior consists of medium-sized, dark-staining, round cells (15 x 12 μ); that lie medial to n. parataenialis. It has the same topographical characteristis as in prosimians, and the cellular features are more accentuated in its dorsal than in its ventral part; stellate cells predominate in the dorsal part while round cells, as well as a few fusiform cells, are found mainly in the ventral part. N. paraventricularis pars posterior contains more round than stellate cells that remain dark-staining and are arranged closely along the ventricular wall

(ii) Hominidae

Homo sapiens

N. paraventricularis (Figs.125-132) may be divided topographically into anterior and posterior parts more obviously than in other primates. The anterior part is, at first, oval-shaped at the level of the interventricular foramen, and then rectangular. Caudally, towards the habenular region, it forms a thin vertical strip of cells, n. paraventricularis pars posterior, which has the same cytological characteristics as the anterior part. It is replaced by the nucleus of the posterior commissure.

Discussion on n. paraventricularis

N. paraventricularis has been divided by most authors into anterior and posterior parts, based rather on topography than on other criteria. Krieg (1944, 1948) divided n. paraventricularis into stellato- and rotundocellular portions, based on cellular differences in the dorsal and ventral regions of this nucleus. The stellatocellular type is more prominent dorsally, while the rotundocellular type is found more in the ventral portion of n. paraventricularis, no matter whether this nucleus is divided into anterior and posterior parts, or not. However, as these parts are homologized with those of any other primate species and of non-primate mammalian species, some confusion of topographical relations of n. paraventricularis may occur. For Krieg, nn. paraventriculares anterior and posterior correspond to nn. intermediodorsalis and rhomboidalis, or n. centralis medialis of Bodian and similarly, he held that the stellato- and rotundocellular parts of n. paraventricularis corresponded to Crouch's n. interparataenialis and the medial part of n. parataenialis in the same primate species. Most investigators prefer the artificial division of n. paraventricularis, although there are slight cytological differences in this nucleus. In all my primate specimens, I have already observed that the cells of n. paraventricularis have such different sizes and shapes that they may be grouped into stellato- and rotundo-cellular parts. Thus, these cellular differences conform with Krieg's descriptions of n. paraventricularis in the rat (1944), and also with the descriptions of Toncray and Krieg (1946) in the macaque monkey, Heiner (1960) in the chimpanzee, and Simmons (1965) in the vervet monkey.

Descriptions of topographical and cytological features of n. paraventricularis do not vary much in primates, including man. Its division into anterior and posterior parts based on topography is arbitrary, but occurs generally at the level of the rostral region of the habenula. The cytological differences in n. paraventricularis, as revealed in this study, appear to be better defined in the Tupaioidea and Lemuroidea, than in the Lorisoidea. Kanagasuntheram et al. (1968) do not mention this cellular differentiation in their lorisoid specimens. Le Gros Clark's n. raphe dorsalis is actually n. paraventricularis of this study, as well as of other authors; it is continuous caudally with his n. centralis medialis which is actually n. rhomboideus in this study, since this latter nucleus lies dorsal to n. centralis medialis.

Feremutsch (1963) does not mention n. paraventricularis in his primate series, but includes it in his pars dorsalis of the periventricular grey matter, while the other midline nuclei are divided among the intermediate, ventral or basal parts. He states that the pars dorsalis (Pd) in all primates remains unchanged in its structural features, and is, therefore, the best developed of all parts of the central grey substance. It reaches its greatest development at the level of the largest cross sectional size of the anterior nucleus. It becomes smaller and narrower in its caudal extent, and continues uninterruptedly into the pars intermedia (Pi) at the level of the beginning of the habenular region. These two parts appear to homologize with the entire n. paraventricularis anterior in my primate specimens. However, in man, further confusion is added to the actual terminology of n. paraventricularis when Feremutsch has the periventricular grey mass divided into dorsal and ventral parts designated 'pm' and 'py' respectively. Even another region is included, 'pi', in this new topographical division. The part 'pm' may be considered as a homologue to both anterior and posterior parts of n. paraventricularis in primates.

Hassler (1959) classifies the midline thalamic group as the thalamic central grey substance (substantia grisea centralis thalami); this term is not supposed to denote all parts of the thalamus which are poor in or free of myelinated fibres, but certain small nuclei located within the substance. The Only two of these small nuclei which can be recognized topographically and cytologically, are <u>n. paramedianus oralis</u> and n. <u>endymalis.</u> N. paramedianus oralis is situated near the rostral end of the thalamus behind the interventricular foramen; it appears to correspond fairly well to n. paraventricularis anterior of Crouch, Walker and Olzsewski, to the pars dorsalis of Feremutsch, and to the rostral part of n. paraventricularis pars anterior in the prosimian thalamus. At the caudal end of the interthalamic adhesion, n. paramedianus oralis becomes narrower and lies close to the third ventricle at the rostral level of the habenula; this may correspond with n. paraventricularis pars posterior.

My observations on n. paraventricularis show that the dorsal part of the midline nuclear region remains stable and unchanged in all aspects throughout the primate scale; it is, however, better differentiated cytoarchitectonically in lower than in higher primates. Topographically, it is divisible arbitrarily into anterior and posterior parts with slight variations in position that may be due to progressive reduction in the size of the interthalamic adhesion. In lower primates, n. paraventricularis lines closely the wall of the third ventricle, while in higher primates, it extends further ventrally to be delimited dorsally ~~only~~ by the nuclei forming the interthalamic adhesion. It has been found that n. paraventricularis is connected rather generally with the periventricular system, but more particularly with n. mediodorsalis.

3. N. rhomboideus (RH) (Plates 1 - 38)

(1) INSECTIVORA

Macroscelidoidea
Elephantulus myurus

N. rhomboideus (Figs. 33-36) is a comparatively small structure identified easily by its diamond-shaped condensation of cells lying ventral to n. paraventricularis pars anterior, and dorsal to n. interanteromedialis. N. rhomboideus lies between the two nuclei mediodorsales; at the level of its greatest development, its lateral extensions are in the angles between nn. mediodorsalis and anterodorsalis. Above and behind the interanterodorsal commissures, n. rhomboideus is triangular in shape with its apex directed dorsally, and its broad base resting on n. centralis medialis. Caudad, n. rhomboideus is replaced by the expanding dorsal part of n. mediodorsalis and the medial part of n. parafascicularis.

(2) TUPAIOIDEA

N. rhomboideus (Figs.43-46) is diamond-shaped and larger, with longer arm-like extensions. At first, it appears as a poorly defined mass of cells lying just ventral to n. paraventricularis pars anterior, and the interparataenial commissure, anterior to the rostral pole of n. mediodorsalis, and ventromedial to n. parataenialis. At the level of replacement of the interanteromedial commissure by n. mediodorsalis, n. rhomboideus expands into a quadrilateral structure. It shifts further ventrally until it comes to be related dorsally to n. centralis medialis throughout its remaining extent. Its lateral 'arms' stretch far out above the medial extensions of n. paracentralis, but they do not come into contact with n. centralis lateralis. The cells of n. rhomboideus are mostly medium-sized (11 x 7 μ), round or oval, stain fairly well and are arranged densely in a horizontal plane. N. rhomboideus disappears at the level of the rostral pole of n. geniculatus lateralis when the centrum medianum/parafascicular complex appears; it is replaced partly by the caudal part of n. centralis medialis, and partly by n. paraventricularis pars posterior.

(3) PROSIMII

(a) Lemuroidea

N. rhomboideus (Figs.53-56; 62 & 63; 71-74) does not show any considerable differences from that of the Tupaioidea, and has the same topographical relations and cytoarchitectonic features. In *Lemur fulvus*, nn. rhomboideus and centralis medialis can be distinguished readily from each other by the smaller size and slightly more densely staining cells of the former nucleus. Where n. mediodorsalis expands rapidly in size, n. rhomboideus is relatively reduced until it merges with n. centralis medialis to form a large, diamond-shaped mass of cells, which do not, however, show uniformity in size, shape and stainability. The cells of n. rhomboideus are 11 x 8 μ.

(b) Lorisoidea

N. rhomboideus (Figs.87 & 88, 99 & 100; 107 & 108) varies in size among the lorisoids, but is mostly recognized by its diamond shape. It lies ventral to the interanteromedial commissure and n.paraventricularis pars anterior. It appears, at first, as a roughly rectangular mass of tightly packed small cells (13 x 9 μ). Caudad, n. rhomboideus enlarges rapidly, assumes its diamond shape and shifts ventrally due to the ventral extent of n. paraventricularis pars anterior, until it comes to abut on the dorsal surface of n. centralis medialis. N. interanteromedialis lies ventral to n. rhomboideus not dorsal as stated by Kanagasuntheram et al (1968) in *Galago senegalensis* and *Nycticebus coucong* , separating n. rhomboideus from n. centralis medialis. When n. interanteromedialis disappears, n. rhomboideus comes into direct contact with n. centralis medialis at the *rostral* level of the habenular region. The cells of n. rhomboideus are small since the Nissl granules are fine and distributed along the periphery of the cell body, but in *Perodicticus potto*, the Nissl granules are concentrated around the nucleus. The myelinated pattern of n. rhomboideus is the same as in other prosimians.

(4) ANTHROPOIDEA

(a) Cercopithecidae

Cercopithecus aethiops

N. rhomboideus begins at the level of n. interanteromedialis as a poorly defined, rounded structure, lying immediately ventral to the latter nucleus. Caudally, n. rhomboideus is triangular in shape and lies between the rostral halves of nn. mediodorsales on both sides of the median plane. The caudal part of n. rhomboideus lies ventral to the medial border of n. mediodorsalis, and dorsal to nn. centralis medialis and reuniens from which it becomes cellularly indistinguishable. The cells of n. rhomboideus are generally small (12 x 12 μ), polygonal and stain fairly well; they are more densely packed in the rostral part than in the caudal part where the cells are smaller than those of n. paraventricularis, but slightly larger than those of n. parataenialis. N. rhomboideus disappears at the level of the rostral pole of n. centrum medianum.

(b) Hominidae

Homo sapiens

Together with n. centralis medialis, *n. rhomboideus* forms the main bulk of the thin, slenderly formed, interthalamic adhesion. It is not well distinguished cytoarchitectonically from n. centralis medialis, but n. rhomboideus has smaller, more lightly staining and more densely arranged cells. It disappears with the interthalamic adhesion at the level of the rostral pole of n. geniculatus lateralis.

Discussion on n. rhomboideus

The descriptions of n. rhomboideus do not vary much among the authors. The existence of the nucleus is ignored even by Feremutsch (1963) who may have included it in his pars intermedia.

Le Gros Clark (1929, 1930) confuses it with n. centralis medialis in regard to its relationships with the internal medullary lamina and n. reuniens. He places n. rhomboideus between the anterior end of n. centralis medialis dorsally and n. reuniens ventrally. This topographical situation does not, however, correspond to that described by other authors, including myself, for whom n. rhomboideus is related dorsally to n. interanteromedialis and ventrally to n. centralis medialis. Bauchot (1963) terms n. rhomboideus nucleus intermedius because of its central position in the midline thalamic region, and its relationships to n. mediodorsalis. However, it is a matter of preference whether this term is used or not, as long as it is meant for the diamond-shaped structure lying above n. centralis medialis. This study has revealed that in lower primates, n. rhomboideus is the most conspicuous structure in the ventral region of the midline nuclear group, while in higher primates, it loses much of its structural identity through reduction in size and partial annexation by centralis medialis. Therefore, my observations have shown that n. rhomboideus is a regressive structure, as it is hardly identifiable in anthropoid apes and man.

4. N. centralis medialis (CM) (Plates 2 - 44)

(1) INSECTIVORA

Macroscelidoidea

Elephantulus myurus (Figs. 35 and 36)

In this species, n. centralis medialis is the most conspicuous structure in the midline nuclear region. It extends from the caudal extremity of n. interanteromedialis to the level of the habenular commissure. Laterally, n. centralis medialis is fused with n. paracentralis; dorsally, it is related, in turn, to nn. interanteromedialis, rhomboideus and mediodorsalis; ventrally, it is separated from n. submedius by its periventricular fibres. The cells of n. centralis medialis are small, round, lightly stained and compactly packed into a horizontally orientated area. It is myelin-poor; fine fibres of the periventricular system course through it from the hypothalamus.

(2) TUPAIOIDEA

N. centralis medialis (Figs.47 & 48) appears at a more caudal level than n. rhomboideus where n. ventralis anterior is replaced by nn. ventrales medialis and lateralis. At this level, n. centralis medialis is roughly rectangular, and lies between nn. rhomboideus and interanteromedialis dorsally and n. reuniens ventrally. This topographical relationship of n. centralis medialis does not correspond with the nucleus massa intermedia (NIM) as illustrated in the stereotaxic atlas of the tupaioid brain (Tigges and Shantha 1969), because the latter nucleus should be homologized with the central grey of the interthalamic adhesion, which is situated dorsally, instead of ventrally, with nn. rhomboideus and reuniens. Caudally, n. centralis medialis expands into a flattened, almost longish, diamond-shaped mass of cells. Its 'arms' stretch out laterally to fuse with the medial limbs of n. paracentralis, forming an almost circular band isolating n. mediodorsalis from the lateral thalamic mass. Towards the level of the habenular region, n. centralis medialis becomes smaller and more flattened dorsoventrally, and is replaced eventually by n. parafascicularis.

The cells of n. centralis medialis of the Tupaioidea are very small (9 x 6 μ), and are round or polygonal, lightly staining and compactly packed. N centralis medialis is very lightly myelinated.

(3) PROSIMII

Lemuroidea and Lorisoidea

N centralis medialis (Figs.53-57; 87-112) does not show any significant differences in topography and architectonics from that of the

Tupaioidea. In these prosimians, the nucleus commences more or less at the level of the rostral pole of n. rhomboideus, to which it lies ventrally, only separated from it by the interanteromedial commissure. N. centralis medialis appears to be better developed and more conspicuous in *Galago* species than it is in *Perodicticus potto* and *Lemur* species. Caudally, n. centralis medialis can be observed easily as a more densely staining and roughly diamond-shaped mass of cells whose lateral extensions are connected with the medial limbs of n. para-centralis on both sides. In myelin-stained sections, in the region of the internal medullary lamina, a band of fine myelinated fibres run through n. centralis medialis to cross the median plane. At the level of the caudal end of the interanteromedial commissure, n. rhomboideus moves ventrally to lie upon n. centralis medialis. This relationship between nn. centralis medialis and rhomboideus remains constant until the habenular region is reached. At this level, n. centralis medialis is related dorsally first to n. interventralis, and then to n. ventralis medialis, and ventrally to n. reuniens. Approaching its termination, n. centralis medialis is further reduced in size until it is replaced by n. parafascicularis.

They are medium-sized (10 x 8 $/^{u}$-Lemur to 13 x 10 $/^{u}$ -Galago), and are generally oval-shaped and stain more lightly than those of n. rhomboideus.

(4) ANTHROPOIDEA

(a) *Cercopithecidae*

Cercopithecus aethiops

N. centralis medialis (Figs. 119 and 120) is an ill-defined structure lying in the interthalamic adhesion adjacent to the rostral end of n. paracentralis with which it is continuous. It extends rostrally from the level of n. interanteromedialis to the rostral level of n. centrum medianum caudally. Throughout its rostrocaudal extent, n. centralis medialis is difficult to identify readily from n. rhomboideus dorsally, n. reuniens ventrally and n. submedius ventrolaterally. The cells of n. centralis medialis are generally medium-sized (14 x 8 μ); they are oval to polygonal in shape and stain well. They are arranged compactly, particularly at the ends where the nucleus is joined to n. paracentralis on both sides.

(b) Hominidae

Homo sapiens

N. centralis medialis is better defined than in monkeys and apes. It is also the largest of all midline nuclei, and forms the bulk of the interthalamic adhesion, thus maintaining almost the sole link between the two thalami on both sides. Its topographical relations are not much different from what have been described for other primates. Its cells are fairly large, pyramidal or oval, and stain more deeply than those of n. rhomboideus. The fibres are not densely interwoven, and run through the nucleus in the internal medullary lamina across the median plane.

Discussion on n. centralis medialis

N. centralis medialis is best developed in insectivores. It is well developed in the Tupaioidea, but not as conspicuously as n. rhomboideus; it is recognized generally by its connection with n. paracentralis. In Prosimii, n. centralis medialis is smaller and more poorly defined, and is not easily demarcated from n. rhomboideus. In higher primates, it is, however, better developed and larger than n. rhomboideus. In man, it resumes some of its former conspicuousness because it happens to form the sole internuclear link across the median plane in a much reduced interthalamic adhesion. Actually, it is an intralaminar nucleus by virtue of its connection with nn. paracentralis and centralis lateralis. Judging by its phylogenetic development in primates, n. centralis medialis is not at all a regressive structure, because it remains more or less unchanged in topography and does not undergo cytoarchitectonic changes, apart from considerable size loss in certain higher primates.

5. N. reuniens (REUN) (Plates 1-49)

(1) INSECTIVORA
and (2) PROMISII (Figs.33-112)

N. reuniens does not differ greatly in all species studied from Elephantulus myurus to Galago crassicaudatus. It may be a phylogenetically stable nucleus as it remains unchanged in structure throughout the prosimian scale.

N. reuniens is well developed and often differentiated into anterior and posterior parts. In all prosimians, n. reuniens makes its appearance in the rostral part of the thalamus at the level of n. paraventricularis hypothalamicus, but slightly caudal to nn. parataenialis and paraventricularis. N. reuniens is, at first, a small, ill-defined mass of small, dark-staining and fusiform cells lying just above (dorsal to) the hypothalamic 'roof'. It does not, however, expand much in size, but caudalwards, its relationships with adjoining nuclei change. Rostrally, n. reuniens is related dorsally at first to n. paraventricularis pars anterior, then to nn. rhomboideus and centralis medialis, and laterally to nn. submedius and medioventralis, and then to n. ventralis medialis. Towards its caudal end, n. reuniens is related dorsally first to the caudal part of n. centralis medialis, and to n. paraventricularis pars posterior; dorsolaterally to n. ventralis posteromedialis and ventrolaterally to nn. centrum medianum and parafascicularis. N. reuniens is replaced at the level of the posterior commissure by n. paraventricularis pars posterior or n. parafascicularis.

In the cells of n. reuniens in all prosimians, the Nissl granules are either hardly ever seen or scattered sparsely in the cytoplasm. In the Tupaioidea, n. reuniens is divided into anterior and posterior parts on cytoarchitectonics. The anterior part contains loosely arranged, medium-sized cells (12 x 8 µ) which stain fairly well, and are polyhedral or stellate in shape; these cells lie between n. interventralis dorsally and the roof of the third ventricle ventrally. The posterior part of n. reuniens has smaller and more darkly staining, fusiform cells that lie immediately ventral to n. centralis medialis, and then to n. paraventricularis pars posterior, before it disappears at the level of the posterior commissure. These cellular parts are not present in lorises and galagos and are poorly defined in the lemurs, as n. interventralis may be large enough to prevent such a division from taking place in n. reuniens and to limit the latter nucleus to the area above the roof of the third ventricle.

(3) ANTHROPOIDEA

(a) Cercopithecidae

Cercopithecus aethiops

Rostrally, n. reuniens (Figs. 117-120) is identified easily as a small mass of cells lying ventral to nn. centralis medialis and rhomboideus, and medial to n. ventralis medialis. Its division into anterior and posterior parts is not well defined in the vervet. The cells of n. reuniens are medium-sized to large (18 x 16 µ), being slightly larger than those of n. rhomboideus; they are rather fusiform, stain fairly darkly , and are loosely distributed. At its caudal end, n. reuniens can be distinguished rather easily from n. submedius which lies slightly dorsolateral to it.

(b) Hominidae

Homo sapiens (Figs. 125-130)

N. reuniens is a well-defined structure which is the most ventrally situated of all midline nuclei. It is, too, one of the constituents of the interthalamic adhesion if it is present in the human thalamus. It extends from the caudal end of the anterior nuclei to the middle part of the interthalamic adhesion. It lies dorsal to the dorsal hypothalamic area. The cells of n. reuniens are medium-sized, oval shaped and they stain better than those of other midline nuclei. It is more myelinated than those of other primates, due to its close relationship to the hypothalamic periventricular fibre system.

Discussion on n. reuniens

N. reuniens appears to be better developed in lower than in higher primates, and it may even be differentiated into anterior and posterior parts. It becomes more and more poorly defined as one ascends the primate scale. Although n. reuniens is essentially an unpaired structure, it tends to be split into two bilateral parts, as has been observed in the Tupaioidea, thus confirming Le Gros Clark's description of n. reuniens in Tupaia minor. However, in Tarsius, this author confused n. reuniens with n. submedius by virtue of its slight paramedian position. The division of n. reuniens into anterior and posterior parts is more clearly evident in the Tupaioidea than in all prosimians used in this study. In higher primates, like nn. paraventricularis and centralis medialis, n. reuniens is still a distinguishable structure, even in a much smaller interthalamic adhesion. In anthropoids apes and in man, n. reuniens comes into a much closer relationship with nn. centralis medialis and interventralis, even if the interthalamic adhesion is not present. Therefore, n. reuniens is a stable rather than a regressive structure in the phylogeny of the primate thalamus.

6. N. interventralis (IV) (Plates 9 - 45)(Figs. 58 - 122)

N. interventralis is identified rarely as a distinct entity and is considered often as a pars reuniens of n. ventralis medialis or the caudal part of n. reuniens. It is well defined, however, in insectivores, tupaioids and certain prosimian species as the most ventrally and caudally situated nucleus in the midline nuclear group. It appears rostrally between nn. reuniens and submedius, and caudally between the internal medullary lamina and the dorsal hypothalamic area. Thus, it is confused sometimes with n. reuniens of Campbell and Ryzen (1953) and with n. reuniens pars posterior of Bodian (1939). Furthermore, the cells of n. interventralis are much smaller than these of n. ventralis medialis. Caudally, n. interventralis is in a region of transition where the dorsal hypothalamic area is difficult to distinguish from the mesencephalic tegmentum.

SUMMARY OF THE MIDLINE THALAMIC NUCLEAR GROUP

The midline nuclear group happens to reach its peak of phylogenetic development in the prosimians, particularly in the Lemuroidea, in which the nuclei are well developed and clearly defined anatomical units. In lower prosimians, as well as the insectivore Elephantulus, and the Tupaioidea, the nuclei occupying the dorsal part of the midline region are better demarcated from one another than in higher forms. In higher prosimians, when the interthalamic adhesion becomes reduced in size, these dorsally situated nuclei, such as nn. parataenialis, paraventricularis, interanterodorsalis, interanteromedialis and rhomboideus, are less clearly defined and tend to overlap one another. The ventrally situated midline nuclei such as nn. centralis medialis, interventralis and reuniens, remain stable and unchanged in all aspects throughout the primate scale. Cytoarchitectonic divisions and cellular distinctions of all the midline nuclei are more pronounced in lower than in higher primates. My observations indicate that the midline thalamic nuclear group shows positive signs of regression, as expansions of the mediodorsal thalamic nucleus, on the one hand, and the ventrolateral thalamic mass, on the other hand, have apparently crowded the midline nuclei into a much smaller space.

Whether the interthalamic adhesion is present or not, particularly in the human thalamus, certain elements of the midline thalamic region, such as nn. paraventricularis, centralis medialis and reuniens are readily identifiable and structurally definable.

The histological features and evolutionary trends of the midline thalamic nuclei are given in Table 11.

TABLE 11. SUMMARY OF THE MIDLINE THALAMIC NUCLEAR GROUP

Features	N. parataenialis (PT)	N. paraventricularis (PV)	N. rhomboideus (RHOM)	N. centralis medialis (CM)	N. reuniens (REUN)	N. interventralis (IV)
STRUCTURAL FEATURES	Larger and better developed in *Elephantulus*; is slightly reduced in *Tupaia*, and is the smallest of all midline nuclei in all primate species. Is closely related to the stria medullaris. N. interparataenialis is present only in prosimians up to the Lorisidae. No architectonic divisions.	Larger in *Elephantulus* and *Tupaia* than in prosimian and simian species, is divisible into anterior and posterior parts; is mostly confined to the wall of the third ventricle. N. interparaventricularis is present only in lower prosimians.	Is the largest midline nucleus in *Elephantulus*, *Tupaia* and certain prosimians, particularly in lemuroids. Starts reduction in size and extent, and fusing with CM from the Galagidae through the Anthropoidea to man. Generally a diamond-shaped structure with large lateral extensions lying dorsal to CM and IC, but not reaching to n. centralis lateralis.	Better developed and more conspicuous in the Lorisidae than in *Tupaia* and the Lemuridae. Partly replaces RHOM and becomes the largest midline nucleus in higher primates. Is clearly connected with n. paracentralis and forms part of the anterior intralaminar region	Rather poorly defined but constantly present throughout the primate scale. Is divided arbitrarily into anterior and posterior parts only in certain prosimians. Is most ventrally and rostrally situated of all the midline nuclei. Is confused often with nn. submedius and medialis ventralis because of its slightly paramedian situation.	Is more distinctly formed in prosimians as well as *Elephantulus* and *Tupaia* than in other midline commissural nuclei. Is identified lying between CM and REUN dorsoventrally, and between the medial ends of n. centralis medialis. Is still present in higher primates but absent in man.
CELLULAR PROPERTIES	Generally small, and less darkly staining and more loosely arranged than those of PV. No cellular divisions. Cells are ~~Type [illegible]~~; scanty Nissl substance. Size of cells varies a little to - between 12 x 9 /u and 14 x 10 /u.	Generally small and dark-staining; varies in shape - round, stellate or fusiform, thus, leading to the idea of grouping cells of PV into stellate and rotund parts ([illegible] 1948). These cellular divisions are evident in the Lemuroidea, but not in the Tupaioidea and Galagidae. Scanty Nissl substance - ~~[illegible]~~. Size of cells is slightly varied (11 x 6 /u *Galago* to 15 x 12 /u - *Cercopithecus*). Cells are mostly densely arranged in a dorsoventral plane close to the wall of the 3rd ventricle.	Cells are mostly small (11 x 7 /u - *Tupaia* to 13 x 12 /u - *Cercopithecus*) are oval or round, more lightly staining than in PV; more densely packed than in CM ~~([illegible])~~. No cellular orientation in all primate species, as well as in *Elephantulus* and *Tupaia*.	Cells are generally small, but are larger than those of RHOM (9 x 6 /u - *Tupaia* to 18 x 14 /u - *Cercopithecus*). Stain better than those of RHOM, but more lightly than those of PV. ~~[illegible]~~ Cells are arranged compactly in a mediolateral direction.	Generally small, but increases in size (10 x 7 /u - *Galago* to 18 x 16 /u - *Cercopithecus*). Oval or fusiform, well staining, but not as darkly as those of PV. ~~[illegible]~~. Loose cell distribution in a dorsoventral direction.	Medium-sized cells, larger than those of other midline nuclei. Similar cytological features to those of VM ~~([illegible])~~. Cells are arranged densely in a horizontal manner.
FIBRE CONTENT AND ARRANGEMENT	Fine fibres radiating through nucleus from SM; is more darkly myelinated than PV. No change in myelin content throughout the primate scale.	Very fine myelinated fibres coursing through the nucleus. No change in myelin content throughout the primate scale.	Lightly myelinated area fibres run dorsoventrally through it towards the hypothalamus.	Lightly myelinated area; horizontal band of fibres runs through it from one side to the other across the median plane. This fibrous band is present even in a much reduced interthalamic adhesion in higher primates.	Slightly more densely myelinated than other midline nuclei; fibres run in both directions dorsoventrally and mediolaterally.	Distinctive fibrous band lying below CM; fibres cross the median plane from one VM to the other VM.
PHYLOGENETIC TRENDS	Varies between stability and regression in prosimians, but is definitely a vestigial structure in higher primates and man.	One of the most stable elements of the thalamus and remains unchanged in all features, except a slight reduction in size. PV of *Tupaia* shows an intermediate stage of development.	Positive signs of regression in prosimians. Shifts from dorsally to ventrally in higher prosimian forms. Is much reduced in size in higher prosimians, and is absent in man.	Is more or less stable in its phylogeny from *Tupaia* to man. Forms the dorsal and main part of the interthalamic adhesion.	No significant phylogenetic changes, and is, therefore, a very stable structure with a certain degree of cytoarchitectonic differentiation. Forms the *ventral* part of the interthalamic adhesion in higher primates.	No significant phylogenetic characteristics; merely acts as a connection between the ventral thalamic nuclei on both sides

CHAPTER 7

THE THALAMUS: MEDIAL AND INTRALAMINAR NUCLEAR GROUPS

The medial nuclear group comprises mainly n. mediodorsalis (or n. medialis in higher primates) and some small, insignificant nuclei, while the intralaminar group consists of nuclei lying within the internal medullary lamina. These latter nuclei are grouped on topographical grounds into anterior and posterior parts. The nuclei forming the medial and intralaminar nuclear groups are:

1.	N. mediodorsalis (MD)	medial thalamic nuclei
2.	N. medioventralis (MV)	
3.	N. submedius (SUM)	
4.	N. paracentralis (PC)	anterior intralaminar nuclei
5.	N. centralis lateralis (CL)	
6.	N. subparacentralis (SPC)	
7.	N. centrum medianum (CEM)	posterior intralaminar nuclei
8.	N. parafascicularis (PF)	
9.	N. subparafascicularis (SPF)	

1. N. mediodorsalis (MD) (Plates 2 - 52)

(1) INSECTIVORA

Macroscelidoidea

Elephantulus myurus (Figs.35-38)

N. mediodorsalis is a small, well developed structure which replaces n. parataenialis caudally. It appears to correspond to the medial part of the nucleus of the same name in primates. As n. mediodorsalis increases progressively in size, it is differentiated cytoarchitectonically into a principal, a dorsolateral and a ventromedial part. The *principal* part contains medium-sized, rather darkly staining and fusiform cells enmeshed in a thick network of fibres. The *dorsolateral* part has smaller and more deeply staining cells lying ventral and medial to nn. parataenialis and habenularis. The *ventromedial* part has larger, well-staining and polyhedral cells that are related ventrally to nn. anteroventralis, paracentralis and parafascicularis. Generally, n. mediodorsalis is a well-organized, monomorphous and anisoform structure. It is connected across the midline by a large internuclear commissure, n. commissura intermediodorsalis, which lies caudal to n. interanteromedialis and dorsal to n. centralis medialis.

(2) TUPAIOIDEA

In this suprafamily, n. mediodorsalis (Figs.45-50) appears to have undergone a marked evolutionary change from that of the Insectivora. It is much larger and more conspicuous than that of the Macroscelididae, and is even better demarcated by the internal medullary lamina from the adjacent lateral nuclei. N. mediodorsalis commences as a small collection of cells at the level of the caudal end of n. anteromedialis which lies ventral to it. Caudalwards, n. mediodorsalis increases in size, until at the level of the rostral pole of n. centrum medianum, it fills most of the medial region of the thalamus. Here, n. mediodorsalis is related medially and dorsally to the internal medullary lamina, ventrally to nn. parataenialis and paraventralis pars anterior and medially to the ventrolateral thalamic mass. The interanteromedial commissure is not present in the Tupaioidea, and n. mediodorsalis is separated completely from its opposite fellow by the central grey mass of the interthalamic adhesion. N. mediodorsalis maintains its greatest cross sectional size further caudally towards the level of the habenular region where it becomes progressively smaller, and is then displaced to a more dorsal position by the centrum medianum/parafascicular complex. At the level of the habenulopeduncular tract, the dorsal part of n. mediodorsalis is replaced by n. pretectalis, while the ventral part merges with n. parafascicularis.

N. mediodorsalis can be divided quite distinctly, on grounds of cytological and architectonic differences, into two parts, a larger dorsomedial part (that corresponds with the principal part of the Macroscelididae) and

and a smaller ventrolateral part. The dorsomedial part contains large, dark-staining, polyhedral cells ($16 \times 10\ \mu$); these are arranged loosely in a dorsolateral relationship to n. paraventricularis pars anterior, and a ventromedial relationship to n. centralis medialis. The ventrolateral part contains mostly small, lightly staining, round cells ($11 \times 9\ \mu$); that are more compactly packed and are related medially to the ventrolateral thalamic nuclear mass.

A third division, a posterolateral part, which has been described in the monkey by Walker (1937) and by Simmons (1965), can be observed with some difficulty in the caudal region of n. mediodorsalis. It is a very small area containing cells which are larger and more darkly staining than those of the dorsomedial part, and arranged more densely along the ventral border of n. mediodorsalis close to n. paracentralis.

(3) PROSIMII

Lemuroidea and Lorisoidea (Figs.54-78; 89-112)

In all of these prosimians, n.mediodorsalis (Figs.54-78; 89-112) appears to have reached a peak of structural growth and differentiation; it has undergone a remarkable change from a small, inconspicuous and cytoarchitectonically rather homogeneous nucleus, as in non-primate mammals, to an enormous, heterogeneous and highly differentiated structure as in primates. But in the prosimians, it shows only a slight increase in relative size, and is not yet differentiated into several cytoarchitectonically distinct areas as in higher primates.

The features described for this nucleus in the Tupaioidea are not very different in the Lemuroidea, except for its caudal part in the posterior region of the thalamus. However, n. mediodorsalis can still be differentiated cytoarchitectonically into three parts that correspond with the parts of the same nucleus in higher primates. N. mediodorsalis appears rostrally at the level of the caudal pole of n. anteromedialis, or of the caudal end of n. parataenialis; it terminates caudally at the level of emergence of the habenulopeduncular tract from the habenular region. In the rostral thalamic region, n. mediodorsalis is related *ventrolaterally* to n. paraventricularis pars anterior, the rostral part of n. rhomboideus and n. interanteromedialis, *dorsally* to n. anteromedialis, *dorsomedially* to n. anteroventralis, and *laterally* to n. parataenialis and the stria medullaris. These relationships are changed at the level where the anterior and parataenial nuclei disappear, and n. mediodorsalis comes to lie ventrally close to the dorsal surface of the thalamus, ventrolateral to n. paraventricularis anterior, and dorsolateral to the caudal part of n. rhomboideus and the rostral part of n. centralis medialis. Its entire ventral border is separated from n. paracentralis by the internal medullary lamina which demarcates n. mediodorsalis from the medial parts of nn. ventrales lateralis and posterior. The lateral relations of n. mediodorsalis are the dorsolateral thalamic nuclei from which it is demarcated by the intralaminar nuclei. Thus, n. mediodorsalis appears as a neatly circumscribed structure which is larger in area than all the ventral posterior nuclei put together. At the level of its greatest size, n. mediodorsalis is divided clearly into a large dorsomedial and a smaller ventrolateral part, each part having different cytological features similar to those described already for the Tupaioidea. The third division, the posterolateral part, is better developed in *Galago* than in *Lemur*, but in the latter genus, it is a thin, crescent-shaped structure spread along the ventrolateral surface of n. mediodorsalis; its cells are smaller, more darkly staining, fusiform cells than those of n. paracentralis.

In *Perodicticus potto*, n. mediodorsalis is divided rather distinctly into medial and lateral parts, not into dorsomedial and ventrolateral parts, as observed in other prosimians. It has a smaller posterolateral portion which appears to be concentrated on the lateral surface of n. mediodorsalis, and whose cells are much larger and more darkly staining than those of the lateral part of n. mediodorsalis. The *lateral part* of n. mediodorsalis appears to be differentiated into two smaller ventromedial and ventrolateral portions, each possessing distinctive cytological characteristics. The *medial* part of n. mediodorsalis consists mainly of large, well staining, polygonal and fusiform cells that distinguish it from the smaller and lighter-staining, round cells of the lateral part.

In all prosimians used in this study, n. mediodorsalis is a heteromorphous, almost dimorphic, and very anisoformic structure; its cells vary in size and nuclear classification (14 x 10 μ in *Galago* to 22 x 15 μ in *Cercopithecus* in the dorsomedial part of n. mediodorsalis; 14 x 8 μ in *Galago* to 20 x 14 μ in *Cercopithecus* in the ventrolateral part of n. mediodorsalis.
The myeloarchitectonic features are characteristic, the fibres being generally well myelinated, and more densely concentrated in the medial than in the lateral parts of n. mediodorsalis. A network of finely myelinated fibres is arranged along its ventral and lateral borders. A thick strand of myelinated fibres runs dorsoventrally in the form of 'dashes and dots' through the medial part of n. mediodorsalis towards the ventral region of the diencephalon; it is possibly the superior thalamic peduncle which conveys fibres to the frontal lobe of the cerebral hemisphere.

(4) ANTHROPOIDEA

(a) *Cercopithecoidea*

Cercopithecus aethiops (Figs. 119-124)

N. mediodorsalis or *n. medialis* is now the largest structure in the medial thalamic region, and its rostrocaudal extent is the longest of all thalamic nuclei. N. medialis extends from the level of the middle of n. anteromedialis where the mamillothalamic tract penetrates its inferomedial border to the level of the habenular commissure. The division into medial and lateral parts is based on cytoarchitectonics rather than on myeloarchitectonics. The *medial* part of n. medialis (MM) contains a richer myelin network, and an irregular distribution of medium-sized to large cells (16 x 14 μ - 26 x 16 μ) that stain well and are mostly polyhedral in shape.

The *lateral* part of n. medialis (ML) is better developed in the caudal regions of the same nucleus than is the medial part; it contains fewer myelinated fibres, and well arranged, darkly staining multipolar, medium-sized cells (20 x 14 μ). The posterolateral part is much larger than that of n. mediodorsalis in lower primates, and is situated in the caudolateral region of n. medialis. This is the magnocellular part of Crouch (1934) and of Aronson and Papez (1934) (MLm). It corresponds to the ventrolateral part of n. mediodorsalis in lower primates, and to the posterolateral part of n. medialis in higher primates.

Further caudally, n. medialis is composed mainly of the lateral part, which is devoid of myelinated fibres, and contains small, fairly well staining cells. Rostral to the habenular commissure, n. medialis is replaced by the medial part of n. pulvinaris pars superior.

(b) *Hominoidea*

Homo sapiens (Figs. 127-136)

N. medialis is the third largest nucleus in the human diencephalon, after nn. ventralis posterior and pulvinaris. N. medialis occupies the dorsomedial part of the middle thalamic region, extending rostrally from the caudal pole of n. anteromedialis to the caudal end of n. ventralis posterolateralis caudally. It is divided distinctly into a medial and a lateral part, the latter containing a small posterolateral magnocellular portion. The cellular characteristics vary greatly in size, shape and stainability; therefore, n. medialis in man is a heteromorphous and anisoformic structure. A rich network of myelinated fibres runs from ventrolaterally to dorsolaterally, while medium-sized bundles of fibres radiate in all directions throughout the nucleus.

Discussion of n. mediodorsalis

The medial and intralaminar nuclear groups form a part of the phylogenetically older thalamus (palaeothalamus) which is dominated by the classical nucleus medialis or n. mediodorsalis of lower primate and non-primate mammalian forms. N. mediodorsalis is probably phylogenetically younger than the anterior nuclei since in reptiles the anlage of the caudal end of n. anterior appears possibly as n. dorsomedialis anterior or n. rotundus.

N. mediodorsalis is a comparatively small nucleus in lower mammals, but increases in size and structural complexity as one ascends the mammalian scale towards the primates. In non-primate mammalian forms, n. mediodorsalis possesses a well-defined internuclear commissure, the commissura intermediodorsalis (IMD), which has been described in the armadillo by Papez (1932) and in the opossum by Bodian (1939). But this commissure has been found, in this study, not to be present in the tree-shrews and all primates.

In rodents, n. mediodorsalis is large and well differentiated into medial and lateral cellular parts (Gurdjian 1927, Holmes 1953, Hess 1955 and Herbert 1962). The magnocellular part of n. mediodorsalis was not described until, in the rat, Krieg (1944) identified it lying in the caudolateral portion of n. mediodorsalis. This portion is a homologue of the posterolateral part of n. medialis of higher primates. In carnivores, n. mediodorsalis appears to reach its peak of development, being, not only the largest nucleus in its own group, but also one of the largest diencephalic structures. However, when it is compared with that of primates, it is relatively smaller and cytoarchitectonically more primitive. In carnivores, the intermediodorsal commissure is either poorly developed or absent, due to the presence of well-formed midline nuclei in the interthalamic adhesion. In the Cetacea, n. mediodorsalis is as well developed and as large as that of the carnivores, but it is a much simpler and more homogeneous structure than that of primates. In primates n. mediodorsalis retains its large size, but is compressed posteriorly and dorsally by the expanding lateral nuclei and pulvinar. The intermediodorsal commissure is absent, and the three divisions can be observed clearly in the primate medial nucleus.

Allison (1947) describes three divisions in his macroscelidoid species - a mediocellular principal part, a parvocellular dorsolateral part, these two parts being related dorsally to nn. parataenialis and habenularis, and a magnocellular ventral part that is related ventrally to the anterior and intralaminar nuclei. These parts correspond well to those of n. mediodorsalis in Elephantulus myurus, the tree-shrews and all prosimians, and to the dorsomedial, ventrolateral and posterolateral parts of higher primates in this study. However, Walker (1938) regarded the magnocellular part as a medial part of n. parafascicularis in the chimpanzee, since it appears to merge with the latter nucleus at the level of the caudal end of n. medialis. In the Insectivora Bauchot (1959, 1963) retains the term n. medialis pars reuniens instead of n. intermediodorsalis, since he uses the term n. medialis instead of n. mediodorsalis, so as not to confuse it with n. dorsalis of his lateral nuclear group. He maintains that n. medialis pars reuniens is a well formed structure in all his insectivore and prosimian specimens. This study has revealed that it is definitely not present in Tupaia glis and Galago demidovii, since the structure homologous to this nucleus is either n. rhomboideus, or the central grey substance of the interthalamic adhesion that separates the two nn. mediodorsales from each other. In *Tupaia minor*, Le Gros Clark (1929) describes n. mediodorsalis as n. medialis which is divided into medial and lateral parts. The medial part consists of sparsely distributed, medium-sized, round cells. The lateral part is much smaller than the medial part; it contains a few large, dark staining fusiform or multipolar cells which are aligned along the ventrolateral border of n. medialis. The latter part corresponds to the ventrolateral part of n. mediodorsalis of *Tupaia minor*, as well as of other tupaioids in this study.

Bauchot (1963) observed, in his prosimian species, that n. mediodorsalis is replaced rather abruptly by n. parafascicularis, which is identified easily by the presence of fibres of the habenulopeduncular tract that run through its substance towards the interpeduncular nucleus. However, in this study, it has been found that n. parafascicularis appears to replace n. centralis medialis, not the caudal part of n. mediodorsalis, as the latter nucleus disappears farther caudally when n. parafascicularis appears to expand dorsalwards. Thus, it is apparent that n. parafascicularis might have developed directly from the internal medullary lamina, particularly from n. paracentralis.

In *Lemur catta*, the dorsomedial and ventrolateral parts correspond rather well to the medial (mx) and lateral (mo) divisions of Pines's nucleus mediodorsalis in the same species (1927). The latter division has been compared by Feremutsch (1963) to the medial part of n. pulvinaris in his lemuroid species, since the subdivisions of the latter nucleus correspond well to the rostral portion (mapg) and a caudal portion (mapa) of Pines's nucleus 'ma'. However, these divisions are not homologous to any part of n. mediodorsalis or n. pulvinaris pars superior in the lemuroids used in this study.

Bauchot (1963) has n. mediodorsalis of *Galago demidovii* divided into two basic parts - M_1 which is medial and magnocellular, and M_2 which is ventrolateral and parvocellular. These parts correspond rather easily with the dorsomedial and ventrolateral parts of n. mediodorsalis in all *Galago* species, and to the medial and lateral divisions of the same nucleus in *Perodicticus potto*. The third division, the magnocellular part, has not been mentioned either by Bauchot, or by Kanagasuntheram et al (1968) in all these species.

In *Tarsius*, n. mediodorsalis is a large, spheroidal mass of cells that is well circumscribed by the internal medullary lamina. Le Gros Clark (1930) had this nucleus divided, on cytoarchitectonic grounds, into a medial and a lateral part which are homologous with those of n. medialis in his tupaioid species. The medial part of n. mediodorsalis of *Tarsius* is homologous also with the large-celled element in *Cercopithecus* (Friedemann 1912) and with Pines's nucleus 'm ' in *Lemur catta*. Lateral to this region is the lateral part of n. mediodorsalis which corresponds well to the ventrolateral part of the same nucleus in these same species.

Finally, the observations of n. mediodorsalis in my prosimian specimens show that this nucleus is in the intermediate stage of phylogenetic development from a simple and undifferentiated structure, as in *Elephantulus*, to a supernucleus containing several cytologically distinct areas as in higher primates. The lateral part of n. mediodorsalis of Prosimii maybe homologous to the posterolateral part of n. medialis of the Anthropoidea.

In this study it has been observed also that the proportion of small cells to large cells, concomitant with the sizes of medial and lateral parts, changes on ascending the primate scale from *Tupaia* to *Homo*. At first, in *Elephantulus*, n. mediodorsalis is composed almost entirely of large cells, but in the Tupaioidea, the proportion of large cells to small cells begins to change, due to cellular differentiation of n. mediodorsalis into medial and lateral parts. The ratio of small cells to large cells increases in the Lemuroidea, as evidenced by the presence of numerous small cells in the ventral and lateral parts of n. mediodorsalis. In *Perodicticus potto*, the lateral parvocellular part is markedly larger than the medial magnocellular part, thus, confirming the statement of Kanagasuntheram et al (1968) that the proportion of small cells to large cells is larger than in lower prosimians. In the vervet, (Simmons 1965), there is a definite trend towards a *smaller* medial magnocellular and a *larger* parvocellular part of n. medialis. This cellular differentiation in n. medialis may be correlated with the phylogeny of the neocortex, since the cortical areas lying anterior to the precentral cortex receive a very large projection of fibres from the lateral part of n. medialis. The medial part of the same nucleus is connected with the hypothalamus and lower centres (Walker 1936, 1959; Sheps 1945, Meyer et al., 1947; Freeman and Watts, 1948 and McLardy 1950).

2. *N. medioventralis* (MV) (Plates 2 and 11)

(i) *INSECTIVORA*

Macroscelidoidea

Elephantulus myurus

N. medioventralis (Figs.35-36) is a small, well-defined structure that replaces n. interanteromedialis caudally. N. medioventralis can be confused topographically with n. submedius which lies dorsal to it. The former nucleus is bounded ventrolaterally by the mamillothalamic tract, laterally by n. ventralis medialis and medially by n. centralis medialis. N. medioventralis contains mostly small, moderately well-staining and round cells, with better myelinated fibres than n. submedius. N. medioventralis is intimately related to the intralaminar and midline nuclei, and may contribute some fibres to the inferior thalamic peduncle.

(2) TUPAIOIDEA

N. medioventralis is present also in the tree-shrews, but is less well defined and smaller in size, thus, showing clear signs of regression, while n. mediodorsalis becomes larger and functionally more important. At the level of disappearance of n. interanteromedialis, n. medioventralis comes to be related ventrally to n. submedius, and medially to nn. centralis medialis and paracentralis. As the ventral nuclei expand in size, n. medioventralis is replaced abruptly by n. ventralis medialis.

(3) PROSIMII

In Lepilemur (Fig. 54) and the Galagidae n. medioventralis can be identified only with considerable difficulty as a small, ill-defined group of small, dark-staining cells lying close to the medial end of n. paracentralis. N. medioventralis is replaced rapidly by n. submedius at the level of n. ventralis medialis.

In Perodicticus potto and Lemur, n. medioventralis cannot be identified, because it can be confused easily with n. submedius.

(4) ANTHROPOIDEA

N. medioventralis has not been identified in the vervet monkey and man; therefore, it may be absent in higher primates.

3. <u>N. submedius (SUM)</u> (Plates 21-66)

(1) INSECTIVORA

Macroscelidoidea

Elephantulus myurus

N. submedius (Figs.35 & 36) is an ovoid mass of small, lightly staining, round cells that are slightly larger than those of n. medioventralis. N. submedius is related laterally to n. centralis medialis, ventrally to n. medioventralis and dorsally to n. reuniens. It is slightly better myelinated and has more fibre connections with the midline and medial thalamic regions than n. medioventralis.

(2) TUPAIOIDEA

N. submedius (Figs.45-47) is better developed as a distinctly large group of medium-sized, well-staining, oval-shaped cells lying in the rostral part of the thalamus (15 x 11 /^{u}).

Since this nucleus lies anterior to the rostral part of n. mediodorsalis, it is related closely to the anterior thalamic nuclei, particularly because its cells resemble those of n. anteromedialis, to which n. submedius lies ventromedially. At the level of the caudal end of the interanteromedial commissure, n. submedius increases slightly in size, and comes to lie dorsolateral to n. reuniens and ventromedial to the rostral pole of n. mediodorsalis. N. submedius is replaced by n. ventralis medialis at the level of appearance of n. interventralis.

(3) PROSIMII

In the Lemuroidea and Lorisoidea, *n. submedius* (Figs. 54-74; 81-103) has the same topographical and cytological features as in the Tupaioidea. Generally, it is a monomorphous and isoformic structure; its cells are small (12 x 9 /^{u}) in both families , and fine, thread-like fibres course through it towards the internal medullary lamina.

(4) ANTHROPOIDEA

In the vervet monkey, *n. submedius* (Figs. 117-120) is a much smaller structure lying lateral to the mamillothalamic tract, ventrolateral to nn. centralis medialis and rhomboideus, and dorsolateral to n. reuniens. The cells of n. submedius are slightly larger than those of the latter two nuclei (21 x 13 μ), and are stellate, stain darkly and are sparsely distributed. N. submedius is either not present or poorly developed in man.

Discussion on nn. medioventralis and submedius

N. medioventralis (or n. medialis ventralis) is better developed in the Insectivora and Prosimii. It lies ventral to n. submedius.

N. medioventralis was termed, in *Lemur catta*, by Pines (1927) n. medioventralis 'mvv' while n. submedius is his 'mv'; it may denote that this author has identified n. medioventralis as a structure lying ventral to n. submedius. In the lemuroids used in this study, n. medioventralis lies dorsomedial to n. submedius, while in the tupaioids, n. medioventralis lies ventrolateral to the latter nucleus. Since there is a tendency to confuse these two nuclei, n. medioventralis is hardly ever mentioned in the literature on the primate thalamus. Some authors substituted n. submedius in its place (Le Gros Clark 1932, Krieg 1948), or homologized it with either n. interventralis in *Tupaia minor* (Le Gros Clark 1929), or with n. ventralis medialis (Rioch 1929, Crouch 1934, Waller 1934, Bodian 1939 and Krieg 1944). Kuhlenbeck (1951) regards n. medioventralis as a poorly differentiated nucleus, and includes it, as well as n. submedius, with the ventral nucleus. As one ascends the primate scale, n. medioventralis is reduced to a vestigial structure, while n. submedius becomes more prominent and larger in size. In *Tupaia glis*, Bauchot (1963) homologized n. submedius with Le Gros Clark's n. rhomboideus in *Tupaia minor*, but the former author describes n. submedius as a considerably larger nucleus with distinct extensions lying ventral to n. paracentralis, and dorsocaudal to n. interventralis. This description fits n. subparacentralis better than n. rhomboideus in this study. In *Galago demidovii*, Bauchot (1963) describes n. submedius as an unpaired median structure situated beneath n. centralis medialis, and states that n. submedius has lateral extensions. These relations correspond to n. reuniens and n. interventralis in *Galago demidovii* and other prosimians used in this study. Feremutsch (1963) does not mention either n. submedius or n. medioventralis in all his primate species. In the anthropoids, n. submedius is still definitely present, though it is very much reduced in size.

It can be inferred from this study and corroborated from the observations of other authors that, in all primates, as well as in the tree-shrews, n. submedius is still an identifiable structure which can be demarcated clearly by traversing fibre bundles of the mamillothalamic tract, from n. ventralis medialis or the medial part of n. ventralis anterior or of n. ventralis lateralis.

4. *N. paracentralis* (PC)
5. *N. centralis lateralis* (CL) } Plates 2-50)
6. *N. subparacentralis* (SPC)

Since these intralaminar nuclei constitute the anterior part of the intralaminar region (internal medullary lamina), and they are intimately connected with each other topographically and cytologically, they will be considered together here.

(1) INSECTIVORA

Macroscelidoidea

Elephantulus myurus

N. paracentralis (Figs.35 & 36) is a lateral extension of n. centralis medialis from which it cannot be distinguished clearly. N. paracentralis contains small, deeply staining, spindle-shaped cells that are arranged with their long axes horizontally within the internal medullary lamina. At its greatest development, n. paracentralis is a broad, triangular structure with its base resting on n. centralis medialis, and it apex connected dorsolaterally with n. centralis lateralis. Caudally, n. paracentralis is replaced by the centrum medianum/parafascicular complex, while n. centralis lateralis continues further caudally until it is replaced by the medial part of n. pretectalis. N. centralis lateralis is crescent-shaped and lies close to the ventrolateral border of n. mediodorsalis, which it separates from the lateral thalamic mass. The cells of n. centralis lateralis are mostly deeply staining, fusiform or spindle-shaped, and are slightly larger in size than those of n. paracentralis.

Lying beneath n. paracentralis, but lateral and caudal to n. medioventralis, is a small oblong mass of cells that are slightly larger and less darkly staining than those of n. paracentralis. This is n. subparacentralis, which has such a very short rostrocaudal extent that it may be regarded as merely a part of the submedial group of nuclei.

(2) TUPAIOIDEA

The anterior intralaminar nuclei appear at more posterior levels than in Elephantulus. N. paracentralis (Fig.54) appears as a thick sward of cells that extends dorsolaterally from n. centralis medialis. For the most part, n. paracentralis is identified easily by its medium-sized, dark-staining, fusiform cells (16 x 10 μ), whose axes run parallel to the fibres of the internal medullary lamina, and also by its lateral relation to n. centralis lateralis which lies in the bent lateral part of the internal medullary lamina.

N. centralis lateralis (Figs.47 & 48) is a discontinuous structur because its cells are formed in small clusters stretching from its ventromedial connection with n. paracentralis to nn. anteromedialis and parataenialis dorsally. The most dorsal cluster of cells is *n. centralis lateralis pars superior*, while the most ventrally situated cluster of cells is *n. centralis lateralis pars inferior*. The superior part is the larger of the two, and has a longer caudal extent than the inferior part; its cells are, however, not much different from those of the inferior part. Generally, the cells of both parts of n. centralis lateralis are slightly larger (17 x 12 μ). and more darkly staining than those of the cells of n. paracentralis N. centralis lateralis stands out more distinctly than nn. paracentralis and centralis medialis in sections stained with cresyl violet and with the Kluver and Barrera methods. Caudally, n. centralis lateralis is replaced by nn. tractus optici and limitans.

N. subparacentralis is a relatively well developed structure lying immediately ventral to n. paracentralis; it has small lateral extensions that spread towards nn. ventrales mediales on both sides. It can be distinguished rather easily from n. paracentralis by the slightly large, less darkly staining, more loosely arranged and more rounded cells of the former nucleus.

The anterior intralaminar nuclei of the Tupaioidea are generally heteromorphous and isoformic. Closely packed myelinated fibres run horizontally and vertically through the internal medullary lamina.

(3) PROSIMII

Lemuroidea and Lorisoidea

N. paracentralis (Figs.54-78; 87-112) appears first as a lateral expansion of n. centralis medialis and stretches gradually lateralward toward n. centralis lateralis as n. mediodorsalis expands in size. N. paracentralis is a thin strand or beaded layer of medium-sized, dark-staining and fusiform cells (15 x 10 μ; in *Lemur*; 17 x 11 μ; in *Galago*). These cells can be distinguished rather easily from those of nn. centrales medialis and lateralis. N. paracentralis lies between n. mediodorsalis dorsally and the medial parts of nn. ventrales lateralis and posterior ventrally. Caudalwards, n. paracentralis expands dorsolaterally to form the ventrolateral border of n. mediodorsalis, separating it from the dorsolateral nuclei. It links up with the superior part of n. centralis lateralis which lies ventral and medial to n. lateralis dorsalis. At the level of the rostral region of the habenula, n. paracentralis becomes considerably thicker with several layers of slightly larger, more darkly staining and fusiform cells. This changed morphology is the result of the ventral displacement of n. centralis lateralis, and to the diminishing size of n. centralis medialis. Further caudally, n. paracentralis is less readily distinguishable from the posterolateral part of n. mediodorsalis and from n. centralis lateralis. N. paracentralis is replaced gradually by the centrum medianum/parafascicular complex, but more by n. parafascicularis.

N. centralis lateralis begins, at a more posterior level, as a small, well circumscribed area of medium-sized, moderately staining, stellate cells lying lateral to the rostral pole of n. mediodorsalis, and to the caudal part of n. anteromedialis. Topographically, n. centralis lateralis can be located fairly easily by its rostral and dorsal relations with the lateral thalamic nuclei, and its caudal and ventral relations with nn. centrum medianum and parafascicularis. Caudad, n. centralis lateralis is displaced ventralwards by the expanding n. mediodorsalis. Here, the cells of n. centralis lateralis are distinguished by their larger size, deeper staining and more polygonal shape (between 16 x 10 μ and 21 x 16 μ) than those of n. paracentralis. N. centralis lateralis is better developed in all *Lemur* specimens and *Perodicticus potto* than in other prosimians. It forms a large, dark-staining, inverted golf-stick shaped structure and can be seen even macroscopically in stained thalamus sections. In *Galago* spp. and *Microcebus murinus*, n. centralis lateralis is merely a disorientated band of cells lying in the dorsal and ventral regions of the thalamus. In all prosimians, n. centralis lateralis is replaced by nn. tractus opticus and limitans in the posterior thalamic region.

N. subparacentralis (Figs. 111 and 112) is present as a rather prominent mass of small, lightly staining and round cells lying ventral to the medial part of n. paracentralis and lateral to n. reuniens. It is, however, less definable in *Perodicticus potto* and *Lemur*.

4. ANTHROPOIDEA

Cercopithecoidea and Hominoidea

N. paracentralis (Figs. 117-122; 129 & 130) is a clearly discernible, thick, and crescent-shaped structure with large, well stained and polygonal cells (19 x 14 μ). Its dorsal end lies ventromedial to n. anteroventralis and joins with n. centralis lateralis; its ventral end is related medially to n. centralis medialis. N. paracentralis has the same topographical relations as in prosimians. In its caudal extent, n. paracentralis decreases rapidly in width, and becomes a broken line of clustered cells lying between the lateral and medial thalamic nuclei. Just anterior to the middle part of n. centrum medianum, it disappears, being replaced by nn. centralis lateralis and mediodorsalis.

N. centralis lateralis (Figs.121 & 122; 129-132) is, at first, difficult to distinguish from the apical end of n. paracentralis, particularly in the rostral levels of the thalamus. Caudad, n. centralis lateralis becomes better defined as a dorsally situated mass of cells lying beneath n. anteroventralis and above n.mediodorsalis. This is the superior part of n.centralis lateralis,which is more clearly definable tha the inferior part of the same nucleus lying between nn. mediodorsalis and ventralis medialis. Where n. paracentralis dwindles away into a thin, discontinuous band of cells, n. centralis lateralis becomes more conspicuous, and shifts ventrolaterally to the lateral border of the expanding n. mediodorsalis. N. centralis disappears just anterior to tn. limitans.

Discussion on nn. paracentralis, centralis lateralis and subparacentralis

The intralaminar nuclei do not seem to have undergone radical changes in phylogeny. These nuclei remain relatively constant in size and development throughout the Primates. In this study, the descriptions of the anterior intralaminar nuclei vary very little from those of other workers on the prosimian thalamus. However, in *Tarsius*, Le Gros Clark (1930) suggests that because n. centralis lateralis is related closely to n. anteroventralis, the former nucleus may be homologue of n. submedius in other mammalian forms. Yet it may be queried whether it is possible for an intralaminar nucleus like n. centralis lateralis to have such structural and functional relationships to a phylogenetically regressive nucleus like n. submedius. These nuclei are different topographically and cytologically from each other; therefore, it is most unlikely that they are related to each other, except that they may be connected by a few strands of fibres running through the internal medullary lamina. Le Gros Clark considered n. paracentralis an interstitial nucleus which developed in the course of fibres of the internal medullary lamina, and he related it to n. rhomboideus instead of to n. centralis medialis. My observations of the intralaminar nuclei reveal that n. paracentralis is essentially an interstitial nucleus, but it is connected nowhere with n. rhomboideus.

In higher primates, the anterior intralaminar nuclei form a relatively broad band of cells along the lateral circumference of n. mediodorsalis. N. centralis lateralis may vary considerably in its posterior extent. Feremutsch (1963) found that n.centralis lateralis does not extend as far posteriorly in the Cercopithecidae as in the Hominidae. Generally, n. centralis lateralis is not a well formed structure, since it contains several clusters of cells, or most frequently, two large groups of cells, the superior and inferior parts of n. centralis lateralis. These parts have been illustrated in the stereotaxic atlases of the thalamus of *Tupaia glis* by Tigges and Shantha (1969) and of the macaque monkey by Olzsewski (1952). However, in the chimpanzee, n. centralis lateralis is not as distinctive as in the monkey and man (Walker 1938, Heiner 1960).

7. N. centrum medianum (CEM)
8. N. parafascicularis (PF) } Plates 3-52
9. N. subparafascicularis (SPF)

Nn. centrum medianum and parafascicularis are the Tweedledum and Tweedledee of the primate thalamus, because they are inseparable from each other, in spite of cyto- and myelo-architectonic differences, and also they share a common border. They complement each other in structure and function. On this basis, they form a nuclear complex, the centrum medianum/parafascicular complex in all specimens used in this study. These nuclei constitute the posterior part of the intralaminar nuclear group, and replace nn. paracentralis and centralis lateralis at the level of the rostral pole of the habenular region.

(1) INSECTIVORA

Macroscelidoidea

Elephantulus myurus

N. centrum medianum (Figs. 37-38) is a relatively small and insignificant structure which replaces n. centralis lateralis caudally. At first, n. centrum medianum is in the form of a thin layer that lies lateral to the larger and roughly triangular n. parafascicularis. Caudad, n. centrum medianum extends further laterally, and comes to lie between n. lateralis dorsalis laterally, n. parafascicularis medially and n. ventralis posterior ventrally. Although n. centrum medianum is fused almost entirely with n. parafascicularis on its medial border, the former nucleus can be distinguished by its smaller, more palely staining and more scattered cells. Because n. centrum medianum is an intralaminar structure, myelinated fibres run through it from the periventricular system, and to a lesser extent, from the corpus striatum and mesencephalic tectum.

N. parafascicularis (Figs.37-38) is the largest and most darkly staining of all the intralaminar nuclei, and is situated most caudally of all the medial thalamic nuclei. N. parafascicularis is not completely demarcated from n. mediodorsalis.

(2) TUPAIOIDEA

N. centrum medianum (Figs.49-50) shows a notable change in that it comes close to possessing the characteristic structure of this nucleus in Primates. The nucleus expands in all dimensions concomitantly with its increasing functional importance in the thalamus. Although n. centrum medianum is relatively larger than the intralaminar nuclei together, it still shares a common border with n. parafascicularis. The cells of n. centrum medianum are small (12 x 10μ), lightly-staining, round or oval, and scattered.

(3) PROSIMII

In all prosimians, at the level of the caudal region of n. mediodorsalis, n. centrum medianum (Figs.57-80; 93-114) replaces n. paracentralis, not n. centralis lateralis as in Elephantulus. N. centrum medianum is a narrow, club-shaped or oblong mass of cells that are smaller and less darkly staining than those of other intralaminar nuclei. N. centrum medianum increases rapidly in size, until it ~~forms a~~ is rounded or ovoid ~~form~~ and extend~~ing~~s farther dorsally into the area that has been occupied previously by n. mediodorsalis. Here, it comes to lie dorsal to n. pretectalis, medial to n. lateralis posterior and ventral to n. ventralis posterior, particularly its medial part, which causes a concave bulging into the ventral border of n. centrum medianum. Caudad, n. centrum medianum becomes progressively larger, and is further differentiated cellularly, but is still incompletely separated from n. parafascicularis. N. centrum medianum has small and medium-sized cells (11 x 9 μ to 15 x 8 μ), pale-staining, round cells that are packed more compactly in its lateral part in relation to n. ventralis posteromedialis than its medial part which lies lateral to n. parafascicularis. Generally, the cells of n. centrum medianum are arranged so loosely among the traversing fibres of the internal medullary lamina that the nucleus has a lightly myelinated appearance in stained brain sections.

In both Tupaioidea and Prosimii, n. parafascicularis is still larger and more conspicuous than n. centrum medianum. The former nucleus commences at a more caudal level than n. centrum medianum, particularly when the habenulopeduncular tract appears to emerge ventrally from the habenular nucleus. At this level, n. parafascicularis replaces n. mediodorsalis, and is related ventrolaterally to n. pretectalis and medially to n. paraventricularis pars posterior. N. parafascicularis is composed mostly of medium-sized, moderately well staining, round cells in small prosimians, as well as in tupaioids, (16 x 10 μ), but in larger prosimians, particularly *Perodicticus potto* and *Galago crassicaudatus*, these cells seem to be larger, more darkly staining and polygonal (17 x 9 μ to 19 x 12 μ). The habenulopeduncular tract bisects n. parafascicularis almost neatly into medial and lateral parts, but there are no cytoarchitectonic and cytological differences in these parts. Therefore, n. parafascicularis appears to be wrapped around the habenulopeduncular tract, as it runs ventrally towards the interpeduncular nucleus of the midbrain.

Both nn. centrum medianum and parafascicularis terminate more or less at the level of the posterior commissure to be replaced by the posterior thalamic nuclei; n. centrum medianum by nn. tractus optici , limitans and suprageniculatus, and n. parafascicularis by n. pretectalis and the bed nucleus of the posterior commissure. When considered individually, nn. centrum medianum and parafascicularis are monomorphous and isoformic, but if regarded together as a nuclear complex, they are clearly dimorphic and anisoformic. N. parafascicularis is more richly myelinated than n. centrum medianum, due to the fibres coming out of the habenulopeduncular tract in its ventralward course.

N. subparafascicularis is an unimportant structure which differs only slightly from n. parafascicularis in having smaller, more palely staining and fusiform cells that are packed closely together beneath n. parafascicularis. It lies dorsal to the zona incerta, ventromedial to n. centrum medianum and dorsomedial to n. ventralis posteromedialis. It runs for only a short distance caudally before it is replaced abruptly by the mesencephalic tectum.

(4) ANTHROPOIDEA

Cercopithecoidea and Hominoidea

In the vervet, n. centrum medianum (Figs.121 & 122) is a pale-staining, oval structure that is slightly richer in myelinated fibres rostrally than caudally, and is comparatively much larger and better defined than that of lower primates. N. centrum medianum commences at the level of the middle region of n. medialis, and is, at first, not easily distinguished from n. medialis pars lateralis. Caudad, n. centrum medianum enlarges rapidly into a more rounded structure that lies ventral to n. medialis and medial to n. ventralis posteromedialis. At this level, n. centrum medianum is more easily discernible, because a clear zone, almost free of myelin, surrounds the nucleus on all sides, except at its medial border, where it merges imperceptibly with n. parafascicularis. As n. parafascicularis expands in size, it displaces n. centrum medianum to such an extent that the latter nucleus comes to rest on the medial border of n. ventralis posteromedialis. As a result of this displacement, n. ventralis posteromedialis becomes markedly lunar or crescentic in shape to accommodate the concave surface of n. centrum medianum. Caudad, n. centrum medianum becomes progressively smaller and less myelinated, and at the level of the caudal end of n. lateralis dorsalis, it is replaced first by n. lateralis posterior, and then by the medial part of n. pulvinaris superior. The cells of n. centrum medianum are mostly medium-sized (19 x 14 μ).

In man, n. centrum medianum (Figs.129-136) commences further caudally than it does in the vervet monkey, that is, at the caudal end of the interthalamic adhesion, and extends to the caudal end of the habenular region. N. centrum medianum is surrounded on all sides by the internal medullary lamina, except at its medial border, where it is not clearly separated from n. parafascicularis. But by comparison with n. centrum medianum of the Tupaioidea and

Prosimii, the delimitation between nn. centrum medianum and parafascicularis appears to be better defined, due to differences in cellular structure and myelin content in each nucleus. The cells of n. centrum medianum are mostly medium-sized, rather lightly staining and polyhedral; they are more concentrated medially and along the borders of n. centrum medianum.

In the vervet, n. parafascicularis (Figs.117-122) appears slightly posterior to n. centrum medianum at the level of the caudal part of n. mediodorsalis. It lies central to n. paraventricularis pars posterior, dorsomedial to the habenulopeduncular tract, dorsal to the zona incerta and ventral to n. limitans. It is split into medial and lateral parts by the habenulopeduncular tract, but they are not different cytologically from each other. The lateral border of n. parafascicularis interdigitates with the medial border of n. centrum medianum, so that there is no definite line of separation between the two nuclei. Caudally, n. parafascicularis is replaced by the habenular nuclei. The cells of n. parafascicularis are medium-sized to large (20 x 11 μ), very darkly staining, spindle shaped or round, and very compactly arranged.

In man,(Figs.128-136) on the other hand, n. parafascicularis is separated rather completely from n. centrum medianum by a fibrous layer on its lateral border. Its topographical relationships to adjoining nuclei are the same as described for the vervet.

Discussion on nn. centrum medianum, parafascicularis and subparafascicularis

N. centrum medianum was described by Le Gros Clark (1932) as one of the most conspicuous and clearly defined elements of the human thalamus, and he stated that it is clearly distinguishable, too, in all primates. Comparative data indicate that n. centrum medianum arose as a specialization of the caudal end of n.

parafascicularis. Therefore, in its primitive form, n. centrum medianum is an interstitial nucleus, being scarcely more than a region of passage of fibres. In lower mammals, such as rodents and carnivores, n. centrum medianum is not clearly differentiated from n. parafascicularis, but it develops in close relation to the internal medullary lamina. It received its most important connections through the internal medullary lamina from the subcortical areas outside the thalamus. In the Cetacea and Primates, n. centrum medianum acquires a more definite configuration and, presumably with an increase in size and differentiation, it becomes associated with more highly specialized fibre connections. In Insectivora, like Talpa europea, Sorex araneus, Elephantulus myurus and Tenrec caudatus, n. centrum medianum is relatively simple and undifferentiated; it lies lateral to n. parafascicularis, which is, by comparison, one of the most massive and best developed intralaminar nuclei in these forms (Bauchot 1963). Collectively, nn. centrum medianum and parafascicularis are not yet discrete structures, since they form a simple cellular mass surrounding the habenulopeduncular tract. In the Insectivora, the habenulopeduncular tract is very well developed, and its very oblique direction is more striking than in lower primates. The large size and oblique direction of the habenulopeduncular tract have been observed in Elephantulus myurus, an insectivore used in this study, and it seems to split n. parafascicularis completely from n. centrum medianum.

While Sachs (1909) states that n. centrum medianum is a recent phylogenetic development in the primate diencephalon, Rioch (1929) argues that it is present in the Carnivora, but only as a small and insignificant structure, which does not differ much from what is described for the insectivores and lower primates. Bauchot attempts to prove that n. centrum medianum may exist in varying degrees of development in different insectivore species, for instance, it is better defined topographically (though undifferentiated cytoarchitectonically) in Talpa than in Sorex and Elephantulus.

This study has revealed that n. centrum medianum is comparatively larger and better developed in the Tupaioidea than in the Insectivora. It has shown, too, that n. centrum medianum may have arisen as a weak differentiation of the caudal part of n. paracentralis in both species, and it is not yet clearly demarcated from either n. paracentralis or n. parafascicularis. Le Gros Clark (1929) identified n. centrum medianum in *Tupaia minor*, but could not find its homologue in *Macroscelides*; therefore, he regarded n. centrum medianum as a development characteristic of the primates. Although Bauchot (1963) has found, in all his insectivore specimens, a nucleus which has similar features to those of n. centrum medianum, this nucleus assumes its identity definitely only in the Tupaioidea and Lemuroidea. Furthermore, Bauchot found that there is a close relationship between nn. centrum medianum and parafascicularis, as he considers that in Insectivora, n. centrum medianum lies *caudal* to the intralaminar nuclei, and its constant relationship and common border with n. parafascicularis is more than significant. In *Galago demidovii*, n. centrum medianum shows more clearly its primate characteristics than in *Tupaia glis*, as already observed in this study. Pines (1927) terms n. centrum medianum his nucleus "mb", and speaks of it as a well differentiated structure, but unfortunately, he did not indicate its supposed origin. In *Microcebus murinus*, and other small lemuroids, n. centrum medianum is less clearly defined, and appears to be a rostrolateral extension of n. parafascicularis. In larger lemuroids and lorisoids, n. centrum medianum is still not well circumscribed, and shows a very close association with n. parafascicularis. N. centrum medianum is relatively smaller, only slightly larger in size than n. habenularis lying dorsal to it. In these species, the arrangement of cells is similar to that in other primates, but it is slightly more myelinated in *Microcebus murinus*. The ventromedial relation of n. centrum medianum is n. pulvinaris, not n. lateralis posterior, since the latter nucleus is smaller in prosimian than in simian primates.

Therefore, in lower primates, as well as in the tree-shrews, n. centrum medianum appears to be a lateral differentiation of n. parafascicularis, but in higher prosimians, such as lemurs and galagos, it has an interstitial development in the internal medullary lamina. There appears to be a gradual displacement of n. centrum medianum in a rostromedial direction, starting probably in *Tupaia*, and it is possible that n. centrum medianum of primates is not homologous to the nucleus occupying the same topographical position in the insectivores. In several subprimate mammalian species, n. centrum medianum or its homologue is more caudally situated than in primates. My observations show that n. centrum medianum of primates is not built up only from the constituents of the internal medullary lamina, but also from the adjoining ventral thalamic nuclei.

Feremutsch (1963) puts nn. centrum medianum and parafascicularis together as the centrum medianum-parafascicular complex since he regards these nuclei as being primitive in their phylogeny in the Prosimii. In lower primates n. centrum medianum is not demarcated clearly from n. parafascicularis, and is generally a monomorphous and isoformic nucleus. Feremutsch observed that in *Loris tardigradus*, n. centrum medianum is slightly smaller than n. parafascicularis, and appears to be divided by the habenulopeduncular tract into medial and lateral components. The medial component is actually n. parafascicularis by virtue of its larger and more deeply staining cells. N. centrum medianum is much more conspicuous in *Tarsius* than in *Tupaia*, *Lemur* and *Galago*, and even more in higher primates and man (Le Gros Clark 1930); it can be sharply differentiated from n. parafascicularis by cytological differences in both nuclei. In *Tarsius*, n. centrum medianum can be recognized without difficulty, and it occupies a relatively higher position in the dorsal, not in the ventral, part of the thalamus, as in higher primates. However, in the caudal region of this nuclear complex, the distinction between nn. centrum medianum and parafascicularis becomes less clear and the cells of the two nuclei intermingle freely with each other.

In the Cebidae and Cercopithecidae (Feremutsch 1963, Simmons 1965), n. centrum medianum is a conspicuously developed structure which is encapsulated almost completely on all sides, except medially by the internal medullary lamina. It is still monomorphous and isoformic, becomes dimorphic in the Pongidae and Hominidae, in which more than one type of cell is found in n. centrum medianum. Feremutsch (1963) finds that in higher primates, n. centrum medianum may be divided, only in its rostral region, into a dorsomedial magnocellular and a ventrolateral parvocellular part. These cellular divisions have not been observed in lower primates of this study. In the caudal part of n. centrum medianum there is, however, a diffuse intermingling of cells.

In Insectivora, Bauchot isolated another nucleus, nucleus subparafascicularis, which is a ventroposterior differentiation of n. parafascicularis. It lies ventral to the habenulopeduncular tract and is closely associated with the subthalamic region. However, he does not mention its presence in Tupaia glis, and in Galago demidovii. N. subparafascicularis has been confirmed, in this study, to be present in the Lemuroidea and Lorisoidea, but it is not clearly demonstrable in the Tupaioidea. It is, however, either poorly developed or absent in the Anthropoidea.

Feremutsch (1963) finds it difficult to separate n. parafascicularis from n. centrum medianum. He assumes n. parafascicularis is located medial to the caudal end of n. centrum medianum near the third ventricle, and in close proximity to the habenulopeduncular tract. Even the cells of n. parafascicularis do not provide criteria to isolate it from n. centrum medianum. Therefore, he may mean that n. parafascicularis is merely a parafascicular extension of n. centrum medianum in lower primates.

In higher primates, n. parafascicularis can be demarcated topographically and cytoarchitectonically from n. centrum medianum, and it is even split up into two or more parts by the habenulopeduncular tract. N. parafascicularis is larger in the chimpanzee than in the monkey. However it appears to be smaller, and extends dorsal to the termination of n. mediodorsalis, whereas it does not do so in the monkey. Kanagasuntheram and Wong (1969) observed in the Hylobatidae that the separation between nn. centrum medianum and parafascicularis is fairly clear throughout their rostrocaudal extent, and is particularly more marked in the caudal part where n. centrum medianum becomes distinctly encapsulated. Sheps (1945) mentioned complete separation in the human thalamus, but Toncray and Krieg (1946), and Dekaban (1954) did not agree with his observation, and maintained that the two nuclei are fused. Hassler (1959) and Mehler (1966) find it very difficult to give a precise delimitation; they believe that only the ventrolateral parvocellular region should be regarded as n. centrum medianum while the dorsomedial magnocellular portions surrounding the habenulopeduncular tract belong to n. parafascicularis. My observations on this point, in all primate species used in this study, agree with those of Hassler and Mehler.

A scheme of topographical demarcation and cytoarchitectonic distinctions of nn. centrum medianum and parafascicularis, modified after that of Feremutsch (1963), is presented in Table 12.

The sign (..) indicates that no definite cytoarchitectonic features can be found in either n. centrum medianum or n. parafascicularis, or in both nuclei. The sign "/" denotes complete separation, while the other sign "-" signifies partial division of n. centrum medianum (CEM) from n. parafascicularis (PF):

Table 12

	FEREMUTSCH	PRESENT STUDY
Insectivora	(CEM)/(PF)	(CEM)-PF
Tupaioidea	(CEM)/(PF)	(CEM)-PF
Microcebus murinus	(CEM)/(PF)	CEM -PF
Propithecus verreauxi	(CEM)/(PF)	?
Lemur spp.	(CEM)/(PF)	CEM -PF
Nycticebus coucang	?	CEM -PF (Kanagansuntheram)
Loris tardigradus	(CEM)/(PF)	?
Tarsius spectrum	?	CEM /PF (Le Gros Clark)
Cebidae	CEM -PF	?
Cercopithecidae	CEM -PF	CEM /PF
Hylobatidae	?	CEM /PF
Pongidae	CEM -PF	CEM /PF
Hominidae	CEM -PF	CEM /PF

SUMMARY OF THE MEDIAL THALAMIC REGION

The most remarkable nuclei in the phylogeny of the medial thalamic nuclear group are n. *mediodorsalis* and the centrum medianum/parafascicular complex. The intralaminar nuclei, nn. centralis lateralis and parafascicularis remain more or less stable throughout the Primates. N. submedius and n. medioventralis are easily confused topographically and cytoarchitectonically with each other; they can be distinguished only on a structural basis from each other, particularly in lower primates and the tree shrews. N. medioventralis undergoes rapid regression as one ascends the primate scale, while n. submedius persists as a small and rather indistinguishable structure even in the Hominidae. Consequently, n. mediodorsalis is often classified as n. medialis, since n. medioventralis has disappeared from the thalamus. N. medialis has evolved from a simple and undifferentiated structure in non-primate mammals to a very highly elaborated and complicated supranucleus in man. In the tree shrew, n. mediodorsalis shows some incipient signs of development by becoming larger in size and differentiated into two cellular areas. In more advanced prosimians, particularly _Lemur_ and _Perodicticus potto_, a third division of n. mediodorsalis appears, and becomes more conspicuous as one ascends the primate scale.

Nn. centrum medianum and parafascicularis are, at first, indistinguishable from each other, since they are contained in a homogeneous mass as observed in non-primate mammals. However, n. centrum medianum can still be differentiated from n. parafascicularis by the smaller and more lightly staining cells of the former nucleus. Throughout the primates, nn. centrum medianum and parafascicularis show gradations in structural demarcation and cytoarchitectonic differentiation. In monkeys and apes, n. centrum medianum can be distinguished more easily from n. parafascicularis in all respects, though it remains attached to n. parafascicularis on the lateral border of the latter nucleus. In man, n. centrum medianum is almost completely dissociated from n. parafascicularis, and is one of the most prominent structures in the human thalamus, while n. parafascicularis is a small area clustered around the habenulopeduncular tract. In the Tupaioidea, n. centrum medianum shows clearly its origin from the caudal end of n. paracentralis, and is situated much higher up in the dorsal thalamic region; n. parafascicularis is relatively larger in size and extent. As one goes up the primate scale, it becomes more evident that n. centrum medianum arose independently of n. parafascicularis and is not its lateral appendage, even though it is attached to n. parafascicularis. Moreover, n. parafascicularis is not to be regarded as a medial appendage of n. centrum medianum, but as a compact cluster of cells wrapped around the habenulopeduncular tract.

A summary of structural features, cyto- and myeloarchitectonic properties and phylogenetic trends is given in Table 13:

TABLE 13 TABLE OF COMPARISON IN THE MEDIAL THALAMIC GROUP

FEATURES	N. mediodorsalis (MD)	Nn. Submedius & medioventralis (SUM) (MV)	Nn. paracentralis (PC) centralis lateralis (CL) and subparacentralis (SPC)	Nn. centrum medianum (CEM) and parafascicularis (PF) and subparafascicularis (SPF)
STRUCTURAL FEATURES	Small in Elephantulus, and possesses an intercellular connection - n. intermediodorsalis. Increases rapidly in size in Tupaia, and becomes one of the largest thalamic structures in all prosimians. In higher primates, MD occupies almost the whole medial thalamic region, and is only slightly smaller in area than n. ventralis posterior and the pulvinar. From Tupaia to Galago, it is divisible into two parts; from Cebus to Homo - three or more parts characteristic of a supra-nucleus. N. intermediodorsalis is absent in Tupaia, prosimian and anthropoid primates.	SUM is present in Elephantulus, Tupaia and in all primates; is more easily identified in lower than higher primates as a small paramedian structure lying ventral to the anterior thalamic nuclei and MD, and lateral to n. reuniens. SUM is relatively reduced in size in monkey, and is absent in man. MV is often confused with SUM in primates, but can be better identified in Tupaia and lower primates as a smaller and more poorly differentiated structure lying ventral to SUM and the internal medullary lamina. In Galago, SUM and MV appear to merge into one nucleus, and as a result, MV is not present in higher primates as a discrete entity.	PC and CL are poorly developed in Elephantulus, due to a small MD and an undifferentiated lateral nuclear mass. In this species, PC is a short and ill-defined structure lying between CM and CL. It increases in size and extent throughout the prosimian series, yet remains horizontally disposed due to CL occupying most part of the internal medullary lamina. In monkey, ape and man, PC is a large, well-defined, crescentic structure that stretches far dorsally toward CL. CL consists of a chain of cell clusters in some prosimians, especially Perodicticus and Galago, but is generally well formed into two groups of cells linked together by a scattered line of cells (part of PC) - superior and inferior parts of CL. In man, CL is a large structure, and occupies a dorsal position between MD and n. lateralis posterior, while PC is a long, thick crescent of cells linking it with CM. SPC is identified with more certainty only in Tupaia, Galago and Perodicticus.	CEM and PF are inseparable from each other. They complement each other in structure and function. CEM is, at first, a small, insignificant structure, even seeming to be an appendage of PF. In Tupaia, CEM becomes larger in size and better defined, but remains relatively smaller than PF. The relative differences in size, shape and cytology change progressively throughout the prosimian and simian species up to man. CEM of man is a very large, semilunar shaped structure, while PF is much smaller and concentrated around the habenulopeduncular tract. In Tupaia and all prosimians, CEM occupies the caudodorsal thalamic region lying dorsal and lateral to PF, but in higher primates, CEM moves ventralwards, due to the expanding MD (M), and lies just lateral to PF and dorsal to n. ventralis posteromedialis. SPF is better identified in all prosimians, as well as in Tupaia, but in higher primates, it appears to be reabsorbed into PF, or is a perinuclear structure of the habenulopeduncular tract linking up with anterior and medial thalamic nuclei.
CELLULAR PROPERTIES (CYTO-ARCHITECTONICS)	The dorsomedial part of MD contains medium-sized to large, dark staining polygonal or round, cells (14 x 9 /^{u} - Galago to 22 x 15 /^{u} - Cercopithecus; [illegible]. The ventrolateral part of MD has small to medium-sized, less darkly staining round cells (11 x 9 /^{u} to 20 x 14 /^{u}). Therefore, size and type of cells change from Tupaia to Homo. In higher primates including Perodicticus and Galago, a third part, a posterolateral part of MD, is present and consists of larger, more darkly staining multipolar cells, which are arranged densely along the ventrolateral border of MD. The cells of the dorsomedial part of MD are less densely arranged than those of the ventrolateral part of MD.	Cells of SUM are mostly medium-sized, lightly staining and oval (12 x 9 /^{u} - Galago to 21 x 13 /^{u} in Cercopithecus). These cells are uniformly distributed throughout the nucleus. MV has smaller, better staining and rounder cells than those of SUM. These cells are seen only in Tupaia and all prosimians up to Galago. Therefore, SUM shows slight increase in size only, not in stainability, as one goes up the primate scale.	PC contains mostly medium-sized, dark-staining, fusiform cells in Tupaia and all prosimians (15 x 10 /^{u} - Lemur to 19 x 12 /^{u}) [illegible]. Increases in size, and changes in classification of neuronal type throughout the primate scale. Cells are packed compactly in a sheath-like manner. CL has, at first, small, less darkly staining and less fusiform cells than those of PC, particularly in Elephantulus and Tupaia, but on ascending the primate scale, increases in size and stainability, and changes shape from fusiform to round (16 x 10 /^{u} - Galago to 21 x 16 /^{u} - Cercopithecus). Cells of CL are arranged closely in two or more isolated groups linked together by a chain of cells. SPC has smaller, darkly staining and less fusiform cells.	CEM shows remarkable increase in size and stainability. The cells of CEM are 11 x 9 /^{u} in Galago and 30 x [illegible] /^{u} in Cercopithecus. However, these cells stain less darkly than those of PF, and are loosely arranged. PF has large, very darkly staining and polygonal cells in all primates, as well as in the Tupaioidea. These cells are 16 x 10 /^{u} in Galago and 20 x 11 /^{u} in Cercopithecus, and are very compactly arranged around the habenulopeduncular tract. SPF has smaller, less darkly staining and rounder cells than those of PF.

TABLE 13 (contd.) TABLE OF COMPARISONS IN THE MEDIAL THALAMIC GROUP

FEATURES	N. mediodorsalis (MD)	Nn. Submedius & medioventralis (SUM) (MV)	Nn. paracentralis (PC) centralis lateralis (CL) and subparacentralis (SPC)	Nn. centrum medianum (CEM) and parafascicularis (PF) and subparafascicularis (SPF)
MYELIN CONTENT AND FIBRE ARRANGEMENTS (MYELO-ARCHITECTONICS)	Variable fibre content among primates. In the medial part of MD, more myelinated fibres are arranged densely than in the lateral part of MD. In *Tupaia*, more fibres are found in the lateral than in the medial part. In higher primates, fewer fibres in the dorsomedial than in the ventrolateral and posterolateral regions of MD. The fibres are distributed mostly in a dorsoventral direction, and form a part of the superior thalamic radiations.	Both SUM and MV have very diffuse fibre arrangement, therefore, they appear as lightly myelinated areas. These nuclei are connected with intralaminar and periventricular fibre systems. The mamillothalamic tract and superior thalamic radiations run through these nuclei.	Both PC and CL are intimately connected with the fibres of the internal medullary lamina. These fibres form a very distinct band than runs dorsolaterally to ventromedially in the shape of a semicircle, separating MD from the lateral thalamic regions. This band of fibres appears as a very dark-staining sheath in brain sections. In CL, fine, thread-like fibres spread among the cells, giving this nucleus a thickened appearance in stained sections.	CEM is generally more lightly myelinated in appearance than PF. In *Tupaia* and lower primates, it contains fibres that are more or less evenly distributed in the substance, and also fibres that appear to be more concentrated on its medial border, thus, giving it an appearance of being demarcated from PF. PF appears, at first, in *Tupaia* and lower primates, to be less densely myelinated than CEM, owing to the larger size of the former nucleus. As one ascends the primate scale, PF becomes more densely myelinated than CEM; the fibres of PF are concentrated around the fascicles of the habenulopeduncular tract. CEM of higher primates is a much more lightly myelinated area than PF, owing to the increase in size of the former nucleus CEM, and PF to a lesser extent, are intimately connected with fibre systems of subcortical areas, such as the basal ganglia.
PHYLOGENETIC TRENDS AND FUNCTIONAL IMPORTANCE	MD (M in higher primates only) is one of the most progressive and stable elements of the thalamus, as well as of the whole diencephalon. In *Tupaia* MD shows first incipient signs of phylogenetic development, and is better differentiated cellularly than in *Elephantulus*, and in other non-primate mammals. Starts as a small and undifferentiated mass of cells in *Elephantulus* and increases progressively in structural size and functional importance throughout the prosimian and simian species to man. In man, MD is a very large structure, smaller only than n. ventralis posterior and the pulvinar.	SUM reduces in size from *Tupaia* to *Homo*, and is identified with difficulty in the human thalamus. It has little functional importance, and may act as a link between MD and the ventral thalamic nuclei. MV is a rudimentary structure, even in prosimians, and is absent in higher primates.	Both PC and CL show more progressive features than n. centralis medialis, i.e., they are more distinctive in higher than in lower primates. CL appears to be more phylogenetically advanced than n. paracentralis and n. centralis medialis together, since it is the principal anterior intralaminar nucleus that possesses a significant functional link between MD and the lateral thalamic mass. In man, CL is a large structure, which emphasizes its functional importance. PC serves only as a connection between n. centralis medialis and CL, as well as between CL and midline nuclei.	CEM is one of the most progressive thalamic structures, having a rapid phylogenetic development, and even surpassing the whole medial thalamic region, with the exception of MD, in structural growth. It has important fibre connections with the basal ganglia and other subcortical centres and may have a fibre projection to the cerebral hemispheres. PF is a less important and smaller structure phylogenetically than CEM. Little is known about functions of PF, apart from the fact that it is wrapped around the habenulopeduncular tract, and is joined on its lateral border to CEM.

CHAPTER 8

THE THALAMUS: DORSOLATERAL NUCLEAR GROUP

In its evolutionary history, the lateral nuclear mass is the most remarkable part of the thalamus. The increase in its nuclear complexity and functional importance is correlated with the growth of neocortical areas in the cerebral hemispheres. The lateral thalamic region is divided on grounds of topography and cytology into dorsal and ventral parts which have been termed by Walker (1937,1938) dorsolateral and ventrolateral thalamic nuclear groups respectively. These terms are used in this study. The nuclei comprising the dorsal part of the lateral thalamic nuclear region are:

1. (a) N. lateralis dorsalis (LD)
   (b) N. lateralis intermedius (LI)
   (c) N. lateralis posterior (LP)

and 2. the posterior extension of these lateral nuclei - the pulvinar or n. pulvinaris (PUL)

Since it is difficult to delimit the lateral nuclei from one another in *Elephantulus myurus* and most prosimians, these nuclei will be described and discussed together under one heading - dorsolateral thalamic nuclear group. The pulvinar is dealt with in a separate section.

1. The Dorsolateral Thalamic Nuclei (Plates 1 - 52)

(1) INSECTIVORA

Macroscelidoidea

Elephantulus myurus

The lateral nuclear group (Figs.33-37) consists of the principal lateral nucleus and its posterior extension, n.

lateralis posterior. The pulvinar is definitely not present, as n. lateralis posterior is a very small and undifferentiated structure. The lateral nucleus proper appears at the same level as the habenular nuclei, as a rounded mass of medium-sized cells that are arranged regularly in an area almost devoid of myelinated fibres. The principal lateral nucleus lies lateral to nn. centralis lateralis, mediodorsalis and habenularis. N. lateralis principalis is related ventrolaterally to the bed nucleus of the stria terminalis and ventromedially to the anterior nuclei. More caudally, nn. geniculatus lateralis and reticularis are consistent lateral relations of n. lateralis principalis. Based on slight cytoarchitectonic differences, n. lateralis principalis may be divided into dorsal and ventral parts. The dorsal part contains numerous small, rather densely staining and fusiform cells that are arranged close to the dorsolateral surface of the thalamus, near the radiating fibres of the superior thalamic peduncle. The ventral part of n. lateralis principalis has larger, more deeply staining and rounder cells than those of the dorsal part. The ventral part lies caudal and dorsal to the ventral thalamic nucleus, lateral to nn. habenularis, mediodorsalis and centralis lateralis, and rostral to n. lateralis posterior, with which it is continuous. The principal lateral nucleus is replaced caudally by the pretectal area.

(2) TUPAIOIDEA

Although the lateral nucleus (Figs. 45-50) has increased considerably in size and caudal extent, it does not undergo much cellular differentiation. It is rather difficult to detect homologies between its divisions and those in higher forms. However, three areas in the lateral nucleus can be grouped rather distinctly into rostral, intermediate and caudal parts. These parts do seem to correspond to the dorsal, anterior and posterior parts of the lateral nucleus in primates. The dorsolateral nuclei are rather easily delimited from the ventral group of nuclei topographically and myeloarchitectonically. Fibre bundles run from the stria medullaris to the subthalamic region, splitting the lateral thalamic mass into dorsal and ventral compartments, each containing its own lateral nuclei. The dorsolateral nuclei are related medially to nn. mediodorsalis and pretectalis, while the ventrolateral nuclei lie ventral to nn. mediodorsalis and centralis medialis, and along the ventral border of the internal medullary lamina.

N. lateralis dorsalis (LD) is a fairly large nucleus that replaces n. anterodorsalis and the dorsal part of n. anteroventralis at the dorsolateral angle of the thalamus ventral to the stria terminalis. The cells of n. lateralis dorsalis are smaller (12 x 9 μ), stain more lightly and are more scattered than those of n. anterodorsalis; they are not easily distinguishable from those of n. lateralis intermedius.

N. lateralis intermedius (LI) appears at the level of the rostral pole of n. mediodorsalis. It lies ventral and caudal to n. anteroventralis, and is larger in area, but has fewer cells and is richer in myelinated fibres than n. lateralis dorsalis. The cells of n. lateralis intermedius are small to medium-sized (13 x 9 μ), stain better and are rounder than those of n. lateralis dorsalis.. At the disappearance of the anterior nuclei, n. lateralis intermedius comes to be related dorsally to n. lateralis dorsalis, laterally to n. mediodorsalis, ventrally to n. ventralis lateralis and, further caudally, to the rostral pole of the pulvinar. Because of structural similarities in all three dorsolateral nuclei, the rostral and caudal boundaries of n. lateralis intermedius cannot be definitely delimited. Only slight cytoarchitectonic and cytological differences can be detected in each of these nuclei. N. lateralis intermedius may merge insensibly with n. lateralis posterior which replaces also n. lateralis dorsalis.

[illegible] (LP) is the largest of the three dorsolateral nuclei. It is not easily delimited rostrally from nn. laterales dorsalis and intermedius. However, n. lateralis posterior is recognized readily by its larger, better staining, and stellate or oval-shaped cells (17 x 10 µ), which are more regularly arranged in its caudal part. In the posterior part of the thalamus, n. lateralis posterior is related laterally to n. pretectalis, ventrally to n. mediodorsalis, dorsally to n. ventralis lateralis and, at more caudal levels, to n. ventralis posterolateralis. At the level of the caudal end of n. pregeniculatus, n. lateralis posterior is replaced by the pulvinar.

(3). PROSIMII

Lemuroidea and Lorisoidea

The dorsolateral nuclei (Figs. 55-80; 89-116) are larger and better developed in larger than in smaller prosimians. In the latter species, the dorsolateral nuclei are so poorly differentiated from one another that their rostral and caudal boundaries cannot be demarcated clearly from adjoining nuclei.

In *Galago demidovii*, nn. laterales intermedius and posterior are more massive than those of *Microcebus murinus*, possibly due to the more advanced structural development of the brain in the former species. By comparison among small prosimian species, like *Lepilemur*, *Microcebus murinus* and *Galago demidovii*, the dorsolateral nuclei of *G. demidovii* appear to be differentiated further myelo- and cytoarchitectonically than in other two species.

In *Microcebus murinus*, *n. lateralis dorsalis* can be distinguished easily from n. lateralis posterior by the darker-staining and stellate appearance of the medium-sized cells of the former nucleus. After n. lateralis dorsalis has replaced n.

anterodorsalis at the caudal pole of n. anteroventralis, n. lateralis dorsalis lies between n. parataenialis medially and the dorsal part of n. reticularis laterally, and dorsal to *n. lateralis intermedius*. The latter nucleus can be demarcated from n. ventralis lateralis more clearly myeloarchitectonically than cytoarchitectonically; fibre bundles run ventromedially between these two nuclei. Caudad, n. lateralis intermedius expands dorsally to replace n. lateralis dorsalis. At the level of the rostral pole of the lateral geniculate body, n. lateralis intermedius becomes progressively smaller, and either merges with n. lateralis posterior or is replaced by the rostral part of the pulvinar.

N. lateralis posterior is delimited from n. lateralis intermedius with difficulty, because these nuclei have similar cytoarchitectonic features, and they merge imperceptibly with the pulvinar. N. lateralis posterior lies immediately dorsal to n. ventralis lateralis and, at more caudal levels, to n. mediodorsalis; medial to n. geniculatus lateralis; and caudolateral to the dorsal part of the pulvinar.

The topographical relations of the dorsolateral nuclei remain unchanged in larger prosimians, although they are more progressively developed and more cellularly differentiated. N. lateralis intermedius appear, on cytoarchitectonic grounds, to be divided into rostral and caudal parts. The rostral part of n. lateralis intermedius contains small, lightly staining, and round cells that lie immediately ventral to n. lateralis dorsalis, and lateral to the caudal pole of n. anteroventralis. The caudal part of n. lateralis intermedius is the main body of the nucleus itself; it has medium-sized, slightly better staining, polyhedral cells that are arranged in neat rows along the horizontally running fibre bundles.

N. lateralis posterior is much larger, and extends much further caudally than n. lateralis intermedius. It replaces both nn. laterales dorsalis and intermedius at the level of the rostral pole of n. geniculatus lateralis. This termination can be compared with that in smaller prosimians, where n. lateralis posterior ends at a more cranial level. The latter nucleus is replaced by the pulvinar at the level of the caudal end of the centrum medianum-parafascicular complex.

In *Perodicticus potto* and *Lemur spp.*, n. lateralis intermedius has expanded to such large proportions that it may be divided more clearly into a smaller dorsal and a larger ventral part, which correspond respectively to the anterior and ventral parts of the lateral nucleus in the monkey (Walker 1937). However, due to structural expansions of nn. lateralis posterior and pulvinaris in *Perodicticus potto* and *Lemur*, n. lateralis intermediu is a virtual transitional zone between nn. laterales dorsalis and posterior which becomes more marked in higher primates.

In all primates studied here, the dorsolateral nuclei are monomorphous and isoformic. Their cells vary in size between 13 x 10 μ in *Galago* and 19 x 12 μ in *Lemur*.

(4) ANTHROPOIDEA

Cercopithecoidea

(a) *Cercopithecus aethiops*

The division of the thalamic region into dorsal and ventral components remains arbitrary, as there is little or no precise definition of the boundaries of these cell masses, even though cyto- and myelo-architectonics are distinct in each division.

The dorsolateral part (Figs.121-122) is larger in size than that in lower primates, and contains the same parts as in these forms. N. lateralis intermedius has been termed by some investigators either *n. lateralis anterior*)Le Gros Clark 1929, 1930; Papez and Aronson 1934, Crouch 1934 and Walker 1937) or *n. lateralis ventralis* (Krieg 1948, Heiner 1960). For the sake of clarity in this study, the term n. lateralis intermedius is retained for higher primates.

N. lateralis dorsalis is an easily identifiable structure. It starts rostrally as a small, rounded nucleus lying dorsolateral to nn. ventralis anterior and medialis (n. mediodorsalis) in the dorsal extremity of the ventrolateral thalamic region. Caudad, it is a large, cigar-shaped structure, and remains thus until, at the rostral end of the habenula, it merges indistinctly with the dorsal part of n. pulvinaris medialis. The cells of n. lateralis dorsalis are larger than those in lower primates (19 x 12 μ), are stellate, stain well and are arranged in loose clumps along the sparsely distributed myelinated fibre bundles. These cells are large , neurones, as compared with those in large prosimians.

N. lateralis intermedius is difficult to distinguish cyto- and myelo-architectonically from n. ventralis lateralis. It can be delimited from the anterior nuclei dorsomedially, n. medialis ventromedially, n. ventralis anterior rostrally and n. ventralis lateralis caudoventrally. The cells of n. lateralis intermedius are larger (21 x 14 μ) than those of n. lateralis dorsalis; they stain more lightly than those of n. lateralis posterior, and are mostly stellate in shape. These cells are arranged regularly along the transverse fibre bundles. N. lateralis intermedius merges into n. lateralis posterior without any definite boundary.

N. lateralis posterior starts where n. lateralis intermedius ends off. N. lateralis posterior is indistinguishably delimited also from n. ventralis lateralis, but can be differentiated from the latter nucleus cytoarchitectonically. The cells of n. lateralis posterior are 21 x 14 μ in size, are mostly polygonal in shape and stain darkly. These cells are arranged neatly in rows along the bundles of myelinated fibres that radiate toward the internal capsule. N. lateralis posterior ends at the level of the caudal extremity of n. centrum medianum where it merges with the pulvinar. There is a small nucleus lying caudal to the rostral pole of n. lateralis posterior between the latter nucleus and the stratum zonale, lateral to n. lateralis dorsalis and medial to the dorsolateral part of n. reticularis. This is n. lateralis posterior pars angularis (ANG) which has been described in the macaque monkey by Walker (1937) and in the chimpanzee by Heiner (1960). Its cells are slightly larger and more darkly staining than those of n. lateralis dorsalis, and are arranged compactly among the fibre bundles.

(b) Hominoidea

Homo sapiens

The lateral nucleus proper (Figs. 131-136) begins as a narrow cellular mass slightly caudal to the anterior boundary of the thalamus at the level of the interventricular foramen. The lateral nucleus gradually becomes larger caudalwards. It is divided clearly into two, not three, parts - nn. laterales dorsalis and posterior. N. lateralis intermedius is either not present, or is merely a small transitional area between the anterior and posterior parts of the lateral thalamic mass, as well as between nn. lateralis posterior and ventralis posterior. Even the boundaries between nn. laterales dorsalis and posterior are indistinct, while the cellular differences are minimal. However they can be distinguished from each other myeloarchitectonically.

In n. lateralis dorsalis, fibre bundles run horizontally from the internal capsule, giving this nucleus a streaky appearance in myelin-stained sections. N. lateralis posterior contains a rich network of fibres that radiate transversely in thick bundles. The cells of n. lateralis dorsalis are larger and better staining than those of n. lateralis posterior; in the latter nucleus the cells are arranged more loosely and irregularly among the myelinated fibres. Both lateral nuclei end at the level of the habenula where they continue insensibly into the pulvinar.

Discussion on the dorsolateral thalamic nuclei

The progressive enlargement of the dorsolateral nuclei is interesting to the neuro-anatomist. The development of the association areas of the cerebral cortex parallels the growth of the lateral thalamic nucleus which reaches a conspicuously large size and undergoes progressive differentiation in primates.

The lateral nucleus of non-primate mammals, particularly in Edentates and Marsupials, is a very small and undifferentiated structure. When one ascends the mammalian scale towards primates, the lateral nucleus increases in size and becomes differentiated into three parts or subnuclei, nn. laterales dorsalis, intermedius and posterior. Gurdjian (1927) mentioned, in the rat, the presence of nn. laterales anterior and posterior. Holmes (1953) and Hess (1955) did not describe such divisions in rodents, because they stated that other investigators had the lateral nucleus split up into so many parts that topographical and architectonic differences could not be detected in the dorsolateral thalamic nuclei. In Sus scrofa, Solnitzky (1938) described the dorsolateral nuclei being relatively smaller than the more prominent and intrinsically differenticted ventrolateral nuclei, and the pulvinar being better developed than that of other ungulates. In carnivores, the lateral thalamic nuclei are more advanced in structural features and topographical delimitation. Rioch (1929), Ingram et al (1932) do not mention the presence of a separate lateral dorsal nucleus; they have apparently included it in their n. lateralis anterior. The pulvinar may be present in carnivores, but it is comparatively small and undeveloped, or is merely a caudal prolongation of n. lateralis posterior, which is homologous to the inferior part of the pulvinar in primates. In Cetacea (Kruger 1959), the dorsolateral nuclear mass is subdivided into three distinct complexes, lateral, posterior and pulvinar complexes. These divisions are based more on cellular similarities than other morphological differences. The lateral complex is divided further into anterior and posterior parts which correspond respectively to nn. laterales dorsalis and posterior in Primates.

In the Insectivora, Bauchot (1959, 1963) bases his terminology of the dorsolateral nuclei on that of Hassler (1959). His terms are compared with those used for the same nuclei of primates in this study as follows:

Table 14

BAUCHOT	THIS STUDY
n. dorsalis superficialis	n. lateralis dorsalis (dorsal part close to the surface)
n. dorsalis oralis	n. lateralis dorsalis (ventral part, and n. lateralis anterior)
n. dorsalis intermedius	n. lateralis intermedius
n. dorsalis caudalis	n. lateralis posterior

In the specimens used in this study, n. dorsalis superficialis may represent the most superficial part of n. lateralis dorsalis, and therefore, in the monkey, it may be homologized with n. lateralis posterior pars angularis. In the Insectivora, n. dorsalis oralis is described by Bauchot as lying slightly caudal to n. dorsalis superficialis in a ventrolateral position. Its topographical relations are similar to those already described for *Elephantulus myurus*, and to a lesser extent, to those of the tree-shrew and prosimians in this study. Bauchot observes an acellular zone, running rostrocaudally, splitting n. dorsalis oralis up into dorsomedial and ventrolateral portions. This cellular division has not been observed in all species used in my study. However, the dorsal part of n. lateralis dorsalis does merge imperceptibly with the ventral part of Bauchot's n. dorsalis intermedius, which is the nucleus lateralis intermedius of this study, or the nucleus lateralis anterior of Walker and other investigators in the primate thalamus. N. dorsalis caudalis of Bauchot is the equivalent of n. lateralis posterior of most investigators, as well as of that in this study. It corresponds also to n. lateralis "pp" in *Tupaia minor* (Le Gros Clark 1929), and to n. lateralis posterior of the same tupaioid here. It has been noted that n. lateralis posterior of the Tupaioidea definitely shows an intermediate position between those of Insectivora and of Primates, as far as its degree of development is concerned.

In all primates, the three subdivisions of the dorsolateral thalamic nucleus appear to be better defined topographically and myeloarchitectonically than cytoarchitectonically. Kanagasuntheram et al (1968) use the present terms, nn. laterales dorsalis, intermedius and posterior for their prosimian specimens, but Bauchot (1963) uses Hassler's terminology, as discussed above, for *Galago demidovii*. Feremutsch (1963) has devised such a different terminology that comparisons with the lateral nuclei in my study are difficult.

In *Tupaia minor* and Tarsius, Le Gros Clark (1929, 1930) defines his n. lateralis 'a' as the main part of the lateral nucleus that is bounded medially by n. mediodorsalis and the internal medullary lamina, laterally by n. reticularis, ventrally by the ventral nucleus and by the posterior end of the thalamus as far as the posterior commissure. N. lateralis 'a' corresponds well to Bauchot's nn. dorsales oralis and superficialis, and to most of n. lateralis dorsalis in this study. Le Gros Clark's nucleus lateralis 'b' appears to be a caudal continuation of n. lateralis 'a' since in its caudal extension, n. lateralis 'b' appears to lose its identity when it continues uninterruptedly into the dorsolateral part of n. ventralis. Thus, n. lateralis 'b' appears to be a homologue of n. lateralis intermedius rather than n. lateralis posterior in my study. Moreover, n. lateralis intermedius is a transitional zone between the anterior part of n. lateralis posterior and n. ventralis lateralis, as well as between nn. laterales dorsalis and posterior. It has been inferred from this study that in all primates there is no clear distinction between the dorsal and ventral divisions of the lateral thalamic region. Therefore, any attempt at differentiation will be considered as artificial, and even myeloarchitectonic differences may not be sufficiently clear-cut to warrant such territorial separation. In <u>Tarsius</u>, Le Gros Clark (1930) describes how towards the posterior end of the thalamus, the lateral nucleus appears to send off two extensions: one is intimately associated with n. geniculatus lateralis and forms its n. lateralis pars posterior; the other expansion is similarly associated with n. geniculatus medialis and forms the suprageniculate nucleus. However, my observations show that the latter extension is not homologous to n. suprageniculatus, but is likely to be either the rostral or inferior part of the pulvinar. Le Gros Clark's n. lateralis pars posterior can be homologized without difficulty to n. lateralis posterior of all my prosimian specimens.

Since in all his specimens except Galago demidovii, Bauchot (1963) does not term the caudal prolongation of n. lateralis posterior the pulvinar, all divisible parts of the latter nucleus are treated as parts of his n. lateralis posterior. In these same specimens, n. lateralis posterior is continuous caudally with the anterior part of the pulvinar, and shares with it the same cellular features. However, Bauchot distinguishes between these two nuclei by the presence of optic fibres that cover the surface of n. lateralis posterior, and some of which penetrate deeply into the nucleus itself. In my tupaioid and prosimian specimens, the fibres of the optic tract cover the lateral and dorsal surfaces of the pulvinar, and penetrate deeply into n. lateralis posterior. Thus, one can infer from this relationship that there is an association between the dorsolateral nuclei and visual centres, and it becomes more firmly established as one goes up the primate scale.

In *Lemur catta*, Pines (1927) has the lateral thalamic region subdivided into an upper and a lower stratum, which relate respectively to the dorsal and ventral divisions in the same species used in this study. The upper stratum is subdivided into a smaller dorsal 'la' and a larger ventral 'lb' parts. The latter part is, in turn, partitioned into a *rostral* portion consisting of a medial part 'lb_{iv}' and a lateral part 'lb_{iii}'; the *caudal* part is divided further into two small components, 'lb_{i}' and 'lb_{ii}'. Pines's method of subdivision is so complicated that all these portions cannot possibly be identified even cytologically in the dorsolateral thalamic nuclei of the same lemur specimen used in my study.

Feremutsch (1963) has a completely different classification of lateral thalamic nuclei. The dorso- and ventro-lateral nuclei are lumped together without any indication of topographical or histological distinctions. He has the lateral thalamic mass divided into a *pars reticularis* which is homologous with the dorsal part of n. reticularis, a *pars principalis* which represents the main division of the lateral nucleus, a *pars ventroposterior* which consists of lateral and medial parts of n. ventralis posterior, and a *pars pulvinaris* which corresponds to the caudal continuation of the dorsal division of the lateral nuclear complex. Within the anterior part of the lateral nuclear complex in all his primate species, Feremutsch describes a dorsal part which is continuous directly with n. lateralis anterior of other workers, and he terms it 'nucleus lateralis pars dorsalis intermedia'. This subdivision may well correspond to nn. laterales dorsalis and intermedius of this study. In *Propithecus* (a lemuroid), there is another discrete area in the posterior part of n. lateralis pars anterior, and Feremutsch terms it 'pars principalis dorsalis' to distinguish it from n. lateralis pars dorsalis intermedia in *Lemur macaco*. However, the pars principalis dorsalis may correspond specifically to n. lateralis dorsalis or to its superficial part in the lemuroid specimens used in this study. Therefore, it appears that the lateral nuclei are better developed and more cellularly organized in the Lorisoidea than in the Lemuroidea. A better developed and larger n. lateralis intermedius is evident in the lorisoids, but it is poorly differentiated in the lemuroids, and even in anthropoids. At least, its subdivision into dorsal and ventral parts corresponds to nn. laterales anterior and ventralis in the monkey (Walker 1937, 1938; Simmons 1965). However, n. lateralis anterior described by me in the vervet monkey has been re-examined in the light of the present investigation. It is clearly either an anterior part of n. lateralis posterior or a caudal extension of n. lateralis dorsalis, or even a part of n. lateralis intermedius itself. In all higher primates, n. lateralis dorsalis is described as a well developed structure which is demarcated almost completely from nn. laterales intermedius and posterior by a thick layer of fibres running horizontally from the external medullary lamina towards the stria medullaris. N. lateralis dorsalis can be clearly distinguished cytologically and cytoarchitectonically also from the rest of the lateral nucleus.

N. lateralis posterior of higher primates does not differ structurally and histologically from that of the prosimians, although there are some differences of its rostral delimitation and topographical relationships with other lateral nuclei. Krieg (1948) and Heiner (1960) include n. lateralis posterior with the medial part of the pulvinar, but Sheps (1945) and Dekaban (1953) maintain these nuclei as separate entities in the human thalamus. The pars angularis of n. lateralis posterior described by me in the vervet monkey is not present in the chimpanzee or in man.

2. The Pulvinar (PUL) (Plates 9 - 58)

In this study, the division of the pulvinar into superior and inferior parts is based on different topographical features, rather than on cellular criteria, because these parts are more easily defined than the lateral and medial divisions of the pulvinar described in the literature on the primate thalamus. However, in all prosimian specimens here, only the superior part is subdivided cyto- and myelo-architectonically into medial and lateral parts (PULSm and PULSl).

(1) INSECTIVORA

Macroscelidoidea
Elephantulus myurus

The pulvinar is not found in this species, because n. lateralis posterior is too small to develop an extension caudalwards.

(2) TUPAIOIDEA

The pulvinar (Figs 49-52) is merely a large caudal continuation of n. lateralis posterior, as well as of the other lateral nuclei. It is a relatively simple mass of medium-sized, lightly staining and polygonal cells. The pulvinar appears at the level of the middle region of n. geniculatus lateralis or of the habenular region, dorsal to n. lateralis posterior and lateral to n. mediodorsalis. The pulvinar can be divided arbitrarily into superior and inferior parts that are homologous to the same areas in the pulvinar of primates. N. pulvinaris pars superior (PULS) is less myelinated and contains small, well staining and polygonal cells (12 x 9 /^{u}); these cells are scattered among the myelinated fibres that run horizontally from the external medullary lamina. The inferior part of the pulvinar (PULI) is richer in myelin content, due to its proximity to the metathalamus. It has larger, more darkly staining cells than those of the superior part. As nn. pretectalis and tractus opticus are shifted ventralwards by the expansion of the mesencephalic tectum, the superior part merges with the inferior part of the pulvinar. Then the pulvinar reduces in size, and disappears finally slightly cranial to n. geniculatus medialis.

PRIMATES

(3) PROSIMII

(a) Lemuroidea

The pulvinar (Figs. 60-84) is comparatively better developed and differentiated into discrete parts than in the Tupaioidea. The rostral or oral part of the pulvinar (PULO) appears ventromedial to n. mediodorsalis and ventrolateral to the caudal region of n. lateralis posterior. Caudad it increases in size, until at the level of the rostral pole of n. geniculatus lateralis, it expands dorsally and medially to form the superior part of the pulvinar (PULS). The latter part is the principal nucleus of the pulvinar, and is divided myeloarchitectonically into lateral and medial portions. The lateral portion (PULS1) occupies the same area as the dorsolateral nuclei which lie anterior to it, and also the greater part of n. ventralis posterior lying dorsal to the geniculate bodies. N. pulvinaris superior pars lateralis is traversed by horizontal bundles of myelinated fibres that fan out towards the medial thalamic nuclei. In this region, there is a dense area of myelinated fibres that radiate from the external medullary lamina like a tuft of grass blades. It may be the bed nucleus of the medial lemniscus (and possibly of the trigeminal lemniscus), termed the zone of Wernicke by several authors, notably Olszewski (1952) and Feremutsch (1963). The zone of Wernicke (W) lies ventromedial to n. pulvinaris superior, dorsal to n. pulvinaris inferior and lateral to n. pretectalis. Caudad, n. pulvinaris superior pars lateralis increases in size, particularly in a dorsolateral direction. It is so well marked with radiating fibre bundles that it gives a striated appearance, even in sections stained with cresyl violet. It remains in this position towards the caudal end of the thalamus, where it becomes more and more cytoarchitectonically homogeneous with the medial part of n. pulvinaris superior and n. pulvinaris inferior. The cells of n. pulvinaris superior are much larger (19 x 10 μ) than those of the medial part of n. pulvinaris superior. The former part can be further subdivided on grounds of differing myeloarchitectonics into dorsal and ventral portions; the ventral portion is much less myelinated than the dorsal portion.

The medial part of n. pulvinaris superior (PULSm) contains small to medium sized cells (17 x 12 μ) that stain less darkly and are arranged more regularly than those of the lateral part of the same nucleus and of n. lateralis posterior. N. pulvinaris superior pars medialis is related medially to the caudal end of n. mediodorsalis and caudal to the latter to nn. pretectalis and thalamicus posterior, from which it is separated by nn. tractus opticus, limitans and suprageniculatus. Caudad, the medial part becomes fused with the lateral part of n. pulvinaris superior.

N. pulvinaris pars inferior is very difficult to demarcate, especially in its rostral region, from n. pulvinaris superior, and from the geniculate bodies. N. pulvinaris pars inferior (PULI) is a fairly conspicuous structure when compared with those of *Perodicticus potto* and *Galago senegalensis*, and of higher primates. It is the most densely myelinated part of the entire pulvinar. N. pulvinaris inferior lies immediately dorsal to the metathalamus, but it is not wedged between the geniculate bodies as in higher primates; it lies only on the dorsal surfaces of these structures. The cells of n. pulvinaris inferior are similar to those in the superior part, but they are more regularly and rather more densely arranged among the myelinated fibres, and are mostly 17 x 11 /'.

(b) Lorisoidea

(i) *Perodicticus potto*

The pulvinar (Figs. 93-96) appears to be even better developed than those of the Tupaioidea and Lemuroidea. It has expanded so greatly in size that it has become one of the largest nuclei in the entire diencephalon. Its subdivisions are even better differentiated cytoarchitectonically.

The oral part of the pulvinar (PULO) is larger than its homologue in *Lemur*, and appears as a well defined mass of cells at the level of the rostral pole of n. geniculatus lateralis. The oral part of the pulvinar can be distinguished from n. lateralis posterior by the smaller size and more lightly staining cells of the former nucleus, and also by its dorsomedial relationship to n. lateralis dorsalis, which it replaces further caudally. At the level where the posterior thalamic nuclei replace the medial and intralaminar nuclear groups, n. pulvinaris pars oralis gives way to n. pulvinaris superior.

N. pulvinaris superior (PULS) covers the whole area that has been formerly occupied by the lateral nucleus and the dorsal part of n. mediodorsalis in lower mammals. It is subdivided further into lateral and medial parts, as in the Lemuroidea. The *medial part* is more cellular while the lateral part is more myelinated in appearance. In the *lateral part*, fibres streak horizontally from the external medullary lamina towards the caudal parts of nn. ventralis posterior and geniculatus lateralis. The medial part of n. pulvinaris superior contains finer myelinated fibre bundles that run throughout it, delimiting it from the posterior thalamic nuclei. Cytologically, the medial and lateral parts of n. pulvinaris superior are not very different from each other, although the lateral part appears to be laminated into two or three layers of cells arranged in neat, regular rows along the radiating fibres of the posterior thalamic peduncle. The medial part of n. pulvinaris superior can be distinguished clearly from n. pretectalis since the cells of the latter nucleus are orientated dorsoventrally in an oblique direction, and are arranged more closely together than those of the medial part of n. pulvinaris superior.

A clear area containing more cells and fewer fibres delimits the *inferior part* from the superior part of the pulvinar. Further caudally, discrete fibrous bundles run transversely through it from Wernicke's zone towards the mesencephalic tectum. The inferior part of the pulvinar lies medial to n. geniculatus medialis, dorsal to the bed nucleus of the medial lemniscus and lateral to nn. suprageniculatus and limitans. Towards the caudal end of the thalamus, n. pulvinaris inferior is shifted towards the lateral surface of the diencephalon by the expanding tegmentum of the midbrain. Here it comes to lie dorsomedial to n. geniculatus medialis, ventromedial to the caudal end of n. geniculatus lateralis, and ventral to n. pulvinaris superior, from which it remains clearly separated, throughout its remaining extent, by the posterior thalamic radiations. At the caudal end of the metathalamus, n. pulvinaris inferior covers the area vacated by the medial geniculate body, and merges with n. pulvinaris superior to form the extreme caudal pole of the thalamus.

(ii) Galagidae

The pulvinar (Figs. 101-106; 113-116) has increased further in size and is better defined topographically into superior and inferior parts than those of Perodicticus potto. In Galago crassicaudatus, the pulvinar is much larger since its superior part is further differentiated cytoarchitectonically into medial and lateral parts. In all Galago spp., n. pulvinaris pars oralis (PULO) is a small round mass of small, lightly staining cells breaking through the ventral region of n. lateralis posterior. It is actually the rostral pole of n. pulvinaris superior since its cells are smaller and less darkly staining than those of n. lateralis posterior. N. pulvinaris superior extends right to the caudal end of the thalamus where it is related dorsolaterally to the superior colliculus. At this level, n. pulvinaris pars superior is cellularly dense, and the fibres of the posterior thalamic radiations appear to be more concentrated in this nucleus than in nn. lateralis posterior and pulvinaris inferior.

N. pulvinaris inferior is a relatively smaller structure which is demarcated fairly well by a horizontal bundle of myelinated fibres from the superior part of n. pulvinaris. It has a streaky appearance due to fibres radiating like an open fan towards the medial thalamic regions. Both inferior and superior parts of the pulvinar are similar in cytological features; the cells are medium sized (16 x 12 μ).

(4) ANTHROPOIDEA

(a) Cercopithecoidea

Cercopithecus aethiops

The pulvinar (Figs. 125-128) is now an enormous posterior outgrowth of the dorsolateral thalamic group, and comprises by far the greater part of the posterior thalamic region. It extends from the rostral region of the habenula to the very caudal end of the thalamus. In higher primates, n. pulvinaris has acquired such proportions that it is subdivided distinctly into medial and lateral parts. The latter part is further differentiated topographically into superior and inferior portions. Thus, the pulvinar will be described here as consisting of medial, lateral, inferior and oral parts.

N. pulvinaris pars oralis (PULO) is the most anterior part of the pulvinar, but it may represent a rostral extension of n. pulvinaris medialis. It lies between nn. ventralis posterior and centrum medianum; its cells are of similar morphology to, but are slightly smaller than those in other parts of the pulvinar.

N. pulvinaris lateralis (PULL) is the intermediate of the three major components of the pulvinar, the smallest pulvinar component being n. pulvinaris inferior. N. pulvinaris lateralis appears to be a caudal continuation of nn. ventrales lateralis and posterior, not of n. lateralis posterior which continues directly into the medial region of the pulvinar. N. pulvinaris lateralis is subdivided topographically into superior and inferior portions. The superior portion (PULLs) lies ventral to n. pulvinaris medialis, while the inferior portion (PULLi) lies dorsolateral to the posterior part of n. geniculatus lateralis, and to n. pulvinaris inferior with which it merges caudally. N. pulvinaris lateralis is heavily myelinated, more in its superior than in its inferior portion, and than n. pulvinaris medialis.

Thick bundles of myelinated fibres run horizontally through n. pulvinaris lateralis towards the medial thalamic regions; another group of fibre bundles run dorsoventrally, delimiting it clearly from n. pulvinaris medialis. The cells of n. pulvinaris lateralis generally are medium-sized (19 x 12 μ), round or polygonal, stain fairly well and are arranged in neat, clustered rows along the radiating fibres. They are very allomorphic in neuronal classification.

N. pulvinaris medialis (PULM) is the largest of all the pulvinar components, and is further divided myeloarchitectonically into medial and lateral parts; -cellular differences in these parts are, however, very slight. The *lateral portion* of n. pulvinaris medialis, which lies dorsal to the superior portion of n. pulvinaris lateralis, is apparently a caudal continuation of n. lateralis posterior and of the dorsal part of n. ventralis posterolateralis. The *medial portion* of n. pulvinaris medialis lies dorsomedial to the superior portion of n. pulvinaris lateralis, lateral to n. habenularis and to the habenulopeduncular tract, and ventral to n. pretectalis. The cells of the medial portion are similar to those of the lateral portion of n. pulvinaris medialis, but in the former portion there are numerous large and pale-staining cells arranged more loosely along fewer myelinated fibres. Caudally, both lateral and medial portions merge to form the main mass of n. pulvinaris medialis. There, n. pulvinaris medialis appears to be less fibrous and more cellular in appearance than n. pulvinaris lateralis. The cells of n. pulvinaris medialis are mostly medium sized (15 x 12 μ), stain less darkly and are arranged more compactly than those of n. pulvinaris lateralis.

N. pulvinaris inferior (PULI) is identified very easily by its being wedged between the geniculate bodies. It lies ventral to the inferior part of n. pulvinaris lateralis with which it becomes continuous caudally. The cells of n. pulvinaris inferior are medium-sized (15 x 12 $/^{u}$) and oval in shape, stain lightly and are scattered evenly in the nucleus. The myelin content of n. pulvinaris inferior is slightly greater than in other parts of the pulvinar, since heavily myelinated fibres run mediolaterally through it from the external medullary lamina and from the terminal region of the medial lemniscus.

(b) *Hominoidea*

Homo sapiens

The pulvinar (Figs. 135-140) is, by far, the largest structure not only in the thalamus, but in the entire diencephalon. It forms the extreme posterior portion of the thalamus that hangs over the geniculate bodies and the dorsolateral surface of the midbrain. As in other primate species, the pulvinar can be differentiated myeloarchitectonically and cytoarchitectonically into oral, medial, lateral and inferior parts. The *lateral part* of the pulvinar, particularly its superior portion, contains dense myelinated fibres that radiate medialwards like a palm frond towards the mesencephalic tectum. The cells of n. pulvinaris lateralis are rather large, deeply staining and arranged regularly in clumps along the fibres. The *medial part* of the pulvinar is now the largest of all the pulvinar parts; it is composed of more compactly arranged, smaller, more lightly staining, polygonal cells. From rostral to caudal, n. pulvinaris medialis is related medially to the caudal part of n. mediodorsalis, then to n. pretectalis, and finally to the superior colliculus of the midbrain.

The *inferior part* of the pulvinar is a well-formed and large structure which can be distinguished from the rest of the pulvinar by its more densely myelinated appearance, and by its relationship to metathalamic structures. It lies dorsal to n. geniculatus lateralis laterally and to n. geniculatus medialis medially, and lateral to the zone of Wernicke. Further caudally, n. pulvinaris inferior disappears, being absorbed into the main mass of the pulvinar. The cells of n. pulvinaris inferior are more lightly staining and less polygonal in shape than those of n. pulvinaris lateralis.

Discussion on the pulvinar

Kruger (1959) does not agree with Le Gros Clark that the pulvinar is an exclusive primate acquisition, because the pulvinar is large and well developed also in the Cetacea. However, he finds it difficult to homologize the divisions of the pulvinar with those of the primate pulvinar, due to discordant descriptions and confusing terminology in the literature. If the pulvinar has actually expanded in higher non-primate forms, then it should be a noteworthy feature in the dolphin thalamus. Kruger points out that the pulvinar is well developed even in the elephant. Therefore, the unique position of the primate pulvinar remains open to question, at least, as concerns its phylogeny and its development from the dorsolateral thalamic region.

Le Gros Clark (1932) discussed the difficulty of homologizing n. lateralis posterior of lower primates with the pulvinar of higher primates, because, up to the time of his work on the thalamus of *Tarsius* (1930), the relationships of n. lateralis posterior to the pulvinar in mammals had not been defined satisfactorily. Kappers (1921) maintained that the pulvinar was entirely a primate acquisition. Vogt (1909) defined the caudal extent of n. lateralis posterior as the pulvinar, but since it is only a topographical definition, the boundaries between these structures are considered not satisfactory for comparative purposes with those of other primate species. Therefore, the boundary between the pulvinar and the dorsolateral thalamic group is still not determined. It is a matter of personal opinion whether a particular cellular group should be allocated to the pulvinar or to the lateral thalamic region. The term "pulvinar" in primates is used to denote a group of nuclei or a large mass of medium-sized, lightly staining, regularly arranged cells forming the posterior extremity of the thalamus that is related topographically to the metathalamus, superior colliculus and optic tract.

Le Gros Clark (1930) compares the topography of the whole n. lateralis posterior of Tarsius with the pulvinar of higher primates, since both are related to the metathalamus and part of the mesencephalic tectum that lies dorsal and medial to the lateral and medial geniculate bodies. N. lateralis posterior of Tarsius and its homologue in higher primates are continuous rostrally with the rest of the lateral thalamic nucleus. Therefore, Le Gros Clark's statement 'far from being a prerogative of the Primates, the pulvinar is a common mammalian feature' appears to contradict his other statement in which he regards the strongly develcped pulvinar as an exclusive primate acquisition. However, my observations show that the relative size of n. lateralis posterior in Elephantulus may raise an objection to any idea or suggestion that the pulvinar is also a non-primate mammalian acquisition. Moreover, the phylogenetic features of the pulvinar throughout the primates show that it has developed directly from the lateral nuclear group, particularly n. lateralis posterior, as observed first in the tree-shrews. The pulvinar represents, without doubt, an elaboration of the posterior or caudal region of the thalamus that is particular to primates, even though it has been said to be present in the dolphin and elephant (Kruger 1959). If the pulvinar is regarded as a part of the cerebral mechanism associated predominantly with visual functions, it should be expected that its representation in the primate thalamus will be proportionally greater than that of n. lateralis posterior in lower forms.

Feremutsch (1963) regards the pulvinar as a caudal continuation of his n. lateralis pars dorsalis intermedius or of n. lateralis pars anterior, not of n. lateralis pars posterior. However, these homologies do not correspond to those of my prosimian specimens, in which the pulvinar is essentially a caudal continuation of the whole dorsolateral nuclear group, not only of one part of the lateral thalamic nucleus. As it is intimately related topographically to the metathalamus and mesencephalic tectum, the phylogeny of n. lateralis posterior/pulvinar appears to be linked very closely to that of n. geniculatus lateralis and the visual areas in the cerebral cortex.

SUMMARY OF THE DORSOLATERAL THALAMIC NUCLEI AND PULVINAR

The dorsolateral nuclear group, particularly the pulvinar, has a significant evolutionary history. It develops from a small, simple and undifferentiated mass lying lateral to the internal medullary lamina in insectivores to a large group of nuclei which extend much farther in primates. The lateral nucleus of Insectivora is a small and undeveloped structure, and is even more primitive than that of certain non-primate mammals, e.g., carnivores and cetaceans. In the tree-shrews, the lateral nucleus takes a further step in phylogeny. It becomes better defined topographically into dorsal, intermediate and posterior parts, and develops a noteable caudal extension, the pulvinar. However, these parts are still homogeneous cytoarchitectonically, and can be delineated from each other mostly on myeloarchitectonic grounds.

In Prosimii, the dorsolateral nuclei remain more or less unchanged in their topographical positions. Cytoarchitectonic differentiation continues in these nuclei, and myeloarchitectonic distinctions are clearer, particularly in the pulvinar, which is divided into superior and inferior parts.

In Anthropoidea, the dorsolateral nuclear group becomes further differentiated into distinct nuclei. Nn. laterales dorsalis and posterior can be distinguished cytologically from each other. N. lateralis intermedius is, at first, a large and well-defined area lying between nn. laterales dorsalis and posterior. As one goes up the primate scale, it is reduced considerably in size until it becomes almost a narrow transitional zone between the dorsolateral and ventrolateral nuclei. The pulvinar is an enormous growth from all the dorsolateral nuclei. On account of its structural expansion, the pulvinar is divided into several parts, each possessing distinct cyto- and myeloarchitectonic features. The pulvinar of higher primates, including man is the most conspicuous feature in the lateral thalamic region; it has progressed rapidly from a simple outgrowth of the lateral nucleus to a very highly developed and intrinsically differentiated supernucleus. Its inferior part intervenes between the geniculate bodies to form a prominent protuberance on the ventral surface of the diencephalon.

The structural features, cyto- and myeloarchitectonic properties and evolutionary trends of the dorsolateral nuclear group are summarized in Table 15.

Table 15 COMPARISONS OF THE DORSOLATERAL THALAMIC NUCLEI

FEATURES	N. lateralis dorsalis (LD)	N. lateralis intermedius (LI)	N. lateralis posterior (LP)	N. pulvinaris superior (PULS)	N. pulvinaris inferior (PULI)
STRUCTURAL FEATURES	In Elephantulus, LD is a simple and undifferentiated structure situated most superficially in the dorsal region of the thalamus. Larger and better developed in the tree-shrew and can be distinguished topographically from LI and LP, but not cytoarchitectonically. In Prosimii, LD increases moderately in size, and is not readily distinguishable from LI and LD, though cytoarchitectonic differentiation appears to occur in these primate species. In higher primates, it is a very well formed structure which appears to be almost encapsulated from the adjoining nuclei, and is even demarcated from LP by a fibrous band.	Not present in Elephantulus. Is a small area in the Tupaioidea; it lies between LD and LI. Is larger and more distinguishable topographically in all prosimians, but no marked cytoarchitectonic and cytological distinctions from other lateral nuclei are present. In a large transitional zone in higher prosimians and cercopithecoids, can be recognised as a much more lightly staining area between LD and LP, and also between LP and n. ventralis lateralis. In higher primates LI reduces considerably in size, and is merely a "buffer zone" between dorsolateral and ventrolateral nuclear regions merges with LP without any distinctions. Is not present in man.	In Elephantulus, LP is smaller in size and extent than LD and LI put together. Increases in structural size and functional importance up the scale from tree-shrews through prosimian and simian primates to man. In the tree-shrew, LP is relatively smaller than LI but has a pronounced caudal extension, the pulvinar. In all prosimians, LP is much larger and better differentiated topographically from LD and LI. It continues expanding caudalwards, forming the main body of the pulvinar. In higher primates, it is shifted farther away from the dorsal surface, and forms the main mass of the dorsolateral thalamic region. It is represented on the dorsal surface only by a small area of large, dark-staining cells - pars angularis (ANG) which is seen in the monkey, but not in man.	Not present in Elephantulus. Probably becomes a notable feature first in the Tupaioidea as a dorsal and caudal expansion of LP, lying dorsal and medial to n. geniculatus lateralis. It is comparatively small and undifferentiated, broader dorsally and narrower ventrally. In all prosimians it increases progressively in size until it becomes clearly differentiated myeloarchitectonically into medial and lateral parts. Is well demarcated from PULI by thick strands of fibres. In higher primates, it continues increasing in size and extent until in man, it becomes the largest structure, not only in the thalamus, but also in the whole diencephalon. It shows signs of lamination into several cellular strata, but is best divided into medial and lateral parts, as well as oral and caudal parts.	Not present in Elephantulus. Is not distinguishable in all respects from PULS in the tree-shrew. In prosimians, it is better demarcated myeloarchitectonically and is distinguishable even cytoarchitectonically from PULS. It is smaller in area, and lies in close relation to the metathalamic structures - known as the geniculate part of PUL. As PUL expands further in size and extent, PULI is pushed further ventrally and caudally to form a sort of wedge between the geniculate bodies. In man, however, PULI lies on the dorsal surface of n. geniculatus lateralis, and forms part of the posterior extremity of the thalamus which is easily seen macroscopically to hang over the geniculate bodies.
CELLULAR PROPERTIES (CYTO-ARCHITECTONIC	Small to medium-sized cells (12 x 9 $/^{\mu}$ in Tupaia to 18 x 12 $/^{\mu}$ in Cercopithecus). Mostly lightly staining and oval-shaped - Are arranged more densely than those of LI and LP. Slight increase in size, but not in stainability and no changes in neuronal classification.	Not much different cytologically from LP. Cells are medium-sized to large (11 x 9 $/^{\mu}$ in Tupaia to 22 x 14 $/^{\mu}$ in Cercopithecus) They are larger and better staining than those of LD. . Notable increase in size and stainability, but this is attributable only to its incorporation into LP.	No cytological differences from LD and LI, particularly in the Tupaioidea and Prosimii. But cytoarchitectonic differentiation from LD and LI occurs as one ascends the prosimian scale towards anthropoids. Cells are much larger, more darkly staining and more regularly arranged along the fibres. Cells are 15 x 10 $/^{\mu}$ in Galago to 21 x 12 $/^{\mu}$ in Cercopithecus, sometimes over 25 $/^{\mu}$.	Cells of PULS in Tupaia are smaller, more lightly staining and less varied in shape than those of LP; they are distributed evenly in a loose manner. In prosimians, there are no significant cytological differences between medial and lateral parts. There are no significant cytological differences. Cells are, however, arranged more densely in the lateral than in the medial part. Cells are 12 x 9 $/^{\mu}$ Tupaia to 19 x 12 $/^{\mu}$ in Cercopithecus; ~~a second~~ ~~[illegible]~~ in higher primates, cells are much larger and more deeply staining and are over 25 $/^{\mu}$.	In Tupaia, PULI forms an inferior part of PUL, and has the same cytological characteristics as the superior part. In prosimians, cells of PULI differ very little from those of PULS, except that they are distributed more densely and regularly among the fibres. Cells are 13 x 10 $/^{\mu}$ in Tupaia to 17 x 12 $/^{\mu}$ in Galago; they are notably smaller in higher primates, being less than 16 $/^{\mu}$ in Cercopithecus. ~~Types [illegible]~~ - changing in neuronal classification as one goes from Tupaia to Cercopithecus and man.

TABLE 15 COMPARISONS OF THE DORSOLATERAL THALAMIC NUCLEI

FEATURES	N. lateralis dorsalis (LD)	N. lateralis intermedius (LI)	N. lateralis posterior (LP)	N. pulvinaris superior (PULS)	N. pulvinaris inferior (PULI)
FIBRE ARRANGEMENT AND MYELIN CONTENT (MYELO-ARCHITECTONICS)	In *Tupaia* and all prosimians LD is more lightly myelinated than LP, and contains more fibres in its lateral than in its medial part. In Lemur and *Galago*, LD appears to be cut off from LI and LP by a horizontal band of fibres, which becomes more attenuated in higher primates.	Is usually a very lightly myelinated area, containing regularly arranged fibres running horizontally from the external medullary lamina medialwards. LI is, however, more densely myelinated in its lateral than in medial part. In higher primates it is much more myelinated but not more than LP.	Richer in myelin content than other dorsolateral nuclei; is usually streaky in appearance due to horizontal and transverse bundles of fibres coursing throughout the nucleus. More fibrous laterally than medially. Contains fibres of the posterior thalamic peduncle, as well as fibre projections from lower centres.	Is generally less myelinated than PULI and LP. More fibrous laterally and ventrally than medially and dorsally. Fibres are arranged in a similar manner as in LP. Shows a close relationship to n. ventralis posterior and n. geniculatus lateralis.	Contains dense fibre bundles in the region proximal to n. ventralis posterior and n. geniculatus medialis, thus showing an intimate relationship with these nuclei.
PHYLOGENETIC TRENDS	Not a differentiated part of the lateral nucleus, in *Elephantulus*. Shows first signs of change in structure in Tupaia, and is better differentiated from LI and LP. Evolves throughout the prosimian scale into a well defined nucleus. Is a well developed structure having a moderate phylogenetic development in the primate thalamus.	Beyond Lemur, LI does not show significant phylogenetic features. Is only a transitional zone between LP and as well as between LP and VL. Is smaller in higher prosimians and reduces considerably in size throughout out the higher primate scale. Has a lower phylogenetic value than LD and LP.	LP is one of the most phylogenetically progressive elements of the thalamus. Is small and insignificant in non-primates and tupaioids, but gains prominence in structure as well as having more cellular distinctions as one goes up the primate scale. Is continuous directly with the pulvinar.	With PULI, it has the most remarkable phylogenetic history of all the elements of the diencephalon. It develops from a small and undivided area, as in the Tupaioidea, and increases rapidly in size and extent throughout the prosimians. In these species, PULS is differentiated cytoarchitectonically into lateral and medial parts, but these do not have the same fibre projections to the cerebral cortex. However, in higher primates, it is of such enormous proportions that it is divided into lateral and medial parts, not of the superior part, but each with cyto- and myelo-architectonic features of its own. Thus, it has the characteristics of a supernucleus since it is subdivided into several separate parts, like n. medialis.	PULI is a distinct feature in the primate diencephalon. Has its own cellular and fibrous particularities which show constant relationships with the ventrolateral nuclei and metathalamus throughout the primate scale. Together with PULS, it is a very phylogenetically progressive element of the primate diencephalon.

CHAPTER 9

THE THALAMUS: VENTROLATERAL NUCLEAR GROUP

In primates, the ventrolateral thalamic nuclei make the most remarkable progress in structural evolution and expansion. As mentioned in Chapter 8, the ventrolateral thalamic nuclear region is distinguishable topographically and histologically from the dorsolateral thalamic nuclei. A well-defined, thick fibrous bundle runs from Wernicke's area lateromedially towards the medial thalamic regions, delimiting these two lateral thalamic areas clearly from each other. The state of development of the ventrolateral nuclei of the Tupaioidea and Prosimii is somewhat between the simple, poorly differentiated ventral nucleus of Elephantulus and the complicated and most highly differentiated ventrolateral thalamic mass of higher primates.

The ventral group of nuclei consists mainly of anterior, lateral and posterior nuclei, as well as other ventral nuclei of smaller size and lesser functional importance. These nuclei are:-

1. N. ventralis anterior (VA)
2. N. ventralis lateralis (VL)
3. N. ventralis medialis (VM)
4. N. ventralis intermedius (VI)
5. N. ventralis dorsomedialis (VDM)
6. N. ventralis posterior which is further subdivided into:
   (a) pars lateralis (VPL)
   (b) pars medialis (VPM)
   (c) pars inferior (VPI)

1. N. ventralis anterior (VA) (Plates 6 - 49)

(1) INSECTIVORA

Macroscelidoidea

Elephantulus myurus

The ventral nucleus is comparatively little differentiated

However, on grounds of cytoarchitectonic differences, Allison (1947) has n. ventralis subdivided into anterior, intermediate and medial parts, but he did not describe the lateral and posterior parts of the same nucleus. In this study, the ventral nucleus of Elephantulus is subdivided, on grounds of both topographical and cytological differences, into anterior, lateral, medial and posterior parts. These parts will be described under their respective headings.

N. ventralis anterior is the largest of all the ventral nuclear divisions. It lies rostral and dorsal to the posterior part of n. ventralis, ventral and medial to the anterior thalamic nuclei, and dorsal and lateral to n. reticularis. N. ventralis anterior has small, rather well staining, round cells that are distributed irregularly among interwoven fascicles of thick fibres. It does not end abruptly but seems to give way to more lightly myelinated areas with more regularly arranged, slightly larger, better staining, polygonal cells that identify the lateral and medial parts of the ventral nucleus.

(2) TUPAIOIDEA

In the tree-shrew, the ventrolateral nuclei are subdivided into separate topographical units more clearly than in the insectivores. However, it is difficult to delimit, with certainty, n. ventralis anterior from nn. ventrales lateralis and medialis, owing to similarities in cytology and cytoarchitectonics of all these nuclei.

N. ventralis anterior (Figs. 43-46) appears at a more rostral level than the other nuclei of the dorso- and ventro-lateral groups. It may be subdivided topographically and myeloarchitectonically into medial and lateral parts, which continue caudally into ventromedial and ventrolateral nuclei respectively. The lateral part of n. ventralis anterior (VAL) lies medial and dorsal to n. reticularis, and ventral to n. anteroventralis. It contains large, deeply staining, polygonal or fusiform cells that are arranged diffusely among thick myelinated fibres. The *medial part* of n. ventralis anterior (VAm) is a more lightly myelinated area containing more regularly arranged cells that are not different cytologically from those of the lateral part of n. ventralis anterior. At the level of the caudal end of the anterior thalamic nuclei, n. ventralis anterior is replaced medially by n. ventralis medialis and laterally by n. ventralis lateralis.

(3) PROSIMII

Lemuroidea and Lorisoidea

N. ventralis anterior (Figs. 52-74; 86-110) appears to be better developed in larger than in smaller prosimians. It is more easily delimited from n. ventralis lateralis, and is seemingly larger that of the Tupaioidea. However, n. ventralis anterior is not as large as nn. laterales intermedius and posterior when combined as in higher primates. N. ventralis anterior commences at the level where n. reticularis is shifted towards the lateral surface of the thalamus. It lies lateral to nn. submedius and reuniens, ventral to nn. anteromedialis and anteroventralis, and dorsomedial to n. reticularis. Caudad, n. ventralis anterior is displaced to a more medial and ventral position by n. ventralis lateralis which appears in the lateral region between the former nucleus and the anterior nuclei. Farther caudally, n. ventralis anterior is replaced by a more lightly staining and more cellularly dense n. ventralis medialis. The cells of n. ventralis anterior can be distinguished quite clearly by their larger size, more intense staining and looser arrangement among fibres of the inferior thalamic peduncle, from those of nn. ventrales lateralis and medialis.

In *Galago crassicaudatus*, n. ventralis anterior has the same features as in smaller galagids, but is structurally larger and better differentiated cytologically. This nucleus in *Perodicticus potto* does not differ much from that of *Lemur* and *Galago*. In all these species, n. ventralis anterior is a rounded and richly myelinated structure that appears in the most rostral region of the thalamus that appears at the oral level of n. anteroventralis. N. ventralis anterior lies medial and ventral to the rostrodorsal region of n. reticularis, from which it can be distinguished by the reticulated appearance of the latter nucleus. In lorises and galagos, n. ventralis anterior is monomorphous and isoformic, having large cells (20 x 11 µ) that stain well, are polygonal and are scattered loosely among thick myelinated fibres.

In the Lemuroidea, n. ventralis anterior is even larger and better developed than that of the Lorisoidea. It is subdivided, on grounds of differing cellular and fibrous features, into medial and lateral parts. The *lateral part* of n. ventralis anterior (VAl) is more densely myelinated than the medial part of the same nucleus; thick fibre fascicles run in all directions through the nucleus from Wernicke's area, and they form a part of the inferior thalamic peduncle. The *medial part* of n. ventralis anterior (VAm) contains fewer fibres, and is more cellular than the lateral part. The cells of n. ventralis anterior in *Lemur* spp. are large (19 x 15 µ), stain very deeply and are multipolar.

(4) ANTHROPOIDEA

(a) *Cercopithecoidea*

Cercopithecus aethiops

N. ventralis anterior (Figs.117 - 118) is even larger and further developed than that of Prosimii. It extends from the rostral pole of n. anteroventralis to the level of n. subthalamicus where it merges with n. ventralis lateralis. The cellular differences between these two ventral nuclei are slight. However, they are clearly delimited myeloarchitectonically from each other. N. ventralis anterior has a characteristic myelin appearance: it is mottled towards the medial side and heavily stippled towards the lateral side, whereas n. ventralis lateralis has well arranged fibres bundles traversing its substance. The cells of n. ventralis anterior are larger than in the prosimians ($27 \times 15\ \mu$); they stain relatively well, are stellate in shape, and are arranged regularly in rows along the radiating fibre bundles.

(b) Hominoidea

Homo sapiens

N. ventralis anterior (Figs.129-130) is displaced to a more rostral position due to the expansion of nn. ventrales lateralis and posterior. It is almost equal in areal size to n. ventralis lateralis, and appears subjectively to be larger than that of the vervet monkey. The architectonic features of n. ventralis anterior are distinctive, thus distinguishing it easily from nn. ventrales lateralis and posterior. It is well encapsulated by fibres on all sides, except caudally, where it continues into n. ventralis lateralis. The cytological features of n. ventralis anterior are the same as those of the vervet monkey; the myelin content is richer due to a dense network of coarse and fine fibres coursing in this nucleus.

Discussion on n. ventralis anterior

The ventral nuclear complex begins as a small ventral extension of the lateral nucleus in rodents, but in ungulates, carnivores and cetaceans, it becomes gradually larger and better differentiated into topographical regions. Eventually, it becomes the most highly elaborated and functionally important region of the thalamus in Primates. The ventral nuclear region is generally composed of six distinct topographical units, each of which possesses its own cyto- and myelo-architectonic characteristics.

Bauchot (1963) states that his n. ventralis oralis is much larger and more voluminous than other ventral nuclei in lipotyphlan insectivores e.g., *Talpa* and *Sorex*, but it is comparatively poorly developed in menotyphlan insectivores, e.g., *Elephantulus*, in tree-shrews, e.g., *Tupaia*, and galagos, e.g., *Galago demidovii*.

In the two latter species, n. ventralis oralis is divided into lateral, intermediate and medial parts. These divisions of n. ventralis oralis of Bauchot appear to correspond well with n. ventralis pars anterior in *Elephantulus*, but these parts are not different from each other cyto- and myelo-architectonically. In all primate species and tree-shrews studied here, nn. ventralis and lateralis intermedius seem to homologize rather well with the intermediate part of n. ventralis oralis, while the medial and lateral parts of n. ventralis oralis may correspond with the rostral part of n. ventralis medialis and the lateral part of n. ventralis anterior respectively. The cellular distinction between n. lateralis intermedius and the lateral part of n. ventralis anterior is, furthermore, better defined in tree-shrews and lower than in higher primates.

Le Gros Clark (1929) had the ventral nucleus of *Tupaia minor* divided into anterior and posterior parts mainly on grounds of structural differences. His n. ventralis anterior is further subdivided into medial and lateral parts which differ from each other in myeloarchitectonic and topographic characteristics; cytoarchitectoni differences have not been described. Le Gros Clark's n. ventralis anterior pars medialis appears to be synonymous with Pines's nucleus "vtm" in *Lemur catta* (1927), Gurdjian's n. ventromedialis in the rat (1927), and with the medial part of n. ventralis anterior in my tupaioid species. However, this nucleus is homologous to n. ventralis medialis of prosimians used in this study and other authors. The lateral part of Le Gros Clark's n. ventralis anterior in *Tupaia minor* is synonymous with Pines's "vtl" in *Lemur catta* and with Gurdjian's n. ventralis pars anterior in the rat. However, it is not easy to decide whether the lateral part of n. ventralis anterior of Le Gros Clark corresponds with the lateral part of the same nucleus or n. ventralis lateralis of my tupaioid species. It is because Le Gros Clark describes this nucleus as a structure containing smaller, more diffusely arranged, fusiform cells that lie lateral to the medial part of n. ventralis anterior, rostral to n. anteroventralis and caudal to his n. lateralis "b". In *Tupaia minor*, as well as in other tupaioids used in this study, the cellular characteristics do not conform with those of Le Gros Clark, since the cells of n. ventralis anterior are typically larger, more darkly staining, multipolar and more regularly arranged in the lateral than in the medial part of n. ventralis anterior. Furthermore, heteromorphism between n. ventralis anterior and n. paracentralis or n. mediodorsalis as described by Le Gros Clark, and subsequently by Feremutsch (1963), is not observed in *Tupaia glis* here. A clear acellular zone extends ventralwards from the lateral extremity of n. paracentralis, separating the medial part from the lateral part of n. ventralis anterior. At this level, Le Gros Clark observed that n. paracentralis appears to be replaced by an irregular, very ill-defined mass of small cells that are distributed more extensively farther caudally. This area is most likely to be Gurdjian's n. ventralis pars dorsomedialis in the rat, and n. ventralis dorsomedialis of higher primates, as will be discussed later in this chapter.

N. ventralis of *Tarsius* (Le Gros Clark, 1930) is a very well developed structure that stands out as a conspicuously lobulated mass in the thalamus. It is divided into anterior and posterior parts, but the anterior part is not well delimited into medial and lateral portions as in tree-shrews and prosimians studied here. The *medial* part of n. ventralis anterior is poorly defined and short in rostrocaudal extent. It continues caudally directly into n. ventralis medialis, while the *lateral* part of n. ventralis anterior forms the main body of the ventral anterior nucleus. The latter structure is much larger and more encapsulated than that of other prosimians;

it is demarcated by a fibrous strand from n. ventralis posterior ventrally and caudally, and from the lateral nucleus dorsally and rostrally. One can infer from structural and cytological differences of n. ventralis anterior in both Tupaia and Tarsius that this nucleus becomes progressively smaller and more compactly constructed on going up the primate scale towards man. This may be due to the expansion of n. ventralis lateralis and its encroachment on n. ventralis anterior. The latter nucleus, thus, appears to be pushed, particularly in its caudal part, towards the medial thalamic region, where it comes to be related closely to the midline and medial thalamic nuclei, and to the subthalamus.

In his prosimian specimens, Feremutsch (1963) does not divide the ventral nucleus, as he regards it as only a ventroposterior extension of the lateral thalamic nucleus. N. ventralis anterior of higher primates corresponds with Feremutsch's n. lateralis pars reticularis, whereas n. ventralis lateralis homologizes with his n. lateralis principalis (see Table 16 page 258). Feremutsch maintains that both nuclei are notably distinct myeloarchitectonically from each other, while in my primate specimens, both cyto- and myeloarchitectonic differences are well discerned in these two ventral nuclei. My observations, thus, conform Shep's (1945) and Dekaban's (1953) descriptions of n. ventralis anterior as a discrete nucleus which can be delineated myeloarchitectonically from n. ventralis lateralis. Toncray and Krieg (1946) and McLardy (1950) do not find any distinction between these two ventral nuclei, even though the latter author maintains that they are separate entities on account of their different fibre projections to the cerebral cortex.

From the above discussions, my opinion is that in higher primates, n. ventralis anterior remains more or less distinguishable from n. ventralis lateralis, and it has a denser myeloarchitectonic pattern than that of the latter nucleus. The cells of n. ventralis anterior are much larger, more darkly staining and polygonal than those of n. ventralis lateralis; they are scattered more irregularly among traversing fibres of the inferior and superior thalamic peduncles. These cells are better observed in the lateral part of n. ventralis anterior, thus confirming Olszewski's description of the same nucleus in the monkey thalamus.

2. N. ventralis lateralis (VL) (Plates 8 - 51)

(1) INSECTIVORA

Macroscelidioidea

Elephantulus myurus

N. ventralis lateralis (Figs. 35-36) is not recognizable as a separate entity in this species. It may form a lateral part of n. ventralis anterior or the main body of the ventral nucleus that has large, deeply staining, polyhedral cells lying below the lateral thalamic nucleus. Caudad, this part merges without any distinction with the posterior part of the ventral nucleus.

(2) TUPAIOIDEA

N. ventralis lateralis (Figs. 47-50) is not easily demarcated rostrally from n. ventralis anterior. It appears at the level of the rostral pole of n. lateralis dorsalis as a less densely myelinated area lying ventral to n. lateralis intermedius, and dorsolateral to n. ventralis anterior. N. ventralis lateralis is a small nucleus with a short rostrocaudal extent. It is not yet differentiated, as in higher forms, into lateral and medial portions. N. ventralis lateralis contains mostly cells that are slightly larger, less darkly staining, more oval than stellate, than those of n. ventralis anterior (16 x 11 μ); these cells are distributed evenly among thick fascicles of fibres that run horizontally and transversely through the nucleus. In its caudal part, n. ventralis lateralis moves dorsalwards into the area which has been occupied rostrally by n. lateralis intermedius, and it becomes an immediate ventral relation of n. lateralis posterior. Where n. ventralis lateralis becomes less densely myelinated, it is replaced by n. ventralis intermedius, which has fewer myelinated fibres and more clustered cells that lie close to Wernicke's area, dorsal to the lateral part of n. ventralis posterolateralis.

(3) PROSIMII

Lemuroidea and Lorisoidea

N. ventralis lateralis (Figs. 55-80; 89-112) is still not clearly demarcated from n. ventralis anterior, but it is identifiable by its more lightly reticulated appearance. N. ventralis lateralis increases considerably in size, and may be divided into medial and lateral parts on both cyto- and myelo-architectonic grounds, particularly in *Galago crassicaudatus*. The *lateral part* of n. ventralis lateralis (VLl) consists of medium-sized to large cells (18 x 15 μ to 20 x 11 μ) that are dark-staining, pyramidal or polygonal, and are arranged irregularly among the fibres. The *medial part* (VLm) is composed of smaller, more lightly staining, fusiform or oval cells that are distributed uniformly throughout the substance; it is less myelinated than the lateral part. N. ventralis lateralis either is replaced by n. lateralis posterior or merges insensibly with n. ventralis posterolateralis.

In *Microcebus murinus*, n. ventralis lateralis has morphological characteristics that resemble those of the Tupaioidea more than of the Lemuroidea. In *Perodicticus potto*, n. ventralis lateralis is better distinguished cytoarchitectonically from nn. ventrales anterior and medialis. However, n. ventralis lateralis has the same cellular characteristics as in other prosimians. It is divided clearly into a larger, densely myelinated, lateral part and a smaller, highly cellular, medial part. The *lateral part* is related dorsally to the anterior nuclei, laterally to the dorsal part of n. reticularis, medially, first, to the caudal part of n. ventralis anterior, and then, to nn. ventralis medialis and paracentralis separating it from n. mediodorsalis, ventrally to the zona incerta and n. reticularis pars ventralis. The *medial part* is related rostrally to n. ventralis anterior, laterally to n. ventralis medialis, ventrally to the intralaminar nuclei, and ventrally to the zona incerta. Farther caudally, n. ventralis lateralis expands in size and replaces n. ventralis anterior medially. There, it lies lateral to n. ventralis medialis, ventral to n. lateralis intermedius, and dorsal to the rostral part of n. ventralis posterior. N. reticularis remains its lateral relation throughout its caudal extent. N. ventralis lateralis is replaced dorsally by n. lateralis posterior and ventrally by n. ventralis posterolateralis.

In all *Lemur* specimens, n. ventralis lateralis is not very different topographically and cytologically from that *Perodicticus potto*. The cells of n. ventralis lateralis are large (20 x 11 μ), stain well, are polygonal in shape and are arranged very closely along fibre fascicles. Generally, n. ventralis lateralis is monomorphous, but it has a slight tendency towards heteromorphism, and is rather anisoformic.

(4) ANTHROPOIDEA

(a) *Cercopithecoidea*

Cercopithecus aethiops

N. ventralis lateralis (Figs. 119-120) is a distinct entity, separable from n. ventralis anterior topographically and architectonically. Some investigators split it between n. lateralis posterior caudally and n. ventralis posterior ventrally, resulting in the formation of smaller ventral nuclei, such as nn.

ventrales ventralis, intermedius and dorsomedialis, as described frequently in the literature on the primate thalamus. On the other hand, n. ventralis lateralis may be regarded as a caudal continuation of n. ventralis anterior, but it has entirely different anatomical and physiological characteristics which distinguish it clearly from nn. ventrales anterior and posterior. Furthermore, n. ventralis lateralis is much larger in size and extent than n. ventralis anterior, and it can be divided into medial and lateral portions, even on grounds of different cellular characteristics. The <u>medial part</u> has small to medium-sized, lightly staining, polygonal cells that are scattered irregularly among the fibres, while the <u>lateral part</u> contains large cells (25 x 15 μ) that stain very darkly, are multipolar, and are arranged more compactly along the horizontal fibre bundles. The topographical relations of n. ventralis lateralis are not the same as in lower primates, because this nucleus has expanded farther caudally towards the posterior thalamic region. Therefore, n. ventralis lateralis is bounded anteriorly by n. ventralis anterior, dorsally by the anterior and dorsolateral nuclei, laterally by n. reticularis, ventrally by n. ventralis posterolateralis and posteriorly by n. lateralis posterior with which n. ventralis lateralis appears to merge insensibly.

(b) <u>Hominoidea</u>

<u>Homo sapiens</u>

<u>N. ventralis lateralis</u> (Figs. 129-134) is demarcated clearly from both nn. ventrales anterior and posterior, and is divided into medial and lateral parts with the same topographical relations as in the vervet monkey. N. ventralis lateralis is replaced at the level of the rostral part of the habenular region by n. lateralis posterior dorsally and n. ventralis posterolateralis ventrally. N. ventralis medialis may have been absorbed into the medial part of n. ventralis lateralis during the rostrocaudal and medial expansion of the latter nucleus. The lateral part of n. ventralis lateralis

is then the main body of the nucleus. It contains very large dark-staining, multipolar cells arranged in a regular manner along the radiating fibres of the inferior and superior thalamic peduncles.

Discussion on n. ventralis lateralis

Pines (1927), Le Gros Clark (1929-1932), Bauchot (1963) and Feremutsch (1963) did not indicate the presence of n. ventralis lateralis as a separate entity in thei~~r~~ tupaiid and prosimian material. They may have included it in the lateral part of their ventral nucleus, either of its anterior or posterior division. Kanagasuntheram et al (1968) identified n. ventralis lateralis by its more reticulated appearance, larger area, and smaller, more lightly staining and more densely arranged cells, that distinguish it from n. ventralis anterior. My observations of n. ventralis lateralis conform with those of Kanagasuntheram et al, but these authors did not subdivide it into medial and lateral parts on the basis of differing myeloarchitectonics as have been described in my prosimian material. In *M. mulatta*, Papez and Aronson (1934) labelled n. ventralis lateralis as n. ventralis pars lateralis, and included n. ventralis posterior with it. Walker (1937, 1938) termed the anterior half of his ventral nucleus as n. ventralis lateralis which was further subdivided cytoarchitectonically into medial and lateral parts. Those features conformed with those in the macaque monkey (Olszewski 1952), the vervet monkey (Simmons 1965) and man (Dekaban 1953).

Kruger (1959) found, in the dolphin, that the distinction between the lateral and medial parts was more striking than in the rostral and caudal parts of n. ventralis lateralis. However, this distinction is less defined in the same nucleus of higher primates, because either cellular differences within the nucleus do not correspond with those found in non-primate forms, or it has not yet been confirmed in primates. Therefore, it is apparent in this study that the medial part of n. ventralis lateralis may be either the medial part of n. ventralis anterior continuing caudally into n. ventralis medialis as in lower primates, or is just a rostral extension of n. ventralis posteromedialis as in higher primates. Any nucleus lying close to n. ventralis lateralis, e.g., nn. ventrales ventralis, intermedius and dorsomedialis, may be regarded as a division of n. ventralis lateralis. Krieg (1948) included n. ventralis lateralis in his n. ventralis ventralis. Heiner (1960) suggested that nn. ventrales lateralis, medialis and intermedius should be re-designated as n. ventralis ventralis owing to the latter nucleus's topographical position in the ventral region of the thalamus. Olszewski (1953) had n. ventralis lateralis of _Macaca mulatta_ subdivided into rostral and caudal parts. - The _rostral_ part contains very large, deeply staining, polyhedral cells arranged in clusters, while the _caudal_ part is less cellular and more myelinated. These subdivisions are better observed in monkeys, apes, and in man than in prosimians. The rostral part appears to be the main ventral lateral nucleus, while the caudal part may be a homologue of Krieg's and Heiner's n. ventralis ventralis, and of n. ventralis intermedius in this study.

Feremutsch (1963) gives special attention to the macaque monkey (_Macaca mulatta_) since he feels that, in this species, the lateral thalamic region has undergone a more marked evolutionary change than in any other primate. Moreover, he considers it the most misinterpreted region of the entire diencephalon, and he attempts to sort out terminological differences by comparing his classification of ventral nuclei with that of Walker's. This comparison and the corresponding terms used in my study, are set out as follows:

Table 16

Walker	Feremutsch	This study
N. ventralis lateralis	chief part of n. lateralis pars reticularis	n. ventralis anterior
N. ventralis lateralis	n. lateralis pars principalis	n. ventralis lateralis
-	n. lateralis pars ventralis	n. ventralis lateralis pars medialis
N. ventralis intermedius	not clearly homologized, but may be in the lateral region of n. lateralis pars ventroposterior	nn. ventrales medialis, intermedius and dorsomedialis
N. ventralis posterior	n. lateralis pars ventroposterior	nn. ventrales posterolateralis, medialis and inferioris

Feremutsch based this structural differentiation of the entire lateral thalamic mass on its cellular arrangement and fibre distribution. He stated that Walker did not describe a nucleus that corresponded to his n. lateralis pars ventralis; the latter nucleus is represented by n. ventralis lateralis pars medialis in this study, and in the work on the thalamus of the vervet monkey (Simmons 1965). Feremutsch's n. lateralis pars principalis may be homologized to Olswewski's n. ventralis lateralis pars medialis, thus, conforming with my description of the ventral lateral nucleus in primates.

Now it is clear that distinctions between the lateral and ventral thalamic nuclear groups have not been complicated by topographical or architectonic differences, but by terminological confusion. Therefore, nn. ventrales anterior and lateralis are separate and distinct entities with their own fibre projections to different cortical areas in the cerebral hemispheres, i.e., n. ventralis anterior to the premotor area and n. ventralis lateralis to the area lying anterior to the precentral cortex in the frontal lobe.

3. N. ventralis medialis (VM) (Plates 7 to 51)

(1) INSECTIVORA

Macroscelidoidea
Elephantulus myurus

N. ventralis medialis is not a discrete entity, but may be represented by a medial part of n. ventralis. This area of n. ventralis has smaller, less darkly staining and more stellate cells than those of the lateral part of the ventral nucleus. It is related medially to nn. centralis medialis and reuniens and dorsally to n. mediodorsalis. Caudad, it is replaced by the medial part of n. ventralis pars posterior.

(2) TUPAIOIDEA

N. ventralis medialis (Figs.45-48) cannot be easily delimited topographically from n. ventralis lateralis, as it appears more or less at the same level as the latter nucleus. However, the cytoarchitectonic and myeloarchitectonic characteristics of these ventral nucleus are slightly different. N. ventralis medialis is more cellularly dense and sparser in myelin content than nn. ventrales anterior and lateralis. It is a small and rather insignificant area lying slightly rostral to n. ventralis lateralis, and between the rostral pole of n. centralis medialis dorsolaterally and n. reuniens ventrolaterally. Caudad, n. ventralis medialis is better demarcated from n. ventralis lateralis by the fibres of the inferior thalamic peduncle. It may show even a well defined internuclear connection, *n. interventralis*, which has already been described in Chapter 7. The cells of n. ventralis medialis are medium-sized (16 x 11 μ), stain more lightly and are more round than pyramidal, and are arranged more loosely among the fibres than those of the medial part of n. ventralis lateralis. N. ventralis medialis is replaced caudally by the magnocellular part of n. ventralis posteromedialis.

(3) PROSIMII

Lemuroidea and Lorisoidea

N. ventralis medialis (Figs.62-89; 96-119) is present as an ill-defined small structure appearing at the same level as nn. ventrales anterior and lateralis. In *Microcebus murinus*, it is relatively larger in area and possesses more distinct cellular and fibrous characteristics. In this species, the cells of n. ventralis medialis are smaller, more oval-shaped and less deeply staining than those of other ventral nuclei, as well as those of other lemuroids.

In all lemuroids and lorisoids, the rostral part of n. ventralis medialis appears to be poorly differentiated from n. ventralis anterior. Caudad, the structural features of the former nucleus change, and it can be regarded as a separate entity. N. ventralis medialis lies slightly behind the extreme ventral and caudal regions of n. ventralis anterior from which it can be distinguished by its finer and more reticulated myelin content. Many coarse fibre bundles run in all directions throughout the nucleus. Farther caudally, n. ventralis medialis becomes less distinguishable, and merges with the magnocellular part of n. ventralis posteromedialis.

In the Galagidae, n. ventralis medialis appears to vary considerably among the species. In *Galago demidovii*, it is better delimited myeloarchitectonically from other ventral nuclei, while in *Galago senegalensis*, it is not demarcated clearly from n. ventralis anterior rostrally, but more definitely from n. ventralis lateralis laterally and caudally. In *Galago crassicaudatus*, n. ventralis medialis is much smaller and is not well delineated from n. ventral lateralis. In all these species, n. ventralis medialis has medium-sized cells (17 x 12 $/^{u}$) that are oval or polygonal, stain fairly well but not as deeply as those of n. ventralis lateralis.

(4) ANTHROPOIDEA

(i) Cercopithecoidea -

Cercopithecus aethiops

In higher primates, n. ventralis medialis (Figs. 119-120) may be either present as a vestigial structure or not at all. In Cercopithecus aethiops, this nucleus is only a pale structure containing scattered small, lightly staining cells and very sparsely distributed myelinated fibres that identify it distinctly from nn. submedius and medioventralis lying medial to it. Furthermore, n. ventralis medialis has become so narrow in its mediolateral extent that it may become n. interventralis itself. Its cells are medium-sized (18 x 12 $/^{u}$).

(ii) Hominoidea

Homo sapiens

(Figs. 129-130) Due to the great expansion of nn. ventrales lateralis and posterior, n. ventralis medialis is not identified in the human thalamus. At best, it may form the medial part of n. ventralis lateralis which is replaced caudally by n. ventralis posteromedialis.

Discussion on n. ventralis medialis

In all primates, n. ventralis medialis is poorly differentiated. It may be often mistaken by several workers as the medial part of either n. ventralis anterior or n. ventralis lateralis. In the stereotaxic atlas of the thalamus of Macaca mulatta, Olszewski (1953) outlined a fairly large cellular area between n. mediodorsalis medially, n. lateralis posterior dorsolaterally and n. ventralis posteromedialis ventrolaterally. He named this area "Nucleus X". Yet, on grounds of topographical and cytological features, this nucleus appears to homologize with n. ventralis medialis more clearly than with other parts of the ventrolateral thalamic group. It may correspond to n. ventralis ventralis of Walker (1937) and of Krieg (1948). Kanagasuntheram et al (1968) do not mention the presence of n. ventralis medialis in their prosimians. Bauchot's (1963) n. ventralis posterolateralis pars caudalis corresponds with n. ventralis posterolateralis of this study. Feremutsch (1963) does not discuss n. ventralis medialis in any of his primates, although he describes it as the pars ventralis of his n. lateralis ventroposterior only in higher primates.

In the tupaioid and prosimian specimens used in this study, it has been found that n. ventralis medialis is a better differentiated part of the ventral nucleus, and can be distinguished more clearly, on cytoarchitectonic grounds, from the medial part of n. ventralis anterior or of n. ventralis lateralis. Its presence is, furthermore, easily identified by its internuclear connection across the median plane. In higher primates, n. ventralis medialis is considerably reduced in size and extent, due to the lateralward expansion of n. ventralis lateralis which pushes n. ventralis anterior into the area occupied by the medial part of the ventral nucleus. In man, it is merely an appendage of n. ventralis lateralis rostrally and of n. ventralis posteromedialis caudally. Therefore, my observations confirm Feremutsch's opinion that n. ventralis medialis is merely a cellular extension of the ventral nucleus with a low evolutionary valency in the primates.

4. N. ventralis intermedius (VI) (Plates 12-51)

(1) TUPAIOIDEA

Since the ventral nucleus is a simple and poorly differentiated structure, it is not possible to find smaller nuclei or subdivisions of larger ventral nuclei, as in primates. Accordingly, n. ventralis intermedius is certainly not present in the Tupaioidea and Insectivora, as n. ventralis lateralis is abruptly replaced by n. ventralis posterior.

(2) PROSIMII

In *Microcebus murinus*, *Lepilemur* and *Galago demidovii*, n. ventralis intermedius (Figs. 55-90) is a small and very lightly myelinated area lying ventrolateral to n. ventralis lateralis and rostrodorsal to n. ventralis posterolateralis. It can be differentiated cytologically from these ventral nuclei; its cells are smaller, more lightly staining and are arranged more closely among fibre bundles than the lateral part of n. ventralis lateralis.

In larger prosimians, e.g., *Lemur catta*, *Galago crassicaudatus* and *Perodicticus potto*, n. ventralis intermedius appears to be further differentiated cyto- and myelo-architectonically from n. ventralis lateralis. It has increased considerably in size, and becomes a sort of transitional area between the anterior and posterior regions of the ventral nucleus. Generally, n. ventralis intermedius is monomorphous and slightly anisoformic.

(3) ANTHROPOIDEA

(a) Cercopithecoidea

Cercopithecus aethiops

N. ventralis intermedius (Figs.119-120) is more difficult to locate than in lower primates, as it lies in a transitional zone between nn. ventrales lateralis and posterior. N. ventralis intermedius is a very small, narrow segment lying ventral to n. ventralis lateralis and anterolateral to n. ventralis posterolateralis, from which it can be easily differentiated by larger and more darkly staining cells of the latter nucleus. N. ventralis intermedius extends from the level of the rostral pole of n. mediodorsalis to the rostral end of n. centrum medianum where it is replaced by the lateral part of n. ventralis posterolateralis

(b) Hominoidea

Homo sapiens

N. ventralis intermedius is either not present, or forms merely a ventral part of n. ventralis lateralis or of n. ventralis posterolateralis in which it appears as a more lightly myelinated area with fewer and more sparsely distributed large and dark-staining cells.

Discussion on n. ventralis intermedius

The descriptions and terminology of nn. ventrales intermedius and ventralis by Walker (1937, 1938), Krieg (1944, 1948) and others are confusing, since these nuclei appear to occupy the same "transitional area" between nn. ventrales lateralis and posterior. They are either parts of this transitional area or of n. ventralis lateralis as already mentioned. Their presence as separate entities in the primate thalamus has yet to be justified by more precise methods of spatial localization of their projections to the cerebral cortex. However, n. ventralis intermedius has been defined differently from ventralis ventralis because it can be seen as a small area lying between the lateral parts of nn. ventrales lateralis and posterolateralis. N. ventralis ventralis has been described by Toncray and Krieg (1946) in both monkey and man as a ventral continuation of n. ventralis anterior that lies immediately dorsal to n. ventralis postero-inferioris and ventral to n. submedius. However, my investigations fail to confirm that n. ventralis ventralis is a separate entity, or it is merely a caudal part of n. ventralis medialis before the latter nucleus continues into n. ventralis posteromedialis.

5. N. ventralis dorsomedialis (VDM) (Plate 44)

N. ventralis dorsomedialis (figs. 119-120) is another doubtful structure in tupaioid and prosimian specimens used in this study. It may not have evolved yet into a separate and identifiable subnucleus of the ventrolateral thalamic group as in higher primates. However, n. ventralis dorsomedialis appears to be best defined only in Tupaia species and Perodicticus potto. This nucleus has similar cellular characteristics to those in the macaque monkey (Krieg 1948), chimpanzee (Heiner 1960) and vervet monkey (Simmons 1965). In Tupaia glis and Lyonogale (a tupaioid), a conspicuous band of irregularly arranged, rather large, dark-staining, polygonal or stellate cells appears at the level of the lateral extremity of n. paracentralis, and lies dorsal to the dorsolateral region of n. ventralis posterolateralis. It could have been identified right away as n. centralis lateralis pars superior, because the cells of the latter nucleus are situated farther dorsally than are those of n. ventralis dorsomedialis, and they are slightly smaller and more deeply staining, thus facilitating identification of n. ventralis dorsomedialis.

In Perodicticus potto, n. ventralis dorsomedialis appears at the level of the caudal pole of n. ventralis lateralis as a well circumscribed area of rather large, well staining, round or stellate cells lying immediately ventral to n. lateralis intermedius, and lateral to the internal medullary lamina (Fig.90) N. ventralis dorsomedialis has a short caudal extent, and disappears at the level where n. ventralis lateralis is replaced by n. ventralis posterolateralis.

In Cercopithecus aethiops, the presence of n. ventralis dorsomedialis (Figs. 119-120) is confirmed more firmly by its distinguishing cellular features and characteristic relationships to the adjacent ventral nuclei. It lies probably in the vicinity of n. ventralis lateralis. There are such differences in cellular features between this area and n. ventralis dorsomedialis that recognition of the latter nucleus can be warranted as a separate entity in the ventrolateral thalamic group, even though its thalamocortical projection and fibre connections are not known. The cells of n. ventralis dorsomedialis are large (24 x 15 μ), stain very well, are pyramidal and are arranged compactly along the fibres of the mamillothalamic tract. These cells lie ventral to the anterior nuclei and to the rostral extremity of n. mediodorsalis, and dorsolateral to n. submedius.

In the human thalamus, n. ventralis dorsomedialis has not yet been identified or described, it may be represented by only a small and insignificant part of n. ventralis lateralis pars medialis.

Discussion on n. ventralis dorsomedialis

N. ventralis dorsomedialis has not been described or observed in primates by most investigators. It was once known as n. ventralis pars submedia by Papez and Aronson(1934). Krieg (1948) retained the present term n. ventralis dorsomedialis to avoid confusion between it and n. submedius. Gurdjian (1927) saw it in the rat, but it is difficult to ascertain whether he was referring to a nucleus in the medial part of n. ventralis anterior, or to one caudal to it. Hess (1955) described n. ventralis dorsomedialis in the guinea pig.

I have already described n. ventralis dorsomedialis in the vervet monkey as a group of large, darkly staining cells lying on the ventromedial border of n. anteromedialis, being separated from it by the internal medullary lamina. It is not distinguishable topographically from n. submedius which lies ventromedial and slightly caudal to it, but cellular differences in these nuclei are sufficient to establish their separate identities. Since n. centralis lateralis pars superior lies just dorsally and immediately caudal to n. ventralis dorsomedialis, the cellular features of these two nuclei may appear almost identical, but the cells of the former nucleus are slightly smaller and arranged more compactly to form a continuity with the cells of n. paracentralis.

N. ventralis dorsomedialis cannot be regarded as any part of n. mediodorsalis pars magnocellularis, even though these structures have a similar cytoarchitectonic pattern, because n. centralis lateralis lies between these two nuclei. Since the magnocellular part of n. mediodorsalis is situated farther caudally than n. ventralis dorsomedialis, the cells lying rostrally in the same vicinity may be the rostral pole of n. mediodorsalis. On the other hand, the cells of n. ventralis lateralis pars medialis are smaller, less darkly staining and more scattered than those of n. ventralis dorsomedialis. It can be inferred from my observations that n. ventralis dorsomedialis may be present in the primate thalamus as a discrete nucleus with its own cyto- and myelo-architectonic characteristics. Because of its close proximity to n. mediodorsalis, there is a possibility of a short connection between these two nuclei. Since n. ventralis dorsomedialis is one of the elements of the ventrolateral thalamic group, it may receive some fibres from ascending sensory pathways, viz., the intralaminar nuclei receiving fibres from the palaeo-spinothalamic pathway (Schroeder and Jane 1971). If it were so, then n. ventralis dorsomedialis should be a centre for integrating somatosensory and somatovisceral sensations.

6. N. ventralis posterior (VP) (Plates 3 - 53)

(1) INSECTIVORA

Macroscelidoidea

Elephantulus myurus

N. ventralis posterior (Figs. 37-40) is a relatively simple and undifferentiated portion of the lateral part of the ventral nucleus. Cyto- and myelo- architectonic differences between a medial and a lateral portion of this nucleus can be detected. The lateral portion of n. ventralis posterior is heavily stippled with myelinated fibre bundles, and large, dark staining cells are scattered irregularly among these fibres. The medial portion is more cellular than fibrous; its cells are slightly smaller, more lightly staining and arranged rather closely together. The medial portion lies lateral and ventral to n. parafascicularis, along whose border it forms a thick crescentic mass. The lateral portion of n. ventralis posterior is the last of all ventral nuclei to disappear at the caudal end of the thalamus. It is replaced, not by the pulvinar which is not yet developed in this species, but by the mesencephalic tectum. Nevertheless, the subdivision of n. ventralis posterior into medial and lateral portions is to justify their being regarded as separate entities as in primates.

(2) TUPAIOIDEA

N. ventralis posterior (Figs. 49-52) is the largest and best differentiated of all ventrolateral thalamic nuclei. It is readily recognised cytologically and cytoarchitectonically by its large, darkly staining, multipolar cells that are arranged in regular rows along the fibres of the inferior thalamic peduncle. In the ventrolateral part of this nucleus, there is a dense collection of myelinated fibres which may be terminating fibres of the ascending sensory pathways.

N. ventralis posterior is divided, on grounds of both topographical and cytological differences, into distinct lateral, medial and inferior parts as follows:

(i) N. ventralis posterolateralis (VPL)

This is the largest and best defined of all three parts of the ventral posterior nucleus. It lies medial to nn. reticularis and peripeduncularis, ventral to the caudal region of n. ventralis lateralis and to n. ventralis intermedius, and lateral to n. ventralis posteromedialis and the centrum medianum/parafascicular complex. N. ventralis posterolateralis can be distinguished from n. ventralis posteromedialis by cytological and architectonic differences between these two nuclei. The cells of n. ventralis posterolateralis are larger (17 x 11 μ) and stain better than those of n. ventralis posteromedialis.

(ii) N. ventralis posteromedialis (VPM)

It can be subdivided into a magnocellular and a parvocellular portion. The *magnocellular portion* (VPMmg) lies along the concave ventral surface of n. centrum medianum and dorsolateral to n. ventralis posterolateralis. The *parvocellular portion* (VPMpv) lies ventral to the magnocellular portion and dorsal to the caudal hypothalamic area from which it is separated by the zona incerta and the fields of Forel. The magnocellular part of n. ventralis posteromedialis extends a little farther caudally than the parvocellular part, and terminates at the rostral level of n. ventralis posterolateralis. The cells of the magnocellular portion are larger (15 x 11 μ), stain more deeply and are more polygonal than those of the parvocellular portion. The latter portion is more densely myelinated due to thick fibre bundles penetrating it from the medial lemniscus.

(iii) N. ventralis posteroinferioris (VPI)

This is a very small and barely discernible structure lying ventral and caudal to n. ventralis posterolateralis. It has a very short rostrocaudal extent, and is replaced by n. suprageniculatus or n. geniculatus medialis at the level of the posterior commissure. The cells of n. ventralis posteroinferioris are 15 x 11 μ, stain moderately well and are fusiform in shape.

(3) PROSIMII

(a) Lemuroidea

N. ventralis posterior (Figs.57-82) is a crescent-shaped mass in the ventrolateral region of the second half of the thalamus, along the medial border of n. reticularis. It lies ventrolateral to n. ventralis lateralis and ventral to n. ventralis intermedius. Its three subdivisions are defined even more clearly than in the Tupaioidea.

(i) N. ventralis posterolateralis (VPL)

This is the largest of all the three ventral posterior subnuclei, but it has not yet the great size it attains in higher primates. It is very well reticulated with thick myelinated fibre bundles that radiate through it from the terminating medial lemniscus. Its cells are much larger than those of the Tupaioidea (23 x 16 μ). These cells stain very well and are mostly pyramidal; the Nissl granules stand out conspicuously in the cytoplasm, and processes can be seen radiating from the nerve cell body.

N. ventralis posterolateralis is bounded dorsorostrally by n. lateralis intermedius, and dorsocaudally by n. lateralis posterior, medially by n. ventralis lateralis in front and by nn. ventrales intermedius, paracentralis and centralis lateralis behind and laterally by n. reticularis and the external medullary lamina. The ventromedial pole of n. ventralis posterolateralis is related laterally to the magnocellular portion of n. ventralis posteromedialis and ventrally to n. ventralis posteroinferioris. Where n. geniculatus lateralis increases in all dimensions and in the degree of lamination, n. ventralis posterolateralis reduces in size. However, n. ventralis posterolateralis retains its distinguishing features towards its termination, and is replaced by nn. pulvinaris inferior and geniculatus medialis.

(ii) N. ventralis posteromedialis (VPM)

This smaller and more compact nucleus is subdivided into a smaller, parvocellular and a larger, magnocellular part. The magnocellular part contains cells (18 x 12 μ) that stain rather deeply, are polyhedral and are distributed along the ventral border of n. centrum medianum. The parvocellular part contains small to medium sized cells (14 x 14 μ) that are more lightly staining and oval, and are scattered loosely among myelinated fibres. The parvocellular part lies ventral to the magnocellular part of n. ventralis posteromedialis, medial to n. ventralis posterolateralis and lateral to the posterior part of n. reuniens.

N. ventralis posteromedialis has a convex medial surface for n. centrum medianum which lies immediately ventral to it, and a concave lateral surface which faces almost entirely towards n. ventralis posterolateralis. N. ventralis posteromedialis extends caudally for some distance before it disappears, at a more rostral level than n. ventralis posterolateralis, where the habenulopeduncular tract appears.

(iii) N. ventralis posteroinferioris (VPI)

This is still comparatively small in its rostrocaudal extent. It is a pale-staining, oval-shaped structure lying at the 'bottom' of the thalamus. It is related immediately to the medial and lateral parts of n. ventralis posterior, dorsal to the zona incerta and fields of Forel, and medial to the rostral region of n. geniculatus lateralis. The cells of n. ventralis posteroinferioris are medium-sized (15 x 11 μ); they stain better and are more fusiform than those of n. ventralis posteromedialis pars parvocellularis. N. ventralis posteroinferioris disappears rostral to the point where n. ventralis posterolateralis is replaced by the pulvinar and n. geniculatus medialis.

In *Microcebus murinus*, n. ventralis posterior has almost identical features as in large lemuroids, the only differences being the comparatively smaller size of n. ventralis posterolateralis and the better differentiation of n. ventralis posteromedialis into parvocellular and magnocellular parts. Generally, n. ventralis posterior of the Lemuroidea is very heteromorphous and anisoformic with a strong degree of dimorphism in its medial part (n. ventralis posteromedialis).

(b) Lorisoidea

Perodicticus potto and Galagidae

N. ventralis posterior (Figs. 89-96; 99-102; 111-114) in these lorisoids is not very different in topography or architectonics from that of Tupaioidea and Lemuroidea.

(i) N. ventralis posterolateralis (VPL)

This is very well developed but much smaller in size than that of higher primates. It is clearly differentiated into cellular and fibrous parts. In *Perodicticus potto* and *Galago crassicaudatus*, n. ventralis posterolateralis is much larger than in *Lemur catta*. It extends from the level of the caudal region of n. lateralis dorsalis rostrally to the level of the caudal end of n. parafascicularis caudally where it is replaced by n. pulvinaris inferior. In all galagids, several large, darkly staining cells (20-25 $/^{u}$) are mingled with predominantly medium-sized cells (17 x 13 $/^{u}$) that stain much less intensely and are less polyhedral. The presence of unusually large cells in n. ventralis posterolateralis indicates that the ratio of large cells to small cells increases as one ascends the primate scale.

(ii) *N. ventralis posteromedialis* (VPM)

This nucleus commences at the caudal level of n. ventralis medialis. It is smaller in *Perodicticus potto* and *Galago crassicaudatus* than in *Lemur catta*. It is clearly divided into parvo- and magno-cellular portions with similar cytological features as in other prosimians. In most of its rostral extent, n. ventralis posteromedialis is related dorsally to nn. mediodorsalis and paracentralis. In its caudal region, n. ventralis posteromedialis is related more ventromedially to n. centrum medianum than to n. parafascicularis. At the level of the habenulopeduncular tract, n. ventralis posteromedialis reduces in size, and merges gradually into n. ventralis posterolateralis.

(iii) *N. ventralis posteroinferioris* (VPI)

This nucleus differs in no way from that of the Tupaioidea and Lemuroidea.

(4) ANTHROPOIDEA

(a) *Cercopithecoidea*

Cercopithecus aethiops

N. ventralis posterior (Figs.121-124) commences at about the level of the rostral end of n. centrum medianum and extends caudalwards to the pulvinar. As usual, it is divided into lateral, medial and inferior parts.

(i) N. ventralis posterolateralis (VPL)

This very well defined nucleus is one of the largest nuclei, not only in the thalamus, but in the whole diencephalon. Its boundaries are easily defined. N. ventralis posterolateralis lies caudal to n. ventralis intermedius which it may include without definite delimitation, and rostral to n. pulvinaris superior pars lateralis. Medial to n. ventralis posterolateralis are nn. ventralis posteromedialis, centrum medianum and parafascicularis. The internal medullary lamina and its nuclei lie dorsomedial to n. ventralis posterolateralis, while the ventrolateral relations of the latter nucleus are nn. reticularis, zonae incertae and ventralis posteroinferioris. The cells of n. ventralis posterolateralis are much larger than those of the corresponding nucleus in prosimians, being 27 x 18 μ on the average; the largest ones often reach the enormous size of 60 μ. These cells stain less darkly than those of n. ventralis lateralis, and are typically multipolar. The cellular distribution is sparse in the rostral part and denser in the caudal part where the cells are arranged compactly among thick fibre fascicles. The myelin pattern shows two sets of fibre bundles, interweaving transverse and horizontal fascicles. N. ventralis posterolateralis appears to have differing myeloarchitectonics in its lateral and medial parts; the lateral part is more densely populated with myelinated fibres than the medial part.

(ii) N. ventralis posteromedialis VPM)

This nucleus has almost the same rostrocaudal extent as n. ventralis posterolateralis, though it ends slightly rostral to the latter. N. ventralis posteromedialis lies on the lateral and ventral borders of n. centrum medianum, medial to n. ventralis posterolateralis and dorsal to n. ventralis posteroinferioris. Caudal to n. ventralis posteromedialis is the pulvinar which replaces this nucleus at the level of the rostral region of the habenula. N. ventralis posteromedialis is divided into medial parvocellular and lateral magnocellular parts whose cytoarchitectonic differences are more accentuated than in lower primates.

The cells of the magnocellular part of n. ventralis posteromedialis are large (24 x 15 $/^{u}$), stain rather darkly and are multipolar. The myelin content is richer with fibre bundles coursing through the area. The parvocellular part lies immediately ventral to n. centrum medianum; its cells are smaller and stain much less intensely than those of the magnocellular part; they are arranged more loosely among the fibres, which are distributed mostly in finer strands. Therefore, the parvocellular part stands out more clearly than the magnocellular part in myelin-stained sections.

(iii) N. ventralis posteroinferioris (VPI)

This lies ventral to n. ventralis posterolateralis. Its cells are very large (24 x 12 $/^{u}$), though not as big as those of n. ventralis posterolateralis. These cells stain fairly well and are scattered loosely among fine bundles of myelinated fibres, thus giving the nucleus a macroscopically pale appearance. N. ventralis posteroinferioris is replaced posteriorly by n. pulvinaris lateralis.

(b) Hominoidea

Homo sapiens

Next to the pulvinar and n. mediodorsalis, n. ventralis posterior (Figs.131-138) is the largest nucleus not only of the thalamus, but also of the whole diencephalon. Its cells are of enormous size, even bigger than those in other primates. N. ventralis posterior is divided into lateral, medial and inferior parts, although the latter part has not been well described by investigators of the primate thalamus.

(i) N. ventralis posterolateralis (VPL)

It has a heavily stippled myelinated appearance because fibres of the medial lemniscus and spinothalamic tracts terminate mainly in this nucleus. The topographical relations of n. ventralis posterolateralis do not differ much from those in prosimian and simian specimens, except that it has a longer posterior extent than nn. ventrales posteromedialis and posteroinferioris. N. ventralis posterolateralis terminates at the level of the middle region of n. geniculatus medialis where it is taken over by n. pulvinaris inferior. The cells of n. ventralis posterolateralis are mostly around 30 μ in diameter, sometimes reaching even 60 μ in size; they stain so deeply that they can be seen clearly macroscopically.

(ii) N. ventralis posteromedialis (VPM)

This nucleus is divided more distinctly than in simians into a *large* parvocellular and a *small* magnocellular parts. The parvocellular part is located lateral and ventral to n. centrum medianum, while the magnocellular part appears to be limited more medially and dorsally to the tectal regions of the midbrain. The cells of the parvocellular part are mostly medium-sized, lightly staining and oval shaped, and are arranged in rather regular rows along the ventral border of n. centrum medianum. The magnocellular part contains fewer and larger cells that are more or less equal in size to the cells of n. ventralis posterolateralis; they stain very darkly and are distributed rather uniformly throughout the nucleus.

(iii) N. ventralis posteroinferioris (VPI)

This is better developed, and more clearly delimited from the other parts of the ventral posterior nucleus. However, it remains relatively small in cross sectional area in the human thalamus. In the nucleus, terminate fibres partly of the medial lemniscus and partly of the trigeminal lemniscus. Therefore, it has a denser fibrous appearance than that of n. ventralis posteromedialis pars parvocellularis. Its cells are rather large and well staining, and are distributed uniformly among radiating fibres. Caudad, n. ventralis posteroinferioris is pushed into n. ventralis posterolateralis by the expanding pulvinar and the medial geniculate body.

Generally, the ventral posterior nucleus of the human thalamus exhibits a strong degree of heteromorphism and anisoformity.

Discussion on n. ventralis posterior

The morphology of n. ventralis posterior in the *Tupaia* species studied by me does not differ much from that of *Tupaia minor* (Le Gros Clark 1929). However, Le Gros Clark does not mention the presence, in *Tupaia minor*, of n. ventralis posteroinferioris, which in my tupaioid species, *Tupaia glis*, is clearly recognizable as a pale-staining area between n. ventralis posterolateralis and the zona incerta. This nucleus has been recognized by Shantha and Tigges (1969) in *Tupaia glis*.

In *Tarsius*, Le Gros Clark (1930) traced the medial lemniscus to its termination in the ventrocaudal aspect of the ventral nucleus. The terminal fibres of the medial lemniscus appeared to 'lobulate' the ventral nucleus into several distinct compartments by forming conspicuous fibrous capsules around them. Two of the 'lobules' in the *caudal* region of the ventral nucleus are doubtless the lateral and medial parts of n. ventralis posterior, while the other 'lobules' at rostral levels are assumed to represent nn. ventrales anterior, lateralis and medialis. N. ventralis posterolateralis of *Tarsius* is much larger though less sharply circumscribed than that of *Tupaia*. N. ventralis posteromedialis of *Tarsius* is well demarcated into medial and lateral portions, but Le Gros Clark did not describe their cellular differences. In the tree-shrews, n. ventralis posteromedialis has been noted to have two cytologically distinct parts, a magnocellular and a parvocellular part, which become more accentuated in prosimians and anthropoids. Le Gros Clark did not mention this cytological distinction in n. ventralis posteromedialis of *Tupaia minor*, even not distinguishing it cytoarchitectonically from n. ventralis posterolateralis. The cellular differentiation in n. ventralis posteromedialis may signify an evolutionary advance, beginning in the tree-shrews and reaching its peak of development in man.

Pines's (1927) nuclei 'vb' and 'vb_1' in *Lemur catta* correspond well to the medial and lateral divisions of the ventral posterior nucleus in my *Lemur catta* specimens; his nucleus 'vb_2' may represent n. ventralis posteroinferioris in this species.

Bauchot's (1963) n. ventralis caudalis in *Tupaia glis* and *Galago demidovii* is homologous to n. ventralis posterior in the same species here; it is also divided clearly into lateral and medial parts. The medial part is further subdivided into parvocellular and magnocellular portions which are clearly defined in these species, as well as in other primates used in this study. However, Bauchot mentions that a second parvocellular portion of n. ventralis posteromedialis may be observed in prosimians. My investigations have failed to reveal the presence of this structure and it is likely to be n. ventralis intermedius or a caudal part of n. ventralis medialis.

Feremutsch (1963) does not divide the ventral nucleus into any parts. In all his primate species, n. lateralis ventroposterior (LVP) appears to consist of only ventrolateral and ventromedial parts of the caudal part of the nucleus lateralis.

N. lateralis pars ventroposterior can be distinguished topographically from n. lateralis pars dorsalis intermedia (LDI), and ventromedially, it forms the lateral boundary of n. centrum medianum. N. lateralis pars ventroposterior has a narrow tongue-like extension that lies beneath n. centrum medianum, and extends towards the midline thalamic region. This nucleus may be a homologue of n. ventralis medialis and its internuclear commissure. From the level of the lateral geniculate body caudad, n. lateralis pars ventroposterior merges with the basal or ventral region of the pulvinar and the dorsal region of the medial geniculate body. Therefore, it is apparent that Feremutsch's n. lateralis pars ventroposterior forms a very large part of n. ventralis posterolateralis, while n. ventralis posteromedialis forms a medial part of his pars ventroposterior. Feremutsch states that n. lateralis pars ventroposterior (n. ventralis posterior) is characteristically dimorphic, since it is divided into two distinct and irregular cellular regions which correspond almost identically with the lateral and medial divisions of n. ventralis posterior in this study. However, Feremutsch classifies two types of cells in these parts, 'magnocellular' and 'parvocellular', which are better observed in n. ventralis posteromedialis in this study. These cells lend a very anisoformic character to n. ventralis posterolateralis in which a variety of cells is found in this nucleus. Thus, even though Feremutsch denies the concept of cellular differentiation or topographical division in the thalamus, he admits that the ventral nuclear mass is composed of various heteromorphic areas divisible within themselves into cellular parts, for example, nn. ventrales anterior, lateralis and posterior.

The evidence of the division of n. ventralis posteromedialis into magno- and parvocellular parts has been given in the investigations on the thalamic tactile region in the cat and rabbit by Rose and Mountcastle (1952). It is significant that this nucleus remains relatively constant throughout the mammalian scale, whereas the lateral parts of the ventral nuclei have developed concomitantly with locomotor dexterity of the upper extremities, particularly in primates. The facial mechanism, which n. ventralis posteromedialis also subserves, is fairly constant in complexity throughout the primate scale, but it becomes somewhat more intricate in man, in which n. ventralis posteromedialis shows a much higher degree of cellular differentiation.

N. ventrocaudalis of Simma (1957) and Hassler (1959) is homologous to the <u>caudal</u> region of n. ventralis posterolateralis, in which fibres of the medial lemniscus and spinothalamic tracts terminate, but this nucleus has not been recognized by some workers as a separate nucleus. N. ventrocaudalis is more intimately related to Wernicke's area than is n. ventralis posterolateralis; therefore, it has been termed <u>n. ventralis posterocaudalis</u> (VPC) in all primates used in this study. However, its cytological differences from those of nn. ventrales posterolateralis and posteroinferioris are not big enough to justify regarding it as a separate entity. On the other hand, its myelin content is very rich, due to dense fibre fascicles traversing it from Wernicke's field and from the terminus of ascending sensory fibre systems. N. ventralis posterocaudalis in my prosimian and simian species is a very darkly staining area lying <u>caudal</u> and <u>ventral</u> to n. ventralis posterolateralis, <u>dorsal</u> to n. pulvinaris inferior and the medial geniculate body, and lateral to the prerubral field of the mesencephalon. The cells of n. ventralis posterocaudalis are very large and deeply staining like those of n. ventralis posterolateralis, and they are scattered loosely among the radiating myelinated fibres. N. ventralis posterocaudalis disappears at the caudal level of n. geniculatus medialis, and is replaced by the mesencephalic tegmentum.

SUMMARY OF THE VENTROLATERAL THALAMIC NUCLEAR GROUP

The phylogeny of the ventrolateral thalamic region in primates is the most progressive and highly elaborate of all the diencephalic regions; for its development is intimately linked with the rapid expansion of sensory and motor areas in the cerebral hemispheres. In non-primate mammals, the ventrolateral nuclear group is only a simple and undifferentiated area lying between the lateral thalamic nucleus dorsally and the hypothalamus ventrally, and between the medial thalamic mass medially and the external medullary lamina laterally. In these forms, the ventral nucleus is better delimited myeloarchitectonically than cytoarchitectonically from the dorsal nucleus, due to the dense collection of myelinated fibres coursing through it from the medial lemniscus. In the Tupaioidea, the ventral nucleus goes a further step in cytoarchitectonic differentiation, in which anterior, lateral, medial and posterior parts can be recognized. The posterior part of the tupaioid ventral nucleus is further subdivided on grounds of both cyto- and myelo-architectonic differences into medial, lateral and inferior parts.

Nn. ventrales anterior and lateralis are larger and better developed in the Tupaioidea than in the Insectivora, as well as being clearly distinguishable cyto- and myelo-architectonically from each other. Each nucleus is subdivided into medial and lateral portions based on cellular distribution and myelin content. There is a transitional zone between the anterior and posterior parts of the ventral nucleus, n. ventralis intermedius, which is relatively better developed than n. lateralis intermedius.

As one ascends the prosimian scale, the divisions of the ventral nucleus become further differentiated, to such a degree that each division has its own morphological features which reflect the increasing importance of its functional capabilities. Smaller units or subnuclei, such as nn. ventrales dorsomedialis, ventralis and intermedius, are formed as a result of territorial sequestration among the larger nuclei, but the physiological aspect of these subdivisions is dubious. In Prosimians, the medial part of n. ventralis posterior is subdivided into two distinct cellular areas, magnocellular and parvocellular which are accentuated as one ascends the primate scale.

This study has revealed that the ventrolateral thalamic nuclei of the Lemuroidea show a remarkable higher degree of phylogeny than that of the Lorisoidea, that is, the condition of structural development is closer to that in the monkey, than to that in the potto. All the ventrolateral nuclei can be homologized directly with those of the anthropoids. N. ventralis lateralis is sufficiently large to be subdivided cytoarchitectonically into lateral and medial parts, although these parts are comparatively smaller than in the monkey. N. ventralis medialis appears to be smaller than in the lorisoids. However, in *Microcebus murinus*, a lemuroid, the architectonic features are somewhat intermediate between the lemurs and galagos, and more similar to those of Tupaia glis than of *Galago demidovii*.

In monkeys and apes, nn. ventrales anterior and lateralis expand further in cross sectional area, and are even better differentiated cytoarchitectonically from each other. N. ventralis posterior is much larger and more decidedly elaborated into three separate subnuclei, each subserving the different parts of the body, i.e., n. ventralis posterolateralis for the lower parts of the trunk and lower extremities, n. ventralis posteromedialis for the upper parts of the trunk, upper extremities and face; and n. ventralis posteroinferioris for the more intricate musculature of the face and neck.

In man, the ventrolateral thalamic group seems to have reached its peak of development, and every one of its elements, even the smaller nuclei, is well represented. *N. ventralis anterior* is enormous, almost equal in cross sectional area to nn. ventrales lateralis and posterior, and extends far rostrad where it is intimately related to the basal ganglia and subthalamus. *N. ventralis lateralis* is further differentiated into medial and lateral regions structurally and cytologically than in monkey and ape, due to increased fibre connections with neocerebellar and neomesencephalic areas. *N. ventralis medialis* has regressed to such an extent that it is merely a continuation of n. ventralis lateralis rostrally or of n. ventralis posteromedialis caudally. *N. ventralis posterolateralis* has surpassed almost every thalamic element in size and morphological development. It is a complex structure with a clear-cut functional localization for various modalities pouring into it from all parts of the body. It extends so much farther caudally that a distinct region appears to be detached from the main nucleus, *n. ventralis posterocaudalis*. This newly formed nucleus serves as a bed terminus for the great ascending sensory pathways. *N. ventralis posteromedialis* seems to be almost segregated into two complete areas, parvocellular and magnocellular. *N. ventralis posteroinferioris* is much larger and better developed in man than in anthropoid apes; this is related to a more highly developed facial musculature in man.

Structural features, cyto- and myelo-architectonic properties and evolutionary trends of the ventrolateral nuclear group are summarized in Table 17:-

TABLE 17 COMPARISONS OF THE VENTROLATERAL THALAMIC NUCLEI

	N. ventralis anterior (VA)	N. ventralis lateralis (VL)	N. ventralis medialis (VM)	N. ventralis postero-lateralis (VPL)	N. ventralis postero-medialis (VPM)	N. ventralis postero-inferioris (VPI)
STRUCTURAL FEATURES	Better developed structurally and differentiated topographically from VP in Tupaia than in Elephantulus. Is well demarcated from AV and LI & IP lying dorsal to it. VA of Lemur is larger and better definable topographically and architectonically than that of Galago and Perodicticus. In higher primates, VA is much increased in size and further developed in all respects. It is a very large and distinctive structure lying in the most rostral region of the thalamus. Caudally, it shifts to a more medial position and merges with VL. In man, VA is well encapsulated by fibres except at its caudal end where it continues into VL.	In Elephantulus, VL is merely a lateral extension of VA. In Tupaia, VL is a more distinctly formed structure lying between VA and VP. VL can be distinguished myeloarchitectonically from both VA and VP. VL continues caudally as ? VL into VP. In Prosimii, VL is further developed structurally and cytologically, though better in Lemur than in Galago and Perodicticus. VL is divisible into medial and lateral parts which are accentuated in higher primates. In Anthropoidea, VL increases in size and cellular differentiation. Its topographical relations change as a result of this morphological development throughout the primates.	VM is apparently well defined as a separate entity from VA and VL in Elephantulus, Tupaia and some lower prosimians. In higher prosimians, e.g., Galago and Perodicticus, VM is of such smaller size and indistinct character that it may be merely a medial extension of VL, though retaining its own cellular characteristics. In monkeys and apes, VM further reduces in size, and is related more to the medial than to the ventral thalamic group. VM is not present in man, or else, it may be a medial extension of both VA and VL, as indicated by the presence of its internuclear connection, n. interventralis (IV).	VPL forms an undifferentiated lateral part of VP in Elephantulus. In Tupaia, VPL is relatively smaller than VA and VL; VP shows a distinct "lobulation" into several compartments, indicating the beginnings of functional localization of sensory modalities within the nucleus. There is a progressive increase in size and structural differentiation as one goes from smaller to larger prosimians and simians. In Galago, VPL is the 2nd largest nucleus in the whole diencephalon. Throughout the anthropoid scale up to man, it is much further elaborated into a complex structure with various functions.	In Elephantulus VPM forms an undifferentiated medial part of VP. VPM has a similar phylogenetic course as VPL throughout the primate scale. It is better demarcated from VPL myeloarchitectonically in Tupaia, but not as clearly divisible into parvo- and magnocellular parts as in Prosimii. However, in Tupaia and Prosimii, VPM is more dorsally and caudally situated in relation to VPL than in Anthropoidea, due to CEM occupying a dorsomedial position in the thalamus, and to the overall small size of the lateral thalamic region in prosimian species. In man, VPM is much larger and more highly developed with a longer caudal extension.	VPI is not identifiable in Elephantulus. It is present first in Tupaia, but it is hardly demarcated topographically from VPL and VPM. It becomes larger and more distinct only in higher primates. In man, VPI becomes as large as VPM, as more intricate facial mechanisms decrease VPI lies at the "bottom" of the thalamus in all prosimian and anthropoid species, just dorsal to the subthalamic and dorsal hypothalamic regions.
CELLULAR CHARACTERS (CYTOARCHITECTONICS)	Cells of VA show a significant increase in all dimensions from Tupaia to Cercopithecus and man. In Tupaia, size is 15 x 10 /u (med. sized) to 27 x 15 /u (large) in Cercopithecus. Cells are generally well staining, polygonal or multipolar with rather distinct Nissl granules. The c cells are more regularly arranged in the medial than in the lateral part of VA. Monomorphous and anisoformic.	Cells of VL show considerable changes in size. In Tupaia, they are 15 x 11 /u (med. sized), and 21 x 13 /u (large) in Cercopithecus. Cells stain moderately well but less darkly than those of VA and VP; are mostly polygonal or oval. Cells are more regularly distributed in the medial than in the lateral part of VL. Monomorphous and anisoformic.	Cells of VM are much smaller and more uniformly distributed than those of VA and VL; fewer myelinated fibres run through VM. Cells of VM are generally med. sized in all primates (16 x 11 /u to 17 x 11 /u); they stain less darkly than those of VA and VL, and are mostly round. Cells are arranged loosely and lie along the fibres. Monomorphous and isoformic.	Conspicuous increases in both cellular size and change of neuronal features. Cells are 17 x 11 /u in Tupaia and 27 x 18 /u in Cercopithecus, but often reach the enormous size of 50-60 /u in higher primates and man. Has all classical features of a multipolar neurone in CNS. Large, coarse Nissl granules and clearly formed processes. Cells are scattered among fibres, but are arranged in neat, regular rows. Tends to be heteromorphous, since there is considerable mixture of small and large cells in VPL.	Divided into a small parvo- and a larger magnocellular part. Cells are mostly in the large neurone range, 15 x 9 /u in Tupaia to 30 x 18 /u in Cercopithecus. Cells in the parvocellular part are smaller, more lightly staining, more oval than polygonal, and more loosely arranged than the cells of the magnocellular part. Heteromorphic and anisoformic; may be dimorphic in man.	Cells of VPI are similar in all respects to those of VPM. 15 x 11 /u in Tupaia, Lemur and Galago; 34 x 17 /u in Cercopithecus. Monomorphous and slightly anisoformic.

TABLE 17 (contd.) COMPARISONS OF THE VENTROLATERAL THALAMIC NUCLEI

	N. ventralis anterior (VA)	N. ventralis lateralis (VL)	N. ventralis medialis (VM)	N. ventralis postero-lateralis (VPL)	N. ventralis postero-medialis (VPM)	N. ventralis postero-inferioris (VPI)
MYELIN CONTENT (MYELOARCHITECTONICS)	VA is the most densely myelinated area of all the ventrolateral nuclei in all primate species. Has a well-marked "reticulated" appearance, but not as accentuated as RET, from which it is distinguished by its clearer appearance. Horizontal and transverse fibre bundles run throughout VA. When VA increases in size in anthropoids, it becomes more intensely myelinated; stippled in its lateral part and mottled in its medial part. Contains fibre systems from basal ganglia and subthalamus.	VL is less densely myelinated than VA and VP. Generally streaky in appearance; more stripes in its lateral than in its medial part. Fibres are distributed less compactly than in VP. In the caudal region of VL, there is a more lightly myelinated area, which is attributed to VI; this nucleus acts as a transitional zone between VA, VL and VPL. VL receives fibres through rubrocerebellar systems, and projects to frontal lobe in the cerebrum.	Much less myelinated than VA and VL. Finer strands of myelinated fibres are arranged irregularly in VM. Fibres of the mamillothalamic and inferior thalamic peduncle course through it. Macroscopically, appears as a pale myelinated area.	Very rich in myelin content. Not as densely myelinated as VA. VPL contains more fibre bundles in its lateral and ventral than in its medial and dorsal parts. Gives a very streaky or stippled appearance. Contains fibres from great ascending sensory fibre pathways.	Less myelinated than VPL. Fewer fibres in magnocellular than in parvocellular part. Fibres are generally arranged in neat, regular bundles, especially in the ventral region of VPM. In the dorsal region of VPM, fibres are more diffusely arranged. Contains fibres of medial and trigeminal lemnisci, as well as of other sensory fibre pathways.	Least myelinated of all ventrolateral thalamic nuclei. Has a characteristically pale appearance in myelin-stained sections. Smaller bundles of fibres radiate into it from VPL and the external medullary lamina. May contain fibres bearing somatosensory modalities for the face from the trigeminal and gustatory pathways.
EVOLUTIONARY TRENDS	Very progressive phylogenetically. Is only a small rostral region in the ventral nucleus in non-primate mammals. Increases in structure and differentiation in lower primates. VA is a relatively large and extremely richly myelinated structure in higher primates. Is not as large as VL in all primates. Cellular differentiation is more evident as one ascends the primate scale to man.	VL has a very rapid phylogenetic development throughout the primate scale, but is not as highly elaborated as VP. It is well differentiated into medial and lateral parts on both cyto- and myeloarchitectonic grounds. Is, at first, an appendage of the anterior part of the ventral nucleus, and expands in size and differentiation until it becomes a very well defined nucleus in man.	VM is more regressive than stable or progressive in its phylogeny. Is well defined only in lower primates. Its functions are not known, it is at best, an integral part of VA or VP.	VPL has the most remarkable phylogenetic history, next only to the lateral geniculate body and the pulvinar. As one ascends the primate scale from Tupaia to Homo, VPL develops from a comparatively small and undifferentiated region of the ventral nucleus to a very highly elaborated supernucleus subserving various sensory modalities.	Very highly progressive in phylogeny, and very advanced in both structural and cytological differentiation. In man, VPM may be further subdivided into two almost complete sub-nuclei, each subserving different sensory modalities from the upper parts of the body and face.	Late phylogenetic development, which may begin in the Tupaioidea and Lemuroidea. Perhaps it has not yet reached its peak of development and complete delimitation from VPL and VPM in man and anthropoid apes.

CHAPTER 10

THE THALAMUS: POSTERIOR NUCLEAR GROUP

The posterior thalamic nuclei consist mostly of phylogenetically older nuclei that are more prominent in the optic tectum and midbrain of reptiles, birds and lower mammals than in primates. In higher mammals, including primates, all these posterior thalamic nuclei, except n. reticularis, seem to have undergone regression to such an extent that they have become either structures of secondary importance or part of the transitional area between the thalamus and midbrain. N. reticularis does not really belong to the posterior thalamic nuclear group, as it is a subthalamic derivative, but, for the sake of convenience and also because of its topographical relationships with the thalamus, it is described with the posterior thalamic nuclei. Such nuclei are enumerated below:

1. N. pretectalis (PRET)
2. N. thalamicus posterior (TP)
3. N. suprageniculatus (SG)
4. N. limitans (NL)
5. N. tractus opticus (NOT)
6. N. commissuralis posterior (NPC)
7. N. olivaris superior (OS)
8. N. reticularis (RET)

1. N. pretectalis (PRET) (Plates 3 - 54)

(1) INSECTIVORA

Macroscelidoidea

Elephantulus myurus

In this species, n. pretectalis (Figs. 37-40) is the most conspicuous of all the posterior thalamic nuclei, as well as one of the largest diencephalic structures. N. pretectalis is related laterally to n. lateralis posterior, dorsolaterally to

n. tractus optici and dorsally to the superior colliculus which forms a sort of cap over n. pretectalis. N. pretectalis is intimately related to n. geniculatus lateralis which lies ventrolateral to it, and to the optic tract which contributes many fibres directly to n. pretectalis. The tectothalamic tract and medial lemniscus also send fibres to n. pretectalis. The cells of n. pretectalis are generally small, stain lightly, are round or polygonal and are arranged compactly in a thick network of fibres that give it a somewhat mottled appearance.

(2) TUPAIOIDEA

N. pretectalis (Figs.51-52) is much reduced in size, though it remains a particularly well developed structure. It is related dorsolaterally to n. thalamicus posterior, ventromedially to n. tractus optici , medially to the pulvinar, and ventrally to nn. geniculati lateralis and medialis. Throughout its extent, n. pretectalis thrusts from under cover of the superior colliculus between the dorsomedial extremity of nn. lateralis posterior and habenularis lateralis. In its caudal part, n. pretectalis can be differentiated cytoarchitectonically into a lateral and a medial part. The *lateral part* contains large cells (18 x 13 μ) that stain rather lightly, while the *medial part* consists of small, more lightly staining, and stellate cells (12 x 8 μ).

Myeloarchitectonically, n. pretectalis appears to be reticulated or heavily mottled with dense fibre bundles that are arranged in neat rows radiating dorsoventrally from the superior colliculus and optic tract.

(3) PROSIMII

In all Lemur specimens and *Perodicticus potto*, n. pretectalis (Figs. 59-84; 95-96) remains comparatively large, and is divided clearly into a lateral parvocellular and a medial mediocellular part. However, its relations are rather different topographically from those in the Tupaioidea. N. pretectalis lies medial to the medial part of n. pulvinaris superior, ventral to n. mediodorsalis, lateral to n. habenularis lateralis, dorsomedial to nn. limitans and suprageniculatus, dorsal to n. tractus opticus and dorsolateral to n. commissuralis posterior. The medial part of n. pretectalis is a rather poorly defined area containing medium-sized cells (13 x 9 μ) that stain more darkly and are more fusiform than those of the lateral part of n. pretectalis. The lateral part of n. pretectalis contains slightly larger cells (17 x 11 μ) that stain lightly and are oval in shape; these cells lie between nn. commissuralis posterior and tractus opticus. Caudad, at the level of the habenular and posterior commissures, n. pretectalis is shifted to a medial and ventral position where it replaces nn. mediodorsalis and centrum medianum, and becomes related directly dorsolaterally to n. commissuralis posterior and ventromedially to n. pulvinaris superior. At the level of the commencement of the mesencephalic central grey, n. pretectalis replaces n. pulvinaris superior, and is itself replaced farther caudally by the superior colliculus.

In the Galagidae, n. pretectalis undergoes further reduction in size, and is pushed to a more medial position by the expanding pulvinar. The cells of n. pretectalis are mostly small (11 x 8 μ), stain very lightly, are fusiform in shape, and are scattered among the terminating fibres of the optic tract. N. pretectalis can be divided into medial and lateral parts as in the Lemuridae. The lateral part is possibly homologous to n. thalamicus posterior of the Tupaioidea, and has small, lightly staining, oval cells that are arranged very closely to n. tractus opticus. The medial part is the larger of the two, and contains medium-sized, more darkly staining, round cells that form the principal part of n. pretectalis.

In all prosimians, n. pretectalis shows a notable change from monomorphous to heteromorphous character, due to two differing cytoarchitectonic areas in the nucleus. However, n. pretectalis maintains its anisoformity, since cells of variable sizes and shapes are seen mingling with one another throughout the nucleus. Myeloarchitectonically, n. pretectalis has a heavily mottled appearance, due to fibres traversing it from the optic tract to the region of the superior colliculus.

(4) ANTHROPOIDEA

(a) Cercopithecoidea

Cercopithecus aethiops

N. pretectalis (Figs.125-128) occurs as a crescentic cup of cells that lie dorsal to n. commissuralis posterior. N. pretectalis is not cytologically distinctive, but can be identified in the thalamus of higher primates. N. pretectalis extends from the rostral end of n. commissuralis posterior to the rostral end of the superior colliculus. The dorsal surface of n. pretectalis is related to the optic fibres traversing the medial surface of the pulvinar.

(b) Hominoidea

Homo sapiens

Immediately rostral to the superior colliculus in the region of the thalamo-mesencephalic junction, is n. pretectalis (Figs. 135-140) which is termed the pretectal area by Olszewski (1952) and Hassler (1959). It contains several indistinct groups of small and large cells, and receives fibres from the optic tract, n. geniculatus lateralis and the superior colliculus.

The discussion on n. pretectalis follows the description of n. thalamicus posterior, as the latter is essentially a part of the pretectal region.

2. N. thalamicus posterior (TP) (Plates 3 - 37)

(1) INSECTIVORA

Macroscelidoidea
Elephantulus myurus

In this species, n. thalamicus posterior (Figs. 37-40) is a relatively large and well developed structure. It lies caudolateral to n. pretectalis, lateral to n. commissuralis posterior and dorsal to n. ventralis posterior. Its cells are smaller, more lightly staining, rounder and packed more loosely in a diffuse myelinated area than are those of n. pretectalis.

(2) TUPAIOIDEA

N. thalamicus posterior (Figs. 51-52) is still present as a very primitive structure, and is easily confused with n. commissuralis posterior to which it is more closely related than to n. pretectalis. N. thalamicus posterior is a large and well myelinated area that replaces the centrum medianum/parafascicular complex caudally and extends to the level of the posterior commissure. It comprises a collection of mixed cells, most of which are medium-sized, well staining and polygonal, and are scattered loosely among myelinated fibres of the posterior thalamic radiations. N. thalamicus posterior is essentially a heteromorphous and anisformic structure with strong connections with the mesencephalic tegmentum, particularly the reticular formation.

(3) PROSIMII

In *Microcebus murinus*, *Lepilemur*, *Galago senegalensis* (Figs. 103-106), n. thalamicus posterior is reduced to an insignificant area that appears partly to form a ventral part of n. pretectalis and partly to be incorporated into n. limitans.

(4) ANTHROPOIDEA

In higher primates, n. thalamicus posterior is no longer present as a discrete entity. It may have been broken up and scattered among other posterior thalamic nuclei.

Discussion on nn. pretectalis and thalamicus posterior

With regard to the use of the terms 'n. pretectalis' and 'n. thalamicus posterior', there is some confusion. Authors like Le Gros Clark, Gurdjian, Rioch, Papez and Bodian, gave different names and descriptions to the area lying in the dorsomedial part of the transitional zone between the diencephalon and mesencephalon. Tsai (1925) named that area 'pretectal area' in the opossum. It was called n. thalamicus posterior in the rat (Gurdjian 1927), and in carnivores (Rioch 1929), while in the armadillo, Papez (1932) included n. pretectalis with n. commissuralis posterior. In *Tupaia minor*, Le Gros Clark had n. pretectalis divided into a dorsal large-celled and a ventral small-celled part which do not correspond to the lateral and medial divisions of n. pretectalis in my tupaioid species. Bauchot (1963) regards Le Gros Clark's n. pretectalis pars dorsalis as his n. lentiformis mesencephali, and n. pretectalis pars ventralis as the actual pretectal area. Le Gros Clark's n. thalamicus posterior corresponds with Bauchot's n. thalamicus posterior in prosimians. N. thalamicus posterior of those authors is not different topographically or cytologically from that in the tree-shrews studied here. Le Gros Clark included, in *Tarsius*, n. thalamicus posterior with n. pretectalis. Possibly, in this prosimian species, n. thalamicus posterior has regressed to such an extent that it has become incorporated into the pretectal area.

In *Tarsius*, Le Gros Clark describes *n. pretectalis* as a well defined structure that extends ventrally and slightly caudally from the dorsal surface of the thalamus to a point immediately caudal to the posterior limit of the ventrolateral thalamic nuclear group. This nucleus is not divided into cellular parts homologous with the lateral and medial parts of the same nucleus in the prosimians used in this study. It consists of cells of varying sizes and shapes that are rather densely packed together in rows parallel to the course of tectothalamic fibres. N. pretectalis of Tarsius is more richly myelinated than those in other primates. Le Gros Clark states that n. pretectalis in Tarsius is connected with its fellow by fibres crossing in the commissure of the superior colliculus. However, in my prosimian material, these fibres have been observed to cross in the posterior commissure, not the superior collicular commissure. The difference in this fibre crossing is possibly due to the fact that n. pretectalis receives fibres from the lateral geniculate body, and relays them to the superior colliculus, whereas its other fibres cross over to the opposite pretectal nucleus in the posterior commissure.

In the Lemuroidea, n. limitans separates n. pretectalis sharply from the nuclear masses which lie ventrolateral to it. If n. limitans is accepted as a boundary line between the thalamus and midbrain, then n. pretectalis cannot be regarded as a thalamic nucleus, but is a somewhat transitional zone between these two regions. Pines (1927) had n. pretectalis of Lemur catta divided into two parts, a dorsolateral large-celled and a ventromedial small-celled part, which correspond well with the same divisions of n. pretectalis in my lemuroid species.

Kanagasuntheram et al (1968) indicate in Galago senegalensis and Nycticebus coucang that n. pretectalis is a poorly defined structure that appears at the rostral level of the oculomotor nuclear complex. These authors observe that n. pretectalis replaces n. commissuralis posterior at this level, whereas in Galago senegalensis of this study, the latter nucleus is replaced by the commissure of the superior colliculus, while n. pretectalis is displaced to a more lateral and ventral position. Furthermore, Kanagasuntheram et al did not subdivide n. pretectalis into medial and lateral parts, and described only the presence of medium and large cells lying between n. suprageniculatus ventrolaterally and n. tractus opticus dorsolaterally. No mention has been made of n. thalamicus posterior, which, these authors presume, has been taken over by other posterior nuclei during phylogeny of the posterior thalamic region.

Crouch (1934) states that if n. pulvinaris inferior of primates is related to the metathalamus, then its homologue in lower mammals should be n. thalamicus posterior, not n. pretectalis. In *Macacus rhesus*, Papez and Aronson (1934) describes n. pretectalis as a small crescentic structure lying dorsal to nn. commissuralis posterior and thalamicus posterior. They stated that n. thalamicus posterior forms a lateral part of the bed nucleus of the posterior commissure. Therefore, in higher primates, there is no sharp delimitation among nn. pretectalis, commissuralis posterior and thalamicus posterior. N. thalamicus posterior has not been identified in *Cercopithecus aethiops* (Simmons 1965), as it has been absorbed into n. pretectalis or broken up into fragments that form parts of nn. limitans and commissuralis posterior. It can be inferred from my observations that n. thalamicus posterior has been taken over by other thalamic nuclei during phylogeny of the primate thalamus, and that n. pretectalis of primates is only a remnant of the pretectum which dominated the posterior thalamic region in lower mammals. Therefore, n. pulvinaris is comprised of posterior parts of the dorsolateral thalamic nuclei, and remnants of nn. pretectalis and thalamicus posterior. In lower primates, and particularly in the Tupaioidea, it is still uncertain whether the size and differentiation of n. pretectalis are associated with the differentiation of telencephalic visual centres, or with the enormous size and elaborated stratification of the superior colliculus, or with the simple structure of the lateral geniculate body. In primates, n. pretectalis becomes reduced in size and its functional importance in relaying visual impulses to the cerebral cortex is replaced almost entirely by the lateral geniculate nucleus. It retains its close connection with the superior colliculus, the pretecto-superior collicular projection as observed in the monkey by Carpenter and Pierson (1973).

3. *N. suprageniculatus (SG)* (Plates 14-54)

In *Elephantulus* and the *Tupaioidea*, *n. suprageniculatus* is a rather well defined structure that lies dorsal to the medial part of n. geniculatus medialis from which it can be distinguished by its larger, more deeply staining, polyhedral cells (18 x 11 μ).

In *Prosimii*, *n. suprageniculatus* (Figs.59-116) is better developed than that of the Tupaioidea. It appears at the caudal level of the centrum medianum/parafascicular complex as a rather well defined structure lying dorsomedial to the geniculate bodies and medial to n. pulvinaris inferior. N. suprageniculatus is related dorsolaterally to nn. pretectalis, commissuralis posterior and tractus opticus, and is connected to these nuclei by n. limitans. It is a dome-shaped structure, the apex of which is directed dorsomedially towards the pretectal region, and the base of which lies on n. geniculatus medialis. N. suprageniculatus consists of large cells (19 x 13 μ in *Lemur*, and 22 x 14 μ in *Galago*) that stain very darkly and are mostly pyramidal in shape; these cells are packed closely together into a small area. Caudad, n. suprageniculatus is replaced by n. olivaris superior.

In *Anthropoidea*, *n. suprageniculatus* (Figs. 125-128) is considerably reduced in size. It lies along the dorsomedial margin of n. geniculatus medialis, and extends for a short distance caudally before it is replaced by the mesencephalic tectum. Its cells are larger (26 x 17 μ) and more darkly staining than those of the corresponding nucleus in prosimians. The cells are arranged very densely just above n. geniculatus medialis.

In man, n. suprageniculatus (Figs.139-140) is a small, ovoid structure lying dorsal to the magnocellular portion of n. geniculatus medialis, and medial to n. pulvinaris inferior. It consists of very large, deeply staining, multipolar cells that are orientated dorsomedially towards the pretectal area, and that are linked with the cells of n. limitans which lie dorsomedial to n. suprageniculatus.

3. N. limitans (NL) (Plates 4 - 54)

In Elephantulus myurus, n. limitans (Figs. 39-40) lies between n. pretectalis and the ventrolateral thalamic region as a thin band of small, dark-staining, fusiform cells arranged in one or two rows from dorsolateral to ventromedial. Thin, myelinated fibres run through n. limitans in the same direction as the cells. It is probably homologous to n. limitans of primates, although the latter runs in the opposite direction, i.e., from ventrolateral to dorsomedial.

In the Tupaioidea, n. limitans is a well defined, short band of cells stretching from the magnocellular part of n. geniculatus medialis ventromedially to link up with n. suprageniculatus dorsally. N. limitans separates the caudal thalamic region from the tegmental area of the mesencephalon.

In Prosimii, n. limitans (Figs. 69-116) does not vary greatly among the species, except that it becomes longer in its caudal extent, and is a more prominent structure separating n.

suprageniculatus from the pulvinar ventrolaterally. Its dorsal part abuts on the centrum medianum-parafascicular complex which has shifted dorsally into the region occupied rostrally by n. mediodorsalis. The cells of n. limitans are as large and dark-staining as those of n. suprageniculatus (18 x 13 μ in *Galago*, and 22 x 17 μ in *Lemur*). These cells are orientated in the same direction as the fibres which constitute the posterior part of the internal medullary lamina.

In *Cercopithecus aethiops*, *n. limitans* (Figs.125-128) is narrower, and extends obliquely from the posterior end of n. parafascicularis towards n. geniculatus medialis. N. limitans comprises several phylogenetically older nuclei such as nn. pretectalis pars lateralis, tractus optici and thalamicus posterior. The cells of n. limitans are smaller, less darkly staining, and less polygonal than those of the same nucleus in the prosimians (15 x 9 μ).

In man, *n. limitans* (Figs.137-140) is present as a thin small band of small, dark staining and fusiform cells that separate the pulvinar from the mesencephalic tectum. Its topography and architectonics do not differ much from those in the vervet monkey. Both nn. limitans and suprageniculatus disappear when the pulvinar becomes detached from the midbrain.

Discussion on nn. suprageniculatus and limitans

The descriptions of nn. suprageniculatus and limitans by Kanagasuntheram et al (1968) for *Galago senegalensis* and *Nycticebus coucang* correspond more or less with those for lemuroids in this study. In *Tarsius*, Le Gros Clark (1930) identified *n. suprageniculatus* as a medially placed portion of the caudal extremity of n. lateralis pars posterior, and having the same topographical relations with nn. limitans, tractus optici and geniculatus medialis as in other prosimians. This author observed that n. suprageniculatus is linked with nn. parafascicularis and centrum medianum by a chain of cells extending laterally between the pulvinar and the parvocellular part of n. geniculatus medialis. Consequently, he considered n. suprageniculatus of Tarsius to be a caudoventral appendage of n. lateralis which becomes eventually incorporated into n. geniculatus medialis. Therefore, its relation with n. geniculatus medialis can be likened to the pulvinar which, being an appendage of the lateral nucleus, is related to n. geniculatus lateralis. In primates, the cells of n. suprageniculatus should not be confused with those of the dorsomedial part of n. geniculatus medialis which are placed ventromedially to, and which are much smaller and less darkly staining than, those of n. suprageniculatus.

In lower primates, n. limitans is regarded only as a part of n. tractus optici. In higher primates, n. limitans is relatively better developed, and n. tractus optici forms a part of its long, narrow structure that separates the pulvinar from the mesencephalic tectum. Walker (1938), Krieg (1948) and Heiner (1960) regard n. limitans as consisting of broken up fragments of large, very darkly staining cells including those of n. tractus optici. Both nn. suprageniculatus and limitans are briefly described in the human thalamus, and they have the same topography and architectonics as already observed in this study.

A sublentiform nucleus (n. sublentiformis) has been described in the monkey (Carpenter and Pierson, 1973) as a crescent-shaped group of small and medium-sized cells lying medial to n. tractus optici and lateral to n. commissuralis posterior. These authors regard it to be the largest nuclear subdivision of the pretectum, though its width and rostrocaudal extent are less than that of n. tractus optici. It is apparent that the sublentiform nucleus of Carpenter and Pierson homologizes with the lateral part of n. pretectalis in lower primates, and with a large portion of n. limitans in higher primates in this study.

5. N. tractus optici (NOT) (Plates 4 - 46)

In *Elephantulus myurus*, this nucleus (Figs.39-40) is present as a narrow cellular layer lying *above* n. pretectalis. It contains medium-sized, oval or fusiform cells that stain much more deeply than any other cells of the thalamus. These cells are arranged with their long axes orientated mediolaterally and are enmeshed in a thick matrix of fibres giving n. tractus optici a heavily dotted appearance.

In the tree-shrews, and particularly the prosimians, *n. tractus optici* (Figs. 51-116) is a most interesting structure from the evolutionary viewpoint. N. tractus optici is a conspicuously large mass of cells lying at the dorsal end of the optic tract, just lateral first to n. commissuralis posterior, and then to the commissure of the superior colliculus. Caudad, n. tractus optici comes to lie ventral to n. pretectalis, and medial to the pulvinar before being replaced by the mesencephalic regions. In all prosimians, the cells are unusually large in size, measuring often over 40 x 25 µ, stain very deeply and are typically multipolar. In *Lemur* spp., where the pulvinar starts to push all other posterior thalamic nuclei towards the medial thalamic region, n. tractus optici shows a slightly altered topography. There, n. tractus optici is related medially to n. pretectalis, and laterally to n. pulvinaris superior pars medialis. It is shaped like a hockey-stick, whose clubbed end is placed dorsally towards the pretectal region, while the tail is connected with n. limitans ventrally. Its cells are very large (28 x 25 µ), stain very darkly, are multipolar, and are packed very closely together in a few rows. Its large size in all prosimians is clearly correlated with the enormous size of the optic tract whose fibres run along the whole thalamic surface towards the habenular complex and the region of the superior colliculus.

In *Anthropoidea*, *n. tractus optici* is an irregularly narrow band of cells running obliquely from the ventrolateral surface of n. habenularis lateralis to n. limitans. N. tractus optici is situated within the transitional zone between the pulvinar and the dorsolateral border of n. pretectalis. In man it is either absent or completely integrated with n. limitans. The cells of n. tractus optici are small (14 x 9 μ), stain less deeply and are more fusiform than pyramidal in shape.

Discussion on n. tractus optici.

N. tractus optici is a more conspicuous structure in lower than in higher primates, due to the well developed accessory optic regions in the pretectum and superior colliculus. When the optic tract is traced in its course to the superior colliculus, in a primitive mammal whose visual system is well developed, e.g., *Elephantulus*, and *Tupaia*, it will be seen that after passing n. lateralis posterior, the optic tract comes into relation with a superficial group of very large, very deeply staining, polygonal cells. This is what Le Gros Clark (1929-1932) named the 'large-celled nucleus of the optic tract', which is equivalent to 'noyau de la voie optique' of Cajal. In *lower* primates, n. tractus optici can be readily recognized as a very conspicuous structure. As the pulvinar increases progressively in size and expands caudally towards the midbrain, n. tractus optici is pushed from its superficial position to become a flattened plate of cells between the pulvinar and n. commissuralis posterior or the mesencephalic tectum. In *higher* primates, n. tractus optici loses its distinct features and is apparently incorporated into n. limitans. In the Cercopithecoidea, n. tractus optici appears as an irregular band of cells lying between the habenular region and the medial geniculate body (Crouch 1934, Papez and Aronson 1934, Krieg 1948). It is absent in man and other higher anthropoids as stated by Sheps

(1945), Dekaban (1953) and Hassler (1959); Carpenter and Pierson do not make mention of its presence in the human thalamus.

6. N. commissuralis posterior (NPC/POC) (Plates

In the Tupaioidea and Primates, n. commissuralis posterior (Figs.51-138) forms the bed nucleus of the posterior commissure. It does not vary greatly in structure and topographical relations with the adjoining thalamic nuclei. It consists of a mixture of small and large, dark-staining, stellate and fusiform cells arranged in rows along the converging fibres of the posterior commissure. It is intimately related ventrally to the nucleus of Darkschewitsch. Cytologically, it is a monomorphous and anisoformic structure.

7. N. olivaris superior (OS)

In the Tupaioidea, n. olivaris superior is a pale-staining, oval shaped structure appearing at the rostral end of the pretectal region. It has a short rostrocaudal extent, and ends at the level of the caudal extremity of the posterior thalamic region. The rostral pole of n. olivaris superior is located deep to the medial border of the brachium of the superior colliculus, where it lies ventral to n. tractus optici and dorsomedial to n. pretectalis pars dorsalis. N. olivaris superior extends caudally in a lateral direction and becomes narrow dorsoventrally. Caudad, it comes to lie between the ventral part of n. pretectalis and n. pulvinaris superior laterally and the mesencephalic tectum medially. The cells of n. olivaris superior are medium-sized, well staining, round or oval, and are situated in a clear myelin-free area through which fine fibres run from the pulvinar to the superior colliculus.

In other Primates, n. olivaris superior extends from the caudal part of the posterior commissure to the rostrolateral part of the superior colliculus. It has similar topographical relations with the adjoining nuclei of the pretectum and posterior thalamic region as in the tree-shrews. It disappears where the pulvinar becomes more sharply delineated from the superior colliculus.

Discussion on nn. commissuralis posterior and olivaris superior

Kanagasuntheram et al (1968) did not make any mention of an area containing very large, intensely staining, multipolar cells scattered among the radiating fibres of the posterior commissure and their relationship to the nucleus of Darkschewitsch. This area of cells is doubtlessly homologous to n. commissuralis posterior of the same lorisid specimens used in this study. Those authors, however, mentioned n. olivaris superior lying in the extreme caudal region of the thalamus between the pulvinar and the superior colliculus.

N. olivaris superior was described by Fuse (1936) in man, other primates and carnivores, and its presence was later affirmed in higher primates by other investigators (Aronson and Papez 1934; Atlas and Ingram 1937; Kuhlenbeck and Miller 1949; Olszewski 1952; Hendrickson et al 1970). N. olivaris superior is said to represent the caudolateral continuation of n. tractus optici , and both nuclei are thought to be derived from a common ontogenetic matrix (Kuhlenbeck and Miller 1949; Giolli and Guthrie 1969). Scalia (1972) stated because several terms have been applied to n. olivaris superior in the pretectal region of several non-primate mammals, it has not been generally recognized as the olivary pretectal nucleus of primates. This nucleus receives a dense projection from the retina (Hendrickson et al, 1970, monkey; Scalia 1972, in rodents, rabbit and tree-shrew), and in view of the widely held concept that the pupillary reflexes to light are mediated through the pretectal region (Ranson and Magoun 1933, Magoun and Ranson 1935), it may be significant that n. olivaris superior appears now to be a constant member of the pretectal or posterior thalamic nuclear group in mammals.

N. olivaris superior has not been noted in the tree-shrew by Le Gros Clark (1929) Bauchot (1963) Campbell et al (1967) and Laemle (1968). The topographic and cytoarchitectonic features of this nucleus in my tupaioid species conform with those described by Scalia (1972). Since the presence of n. olivaris superior in a wide variety of mammalian species was not mentioned by most investigators, it is understandable that its physiological rôle in pretectal mechanisms of visual function is not well known.

According to Jones and Powell (1971), the posterior thalamic group should be included with the intralaminar group of nuclei, and the region containing those groups should be considered as the pretectum ot pretectal area into which nn. tractus optici , commissuralis posterior and olivaris superior are incorporated. If this hypothesis is proved correct, there should be a continuous and well-organized projection of the neocortex upon the entire extent of the intralaminar nuclei-posterior thalamic nuclei-pretectal area complex. The prefrontal and limbic cortices are related to the rostral intralaminar nuclei (nn. paracentralis and centralis lateralis), while Areas 4 and 6 project to the medial division of the posterior thalamic group (possibly nn. centrum medianum and parafascicularis, the medial part of n. pretectalis and n. tractus optici), and the auditory cortex to the lateral division of the same nuclear group (nn. suprageniculatus and limitans). The suprasylvian gyrus of non-primate mammals or the superior temporal gyrus of primates send fibres to n. suprageniculatus and the intermediate division of the posterior thalamic group, and the visual cortex send fibre projections to the pretectum and adjoining regions.

These observations of Jones and Powell conform to some extent, with my observations on the comparative structure and phylogeny of the intralaminar and posterior thalamic nuclei in this study. There is no reason why these nuclei cannot be considered as a sort of continuous group of intermediate thalamic nuclei interposed between the medial and lateral thalamic nuclear groups in primates. The intralaminar origin of nn. centrum medianum and parafascicularis appears to confirm this morphological relationship between the intralaminar and posterior thalamic groups. Further investigations are necessary to glean more concrete facts on this intermediate thalamic group.

8. *N. reticularis* (RET) (Plates 1 - 54)

(1) INSECTIVORA

Macroscelidoidea
Elephantulus myurus

N. reticularis (Figs.33-38)is a prominent mass of medium-sized to large, very darkly staining, fusiform cells that are arranged regularly with their long axes directed dorsolaterally among dense fibre bundles. It becomes a thick crescent lying on the lateral surface of the thalamus extending from a position below the bed nucleus of the stria terminalis to the level of the habenular commissure. It is linked dorsolaterally with n. pregeniculatus and ventromedially with the subthalamus.

(2) TUPAIOIDEA

N. reticularis (Figs.43-50)is a very large nucleus that has the longest rostrocaudal extent of all nuclei of the thalamus. It commences at the level of the bed nucleus of the stria terminalis and ends at the rostral pole of the habenular commissure. N. reticularis appears to be subdivisible on a cellular basis, into a dorsolateral and a ventromedial part. The *dorsolateral part* which represents the actual n. reticularis of higher forms, extends from the stria terminalis to the rostral pole of n. geniculatus lateralis at the point of entry of fibres of the optic tract. Its cells are medium-sized (16 x 11 µ), well-staining and fusiform, and are scattered in a reticulated manner among thin bundles of fibres. The *ventromedial part* of n. reticularis begins at the caudal level of the dorsolateral part of the same nucleus, and ends blindly somewhere between the caudal part of n. geniculatus lateralis and n. pulvinaris inferior. The cells of the ventromedial part are smaller (15 x 9 µ), stain more darkly and are less fusiform in shape than those of the dorsomedial part of n. reticularis. These cells are scattered irregularly among densely reticulated fibre bundles connecting the ventromedial part of n. reticularis with the subthalamic formations.

(3) PROSIMII

(i) Lemuroidea and Lorisoidea

N. reticularis (Figs. 53-82; 85-110) is not clearly split into dorsal and ventral parts as in the Tupaioidea. However, in *Microcebus murinus* and *Perodicticus potto*, the division of n. reticularis into dorsal and ventral parts is retained, thus showing a more primitive condition in these two primates. In these species, the rostrocaudal extent of n. reticularis is much shorter. N. reticularis appears to end just at the level of the *rostral* pole of n. geniculatus lateralis, whereas in other species, it ends at the *caudal* extremity of the same nucleus. In *Microcebus murinus*, n. reticularis decreases gradually in size, until it becomes a small area of cells lying medial to n. geniculatus lateralis which has increased in size at the same time. N. reticularis has similar cellular features as those of the zona incerta. Caudad, n. reticularis is absorbed into the mesencephalic tegmentum (reticular formation). In *Perodicticus potto*, n. reticularis has similar topographical and cytological features as in *Microcebus murinus*. However, the double origin of n. reticularis is more clearly demonstrated in this species than in other prosimian species. In *Lemur* spp., the cells of n. reticularis pars dorsalis are smaller (15 x 11 µ), stain more darkly and are less fusiform in shape than those of n. reticularis pars ventralis (19 x 12 $/^{u}$).

N. reticularis of *Galago* spp. does not differ very much from those of *Lemur* and *Perodicticus*. In the rostral part of the thalamus, n. reticularis is seen as a large, reticulated mass of large, dark-staining, multipolar cells lying lateral to the anterior thalamic nuclei and ventral to n. ventralis anterior. As the thalamus expands in area, n. reticularis is pushed against the internal capsule and basal ganglia. There, n. reticularis is a thin crescentic band that extends dorsoventrally from the stria terminalis towards n. pregeniculatus to link up with the zona incerta. In *Galago senegalensis*, n. reticularis pars dorsalis is more accentuated than the ventral part of the same nucleus which loses its identity caudalwards when it merges with the lateral part of the zona incerta. Generally, n. reticularis is composed of large cells (18 x 10 - 20 x 9 $/^{u}$) that are well staining, oval or fusiform in shape and are enmeshed in a loose reticular framework of fibres. It is more monomorphous than dimorphous in character, particularly in *Galago crassicaudatus*; the cells are more isoformic than in other prosimians. In *Galago demidovii*, n. reticularis has almost identical characteristics as in the Tupaioidea, but the dorsal part is thinner and longer than the ventral part of n. reticularis.

(4) ANTHROPOIDEA

(a) Cercopithecoidea

Cercopithecus aethiops

N. reticularis (Figs. 117-128)is a narrow band of large, deeply staining, fusiform cells (25 x 10 $/^{u}$) that are arranged in a crescent between the external medullary lamina and internal capsule, lateral to n. geniculatus lateralis and the ventrolateral thalamic mass. It is not divided into dorsal and ventral parts as in lower primates; instead it forms a continuous and unbroken shell-like structure lining the lateral surface of the thalamus. It extends from the rostral part of the thalamus where it appears as a large, oval-shaped mass of darkly-staining cells to a very thin band of small, fusiform cells in the most caudal part of the thalamus. The rostral part of n. reticularis is continuous ventrally with the zona incerta, while the caudal part of the former nucleus merges with n. peripeduncularis.

(b) Hominoidea

Homo sapiens

N. reticularis (Figs. 133-140) in the human thalamus has essentially similar topographical and cytological features as in the monkey, so that there is no need to describe it in this study.

Discussion on n. reticularis

There is not much for specific discussion or comparisons of n. reticularis because its morphological, topographical and cytological features are almost identical among non-primate mammalian and primate species. Almost all workers on the mammalian thalamus include n. reticularis and n. pregeniculatus with the subthalamic formations, due to their common ontogenetic origin from the ventral thalamic anlage. However, in primates, n. reticularis is divided into dorsal and ventral parts which are allotted to the thalamus and subthalamus respectively. In these parts, cytological differences can be well observed, particularly in prosimians and tree-shrews. My observations on n. reticularis have shown that in higher primates, the ventral part of n. reticularis is much less defined than the dorsal part which forms a continuous band of cells from the dorsal thalamic surface ventralwards towards the metathalamus. There it skirts the lateral surface of n. geniculatus lateralis to end near the ventral thalamic surface. It has been also noted that both the ventral and the caudal extent of n. reticularis vary among primates. In prosimians, n. reticularis disappears at the level of the *rostral* pole of n. geniculatus lateralis, while in higher primates, it ends at the level of the *caudal* pole of n. geniculatus lateralis. In man, n. reticularis extends along the lateral circumference of the thalamus as far as the medial geniculate body where it broadens out into a sparse cellular area above n. geniculatus lateralis, and continues ventrally into the zona incerta (Feremutsch 1963).

SUMMARY OF THE POSTERIOR THALAMIC NUCLEAR GROUP

The phylogeny of the posterior thalamic nuclear group, like that of the midline thalamic nuclei, shows more regressive than progressive changes throughout the primates. The posterior thalamic nuclei are generally well developed in the insectivora, and demonstrate a higher degree of specialization in the Tupaioidea and Prosimii. In higher prosimians, such as the Galagidae, and possibly the *Tarsiidea*, the posterior thalamic nuclei start a phylogenetic decline in which they become less individually definable, and even less distinguishable cytologically from one another. In the Anthropoidea, the posterior nuclear group appears to be "caught up" between the expanding pulvinar and the ventrolateral nuclear region rostrally and dorsally, and the mesencephalon caudally and ventrally. Consequently, the posterior thalamic group becomes fragmented into small, non-discrete groups of large and small, dark staining, polygonal and fusiform cells that constitute mainly n. limitans and the pretectal area.

In the Insectivora and Tupaioidea, *n. pretectalis* is, by far, the best developed and largest of all the posterior thalamic nuclei. It is well differentiated into two cellular regions: one contains large, dark staining and fusiform cells lying lateral to n. commisuralis posterior and the mesencephalic central grey; the other consist of small, lightly staining and round cells lying medial to the medial border of the pulvinar and to nn. limitans and tractus optici. As one goes up the prosimian scale, n. pretectalis reduces gradually in size, and its cyto- and myelo-architectonic features do not vary considerably. In the Anthropoidea, due to territorial expansion of the thalamus towards the hindbrain regions, n. pretectalis is reduced to a small pretectal area, lying between the pulvinar dorsolaterally and the posterior commissure ventromedially. In man, n. pretectalis is still present as a very small and circumscribed region situated anteriorly to the superior colliculus, and possessing an important function in optic reflexes. N. thalamicus posterior is a region of disputable origin, and is either a part of the posterior commissure or a ventromedial part of the pretectal area. It is not well defined in higher prosimians and anthropoids.

Other posterior thalamic nuclei that remain more stable than regressive phylogenetically are nn. suprageniculatus and limitans. N. tractus optici is a very well formed structure with its own cytological characteristics only in the Tupaioidea and Prosimii. In higher primates, as n. geniculatus lateralis is displaced to a ventral and caudal position, n. tractus optici is a reduced structure and is incorporated into n. limitans. Nn. suprageniculatus, limitans and olivaris superior form the posterior part of the intralaminar nuclear group, and they are enmeshed in the fibrous network of the internal medullary lamina. Thus, these nuclei, when they replace nn. centrum medianum and parafascicularis, keep the medial and lateral thalamic regions separated from each other right to the end of the diencephalon.

Phylogenetic and ontogenetic studies of n. reticularis have shown that it is composed of distinct dorsal and ventral regions which are cytologically different from each other. The dorsal part of n. reticularis is a derivative of the thalamic anlage, while the ventral part of the same nucleus is actually an ontogenetic part of the subthalamus. However, as one ascends the primate scale, these two parts become more and more indistinctly demarcated from each other. The dorsal part remains predominant and forms the main body of n. reticularis in higher primates and man. The ventral part is a very small area lying between nn. pregeniculatus and subthalamicus, and is continuous medially with the zona incerta, or it may form a part of n. peripeduncularis.

The structural features, cyto- and myeloarchitectonics and phylogenetic trends of the posterior thalamic nuclei are summarized in Table 18.

TABLE 18. COMPARISONS OF THE POSTERIOR THALAMIC NUCLEAR GROUP

Features	N. pretectalis (PRET)	N. suprageniculatus (SG)	N. limitans (NL)	N. tractus opticus (NOT)	N. commissuralis posterior (NPC)	N. reticularis (RET)
STRUCTURAL FEATURES	Largest nucleus in *Elephantulus*, even bigger in size than all other diencephalic structures. In *Tupaia*, PRET reduces considerably in size due to expansion of dorsolateral thalamic nuclei which pushes it against the mesencephalon. In all prosimians, it retains its size, and is divisible, on a cellular basis, into medial and lateral parts. In higher primates, PRET undergoes such further reduction in size that it becomes an insignificant region between pulvinar and mesencephalic tectum. In man, it is still present as the pretectal area.	Not present in *Elephantulus*, and poorly defined in *Tupaia* and lower prosimians. In higher prosimians and simians, SG gains prominence at the expense of n. thalamicus posterior (TP). It becomes a rather large and well formed structure lying between n. geniculatus medialis dorsomedially and NL and NOT ventrolaterally. In man and anthropoid apes, SG is a large, ovoid mass that can be observed lying close and dorsal to the magnocellular part of n. geniculatus medialis. It is intimately related with PUL.	Present in *Elephantulus* as an ill-defined band of cells between PRET and lateral nuclear mass. It *Tupaia*, NL is better developed, and forms a well defined band of cells stretching from n. geniculatus medialis ventrally to n. tractus opticus dorsally. NL is the "separating" boundary between the thalamus and mesencephalon. NL appears to be best developed in prosimian primates. In these species, NL is a thick sward of cells running dorsoventrally from PRET to n. geniculatus medialis. In anthropoids and man NL loses its prominence, and is a very narrow band of cells between nn. parafascicularis and geniculatus medialis. It contains fragments of other posterior thalamic nuclei.	NOT is best developed in prosimians, particularly *Lemur* and Galago. In *Tupaia* NOT is rather large and well defined, but is not as elaborated as in the prosimians. In the latter species, NOT is easily discerned as a large, club-shaped structure lying near the dorsal surface of the thalamus between the medial part of n. pulvinaris superior and PRET medially, and below the superior colliculus. It is the terminus of fibres of the optic tract conveying reflex optic stimuli. In higher primates and man, NOT is a much smaller structure and forms the dorsal part of NL.	*TP forms an integral part of both PRET and NPC only in *Elephantulus* and *Tupaia*. TP is absorbed gradually into PRET as one ascends the primate scale. NPC remains unchanged in structure throughout the primate scale as it is the bed nucleus of the posterior commissure. NPC lies between PRET dorsolaterally and the central grey substance of mesencephalon ventromedially. It increases in size only in higher primates, and is the most prominent feature of the regressing posterior thalamic nuclear mass. *TP = N. thalamicus posterior	Does not vary much in structural features from *Tupaia* to Cercopithecus. In *Tupaia* and prosimians, RET is divisible into dorsal and ventral parts. The *dorsal* part is intimately connected with the thalamus, and the *ventral* part with the subthalamus. The dorsal part in *Tupaia* and prosimians is very large and forms a large part of the rostral thalamic region. Lies between nn. anteroventralis and ventralis anterior medially and internal capsule laterally. Caudad, n. reticularis pars dorsalis dwindles to a thin band of cells and is continuous with the ventral part of the same nucleus ventro-medially. In *Tupaia* and prosimians, RETv is a large band of cells that is intimately related with ZI medially and with the fields of Forel and n. pregeniculatus laterally. In higher primates, RET retains these divisions, but not as clearly as in lower primates. In man, RETv is absent, and RETd forms a thin neuronal shell covering the lateral surface of the thalamus.
CELLULAR CHARACTERISTICS (CYTO-ARCHITECTONICS)	Cells of PRET vary in size (11 x 8 /^{u} in *Cercopithecus* to 13 x 18 /^{u} in *Tupaia*). Are mostly lightly staining and oval in all primate species; they are arranged more compactly in the medial part close to posterior commissure than in lateral part close and PUL. Cellular size and composition decrease through the primate scale. PRET is at first heteromorphous, but becomes more monomorphous as one goes up the primate scale.	Cells of SG are relatively large in size (13 x 11 /^{u} in *Tupaia* to 25 x 20 /^{u} in *Cercopithecus*). Mostly well staining and polygonal , and are arranged in a tight area. Is monomorphous, and isoformic. Notable increase in cellular composition.	Cells of NL are in the range of medium-large cells (14 x 8 /^{u} in *Tupaia* to 22 x 17 /^{u} in *Lemur*). Are dark-staining and fusiform, and are arranged in neat rows running dorsolaterally to ventromedially. In higher primates NL undergoes moderate reduction in cellular size	Cells of NOT are larger and more darkly staining in lower than in higher primates, i.e., 25 x 18 /^{u} in *Lemur* 14 x 8 /^{u} in *Cercopithecus* Cells are packed compactly in an ovoid mass in these species and in loose rows joining those of NL. In higher primates, cells are arranged more loosely. Notable decrease in cellular size and density.	Cells of NPC are 25 x 20 /^{u} in *Lemur* and 15 x 7 /^{u} in *Cercopithecus*. They stain less darkly than those of NL and SG, and are scattered among fibres of posterior commissure.	Cells of RET vary in size, shape and stainability, not only in dorsal and ventral parts, but also from species to species. Cell size increases from 15 x 9 /^{u} in *Tupaia* to 25 x 11 in *Cercopithecus*. Cells are generally dark-staining and fusiform and are arranged in tight rows. Heteromorphous and isoformic in lower primates, and monomorphous and anisoformic in higher primates.

TABLE 18: (contd.) COMPARISONS OF THE POSTERIOR THALAMIC NUCLEAR GROUP

Features	N. pretectalis (PRET)	N. suprageniculatus (SG)	N. limitans (NL)	N. tractus opticus (NOT)	N. commissuralis posterior (NPC)	N. reticularis (RET)
MYELIN CONTENT AND FIBRE ARRANGEMENT (MYELOARCHITECTONICS)	PRET is densely myelinated in Elephantulus and Tupaia with a mottled look that distinguishes it from n. thalamicus posterior. In some prosimians, PRET is very densely myelinated in its medial part where it is related closely to superior colliculus. In other prosimians, PRET is much more lightly myelinated, especially in its lateral part. In higher primates, PRET is almost entirely lightly myelinated and can be detected easily lying between superior colliculus and pulvinar. In man, it is even lighter; few fibres flow through it from the lateral geniculate body to superior colliculus.	Not observed in Elephantulus. SG is a thickly myelinated area in Tupaia, Microcebus and G. demidovii. Dense fibre fascicles give SG a mottled look. In larger prosimians, SG is a more lightly myelinated area with finer fibres running through it from MGN and PULI to NL. In man and anthropoids, SG is a rather densely myelinated and ovoid mass easily distinguishable from the magnocellular part of medial geniculate body and n. limitans.	In Tupaia, NL is a thin, dark band of delimiting SG and PULI from NOT and NPC. In prosimians, NL is thicker. In larger prosimians, NL has increased its width so that it resembles a thick sward delimiting the pulvinar from the mesencephalon. In man and anthropoid apes, NL is reduced considerably in width, and is a thinner band of myelinated fibres, demarcating the posterior thalamic region from the midbrain.	In Elephantulus, NOT is an irregularly arranged and narrow area of fibres lying dorsal to PRET. In Tupaia, NOT is a dense, mottled area related ventrally to PRET. In smaller prosimians, NOT is a consolidated area of fibres lying dorsomedial to NPC and PRET. In larger prosimians, NOT is covered with a dense feltwork of fibres. In higher primates, NOT is a much smaller area with more finely myelinated fibres running through it to NL. Is not easily seen in man, since it forms a part of NL.	NPC does not vary much in myelin content and fibre arrangement in Tupaia, Lemur, Galago and Perodicticus as well as in higher primates. NPC is delimited very clearly from PRET and NOT on its lateral side, and from mesencephalic tectum on its medial side. Fibres converge from the region of the nur nucleus of Darkewitsch dorsally to form the posterior commissure.	In Elephantulus, RET gives a criss-cross appearance, and is the most densely myelinated area in the rostral thalamic region. In Tupaia, RET is more dense in its ventromedial part than in its dorsolateral part, which is almost devoid of fibres. In Tupaia and all prosimians, RET forms a very deeply staining and reticulated area, in the rostral regions of the diencephalon. In all prosimians and intermediate primates, the dorsolateral part of RET is thicker than its ventromedial part, since the latter part is much reduced in size and extent. In anthropoid apes and man, RET is a thin, scattered band of fibres lying between the lateral thalamic mass and the internal capsule.
PHYLOGENETIC TRENDS	PRET is non-primate mammals and insectivores appears to be a very well developed structure in comparison with superior colliculus and lateral geniculate body. In Tupaia, as visual reflexes are more invested in the superior colliculus and LGN is more advanced in structural development, PRET regresses in structural size and functional importance. These phylogenetic changes are stressed as one ascends the primate scale, until in man, PRET is almost divested of functional importance and is only a centre for pupillary reflexes.	Is more of a stable than regressive structure in the Tupaioidea and Prosimii. In higher primates, though SG is further reduced in size, it remains stable. Its functions are not known apart from the fact that it and NL form the posterior part of the intralaminar nuclear group which are supposed to have connections with some areas in the frontal and superior temporal regions of the cerebrum.	Also a stable structure, forming a part of the posterior intralaminar region, co-ordinating PRET and other post thalamic nuclei with Areas 4 and 6 in the cerebral cortex. Is best known as the delimiting line between the posterior thalamic region and the mesencephalon.	NOT is phylogenetically more prominent in Tupaia and many prosimians, particularly where n. geniculatus lateralis has shifted slightly to a lateral position. It regresses gradually up the primate scale to man. Functions as a receptive area for optic tract fibres going to PRET and superior colliculus.	NPC is a very stable structure phylogenetically; does not change structure and function throughout the primate scale. Is a bed nucleus of posterior commissure which connects thalamic visual centres with mesencephalic visual areas.	RET is also a very stable phylogenetic structure; does not change much in structure, except that it has a double embryonic origin, connecting the diencephalon and the reticular formation of hindbrain with the reticular areas in the cerebral cortex.

PART IV

THE PARATHALAMIC FORMATIONS: OBSERVATIONS AND DISCUSSIONS

CHAPTER 11

THE EPITHALAMUS

The epithalamus is the dorsal division of the diencephalon, and is clearly demarcated dorsally and caudally from the thalamus. It consists of the habenular complex, the epiphysis or pineal organ, and the posterior commissure, the bed nucleus of which has already been described in Chapter 11.

1. The Habenular Complex (Plates 1 - 54)

It consists of nn. habenulares lateralis and medialis, and a habenular commissure. In all species studied here, the habenular nuclei do not show any significant variations in regard to size, shape, cellular composition and topographical relations.

(a) N. habenularis medialis (HABm)

This nucleus (Figs.33-36) is a prominent mass of small, deeply staining cells situated very close to the ependyma of the third ventricle. Caudad, n. habenularis medialis enlarges dorsoventrallyand extends farther caudally than n. habenularis lateralis. It ends just ventral to the habenular commissure. N. habenularis medialis is related dorsally to n. paraventricularis posterior, dorsolateral to the caudal end of n. mediodorsalis, and caudal to n. parataenialis. Ventrolaterally, n. habenularis medialis joins the more widely spaced cells of n. habenularis lateralis. Along the whole of its length, n. habenularis medialis is intimately related ventrally to the stria medullaris, which contributes fibres to it. N. habenularis medialis contributes fibres to the habenular commissure which lies ventral to it, and to the habenulopeduncular tract

N. habenularis medialis is more densely cellular and less myelinated than n. habenularis lateralis. Lateral extensions spread from it dorsally over the latter nucleus and beneath the stria medullaris. N. habenularis medialis stains more intensely than not only its lateral counterpart, but also all other thalamic nuclei lying adjacent to the habenular complex. The cells of n. habenularis medialis vary much in size (6 x 4 μ in *Galago* to 11 x 5 μ in *Cercopithecus*); they are, therefore, generally small and are mostly round in shape. These cells are arranged in 'rosettes' around eosinophically staining homogeneous areas of neuropil.

(b) *N. habenularis lateralis* (HABl)

N. habenularis lateralis (Figs.33-140) begins rostrally at the same level as, or slightly caudal to, n. habenularis medialis, and ends slightly rostral to the latter nucleus at the level of the rostral end of the habenular commissure. Although n. habenularis lateralis is less conspicuous than its medial counterpart, it is the larger of the two, particularly in larger prosimians and in higher primates. It is intimately related to the stria medullaris, and contributes many fibres to the afferent epithalamic tracts, notably the habenulopeduncular tract. N. habenularis lateralis lies dorsal first to the caudal end of n. mediodorsalis, and to the centrum medianum-parafascicular complex, then to the bed nucleus of the posterior commissure, and lateral to nn. pretectalis and tractus opticus. The cells of n. habenularis lateralis are medium-sized (between 10 x 6 μ in *Tupaia* and 14 x 9 μ in *Cercopithecus*), round or fusiform with a tendency towards polymorphism. These cells vary in staining capacity from very light in Tupaia to very dark in Galago crassicaudatus, but they are not as deeply stained as those of n. habenularis medialis. The cells of n. habenularis lateralis are arranged loosely along the transverse fibres of the habenulopeduncular tract.

Both habenular nuclei are monomorphous; the lateral habenular nucleus is more anisoformic than the medial part, and large cells are frequently found in the former nucleus.

In Elephantulus, n. habenularis medialis is triangular while its lateral counterpart is ovoid in shape. In the Tupaioidea, n. habenularis medialis is shorter and more squat mediolaterally than dorsoventrally, while n. habenularis lateralis is rounded and shaped like an inverted comma. In the Lemuroidea, n. habenularis lateralis increases slightly in size and in dorsoventral extent; it is shaped like an inverted comma. N. habenularis medialis is smaller and narrower, being compressed against the wall of the third ventricle by the expanding n. habenularis lateralis, and to a larger extent, by the pulvinar. In all prosimians used in this study, n. habenularis lateralis shows marked anisoformity, that is, there is more than one type of cell in this nucleus, medium-sized cells that are oval, dark-staining and compactly arranged among large, less darkly staining and polyhedral cells. N. habenularis lateralis has a richer myelin content than n. habenularis medialis. Fibres collect at the ventral border of n. habenularis lateralis and run medialwards where they are joined by more sparse fibre bundles from n. habenularis medialis. These fibres form the habenulopeduncular tract which runs ventralwards through the medial thalamic region to end in the interpeduncular nucleus of the midbrain.

In the Anthropoidea, the habenula is a small, depressed triangular area - trigonum habenulae - situated in front of the superior colliculus and medial to the posterior thalamic region. N. habenularis medialis is a small, prominent mass of small, deeply staining, round cells situated close to the ependyma of the third ventricle. Caudad, n. habenularis medialis enlarges in size and extends farther caudally than n. habenularis lateralis. Its topographical relationships are identical to those found in lower primates. N. habenularis medialis is closely related to the stria medullaris, from which it receives fibres, and to the habenular commissure which is situated immediately above its caudal extremity.

N. habenularis lateralis does not differ much in its topography and cytoarchitectonics from that of prosimians.

(c) Habenular Commissure (HABC)

It constitutes the dorsal peduncle of the epiphysis. It varies in position and relation to the epiphysis among all primate species. The stria medullaris and habenular region contribute fibres to it. The habenular commissure lies rostral and dorsal to the posterior commissure, with which it merges caudally. At this level of fusion, both commissures are replaced by the commissure of the superior colliculus.

2. The Epiphysis or Pineal Body (P)

The epiphysis is a small outgrowth of the roof of the diencephalon in the region immediately dorsal and caudal to the posterior and habenular commissures. It is placed below the corpus callosum being separated from it by the tela chorioidea of the third ventricle. It extends as far caudally as the rostral end of the superior colliculus. The epiphysis is attached to each side of the habenula~~r~~ by a short stalk or peduncle, the dorsal lamina of which is formed by the habenular commissure and the ventral lamina of which is formed by the posterior commissure. Between these laminae, is a small recess lying rostral and ventral to the aqueduct of the midbrain - *recessus pineale*.

In prosimian specimens used in this study, the epiphysis is relatively small and rostrocaudally short. It is generally ovoid or spherical in shape, but is almost pyramidal in *Galago crassicaudatus*. The epiphysis lies in the roof of the third ventricle between the stratified region of the superior colliculi of both sides. In *Lemur* and *Galago*, the epiphyseal peduncle is very short and stout, and its connection with the posterior commissure is not as clearly defined as in higher primates, although there are some fibres connecting the epiphysis with the posterior commissure just ventral and caudal to the habenular commissure.

The epiphysis in all primates is composed principally of pinealocytes with a fair amount of interstitial cells which resemble neuroglia in many features. Brain-sand or acervuli have not been observed in the prosimian material used in this study. However, in one of the Perodicticus potto specimens, small, very dark and refractile, concentric forms are seen distributed among the cells. In this same specimen, the pinealocytes appear to be of two types, like those in the human pineal gland: light and dark cells. The light cells may be the actual principal pineal cells while the dark ones may be the interstitial cells.

Discussion on the epithalamus

Although the epithalamus is an ancient component of the vertebrate diencephalon, it is a well developed mammalian structure, like the 'dorsal' thalamus.

Nn. habenulares medialis and lateralis appear to reach their peak of development in lower vertebrates. They undergo gradual regression as one goes up the mammalian scale towards primates. N. habenularis is readily identifiable in all vertebrate forms, and remains remarkable constant in its cyto- and myelo-architecture throughout the mammalian scale to man. In mammals, n. habenularis forms most of the epithalamic region, and its commissure is comparatively larger in lower than in higher mammals.

In Elephantulus myurus, the large size and well developed appearance of the epithalamus confirm Bauchot's (1963) descriptions in his macroscelidoid specimens, in which are found also a prominent stria medullaris, a thick habenulopeduncular tract and a well formed habenular commissure. The epiphysis in Elephantulus is comparatively larger than those of other insectivores. The habenular complex of *Elephantulus* is even larger with a longer rostral extent than in the Tupaioidea and Prosimii. Bauchot observes, in *Tupaia glis*, that n. habenularis lateralis is divided into two different cellular parts, the medial part having a greater caudal extent and less scattered cells than the lateral part. Possibly the cellular division in n. habenularis lateralis is due to the presence of denser fibre arrangement than in n. habenularis medialis. This cellular division is observed also in the same species or in any other tupaioid and prosimian specimens in this study, as most of the fibres forming the habenulopeduncular tract originate from n. habenularis lateralis.

In *Tupaia minor*, Le Gros Clark (1929) described no cellular divisions; the habenular nucleus is only a flattened band of deeply staining, medium-sized cells packed together and lying immediately beneath the ependyma at the dorsomedial border of the thalamus. Lying lateral to the habenular 'ganglion', Le Gros Clark observed clusters of small cells along the dorsal surface of the thalamus. He homologized that area to n. habenularis pars lateralis in the opossum (Tsai 1925). Those scattered cell clusters are well observed in *Tupaia minor* and also in other tupaioids in this study, and they are found, not outside the habenular ganglion, but within n. habenularis lateralis.

Bauchot (1963) found that, in *Galago demidovii*, n. habenularis extends farther caudally than in *Tupaia glis* and all insectivores. In *Galago demidovii*, n. habenularis medialis is not subdivided into two cellular areas, and differs from n. habenularis lateralis only in cellular composition. This cytoarchitectonic feature is confirmed in the galagid species in this study, and nothing more significant than this is observed in all other prosimians. However, the course of the habenular tract is vertical and straight, not oblique and 'retroflexed' as in higher primates, particularly in man. In *Tarsius*

(1930), Le Gros Clark observed that the habenular region is well demarcated into medial and lateral parts that are cytoarchitectonically different from each other. The medial part of n. habenularis is smaller in size and shorter in its dorsoventral extent than n. habenularis lateralis. The latter nucleus contains a mixture of medium-sized and large cells, which are less darkly staining, more polygonal and more loosely arranged among the fibres of the habenulopeduncular tract than those of n. habenularis medialis. It can be inferred from Le Gros Clark's observation that the habenular region of Tarsius corresponds more closely to that of higher than of lower primates. However, the habenulopeduncular tract differs from that of simian primates in having a straight course towards the interpeduncular 'ganglion' of the mesencephalon.

Olszewski (1952) observed in Macaca mulatta that n. habenularis lateralis contains massive nests of cells which are arranged more closely along the lateral border of the habenular region. In Cercopithecus aethiops, n. habenularis lateralis does not exhibit this characteristic, as its cells are scattered more loosely among the fibres of the habenulopeduncular tract. Therefore, it is possible that Olszewski's specimen may be unique in having this cytoarchitectonic feature, or those massive nests of cells may be located in the lateral part of the medial habenular nucleus that has shifted towards the lateral habenular nucleus.

SUMMARY OF THE EPITHALAMUS

The epithalamus does not show considerable variations in its topography throughout the primate scale. Evolutionary trends are rather evident in the tree-shrews and prosimians. However, between Elephantulus and Homo, there is a wide range of differences in cellular characteristics in the habenular region.

The habenular region, in all primate species, is generally divided into medial and lateral parts which are different cytoarchitectonically from each other. It is a more conspicuous structure in *Elephantulus* than in *Tupaia* and all primates. In Primates, the habenular region undergoes gradual reduction in size, and is 'pushed' by the developing thalamic mass to a more caudal position. The epiphysis in *Elephantulus* is very well developed, too, and is well connected by the habenular and posterior commissures to the habenular and posterior thalamic regions respectively.

Structural variations, cellular characteristics, fibre arrangements and evolutionary trends are further summarized in Table 19.

TABLE 19 COMPARISONS OF THE EPITHALAMIC STRUCTURES

	N. habenularis medialis (HABm)	N. habenularis lateralis (HABl)	Epiphysis (Pineal Body - P)
STRUCTURAL FEATURES	In Elesphantulus, HABm is larger than HABl. Generally, in non-primate mammals, the epithalamus is very large and prominent with a much longer rostro-caudal extent than in the Tupaloide and Primates. All the elements of the epithalamus, (stria medullaris, habenula, habenular commissure, posterior commissure and epiphysis) are large in relation to those observed in Primates. In Elephantulus, HABm is triangular in shape, and ends slightly caudal to HABl. In the Tupaloidea, HABm is shorter than HABl, and is not elongated dorsoventrally. It is much smaller in relative size, but is one of the most intensely staining elements of the diencephalon. In all prosimians, HABm is much smaller and has a longer caudal extent than HABl. Its shape varies considerably from species to species - is mostly narrow and shaped like a loaf or an inverted comma. In higher primates and man, it is much narrower and elongated dorsoventrally, due to a deeply furrowed third ventricle.	HABL in Elephantulus is smaller and triangular with its base resting on the lateral surface of HABm. In Tupaia, it has a shorter rostrocaudal extent than HABm, and is rounder in shape. Is the smallest epithalamic structure, and can be easily distinguished from HABm by its very lightly stained appearance. In the Prosimii, HABl varies in structure from a stout comma-shape to triangular. It is the smallest structure, not only in the epithalamus, but in the whole diencephalon. In higher primates, HABl is broader in shape, and has a longer caudal extent, ending only slightly rostral to HABm. Both HABL and HABm are related closely to the stria medullaris, to nn. parataenialis and pretectalis, to the epiphysis and habenular commissure. HABl contributes most fibres to the habenulopeduncular tract.	The epiphysis varies considerably in size and shape in all Insectivore and primate species. Its topography and relations with other diencephalic structures remain more or less the same throughout the primate scale. However, in Tupaia, it is relatively smaller in size than that of Elephantulus. In Prosimii and Anthropoidea, the epiphysis is comparatively smaller and rounder in shape. It is attached to the epithalamus by a stout peduncle, composed of two laminae. The dorsal lamina is formed by the habenular commissure which attaches the epiphysis to the epithalamus. The ventral lamina is provided by the posterior commissure which connects the epiphysis to the thalamus. These laminae appear better developed in higher primates than in Tupaloidea and Prosimii. where the dorsal lamina is but a thin bundle of fibres running through the habenular commissure.
CELLULAR CHARACTERISTICS (CYTOARCHITECTONICS)	Cells of HABm are generally small to medium-sized (6 x 4 /^{u} in Galago to 11 x 5 /^{u} in Cercopithecus). These cells stain moderately well in Elephantulus, Tupaia, Microcebus and G. demidovii, but much more deeply in larger prosimians and higher primates. They are mostly round or fusiform in shape.([illegible]), and are arranged in "rosettes" around eosinophically stained neuropil. In higher primates, cells of HABm stain more darkly than those of HABl, and are compactly arranged. HABm is monomorphous and isoformic.	Cells of HABl are slightly larger than those of HABm; (10 x 6 /^{u} in Tupaia to 14 x 9 /^{u} in Cercopithecus). They stain much less intensely than those of HABm, and are usually oval or stellate in shape.([illegible]). The cells of HABl are arranged in a loose and scattered manner among the converging fibres of the habenulopeduncular tract. HABl is monomorphous in lower prosimians, may be dimorphous in higher prosimians, but is heteromorphous in Elephantulus and higher primates. In all species, it is anisoformic.	The epiphysis is composed of two types of cells - pinealocytes which are small, round and dark-staining, and interstitial cells which resemble neuroglia in many respects, and are slightly larger, more lightly staining and more stellate than pinealocytes. These cell types are better defined in higher prosimians and all higher primates. Brain-sand has not been observed in all primate species, the Tupaiidae and Elephantulus. The brain-sand may be more commonly found in man and higher anthropoids.
MYELIN CONTENT (MYELOARCHITECTONICS)	Sparser myelin content in HABm than in HABl. Fibres are entwined mostly along the lateral and ventral borders of HABm, and contribute fewer fibres to the formation of the habenulopeduncular tract. Finer myelinated fibres course in all directions and surround the cell nests.	Dense fibre bundles run through HABl, mostly in a dorsoventral direction, and along its medial and ventral borders.	In Elephantulus, Tupaia and lower prosimians no fibres can be detected in the epiphysis, except very fine, unmyelinated fibres coursing through it. Myelinated fibres gather on its lateral sides where they may form the epiphyseal stalk or peduncle. In higher prosimians, isolated fibre bundles are seen in the gland. These are more evident in higher primates and man.
EVOLUTIONARY TRENDS	No significant changes in phylogeny except slight increase in size. Cellular features are better differentiated in lower than in higher primates. Stable in character throughout the primate scale.	No significant phylogenetic changes. Is stable in all primate species. Both HABL and HABm are pushed to a more caudal position as the thalamus increases in its posterior extent.	No significant phylogenetic features, apart from a slight reduction in size, and better cytological differentiation in higher than in lower primates.

CHAPTER 12

THE METATHALAMUS: A. LATERAL GENICULATE BODY

Although the metathalamus is essentially a part of the 'dorsal' thalamus, its phylogeny is so interesting and different from that of other thalamic formations that it merits special consideration.

The metathalamus comprises only the lateral and medial geniculate bodies, which, due to variations in structure and function in each formation, will be described and discussed in three separate chapters, namely (A) the lateral geniculate body, in Chapter 12 and 13, and (B) the medial geniculate body in Chapter 14. As mentioned in Chapter 3, the lateral geniculate body represents an entity that consists of two structurally and functionally different parts - (1) n. pregeniculatus that will be described in this chapter and (2) n. geniculatus lateralis which will be dealt with in Chapter 13.

1. N. pregeniculatus (PGN) (Plates 2 - 53; 55 - 68)

(1) INSECTIVORA

Macroscelidoidea

Elephantulus myurus

N. pregeniculatus (Figs. 35-38; 141-142) is an oval mass of small, rather darkly staining, round cells lying in the diencephalic wall between the optic chiasma rostrally and the posterior commissure caudally. It is related dorsally to n. geniculatus lateralis, medially to the ventrolateral thalamic region, and ventrally to n. reticularis. Its outer convex surface is related to the optic tract, from which it receives numerous fibres. N. pregeniculatus contributes fibres to the superior colliculus through the optic tract, as the latter passes along the dorsal surface of the thalamus.

(2) TUPAIOIDEA

N. pregeniculatus (Figs.45-50; 143-144) is a very large, reticulated structure which is not laminated like n. geniculatus lateralis. In myelin-stained sections, n. pregeniculatus appears as a more lightly staining area than nn. geniculati lateralis and medialis. The cells of n. pregeniculatus are medium-sized (14 x 10 μ), stain more darkly, are stellate or fusiform, and are arranged more loosely than those of n. geniculatus lateralis. N. pregeniculatus lies immediately ventral to n. geniculatus lateralis and medial to n. reticularis pars ventralis. Caudad, n. pregeniculatus expands ventrally along the concave surface of the optic tract, and then becomes gradually smaller in size. Before it disappears, n. pregeniculatus lies on the ventral aspect of the thalamus, immediately lateral to nn. peripeduncularis and subthalamicus, and is replaced by the former nucleus.

(3) PROSIMII

(a) *Lemuroidea*

(i) *Microcebus murinus*

N. pregeniculatus (Figs.58; 145-146) is not as apparent in this species as in *Tupaia*, but it may be seen as a small group of scattered, large, dark-staining, fusiform cells lying rostral and ventromedial to n. geniculatus lateralis. N. pregeniculatus has a shorter rostrocaudal extent than that of the Tupaioidea; it ends just rostral to the caudal pole of n. subthalamicus. In *Microcebus murinus*, the topographical position of n. pregeniculatus is different from that in the tree-shrew; it does not lie ventral but ventromedial to the innermost layers of n. geniculatus lateralis.

(ii) *Lemur spp.*

In these species, *n. pregeniculatus* (Figs. 79-80; 149-154) is less well developed. At first, it resembles a wedge that lies between the cerebral peduncle ventrally and the rostral pole of n.geniculatus lateralis dorsally. Caudad, n. pregeniculatus elongates along the ventrolateral surface of the thalamus. Possibly due to the ventralward shift of n. geniculatus lateralis and posterior expansion of the pulvinar, n. pregeniculatus is shifted to a more medial than ventral position. This altered topographical situation is maintained through all lemurines studied here. The cells of n. pregeniculatus are larger than those of the Tupaioidea (17 x 10 μ), stain less darkly and are more fusiform than stellate in shape. N. pregeniculatus disappears at the rostral level of n. centrum medianum where it is replaced by n. peripeduncularis. Throughout its rostrocaudal extent, a thin strand of small, darkly staining, spindle-shaped cells runs from the ventromedial surface of n. pregeniculatus towards the zona incerta and fields of Forel, thus showing its ontogenetic connection with the subthalamus rather than with the thalamus.

(iii) *Lepilemur*

N. pregeniculatus (Figs. 67-68; 147-148) appears to be better defined in this species than in other lemuroids, and it resembles more closely that of the Tupaioidea. N. pregeniculatus is a small, cone-shaped structure lying ventromedial to n. geniculatus lateralis. Its cells are smaller, less darkly staining and more fusiform than those of n. geniculatus lateralis, and these cells are scattered among the fibres of the optic tract, which runs through it towards n. geniculatus lateralis. The connection of n. pregeniculatus with the subthalamus can be clearly observed as in the Tupaioidea.

(b) *Lorisoidea*

(i) *Perodicticus potto*

In this species, *n. pregeniculatus* (Figs.94; 155-156)shows definite signs of regression. At the level of the caudal end of the mamillary region, n. pregeniculatus is seen as a much smaller structure that appears slightly rostral to n. geniculatus lateralis. Caudad, the n. pregeniculatus changes from a wedge-shape to a crecentic form; its *dorsal* end fans out towards the ventral end of n. reticularis, while its *ventral* end tapers as a tail-like formation, towards the cerebral peduncle. It is very short in rostrocaudal extent. The cells in the dorsal end of n. pregeniculatus are medium-sized, well staining, oval or round, and packed compactly into an ovoid area, while those in the ventral end of the same nucleus are fusiform and slightly more darkly staining. Caudad, n. zonae incertae abuts on n. pregeniculatus laterally, and above the latter nucleus,is n. ventralis posterior. N. pregeniculatus then dwindles in size, and terminates at the level of the first sign of lamination in n. geniculatus lateralis.

(ii) *Galagidae*

In *Galago* spp., *n. pregeniculatus* (Figs. 157-158) is a small simple structure lying medial to n. geniculatus lateralis. N. pregeniculatus commences more rostrally than the latter nucleus, and is seen as an oval shaped mass of medium-sized cells (14 x 8 μ) that are more darkly staining and fusiform than those of n. geniculatus lateralis, and that border on the medial aspect of the optic tract. As n. geniculatus lateralis increases in size and in degree of lamination, n. pregeniculatus is reduced to a vestigial structure facing dorsolaterally towards the former nucleus. Farther caudally, n. pregeniculatus is absorbed into the subthalamic region.

(4) ANTHROPOIDEA

(a) Cercopithecoidea

Cercopithecus aethiops

In this species, n. pregeniculatus (Figs. 119-122; LGBv) is much smaller and more crescentic in shape than geniculatus lateralis. Morphologically and phylogenetically, n. pregeniculatus is related more closely to nn. reticularis and zonae incertae than to n. geniculatus lateralis. N. pregeniculatus can be differentiated rather clearly into an internal or medial and an external or lateral portion. The internal portion is continuous with the zona incerta, and consists of small to medium-sized cells (9 x 8 μ) that stain more lightly and are more oval than fusiform in shape. The external portion is poorly developed, and is found mainly in the caudal part of the subthalamic region; it forms a thin crescent of large, deeply staining fusiform cells (14 x 10 μ) that lie along the medial aspect of the optic tract. It disappears just rostral to the commencement of n. geniculatus lateralis.

(b) Hominoidea

Homo sapiens

N. pregeniculatus (Figs. 137-138; 167-168) is represented only by a small lunate mass of small, pale-staining, stellate cells lying medial to n. geniculatus lateralis and lateral to the zona incerta. These cells are scattered among the fibres of the optic radiation. Although n. pregeniculatus is much reduced in man, it is still divisible into internal and external portions. The internal portion can be discerned as a thin strand of small, pale-staining and fusiform cells linking n. pregeniculatus with nn. peripeduncularis and zonae incertae. The external portion forms the main body of n. pregeniculatus, and is well connected with n. reticularis above it. The posterior expansion of the pulvinar causes an almost complete inversion of n. geniculatus lateralis, so that n. pregeniculatus appears to be displaced to a dorsomedial position above the latter nucleus.

Discussion on n. pregeniculatus

N. pregeniculatus is a homologue of the phylogenetically older part of the lateral geniculate body or the pars ventralis of n. geniculatus lateralis of primitive mammals. It appears first in lower vertebrates, particularly in reptiles, and is differentiated more and more clearly from the dorsal part of the lateral geniculate body as the phylogenetic scale is ascended from this group through mammals to Primates. However, n. pregeniculatus is still poorly differentiated in lower mammals, and reaches its peak of phylogenetic development only in ungulates and carnivores. As one goes up the higher mammalian scale, n. pregeniculatus becomes poorly developed and is reduced in size until it becomes a vestigial appendage of n. geniculatus lateralis in primates.

Niimi et al (1963) carried out a survey of the cytoarchitectonics of n. pregeniculatus, in a series of mammals ranging from Rodentia to Primates. They demonstrated that n. pregeniculatus was subdivided cytoarchitectonically into an internal or medial and an external or lateral part or layer. The external layer forms a band of large and deeply staining cells, and is covered laterally by the optic tract. The internal layer, containing smaller and less darkly staining cells, fuses ventromedially with the zona incerta. However, these cellular subdivisions do not occur in lower primates, particularly in the Lemuroidea and Lorisoidea, presumably because n. pregeniculatus is so reduced in size. This cellular differentiation has not been found in the Insectivora or Tupaioidea, nor even in the lower prosimians, such as Microcebus murinus and Lepilemur, where n. pregeniculatus is larger and better developed. However, in the latter two species, the cells lying nearer to the subthalamic region, tend to be smaller and less darkly staining than those lying close to n. geniculatus lateralis and n. reticularis.

Le Gros Clark (1929) states that n. pregeniculatus of *Tupaia minor* is a discrete ventral division of the lateral geniculate body, and that its cells are smaller, more lightly staining and triangular than those of n. geniculatus lateralis. N. pregeniculatus commences at a rostral level immediately ventral to n. geniculatus lateralis and lateral to n. reticularis. It expands ventralwards along the concavity of the optic tract until it becomes equal in size to n. geniculatus lateralis. At that level, n. pregeniculatus appears to be separated into medial and lateral portions. It is possible that the medial and lateral portions may correspond with the internal and external parts of n. pregeniculatus of Niimi et al (1963), even though Le Gros Clark considered the *medial* part to be homologous with either n. suprageniculatus or corpus praegeniculatum of higher mammals. Farther caudally, the lateral and medial parts fuse together, and n. pregeniculatus is reduced in size, and becomes related medially to nn. peripeduncularis and subthalamicus. At this level, n. pregeniculatus lies close to the *ventral* surface of the thalamus, thus indicating that it has not yet been displaced to a more rostral and medial position by the lateral thalamic mass and n. geniculatus lateralis as in primates. Cellular divisions of n. pregeniculatus have not been observed in *Tupaia glis* or any of the other tupaioids in this study, but it has been noted that the medial portion of n. pregeniculatus is included in the subthalamic region, while the lateral part is related closely to n. reticularis.

N. pregeniculatus is not mentioned by Feremutsch (1963) in his studies on the prosimians. Bauchot (1963) describes n. pregeniculatus as n. geniculatus lateralis pars ventralis which contain small cells lying dorsal and superficial to n. reticularis; caudally, it is large, crescent-shaped structure lying ventral to n. geniculatus lateralis pars dorsalis, and parallel to the lateral surface of the thalamus. Laemle and Noback (1970) described n. pregeniculatus as one of the stations of retinofugal projections in *Nycticebus coucang* and *Galago crassicaudatus*. In these prosimians, the nucleus was described by Kanagasuntheram et al (1968), who located it ventral to n. geniculatus lateralis, medial to the optic tract and lateral to the zona incerta. N. pregeniculatus of *Galago crassicaudatus* is considerably larger than that of *Nycticebus coucang*, thus indicating a slightly less developed condition in *Galago* spp. than in other lorisoids. These authors observed large polygonal cells interspersed among small fusiform cells in this species; this cellular composition may correspond to the cytological differentiation of n. pregeniculatus as described by Niimi et al (1963) in mammals. In the present study, however, these cells have not been observed in n. pregeniculatus of *Galago crassicaudatus* or in any of the other lorisoid specimens studied here.

In spite of the abundant literature on the primate geniculate bodies, our knowledge of n. pregeniculatus is still scanty. This nucleus was first described in *Cercopithecus* by C. and O. Vogt (1909) who presumed that it was a part of n. reticularis. Minkowski (1920) proved that it was an integral part of the optic system, and contributed fibres to the superior colliculus. Balado and Franke (1938) studied n. pregeniculatus in a series of primates, and designated it as the praegeniculatum. These authors stated that n. pregeniculatus could be differentiated into a loose and a dense part, to which entirely different functions were ascribed. Architectonically, this cellular distinction has been well established in this study, as well as by other authors. Balado and Franke stated that the praegeniculatum was composed of three parts - partes grisea, fibrosa and interstitialis. The *pars griseum* contained more cells than fibres whereas the *pars fibrosa* had more fibres than cells. From those parts, small islets of cells become isolated rostralwards within the optic tract, forming the *pars interstitialis*. The pars griseum may be homologous to the lateral portion of n. pregeniculatus, while the pars fibrosus may be the circumgeniculate area and the pars interstitialis the cellular connection with the subthalamus. These parts form the medial portion of n. pregeniculatus, and correspond well with n. parageniculatus of Polyak (1957). The development of this nucleus seems to be an exclusive feature in the phylogeny of the primate lateral geniculate body. Polyak states that it appears about halfway along the longitudinal extent of n. geniculatus lateralis far behind the point at which n. pregeniculatus has disappeared. However, n. parageniculatus has not been noted in my primate material, though it may be synonymous with a part of n. pregeniculatus which is connected to the zona incerta.

My observations of n. pregeniculatus in monkey and man have shown that this structure roughly resembles a skull-cap, and is more or less triangular in shape in its rostral part. In cercopithecoids and ceboids, n. pregeniculatus is situated in the rostral part of the caudal half of the thalamus, whereas in man (and possibly, in other anthropoids), it extends only as far as the midpoint of the anteroposterior extent of n. geniculatus lateralis. In all higher primates, n. pregeniculatus occupies a dorsomedial position above the latter nucleus.

The existence of a cellular strand connecting n. pregeniculatus to the subthalamus has been confirmed in this study. Its presence lends support to the theory that at some stage in the phylogeny of the lateral geniculate body, n. pregeniculatus may have become detached, not from the geniculate region, but from the lateral part of the zona incerta to migrate to its final position. During the expansion of the pulvinar into the posterior region of the thalamus, the ventralward migration of n. geniculatus lateralis and the inversion of its layers may have caused n. pregeniculatus to move first dorsally, then dorsolaterally and finally dorsomedially, to lie above the latter nucleus as in the human thalamus.

Campus-Ortega and Hayhow (1970) described the presence of an intermediate group of cells related to both nn. pregeniculatus and geniculatus lateralis. This cellular group, which they term the intermediate geniculate nucleus (MIN), has been demonstrated in certain cercopithecoids. It may be identified with considerable difficulty in C. aethiops, and is differentiated cytoarchitectonically into a dorsal and a ventral group of cells that lie ventral and caudal to n. pregeniculatus. The dorsal group of cells lying rostral to the ventral group contains small and lightly staining fusiform cells, and is related very closely to the zona incerta and n. reticularis. The ventral group of cells is better defined than the dorsal group of the intermediate geniculate nucleus; it has larger, more darkly staining and stellate cells that lie medial to the two innermost layers of n. geniculatus lateralis (Layers 5 and 6). The intermediate geniculate nucleus has not been observed in any of my prosimian species. However, in Lemur catta, it may exist as a very small and ill-defined cluster of large, well-staining stellate cells that lie between the medial surface of n. geniculatus lateralis and nn. peripeduncularis and zonae incertae. It cannot possibly be the medial portion of n. pregeniculatus, because the latter nucleus disappears far rostral to the point where the intermediate geniculate nucleus makes its appearance. However, further examination of the intermediate geniculate mass will be necessary to establish its separate identity, as well as its relationships with the lateral geniculate body and other adjoining structures, particularly in prosimians.

SUMMARY OF THE PREGENICULATUS NUCLEUS

N. pregeniculatus is a more primitive structure phylogenetically than n. geniculatus lateralis. It is linked more closely with the subthalamus than with the dorsal part of the lateral geniculate body, which is essentially a thalamic formation. In non-primate mammals, including insectivores, it is as structurally well developed as n. geniculatus lateralis. In the Tupaioidea, it shows evident signs of phylogenetic regression which continues right through the prosimian and simian series towards man. In Prosimii, n. pregeniculatus is relatively smaller in size, and less clearly differentiated into cellular parts than those of the Tupaioidea and Insectivora. It still lies ventral to n. geniculatus lateralis, but the migration of its cells along the lateral surface of the latter structure is observed in several prosimians. In higher primates, n. pregeniculatus undergoes further reduction in size and changes its topographical position. As n. geniculatus lateralis moves ventralwards and caudalwards, n. pregeniculatus shifts to a rostral and dorsomedial position. N. pregeniculatus of higher primates may be divisible still into portions or layers of cells which show the relationships of this nucleus with the subthalamus and with n. reticularis. Its structural features, cellular and fibrous properties are summarized, together with those of nn. geniculati lateralis and medialis, in Table 21.

CHAPTER 13

THE METATHALAMUS: A. LATERAL GENICULATE BODY

2. N. Geniculatus Lateralis (LGN) (Plates 2 - 68)

A great deal has been written, and is still being up to the present time, on the comparative structure and fibre connections of the lateral geniculate nucleus in primates. In this chapter, in contrast with the previous ones, the nucleus will be described in full, taxon by taxon. Systematic comparisons will be made of the dorsoventral shift of the nucleus, lateral rotation around a rostrocaudal axis, variations in number of layers and cellular types. It is hoped that this sequence will give a clearer picture of the evolution of n. geniculatus lateralis in the Primates.

Classification of the lateral geniculate nucleus in primates:

Before the description of n. geniculatus lateralis is made, it may be useful to note the different categories of the lateral geniculate nucleus observed in my primate specimens, based on those defined by Woollard and Beattie (1927) and Campbell (1972).

Woollard and Beattie described two categories of lateral geniculate nucleus. The first category is a heterogeneous structure consisting of a dorsal laminated portion containing medium-sized and large cells, and of a ventral unlaminated portion containing scattered small cells. The second category is a homogeneous structure with a tapering dorsal elongation and a thicker ventral part; the cells are generally uniform in size and shape, and are better arranged in regular rows in the ventral than in the dorsal portion of the nucleus. The ventral portion in the first category of lateral geniculate nucleus appears to correspond with n. pregeniculatus, while the dorsal portion is definitely n. geniculatus lateralis, the degree of lamination of which depends largely on the presence of rods and cones in the retina. The second category of lateral geniculate nucleus is more commonly found in lower primates, as well as in the tree-shrews, as will be described below.

Campbell (1972) bases his classification of n. geniculatus lateralis on that of Woollard and Beattie. He classifies the lateral geniculate nucleus into two broad categories of cellular stratification as well as based on the pattern of retinal input in the nucleus. The first category includes all lateral geniculate nuclei of various mammalian groups that do not show clear cellular stratification, and have only axones from the contralateral retinae. The ipsilateral retinal projection, if present, is localized in a small portion of the nucleus, and often overlaps the contralateral projection field. The homogeneous lateral geniculate nucleus is found in most non-primate mammals, and usually contains large, pale-staining and round cells that are less compactly arranged than those of n. pregeniculatus. The second category is cytoarchitectonically definable into laminae or layers that can be more or less well separated from one another by fibrous layers. This type of nucleus is found in primates, tree-shrews and certain non-primate mammals, particularly carnivores and cetaceans.

In this study, n. geniculatus lateralis appears to fall, not into these two categories, but into five, based on cytoarchitectonic differentiation, correlated with the manner of overlapping of ipsilateral and contralateral retinal projections as postulated by Campbell. These five categories are:

Category 1

n. geniculatus lateralis is almost entirely homogeneous with no obvious signs of lamination. There is no overlapping of ipsi- and contralateral retinal projections, since the optic fibres cross almost entirely in the optic chiasma. This category is found in all non-primate mammals, including the Insectivora. However, in the latter, there may be some areas that show no terminal degeneration and in which a few ipsilateral fibres presumably terminate, e.g., Talpa (mole - Campbell 1972).

Category 2

partial lamination with an undifferentiated mass containing concealed lamination revealed by experimental methods only. The extent of overlapping of ipsi- and contra- lateral retinal projection fields is not known. Examples of this category are found in almost all ceboids, as well as in Ptilocercus (pen-tailed tree-shrew) and in certain carnivores, e.g., cat.

Category 3

complete lamination but with some degree of concealment of layers, i.e., fusion or non-separation of certain layers. This category of nucleus contains a large dorsal and a small ventral part, and is either partly or entirely inverted. There is some degree of overlapping of retinal projection fields. Examples are found in all tupaioids, lorisoids and galagids.

Category 4

complete lamination with clear, unconcealed layers. This category of nucleus has a large ventral and a small, narrow or tapering dorsal part, and is completely inverted. Examples of this nucleus are found in all lemuroids, except sportive and mouse lemurs, and in the tarsier and gibbon. There is little or no overlapping of retinal projection fields.

Category 5

general category of nucleus as found in all higher primates including man. There is complete and unconcealed lamination in the lateral geniculate nucleus which is entirely everted. No overlapping of contralateral and ipsilateral retinal projections have been experimentally investigated in these primates, since nearly all retinal fibres cross in the optic chiasma.

(1) INSECTIVORA

Macroscelidoidea

Elephantulus myurus

Observations:

N. geniculatus lateralis (Figs.35-38 RN and RR) lies dorsolateral to the lateral nucleus, and at more caudal levels, lateral to n. lateralis posterior, from which it is separated by a narrow acellular zone. Ventromedially, n. geniculatus lateralis is connected with the ventral nucleus, particularly its posterior part. N. geniculatus lateralis consists of medium-sized, moderately well staining and polygonal cells that show no signs of arrangement into laminae, and are arranged uniformly throughout the nucleus. These observations classify it as Category 1 of lateral geniculate nucleus. No lateral rotation has been observed, and the nucleus remains dorsally situated throughout its rostrocaudal extent.

Discussion:

Bauchot (1963) observed that in certain insectivore families, e.g., Talpidae and Soricoidea where the visual sense is poorly developed and the visual centres are almost atrophic, n. geniculatus lateralis is accordingly reduced in size. However, in the Macroscelidoidea, n. geniculatus lateralis is very well developed, due to the macroptic state of these ground-shrews. Bauchot points out that the progressive development of n. geniculatus lateralis is not associated with a macroptic system, for the nucleus in Elephantulus is better developed only in relative size, not in the degree of lamination, or in number of crossed and uncrossed fibres in the optic chasma, than in Sorex. Bauchot found no cellular lamination in his macroscelidoid specimens; he mentions only the presence of a crescentic layer of large, dark-staining cells lying on the lateral surface of n. geniculatus lateralis, particularly in its caudal part. This layer of cells may correspond to n. magnocellularis of the optic tract in Macroscelides and T. minor

(Le Gros Clark 1928, 1929, 1932); it can be also compared with the superficial layers (Layers 1 and 2) in the same species used here.

(2) TUPAIOIDEA

Observations:

The *lateral geniculate nucleus* (Figs. 45-50; 143-144) shows little or no structural and cytological variations in all my tupaioid specimens. This nucleus is situated caudal to n. pregeniculatus, and forms a large crescent of vertically arranged cells lying between the dorsolateral surface of the thalamus and n. lateralis. Its dorsal pole is situated rostrally and its ventral pole caudally, while the central mass between these poles lies in the concavity of the optic tract. As compared with those of insectivores and other non-primate mammals, n. geniculatus lateralis shows a more definite lamination. According to Glickstein (1967), this nucleus has *five* well developed laminae, plus one easily separable one lying immediately adjacent to the optic tract. This sixth layer, termed Layer "S" by Glickstein, has been observed in all my tupaioid specimens; it is a thin layer of small, darkly staining, spindle-shaped cells (too few and too diffusely arranged for measurement), and it has a much shorter caudal extension than the other layers.

Layers 1 and 2 of n. geniculatus lateralis face medially and inwards, and are composed of large, well-staining, stellate cells that can be separated fairly easily from each other by a thin, fibrous layer (Layer 1 - 17 x 12 $/^{u}$; Layer 2 - 16 x 12 $/^{u}$). Layers 3 and 4 are the thickest of all layers, and contain respectively small and medium-sized, very lightly staining, round or polygonal cells (Layer 3 - 17 x 12 $/^{u}$; Layer 4 - 16 x 11 $/^{u}$). These cells are arranged more compactly in the third than in the fourth layer. Layer 5 is the broadest of all the layers in the nucleus; it consists of mostly medium-sized, round cells (15 x 10 μ) that stain more darkly than Layers 3 and 4, but less than those of Layers 1 and 2.

The tupaioid lateral geniculate nucleus shows a definite arrangement into 5 or 6 layers, although some layers are well concealed, particularly Layer 5 which is too dense to be separated into two layers comparable with Layers 5 and 6 of other authors (see below). It is not clear whether the superficial layer (Layer "S") can be demarcated from Layer 1 throughout the entire extent of the latter layer, or whether it merely forms a small separable segment along the most dorsalward part of Layer 1.

In the Tupaioidea, n. geniculatus lateralis occupies the most rostral position in the thalamus, lying dorsal even to nn. laterales dorsalis and posterior; it lies below the dorsal surface of the thalamus. Caudad, n. geniculatus lateralis elongates in both directions, particularly ventralwards, and there becomes more clearly laminated. This ventralward shift is due to the expanding bulk of n. lateralis lying *above* it, and farther caudally, to n. pretectalis that lies dorsal to n. geniculatus lateralis and n. lateralis posterior. When the pulvinar appears, n. geniculatus lateralis is already a large, well laminated lenticular nucleus. Farther caudally, n. geniculatus lateralis reduces in size, being encroached upon by the pulvinar, but it remains more or less clearly laminated in appearance. As n. geniculatus medialis makes its rostral appearance, n. geniculatus lateralis becomes smaller. The innermost layers are the first to disappear, forming the medial border of n. geniculatus lateralis; the outer layers become indistinguishable from each other, and form a homogeneous mass of rather large, more lightly staining, oval cells resembling those of the pulvinar. Finally, n. geniculatus lateralis disappears at the level of the superior colliculus.

Discussion:

In his comparative study of the lateral geniculate nucleus in Primates, Glickstein (1967) follows the system of numbering laminae devised by Feremutsch (1963) and Tigges (1966); the laminae are numbered, from medial to lateral, 1 through 5. He was able to distinguish a sixth layer adjacent to the optic tract. It differs from Layer 5 by the arrangement of its cells which are small, spindle-shaped and packed more compactly along the lateral surface of Layer 5. However, Glickstein does not regard the sixth layer as a true lamina of the lateral geniculate nucleus, and he designates it as Lamina "S", because its cells are arranged too diffusely among the fibres of the optic tract as to compare well with the other layers. All the five layers, including Layer "S" have been observed in the tree-shrew specimens used in this study. Therefore, the number of laminae recognized in the lateral geniculate nucleus of Tupaia glis, as well as in other Tupaia spp., should be given as five, possibly even with a sixth layer (Glickstein's Layer "S") lying, as the most superficial layer, between Layer 1 and the fibres of the optic tract.

In Tupaia minor Le Gros Clark (1929) showed that n. geniculatus lateralis is situated in the dorsolateral region of the thalamus, and appears to have four distinct cellular layers, two lateral and two medial. Each of these layers is composed of large and polygonal cells, and between these layers, is a central core of small, round cells. Farther caudally, n. geniculatus lateralis is pushed down to a more ventral position by the increasing bulk of n. lateralis posterior lying above it, and caudally by n. pretectalis. The caudal extremity of n. geniculatus lateralis is situated immediately dorsolateral to the rostral part of n. geniculatus medialis. These relations correspond well with those in the same species used in this study. Le Gros Clark did not describe in Tupaia minor a fifth layer, which may have been aligned too closely on the fourth layer, so that he could not distinguish those two layers. The 'central core of small round cells' may represent Layer 3, and the 'ventral crest of large cells of Kornyey' is possibly equivalent to the superficial or sixth layer of Glickstein.

Bauchot (1963) made a detailed examination of n. geniculatus lateralis in Tupaia glis, and found that there is a large difference in the structure of this nucleus between the Insectivora and Tupaioidea. In Tupaia glis, both optic chiasma and tracts are larger in size than in insectivores, and consequently, n. geniculatus lateralis shows a marked increase in size, as well as a beginning of cellular arrangement into definite layers. Bauchot states that there are no actual dorsal and ventral lateral geniculate nuclei, only a rostrally placed parvocellular nucleus which is homologous to n. pregeniculatus, and a caudally situated magnocellular nucleus that acquires such structural and functional importance as to merit the name of the lateral geniculate nucleus in primates. According to this author, n. geniculatus lateralis of Tupaia glis is composed of four cellular layers that alternate with four fibrous layers. These layers are arranged parallel to the optic tract laterally and to the external medullary lamina medially. Two of the cellular layers which consist of large cells correspond to Layers 1 and 2 (most lateral layers), and the other two layers contain mostly small cells, and correspond to Layers 3 and 4. The fifth layer (Layer 5) observed in my Tupaia glis specimens, has not been described by Bauchot, although he reports the presence of a layer lying between Layer 1 and the optic tract fibres. This layer may correspond to the actual first layer, or to Glickstein's Lamina "S". Therefore, if Bauchot meant that there are five, not four, layers in the lateral geniculate nucleus of Tupaia glis, then this layer should be termed Layer 1, and other medially related layers from Layer 2 through Layer 5.

Bauchot (1963) mentioned that there is a dorsoventral shift in Tupaia glis, and also a horizontal orientation of n. geniculatus lateralis in C. demidovii. Glickstein (1967) did not make any statement about those features in his tupaioid specimens. It has been observed in this study that the nucleus goes through a slight rotation between 0° and 10° along its rostrocaudal extent. This marks the beginning of changes in position correlated with the stratification of cells into definite layers, and with the development of stereoscopic vision in primates.

3. PRIMATES

(1) PROSIMII

(a) Lemuroidea

(i) Microcebus murinus

Observations:

The degree of lamination is more evident in this lemuroid than in the Tupaioidea, but it is more primitive and less clearly definable than that of the Galagidae. In Microcebus murinus, n. geniculatus lateralis (Figs. 57-60; 145-146) occupies a ventrolateral position in the thalamus. At the level where there are clear signs of lamination in the nucleus, n. geniculatus lateralis elongates in a dorsalward direction. Its dorsal part stretches along the medial surface of the internal capsule to reach the dorsal surface of the thalamus just beneath the caudate nucleus and to lie lateral to n. pulvinaris superior. As n. geniculatus lateralis attains its maximal size, the stratification of its cells into layers becomes much clearer. There are six laminae: two outer magnocellular layers (Layers 1 and 2); two small-celled layers (Layers 3 and 4) in the middle, and two inner medium-sized cellular layers (Layers 5 and 6) facing medially towards the ventrolateral thalamic nuclear group. All these laminae are dorsoventrally disposed with a lateral convexity and a medial concavity, thus showing the typical lemuroid inversion pattern. Layers 1 and 2 have much larger and more deeply staining cells than are found in other layers. Also, the relative proportion of large to small cells appears to vary with the differentiation of parvocellular layers in transverse sections of the lateral geniculate nucleus. In the middle third of the thalamus, small cells appear to predominate, and in the caudal part of the thalamus, large cells outnumber small cells. The magnocellular layers (Layers 1 and 2) extend over the entire convex lateral surface of the nucleus, curve around its ventral border to reach the ventromedial surface of the same nucleus, and increase in length towards its caudal end. Some fibres of the optic tract enter directly into the two innermost layers (Layers 5 and 6), while most fibres run along the lateral and dorsal surfaces of the thalamus to enter medially into the outer layers. At more caudal levels, n. geniculatus lateralis is shifted to a more *dorsal* (not ventral as in other primates) position by the expanding medial geniculate nucleus, and finally by the mesencephalic tegmentum. There, n. geniculatus lateralis lies lateral to the pulvinar, and is replaced by n. pulvinaris inferior at the level of the rostral region of the superior colliculus.

The lateral geniculate nucleus of *Microcebus murinus* appears to belong to Category III. In spite of its definite stratification into six layers, Layers 5 and 6 are not easily separated from each other at all levels. The degree of its lateral rotation has been calculated from the stained serial sections and photomicrographs; it varies between 0° and 15°, which is comparable to that of the same nucleus in the Tupaioidea. Therefore, *Microcebus murinus* has the most primitive type of lateral geniculate nucleus in the whole Primate Order.

Discussion:

Le Gros Clark (1931) observed that the lateral geniculate nucleus of *Microcebus murinus* was larger and more highly differentiated than that of *Tupaia minor*; it consists of six concentrically arranged cellular layers separated from one another by well defined medullary laminae. The outer layer is very thin and contains only small cells; it corresponds to Layer 1 of the typical arrangement in Primates. The second outer layer consists of larger and more deeply staining cells, and corresponds to Layer 2. The other inner or medial layers, containing small and medium-sized cells, homologize with Layers 3 to 6.

Chacko (1948) observed in *Microcebus murinus* that the deepest lying laminae (Layers 5 and 6) are composed of densely packed, small cells, and at their ventral ends, these layers tend to crinkle into small convolutions, and are slightly everted, which do not, however, show up well in my specimen.

Feremutsch (1963) observes that the position of n. geniculatus lateralis of *Microcebus murinus* is dorsal and lateral, and in transverse sections, it shows a bent form with a medial convex surface and a lateral concave surface which forms a part of the dorsolateral surface of the thalamus. As Feremutsch rejects the concept of cellular division in all thalamic structures, and such a stratification of cells in the lateral geniculate nucleus is not possible, he regards the latter nucleus as a monomorphous and anisoformic structure. However, he admits that there is a differentiation of cells into large and small elements in n. geniculatus lateralis, thus affirming the cellular differentiation into parvocellular and magnocellular layers in *Microcebus murinus*.

(ii) *Lemur spp.*

Observations:

N. geniculatus lateralis shows a more remarkable phylogeny in *Lemur* than in *Microcebus* and *Tupaia*. In all three *Lemur* specimens studied here, the position of this nucleus is *ventral* with a slight inclination towards the dorsal surface, forming the tip or 'handle' of the lateral geniculate nucleus. The nucleus is situated mainly in the caudal third of the diencephalon. It commences at the level of, or slightly rostral to, the habenular complex, extends further towards the caudal end of the thalamus, and ends rostral to n. geniculatus medialis at the level of the commissure of the superior colliculus.

The size and shape of the lateral geniculate nucleus varies considerably among the members of the Lemuridae studied here. In Lemur catta, n. geniculatus lateralis (Figs.79-84; 153-154) is generally club-shaped, its broader end points medially and its body tapers lateralwards into a slender, rather sharp tip that curves along the medial surface of the external medullary lamina towards the dorsal surface of the thalamus. The dorsal surface of the innermost layer (Layer 6) is very serrated. The two inner layers (Layers 5 and 6) are not easily demarcated from each other. In its rostral extent, n. geniculatus lateralis is arranged in two separate masses of cells. One of these masses is medially situated and lies dorsolateral to n. pregeniculatus; it contains small, pale-staining round cells that identify it as comprising Layers 3 and 4 together. The other mass contains large, dark-staining, stellate cells that separate gradually into two layers which lie ventral to the first mass - Layers 1 and 2. Caudad, n. geniculatus lateralis attains its maximal size and full stratification. As the habenulopeduncular tract runs towards the peduncular region of the midbrain, n. geniculatus lateralis decreases in size, its surfaces are smoothed out all around, and the nucleus resembles a lozenge or a rectangle with rounded off edges. The fifth and sixth layers merge with each other to form one continuous layer, while the third and fourth layers form a pale-staining, homogeneous mass in the centre. The first and second layers remain more or less indistinctly separated from each other. Towards the caudal end, n. geniculatus lateralis disappears at the rostral level of the mesencephalic nucleus of the trigeminal nerve.

The lateral geniculate nucleus of Lemur fulvus (Figs.149-150) is much larger and more crumpled with better defined layers than those of Lemur catta and Lemur macaco The dorsal surface of n. geniculatus lateralis is irregularly saw-toothed, and its ventral surface is smooth and faces the optic tract. As in Lemur catta, n. geniculatus lateralis appears in two separate masses; one lies ventral to n. pregeniculatus and dorsal to the other mass which may contain cells belonging to Layers 1 and 2. At the level of its maximal size, n. geniculatus lateralis is shaped like a concertina with its serrated dorsal surface wedged between the medial and lateral aspects of the nucleus. Towards the caudal end of the thalamus, n. geniculatus lateralis smoothens into a boat-shaped structure with all layers remaining clearly defined.

The lateral geniculate nucleus of Lemur macaco (Figs. 151-152) resembles more that of Lemur catta than that of Lemur fulvus, but the shape is like a comma with a thick tail which is directed higher up dorsally. It commences also as two separate cellular masses; one dorsomedial and the other ventrolateral. The dorsal surface of n. geniculatus lateralis is serrated, but to a lesser degree than in Lemur fulvus.

The topographical relations of n. geniculatus lateralis are the same in all three Lemur specimens. Medial to the nucleus, are nn. pregeniculatus and pulvinaris inferior dorsally, and then n geniculatus medialis ventromedially and n. peripeduncularis ventrally. Lateral to n. pregeniculatus lies the hippocampus; dorsal is the caudal part of n. ventral posterolateralis, n. pulvinaris inferior, and then n. pulvinaris superior, while ventral to it are the fibres of the optic tract.

The positions of the hilus and optic radiation are both dorsal; in Lemur fulvus, they are slightly dorsal; in Lemur macaco, the hilus leans slightly towards the medial side. In all Lemur specimens, it has been noted that n. geniculatus lateralis goes through a rostrocaudal rotation from 80° to 90°, i.e., a marked displacement from its former cranial situation in the thalamus at the rostral level of the lateral nucleus, as in the Tupaioidea, to a more caudal place in the thalamus at the rostral level of the habenular complex as in higher primates.

In all *Lemur* specimens, the number of laminae are six: Layers 1 and 2 are magnocellular whereas Layers 3, 5 and 6 are mediocellular and Layer 4 is parvocellular. In regard to the cellularity of the latter four layers, it would be more convenient to define them all as parvocellular, no matter how much larger the cells in one layer are than in the other layer. Cytological details of these layers are as follows:

Layer 1 is distinctly separated from Layer 2 by a thick fibrous band. Its cells are mostly large (20 x 15 μ) and they stain well with small, round Nissl granules in the cytoplasm, and are arranged in loose rows.
Layer 1 in *Lemur catta* appears to be smaller than Layer 2 in its mediolateral extent, and joins the latter layer at the base of the tail of the nucleus. In *Lemur fulvus*, the cells of Layer 1 are more compactly arranged on its medial than on its lateral side. Layer 1 is thicker than Layer 2. In *Lemur macaco*. Layer 1 is thicker and longer than Layer 2, even extending right into the tip. The cells are large, well-staining and are arranged less densely than those of Layer 1 in other lemurs.

Layer 2 contains large, dark-staining cells (20 x 15 μ) that are arranged more regularly in neat rows than those of Layer 1. In *Lemur macaco*, Layer 2 is shorter than Layer 1, but is much longer in *Lemur catta* and *Lemur fulvus*.

Layer 3 contains more medium-sized than small or large cells (15 x 11 μ) that stain better than those of Layer 4, but not as darkly as those of Layers 1 and 3.
In *Lemur catta*, Layer 3 is not well demarcated from Layer 4, but a thin fibrous layer intervenes between these layers. In *Lemur fulvus* and *Lemur macaco*, this demarcation is formed by a thicker fibrous band.

Layer 4 is thicker and more massive, particularly in its rostral and caudal parts. It is more fibrous than cellular. The cells are mostly small (14 x 11 μ), pale-staining, round and are not arranged as regularly as in other layers. This layer forms the 'central core' of the nucleus. It can be separated from Layer 5 with considerable difficulty, but the darker staining appearance of the latter layer betrays its presence. Layer 4 continues farther dorsally into the tip where it merges with Layers 1 and 2.

Layer 5 is very crenated in all Lemur species. It is not well demarcated from Layer 6, because these layers have similar cellular features. The cells of Layer 5 stain less intensely than those of Layer 6, and are relatively smaller in size (15 x 11 μ) than those of Layers 1 and 2; these cells are arranged more compactly and extend far into the tip forming its dorsomedial surface.

Layer 6 is also crenated in all Lemur species, and spreads out more thinly along the dorsomedial surface of Layer 5. Layer 6 does not extend much farther laterally than Layer 6, and is, therefore, smaller and narrower than all other layers. The cells of Layer 6 are slightly larger (16 x 12 μ), stain more darkly and larger than those of Layer 5, particularly in Lemur fulvus.

Finally, the lateral geniculate nucleus in all these lemurs is invariably Category 4 of classification of primate lateral geniculate nucleus, although there is some degree of concealment of the two innermost layers (Layers 5 and 6); Layers 3 and 4 are not very clearly demarcated from each other in some places.

Discussion:

Chacko (1948, 1954) showed the lateral geniculate nucleus of Lemur fulvus to be a somewhat irregularly shaped, roughly oval structure with an excavated rostral surface; the main mass of the nucleus is composed of lateral and medial parts. The lateral part shows a pattern of 'inversion' of its laminae, and is continued into the medial part in which a pattern of eversion is manifested. 'Seen from anteriorly, the irregular anterior surface is marked by a large cavity which is bounded ventrally and laterally by the rostral lip prolonged forwards from the lateral part, and posteromedially by the rostral prominence of the medial part of the main mass of the body'. This description of Chacko fits that of the tapering part of n. geniculatus lateralis that extends dorsalwards along the lateral surface of the thalamus in the same lemur specimen used in this study. The laminar pattern of *Lemur fulvus* resembles generally that of *Microcebus murinus*, but the laminae are more elaborately folded in an inverted manner.

Woollard and Beattie (1927) observed that *Lemur fulvus* had *four* laminae in its lateral geniculate nucleus, but Chacko (1954) and I have been able to identify *six* layers in the same lemur. My description of the lateral geniculate nucleus in this specimen confirms that of Chacko more than that of Woollard and Beattie. At the level where Layers 4 and 5 appear to be a poorly separable layer containing small and medium-sized cells, Woollard and Beattie possibly took n. geniculatus lateralis of *Lemur fulvus* to be a four-layered structure. In all Lemur specimens, n. geniculatus lateralis shows a lateral rotation about a rostrocaudal axis from a vertical position as in *Microcebus murinus* and *Lepilemur* to a horizontal disposition on the ventral surface of the thalamus. Therefore, in all lemurs, the nucleus appears to have rotated through almost a right angle, that is., from 0° vertically to 90° horizontally, but in the dorsal portion of the lateral geniculate nucleus, the layers show an inclination of 60° to the vertical plane. In most primitive lemuroids, such as *Microcebus*, *Lepilemur* and *Propithecus*, the angle of rotation is only between 10° and 20°. It is obvious that these morphological changes in the nucleus are more evident in the Lemuroidea than in any other primate group, i.e., a much clearer definition of six layers and a gradual change of inversion to eversion in the lateral geniculate nucleus are found in lemurs than in other primates.

Solnitzky and Harman (1946) regard *Lemur mongoz*, not *Perodicticus potto* and *Galago demidovii*, as a representative of true lemurs. Those authors were able to show that there is a shift from the strict nocturnal state observed in the two latter specimens towards the diurnal state, the degree of which, however, varies among different lemurs. In several of the *Lemur* species, studied by Solnitzky and Harman, *Lemur catta* appears to be the only diurnal animal, while *Lemur macaco* and *Lemur fulvus* are either crepuscular or both diurnal and nocturnal. According to Walls (1953), there is no relationship between nocturnality and geniculate layering, since there are several prosimians which do not have a colour vision, but their lateral geniculate nuclei have generally six layers, e.g., *Lemur mongoz*, *Microcebus*, *Galago* and *Perodicticus*. Hassler (1966) finds, in his studies of primates, that the magnocellular, not the parvocellular, laminae are larger and contain greater numbers of cells in *nocturnal* as compared with *diurnal* forms. In his transneuronal cell degeneration studies, Jones (1964) identified only *four* laminae in *Aotes*, a nocturnal ceboid (platyrrhine monkey), while other workers find six or seven laminae in diurnal ceboids (*Saimiri* - Doty et al 1966; Tigges and Tigges 1969; *Ateles* - Jones 1964; Giolli and Tigges 1970). These findings seem to support Walls's theory that the number of layers in the lateral geniculate nucleus does not correlate with nocturnal or diurnal habits of the prosimians.

(iii) *Lepilemur*

Observations:

N. geniculatus lateralis of this lemuroid (Figs.67-70; 147-148) is uniquely primitive in structure, resembling that of *Microcebus* more than that of *Lemur*. N. geniculatus lateralis occupies the entire lateral surface of the thalamus, and is not shifted ventrally. There are five laminae, which are not well demarcated from one another. One or two outer layers are magnocellular, while three inner layers are medio- or parvocellular. Layer 1 is not clearly separated from Layer 2; Layer 1 can be identified by its more compactly arranged and darkly staining cells. Layer 3 is a broad layer consisting of small, pale-staining and loosely arranged cells. Layers 4 and 5 are delimited somewhat indistinctly from each other; they are composed of medium-sized, well-staining, fusiform cells that are arranged mediolaterally in neat rows. The optic tract enters the lateral geniculate nucleus on its lateral aspect, while the fibres of the optic radiation come out its medial convex surface. N. geniculatus lateralis is well encapsulated by fibres on all sides, and is clearly delimited in its rostral region from n. pregeniculatus. The fibrous strata do not demarcate the cellular laminae well from one another, and therefore, the entire nucleus appears to contain a dense network of fibres running lateromedially from the optic tract. The lateral geniculate nucleus of Lepilemur appears to belong to Category II rather than to Category III or IV of lateral geniculate nuclear classification.

Discussion:

The lateral geniculate body of Lepilemur (and of Propithecus) have been described very briefly only by Feremutsch (1963), who found that this structure in these two species compares more favourably with that of Microcebus than with those of Lemur and Loris, and even that of Tupaia. Though Feremutsch regards the lateral geniculate nucleus of Lepilemur to be a monomorphous and anisoformic structure without any definite stratification of cells, similar to that of Microcebus, it has apparently five laminae, the sixth layer being possibly fused with, or not well separated from, the fifth layer.

(b) Lorisoidea

(i) Perodicticus potto

The lateral geniculate nucleus of this prosimian (Figs. 93-96; 155-156) is more primitive in both topographical situation and in the degree of lamination than those of Lemur, and resembles more closely those of Tupaia and Microcebus.

N. geniculatus lateralis commences at the junction of the rostral one-third with the caudal two-thirds of the thalamus, i.e., at the level of the rostral region of the centrum medianum/parafascicular complex. Farther caudally, n. geniculatus lateralis assumes a more definite shape. There, it is more or less clearly divided into *six* layers, but these layers are not as well arranged as those of *Lemur*. The two outermost layers (Layers 1 and 2) are fused almost closely so that they appear as one layer; only the larger size and more intense staining of the cells of layer 1 distinguish them from those of Layer 2 which are mostly medium-sized and are arranged more compactly in rows. Layers 3 and 4 are more or less undifferentiated, and are ill-defined, thick layers of small, pale-staining round cells that are slightly separated from each other by a very thin layer of fibres. Further caudally, layers 3 and 4 become better differentiated cytologically and cytoarchitectonically from each other. The cells of Layer 3 are smaller, more lightly staining and polygonal than those of Layer 4, whose cells are arranged more loosely in a broader layer. A thick, fibrous layer separates these two layers from each other, and Layer 4 is applied quite closely to the ventral surface of Layer 5. Layer 5 is the thickest of all layers, and consists of closely arranged fairly well staining, round or oval, medium-sized cells arranged along the medial contour of the lateral geniculate nucleus. Layer 6 is rather poorly defined, and can be demarcated with difficulty from Layer 5, to whose dorsal surface it is applied very closely. However, the cells of Layer 6 are smaller and more darkly staining, and they are arranged more compactly in one or two rows than are those of Layer 5. At the level of its maximal size, n. geniculatus lateralis is very well stratified and its constituent layers are separated from one another by fibrous strata.

In *Perodicticus potto*, n. geniculatus lateralis is shaped more or less like a truncated pyramid; the apex is directed dorsally, and the base lies ventral to the dorsal surface of n. geniculatus medialis. The medial surface of n. geniculatus lateralis is smooth, but at the level of the habenulopeduncular tract, it becomes contoured, so that the nucleus appears to face slightly more dorsally than medially. Generally this nucleus occupies an almost perfectly lateral position as compared with the ventrally disposed lateral geniculate nucleus of *Lemur*. It is slightly ventrally directed in its dorsoventral shift, and does not possess a clear-cut hilus. By all these observations, the lateral geniculate nucleus of *Perodicticus potto* is classified as Category III of nucleus in primates.

Discussion:

Woollard and Beattie (1927) gave such a very brief account of the lateral geniculate nucleus in *Perodicticus potto* that it is inadequate to make any comparisons in this study. Those authors did not give a definite number of layers, because they considered the nucleus of this species to be poorly laminated, as compared with other prosimians. However, in *Perodicticus potto*, Solnitsky (1945) found a structurally primitive mass with six inverted, curvilinear and vertically arranged cell layers, five large and one small, without any indication of a central mass as seen in *Lemur*. Chacko (1954) also commented on the primitive morphology of the lateral geniculate nucleus in *Perodicticus potto*. In most of the rostrocaudal extent of n. geniculatus lateralis Chacko was able to identify *four* laminae, but in its caudal part, two extra layers were observed, thus bringing the total number of laminae to *six*. All the layers, except the middle ones, are magnocellular, and arranged in such a concentric manner that the lateral convex surface of the nucleus is directed towards the lateral surface of the thalamus. The small-celled layers (Layers 3 and 4) are contained within the concavity of the superficial layers (Layers 1 and 2). This laminar pattern conforms with the inversion pattern of the prosimian lateral geniculate nucleus, although the description of its morphology in this study is slightly different from that of Chacko. N. geniculatus lateralis of *Perodicticus potto* is definitely located in the dorsal half of the diencephalon, and it represents a rostromedial concavity from which issue fibres of the optic radiation. The laminae are inverted with the parvocellular layers arranged concentrically within the concavity of the two peripheral magnocellular layers. In the ventromedial portion of the lateral geniculate nucleus, the parvocellular layers show greater development, resulting in folding in the opposite direction and consequently a local 'eversion' pattern. Thus, the lateral geniculate nucleus shows a combination of 'inversion' and 'eversion' patterns, the latter being of varying degrees of development from *Perodicticus* through all higher prosimians to *Lemur*. The lateral geniculate nucleus of *Perodicticus* potto resembles more closely that of *Lepilemur*, *Microcebus*, and *Tupaia* than that of *Lemur*, and is regarded as Category III rather than Category IV of primate lateral geniculate nucleus.

Among other lorisoid specimens studied outside this investigation are *Loris tardigradus* (Feremutsch 1963, Hassler 1966), *Nycticebus coucang* (Kanagasuntheram et al 1968, Laemle and Noback 1970), and *Loris gracilis* (Chacko 1948, 1954). N. geniculatus lateralis of *Loris gracilis* (Fig.159) is comma-shaped, like that of *Galago crassicaudatus*. The main bulk of this nucleus forms the *medial* part of what is disposed in a nearly horizontal manner in the thalamus. Its *lateral* part continues dorsalwards in a 'tapering' tail, i.e., it is bent at right angles to the body, and lies parallel closely to the middle third of the lateral surface of the thalamus. The outer convex surface of n. geniculatus lateralis is shaped by the fibres of the optic tract that run along the entire lateral surface of the thalamus towards the pretectal area and n. tractus opticus. The inner concave surface of the lateral geniculate nucleus is formed by the dorsal surface of its 'body', while the medial surface of its 'tail' presents an excavation that is characteristic of the nucleus in all prosimians, and from which the fibres of the optic radiation emerge. The 'tail' is convex laterally and grooved medially. Six laminae are present in *Loris gracilis*, *Loris tardigradus* and *Nycticebus coucang*. Layers 2, 3 and 4 appear to fuse into one layer while Layers 5 and 6 merge with each other. These fusions are more apparent in the tail than in the body. The laminae of the nucleus lie in a curve dorsal and lateral to the concave surface of the nucleus, while the convex shape is followed closely by the cells of Layer 1. The other laminae, Layers 2 to 6, are arranged concentrically, each lying along the concave surface of the preceding layer. This laminar pattern of the lorisoid lateral geniculate nucleus, therefore, belongs to the inverted type with a considerable degree of eversion, and the nucleus itself falls within Category III of lateral geniculate nuclear classification. Moreover, it is inferred from the above observations that the lateral geniculate nucleus of Loris and Nycticebus resembles more that of Lemur than that of Perodicticus, thus placing Loris in the intermediate position between the lemuroids and galagids in the phylogenetic development of the lateral geniculate nucleus.

(ii) Galagidae

Observations (A) Galago demidovii

In this species, n. geniculatus lateralis (Figs.157-158) is situated in a more ventral position than in Microcebus murinus and Perodicticus potto, but it does not show a clear stratification of its cells as in Microcebus. Six laminae can be observed - two magnocellular (outer) layers directed ventrally and laterally, two innermost layers (Layers 5 and 6) facing dorsally and medially, and the two inner layers (Layers 3 and 4) forming a 'central mass' of small, lightly staining, round cells. The optic tract ends mostly on the ventral surface of n. geniculatus lateralis. This nucleus is dome-shaped, resembling more or less those of Lemur species, and showing the inverted pattern, more strongly than the everted, as in Perodicticus potto. The degree of lateral rotation is from 60° to 80°, with an angle of 20° from dorsal to ventral. In its ventralward shift, n. geniculatus lateralis lies ventrolateral to n. pulvinaris inferior.

(B) *Galago senegalensis*
and (C) *Galago crassicaudatus*

In these two *Galago* species, n. geniculatus lateralis (Figs. 101-104; 111-116) is identical topographically, structurally and cytologically. The nucleus commences, at the level of the middle region of the thalamus, as a collection of dark and light-staining cells arranged in two outer and inner layers respectively. At the level of the habenulopeduncular tract, n. geniculatus lateralis is fully formed. Its layers show lateral rotation from 60° to 90°, when traced to the caudal region of the thalamus. In *Galago crassicaudatus*, the hilus of n. geniculatus lateralis points more dorsolaterally than dorsomedially as in other two *Galago* spp.

In both *Galago* species, *five* laminae are observed. Layer 1 consists of medium-sized cells (16 x 10 μ) that are dark-staining and fusiform in shape. Layer 2 has smaller and more oval cells (14 x 9 μ). Layers 3 and 4 are well demarcated from each other by a wide fibrous band (similarly, a narrower band of fibres separates Layer 3 from Layer 2). The cells in Layer 3 are smaller (13 x 10 μ), stain more lightly and are more polygonal than those of Layer 2. The cells of Layer 4 are slightly larger (14 x 12 μ), and are scattered loosely in a small band that lies rather close to Layer 5. Layer 5 is more distinct than Layers 3 and 4; its cells are mostly medium-sized (15 x 11 μ), stain rather darkly and are stellate. Several large, dark-staining, spindle-shaped cells are observed to lie along the dorsal aspect of Layer 5; they are possibly the cells of Layer 6. Both layers are long and thick cellular bands following closely the dorsomedial and medioventral contours of the lateral geniculate nucleus.

Farther caudally, n. geniculatus lateralis is reduced in size, until at the level of nn. pretectalis and tractus opticus, the former nucleus is replaced partly by n. pulvinaris inferior and partly by the medial geniculate nucleus. Generally, the lateral geniculate nucleus of all the three *Galago* species belongs to Category III of the primate lateral geniculate nucleus.

Discussion:

Woollard and Beattie (1927) and Kanagasuntheram et al (1968) reported the presence of *five*, not six, laminae in the lateral geniculate nucleus of both *Galago senegalensis* and *Galago crassicaudatus*. However, Laemle and Noback (1970) and Campos-Ortega and P.Glees(1967) describe a six-layered structure in *Galago crassicaudatus*, as well as a seventh layer that lies ventral to the *first* layer in the medial third of the caudal part of the nucleus. This seventh layer may be homologized to Glickstein's Lamina "S" in *Tupaia*. The odd lamination has been reported also in the same *Galago spp.* e.g., Lamina "O", by Tigges and Tigges (1969) and Giolli and Tigges (1970). In my *Galago* spp., this superficial layer has not been recognized, even in the region specified by these authors. However, even if more than five laminae are present in the galagid lateral geniculate nucleus, and if Layer 4 actually consists of two sublayers, each containing fibre projections from different eyes (Ionescu and Hassler 1968), the layers are enumerated 1 to 5. Therefore, it is apparent that the lateral geniculate nucleus of *Galago crassicaudatus* may present an example of incipient extra lamination. This leads to the assumption that there may be more than six laminae in all primate species, as accepted generally in the literature. *Galago demidovii* and *Nycticebus coucang* each possesses a six-layered lateral geniculate nucleus (Solnitzky and Harman 1946, Kanagasuntheram et al 1968, Laemle and Noback 1970). Bauchot (1963) describes a *four* layered lateral geniculate nucleus in *Galago demidovii*, in which Layer 3 seems to be a redoubled layer. Laemle and Noback (1970) observed that in *Galago*, the laminae are shaped like arcs with a slight dorsal concavity which makes an angle of approximately 60° with the median plane of the brain-stem. On the other hand, the laminae show a gradual change from *inversion* in the dorsal and lateral regions to eversion in the ventral and medial regions of the lateral geniculate nucleus, but remain generally inverted.

(c) Tarsioidea

According to Le Gros Clark (1930), the lateral geniculate nucleus of Tarsius (Fig. 160) is a remarkably large, oval-shaped structure that lies on the lateral and ventrolateral aspects of the thalamus with its long axis directed caudocentrally. It is deeply excavated in the shape of a "C", the rim of which is turned in from the lateral aspect. There are three laminae, one peripheral and two central. The peripheral layer is distinct and better demarcated cyto- and myelo-architectonically than the central layers. The latter layers which fill up the centre of the nucleus, are broader than the peripheral layer, and consist of large and pale-staining cells. The optic tract fibres reach the nucleus at its ventromedial pole; a few of them extend to n. pregeniculatus that lies dorsal to it. Despite the aberrant development of the lateral geniculate body in Tarsius, the lateral geniculate nucleus is related more closely to that of the Anthropoidea than to the Lemuroidea. Moreover, the nucleus exhibits a marked eversion of the medial or central laminae, which are convex mediodorsally, and extend over the lateral aspect of the nucleus. The fibres of the optic tract enter entirely into the ventromedial pole of n. geniculatus lateralis while the fibres of the optic radiation emerge from the rostrally and medially situated hilus of the same nucleus. The peripheral lamina of the tarsiid lateral geniculate nucleus may correspond to the central mass of the simian lateral geniculate nucleus, but there is no element in Tarsius which can be homologized with certainty to the large-celled layers (Layers 1 and 2) in the anthropoid lateral geniculate nucleus. In Tarsius, however, Le Gros Clark observed large cells lying on the dorsal aspect of the nucleus; he termed that layer "pars magnocellularis" of the lateral geniculate nucleus. These cells may be a localized specialization of the peripheral lamina. The tarsiid lateral geniculate nucleus is of enormous size, dominating the entire caudal and ventral regions of the diencephalon. It forms such a prominence on the lateral thalamic surface that it displaces the medial geniculate body to a more rostral and ventral position and comes to be related closely to the pulvinar surrounding the metathalamic structures.

(2) ANTHROPOIDEA

(a) *Cercopithecoidea*

Cercopithecus aethiops

Observation:

The lateral geniculate body of this species (Figs. 119-128; 163-164) corresponds almost identically with that of other simian primates, though there are considerable variations in size, shape and topographical position among anthropoid species.

N. geniculatus lateralis of *Cercopithecus aethiops* is composed of six layers arranged concentrically around the fibres of the optic tract that enter the nucleus through the hilus on its ventral surface. On the dorsal surface of n. geniculatus lateralis is a dense fibrous layer - the fibres of the optic radiation. The laminae of n. geniculatus lateralis are arranged with alternating layers of cells and fibres in a ventromedial to dorsolateral direction. The two ventrally situated layers (Layers 1 and 2) consist of large, very dark-staining, stellate cells arranged in irregular rows orientated in a mediolateral direction (Layer 1 - 18 x 8 μ; Layer 2 - 19 x 11 μ). The other four layers (Layers 3 to 6) laying above the magnocellular layers are mostly small and medium-sized, light staining and oval or polygonal, and are arranged in a more regular manner than those of Layers 1 and 2 (Layers 3 and 4 - 15 x 9 μ; Layers 5 and 6 - 13 15 μ). Layer 6 is thicker and is arranged like a dome over the other layers. A thin strand of large, dark-staining, fusiform cells lies around the hilus between Layer 1 and the optic tract, particularly in the middle region of the nucleus. This layer may be homologous to Glickstein's Lamina "S" or to Tigges's Lamina "O", and the number of layers may be brought up from six to seven. However, supernumerary layers, due to splitting of Layer 3 or Layer 4 have not been observed in *Cercopithecus aethiops*. The lateral geniculate nucleus is completely everted with a definite lateral rotation of *more than* 90°, i.e., 110°, as the hilus appears to point more ventromedially than dorsolaterally, i.e., towards the medial regions of the thalamus than it does in lower primates. N. geniculatus lateralis terminates at the level of the commissure of the superior colliculus, and is replaced by n. pulvinaris inferior.

Discussion:

In prosimians, the lateral geniculate nucleus is generally inverted and displaced from the dorsal to ventral position in the diencephalon. In higher primates, the nucleus is characterized mainly by the change from inversion to eversion of its constituent laminae. This phenomenon is largely owing to the expansion of the cerebral hemispheres in all directions (i.e., the rostrocaudal displacement of the hippocampal region and the caudal development of the internal capsule and corpus striatum) and more particularly to the rapid growth of the lateral thalamic region.

The lateral geniculate nucleus of the *Ceboidea* (*Ateles*, *Cebus*, *Callithrix* and *Saimiri* (Figs. 161-162) has been described by various investigators, notably Balado and Franke (1937) Le Gros Clark (1941b), Solnitzky and Harman (1946), Feremutsch (1963), Jones (1964), Doty (1966) and Tigges and Tigges (1970). Le Gros Clark (1941c) claimed that n. geniculatus lateralis of *Ateles* is inferior to that of *Cebus* in structural organization, but Solnitzky and Harman (1946) were able to show, by means of their wax reconstruction and histological methods, that it was the other way around. N. geniculatus lateralis of *Cebus* consists of six laminae, all of which are everted; two laminae are magnocellular and the other four parvocellular. The nucleus is located more ventrally in the caudal third of the diencephalon than in the prosimians, but its lamination is not as well defined as in higher anthropoids. Le Gros Clark found small significant variations in form and degree of lamination in the lateral geniculate nuclei of other ceboids. In *Ateles*, he was unable to find stratification of the parvocellular portion of the lateral geniculate nucleus. In respect of the unclear separation of the parvocellular portion into layers as in other primates, Giolli and Tigges (1970) pointed out that such a "concealed" lamination of this cellular mass occurs not only in non-primate mammals, but also in ceboids (platyrrhine monkeys). Solnitzky and Harman (1943, 1946) were able to demonstrate that the lateral geniculate nucleus of *Ateles* possesses four parvocellular and two magnocellular layers; its macular (central) segment is relatively larger and better developed than in *Cebus*. In the latter species, the lateral geniculate nucleus is more everted, and presents a more distinct hilus than does that of Ateles. From the phylogenetic standpoint, these structural differences appear to place the visual system of *Cebus* above that of *Ateles*.

As the lateral geniculate nucleus of the *Cercopithecoidea* has been the subject of numerous anatomical and experimental investigations, it will not be necessary to discuss its comparative structure here. Feremutsch (1963) considers the lateral geniculate nucleus of the Cercopithecoidea to be a dimorphic structure, since it exhibits not only a clear stratification into six layers, but also a division into 'dorsal' and 'ventral' parts (nn. geniculatus lateralis and pregeniculatus respectively).

According to Solnitzky (1945), the macular (central) part of n. geniculatus lateralis in cercopithecoids is better developed than in ceboids and higher anthropoids; it can be separated by a clear, fibrous layer from the peripheral segment. In the lateral geniculate nucleus of *Macaca mulatta*, the arrangement of cell layers shows a greater linearity than in all other anthropoid species. However, n. geniculatus lateralis of *Cercopithecus aethiops* is more advanced than that of *Macaca mulatta* in having macular and peripheral segments more clearly marked off from each other by surface identations. Le Gros Clark (1962) stated that the degree of lamination of the lateral geniculate nucleus of the Cercopithecoidea is much higher than in man, for in *Macaca mulatta*, two more laminae may be observed, in addition to the central layers (Layers 3 and 4) which comprise the macular segment. The total number of laminae in the lateral geniculate nucleus would then be eight, instead of the usual six. However, Crouch (1934), Aronson and Papez (1934), Walker (1937), Krieg (1948), Olszewski (1952) and Simmons (1965) did not observe those extra two laminae in their cercopithecoid specimens. The presence of a superficial layer (Lamina "S") in *Cercopithecus aethiops* confirms the existence of that superficial layer which has been observed in *Macaca mulatta* by Campos-Ortega and Hayhow (1970) and by Giolli and Tigges (1970). Therefore, the number of layers in the lateral geniculate nucleus of *Cercopithecus aethiops* and other more closely related specimens may not be six, but seven or even more, making this primate appear to possess better stereoscopic vision than any other primate, including man. Moreover, the lateral geniculate nucleus of *Cercopithecus aethiops* shows a higher degree of eversion than that of *Macaca* the most medial lamina is bent almost double around the hilus. This eversion is complete in all other catarrhine monkeys, but not in anthropoid apes and man, where the lateral extremities of the layers project to form a spur or tail.

Hassler (1966) emphasizes that, in all primate species, the lateral geniculate body is characterized by an *even* number of cell layers (four or six) which are equally divided between the ipsilateral and contralateral optic nerve projection fields. However, Ortega-Campos and Hayhow (1970) and Kanagasuntheram (1970) indicate that there is an odd number of laminae e.g. six or *seven* in *Galago* and *Cebus*; *seven*, eight or ten in *Macaca*; *nine* in *Papio*. The extra laminae in the primate lateral geniculate nucleus may be related to the homonymous hemiretinae, e.g., three to five 'crossed' and three to five 'uncrossed' laminae in *Galago*, *Cebus* and *Macaca*; five 'uncrossed' and four 'crossed' laminae in *Papio*. The occurrence of an extra-laminar representation of ipsilateral *temporal* hemiretinae in the primate lateral geniculate nucleus suggests that there may be a group of diageniculate fibres projecting from the macular region of the retina, but these fibres may not be present in the projections from the contralateral *nasal* hemiretinae (Walls 1953).

(b) *Hominoidea*

Homo sapiens

Observations:

The lateral geniculate nucleus of man (Figs. 137-140; 167-168) is a distinctly laminated mass shaped like a horse-shoe whose hilus is directed ventromedially. In the most rostral portion of the nucleus, i.e., at its anterior pole where the optic fibres enter, four laminae are observed. Caudally, in the middle third of the nucleus, *six* laminae are better defined; this appearance is maintained throughout the remainder of the anteroposterior extent of the nucleus to the caudal region of the thalamus. The six layers are concentrically arranged around the hilus; the cellular layers are clearly separated from one another by thick fibrous bands. The four laterally situated layers (Layers 3 to 6) are mediocellular, while the two medially directed layers (Layers 1 and 2) consist of large, very darkly staining, pyramidal cells arranged more loosely than those of the other layers. It is not certain whether a small band or an isolated group of large and dark-staining cells lying in the vicinity of the hilus corresponds with Lamina "S" in other primates, or not. These cells may have been isolated from Layer 1 by the intervening fibres entering this layer from the optic tract. The human lateral geniculate nucleus is typically everted, but not to such an extent as in the *Cercopithecoidea*.

It appears to have a squarish shape, although a large 'spur' of cells appears to jut from fused layers belonging to Layers 3, 4, 5 and 6, outwards toward the lateral surface of the thalamus. Its lateral rotation is between 90° and 150° throughout its entire anteroposterior extent. In the most anterior region of the nucleus, the angle of rotation is 90°, and it goes through a further 60° towards the posterior regions of the thalamus. When the posterior pole of the lateral geniculate nucleus is reached, the rotation appears to have gone through an angle of 150°, i.e., the nucleus faces more ventromedially than dorsolaterally, as it does in other higher anthropoids. N. geniculatus lateralis has a much longer caudal extent in man than in Cercopithecus aethiops; it extends as far caudally as the posterior pole of the pulvinar, where it ends at the level of the rostral part of the inferior colliculus, that is, beyond the commissure of the superior colliculus.

Discussion:

Kanagasuntheram and Wong (1969) and Kanagasuntheram (1970) reported the presence of a four-layered lateral geniculate nucleus in the Hylobatidae. Similarly, a four-layered lateral geniculate nucleus was noted in Pongo (Fig. 165) by Balado and Franke (1937), Chacko (1954) and Feremutsch (1963). This aberrant form of lateral geniculate nucleus appears to be an exception in the Hominoidea where the six-layered pattern is found as a rule in all anthropoid apes and man. Although the four-layered pattern appears to be found in the family Hylobatidae, Siamang has a six-layered lateral geniculate nucleus, in which Layer 1 (magnocellular) is split up into two extra layers. According to Kanagasuntheram and Wong (1969), this subdivision may involve only the lateral part of the lateral geniculate nucleus that is concerned with peripheral vision. From the photomicrographs and diagrams in those authors' papers, the lateral rotation of the lateral geniculate nucleus of the Hylobatidae has gone through an angle between 90° and 110° around the entire anteroposterior axis of the nucleus.

In *Pan* and *Gorilla*, n. geniculatus lateralis appears to be better developed in structure than that of the Cercopithecoidea, and even than that of man. The laminae of n. geniculatus lateralis of the Pongidae are *six* in number, and they are arranged concentrically around the hilus, but not to a greater degree than in *Cercopithecus*. In *Pan* (*and Gorilla*), the lateral geniculate nucleus (Fig. 166) is squat and square; its laminae are arranged like an admiral's hat with its tips pointing medially and laterally. In these species, the lateral geniculate nucleus is entirely everted, and the angle of lateral rotation is from 90° in the anterior region to 140° in the posterior region of the thalamus. No superficial layer, homologous to the "S" layer of Glickstein, has been observed or mentioned in any anthropoid apes, nor in man.

Three points of importance in the lateral geniculate nucleus in man, which distinguish it from those of non-human primates, are as follows:

(1) the large lateral spur;
(2) the massive, thick, well-demarcated six cellular layers;
(3) no presence of secondary splitting or fusion of layers.

In the external configuration, the lateral geniculate nucleus of man may be similar to that of the chimpanzee, but as far as differentiation of macular and peripheral segments are concerned, the human lateral geniculate nucleus is the more advanced of the two, particularly the macular segment, which is the most highly developed in all primates. My observations on the cytology and cytoarchitecture of the human lateral geniculate nucleus do not differ greatly from those given in the literature on this nucleus.

SUMMARY OF THE LATERAL GENICULATE NUCLEUS

The lateral geniculate nucleus has a very remarkable phylogenetic development in Primates. Changes in structural and cytological features comply with the increasing functional importance of the visual sense in this mammalian group. The phylogeny of the lateral geniculate nucleus can be traced from a simple, undifferentiated oval-shaped mass of small and medium-sized, light-staining, round cells lying in the dorsal region of the thalamus, as in Elephantulus, to a very highly developed six-layered structure situated in the ventral and caudal regions of the diencephalon, as in the Anthropoidea. Signs of definite stratification of cells into laminae are observed first in the Tupaioidea, where the two outermost layers (Layers 1 and 2) containing large and dark-staining cells, become segregated by a fibrous stratum from the inner mediocellular layers (Layers 3, 4, 5 and 6). The process of separation among the layers of the lateral geniculate nucleus can be traced throughout the prosimians and anthropoids to man, where the layers are more definitely demarcated from one another by thick fibrous layers.

Other interesting features in the phylogeny of the lateral geniculate nucleus are as follows:

(1) a lateral rotation of the nucleus is observed going around a craniocaudal axis from a dorsal to a ventral position in the thalamus;

(2) there is a gradual change from the inverted type as in the Tupaioidea and Prosimii to the everted type as in the Cercopithecoidea and Hominoidea;

(3) the presence of supernumerary laminae in the nucleus, e.g., seven- or ten-layered lateral geniculate nucleus, has been reported in some primate species, particularly in the Cercopithecoidea;

(4) the Tarsiidae and Hylobatidae possess an aberrant or specialized form of lateral geniculate nucleus;

(5) Mode of fibre projections from the retinae on both sides of the eye to macular and peripheral sections of the nucleus, which is more evident in higher than in lower primates, has been studied by many investigators, and possible changes from nocturnal

> to diurnal state, and evolutionary progress in the development of stereoscopic vision in primates may be related to these fibre projections.

Structural features, cyto- and myelo-architectonics, and evolutionary trends of all the metathalamic structures, i.e., nn. pregeniculatus, geniculati lateralis and medialis are summarized in Table-21. Another table is included with this chapter to show the different enumeration of layers and their cellular constitution in Primates (Table 20).

TABLE 20 COMPARISONS OF NUMBERS OF LAYERS AND CELL TYPES IN PRIMATE LATERAL GENICULATE NUCLEUS

	SPECIMEN	THIS STUDY Number and types of cells in Layers	IN THE LITERATURE Number and Types of Cells in Layers	Author/s
I.	INSECTIVORA (non-primate) Elephantulus myurus	0 homogeneous	0	-
II	TUPAIIDAE Tupaia glis	5 (+ "s") = 2 - magnocellular 3 - parvocellular "s"-magnocellular	5 (+ "s" layer)	Campbell (1972)
			4 (+ "s") - magno- and 2 parvocellular	Bauchot (1963)
			4 - ? homogenous	Feremutsch (1963)
			6 (5 + "s") = 3 magno- and 3 parvocellular	Noback et al (1970) Hassler (1966)
	Tupaia minor	5 - 2 magnocellular 3 parvocellular	4 = 2 magnocellular 2 parvocellular	Le Gros Clark (1929)
	Ptilocercus		5 = 2 magnocellular = parvocellular	Le Gros Clark (1927)
III 1.	PROSIMII LEMURIDAE (a) Microcebus murinus	6 = 2 magnocellular 4 parvocellular (no "s" layer)	6 = 2 magnocellular 4 parvocellular	Le Gros Clark (1931); Chacko (1954), Feremutsch (1963), Hassler (1966)
	(b) Lemur species L. catta L. fulvus L. macaco L. mongoz	6 = 2 magnocellular 4 parvocellular	6 = 2 magnocellular 4 parvocellular	Fines (1927), Feremutsch (1963), Chacko (1954), Hassler (1966)
		-	6 = 4 magnocellular 2 parvocellular	Solnitzky & Harman (1946)
			4 = 2 magnocellular 2 parvocellular	Woollard & Beattie (1927) Feremutsch (1963)
	(c) Lepilemur	5 = 1/2 magnocellular 3/4 parvocellular (6th layer not observed)	?6= 2 magnocellular 4 parvocellular	Feremutsch (1963) Hassler (1966)
	(d) Propithecus	-	?6= 2 magnocellular 4 parvocellular	Feremutsch (1963)
2.	LORISIDAE (a) Perodicticus potto	6 = 2 magnocellular 2 parvocellular 2 mediocellular (no "s" layer observed)	6 = 5 magnocellular 1 parvocellular	Solnitzky & Harman (1946)
			6 = 4 magnocellular 2 parvocellular	Chacko (1954)
			?4= all magnocellular (partly laminated)	Woollard & Beattie (1927)
	(b) Loris gracilis	-	6 = 2 magnocellular 4 parvocellular	Feremutsch (1963), Chacko (1954) Hassler (1966)
	(c) Loris tardigradus	-	6 = 4 magnocellular 2 parvocellular (= ?7th layer)	Laemle & Noback (1970); Kanagasuntheram et al (1968, 1970)
	(d) Nycticebus coucang	-	(= "s" layer)	Giolli & Tigges (1971)
		-	4 = all magnocellular	Feremutsch (1963)
3.	GALAGIDAE (a) Galago demidovii	6 = 2 magnocellular 2 parvocellular 2 mediocellular (?"s" layer present)	5 = 2 magnocellular 3 parvocellular	Bauchot (1963), Woollard & Beattie (1927)
			6 = 5 magnocellular 1 parvocellular	Solnitzky & Harman (1946) Kanagasuntheram (1970)
	(b) Galago senegalensis	5 = 2 magnocellular 2 parvocellular 1 mediocellular (6th layer "hidden"; "s" layer ? present)	5 = 2 magnocellular 3 parvocellular (+6th? layer)	Kanagasuntheram et al (1968), Woollard & Beattie (1927)
	(c) Galago crassicaudatus	5 = 2 magnocellular 2 parvocellular 1 mediocellular (6th layer "hidden" and "s" layer present)	5 = 4 magnocellular 1 parvocellular	Woollard & Beattie (1927) Kanagasuntheram et al (1968)
			6 = 2 magnocellular 2/4 parvocellular (2 mediocellular) (+ "s" layer present)	Campos-Ortega & Hayhow (1970) Laemle & Noback (1970); Hassler (1966) Ionescu & Hassler (1968)

TABLE 20 (contd.) COMPARISONS OF NUMBERS OF LAYERS AND CELLULAR TYPES IN PRIMATE LATERAL GENICULATE BODIES

	SPECIMEN	THIS STUDY	IN THE LITERATURE	
		Number and Types of cells in Layers	Numbers and Types of Cells in Layers	Authors/s
4.	TARSIIDAE Tarsius spectrum	-	3 = 2 magnocellular 1 parvocellular	Le Gros Clark (1930)
			4 = 3 magnocellular 1 parvocellular	Woollard (1926) Hassler (1966)
IV	ANTHROPOIDEA			
1.	CEBIDAE (a) Hapale	-	5 = 2 magnocellular 3 parvocellular	Woollard (1926)
	(b) Cebus	-	6 = 2 magnocellular 4 parvocellular	Le Gros Clark (1941) Solnitzky & Harman (1946)
	(c) Ateles	-	6 = 2 magnocellular 4 parvocellular (+ "s" layer)	Le Gros Clark (1941) Solnitzky & Harman (1946) Giolli & Tigges (1970)
	(d) Saimiri	-	6 = all magnocellular (+ "s" layer)	Campbell (1972)
	(e) Aotes (f) Callithrix	-	4)- all magnocellular 4)	Ionescu & Hassler (1965)
2.	CERCOPITHECIDAE (a) Cercopithecus aethiops	6 = 2 magnocellular 2 parvocellular 2 mediocellular (+ "s" layer)	6 = 2 magnocellular 4 parvocellular (+ "s" layer)	Campos-Ortega & Hayhow (1970), Giolli & Tigges (1970); Solnitzky & Harman (1946-without "s" layer)
	(b) Macacus mulatta	-	8 = 2/3 magnocellular 5/6 parvocellular	Le Gros Clark (1941) Solnitzky & Harman (1946)
			7 - 10 = 2 magnocellular 5-8 parvocellular and mediocellular	Campos-Ortega & Hayhow (1970), Kanagasuntheram (1970) Giolli & Tigges (1970).
	(c) Papio spp.	-	9 - 10 = 2 magnocellular) and others parvo-) and medio-cellular)	Kanagasuntheram (1970). Giolli & Tigges (1970), Solnitzky & Harman (1946)
			6 = 2 magnocellular 4 parvocellular	Feremutsch (1963)
3.	HYLOBATIDAE (a) Hylobates (c) Siamang	- -	4 = 2 magnocellular 2 parvocellular	Balado & Franke (1938); Feremutsch (1963) Kanagasuntheram et al (1969),(1970).
	(b) Symphalangus	-	4/6 = 2/3 magnocellular 2/3 parvocellular	Kanagasuntheram et al (1969, 1970)
4.	PONGIDAE (a) Pongo	-	4 = 2 magnocellular 2 parvocellular	Kanagasuntheram (1970) Balado & Franke (1938), Feremutsch (1963), Chacko (1954)
	(b) Pan	-	6 = 2 magnocellular 4 parvocellular	Feremutsch (1963) Solnitzky & Harman (1946)
	(c) Gorilla	-	6 = 2 magnocellular 4 parvocellular	Feremutsch (1963)
5.	HOMINIDAE Homo sapiens	6 = 2 magnocellular	6 = 2 magnocellular 4 parvocellular or 4 mediocellular or 2 parvocellular and 2 mediocellular	By most workers dealing with the morphology and function of the lateral geniculate body.

CHAPTER 14

THE METATHALAMUS:β.MEDIAL GENICULATE BODY

N. Medialis Geniculatus (Plates 4 - 54)

Like n. geniculatus lateralis, n. geniculatus medialis will be described in full, taxon by taxon.

Although the medial geniculate body is not separable into two morphologically distinct parts like the lateral geniculate body, it is termed the medial geniculate nucleus in order to bring it into conformity with the method of classification used in this study. Morest (1965) reported in the cat that n. geniculatus medialis exhibits a laminated structure, particularly in its ventral part, but the arrangement of small and large cells into layers is not as well organized as in n. geniculatus lateralis of primates. Moreover, such a laminated feature is not present in the medial geniculate body of non-primate and primate species used in this study, except that, n. geniculatus medialis is, throughout the primate scale, divisible into two cytologically different parts.

Morphologically, n. geniculatus medialis is easily recognized at the base of the brain as a well pronounced protuberance lying beneath the pulvinar. Dorsally and rostromedially, n. geniculatus medialis blends with other thalamic nuclei, particularly with n. pulvinaris inferior. N. geniculatus medialis is the most caudally situated nucleus of the whole thalamus.

(1) INSECTIVORA

Macroscelidoidea

Elephantulus myurus

Observations:

N. geniculatus medialis (Figs. 39-40) is a rounded mass of moderately dark-staining cells lying at the caudolateral extremity of the thalamus, where it forms a distinct tubercle on the ventral surface of the brain. N. geniculatus medialis lies medial and caudal to the optic tract, ventromedial to n. suprageniculatus and dorsolateral to the cerebral peduncle. It disappears at the level of the rostral appearance of the trochlear nucleus.

Discussion:

In all mammalian groups, and also throughout the primate scale to man, n. geniculatus medialis is generally divided, not only on a ctyoarchitectonic basis, but also from a functional point of view, into a dorsomedial magnocellular part and a ventrolateral parvocellular (principal) part. The magnocellular part consists of very large, dark-staining, multipolar cells that are scattered loosely in the nucleus. The parvocellular part consists of small and medium-sized, lightly staining and polygonal cells that are arranged more compactly than those in the ventrolateral part. According to Knighton (1950), the mammalian medial geniculate body is composed of a medially placed group of large cells which is continuous with the caudally placed large-celled portion of n. ventralis posterolateralis, and a peripherally disposed crescentic portion of medium-sized cells, which partially surround the former part. Rostrally, the crescentic portion of n. geniculatus medialis is continuous with, and is indistinguishable from, n. lateralis posterior. As this crescentic portion extends dorsomedially to replace a particular part of n. lateralis posterior, this area becomes n. suprageniculatus. Lying dorsomedial to the ventrolateral division of n. geniculatus medialis is a third division, whose cells are much larger and more loosely arranged than those of the dorsomedial part of n. geniculatus medialis.

In all insectivores, the medial geniculate body forms the extreme caudal pole of the diencephalon; it can be seen as a rounded eminence lying above the cerebral peduncle on the ventral surface of the thalamus (Bauchot 1963). It is less easily recognizable rostrally than caudally, as its borders with the ventrolateral thalamic nuclei are not clearly definable. The medial geniculate body is divided into a central region which is clearly delimited from the peripheral region. These regions may correspond to the partes principalis and magnocellularis of n. geniculatus medialis of other non-primate mammals. In the Insectivora, a third division containing small and dark-staining cells has been observed by Bauchot to lie dorsal to the magnocellular division of n. geniculatus medialis. He regards the third division as an equivalent of the primate suprageniculate nucleus, though the latter nucleus has generally larger and much more darkly staining cells than those of n. geniculatus medialis. Bauchot also finds homologization of the caudal part of n. geniculatus medialis with that of primates difficult, because his horizontal sections of the insectivore diencephalon show that the transition of some areas belonging to either n. ventralis posterior, or n. lateralis posterior, or intermedius, to the region of the medial geniculate body is not sufficient to demonstrate the relationship of n. geniculatus medialis with the lateral thalamic mass. In this study, this homologization is also not possible, as the medial geniculate nucleus of *Elephantulus myurus* is divided simply into a larger magnocellular and a smaller ventrolateral part; these divisions hardly demonstrate any relationship with the lateral thalamic mass.

(2) TUPAIOIDEA

Observations:

N. geniculatus medialis (Figs.51-52) appears at a much more caudal level than n. geniculatus lateralis, and is found in the same topographical position as n. peripeduncularis, which lies rostral and medial to it. N. geniculatus medialis increases in size as n. geniculatus lateralis dwindles away; the former structure forms a more prominent protuberance caudally on the ventrolateral surface of the thalamus. N. geniculatus medialis is divided cytologically into magnocellular and parvocellular parts. The magnocellular part (MGN-mg) occupies the rostral, dorsomedial and caudal regions while the parvocellular part (MGN-pv) forms the ventrolateral and main regions of the nucleus. The cells of the magnocellular part are larger (19 x 11 μ), and stain rather more deeply and are more polyhedral than those of the parvocellular part (15 x 9 μ).

The parvocellular part is intimately related to n. limitans while the magnocellular part is linked closely with n. suprageniculatus. The medial geniculate body is the last thalamic structure to disappear in the transition of diencephalic regions into mesencephalic regions.

Discussion:

Le Gros Clark (1929) found, in *Tupaia minor*, that it was not possible to analyze the constituents of n. geniculatus medialis, as its structure appeared to be better arranged on the lateral than on the medial side of the thalamus. He pointed out that the lack of differentiation might be owing to the diminutive size of the inferior colliculus and the apparent degenerate nature of the external ear of this animal. On the other hand, Le Gros Clark stated that the uniform cellular make-up of the medial geniculate body is a primate characteristic. From my observations in all tupaioids, n. geniculatus medialis is clearly differentiated into a ventral parvocellular and a dorsomedial magnocellular region that corresponds well with those in *Tupaia glis* (Bauchot 1963), as well as with those in primates. Furthermore, *Tupaia* possesses very fine hearing, and the apparently small size of the medial geniculate body in this animal may have been affected by the relative size and more rapid development of the lateral geniculate body.

(3) PROSIMII

(a) Lemuroidea

(i) *Microcebus murinus*

Observations:

N. geniculatus medialis (Figs. 59-60) is well differentiated into two cellular parts - a dorsomedial magnocellular and a ventrolateral parvocellular part. The third division is better developed in this species than in *Tupaia*; it contains several large, deeply staining, stellate cells that are situated in the dorsomedial angle of the medial geniculate body. This third part of n. geniculatus medialis has an intimate relationship with nn. suprageniculatus and limitans. Caudally, the parvocellular part of n. geniculatus medialis increases in size and extent, and is the largest of all divisions of the nucleus. In this species, the pulvinar, not the medial geniculate body, is the latest thalamic structure to disappear before the mesencephalic regions dominate the picture. Therefore, the medial geniculate body is replaced by the inferior part of the pulvinar.

(ii) *Lemur spp.*

Observations:

In these species, the medial geniculate body (Figs. 81-84) is a well defined structure which protrudes clearly below the ventral surface of the thalamus. It appears first at the level of the habenulopeduncular tract, and is a large, oval-shaped structure which contains a mixture of small and medium-sized, pale-staining, round to fusiform cells. N. geniculatus medialis pars parvocellularis (MGN-pv) lies ventral to n. ventralis posterolateralis, and medial to n. geniculatus lateralis. As n. geniculatus medialis increases in size and cellular density, it shifts ventralwards and forms the obvious bulge on the ventral surface of the thalamus. At this level, n. geniculatus medialis attains its full pear-shaped form, the sharp pole of which forms the dorsomedial magnocellular part of the nucleus. The dorsomedial part is linked by a trail of large, dark-staining cells with n. limitans. The cells of the dorsomedial part are, upon visual inspection, not as large as those of n. suprageniculatus, but they appear to be slightly larger than those of the parvocellular region. Most of the fibres of the auditory pathway appear to terminate in the dorsomedial part, while other fibres from the medial lemniscus and n. ventralis posterior go to the ventrolateral part of n. geniculatus medialis. The latter region increases both in size and extent, until, at the level of the caudal pole of the pulvinar, it dominates the entire region, and finally disappears rostral to the pulvinar. The third division of n. geniculatus medialis, as identified in *Tupaia* and *Microcebus murinus*, has not been observed in all Lemur spp.

(iii) *Lepilemur*

In this lemuroid, *n. geniculatus medialis* (Figs.69-70) seems not to be as large as that of *Lemur*. It causes a smaller protuberance on the ventrolateral surface of the thalamus than is seen in *Microcebus murinus*. N. geniculatus medialis is rather well differentiated into a dorsomedial and a ventrolateral part; the third part is not present. It is lightly myelinated in appearance, particularly in its dorsomedial part. On its dorsal border, streaks of myelinated fibres run from the brachium of the inferior colliculus into the lateral region of n. geniculatus medialis; these fibres are evidently a part of the auditory pathway, particularly of the inferior colliculus and lateral lemniscus. The medial lemniscus contributes some fibres to the medial part of n. geniculatus medialis, thus showing a close relationship between this nucleus and n. ventralis posterior.

Discussion:

Le Gros Clark (1931) had the medial geniculate body of *Microcebus murinus* subdivided into three components; a central area of small cells, a dorsolateral element of larger and more deeply staining cells and a caudoventral group of scattered small cells. These divisions do not fit well into the pattern of cellular differentiation of n. geniculatus medialis in all prosimian specimens used in this study. However, the central area appears to be a part of the parvocellular region, while the large-celled dorsolateral element and the caudoventral extension may be included in both dorsomedial and ventrolateral parts of n. geniculatus medialis in the same lemuroid.

In the Lemuridae, there is a sort of structural relationship between the dorsomedial part of n. geniculatus medialis with nn. suprageniculatus and limitans. The ventrolateral part is related both structurally and functionally with n. ventralis posterior and the pulvinar, and contributes most of its fibres to the auditory radiation which forms a posterior part of the inferior thalamic peduncle. The third division has not been observed in the Lemuroidea by most investigators.

(b) Lorisoidea

(i) Perodicticus potto

Observations:

N. geniculatus medialis (Figs.95-96) is a well formed structure that is divided into ventrolateral and dorsomedial parts. In this species, n. geniculatus medialis contains more large than small cells in its rostral region. Towards the caudal region of the nucleus, the ventrolateral part contains almost entirely small and medium-sized, pale-staining round cells, while the dorsomedial part, which is smaller in area than the ventrolateral part, consists of large, dark-staining, triangular cells. On the dorsal edge of the magnocellular part, is a band of large, dark-staining, pyramidal cells that links n. geniculatus medialis with nn. limitans and suprageniculatus. This band of cells may be the third division of the medial geniculate body.

Caudally, the dorsomedial magnocellular part of n. geniculatus medialis increases to such an extent that the ventrolateral parvocellular part is displaced to a more lateral and caudal position. This topographic situation remains unchanged till the caudal end of the medial geniculate body is reached. However, in the caudal pole of the medial geniculate body the large cells decrease in number, and are confined to the dorsal surface of the medial geniculate nucleus. The ventrolateral part correspondingly increases in size until it eventually occupies the entire region.

(ii) *Galagidae*

In all *Galago* spp., n. geniculatus medialis (Figs.103-106; 113-116) is a prominent structure lying ventromedial to n. geniculatus lateralis. It causes a very significant protuberance on the ventral surface of the thalamus; this tubercular appearance is more accentuated in *Galago crassicaudatus* than in *Galago senegalensis* and *Galago demidovii*. N. geniculatus medialis is divided, as usual, into a dorsal magnocellular and a ventral parvocellular part. The third division is hardly observed in all Galago specimens, otherwise, it can be easily mistaken for the dorsal edge of the magnocellular part that links the medial geniculate nucleus with n. suprageniculatus. The parvocellular part contains small (14 x 9 μ), lightly staining and round cells, the magnocellular part is composed of large (19 x 12 μ), dark-staining and multipolar cells. N. geniculatus medialis extends much farther caudally than n. geniculatus lateralis, and is replaced by n. pulvinaris inferior.

Discussion:

Kanagasuntheram et al (1968) observed that n. geniculatus medialis of *Galago senegalensis* and *Nycticebus coucang* is represented almost entirely by the parvocellular region, although a few, scattered large cells lying medial to this region, may represent the dorsomedial magnocellular part. In my lorisoid specimens, the dorsomedial part is so distinctly formed that it occupies a considerable area of the medial geniculate nucleus. A close relationship is observed between n. ventralis posterior and the parvocellular part of n. geniculatus medialis; this may indicate that these regions may have developed ontogenetically from the ventral anlage of the 'dorsal' thalamus. My observation, thus, agrees with Cooper's (1950) that these nuclei may have arisen from a common region in the lateral thalamic mass.

In Tarsius, Le Gros Clark (1930) observed a larger and better developed medial geniculate body, which could be readily differentiated cytoarchitectonically into a large central mass of small cells and a small dorsolateral element of large, dark-staining cells. These regions are homologous to the parvocellular and magnocellular parts of n. geniculatus medialis of Lemur and Galago. The third division of n. geniculatus medialis is present in Tarsius, and it is much smaller and more closely related to n. pulvinaris inferior than to n. suprageniculatus.

(4) ANTHROPOIDEA

In the vervet monkey and man, the medial geniculate body (Figs. 123-128; 139-140) lies posterior to the lateral geniculate body in the medial angle between the thalamus and the tegmentum of the midbrain. The structural differences in both primates are slight and will not be described in detail. N. geniculatus medialis is divided clearly into a large ventrolateral parvocellular and a small dorsomedial magnocellular part. In Cercopithecus aethiops, the cells of the ventrolateral part consist of small to medium-sized cells ($14 \times 11\ /^{u}$) while those of the dorsomedial part are larger and more dark-staining ($25 \times 12\ /^{u}$).

The latter part receives fibres directly from the lateral lemniscus and other lower centres of the auditory pathway. Because the ventrolateral part is related closely to the ventrolateral thalamic mass, and receives fibres from the inferior colliculus, this part has a polysynaptic input whereas the dorsomedial part is mostly auditory in character.

Kruger (1959) observed, in the Cetacea, that the ventrolateral part of n. geniculatus medialis is relatively very large and extremely well developed. The large size of n. geniculatus medialis appears to be consistent with unusually large auditory nerves and inferior colliculi in the dolphin. These morphological features have been confirmed by Johnston and Simmons (1972) in certain cetacean species (*Tursiops truncatus*, *Stenella euphrosyne* and *Globicephala macrorhyncha*). However, the internal configuration of n. geniculatus medialis of cetaceans resembles more that of carnivores than of primates, as it appears to conform with the description given by Morest (1965) in the cat. The cells of the parvocellular part of n. geniculatus medialis of cetaceans appear to be arranged in rather regular rows or layers. The magnocellular part of the medial geniculate nucleus is situated medioventrally to the parvocellular part, from which it can be very clearly demarcated by a band of fibres. It is rather difficult to homologize the magnocellular part of the cetacean medial geniculate nucleus with that of the same nucleus in my primate specimens, although it may correspond to the same region in *Cercopithecus* as described by Friedemann (1912).

In *Macaca mulatta* (macaque monkey) Walker 1937, 1938; Krieg 1948; Chow 1951, Olzsewski 1952) and in *Cercopithecus aethiops* (Simmons 1965), n. geniculatus medialis is described as having a larger lateral parvocellular part and a smaller medial magnocellular part. The parvocellular part does not show the laminar pattern as in the cat, and its cells are distributed uniformly and rather loosely throughout the substance. The magnocellular part is limited to the dorsomedial margin of n. geniculatus medialis, and is not clearly demarcated from n. suprageniculatus which has been displaced to a more ventral position by the expanding pulvinar. There is some disagreement among the workers (Walker, Chow and Krieg) about the cytoarchitecture of the magnocellular division of n. geniculatus medialis in relation to n. suprageniculatus. Walker (1938) described the former structure as composed of large, darkly staining and fairly compactly arranged cells interspersed with a few medium-sized cells, whereas the cells of n. suprageniculatus are larger, more darkly staining and more pyramidal in shape. Krieg (1948) stated that the magnocellular part of n. geniculatus medialis consists of 'scattered, very large, irregular cells with abundant Nissl granules', and n. suprageniculatus is only 'a dense, compact accumulation of small, round, very closely packed cells'. Chow (1951) agrees with Walker that the magnocellular part should be considered as a group of large, rather compactly arranged cells lying in the dorsomedial corner of the parvocellular region of n. geniculatus medialis. Chow observed, in the transverse sections of n. geniculatus medialis, that the nucleus is elongated and oval-shaped, and a band of very large, dark-staining scattered cells appears to run dorsomedially from the magnocellular part to blend with the cells of n. pulvinaris inferioris. Chow regarded this magnocellular portion to be cytoarchitectonically different from that of n. geniculatus medialis, and stated that the former portion should be called n. suprageniculatus

This is in contradistinction to Krieg's descriptions of both structures. However, Krieg, by personal communication with Chow, insisted that his descriptions of these structures remained unchanged, confirming Walker's definitions of nn. suprageniculatus and geniculatus medialis pars magnocellularis. My studies of these nuclei in primates conform with those of Krieg and Walker, particularly that nn. suprageniculatus and geniculatus medialis pars magnocellularis are separable identities, even though their cytological features may appear to be almost identical. Moreover, these nuclei have different ontogenetic origins; the pars magnocellularis from the thalamic anlage, and n. suprageniculatus from the subthalamic anlage.

Kuhlenbeck (1954) stated that the medial geniculate body of man is divided into a dorsal and a ventral part on embryological and anatomical grounds, but he did not mention relative sizes and cellular composition of those parts. However, the dorsal part is further subdivided into a dorsomedial magnocellular and a ventrolateral parvocellular part, thus conforming well with the descriptions of the same nucleus in other primates. The ventral part is located lateral and caudal to the peripeduncular part of the zona incerta, and ventromedial to the main part of the medial geniculate body. Kuhlenbeck concluded that although the dorsal and ventral parts of the medial geniculate body are related to each other in all respects, the lateral lemniscus does not have direct connections with the ventral part of the medial geniculate body. Locke (1962) found in man that there are two distinct projections from the medial geniculate body to the auditory cortex. Therefore, there may be two parts of the medial geniculate body that are structurally and functionally different from each other. However, fibre projections from these parts have yet to be further investigated before a conclusion can be reached on the morphology of the medial geniculate body.

SUMMARY OF THE MEDIAL GENICULATE BODY

The phylogeny of the medial geniculate body is less remarkable than that of the lateral geniculate body. It does not change greatly in structure and cytology. N. geniculatus medialis is, at first, a small and totally undifferentiated mass of cells lying ventromedially to n. geniculatus lateralis, as in Tupaia, and goes through a structural differentiation until it becomes very large and heterogeneous mass of cells in man. Throughout the primate scale, n. geniculatus medialis generally consists of a medial magnocellular and a lateral parvocellular region. In Prosimii, the dorsomedial part is predominant; the parvocellular part increases in bulk only where the medial geniculate body reaches its termination in the extreme caudal region of the diencephalon. As the primate scale is ascended, the parvocellular part forms the main body of n. geniculatus medialis, and the dorsomedial part is confined to the dorsal margin of the same nucleus. There is some cytological resemblance between this latter part and n. suprageniculatus, but n. suprageniculatus has larger and more deeply staining cells than the dorsomedial part of n. geniculatus medialis. The third division is readily identified in <u>Elephantulus</u>, <u>Tupaia</u> and some lower prosimians, but not in higher prosimians and all simian primates. It is often confused for n. suprageniculatus in higher primates. The medial geniculate body does not appear to be divided into structurally and functionally distinct parts as is the lateral geniculate body, but the differing cytoarchitectonic and cytological features may reveal the fact that the medial geniculate body has two different regions, each sending a separate fibre projection to the cerebral cortex and being connected with various diencephalic regions.

The general structure, cytological properties, myelin content and phylogenetic trends of n. geniculatus medialis are summarized in Table 21.

TABLE 21 COMPARISONS OF THE METATHALAMIC STRUCTURES

Features	N. pregeniculatus (PGN)	N. geniculatus lateralis (LGN)	N. geniculatus medialis (MGN)
STRUCTURAL FEATURES	In Elephantulus and Tupaia, PGN is a more prominent and larger structure than that of primates. In Tupaia, as well as in lower prosimians, PGN is placed ventrally to LGN, and shows a well defined connection with the subthalamus. In the Lemuroidea, PGN starts to reduce in size and also in functional importance: it is relatively much smaller in structure than LGN and MGN. In the Cercopithecoidea, PGN is no more than a vestigial structure which has been shifted to a more rostral and dorsomedial position lying between LGN ventrally and ZI and RET dorsally. In the Anthropoidea including man, PGN comprises only of a few, scattered large cells lying in the perigeniculate "capsule" lateral to ZI and PP.	LGN is a relatively small and undifferentiated cellular mass lying dorsal to the lateral nucleus in Elephantulus. It shows incipient signs of cellular lamination and ventralward shift first in the Tupaioidea. In certain species of the Lemuroidea, e.g., Microcebus, Lepilemur, Perodicticus, LGN still occupies a dorsal position in the middle part of the thalamus. In other lemuroids, as well as in lorisoids and tarsioids, LGN shows very marked changes in structure and topographical position. In these prosimians, it occupies a ventral position in the caudal part of the thalamus, as well as undergoing a lateral rotation through an angle of 80-90° the craniocaudal axis. At the same time, LGN has also undergone a definite cellular arrangement into 3 to 6 layers, but mostly six layers. The cellular layers are not as clearly demarcated from one another as in higher primates, and show a typical inverted pattern throughout the prosimian scale. In the Anthropoidea, LGN is much more clearly laminated into six layers, though in certain cercopithecoids, one or two more laminae are observed, and four laminated LGN's can be found in the Hylobatidae. The cellular laminae are more widely separated from each other by well defined fibrous layers. Throughout the Anthropoidea, LGN exhibits an everted type of lamination and is situated more ventrally and caudally in the posterior part of the thalamus.	In Elephantulus, MGN is a small, simple and cellularly homogeneous structure. In Tupaia, MGN is definitely split up into a larger dorsomedial magnocellular and a smaller ventrolateral parvocellular part. In this species, as well as in all prosimians, MGN shows the beginning of protrusion below the ventral surface of the diencephalon; this protrusion develops concomitantly with the progressive increase in size and differentiation of the nucleus throughout the primate series to man. As one ascends the primate scale, the ratio of large to small cells is reversed that is, more and more small cells become evident and the ventrolateral part becomes the larger of the two. In the Anthropoidea, including man, MGN appears to be composed almost entirely of the parvocellular element, whereas the magnocellular element is restricted to the dorsal margin of the nucleus. A third division consisting of cells that are much larger and more dark-staining than those of the dorsomedial division has been described in MGN of several prosimians as well as in certain anthropoid species. It has not been yet ascertained whether it is a part of MGN or SC (n. suprageniculatus).
CELLULAR PROPERTIES	Cells of PGN are mostly medium-sized (14 x 10 /$^{\mu}$ in Tupaia to 17 x 12 /$^{\mu}$ in Lemur) but are much smaller in Cercopithecus (9 x 8 /$^{\mu}$). ~~Neuronal type is variable among primates (from Type III to Type VII~~). Cellular size and density decrease as one goes up the primate scale.	Cells in the outermost layers (Layers 1 and 2) are generally large and dark-staining, while the inner layers (Layers 3 to 6) are small and medium-sized and lightly staining. Cellular size and density in all these layers do not decrease or increase much throughout the primate scale (between 13 and 17 /$^{\mu}$). ~~Neuronal types vary considerably among primates (from Type III to VII~~).	Cells in the dorsomedial part of MGN are larger and more darkly staining than those of the ventrolateral part of the same nucleus. In lower primates, as well as in the Tupaioidea, there are more large cells than small cells, while the small cells predominate greatly in the MGN's of higher primates. The large cells are from 16 x 11 /$^{\mu}$ in Lemur to 25 x 11 /$^{\mu}$ in Cercopithecus. while the small cells are invariably 14 to 16 /$^{\mu}$.
MYELIN CONTENT	PGN is generally more lightly myelinated than LGN and MGN in all species studied here. Fibres course ventromedially through it from the optic tract to the subthalamic region. In higher primates, it can be seen as a small, very lightly stained area situated among the densely myelinated fibres of the perigeniculate "capsule" or area.	Fibrous bands intersperse between cellular layers in all primates; they are thin and hardly discernible in Tupaia and all prosimians, and increase in thickness as one goes up the primate scale. Fibres run from the optic tract through the outermost layers to the innermost layer, and ramify throughout the nucleus. In lower primates, fibres of the optic tract run along the lateral surface of LGN, and emerge from the medial surface as fibres of the optic radiation. In higher primates, as LGN undergoes a ventralward shift and lateral rotation, the fibres of the optic tract enter LGN ventrally and leave as fibres of the optic radiation from the dorsal surface of LGN.	Fibres radiate from the lateral lemniscus and inferior colliculus through the nucleus in a ventrolateral-dorsomedial direction. The parvocellular part appears to be more lightly myelinated than the dorsomedial part, thus MGN is relatively a light-staining area particularly in higher primates.
EVOLUTIONARY TRENDS	Shows a significant phylogenetic regression from Elephantulus and Tupaia through the prosimians and anthropoids to man, but it does not disappear altogether.	Shows the most marked phylogenetic development in the entire diencephalon. Its evolution from a simple and undifferentiated to a most highly elaborated structure is concomitant with the development of the cerebral cortex.	MGN has also a significant phylogeny as LGN, but to a lesser degree. It shows a clear separation into two structurally and functionally different parts.

CHAPTER 15

THE SUBTHALAMUS

Although several investigators term the region lying between the ventrolateral nuclear group of the thalamus dorsally and the hypothalamus ventrally the 'ventral thalamus', the other term 'subthalamus' is preferred in this study. The subthalamus covers a broader area than the so-called ventral thalamus which does not include the fields of Forel, nn. entopeduncularis and peripeduncularis, and other structures belonging to the transitional zone between the diencephalon and mesencephalon. The line of demarcation between the thalamus and subthalamus is well defined, but not between the subthalamus and hypothalamus in primates, particularly the Tupaioidea and Prosimii. The subthalamus is continuous caudoventrally with the tegmentum of the midbrain, thus, making the topographical delimitation between these two regions rather difficult.

The subthalamus is composed largely of fibre fields containing ascending and descending fibre systems which are interpolated between the corpus striatum on the one hand and n. ruber, the oculomotor centres and tegmental areas of the midbrain on the other hand. Such prominent fibre bundles of the subthalamus are the tegmental or prerubral field H of Forel, the ansa lenticularis, the fasciculi thalamicus (field H_1) and lenticularis (field H_2). Nuclei of the subthalamus listed for description are:

1. N. subthalamicus (S)
2. N. zonae incertae (ZI)
3. Nn. campi Forelii(or nuclei of the fields of Forel) (FF, H_1 and H_2)
4. N. entopeduncularis (EP)
5. N. peripeduncularis (PP)

1. N. subthalamicus (S) (Plates 4 - 51)

(1) INSECTIVORA

Macroscelidoidea

Elephantulus myurus

N. subthalamicus (Figs. 39-40) is a prominent, oval-shaped structure which is associated closely with the dorsal surface of the cerebral peduncle. It lies lateral to the zona incerta, caudal to n. entopeduncularis and rostrodorsal to the substantia nigra of the mesencephalon from which it is rather poorly demarcated.

(2) TUPAIOIDEA

N. subthalamicus is identified as an elongated, flattish-oval structure lying mediolaterally or rather horizontally on the dorsal surface of the cerebral peduncle. N. subthalamicus is related dorsally to nn. pregeniculatus and peripeduncularis, medially to n. zonae incertae and the field H_2 of Forel, and caudoventrally to the substantia nigra which replaces it at the level of the oculomotor nucleus. The cells of n. subthalamicus are medium-sized (16 x 10 μ), stain moderately well, and are oval- in shape, and are arranged compactly in a nutshell-like area. Fibres are arranged densely around the nucleus, as well as in a fine meshwork throughout its substance. N. subthalamicus of the Tupaioidea is monomorphous and isoformic.

(3) PROSIMII

(a) Lemuroidea

N. subthalamicus (Figs. 57-58; 67-68; 77-80) does not vary much topographically and cytologically in all Lemur specimens. It has similar relationships with other subthalamic formations as in the Tupaioidea. N. subthalamicus is much larger and shaped like an eye lying obliquely on the dorsal surface of the cerebral peduncle. The cells of n. subthalamicus are mostly medium-sized (17 x 10 μ), stain well and are polygonal; they are arranged rather regularly along the mediolaterally running fibres. N. subthalamicus is very well encapsulated by the fibres of the ansae lenticularis and thalamicus, but on its medial aspect, it appears to be continuous with the fields of Forel and the lateral hypothalamic area.

(b) Lorisoidea

(i) *Perodicticus potto*

In this species, *n. subthalamicus* (Figs. 87-88) is smaller and more flattened than that of the Lemuroidea. It has the same topographical and architectonic features as in other prosimians. The cells are mostly medium-sized, lightly staining and oval, and are distributed rather uniformly throughout the nucleus.

(ii) Galagidae

N. subthalamicus (Figs. 101-102; 111-112) is much larger and more ovoid in shape than that of other prosimians. It is orientated in an oblique direction from dorsolaterally to ventromedially. It is well encapsulated on all sides, and contains a rather loosely arranged network of fibres running through its substance. The cells of n. subthalamicus are medium-sized (16 x 9 μ), oval or fusiform and are mostly pale-staining, and are arranged in closely packed rows along the fibres. In *Galago crassicaudatus*, n. subthalamicus is enormous in size, and is rather flattened dorsoventrally instead of being oval or round as in other species.

(4) ANTHROPOIDEA

Throughout the higher primate scale, *n. subthalamicus* (Figs. 117-122; 131-134) increases progressively in size and becomes more flattened mediolaterally. It lies upon the dorsal aspect of the cerebral peduncle, rostral to the substantia nigra and ventral to the zona incerta. In Cercopithecus aethiops, the cells of n. subthalamicus are medium-sized (17 x 10 μ), stain rather well and are round or polygonal in shape; they are scattered more or less uniformly throughout the nucleus. N. subthalamicus is encapsulated on all sides except on its medial surface, where it comes into contact with the prerubral field of Forel.

Discussion on n. subthalamicus

In reptiles and birds, there is no structure with which n. subthalamicus of primates can be homologized (Huber and Crosby 1929), Kappers, Huber and Crosby 1936). Therefore, it is possible that n. subthalamicus is exclusively a mammalian acquisition, since its beginnings can be discerned in lower mammals, and it gains in size and structural prominence as the phylogenetic scale is ascended. Although Śmiatowski (1971) gave a detailed description of n. subthalamus and its fibre connections, in the dog, he did not make any comparisons with that of primates. However, judging from the contents of his paper, the features of the carnivore subthalamus do not differ, in any way, from those of the primate subthalamic nucleus. N. subthalamicus of carnivores and in other non-primate mammals is well encapsulated, and has the same connections with the fields of Forel, the striatal regions and the lateral hypothalamic region as in primates.

In Insectivora, Bauchot (1963) describes n. subthalamicus as a well developed structure that is surrounded on all sides by a capsule of fibres. It is generally lentiform in shape, biconvex on both sides and lies on the dorsal surface of the cerebral peduncle between n. reticularis dorsally and the zona incerta ventrally. Caudad, n. subthalamicus shrinks in size, and its cells mingle with those of the substantia nigra. Observations on the structure of n. subthalamicus of *Elephantulus myurus* as well as *Tupaia spp.* in this study are not different from those of Bauchot. Here, the phylogenetic state of the subthalamic nucleus is more primitive than it is in the prosimians, although there are some discernible differences in size and topography between non-primate and primate forms.

Feremutsch (1963) states that as one ascends the primate scale, n. subthalamicus appears to be progressively larger and better encapsulated, although its topographical relationships and cytological features are more or less identical in all species. He observes a very close relationship between n. subthalamicus and the zona incerta; these two structures are connected more closely with the hypothalamus than with the thalamus. For instance, in *Lemur macaco*, n. subthalamicus lies so close to the zona incerta that it comes into direct contact with the dorsal hypothalamic area. In this same species, n. subthalamicus is shaped like a slender spindle, making it appear narrower in outline than that of *Lemur catta*. As my observations of n. subthalamicus and its relationships with the zona incerta and hypothalamus in these prosimians confirm those of Feremutsch, there is no need for further discussion.

In *Perodicticus potto*, Bauchot (1967) states that n. subthalamicus is a very well defined formation, not only by its peripheral capsule, but also by its architecture and dimorphic character. Bauchot observed that the parapeduncular part (lateral part) of n. subthalamicus contains larger, more lightly staining and more oval-shaped cells than those of the para-incertaine part (medial part) of the same nucleus. However, this cytological differentiation has not been observed in the same species used in this study. My observations of n. subthalamus being monomorphous and isoformic in the tupaioids and all primate species conform well with Feremutsch's observations. However, Feremutsch states that there are varying degrees of anisoformity in some species.

for example, in some lorisoids such as *Loris tardigradus* and *Perodicticus potto*, and in the Pongidae.

2. *N. zonae incertae* (ZI) (Plates 2 - 50)

(1) INSECTIVORA

Elephantulus myurus

N. zonae incertae (Figs.35 - 38)is a well developed structure that can be divided cytoarchitectonically into medial and lateral parts. The *lateral* part is related to the thalamus while the *medial* part is applied closely to the dorsal hypothalamic area. In both parts, the cells are fusiform, stain rather well, and are packed more densely in the medial than in the lateral part. The fibres of n. mamillo-thalamic tract run through the lateral part of n. zonae incertae on its way to the mamillary region.

(2) TUPAIOIDEA

N. zonae incertae (Figs.45 - 50)is not as well developed as in the Insectivora. It does not extend farther caudally. It is concentrated into a small, diffuse area of medium-sized, darkly staining, fusiform-oval cells (18 x 13 $/^{u}$) that lie just dorsal and lateral to the roof of the third ventricle, and ventral to n. reuniens. These cells are arranged in neat rows with their long axes directed mediolaterally. In myelin-stained preparations, n. zonae incertae appears to be reticulated and more lightly staining than n. entopeduncularis.

(3) PROSIMII

(a) *Lemuroidea and Lorisoidea*

In *Lemur* spp. and *Perodicticus potto*, *n. zonae incertae*(Figs. 73 - 76; 87 - 92) commences at the level of the rostral pole of n. mediodorsalis as n. reticularis pars ventralis is shifted towards the lateral surface of the thalamus. N. zonae incertae is intimately related to n. subthalamicus ventrally, to n. reticularis laterally, and to n. peripeduncularis ventrolaterally which separates it from n. pregeniculatus. N. zonae incertae consists of a double band of mediolaterally orientated, large, well staining, spindle-shaped cells (20 x 9 μ). Farther caudally, n. zonae incertae comes to be related ventrally to n. ventralis posterolateralis from which it is separated by the field H_1 of Forel. As the medial geniculate body makes its rostral appearance, n. zonae incertae disappears, together with n. subthalamicus and the fields of Forel.

(b) *Galagidae*

In these species, *n. zonae incertae* (Figs. 99-102; 109-112) shows clearly a dimorphic character, whereas it is monomorphous and isoformic in the Tupaioidea, and heteromorphic in the Lemuroidea and Lorisoidea. N. zonae incertae is divided into a medial and a lateral part, which are more pronounced in *Galago demidovii* than in other galagids. In this species, the cells of the medial part are small, deeply staining and spindle-shaped, and are packed parallel to the direction of the fibres. The lateral part contains larger cells that are loosely arranged among the densely myelinated horizontally running fibres. In *Galago senegalensis* and *Galago crassicaudatus*, n. zonae incertae appears as a broom-like structure, the wide end of which points medially, and the 'stick' is attached to the ventral part of n. reticularis. N. zonae incertae is related ventrally to the cerebral peduncle, dorsally to the periventricular grey matter of the thalamus, and laterally to the third ventricle and the dorsolateral hypothalamic area. Caudad, n. zonae incertae broadens out into a well defined band consisting of medium-sized (17 x 8 μ), dark-staining and fusiform cells. At this level, the relationships of n. zonae incerta to other structures are changed. There, n. zonae incertae lies dorsal to n. subthalamicus and the field H_1 of Forel, ventral to nn. centrum medianum and parafascicularis, and medial to the posterior hypothalamic and mamillary regions. The cells are scattered more loosely than those in the rostral region of the zona incerta. N. zonae incertae disappears at the caudal level of n. subthalamicus.

(4) ANTHROPOIDEA

(a) Cercopithecoidea

(i) *Cercopithecus aethiops*

N. zonae incertae (Figs. 119-122) is a narrow band of small to medium-sized cells (17 x 8 μ) that stain rather palely and are fusiform; these cells lie in the same circumferential lamina as n. reticularis. These two nuclei are, however, not contiguous with each other, as n. zonae incertae often overlaps the caudal part of n. reticularis for a considerable distance. N. zonae incertae is also interposed between the fields of Forel. Caudad, n. zonae incertae extends as far as n. ruber, where its lateral part merges with n. peripeduncularis, and its medial part with the field H_1 of Forel.

(ii) Hominoidea

Homo sapiens

N. zonae incertae (Figs. 129-132) is a small strip of diffusely arranged, small, palely staining and fusiform cells situated between the thalamic and lenticular fasciculi. N. zonae incertae is, however, more clearly divided, than in *Cercopithecus aethiops*, into a medial and a lateral part. The *medial* part lies dorsal to n. reticularis with which it becomes continuous laterally and caudally, and the *lateral* part is related closely to nn. geniculatus medialis and peripeduncularis. N. zonae incertaeis cytoarchitectonically dimorphous and markedly anisoformic, for the cells in its caudal part tend to mingle with those of the reticular formation of the midbrain.

Discussion on n. zonae incertae

In Insectivora, n. zonae incertae is a relatively simple structure which appears to be divided into two distinct parts - a *dorsal* part lying caudal to n. reticularis and a *ventral* part rostral to n. perifornicalis, connected to it by a thin strand of cells.

The ventral part is further divided into a *medial* portion which is more cellular than the *lateral* portion. In *Elephantulus myurus*, the division of the zona incerta into dorsal and ventral parts has not been observed. The *dorsal* part obviously corresponds to the ventral segment of n. reticularis, with which n. zonae incertae is intimately connected as seen not only in this insectivore species, but also in tupaioid and prosimian spp. used in this study. The *ventral* part itself is possibly the entire nucleus of the zona incerta.

Le Gros Clark (1929, 1930) did not describe the zona incerta in either *Tupaia minor* or *Tarsius*. In *Tupaia glis* and *Galago demidovii* (Bauchot 1963), and in *Galago senegalensis* and *Nycticebus coucang* (Kanagasuntheram et al 1968), the zona incerta is a double band of transversely orientated cells that are related medially to the ventral part of n. reticularis, to n. pregeniculatus, and ventrally to n. subthalamicus and the cerebral peduncle. In *Lemur macaco*, Feremutsch (1963) describes the zona incerta as a well-developed structure which appears to be a ventromedial continuation of n. reticularis which it resembles cytologically. Since n. zonae incertae is related laterally to the rostral pole of n. geniculatus medialis, it has been often regarded as a part of the latter structure by Schneider (1970) in the Cercopithecoidea. Cytoarchitectonically, the zona incerta is a dimorphic structure, and towards the median plane, it shows a marked tendency towards heteromorphism, due to its close relationship to both nn. ventralis posterolateralis and geniculatus medialis. In other prosimian specimens studied by Feremutsch (1963), the zona incerta shows a similar organization to that in my specimens. N. zonae incertae is rather superficially situated, except in *Microcebus murinus*, where it is applied more closely to n. subthalamicus than to nn. pregeniculatus and reticularis. In *Propithecus verreauxi*, the zona incerta is shorter in its dorsoventral extent, and is connected closely to the hypothalamus. In all their prosimian species, Feremutsch and other authors did not describe the cellular division of n. zonae incertae into medial and lateral parts which are well observed in the same species used in this study. The superficial position of n. zonae incertae to n. subthalamicus has not been observed in *Microcebus murinus* in this study, because there is a considerable amount of cells and fibres belonging to the fields of Forel that separate these two structures.

In the Cercopithecoidea, the zona incerta is better differentiated, and continues directly and laterally into n. reticularis. It is broader in its medial than in its lateral portion and protrudes into the anterior hypothalamic region. Caudad, n. zonae incertae is intimately related with the tegmental areas of the mesencephalon. The zona incerta is more dimorphous than that of lower primates. However, Feremutsch maintains that n. zonae incertae has a heteromorphous character which happens to be more pronounced in *Cercopithecus aethiops* and *Macaca mulatta* than in other cercopithecoids, because the medial and lateral parts of the zona incerta are cytologically and architectonically different from each other. However, these features are not observed in my cercopithecoid species in which the zona incerta appears to be more heteromorphous, i.e., all the cells of n. zonae incertae are distinctly grouped into two parts which differ from each other cytologically and cytoarchitectonically.

In anthropoid apes and man, Feremutsch (1963) notices that the zona incerta is not as well distinguishable as n. subthalamicus in regard to position and form, because n. zonae incertae has marked cytoarchitectonic differences from that of lower forms in the chimpanzee, the zona incerta is monomorphous and isoformic; in the gorilla, it is more dimorphous caudally than rostrally, while in the orang-utan, it is entirely dimorphous. Kanagasuntheram and Wong (1969) compare the zona incerta of the Hylobatidae with that of the Galagidae, and find in the former species that n. zonae incertae may be monomorphous rostrally and dimorphic caudally, while in the Galagidae, it remains isoformic in its rostrocaudal extent. Feremutsch (1963) maintains that in man, the zona incerta is dimorphous and anisoformic throughout its whole anteroposterior extent, although it tends to be heteromorphous in its caudal region where its cells mingle with those of the mesencephalic tegmentum. The description of n. zonae incertae in this study confirms his observation, as the caudal part of n. zonae incertae appears to be more markedly heteromorphous than dimorphous or monomorphous as in other primates.

3. Nn. campi Forelii or the fields of Forel (FF, H_1, H_2) (Plates 4 - 51)

(1) INSECTIVORA

Macroscelidoidea

Elephantulus myurus

The fields of Forel (Figs. 39-40) are poorly defined and recognized only by their association with the ansa lenticularis. These fields are continuous laterally with the zona incerta, dorsally with the external medullary lamina, and medially with the dorsal hypothalamic area. The fasciculi lenticularis and thalamicus connect the fields of Forel with the basal ganglia and thalamus respectively.

(2) TUPAIOIDEA

The fields of Forel spread out in a broader and more rectangular area. They are still not clearly distinguishable from each other, although the fasciculi thalamicus and lenticularis are beginning to separate them into H_1 and H_2 fields as in primates.

(3) LEMUROIDEA AND LORISOIDEA

In Microcebus murinus, the fields of Forel (Figs. 55-58) are better differentiated cellularly than in the Tupaioidea, but in other prosimians, particularly Galago demidovii, the fields are not clearly delimited topographically from each other. In larger prosimians, such as Perodicticus potto and Galago crassicaudatus, the fields H_1 and H_2 (Figs. 89-94; 101-102) are well defined areas. Field H_1 lies between nn. zonae incertae and ventralis posterolateralis, while field H_2 is interposed between nn. zonae incertae and subthalamicus The cells of field H_1 are larger in Lemur spp. (21 x 9 $/^{u}$) than those in Galago spp. (12 x 8 $/^{u}$), and in both species, these cells are generally dark-staining and fusiform in shape. The cells of field H_2 are more or less the same in size, being medium-sized (17 x 10 $/^{u}$) and more lightly staining, and less spindle-shaped than those of field H_1.

(4) ANTHROPOIDEA

The fields of Forel (Figs. 119-122; 129-134) are represented by dense fibrous areas lying anterior to n. ruber and ventral to the substantia nigra. The fields H_1 and H_2 are separated by the zona incerta in their rostral and lateral areas, while they converge caudally and medially towards the region of the red nucleus, at the level of which they disappear, being replaced by the prerubral area. In Cercopithecus aethiops, the dorsally situated field of Forel (H_1) contains large (19 x 10 $/^{u}$) cells that are dark-staining and fusiform, and are rather densely packed towards the hypothalamic regions. The cells of field H_2 are smaller (16 x 10 μ), stain rather palely, and are irregularly polygonal, and are scattered loosely in the area between n. subthalamicus and the zona incerta.

Discussion on the fields of Forel

The fields of Forel are not discussed very much in the literature on the primate diencephalon. Feremutsch (1963) could not distinguish the fields of Forel clearly from the zone incerta, but found many large cells lying in the medial region of the zona incerta that might indicate their presence in lower primates. However, he insists that the subthalamus is the least properly investigated diencephalic region despite its rich connections with the subcortical structures such as the corpus striatum and olfactory areas of the telencephalon. Feremutsch doubts that the fields of Forel should form a part of the subthalamus, as they are too diffuse and heteromorphous to be classified properly as nuclear structures. However, in this study, there is such a constant relationship between the fields of Forel and the zona incerta that the former structure can be distinguished rather clearly from other subthalamic and mesencephalic formations. The development of fields H_1 and H_2 is related to the increased influx of fibres from the striatal regions and all other parts of the brain to the thalamus. In all primate species studied here, the fields of Forel appear to be better defined myelo-architectonically than cytoarchitectonically, since they are enriched with numerous myelinated fibres from the lenticular and thalamic fascicles. The cellular density of the fields of Forel is lower than in other subthalamic structures, owing to this fibrous concentration, and also to the various sizes, shapes and density of the cells in these structures.

5. N. entopeduncularis (EP) (Plates 4 - 46)

In all species studied here, n. entopeduncularis shows little structural differentiation, except that there is a definite shift in its topographical position.

(a) Elephantulus myurus

In this species, n. entopeduncularis is situated in the rostrodorsal part of the thalamus at the level of the caudal preoptic region. It is a large, rather diffuse mass of cells lying dorsolateral to n. preopticus lateralis; its cells are rather small, moderately well staining, fusiform and arranged loosely among the fibres of the internal capsule above the cerebral peduncle. In myelin-stained sections, n. entopeduncularis gives a reticulated appearance that distinguishes it more readily from the more densely myelinated medial part of the globus pallidus.

(2) TUPAIOIDEA

N. entopeduncularis (Figs.43-50) is the most rostrally situated structure of the subthalamic group, and appears at the rostral level of the supraoptic region. N. entopeduncularis is a diffuse mass of medium-sized cells (18 x 13 μ) that are mostly round and lightly staining, and are arranged loosely among the reticulated fibres. N. entopeduncularis is intimately related to the ansa lenticularis which lie dorsolateral to it. The lateral hypothalamic area is its medial relation throughout its whole rostrocaudal extent. N. entopeduncularis disappears at the rostral level of n. subthalamicus.

(3) PROSIMII

(a) Lemuroidea

N. entopeduncularis (Figs. 69-70; 81-84) appears rostrally to n. subthalamicus. It lies medial to the lateral hypothalamic area, and lateral to the large-celled, dark-staining medial division of the globus pallidus. The cells of n. entopeduncularis are very large (23 x 16 µ), stain well and are mostly oval-shaped, and are scattered loosely among the fibres of the internal capsule dorsal to the optic tract. These cells can be distinguished from those of the globus pallidus by being smaller, more lightly staining and more loosely arranged among the fibres of the internal capsule. The fibres of the fasciculus lenticularis (FL), coursing through this nucleus, concentrate more heavily there than in other subthalamic areas. Caudad, n. entopeduncularis continues beyond the globus pallidus and terminates just rostral to n. subthalamicus at the level of n. premamillaris.

(b) Lorisoidea

(i) *Perodicticus potto*

N. entopeduncularis (Figs. 85-86) shows similar topographical and cytological characteristics as in the Lemuroidea. It appears at more rostral levels of the diencephalon, at the same place as nn. ventralis anterior and reticularis pars ventralis, than in other primates. N. entopeduncularis lies medial to the globus pallidus and putamen, dorsal to the optic tract, and lateral to the medial forebrain bundle and lateral hypothalamic area.

(c) Galagidae

N. entopeduncularis (Figs. 97-100; 107-110) appears subjectively to be a larger structure. It may be much larger in *Galago crassicaudatus* than in other *Galago* spp., and is even better developed with a longer rostrocaudal extent than in the lemurs, lorises and tupaiids. However, its topographical relationships with adjoining diencephalic structures do not differ from those in other prosimians. Its cells are mostly medium-sized (14 x 9 µ), stain lightly, and are oval or polygonal in shape; they are scattered loosely among thick fibre bundles. N. entopeduncularis disappears as n. pregeniculatus is shifted ventrally, and the cerebral peduncle increases in length.

(4) ANTHROPOIDEA

In Cercopithecus aethiops and Homo sapiens, n. entopeduncularis is associated very closely with the ansa lenticularis. Its cells are very large (22 x 10 μ), stain very palely, and are fusiform in shape; these cells may resemble those of the medial segment of the globus pallidus. At rostral levels, n. entopeduncularis is coincident with the medial edge of the anterior commissure, as the latter runs caudolaterally towards the amygdaloid area.

Discussion on n. entopeduncularis

N. entopeduncularis is a very well developed oval-shaped formation which has a stable phylogenetic history in Primates. In Insectivora, it appears in the fibre system of the ansa lenticularis; Bauchot (1963) considers it as the caudal pole of the globus pallidus. It is difficult to find the homologue of the entopeduncular nucleus in different mammalian species, due to its cellular resemblance to the globus pallidus. N. entopeduncularis, described in Tupaia minor by Le Gros Clark (1929) and in the opossum by Bodian (1939), lies much farther rostrally than those in insectivores and primates, and therefore, it appears to form the medial segment of the pallidum. However, the cells of n. entopeduncularis are much smaller, better staining and are more scattered than those of the globus pallidus; this cytoarchitectonic difference marks its distinguishing feature which is observed in all primate species in this study. Other distinguishing features of n. entopeduncularis are its most anterior extent in the diencephalon and close relationships to the internal capsule, ansa lenticularis and cerebral peduncle. Bauchot (1963) does not recognize the presence of n. entopeduncularis in Tupaia glis but in Galago demidovii; in the latter species it is more massively developed and situated superficially at the caudal level of the medial forebrain bundle.

4. N. peripeduncularis (PP)(Plates 4 - 46)

The question of relationship between nn. entopeduncularis and peripeduncularis is whether n. entopeduncularis is continuous with n. peripeduncularis caudally or not. It has been observed here that there is a considerable interval of space between these two nuclei. N. peripeduncularis lies immediately medial to the ventral pole of n. geniculatus lateralis, and dorsal to n. subthalamicus, while n. entopeduncularis is related rostrally to, and terminates before, n. subthalamicus. Therefore, n. peripeduncularis is not related, in any respect, to n. entopeduncularis, although they form integral parts of the subthalamus.

(1) INSECTIVORA

Macroscelidoidea

Elephantulus myurus

N. peripeduncularis (Figs. 39-40) is a small and insignificant nucleus lying between nn. entopeduncularis, subthalamicus and pregeniculatus. The cells of n. peripeduncularis are generally small, lightly staining, fusiform and packed together into a wedge-shaped area whose axes are pointed dorsoventrally. N. peripeduncularis is more lightly myelinated than its dorsal part, and denser than n. pregeniculatus.

(2) TUPAIOIDEA

N. peripeduncularis is large and triangular in shape. Its cells are rather large (17 x 9 $/^{u}$), deeply staining and spindle-shaped; they lie along the dorsolateral surface of the cerebral peduncle, lateral to the substantia nigra and medial to n. geniculatus medialis.

(3) PROSIMII

Lemuroidea and Lorisoidea

N. peripeduncularis can be identified with some difficulty, between n. pregeniculatus dorsolaterally, n. zonae incertae dorsomedially and the cerebral peduncle ventrally. The cells of n. peripeduncularis are very similar to those of the substantia nigra, being medium-sized (15 x 7 μ), dark-staining and fusiform; they are arranged regularly along the horizontal fibres which connect n. peripeduncularis with the zone incerta and n. subthalamicus. Caudally, n. peripeduncularis interposes between n. geniculatus lateralis medially, and the zona incerta laterally. It runs for a very short distance, and ends almost immediately at the level of the caudal pole of n. pregeniculatus.

In *Galago* spp., *n. peripeduncularis* (Figs.101-102; 111-112) varies in size and shape. In *Galago crassicaudatus*, it appears to be larger and better defined than in other galagids. Its topographical relationships are, however, not different from those in other prosimians. The cells of n. peripeduncularis are much larger and more darkly staining than those in the Lemuroidea (18 x 8 μ).

N. peripeduncularis disappears at the level of the caudal end of n. pulvinaris inferior.

(4) ANTHROPOIDEA

(a) *Cercopithecoidea*

Cercopithecus aethiops

N. peripeduncularis (Figs.123-124) replaces the zona incerta at the level where the former structure bends out to lie medial to the lateral geniculate body. It is related ventrally to the medial lemniscus and medially to n. reticularis. Caudad, n. peripeduncularis turns dorsally through the medial lemniscus to enter the lateral tegmental region where it dissipates itself. The cells of n. peripeduncularis are large (18 x 10 μ), and stain more darkly than those of the zona incerta.

(b) Hominoidea

Homo sapiens

N. peripeduncularis of man does not differ greatly in structure and topography from that of monkey and ape. Although this nucleus is comparatively smaller and contains fewer cells, its cells are large, intensely staining and spindle-shaped, and are packed very closely into a small area between the cerebral peduncle and medial lemniscus ventrally and the medial geniculate body dorsally.

Discussion on n. peripeduncularis

In his primate species, Feremutsch (1963) does not mention the fields of Forel and n. peripeduncularis, since they are included in his ventral thalamus. As n. peripeduncularis reduces in size on progressing up the primate scale, it is more difficult to distinguish it from n. pregeniculatus which, likewise, reduces in size and structure. In *Perodicticus potto*, Bauchot (1967) describes n. peripeduncularis as a caudal and dorsolateral part of the zona incerta that surrounds the cerebral peduncle; its cells are oriented concentrically on the peduncular surface of the latter structure. Kanagasuntheram et al (1968, 1969) term n. peripeduncularis their *n. peduncularis pars medialis*, which, in the Hylobatidae, is represented by a cluster of large and dark-staining cells that lies medial to the cerebral peduncle, and ventral to the fields of Forel and the caudal part of the lateral hypothalamic area.

In my studies, n. peripeduncularis does not occupy a position *medial* to the cerebral peduncle, as stated by Kanagasuntheram et al (1969), as this area is a part of the lateral hypothalamic region. In all species used in this study, n. peripeduncularis has been observed to lie between n. pregeniculatus laterally and the dorsolateral surface of the cerebral peduncle. N. peripeduncularis is hardly described or mentioned in the literature dealing with the human diencephalon.

SUMMARY OF THE SUBTHALAMUS

The subthalamus shows a more or less stable phylogeny throughout the primate scale, although there are some slight variations in its topography and relationships with the thalamus and hypothalamus. The most interesting evolutionary feature of the subthalamus is the subthalamic nucleus. In Elephantulus myurus, n. subthalamicus develops from a very small, round and homogeneous mass of medium-sized, well staining, polygonal cells to a very large, egg-shaped, rather heterogeneous nucleus in man. In Prosimii, n. subthalamicus is very well developed and shaped like an eye; there are no or little variations in its structure or topographical relationships with other diencephalic structures. During the progressive expansion of the thalamus, n. subthalamicus appears to be less rostrally situated than in the Tupaioidea and Insectivora. In higher primates and man, n. subthalamicus is situated farther caudally than the mamillary region, i.e. it appears either at the level of the interpeduncular nucleus or of the rostral pole of the red nucleus.

The zona incerta remains fundamentally the same throughout the primate scale, but is divided more clearly into medial and lateral parts in higher than in lower primates. In Elephantulus, the field of Forel is not separated into two fields; only one field - the field H_1 - is present. The fields of Forel (fields H_1 and H_2) become increasingly differentiated from each other as one ascends the prosimian scale to monkeys, apes and man. In higher primates, the fields of Forel are very well formed structures.

N. peripeduncularis is not easily identified in all prosimians up to the Lemuroidea, because the relationship of the cerebral peduncle to the optic tract changes with the progressive expansion of the thalamus. Finally, in higher forms, n. peripeduncularis can be seen as an isolated group of large, lightly staining, polygonal cells lying along the dorsolateral surface of the cerebral peduncle medial to the lateral geniculate body. N. entopeduncularis is identified without difficulty in all species, and is the most anteriorly situated subthalamic component. It may be more closely identified with the globus pallidus than with the subthalamus.

The structural features, cyto- and myeloarchitectonic differences and evolutionary trends of the subthalamic nuclei are further referred to in Table 22.

TABLE 22: COMPARISONS OF THE SUBTHALAMIC NUCLEI

FEATURES	N. subthalamicus (S)	N. zonae incertae (ZI)	N. campi Forelli (FF, H_1, H_2)	N. entopeduncularis (EP)	N peripeduncularis (PP)
STRUCTURAL FEATURES	In Elephantulus, S is a prominent, oval structure based dorsally on the cerebral peduncle. In Tupaia and Prosimii, S is much larger and lenticular in shape. It has the same topographical relationships with ZI, FF and n. pregeniculatus throughout the primate scale. It is concave dorsally and flattened ventrally; well encapsulated on all sides, except on its medial side, where it is continuous with the fields of Forel and the hypothalamus.	In Elephantulus, ZI is a well developed structure which is divided into medial and lateral parts. In Tupaia, it is comparatively ill-defined and shaped like a horn, whose tip reaches towards n. reticularis. In lower prosimians, ZI is better defined, and more fibrous in its lateral part and more cellular in its medial part. In higher prosimians, these two parts are more clearly separated from each other myelo- and cyto-architectonically. In higher primates and man, ZI is much narrower, and its lateral part overlaps n. reticularis in its caudal part, and is continuous with PP.	In Elephantulus and Tupaia, FF are poorly developed, and contain only one field - the prerubral field. It is recognized only by its association with the ansa lenticularis. In Tupaia, however, FF may be separated in its medial part into fields H_1 and H_2. In lower prosimians, FF are not well separable into fields H_1 and H_2. In higher prosimians, these fields are better defined and continue to be so in all anthropoids. In man, these fields are large and very distinctly formed.	EP does not vary much in structural features from Elephantulus through Tupaia and all prosimians to higher primates and man. EP is the most rostrally situated subthalamic structure, and closely associated with the globus pallidus.	In Elephantulus, PP is a small, triangular structure lying between EP and S, and n. pregeniculatus. In Tupaia and all prosimians, PP is much smaller and shaped like a wedge lying between the substantia nigra and cerebral peduncle medially, and n. pregeniculatus laterally, and ZI dorsally and the ventral surface of the diencephalon ventrally. In higher primates, it reduces further in size, and does not change much in its topography and cytology.
CYTOARCHITECTONICS	In all species, cells of S are mostly medium-sized (16 x 9 /μ to 17 x 10 /μ). They stain moderately well are oval-shaped and are arranged compactly into rows along fibres that run mediolaterally. No change in cellular characteristics throughout the primate scale.	mixture of cells in prosimians - large, lightly staining and oval cells in the lateral part, and small, dark-staining and fusiform in the medial part. In higher primates, where these parts are fused, the cells are mostly medium-sized, dark-staining and fusiform (17 x 8 /μ in Cercopithecus to 20 x 9 /μ in Lemur). Cellular size and composition are lower in higher than in lower primate.	Cells in fields H_1 and H_2 differ from each other in size, shape and other features. Cells in H_1 are medium-sized to large (12 x 8 /μ in Galago and 21 x 9 /μ in Lemur), stain more darkly and are more polygonal than those in H_2. Cells in H_2 are smaller than those in H_1 (16 x 10 /μ in Tupaia). Cell size and stainability decrease on ascending the primate scale.	Cells are generally large, pale-staining and oval or polygonal, and resemble those of the medial segment of the globus pallidus. These cells are 15 x 9 /μ in Galago and 23 x 16 /μ in Lemur. Cell size and stainability decrease as one goes up the primate scale.	Cells of PP are smaller and more darkly staining than those of ZI (15 x 7 in Lemur to 18 x 8 /μ in Galago). In higher primates, cells decrease in size and stainability on going up the primate scale.
MYELOARCHITECTONICS	S is surrounded on all sides by a dense, fibrous capsule, and contains a fine meshwork of myelinated fibres coursing lateromedially throughout the nucleus from the telencephalic areas to the mid-brain and hypothalamus.	Fibres are arranged more densely in the lateral and dorsal than in the medial and ventral parts, and in a lateromedially or horizontally.	Fibres in field H_1 are arranged less densely than in field H_2, and run lateromedially from subcortical areas to the diencephalic regions.	In all species, EP is reticulated in appearance with transverse and horizontal fibre bundles running through it from the globus pallidus to the diencephalon. EP stains more lightly than n. pregeniculatus and globus pallidus.	Dense, horizontal fibres connect PP to ZI,S, and n. pregeniculatus. Is closely applied to the cerebral peduncle on its lateral aspect.
EVOLUTIONARY TRENDS	Stable phylogenetic character. Increases in size only.	Stable phylogenetic character. Variable cellular features.	Rather progressive in phylogenetic development	No significant phylogenetic changes.	No significant phylogenetic changes.

CHAPTER 16

THE HYPOTHALAMUS

Introduction

The hypothalamus, from the phylogenetic point of view, is one of the most ancient parts of the vertebrate forebrain. It is very intimately associated with the hypophysis cerebri or pituitary gland. The neural or posterior portion of this endocrine gland (neurohypophysis) is developed ontogenetically from the floor of the third ventricle. Conspicuous masses of nerve cells are differentiated in the grey matter surrounding the third ventricle to form a number of hypothalamic nuclei in close topographical relation to the infundibular stalk.

The hypothalamus is, therefore, a sort of complex ganglion which is directly associated with the hypophysis. This interpretation is reinforced by the fact that disturbances of hypothalamic activities are commonly associated with disturbances of fundamental vegetative functions such as carbohydrate and water metabolism, vasomotor and visceromotor reactions associated with emotional states. This neuro-glandular mechanism comprised of the hypothalamic nuclei and hypophysis does not change its basically important character throughout the vertebrate series.

The rostral and caudal limits of the hypothalamus are ill-defined, since it passes over without any sharp demarcation into the parolfactory region rostrally and into the tegmental region of the mesencephalon caudally. The lateral limits of the hypothalamus are also vague, for here, it is directly continuous with the subthalamus; sometimes this latter structure is classified with the hypothalamus. As the hypothalamus contains the grey matter immediately adjacent to the ventral part of the third ventricle, it has developed topographically in close relation to the hypophysis and the medial forebrain bundle. The medial forebrain bundle contains fibre connections between the olfactory areas and lower brain centres; it appears to represent the major longitudinal conduction tract of the hypothalamus. Similarly, the subthalamus is developmentally related to the lateral forebrain bundle which passes from the cerebral hemispheres to lower levels, and which links the subthalamus up with the corpus striatum and the neocortex. The lateral forebrain bundle of non-primate mammals is a direct homologue of the internal capsule in primates.

Difficulties arise in connection with descriptions of the comparative anatomy of the hypothalamus. In parvocellular hypothalamic regions of lower mammals, cytomorphological analysis is almost impracticable, as structural differences between small-celled areas, which even in higher mammals, are relatively undifferentiated, cannot be determined. The identification of such nuclei in lower mammals is usually based on a comparison with the nuclear pattern in higher mammals. Moreover, although in the vertebrate series the fundamental topographical nuclear pattern of the hypothalamus is preserved, there are variations in relative position, form and dimensions of nuclei from species to species. These variations are compatible with invariant functional connections. Furthermore, if such variations are observed within one and the same species these are likely to be the result of extraneous factors. In view of the rapid change in size and shape of cell groups in a sequence of serial sections, especially in small animals, it is conceivable that the observer's impression of the nuclear pattern will vary to a significant extent with variations in the plane of sectioning.

These considerations may explain the discrepancies between the regional and nuclear hypothalamic subdivions put forward by different authors. There is no doubt that within the regions of the hypothalamus, describable areas and nuclei with distinctive structural and cytoarchitectonic characteristics exist as distinct entities. But in cases of disagreement over these criteria, any given subdivision or structural differentiation of the hypothalamus must be regarded as tentative. As nuclei and areas in the hypothalamus do not vary much in prosimian species, nor in the insectivore Elephantulus myurus, they are described here in general terms; any variations in position, form and structure are mentioned specifically. The hypothalamic nuclei of the vervet monkey and of man are also briefly described, particularly where there are significant topographical and cytoarchitectonic differences.

In this study, as well as in the literature on the primate hypothalamus, despite the insufficient delimitation into regions, it is apparent that the hypothalamus is clearly subdivided at the level of the optic chiasma into two parts, prechiasmatic and postchiasmatic. The prechiasmatic part extends from the level of the anterior commissure rostrally to the level of the caudal part of the optic chiasma; it contains the preoptic and supraoptic regions, which together form the prothalamus or preoptico-supraoptic region (see Chapter 5). However, in this chapter, the preoptic and supraoptic regions are described as separate sections of the hypothalamus. The postchiasmatic part extends from the caudal border of the optic chiasma to the caudal end of the mamillary region, and contains the infundibular and mamillary regions. These regions are described in Chapter 17.

1. THE PRECHIASMATIC PART OF THE HYPOTHALAMUS (Plates 1-38; 69-72)

A. THE PREOPTIC REGION

Although the preoptic region belongs structurally to the unevaginated part of the telencephalon, it is here included with the hypothalamus because it cannot be demarcated topographically from the supraoptic region. The preoptic region extends from the parolfactory area and lamina terminalis rostrally to the region of the optic recess at the level of the rostral part of the optic chiasma caudally. The preoptic region is divided into medial and lateral nuclei, neither of which is clearly defined, though they can be distinguished cytoarchitectonically and cytologically from each other.

(a) N. preopticus medialis (POM)

This nucleus (Figs.33-34; 41-42; 71-72; 169-170) consists of three histologically distinct parts, principal, median and periventricular; these parts are termed nn. preoptici principalis or medialis, medianus and periventricularis for the sake of easier identification.

N. preopticus medialis commences at the level of the rostral part of the anterior commissure first as a median formation, n. preopticus medianus (POMd). However, if n. preopticus medialis is traced farther rostrally, it comes into relation with the diagonal band of Broca dorsally and medially. N. preopticus medianus is an unpaired cellular condensation lying immediately dorsal to the third ventricle; its cells are small, moderately dark-staining, fusiform and are packed closely together. In its ventral portion, these cells are arranged in vertical columns extending from the anterior commissure towards the preoptic periventricular area. N. preopticus medianus is related dorsally to n. preopticus periventricularis, from which it is not very well distinguished cytoarchitectonically, and medially to the interstitial nucleus of the medial forebrain bundle and to the lateral preoptic area.

N. preopticus principalis (POP) is the largest structure filling most of the medial preoptic area. In fact, it is the main body of n. preopticus medialis, while the other preoptic nuclei are only smaller extensions of the same nucleus. N. preopticus principalis contains mostly medium-sized, well-staining and round cells that lie lateral to the dorsal part of n. preopticus periventricularis. These cells are arranged more diffusely than those of other preoptic nuclei. N. preopticus principalis extends far into the supraoptic region as n. preopticus medialis itself, and is replaced by the dorsal hypothalamic area.

N. preopticus periventricularis (POMV) is a rostral extension of the hypothalamic periventricular system. It consists of diffusely arranged, dark-staining, fusiform and small cells that occupy the wall of the rostral part of the third ventricle. These cells are poorly differentiated from the ependymal lining of the third ventricle. The dimensions and cell density of this nucleus appear to be greatest in the ventral region adjacent to the supraoptic recess. In the dorsal region, the nucleus becomes narrower and less sharply defined, and it merges with n. preopticus medianus dorsally and with n. preopticus principalis laterally.

(b) N. preopticus lateralis (POL)

This nucleus (Figs. 33-34; 41-42; 71-72; 169-172) is the interstitial nucleus of the medial forebrain bundle. It can be subdivided cytoarchitectonically into an interstitial and a magnocellular portion, and is distinguishable cytologically from the medial preoptic area. N. preopticus lateralis appears in the region of the anterior commissure at more or less the same level as n. preopticus medianus. Its magnocellular portion (POLm) is easily identified by its conspicuously broad band of large, deeply staining pyramidal cells lying on the caudal border of the olfactory tubercle and on the diagonal band of Broca. The interstitial portion (POLi) lies dorsal and medial to the magnocellular portion. It is rather easily identified, and consists of medium-sized, rather lightly staining, oval cells that are arranged less compactly than the magnocellular portion. N. preopticus lateralis is replaced by the lateral hypothalamic area with which it merges imperceptibly.

In Elephantulus myurus, the preoptic region commences at the level of the rostral border of the anterior commissure and ends at the level of the caudal border of the optic chiasma. The preoptic region is more clearly divided into medial and lateral areas than in primates. The myeloarchitectonic differences in these areas are, however, slight. The lateral preoptic area contains a fine network of fibres coursing through it dorsoventrally from telencephalic areas. The cytoarchitectonic features distinguish it readily from the medial preoptic area by its larger, deeply staining and stellate cells that are distributed unevenly among the fibres.

In the Tupaioidea, the preoptic region has a shorter rostrocaudal extent. It merges insensibly with the supraoptic region at the level of the rostral border of the optic chiasma. The medial and lateral preoptic areas and their constituents can be easily identified. The cells of the medial preoptic area are the smallest in the hypothalamus, as well as in the entire diencephalon (8 x 5 $/^{u}$); they are round in shape and stain very lightly. The cells of the lateral preoptic area are larger (10 x 8 $/^{u}$), stain more darkly and are stellate or fusiform.

In the Lemuroidea and Lorisoidea, there are no significant structural or architectonic variations in the preoptic region among the species. The medial and lateral preoptic areas are not well demarcated from each other. The entire preoptic region is relatively short and compressed between the parolfactory region and the anterior hypothalamic region. The cells of the medial and lateral preoptic areas do not differ much from those of the Tupaioidea. In the medial preoptic area, the cells are generally small (9 x 6 $/^{u}$ in Lemur and Galago), stain lightly and are round in shape; they are packed together more densely in the median and periventricular parts than in the principal part. The cells of the lateral preoptic area are slightly larger (13 x 10 $/^{u}$ in Lemur and 14 x 10 $/^{u}$ in

Galago), and are more darkly staining and stellate in shape.

These preoptic areas are very lightly myelinated; fibres run in all directions, especially in the lateral preoptic area, appearing as a meshwork in myelin-stained sections.

In *Cercopithecus aethiops*, the preoptic region is more rostrally situated, even anterior to the anterior commissure and optic chiasma. However, compared with that of prosimians, the preoptic region is not well developed, and it is less clearly subdivided into medial and lateral areas. The medial preoptic area is composed mainly of small cells (9 x 6 μ) that are round and lightly-staining, and are arranged rather compactly along the wall of the third ventricle, preoptic recess and in the median plane ventral to the anterior commissure. The cells of the lateral preoptic area are mostly medium-sized (14 x 9 μ), darkly staining, stellate or fusiform, and are scattered all over this area. The lateral preoptic area contains dense fibre fascicles of the medial forebrain bundle that run through it towards the basal telencephalic areas.

In man, the preoptic region appears to be further compressed into a smaller space within the unevaginated part of the telencephalon (telencephalon medium). The anterior commissure constitutes the superior border of the preoptic region and separates it from the overlying columns of the fornix. The caudal border of the preoptic region cannot be defined, as it continues imperceptibly into the anterior hypothalamic region. At least, the lateral hypothalamic area appears to be a rostral extension of the lateral preoptic area and its nuclei, whereas the medial preoptic area is continuous with the basal olfactory area and the diagonal band of Broca.

Discussion on the Preoptic Region

Although the preoptic region is essentially a telencephalic formation, it is considered by many workers to be an integral part of the hypothalamus. As this region merges caudally with the supraoptic region, the nuclei and areas of both regions appear almost at the same time in any level of the chiasma. Therefore, my opinion is that the preoptic region should be regarded as a rostral part of the hypothalamus. The rostral border of the preoptic area, in all primate species, is better defined than the caudal border which varies from species to species. Some authors describe an interstitial nucleus of the stria medullaris (nist) in the preoptic region. Bauchot (1963, 1967), and Kanagasuntheram et al (1968) mention it in their prosimian species. Although it has been observed in my primate material, this nucleus is only a part of the telencephalon, and therefore, is not included in this study. Likewise, the interstitial nucleus of the inferior thalamic peduncle is not included with the preoptic region.

Smialowski (1972a) describes, in the macaque monkey, a cell layer in the lamina terminalis lying rostral and medial to the medial preoptic nucleus. Judging from the illustration in his paper, this cellular area can be regarded as a part of n. preopticus medialis, thus confirming the descriptions of this nucleus by Krieg (1948), Diepen (1962), Kanagasuntheram et al (1968) in different primate specimens.

N. preopticus periventricularis in Perodicticus potto (Bauchot 1967) is homologous to the anterior part of the periventricular area in all my prosimian species. In higher mammals, particularly primates, the cells of n. preopticus periventricularis are poorly differentiated from those of the ependymal lining of the third ventricle. The dimensions and cellular density of n. preopticus periventricularis appear to be greater in the ventral than in the dorsal region of the preoptic area, where this nucleus becomes much narrower in outline and merges with n. preopticus medianus lying above it.

The preoptic region is intimately connected with the olfactory tubercle, septum and adjoining anterior hypothalamic region, as well as with the piriform cortex (amygdala). No significant phylogenetic changes have been detected in all my primate species, except that it is slightly reduced in all dimensions, and that it is situated farther rostrally in the telencephalon with a better defined anterior than posterior border.

B. THE SUPRAOPTIC REGION

This region extends approximately from the level of the rostral margin of the optic chiasma to the tuber cinereum. Nn. supraopticus and paraventricularis figure most prominently in the supraoptic region, and they appear to be the only hypothalamic nuclei that are actively neurosecretory and are associated closely with neurohypophyseal functions. Included with these nuclei are nn. periventricularis anterior, suprachiasmaticus and supraopticus diffusus and the anterior hypothalamic area.

(a) N. supraopticus (SO)

This nucleus (Figs. 41-42; 61-62; 97-98; 10-108; 171-176) is very conspicuous in the rostral part of the prothalamus or preoptico-supraoptic region. Its topographical and architectonic features are more or less identical in the Tupaioidea and Prosimii. However, its rostral extent varies from species to species. In some prosimians, n. supraopticus commences as a small, flattish crescentic mass of cells lying around the optic tract in the preoptic region, while in others, it is stretched out rather thinly on the dorsal surface of the optic chiasma at the same level as n. paraventricularis. In all species, n. supraopticus extends caudalwards towards the rostral part of the infundibular region. It lies lateral to nn. suprachiasmatic and periventricularis anterior, ventral to the anterior and lateral hypothalamic areas, and medial to the globus pallidus. At the caudal level of the optic chiasma, n. supraopticus is replaced by n. supraopticus diffusus and lateral hypothalamic area.

N. supraopticus of *Tupaia* is much larger and more conspicuous, and has a longer rostrocaudal extent than that of *Elephantulus*. The cells of n. supraopticus are larger and more darkly staining (21 x 10 μ) in *Tupaia* than in *Elephantulus*. In *Perodicticus* and *Galago*, the supraoptic region extends farther rostrally into the preoptic region, and therefore, n. supraopticus comes to be related ventrally and medially to the lateral preoptic area, and laterally to the parolfactory area. In these species, n. supraopticus is differentiated clearly into ventromedial and dorsolateral parts. The *ventromedial part* contains mostly medium-sized, lightly staining, fusiform cells that are oriented parallel to the fibres of the optic chiasma. The *dorsolateral* part is much larger and less clearly separated from the ventromedial part in *Galago senegalensis* than in *Galago crassicaudatus*. Its cells are larger (16 x 11 μ on the average) and stain more deeply and are pyramidal; these cells are arranged perpendicularly to the optic chiasma.

In all prosimian species, the cells of n. supraopticus, like those of n. paraventricularis, are characterised by the presence of colloid vacuoles and by peripherally aligned Nissl granules in the cytoplasm. N. supraopticus is generally lightly myelinated in all

running through it. In *Galago demidovii* and *Lepilemur*, a small and poorly defined bundle of fibres (Figs. 15-16) can be observed between n. supraopticus and n. paraventricularis; this fibrous connection may form a part of the hypothalamico-hypophyseal tract.

In *Cercopithecus aethiops* and man n. supraopticus commences at a more caudal level than in lower primates. It extends rostrally to the rostral border of the optic chiasma, and caudally to a much more caudal level in the infundibular region than that of lower primates. N. supraopticus is split by the optic chiasma into a large anterolateral and a small posteromedial part, which are connected with each other by a thin strand of cells. The cells of n. supraopticus in *Cercopithecus aethiops* are large (19 x 10 μ), stain moderately well and are oval in shape. Colloid vacuoles and peripherally arranged Nissl granules are observed in these cells. The cells of n. supraopticus are packed together densely along the dorsolateral border of the optic chiasma. In man, nn. supraopticus and paraventricularis are situated so closely to each other that a string of cells is observed extending from one to the other. This cellular connection is augmented by the presence of a well defined fibre bundle lying between these neurosecretory nuclei - possibly a part of the hypothalamico-hypophyseal tract.

Discussion on n. supraopticus

In spite of its close proximity to the optic tract, n. supraopticus does not have any functional relationship with the visual system. In most mammalian species, n. supraopticus is a complicated structure, as it appears to comprise two separable cellular masses. The first cellular mass is situated dorsally and laterally to the optic tract, and extends rostrally above the optic chiasma in the preoptic region - this is the dorsolateral part of n. supraopticus. The second cellular mass, the ventromedial part of n. supraopticus, lies ventral and medial to the optic tract, and caudal to the optic chiasma. These two parts are connected rather indistinctly with each other by a narrow band of cells, the "supraoptic isthmus", which stretches along the dorsal border of the optic chiasma and tract. This cellular band has been termed n. supraopticus diffusus by most authors. In primates, the dorsolateral part of n. supraopticus is relatively well developed and massive, and represents the main body of the nucleus, while the ventromedial part is merely a small collection of cells that may have drifted away from the main mass during phylogeny of the diencephalon.

In the Insectivora, n. supraopticus is not as well developed as in the Prosimii. However, in *Elephantulus*, the dorsolateral part is larger and better defined than the ventromedial part of n. supraopticus as compared with those of the same nucleus in Talpa (hedgehog). In the latter species, as well as in all lipotyphlan insectivores, n. supraopticus does not have the well differentiated tuberal and isthmal parts. Bauchot (1963) states that the reduction in functional importance of this nucleus does not coincide with the poor development of visual centres, as it is not connected at all with the evolution of the visual system; its reduced size may correlate only with the absence of neurosecretory activity and with the presence of a smaller hypophysis in these lipotyphlans.

Le Gros Clark (1929) limited his study of the hypothalamus in Tupaia minor to a few nuclei, particularly those belonging to the supraoptico-infundibular areas. His n. tangentialis is homologous to n. supraopticus, while his n. hypothalamicus magnocellularis appears to synonymize with n. paraventricularis in the literature on the hypothalamus. The lateral parvocellular part of n. paraventricularis in my tupaioid and prosimian specimens may homologize with Le Gros Clark's n. filiformis (fil). Both nuclei are equivalent to n. hypothalamicus parvocellularis of Kaelber (1966) and of Kanagasuntheram et al (1968). Le Gros Clark had n. supraopticus split up into pre- and postchiasmatic parts which correspond well with the dorsolateral and ventromedial parts of the same nucleus in my tupaioid specimens, but he did not mention the presence of an isthmus linking these two parts.

In Propithecus and Loris tardigradus, Feremutsch (1955, 1957) describes n. supraopticus as a monomorphous and slightly anisoform structure with a poorly developed "bed nucleus". Kanagasuntheram et al (1968) observed in Galago senegalensis and Nycticebus coucang that there is a band of cells overlying the optic tract caudal to the dorsolateral part of n. supraopticus. This cellular band may be actually n. supraopticus diffusus, as its cells are smaller, more lightly staining and fusiform than those of the supraoptic isthmus.

In higher primates, the cellular connection between the two parts of n. supraopticus has not been described by most authors. However, Smialowski (1972b) does state that n. supraopticus of the macaque monkey is divided into two separate parts, an anterior and a posterior, connected with each other by a narrow cellular bridge over the optic chiasma. These features do conform with those in my cercopithecoid specimen, thus establishing more firmly the fact that in the Primates, n. supraopticus consists of two cellularly distinct parts linked with each other by an isthmus; it is not at all connected with the supraoptic decussations that lie above the nucleus. Kanagasuntheram and Wong (1969) have reported that, in the Hylobatidae, the anterior and posterior parts do converge and meet each other dorsal to the optic tract. In man, n. supraopticus has been said to consist of three parts - dorsolateral, ventromedial and dorsomedial parts; the medial parts are linked together by a thin strand of cells, while the dorsolateral part is the main body of n. supraopticus (Gagel 1928, Kuhlenbeck and Haymaker 1949, and Macchi (1951). However, the dorsomedial part has not been observed in my primate species, and possibly it may be a dorsal extension of the ventromedial part over the surface of the optic tract. It is obvious from this study that, in the Primates, n. supraopticus shows a consistent pattern, and is clearly divisible into ventromedial and dorsolateral parts linked with each other by a cellular band lying on the dorsal surface of the optic tract.

(b) N. supraopticus diffusus (SOD)

In the Tupaioidea and the Primates, n. supraopticus diffusus (Figs. 49-50; 62; 73-74; 99-100; 109-110; 73-74) is a poorly defined structure which can be identified as a thin band of medium-sized, pale-staining, fusiform cells lying between the diverging optic tracts at the level of the caudal part of the supraoptic region. These cells are scattered among the fibres of the dorsal supraoptic commissure of Ganser, particularly in Perodicticus potto; this feature has been described in the same species by Bauchot (1967) who termed it *nucleus* or *area commissuralis postopticus*. In other prosimians, n. supraopticus diffusus has been described by many workers as a band of cells arranged spirally between the dorsolateral part of n. supraopticus in the supraoptic region, and the ventromedial part of the same nucleus in the infundibular region. In *Lemur*, n. supraopticus diffusus extends farther caudally into the rostral part of the infundibular region, where it disappears at the level of n. ventromedialis.

Note on the Supraoptic Commissures (Figs. 15-16)

Dorsal to the optic tract (and chiasma), there are several bundles of fine fibres crossing the midline - these constitute the hypothalamic or supraoptic decussations. The largest one is the *dorsal supraoptic decussation of Meynert* (DSC) which consists of fibres that arise from n. subthalamicus and pass to the contralateral globus pallidus. Immediately ventral to it, is the *ventral supraoptic commissure* of Gudden (VSC) which is closely applied to the dorsal surface of the optic tract and chiasma. Fibres of this commissure are apparently related to auditory pathways since they can be traced laterally into n. geniculatus medialis and its capsule. A third commissure, located somewhat rostrally is the *anterior hypothalamic commissure of Ganser* (ASC), whose entire composition is not known. Fibres of this commissure project ventromedially from Forel's field H, arch over the fibres of the fornix and enter the hypothalamus. It is presumed that these fibres arise from the medial segment of the globus pallidus.

All these supraoptic commissures are shown in the photomicrographs of the sections at the level of the rostral part of the infundibular region (Figs. 15 + 16). In *Lemur catta*, *Galago demidovii* and *Cercopithecus aethiops*, these commissures are well developed and are easily located where n. supraopticus diffusus marks the caudal level of the optic chiasma.

EXPLANATIONS OF FIGURES

Figure 15.

Transverse section through the supraoptico-infundibular part of the hypothalamus of *Lemur catta* to illustrate the presence of supraoptic commissures.

Note: Fibres of the anterior supraoptic commissure (of Ganser ASC) arise from the region of the globus pallidus (GP) and cross the midline in close association with fibres of the dorsal supraoptic commissure (of Meynert - DSC). The ventral supraoptic commissure (of Gudden - VSC) is a clearly discernible thick bundle of fibres that run along the surface of the optic tract (OT) towards the region of the entopeduncular nucleus (EP) to end in the medial geniculate nucleus.

Klüver and Barrera stain x80

Figure 16.

Transverse section through the supraoptico-infundibular part of the hypothalamus of Cercopithecus aethiops to illustrate the presence of supraoptic commissures of Meynert (DSC) and of Gudden (VSC).

Klüver and Barrera stain x80

Other abbreviations in Figures 18 and 19

AC - anterior commissure
HYPO - hypothalamus
INF - infundibulum
pav - n. paraventricularis hypothalami
3 - third ventricle

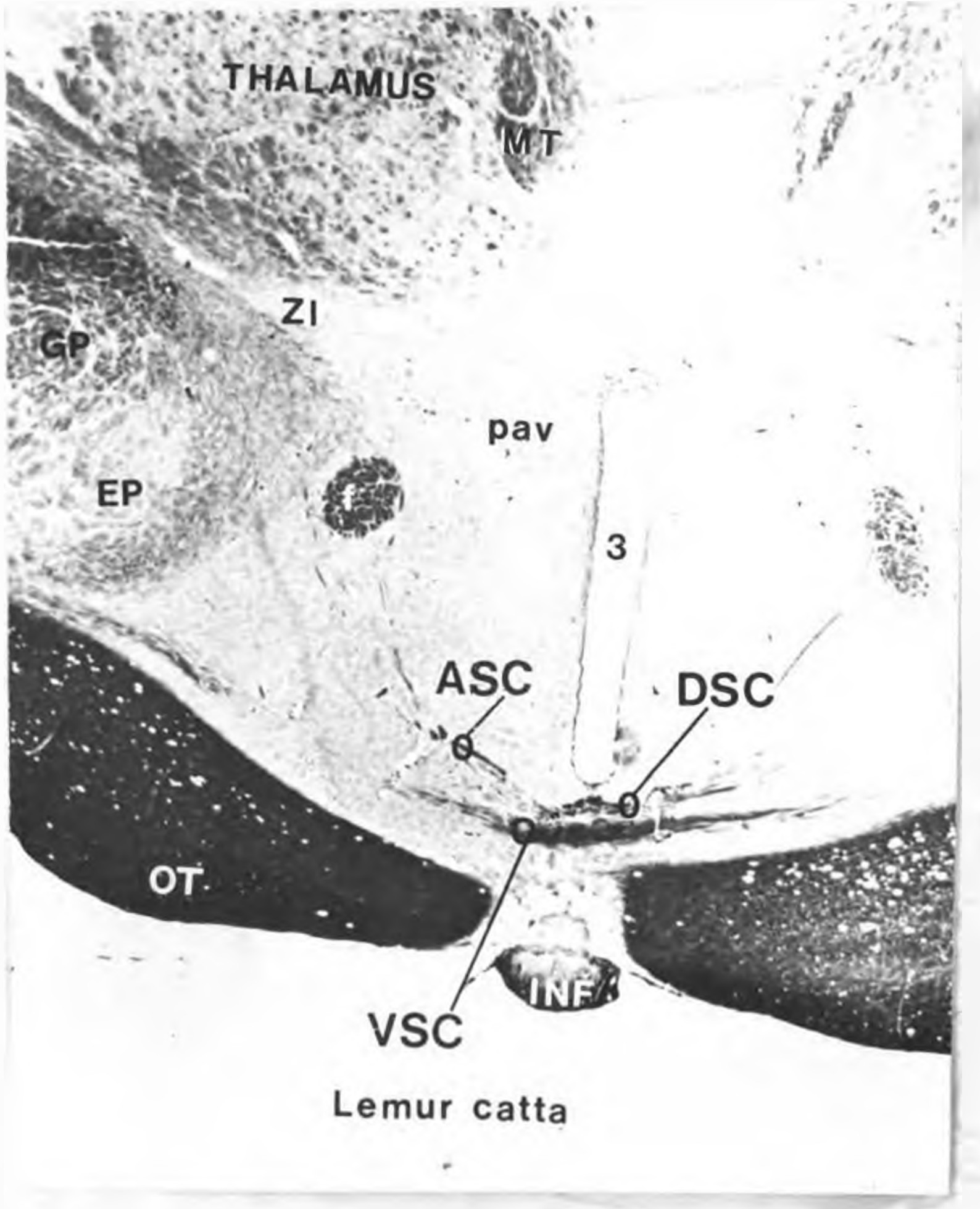

Figure 15.

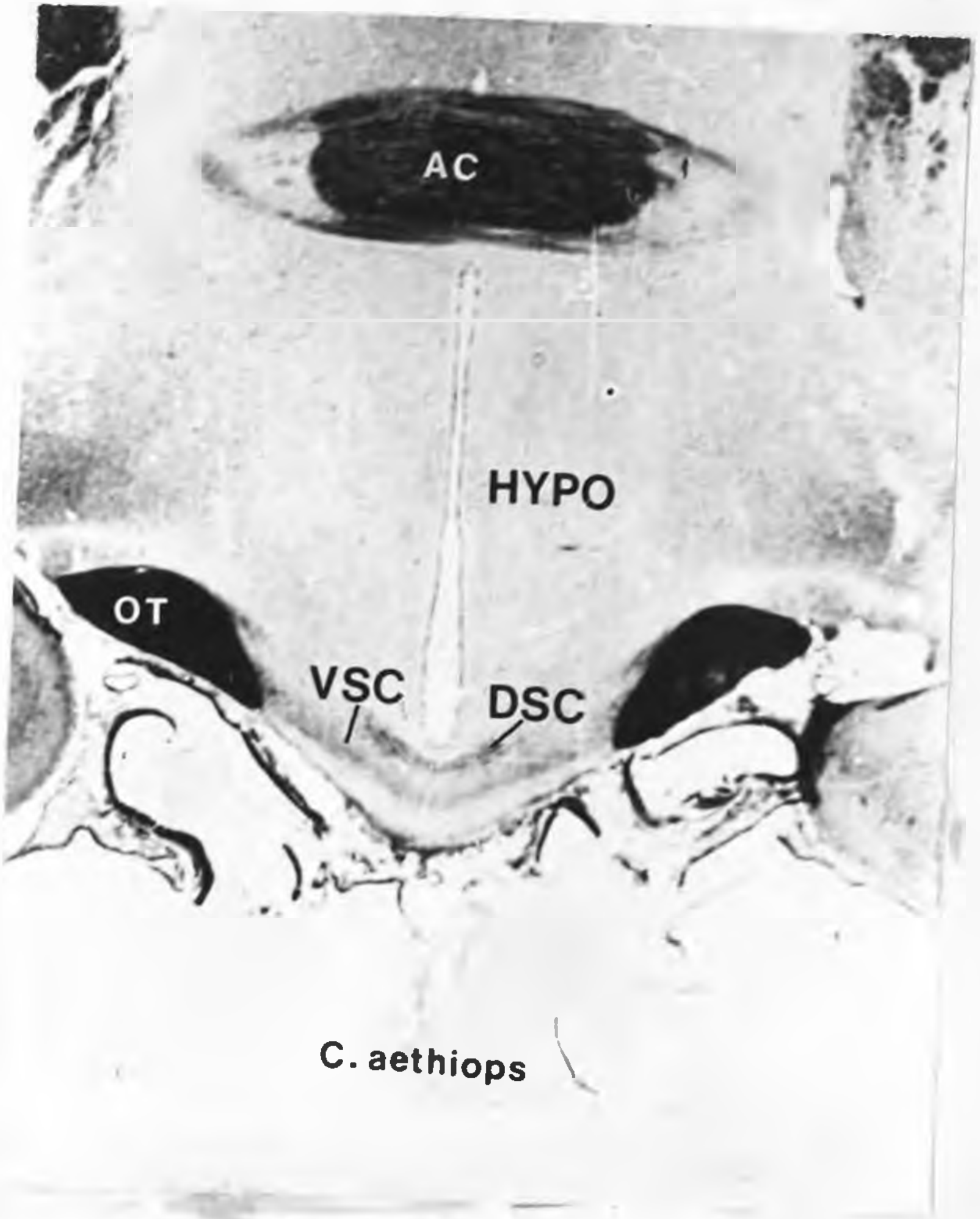

Figure 16.

(c) *N. paraventricularis* (PAV)

Like n. supraopticus, n. paraventricularis (Figs. 35; 43-44; 61-62; 73-74; 85-86; 97-100; 107-108; 173-176) is a very large and conspicuous structure. Its dimensions vary considerably in all primates studied here. In the transverse plane of section n. paraventricularis forms a vertical column of cells that lie close to the third ventricle, and reach dorsally from the optic chiasma to the ventral border of the zona incerta. At its dorsal extremity, n. paraventricularis widens out into a butterfly-like or flag-like form that stretches far laterally towards the fornix column and the cerebral peduncle. In sagittal sections, n. paraventricularis is seen as a broad, flat plate of cells that extend over a considerable part of the dorsal hypothalamic region, and reach as far rostrally as the caudal border of the optic chiasma. Its cells are generally medium-sized (16 x 13 μ in *Tupaia*, 14 x 10 μ in *Lemur* and *Galago*, 15 x 9 μ in *Cercopithecus*), they stain as darkly as those of n. supraopticus, are polygonal in shape, and are packed closely together. N. paraventricularis is intimately related to the rich capillary network that diffuses into the area between it and n. supraopticus.

In *Lemur spp.* and *Galago demidovii*, at the rostral pole of n. mediodorsalis thalami, the rostral part of n. paraventricularis commences as a fairly well localised, round mass of cells which extends caudally to where it is replaced by the main or neurosecretory part of n. paraventricularis. There, n. paraventricularis expands laterally and ventrally towards n. suprachiasmaticus. At this level, n. paraventricularis is readily identified by its butterfly-like form, as well as by its close relationship to n. hypothalamicus periventricularis. N. paraventricularis lies lateral to the anterior and dorsal hypothalamic areas. Caudad, n. paraventricularis expands farther ventrally towards the optic chiasma, then it reduces in size, and disappears gradually in the rostral infundibular region, where it is replaced by the dorsal hypothalamic area.

In *Cercopithecus aethiops*, n. paraventricularis is a vertical column of cells that is situated more ventrally than in lower primates; it is closely applied to the ependymal lining of the wall of the third ventricle. N. paraventricularis is relatively smaller in size, and has a rounded club-shaped form with no lateral extensions. In sagittal sections, n. paraventricularis expands dorsally into a triangular shape, but it does not extend ventrally towards the surface of the hypothalamus.

In man, n. paraventricularis is a much smaller and thicker column of cells lying dorsal to n. suprachiasmaticus and close to the wall of the third ventricle. It has no lateral extensions, and ends rather abruptly near the rostral infundibular region. The cells are larger and more darkly staining, but they are less densely arranged than those in prosimians and simians. No cellular connection between this nucleus and n. supraopticus has been observed in this study.

A peculiar and very interesting accessory nucleus has been noted in the supraoptic region of *Galago demidovii* and *Lepilemur*. An isolated group of cells with features characteristic of neurosecretory nuclei, appears at about the level of the middle part of the supraoptic region on both sides. It lies *lateral* to n. paraventricularis and its caudal continuation, n. paraventricular parvocellularis, *medial* to n. perifornicalis, *ventral* to the zona incerta and n. ventralis anterior thalami, and *dorsal* to the lateral hypothalamic area. This group of cells extends for a short distance and disappears abruptly before n. paraventricularis is replaced by the dorsal hypothalamic area. In myelin-stained sections, this accessory nucleus is seen to be surrounded by a thin capsule of myelinated fibres; it cannot be taken as n. perifornicalis, the fibres of which are more densely myelinated and which lies ventromedial to it. A direct relationship between the accessory neurosecretory nucleus and n. paraventricularis is observed; these two nuclei appear to be connected with each other by a thin strand of large, dark-staining cells. The accessory neurosecretory nucleus has also a direct relationship with n. supraopticus to which it lies dorsal. Thus, an isosceles triangle is formed with the accessory nucleus at the apex, while at the other angles are n. paraventricularis dorsomedially and n. supraopticus ventrolaterally.

In the Tupaioidea, the accessory nucleus may be represented only by a few large, dark-staining, polyhedral cells extending from n. paraventricularis rostrally towards the fornix or the dorsal border of the cerebral peduncle caudally. Possibly this nucleus is an aberrant structure that became dissociated from either n. supraopticus or n. paraventricularis during the phylogeny of the hypothalamus in mammals. Neither the accessory neurosecretory nucleus nor the cellular connection among these three nuclei has been found in _Lemur spp._, _Galago spp._, _Perodicticus_, _Cercopithecus aethiops_ and _Homo sapiens_.

Based on its relationships with nn. paraventricularis and supraopticus, the accessory neurosecretory nucleus should be termed _n. paraventricularis accessorius_, or n. filiformis lateralis in order to distinguish it from n. filiformis anterior that is a rostral extension of n. paraventricularis. N. paraventricularis accessorius is illustrated (Figs.17-18; 61-62; 173-174) in which it is denoted by the abbreviation 'PAVa'.

Discussion of n. paraventricularis and n. paraventricularis accessorius

N. paraventricularis, like n. supraopticus, is massive and slightly extended in prosimians; it is cytologically identical to the latter nucleus, possessing large, dark-staining and oval cells that show neurosecretory activity.

There is considerable confusion over the terminology of n. paraventricularis. Some authors, notably Le Gros Clark (1929, 1930,

EXPLANATIONS OF FIGURES

Figure 17.

Transverse section through the supraoptic region in the hypothalamus of *Lepilemur*.

(Klüver and Barrera stain x80)

Figure 18.

Transverse section through the supraoptic region in the hypothalamus of *Galago demidovii*.

(Klüver and Barrera stain x80)

Note in both Figures 15 and 16

The presence of an accessory paraventricular nucleus (pava), and its relationship with the neurosecretory hypothalamic nuclei (paraventricular and supraoptic nuclei) as indicated by arrows.

Abbreviations:

3 - third ventricle
f - fornix
lha - lateral hypothalamic area
MT - mamillothalamic tract
OC - optic chiasma
pav - n. paraventricularis hypothalami
pava - n.n. paraventricularis accessorius
so - n. supraopticus
vm - n. ventromedialis hypothalami

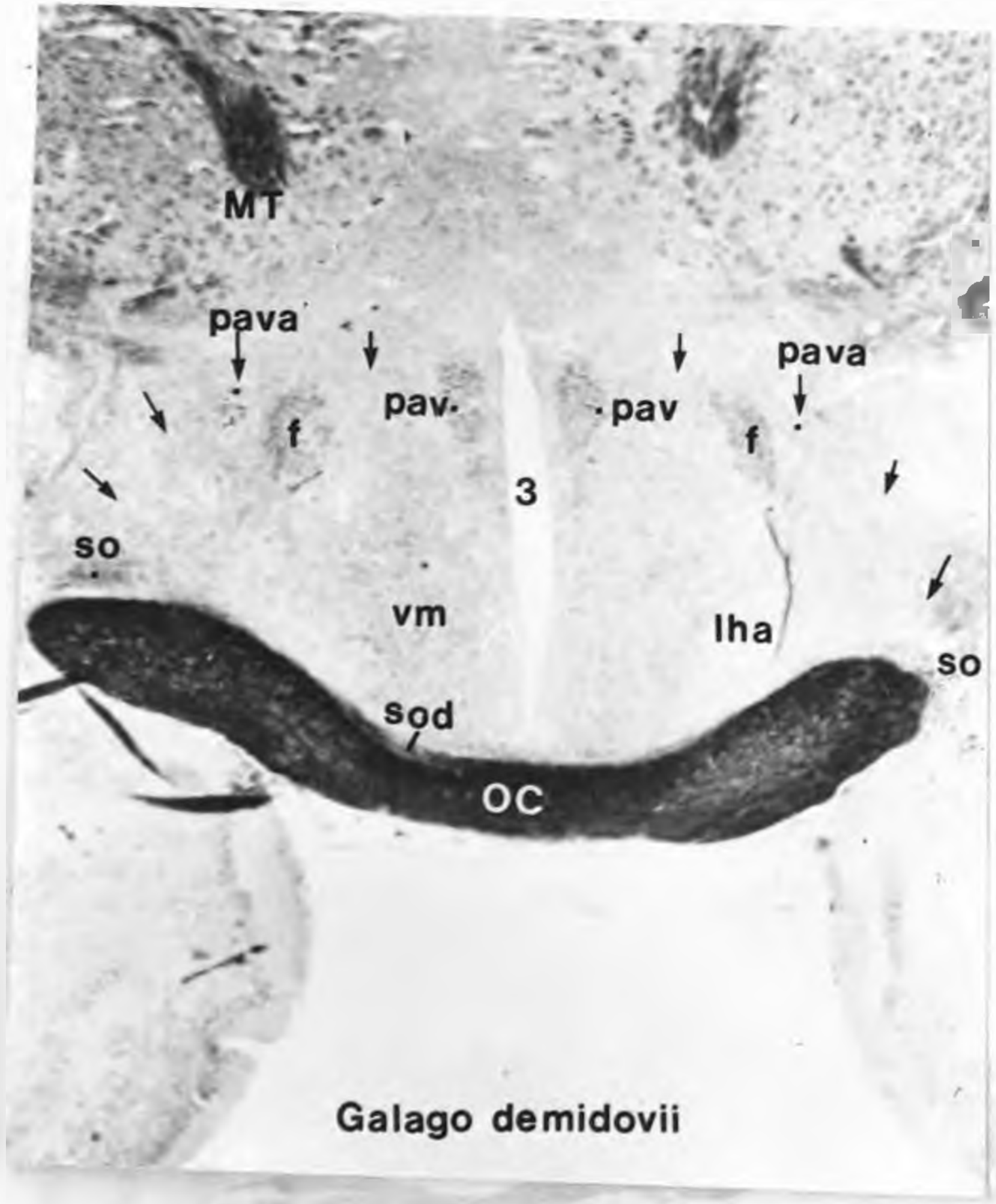

Figure 17 .

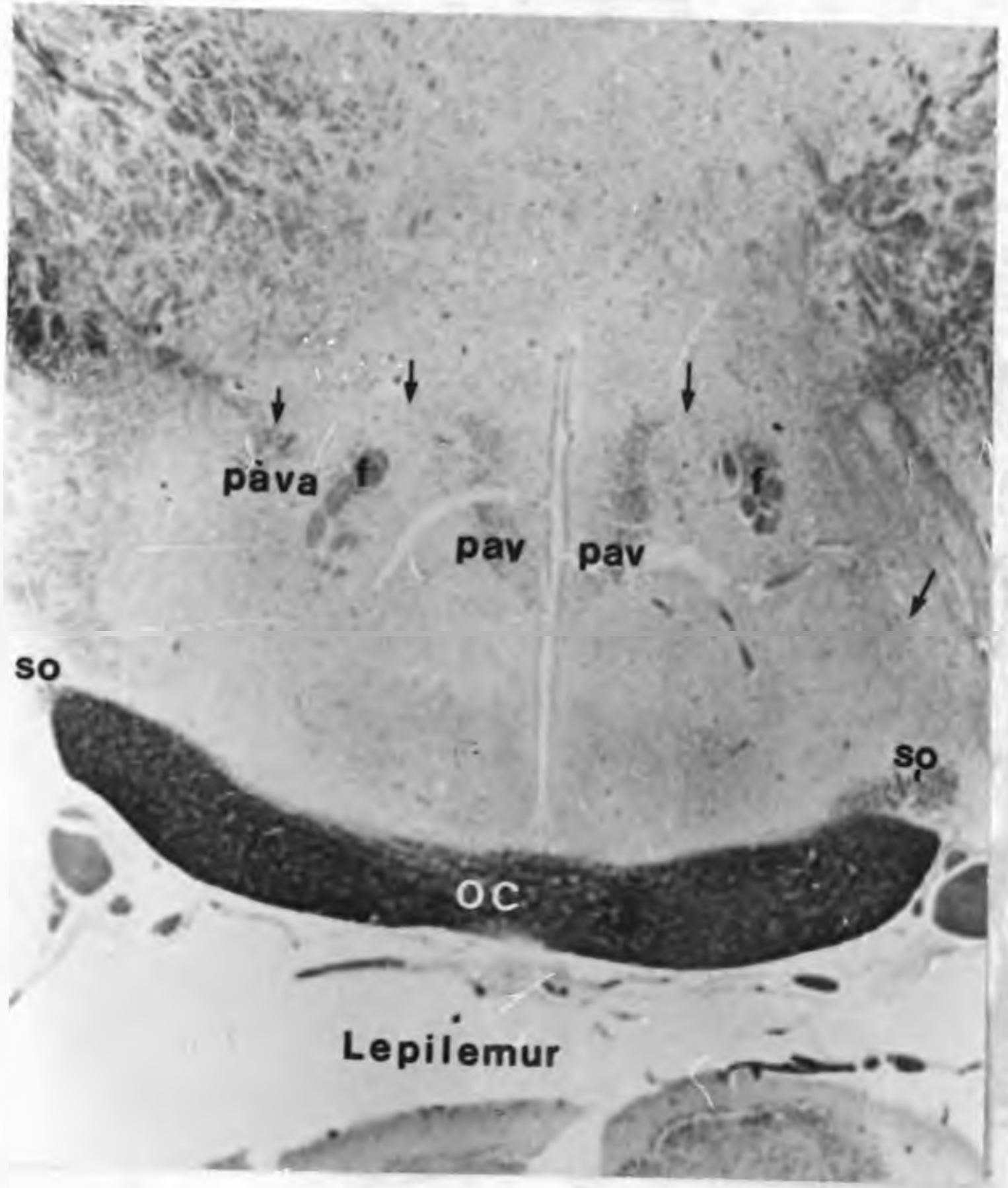

Figure 18 .

1938), Rioch (1929), and Krieg (1944), term n. paraventricularis *n. filiformis*, while others such as Tsai (1925), Papez and Aronson (1934), Krieg (1948) and Heiner (1960) call it *n. magnocellularis hypothalami*. Bauchot (1963) homologizes n. paraventricularis of his prosimian specimens with both of these nuclei. Therefore, it is possible that in this study, n. filiformis represents the rostral part of n. paraventricularis; the cells of the latter nucleus are smaller, more lightly staining and polygonal with no neurosecretory activity. N. filiformis does not have lateral extensions and is situated more dorsally than n. paraventricularis it lies ventrally to n. reuniens and lateral to the roof of the third ventricle. *N. magnocellularis hypothalami* is actually the main body of n. paraventricularis itself. N. filiformis is not present in most non-primate mammals, and is rather poorly defined in lower primates, in which it has been often confused with n. parvocellularis hypothalami. If n. filiformis is definitely present, as in higher primates, it may be considered as a lateral extension of n. paraventricularis without having a neurosecretory character (n. filiformis lateralis).

In *Perodicticus potto*, Bauchot (1967) describes a nucleus with large, well staining and polygonal cells that exhibit an active neurosecretory character; this nucleus lies dorsolateral to n. paraventricularis at the level of n. dorsomedialis thalami, and in close contact with the zona incerta. This may be n. paraventricularis accessorius which has been observed in *Galago demidovii* and *Lepilemur* in this study. N. paraventricularis accessorius has been noted in other mammals by various authors, e.g., in *man* (Nicolesco and Nicolesco 1929; Meyer 1935; Brockhaus 1942; Bergquist, 1954), in *primates*, particularly monkey (Koikegama 1938; Feremutsch 1957, 1959; Diepen 1962), in the dog (Smialowski 1966), and in the *rat* Bandaranayake 1971). An accessory *supraoptic* nucleus possessing identical cytological properties as the accessory paraventricular of this study has been described in primates by Koikegama (1938) and Christ (1966), and in the rat by Bandaranayake (1971). This nucleus has, however, not been identified in all species studied here. It is possible that one of these accessory neurosecretory nuclei, or both, forms a sort of link-up with the two principal neurosecretory nuclei. The cells of the accessory nuclei may have migrated dorsomedially from n. supraopticus to n. paraventricularis, or vice versa; these cells are intimately associated with the development of a rich capillary bed in the area between the two neurosecretory nuclei.

Śmialowski (1966) describes, in the dog, a cluster of large, well staining and oval cells lying lateral or ventrolateral to the rostral pole of n. paraventricularis in the anteroventral part of the lateral hypothalamic region. This author terms this nucleus massa intermedia of the hypothalamus, which is, otherwise, synonymous with n. paraventricularis accessorius of this study and of other workers. He considers that such a group of large, dark-staining and pyramidal cells lying lateral to n. paraventricularis and dorsal to n. supraopticus is a result of the division of the original n. supraopticus into two or more neurosecretory nuclei, i.e., nn. paraventricularis, supraopticus and their accessory parts. Smialowski was not able to trace a fibrous connection between nn. paraventricularis and supraopticus, as well as with other hypothalamic nuclei, because the accessory nucleus contains too few fibres which are very sparsely distributed. He suggested that, if the cluster of cells lying lateral to n. paraventricularis is n. paraventricularis accessorius, it may have developed as a result of the displacement of a certain number of cells from n. supraopticus by blood vessels growing into that particular hypothalamic area.

Bandaranayake (1971) observes that the preoptic nucleus of fishes and amphibians is situated in much the same topographical position as n. paraventricularis of reptiles and mammals. Therefore, it is possible that n. paraventricularis is phylogenetically older than n. supraopticus, and may have arisen directly from n. preopticus of lower vertebrates. Furthermore, the cells of n. paraventricularis remain close to their site of origin, while those of n. supraopticus migrate ventrolaterally from the preoptico-supraoptic area towards their present position on the dorsolateral border of the optic chiasma as in higher mammals. Somewhere in the migration, a cluster of cells may have been left close to the fornicate area; thus, an accessory neurosecretory nucleus, which is termed not only by Bandaranayake, but also in this study, n. paraventricularis accessorius, is formed as illustrated in Fig. 19.

I have identified only one accessory nucleus in isolated cases, that is, n. paraventricularis accessorius in different prosimian species, viz., Galago demidovii (Lorisoidea) and Lepilemur (Lemuroidea). However, my findings may not be sufficient to prove that accessory neurosecretory nuclei are present in all primates. It is necessary to investigate whether these particular nuclei are present, or not, in all vertebrates, particularly primates, as well as to find a phylogenetic and functional connection between nn. supraopticus and paraventricularis.

In their prosimian species, Feremutsch (1957) and Bauchot (1963, 1967) describe an area lying dorsal and caudal to n. paraventricularis, and consisting of small and large cells that do not show neurosecretory characteristics. These authors term it area paraventricularis; it may be homologous to the lateral part of the dorsal hypothalamic area that lies close to the zona incerta. In this study, the area paraventricularis appears to cover most of the region between the caudal pole of n. paraventricularis and n. perifornicalis, and dorsal to n. dorsomedialis hypothalami.

(d) N. suprachiasmaticus (SCH)

N. suprachiasmaticus (Figs. 35-36; 41-42; 61-62; 97-98; 107-108; 171-172) is much less conspicuous than nn. supraopticus and paraventricularis. In all primate species, n.

EXPLANATION OF FIGURE

Figure 19.

Diagram to illustrate the relationship of n. paraventricularis accessorius (PAVA) to nn. paraventricularis (PAV) and supraopticus (SO).

Arrows indicate the probable migration of neurosecretory cells from nn. paraventricularis and supraopticus to form an accessory neurosecretory nucleus (PAVA), and also the probable connection between the paraventricular and supraoptic nuclei.

(OC - optic chiasma)

(Drawn and modified from Smialowski 1966, Fig.7 p.109)

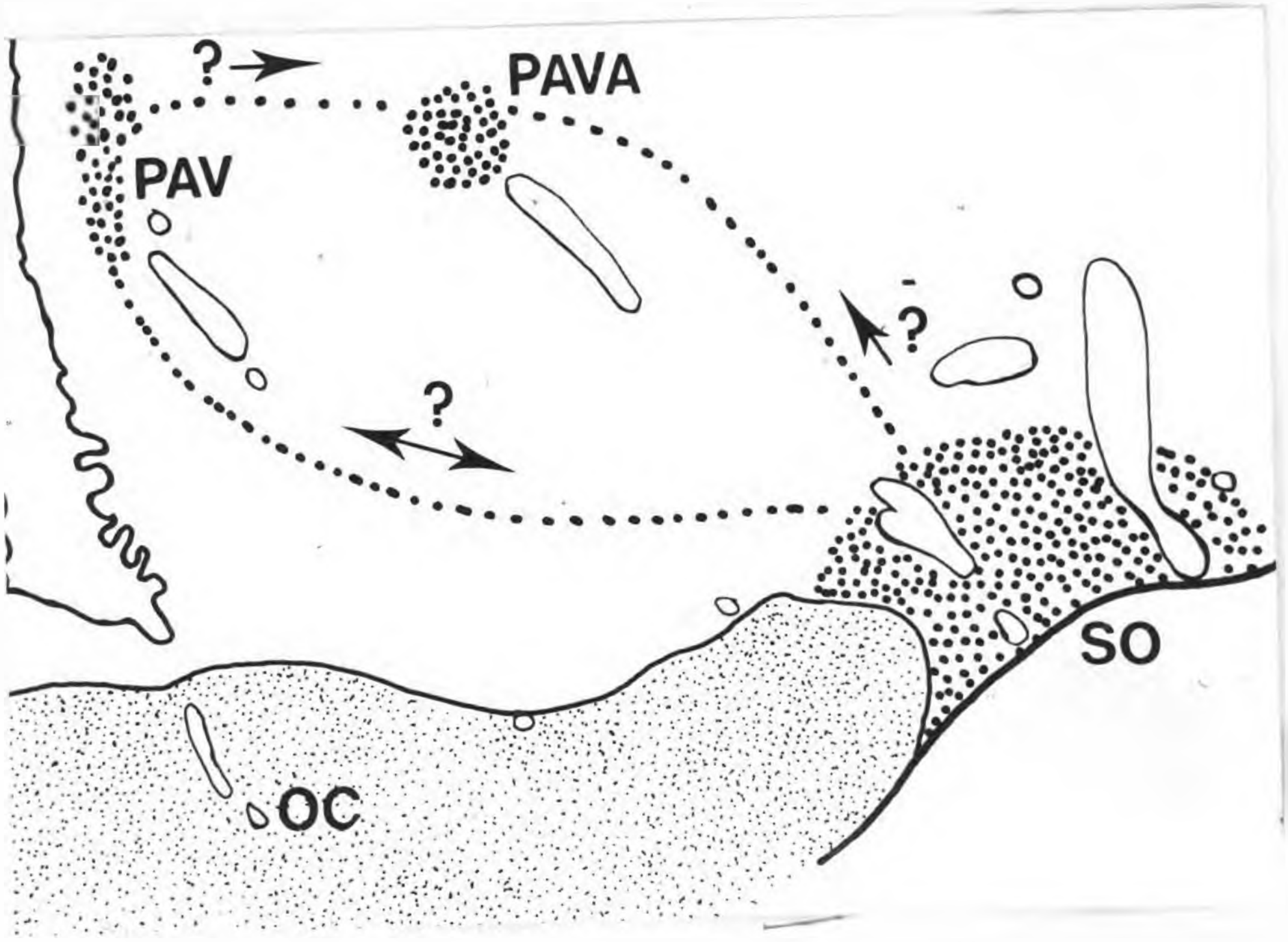

Figure 19.

suprachiasmaticus is a well-defined structure lying between the floor of the third ventricle and the dorsal surface of the optic chiasma. In certain prosimians, such as *Lemur fulvus* and *Lemur macaco*, n. suprachiasmaticus is a diffuse mass of very closely packed, pale staining, small round cells lining the ventral part of the floor of the third ventricle, and spreading along the ventral hypothalamic surface above the optic chiasma. In other prosimians, the shape of n. suprachiasmaticus is either triangular or spherical, and the nucleus has identical relationships with the third ventricle and optic chiasma as described above. Caudally, n. suprachiasmaticus becomes more poorly defined, and merges with n. periventricularis anterior at the level of the rostral or middle part of n. paraventricularis.

In higher primates, n. suprachiasmaticus is much smaller and is almost indistinguishable from n. periventricularis anterior; it lies very close to the supraoptic recess of the third ventricle. The cells of n. suprachiasmaticus are condensed to form a part of the hypothalamic periventricular system. These cells are very small (6 x 5 μ to 9 x 6 μ), and stain very palely.

In myelin-stained preparations, n. suprachiasmaticus can be easily identified by its very lightly myelinated appearance.

Discussion on n. suprachiasmaticus

N. suprachiasmaticus is conspicuous only by its proximity to the optic chiasma. This nucleus has been regarded by Laruelle (1934) and Bauchot (1963, 1967) as a ventral extension of n. paraventricularis, but it is difficult to reconcile such a relationship with the fact that these nuclei have entirely different cytological properties. A suprachiasmatic 'hillock' has been described by Bauchot (1963) in certain insectivores, such as *Talpa* and *Sorex araneus*; he regards it as compensating for the absence of a large optic chiasma in these microptic animals. The

(f) Anterior hypothalamic area (AHA)

The anterior hypothalamic area (Figs. 41-44; 61-62; 97-98; 171-174) is difficult to demarcate precisely from the medial preoptic area with which it is continuous. It is difficult also to ascertain its rostral and caudal limits. However, the anterior hypothalamic area can be seen, in all species used in this study, as a diffuse area of small, lightly staining, round or oval cells scattered among fine myelinated fibres. It lies ventromedial to n. interstitialis of the medial forebrain bundle, medial to the lateral hypothalamic area and lateral to n. periventricularis anterior. The anterior hypothalamic area appears to extend more rostrally than laterally; caudally it is replaced by the dorsal hypothalamic area and n. dorsomedialis hypothalami. In the anterior hypothalamic area, there is a central condensation of slightly larger and more darkly staining cells that lie rostral and dorsal to n. suprachiasmaticus, ventral to the rostral pole of n. paraventricularis and lateral to n. periventricularis anterior. It may be regarded as a pronucleus, which has often been termed n. hypothalamicus anterior.

In Tupaia, the anterior hypothalamic area is much less conspicuous. It spreads out into a roughly rectangular area which is bounded dorsolaterally by the corpus striatum, medially by n. paraventricularis and ventrally by n. supraopticus. In all prosimians, the anterior hypothalamic area appears to be better differentiated than that of the Tupaioidea, but is is not sufficiently well defined in higher primates, to be called a true nucleus. However, owing to its lack of specific cytological differentiation, the anterior hypothalamic area stands out more clearly in various planes than nn. supraopticus, paraventricularis and other nuclei of the supraoptic region. In man, too, the anterior hypothalamic area cannot be defined as a true nucleus because of its extremely diffuse cellular nature and its poor myelin content.

SUMMARY OF THE PREOPTIC AND SUPRAOPTIC REGIONS OF THE HYPOTHALAMUS

The preoptic and supraoptic regions constituting the prechiasmatic or rostral part of the hypothalamus do not show significant phylogenetic changes throughout the primate scale. The boundaries of these regions are rendered more indefinable by the development of the thalamus and by the expansion of the neopallial areas in the cerebral hemispheres. In the Macroscelididae, the hypothalamus appears at a more caudal level than the thalamus, that is, the hypothalamic structures, e.g. nn. paraventricularis, supraopticus and suprachiasmaticus appear at the level of the caudal habenular region. In the Tupaioidea, the rostral border of the preoptico-supraoptic region is shifted rostrally towards the anterior commissure. In prosimians, the rostral border is better defined than the caudal border of the preoptic region which lies somewhere at the level of the middle part of the optic chiasma. In higher primates, the preoptic region is much smaller, and is caudally continuous with the supraoptic region. The nuclei of the preoptic area, in all species, are well defined and cytologically distinguishable from each other. Nn. supraopticus and paraventricularis show considerable variations in topographical, structural and cytological characteristics in all primate species studied here. These nuclei have been observed to possess accessory neurosecretory parts, particularly n. paraventricularis, whose cells have migrated laterally towards the perifornicate area to form an accessory paraventricular nucleus. This accessory paraventricular nucleus has been identified only in two prosimian specimens, *Galago demidovii* and *Lepilemur*. A cellular connection has been noted in these specimens, as well as in some tupaioids, between nn. supraopticus and paraventricularis; possibly it marks the passage of migratory cells from either n. paraventricularis or n. supraopticus to the site of the accessory neurosecretory nucleus. The anterior hypothalamic area may have some of the attributes of a true nucleus, but as it has an extremely diffuse cellular nature, it is perhaps more appropriate not to regard it as a nucleus. Other nuclei in the supraoptic region which do not show either progressive or regressive variations or morphological trends in their phylogeny throughout the primate scale, are nn. suprachiasmaticus and periventricularis anterior; these nuclei form parts of the hypothalamic periventricular system.

The structural features, cyto- and myelo-architectonic properties and evolutionary changes of only the larger and more important nuclei in both preoptic and supraoptic regions are summarized in Table 23.

TABLE 23: THE PRECHIASMATIC PART OF THE HYPOTHALAMUS

Features	N. preopticus medialis (POM)	N. preopticus lateralis (POL)	N. supraopticus (SO)	N. paraventricularis (PAV)	N. suprachiasmaticus (SCH)
STRUCTURAL FEATURES	In the Tupaioidea and Prosimii, POM is not clearly demarcated from POL; it is the smaller and more compact of the two. POM is divisible into median, periventricular and principal parts. The principal part is the main body of the medial preoptic area; it is continuous with the anterior hypothalamic area caudally and with the parolfactory area rostrally. In higher primates, POM is compressed into a smaller area between lamina terminalis and the anterior hypothalamic region. It remains well defined and cytoarchitectonically distinct from POL.	In all species, POL is more greatly developed than POM; it is divisible into magnocellular and interstitial parts. The latter part is the bed nucleus of stria terminalis, and the magnocellular part is rostrally continuous with the diagonal band of Broca. Both parts are replaced by the lateral part of the anterior hypothalamic region.	In *Tupaia*, SO is a large, crescentic mass of cells lining the dorsolateral surface of the optic chiasma; it is not clearly subdivided into ventromedial and dorsolateral parts as in prosimians. In lower primates SO varies considerably in size and extent, and consists of two parts linked together by an isthmus. In higher primates, SO is a much elongated structure that is applied very closely to the dorsal edge of the optic chiasma, and extends along the optic tract in the infundibular region. In man, it is clearly divided into anterolateral and posteromedial parts joined together by a thin strand of cells. An accessory supraoptic nucleus has been observed in certain primate species.	In *Tupaia*, PAV is a large, butterfly-shaped structure which has rostral (n. filiformis), caudal (n. hypothalamicus parvocellularis) and lateral extensions. PAV also extends centrally towards SCH. In all prosimians, PAV is much more conspicuous, and is shaped like a wing with longer lateral extensions. In some species, e.g., *Galago demidovii* and *Lepilemur*, an accessory paraventricular nucleus is definitely present; it has the same neurosecretory properties as PAV and SO. This accessory nucleus may be linked with PAV and SO by delicate cellular and fibrous strands. In higher primates, PAV is much reduced in size and extent; it appears to have been displaced to a more ventral position, that is, closer to SCH and the ventricular wall.	SCH is comparatively poorly developed in all primate species, as well as in *Tupaia*. It is generally triangular in shape, and lies between the optic chiasma and the floor of the third ventricle. In *Galago demidovii* and *Perodicticus potto*, SCH is slightly larger and better defined; it can be differentiated cytoarchitectonically from the periventricular system. In higher primates, SCH is smaller and more ill-defined with a short rostrocaudal extent. In man, SCH is more difficult to distinguish from the periventricular nucleus, and it is condensed into a flat plate lining the dorsal surface of the supraoptic recess.
CELLULAR PROPERTIES	Small (8 x 5 $/^{u}$ in *Tupaia* to 9 x 6 $/^{u}$ in *Cercopithecus*). Round and well staining ; cells are densely arranged in median and periventricular parts, and scattered in the principal part of POM.	Larger than those of POM (10 x 7 $/^{u}$ in *Tupaia* to 14 x 10 $/^{u}$ in *Galago*). Cells stain darkly and are stellate in shape ; they are very loosely distributed.	Rather large, well staining and generally oval cells in all species (15 x 8 $/^{u}$ in *Lemur* to 21 x 10 $/^{u}$ in *Tupaia*!) Cells are packed together very closely. Characterized by the presence of vacuoles in the cytoplasm, indicating neurosecretory activity.	Smaller, more darkly staining, rounder and less densely arranged than those of SO. Cells are uniform in size and neuronal type in all spp., 14 x 8 $/^{u}$ in *Lemur* to 16 x 13 $/^{u}$ in *Tupaia*. in all species. Cells are packed more closely in the medial than in the lateral portion of PAV. Cells of the accessory paraventricular nucleus are larger and more darkly staining than those of PAV and SO.	In all species, cells of SCH are very small (6 x 5 $/^{u}$ in *Cercopithecus* to 8 x 5 $/^{u}$ in *Tupaia*). These cells stain very lightly and are round ; they resemble strongly those of the periventricular system of the diencephalon.
MYELIN CONTENT	Poor in all species. Fibres run through POM from the sub-cortical areas to the olfactory regions in the telencephalon.	Better than POM; is the bed nucleus of the medial forebrain bundle.	Generally light; may be partially surrounded by fibres. A delicate fibrous connection is present between SO and PAV, and also with the hypophysis.	Lightly connected with SO and the hypophysis by the hypothalamico-hypophyseal tract.	Very finely connected with the the periventricular fibre system of the diencephalon.
EVOLUTIONARY TRENDS	No significant morphological trend.	No significant morphological trend.	Stable morphological state throughout the primate scale, though reduced in size and pushed to a more ventral position in higher primates. It possesses a notable cellular connection between its two parts.	Stable morphology throughout the primate scale. Is phylogenetically younger than SO, and has an accessory part in certain primate spp. Increases in a dorsoventral extent, and comes to lie ventrally close to SCH.	No significant phylogenetic trends; rather regressive in higher primates.

CHAPTER 17

THE HYPOTHALAMUS: POSTCHIASMATIC PART

A. THE INFUNDIBULAR REGION (Plates 3 - 41; 72 - 74)

Topographically and structurally, the infundibular region (tuber cinereum) is an oval eminence of grey matter lying between the optic chiasma and the mamillary bodies. Suspended from the floor of the infundibular region by a peduncle is the hypophysis cerebri or pituitary gland. The nuclei of the infundibular region are less well defined in primates, particularly in anthropoid apes, than in non-primate mammals. These nuclei are even more obscure in man, but this does not mean that they are altogether absent nor reduced numerically; they are separated more widely from one another by diffuse hypothalamic areas. The hypothalamic areas contain small and medium-sized, moderately well staining cells; in the caudal parts of these areas are found numerous large, dark-staining and multipolar cells. In myelin-stained sections, the infundibular region appears to be almost devoid of myelinated fibres, but it contains a rich neuropil of unmyelinated fibres.

The nuclei of the infundibular region have been described so repeatedly in all mammals, including man, that their homologies can be detected rather easily among these forms. In primates, these nuclei, together with the hypothalamic areas in the infundibular region, are as follows:

(a) N. ventromedialis (hypothalami) (VMH)
(b) N. dorsomedialis (hypothalami) DMH)
(c) N. tuberalis lateralis (TL)
(d) N. tuberomamillaris (TM)
(e) N. periventricularis posterior (PEVp)
(f) N. perifornicalis (PRF)
(g) Dorsal hypothalamic area (DHA)
(h) Lateral hypothalamic area (LHA)
(i) Posterior hypothalamic area (PHA).

(a) *N. ventromedialis* (VMH)

This nucleus (Figs. 35-38; 45-50; 54-56; 62-64; 73-76; 85-88; 99-102; 107-112; 172-176) is a dense mass of small, moderately well-staining and round cells that are separated from the ependymal layer by an acellular zone. In the Lorisoidea, n. ventromedialis is a better defined and larger structure than n. dorsomedialis, while in the Tupaioidea and Lemuroidea, n. ventromedialis appears to have features characteristic of an area with poorly demarcated boundaries. In *Galago*, n. ventromedialis is separated medially by a perinuclear zone from the ventricular cavity, and laterally from n. tuberalis lateralis. In other prosimians, n. ventromedialis occupies a paraventricular position in the ventral part of the infundibular region; it lies dorsomedial to n. periventricularis, ventral to n. dorsomedialis, ventrolateral to the dorsal hypothalamic area, and caudal to the anterior hypothalamic area. Caudally, n. ventromedialis is related to the lateral hypothalamic area and to the fornix. In all species studied here, the cells of n. ventromedialis are more uniform in size, shape and stainability than those of n. dorsomedialis; they are between 12 μ and 14 μ, stain rather darkly, and are packed compactly in a small area. N. ventromedialis extends farther caudally than n. dorsomedialis, and towards the mamillary region it is replaced partly by n. premamillaris and partly by the lateral hypothalamic area.

In *Cercopithecus aethiops* and man, n. ventromedialis is more poorly defined than that of lower primates, and may hardly be regarded as a proper nucleus. However, it is present in higher primates as a roughly oval condensation of medium sized (13 x 7 μ), rather well staining, round or oval-shaped cells in the ventromedial part of the infundibular region. N. ventromedialis lies caudal to the anterior hypothalamic area and n. suprachiasmaticus. It is bounded laterally by the lateral hypothalamic area, dorsomedially by the fornix and medially by n. periventricularis posterior. Its caudal extremity lies slightly rostral to n. premamillaris. In the caudal part of n. ventromedialis, there are many large, dark-staining, pyramidal cells that mingle with other cells; these cells may represent an incursion of the posterior hypothalamic area which replaces n. ventromedialis in the mamillary region.

Discussion on n. ventromedialis

N. ventromedialis appears to decrease progressively in size as one ascends the primate scale. It is larger and better developed than n. dorsomedialis in all prosimians, and occupies almost the entire hypothalamic region lying ventral to the fornix. In *Tupaia glis* and *Perodicticus potto*, Bauchot (1963, 1967) described n. ventromedialis as a large, diffuse structure that is poorly delimited from n. periventricularis posterior medially, and from the lateral hypothalamic area and n. tuberomamillaris laterally. These relationships conform with those of n. ventromedialis in my tupaioid and prosimian specimens. In all species studied here and those used by other workers, n. ventromedialis has been observed to be separated by an acellular zone from n. dorsomedialis and other adjoining hypothalamic nuclei. Kanagasuntheram et al (1968) state that n. ventromedialis is more conspicuous in monkey than in man, and is, indeed, a very prominent nucleus in their lorisoid specimens. These authors presume that the phylogenetic development of n. ventromedialis may be directly related to the degree of docility in different primate species, since injuries to this nucleus lead to changes in emotional behaviour. Bauchot (1967) observed in *Perodicticus potto* a slender fibrous connection between n. ventromedialis and the hypophysis that may indicate the rôle of n. ventromedialis in regulating behaviour and appetite.

It is inferred from this study that n. ventromedialis has a rather regressive evolution throughout the primate scale. In spite of its more diffuse and less easily defined nature than that of n. dorsomedialis, n. ventromedialis is definitely present as an entity in man and anthropoid apes.

(b) N. dorsomedialis (DMH)

In *Tupaia*, *Lemur*, *Perodicticus* and *Galago demidovii* n. dorsomedialis (Figs. 45-50; 75-76; 85-88; 173-176) is a rather ill-defined structure whose borders may be demarcated with considerable difficulty from those of adjoining nuclei in the infundibular region. However, the smaller and more lightly staining cells of n. dorsomedialis facilitate its identification. In all prosimians, n. dorsomedialis appears at a more caudal level, and has a longer caudal extent than n. ventromedialis. N. dorsomedialis lies lateral to the third ventricle, ventral to the dorsal hypothalamic area, dorsal to n. ventromedialis and the medial part of the lateral hypothalamic area. Caudally, it comes into relation with n. perifornicalis medially, and with the posterior hypothalamic area laterally and caudally. The cells of n. dorsomedialis vary considerably in size among the primate species, i.e. 10 x 7 $/^{u}$ in *Tupaia*, 12 x 8 $/^{u}$ in *Lemur*, 14 x 8 $/^{u}$ in *Galago*, and 16 x 9 $/^{u}$ in *Cercopithecus*.

The cells of n. dorsomedialis are larger, better staining and more polygonal, and are arranged rather more densely than those of n. ventromedialis. N. dorsomedialis is more lightly myelinated than other hypothalamic nuclei lying adjacent to it; fibres run through it linking up with n. ventromedialis and with the hypophysis.

Discussion on n. dorsomedialis

In all primate species, n. dorsomedialis hypothalami is less distinctly developed than n. ventromedialis, and should be considered rather as an area than a nucleus of the hypothalamus. However, n. dorsomedialis of higher primates can be distinguished cytoarchitectonically and cytologically from n. ventromedialis by the larger, more darkly staining and multipolar cells of the former nucleus. It is even physiologically different from n. ventromedialis and the dorsal hypothalamic area, as it has been found experimentally to play a rôle in feeding instincts, particularly in lower primates and non-primate mammals.

In Galago and Nycticebus, Kanagasuntheram et al (1968) identified a wing-shaped structure extending lateralwards from n. dorsomedialis, and termed it n. dorsolateralis (DLH). This nucleus is not clearly identified in all my prosimian specimens. However, in Tupaia and Galago demidovii n. dorsolateralis (Figs. 47-50; 173-176) can be observed stretching ventralwards from n. dorsomedialis towards the perifornicate area. It is related dorsally to n. hypothalamicus parvocellularis and the zona incerta, and rostrally to the lateral hypothalamic area. N. dorsolateralis runs for only a short distance, and ends at the same level as n. dorsomedialis in the caudal part of the infundibular region. Kanagasuntheram et al (1968) mentioned in their prosimian species another nucleus which is related to n. paraventricularis. They termed it n. hypothalamicus parvocellularis to distinguish it from the magnocellular part of n. paraventricularis. It extends caudolaterally from n. paraventricularis towards the ventral surface of the thalamus. It has not been identified in most of my specimens. Its topographical situation as described by Kanagasuntheram et al, is occupied by smaller, pale-staining and round cells that appear caudally and laterally to n. paraventricularis, particularly in Tupaia glis (Fig. 50) and Galago demidovii (Figs.173-176).

(c) N. tuberalis lateralis (TL)

N. tuberalis lateralis (Figs. 45-50; 65-66; 76; 101-103; 109-112; 175-180) is more readily identifiable in apes and man than in monkeys, prosimians and tupaiids. It attains its peak of development in man.

In all my prosimian specimens, n. tuberalis lateralis is a very poorly defined structure lying in the ventral part of the lateral hypothalamic area, lateral to n. tuberomamillaris with which it has an inverse developmental relationship. In the Tupaioidea, n. tuberalis lateralis is represented by one, sometimes two, groups of small, lightly staining, round cells (13 x 8 $/^{u}$) that lie medial to n. tuberomamillaris and ventral to the lateral hypothalamic area. N. tuberalis lateralis is situated deeply in the hypothalamic substance, and therefore, does not show any protrusion on the ventral surface of the hypothalamus, as in primates.

In *Lemur* and *Galago*, the development of n. tuberalis lateralis goes a step further: the nucleus becomes more differentiated cytologically from n. tuberomamillaris. N. tuberalis lateralis can be located with certainty in the ventral part of the infundibular region; it appears first at the level of the middle part of n. ventromedialis, to which it is related medially. Only one group of cells has been observed so far in all my lemuroid and lorisoid specimens. The cells of n. tuberalis lateralis vary in size i.e. between 13 and 17$/^{u}$.

As one ascends the primate scale, n. tuberalis lateralis is much better developed with an increasing degree of cellular differentiation. In *Cercopithecus aethiops*, n. tuberalis lateralis consists of scattered medium-sized (13 x 10 $/^{u}$), pale-staining and oval polygonal cells that have not consolidated into groups, sufficient to make protrusions on the ventral surface of the hypothalamus. It man, n. tuberalis lateralis is distinct. It consists of two or three clusters of small, lightly staining and oval cells that lie close to the ventral surface of the hypothalamus. In sagittal sections, n. tuberalis lateralis extends from the posterior end of n. supraopticus rostrally to the anterior mamillary region caudally.

Discussion on n. tuberalis lateralis

N. tuberalis lateralis is definitely not present in non-primate mammals. It can be identified with considerable difficulty in lower primates, in which it may be represented by one or two small cellular condensations in the intermediate zone of the infundibular region, between the lateral hypothalamic area and n. ventromedialis. These condensations may resemble the cell groups of n. tuberalis lateralis in man, but they do not lie anywhere near the ventral hypothalamic surface. In the Hylobatidae, Kanagasuntheram and Wong (1969) identified n. tuberalis lateralis as two well-defined masses that occupy the ventral part of the hypothalamus at the level of the caudal end of n. ventromedialis. The medially situated mass is larger than the lateral one, and contains densely arranged, medium sized cells that are related laterally to n. ventromedialis. The lateral mass is less sharply defined; it contains loosely arranged, small and more lightly staining cells that distinguish it from n. perifornicalis and n. premamillaris which lie dorsal to n. tuberalis lateralis. In the Pongidae (Feremutsch 1963), n. tuberalis lateralis contains well-circumscribed groups of cells ventral to n. tubero-mamillaris; these groups of cells form visible swellings on the ventral hypothalamic surface. In the gorilla, chimpanzee and man, n. tuberalis lateralis consists of two or three distinct structures with similar cytological features to those of the gibbon and siamang. These tuberal nuclei are found embedded in the lateral hypothalamic area in the region of the tuber cinereum.

(d) N. tuberomamillaris (TM)

In the Tupaioidea and Prosimii, n. tuberomamillaris (Figs. 45 - 50; 66; 76; 99 - 102; 175 - 178) has the features characteristic of a hypothalamic area in that its cells are diffusely distributed over a wider area than n. tuberalis lateralis. However, its cells are smaller (12 x 8 μ), stain better and are more polyhedral in shape than those of the lateral hypothalamic area. In the Lemuroidea, n. tuberomamillaris is so poorly defined that it may form rostral and ventral parts of the posterior hypothalamic area.

In Cercopithecus aethiops, as well as in other higher primates, n. tuberomamillaris is a group of medium-sized (16 x 9 μ), dark-staining, polyhedral cells lying on the ventromedial border of the optic tract, and medial to the lateral hypothalamic area rostrally and to n. premamillaris caudally. N. tuberomamillaris may form a part of the posterior hypothalamic area, or may actually be identical with n. perifornicalis itself, since these two nuclei seem to occupy the same topographical position beneath the fornix. In man, n. tuberomamillaris is hardly identifiable, and is included in a greatly expanded posterior hypothalamic area.

Discussion on n. tuberomamillaris

N. tuberomamillaris appears to be a better developed and more discrete structure in non-primate mammals and lower primates than in higher primates and man. In primates, the cells of n. tuberomamillaris are diffusely distributed throughout the lateral hypothalamic area, in the ventral part of which they form rather conspicuous condensations close to the surface. N. tuberomamillaris extends caudally to the region lying lateral to the mamillary complex. At some levels, n. tuberomamillaris is co-extensive with the posterior hypothalamic area and n. perifornicalis. As n. tuberomamillaris is situated between the infundibular and mamillary regions, it has been termed n. mamilloinfundibularis by several workers, notably Feremutsch (1955, 1957), Diepen (1962)and Bauchot (1963, 1967), but it has been found to have no functional connection with the infundibulum. Furthermore, these workers regard it as a part of the lateral or posterior hypothalamic area. If this view is correct, it cannot be a homologue of n. tuberalis lateralis which appears to be found only in the infundibular region of anthropoid apes and of man.

(e) N. periventricularis posterior (PEVp)

This nucleus (Figs. 37-112; 171-178) is an arciform structure lying close to and around the ventral part of the third ventricle. In non-primate mammals and lower primates, a nucleus arcuatus is actually a condensation of cells that forms a part of the hypothalamic periventricular system. It has been designated n. infundibularis by Feremutsch (1957), Bauchot (1963, 1967) and Nauta and Haymaker (1969) because it has every close topographical relationship to the infundibulum. However, the term n. periventricularis posterior is preferred in this study, for this nucleus is continuous with n. periventricularis anterior in the supraoptic region, and with n. inframamillaris which lies lateral to the mamillary recess in the mamillary region. N. periventricularis posterior is separated by a cell-poor zone from n. ventromedialis laterally, but it is continuous with n. dorsomedialis dorsally. The cells of n. periventricularis posterior are small, lightly staining and round, and are arranged very densely in the ventricular wall; they resemble very much those of other parts of the periventricular system.

N. periventricularis posterior is less clearly defined and larger in *Tupaia* than in *Elephantulus*. Bauchot (1963) states that this nucleus is not well developed in mammals which have poorly differentiated neurosecretory hypothalamic nuclei. Generally in these forms n. periventricularis posterior is merely a juxtaventricular cellular condensation, like nn. ventromedialis and dorsomedialis.

All the periventricular nuclei are connected with the thalamic periventricular system, the medial forebrain bundle and stria medullaris. These nuclei may be regarded as secondary olfactory centres, but Adey and Meyer (1952) have shown that they may be concerned with adiposexual equilibrium, and this function is related to the reception of integrated olfactory and somatic impulses.

(f) N. perifornicalis (PRF)

In all species used in this study, n. perifornicalis (Figs. 64; 74; 101-102; 111-112; 173-176) can be seen as a thin ring of medium-sized (15 - 19 μ), dark-staining and pyramidal cells surrounding the column of the fornix as the latter descends towards the mamillary region. N. perifornicalis lies dorsal to nn. paraventricularis and dorsomedialis, dorsolateral to the lateral hypothalamic area, and medial to the roof of the third ventricle. The ventral part of n. perifornicalis appears to merge with the lateral part of n. dorsomedialis to form a common part of the dorsal hypothalamic area. N. perifornicalis disappears as the fornix enters the mamillary region.

(g) Dorsal hypothalamic area (DHA)

(Figs. 43-88; 173-176) Like the anterior hypothalamic area whose dorsomedial part it replaces, the dorsal hypothalamic area has no definite nuclear characteristics, and is diffuse. The dorsal hypothalamic area lies ventromedial to n. paraventricularis, ventrolateral to n. dorsomedialis, dorsal to n. ventromedialis and medial to n. perifornicalis. Caudad, the dorsal hypothalamic area replaces n. paraventricularis, and then comes to lie lateral to n. periventricularis posterior and ventral to the zona incerta. The dorsal hypothalamic area contains small, well-staining, round or polyhedral cells; several large, dark-staining and pyramidal cells are seen scattered among the small cells. Towards the mamillary region, it is replaced by both lateral and posterior hypothalamic areas.

(h) Lateral hypothalamic area (LHA)

(Figs. 35-112; 171-178) This is a triangular area of cells lying between the nuclei of the infundibular region medially and the optic tract laterally, and between the dorsal hypothalamic area and the fornix dorsally and the ventral border of the diencephalon ventrally. The lateral hypothalamic area is connected with the anterior hypothalamic area rostrally and with the posterior hypothalamic area caudally. It commences at the level of the caudal end of n. supraopticus and extends into the mamillary region as far caudally as the medial mamillary nucleus. The lateral hypothalamic area contains a diffuse collection of small and medium-sized, lightly staining, round or polygonal cells with a scattering of large, dark-staining, stellate cells.

(i) Posterior hypothalamic area (PHA)

(Figs. 39-114; 177-180;). This area is located at the level of the caudal end of n. ventromedialis, as a caudal continuation of both dorsal and lateral hypothalamic areas. The posterior hypothalamic area is relatively better developed than the other hypothalamic areas, in having clearly defined borders and a denser collection of cells. Thus, it has often been regarded as a nucleus in the literature, n. hypothalamicus posterior, and several functions have been attributed to it. The posterior hypothalamic area extends caudally towards the tegmentum of the midbrain with which it is continuous. At the level of n. mamillaris medialis, n. periventricularis posterior fuses with the posterior hypothalamic area to form a continuous mass lying ventral to the third ventricle and medial to the mamillary recess. The mamillothalamic tract lies lateral to the posterior hypothalamic area; n. supramamillaris is related ventrolaterally to the latter structure only for a short distance. The cells of the posterior hypothalamic area are generally mixed in size, shape and stainability, and are scattered throughout the area.

As the dorsal, lateral and posterior hypothalamic areas do not differ much in structural and cytological features among the primates, they will not be discussed here.

B. THE MAMILLARY REGION (Plates 4-41; 73-74)

From the viewpoint of topographical definition, the mamillary region is certainly the best differentiated part of the hypothalamus in higher mammals, particularly primates. This region is composed mainly of two hemispherical mamillary bodies, which are associated with the fornix and mamillothalamic tract. Nuclei contained in the mamillary region are:

(a) N. premamillaris (PRM)
(b) N. mamillaris medialis (MM)
(c) N. mamillaris lateralis (ML)
(d) N. mamillaris intercalatus (MIC)
(e) N. supramamillaris (SPM)
(f) N. inframamillaris (IFM)

(a) N. premamillaris (PRM)

This nucleus (Figs. 65-68; 87-88; 175-176) is the 'harbinger' of the mamillary region. It appears in the caudal region of the tuber cinereum as a very small, narrow, crescentic band of medium-sized (10 - 14 μ), well staining and polygonal cells that are related dorsally to the fornix, dorsolaterally to n. tuberomamillaris and ventromedially to n. tuberalis lateralis. Caudally, n. premamillaris is replaced by n. mamillaris medialis.

Discussion on n. premamillaris

N. premamillaris is sometimes termed n. tuberomamillaris, since these two nuclei appear to occupy an almost identical topographical position in the infundibulo-mamillary zone. In lower primates, n. premamillaris is a rather conspicuous structure which is divisible into ventral and dorsal parts (Feremutsch 1955, 1957; Bauchot 1963). These parts have been recognized in the macaque by Aronson and Papez (1934), but not in n. premamillaris in all my tupaioid and prosimian specimens. In fact, n. premamillaris in these animals is only a collection of cells lying ventral to the fornix without any sign of separation into distinct groups. Crouch (1934) recognized a very small premamillary nucleus in Macacus rhesus; Le Gros Clark (1938) did, likewise, in the human hypothalamus. But n. premamillaris may not be present at all in man (Crosby, Humphrey and Lauer (1962). at most, it is merely a zone of transition from the lateral or posterior hypothalamic area to the mamillary region.

(b) *N. mamillaris medialis* (MM)

N. mamillaris medialis (Figs. 39-114; 177-178) is the largest and most important constituent of the mamillary region, as well as one of the most conspicuous nuclei in the entire diencephalon. It shows a higher degree of development in *Lemur* and *Perodicticus* than in other prosimians. In these two prosimians, n. mamillaris medialis exhibits a distinct protuberance on the ventral hypothalamic surface. N. mamillaris medialis may be divided, on both cyto- and myelo-architectonic grounds, into medial and lateral parts, as well as into supramamillary and inframamillary parts. The *lateral part* of n. mamillaris medialis (MMl) is densely packed with small (11 - 13 $/^{u}$), well-staining cells, that lie medial to nn. mamillaris intercalatus and supramamillaris. The *medial part* (MMm) is smaller than the lateral part, and contains larger (13 to 16 $/^{u}$), less darkly staining cells that are arranged close to the median plane of the mamillary region. The medial part of n. mamillaris medialis has been termed *n. mamillaris medianus* (Md) by several workers, but it is not treated as a separate entity in this study.

N. mamillaris medialis is larger and better developed in higher than in lower primates; in the former it can be differentiated into median, medial and lateral parts. The *median part* is a narrow, vertical band of medium-sized (15 x 9 $/^{u}$), very darkly staining, fusiform cells bordering the medial edge of the nucleus. The *medial part* covers more than half of the whole mamillary nucleus; it consists of medium sized (11 to 15 $/^{u}$), less darkly staining, oval or polygonal cells that are packed together rather compactly. The *lateral part* is smaller, compared to that in prosimians, and contains loosely arranged, med. sized (14 x 8 $/^{u}$), better staining, stellate cells that lie lateral and close to nn. mamillares lateralis and intercalatus.

Discussion on n. mamillaris medialis

In the Tupaioidea and all primates, n. mamillaris medialis is the largest cell group of the mamillary complex, and is generally spherical or ovoid in shape. It is divided into median, medial and lateral parts, which are better discernible in higher than in lower primates. In Perodicticus potto, Bauchot (1967) observed that n. mamillaris medialis appears to be divided into dorsal, ventral and rostral parts, rather than into medial and lateral parts as recognized in the same species in this study. The dorsal part of n. mamillaris medialis contains densely arranged cells that are much larger and more darkly staining than those of other parts. However, these divisions of Bauchot appear to correspond to the medial and lateral parts of the medial mamillary nucleus, and n. premamillaris in the prosimian mamillary region. Le Gros Clark (1938) did not mention the smaller divisions of n. mamillaris medialis in the human hypothalamus, but Papez and Aronson (1934) did so in the macaque. Śmialowski (1973) describes the medial mamillary nucleus of the macaque as consisting mainly of medial and lateral parts, readily distinguished in transverse sections. The lateral part of n. mamillaris medialis corresponds to its namesake distinguished by Gurdjian (1927) who observed that most fibres of the fornix end in this part of the rat brain. My observations of this termination of fornicate fibres, in not only the vervet and man, but also in Lemur and Galago, conform with those of Śmialowski in the macaque. The other parts of n. mamillaris medialis, particularly the median and medial parts, in all my tupaioid and primate specimens correspond well with those mentioned by Śmialowski and Papez and Aronson in the macaque.

The fact that the divisions of n. mamillaris medialis are more clearly defined in Cercopithecus aethiops than in lower primates may indicate evolutionary progress in the differentiation of the mamillary region in higher primates. In man, the mamillary regions are so large that they cause very marked swellings on the ventral surface of the hypothalamus. The human medial mamillary nucleus is more distinctly divided into median, medial and lateral parts than that of monkey and ape.

(c) N. mamillaris lateralis (ML)

N. mamillaris lateralis (Figs. 39-114; 179-180) is comparatively less well developed particularly in lower primates. It is difficult to distinguish this nucleus topographically and architectonically from the lateral part of n. mamillaris medialis. N. mamillaris lateralis is often confused with n. intercalatus which lies dorsolateral to it, but these two nuclei are better identified as separate entities in lower than in higher primates.

In the Tupaioidea, n. mamillaris lateralis is a comma-shaped structure lying along the ventrolateral surface of n. mamillaris medialis. Its cells are medium-sized (13 x 8 μ), well-staining and stellate. N. mamillaris lateralis terminates at a more rostral level than all other mamillary nuclei. The fibres of the fornix terminate mainly in n. mamillaris lateralis, thus giving it a more intensely myelinated appearance than n. mamillaris medialis.

In Prosimii and Anthropoidea, n. mamillaris lateralis is more easily distinguished from n. mamillaris intercalatus by its larger, more deeply staining and pyramidal cells. Furthermore, it can be located topographically by the terminating fibres of the fornix.

In Lemur catta and Cercopithecus aethiops, n. mamillaris lateralis lies medial to the lateral part of n. mamillaris medialis, lateral to the medial forebrain bundle and to the principal mamillary peduncle. Rostrally, it is limited by the lateral part of the posterior hypothalamic area. A dense network of fibres can be seen inside n. mamillaris lateralis; these fibres form a distinct bundle which runs mediodorsally through this nucleus and the lateral part of n. mamillaris lateralis to join the main mamillary fascicle. Other fibres run ventrolaterally from the lateral mamillary nucleus towards the mamillary peduncle which is the main fibrous connection between the mamillary region and the rest of the hypothalamus. The cells of n. mamillaris lateralis are large (15 x 10 μ), stain moderately darkly and are mostly stellate in shape and are packed closely together.

Discussion on n. mamillaris lateralis

There is still much disagreement today in regard to the location and extent of the cellular aggregates that are considered to represent either n. mamillaris lateralis, or n. intercalatus, or the caudal part of n. tuberomamillaris. According to Diepen (1962), n. mamillaris lateralis of Rose (1940) is equivalent to nn. mamillaris lateralis and tuberomamillaris pars caudalis of Brockhaus (1942). In Pongo and Gorilla, Feremutsch (1955, 1957) is not decided on the actual identity of n. mamillaris lateralis, as its cells are too scattered in the vicinity of the mamillo-infundibular zone to be considered a circumscribed nucleus. In the chimpanzee, however, n. mamillaris lateralis is cytologically similar to n. mamillaris medialis pars lateralis, whereas in man, these two nuclei are grouped together as the principal mamillary nucleus. In the Hylobatidae (Kanagasuntheram and Wong 1969), nn. mamillares lateralis and intercalatus of Ingram (1940) are incorporated into their n. mamillaris lateralis, which is then subdivided into dorsal and ventral parts. However, in this study, these two nuclei do remain separate entities as they possess distinct cytological and topographical characteristics. Therefore, in order to avoid unnecessary misinterpretation, it is convenient to term the small, comma shaped mass of large, dark-staining polygonal cells lying along the lateral border of n. mamillaris medialis n. mamillaris lateralis, and the smaller, less darkly staining, fusiform cells lying ventral and slightly caudal to n. mamillaris lateralis n. mamillaris intercalatus.

(d) N. mamillaris intercalatus (MIC)

In the Tupaioidea and lower primates, n. mamillaris intercalatus (Figs. 39-114; 177-180) is more poorly defined than nn. mamillares medialis and lateralis. It can be identified by its smaller (13 x 8 $/^{u}$), less darkly staining, stellate cells. They lie dorsal to n. mamillaris lateralis, close to the origin of the mamillothalamic tract, and medial to the posterior hypothalamic area. N. mamillaris intercalatus is a triangular structure that is wedged between the periventricular grey matter medially, and the tegmental region of the midbrain laterally. It extends farther caudally than n. mamillaris lateralis to the level where the mamillary body appears to be 'disembodied' from the hypothalamus.

In higher primates, n. mamillaris intercalatus is much more ill-defined, but can be identified as a small structure lying caudal to the rostral pole of n. mamillaris medialis, and extending much farther caudally than n. mamillaris lateralis towards the caudal end of the hypothalamus. The cells of n. mamillaris intercalatus are larger (18 - 22 $/^{u}$), more darkly staining and more pyramidal in shape than those of lower primates; they are arranged rather loosely between the mamillothalamic tract medially and the cerebral peduncle laterally.

Discussion on n. mamillaris intercalatus

The literature on n. mamillaris intercalatus is a history of terminological confusion. Today the term n. intercalatus is generally applied to the condensation of cells situated between the mamillary body and n. tuberomamillaris. Laruelle (1938) incorporated nn. mamillaris intercalatus and lateralis of Malone (1910) into his *paramamillary nucleus*. This term has been adopted by Diepen (1962) for his definition of a nucleus containing large, dark-staining, stellate cells lying lateral to n. mamillaris principalis (medialis and lateralis). Bauchot (1963, 1967) believes that the substitution of n. mamillaris principalis does not hold well for the caudal part of n. tuberomamillaris, nor does n. intercalatus (of Malone) for n. mamillaris lateralis. Bauchot (1963) suggests that the term n. intercalatus should be abandoned in favour of Diepen's term 'nucleus paramamillaris'. Whichever term, n. paramamillaris or n. intercalatus, is applied to the group of large and dark-staining cells lying lateral to the principal mamillary nucleus, is equally acceptable, as n. intercalatus can be cytologically and cytoarchitectonically distinguished from n. mamillaris lateralis as already observed in this study.

In the macaque Smialowski (1973) describes not one, but two intercalated nuclei, *nuclei intercalatus I and II*. N. intercalatus I is situated on the dorsolateral side of the principal mamillary nucleus. N. intercalatus II lies in the caudolateral part of the mamillary region between the mamillary peduncles and the fibrous capsule of the mamillary bodies. I have not observed the separation of n. intercalatus into these two parts in any of my tupaioid and primate specimens, as n. intercalatus in these animals is too small and ill-defined to justify any cellular or fibrous differentiation. In fact, n. intercalatus is merely a poorly formed collection of large, intensely staining, pyramidal cells lying ventral and lateral to n. mamillaris lateralis and forming a ventral part of the bed nucleus of the supramamillary decussation.

(e) *N. supramamillaris* (SPM)

N. supramamillaris (Figs. 39-114; 177-180) is a small band of small, darkly staining, fusiform cells covering the dorsal surface of n. mamillaris medialis between n. premamillaris rostrally and the caudal end of the mamillary body caudally. It is considered by many workers not as a separate entity, but as a local condensation of n. tuberomamillaris. Bauchot (1963, 1967) calls it perimamillary nucleus, because its cells form a sort of arch over the main mamillary nucleus, demarcating the mamillary region from the surrounding posterior hypothalamic area. Several authors such as Crosby and Woodburne (1940), Jessup and Shanklin (1940), Crosby et al (1962), and Crosby and Showers (1969) consider n. intercalatus as the ventral part of n. supramamillaris, for the cells of the former nucleus are scattered among the fibres of the supramamillary decussation.

In tupaioid and primate specimens used in this study, n. supramamillaris is a large, unpaired nucleus, common to both mamillary bodies, and lying transversely to the sagittal plane of the brain. In transverse sections, it is rectangular in shape. Laterally, n. supramamillaris lies close to the main mamillary fascicle, the terminating fibres of the fornix, n. intercalatus, the fields of Forel of the subthalamus, and the lateral part of the hypothalamic area. Dorsally, it borders on the dorsal part of the posterior hypothalamic area and the floor of the third ventricle.

The supramamillary commissure or decussation (smc or smd) is the main system of fibres which run in a compact bundle through the supramamillary nucleus over the principal mamillary nucleus to enter the subthalamus and posterior hypothalamic area. The cells of n. supramamillaris are almost identical in form to those of n. intercalatus, being large, well staining and stellate; they are arranged in neat rows among the arching fibres of the supramamillary commissure.

N. supramamillaris appears to be better developed in higher than in lower primates, particularly because the mamillary region has expanded to such an extent that it can be differentiated cytologically and topographically from other nuclei. My observations of n. supramamillaris and the supramamillary commissure in

Cercopithecus aethiops and *Homo sapiens* conform entirely with those of Śmialowski (1973) in the macaque.

(f) *N. inframamillaris* (IFM)

N. inframamillaris (Figs.40; 51-52; 89-90; 177-178) is situated mainly on the walls of the mamillary recess, and immediately caudal to the periventricular area of the infundibular region. Its cells so closely resemble those of n. periventricularis posterior that n. inframamillaris may form a part of the hypothalamic periventricular system. These cells are very small, lightly staining, round and are packed very closely along the walls of the inframamillary recess (imr).

N. inframamillaris is not mentioned by most workers, but it may be homologous to n. mamillaris cinereus of Crosby and Showers (1969).

N. inframamillaris is more readily identified in *Lemur* and *Perodicticus* than in any other species. In *Cercopithecus aethiops*, it is hardly present at all; therefore, my observation of this nucleus does not confirm that of Śmialowski (1973) in the macaque. This author described it as a small nucleus connected with the fibrous capsule of the mamillary body and the tuberomamillary bundle from the posterior hypothalamic area. I have not been able to trace these connections of n. inframamillaris in my primate specimens. Otherwise, this nucleus is merely another small formation connected with the supramamillary commissure, and with the hypothalamic periventricular system. N. inframamillaris is not present in anthropoid apes and man, thus indicating that it undergoes progressive reduction in structure and in functional importance as one goes up the primate scale.

SUMMARY OF THE POSTCHIASMATIC PART OF THE HYPOTHALAMUS

The infundibular and mamillary regions do not show many significant changes in structure and cytology. Perhaps the main change evident is that, through an increased number of cells and thicker fibre content, the mamillary bodies make notable protrusions below the ventral surface of the hypothalamus.

The nuclei of the infundibular region, particularly nn. ventromedialis and dorsomedialis appear to be better developed in lower than in higher primates, and in the former, each of these nuclei is cytoarchitectonically clearly differentiated into parts. N. ventromedialis is comparatively larger and better circumscribed than n. dorsomedialis throughout the primate scale. N. dorsomedialis is an ill-defined nucleus which is more closely related to the dorsal hypothalamic area than to n. ventromedialis. In all primates, the dorsal, lateral and posterior hypothalamic areas are large, diffuse masses of cells of varying sizes, shapes and staining intensity. Of these three areas, the posterior hypothalamic area shows best the attributes of a true nucleus, because it has not only definable borders, and a dense collection of medium-sized cells, but also different functions from those of the lateral and dorsal hypothalamic areas.

The mamillary region is the largest and best differentiated part of the entire hypothalamus. It consists mainly of lateral, medial and intercalated mamillary nuclei. The medial mamillary nucleus is the biggest of all the mamillary nuclei. It is well differentiated into median, medial and lateral parts. The lateral mamillary nucleus has been confused topographically and terminologically with the lateral part of n. mamillaris medialis and with n. mamillaris intercalatus. However, n. mamillaris lateralis has been definitely identified as a small area of large, dark-staining, stellate cells lying between n. mamillaris medialis and n. intercalatus. N. mamillaris intercalatus may be the ventral part of the supramamillary decussation, and can be seen lying lateral and caudal to nn. mamillares lateralis and medialis. The superamamillary and inframamillary nuclei are merely integral parts of the medial mamillary nucleus.

The structural features, cellular properties, myelin content and evolutionary trends of the nuclei of both infundibular and mamillary regions are summarized in Table 24.

TABLE 24 POSTCHIASMATIC PART OF THE HYPOTHALAMUS

	N. ventromedialis (VMH)	N. dorsomedialis (DMH)	N. tuberalis lateralis (TL)	N. tuberomamillaris (TM)	N. mamillaris medialis (MM)	N. mamillaris lateralis (ML)	N. mam. intercalatus (MIC)
STRUCTURAL FEATURES	Relatively larger and better developed in the Tupaioidea and in lower than in higher primates. Is separated from DMH and other nuclei by a clear acellular zone. In man, VMH is present, but is small and poorly defined, and seems to merge with the lateral hypothalamic area.	Better defined in Tupaia and lower primates than man and anthropoid apes. In the latter species, DMH loses its delimitations, but still retains its structural identity. It is surrounded by the lateral and dorsal hypothalamic areas on all sides.	Not well formed in Tupaia, but may be present as one or two small cell groups in the ventral part of the lateral hypothalamic area. Becomes progressively better defined on ascending the primate scale. In lower primates, TL is identified by some small cell condensations between VMH and TM. In higher primates, TL is well identified by two or more tubular groups which may be visible as tiny swellings on the ventral hypothalamic surface.	TM is more conspicuous than TL only in Tupaia and lower primates; in man and anthropoid apes, it forms merely a part of the posterior hypothalamic area. TM is located between the cerebral peduncle laterally, and TL and VMH medially, and beneath the terminating fibres of the fornix.	In all species, MM is comparable larger than ML and MIC; it is divisible cyto-architectonically into median, medial and lateral parts, as well as supra- and inframamillary portions. These portions are considered as separate entities, because they have differing topographical and cytological features. In higher primates, including man, MM increases so much in size and extent that it takes over almost the entire mamillary region. It forms the main part of the mamillary bodies that are visible as swellings on the ventral surface of the hypothalamus.	In all species, ML is a small, ill-defined structure that has often been termed either MMI or MIC. It is wedged between these two structures, and is distinguishable by its cellular characteristics and by being the terminus for the fornix system. ML has a much shorter rostrocaudal extent than all mamillary nuclei.	Is even smaller and more difficult to differentiate from ML. However, it is identified by its paramamillary position, by its forming part of the supramamillary decussation.
CELLULAR PROPERTIES	Cells are medium-sized (12 x 8 $/^u$ in Tupaia to 13 x 7 $/^u$ in Cercopithecus); they stain rather well and are oval to polygonal. There may be some large cells incursing into VMH from the lateral hypothalamic area. ~~Neuronal type of VMH is Type VI in all species~~.	Larger in size than VMH (13 x 9 $/^u$ in Tupaia to 16 x 11 $/^u$ in Cercopithecus). These cells stain more lightly and are rounder than those of VMH ~~(Type V)~~; they are packed more compactly.	Few medium-sized, well-staining, oval cells in Tupaia and lower primates (13-16 $/^u$; Type III). The cells increase in number, and are grouped into 1-4 small condensations lying above the surface of the tuber cinereum. These cells are large deeply staining and fusiform or polygonal (17 x 11 $/^u$, ~~Type VII~~ in Cercopithecus).	In lower primates, TM consists of a mixture of small and medium sized well-staining cells scattered throughout the nucleus. In higher primates, these cells are identical to those of the lateral and posterior hypothalamic areas.	Medium-sized, lightly staining and round cells (11 x 8 $/^u$ in Tupaia to 14 x 11 $/^u$ in Lemur) ~~mostly Type V~~. These cells are packed less densely than those of ML, but are rather dense in the dorsal part of MM.	Cells of ML are larger more darkly staining and pyramidal than those of MM (13 x 9 $/^u$ to 15 x 9 $/^u$; ~~Type V~~) in all species. In higher primates, cells of ML can easily be distinguished from those of MIC.	Cells of MIC are larger, less deeply staining, than those of ML. They are fewer in number, and are packed together rather loosely, particularly in its ventral part. The cells are 13 x 9 $/^u$ in Tupaia to 20 x 12 $/^u$ in Lemur.
MYELIN CONTENT	Light in all species.	Light in all species.	Fine fibres circumscribe the cell groups. A fibre bundle may connect TL with hypophysis.	Fibres course through TM, giving it a light network appearance.	MM is well myelinated in all species; more fibres in its lateral than medial part. Fibres of the mamillo-thalamic tract originate mainly in MM.	ML is more deeply myelinated than MM; the fibres of the fornix system terminate mainly in this nucleus.	Forms a part of the supramamillary decussation; is more myelinated than ML and MM.
EVOLUTIONARY TRENDS	Is slightly regressive, but has generally a stable phylogenetic valency throughout the primates. Monomorphous and isoform.	Is more regressive than VMH, but retains its identity in all primate species. Is rather heteromorphous and anisoform.	Appears very late in primates; its peak of progressive development is attained in man.	Regressive morphological features; is not definitely present in higher primates. Appears to have an inverse developmental relationship with TL in the primate scale.	Stable/progressive development from Tupaia to Homo. Marked increase in cellular differentiation into discrete parts.	No marked changes in structural and cytological features.	Progressive phylogenetic characteristics in higher primates. It is better developed and more distinct from ML and MM.