

# Zinc oxide-eugenol and calcium hydroxide pulpectomies in baboon primary molars: histological responses

P. CLEATON-JONES\*, M. DUGGAL\*\*\*, R. PARAK\*, S. WILLIAMS\*, S. SETZER\*\*

**ABSTRACT.** *Aim* To compare histological responses to zinc oxide-eugenol (ZOE) and calcium hydroxide (CH) pulpectomies in primary molar teeth with inflamed pulps. *Study design* This was an experimental study in 17 juvenile baboons (*Papio ursinus*). *Methods* Pulpitis was induced with fresh human carious dentine or *Streptococcus mutans* placed into occlusal cavities in 78 primary molars; after 14 days a pulpectomy was performed on the same primary molars with the two root fillings randomly allocated. The root canal openings were then covered with IRM and the cavity filled with amalgam. After 90 days specimens were harvested and examined under the light microscope with the examiner blind to the treatment. *Results* Reaction frequencies in the ZOE-treated versus CH-treated teeth were: no recognisable pulp 89% and 82%, internal root resorption 0% and 1%, external root resorption 11% and 24%, presence of bacteria 5% and 18%, periapical abscesses 24% and 52%. *Statistics* Fisher's exact probability test showed a statistically significant higher prevalence of periapical abscesses in the CH-treated group ( $P=0.03$ , relative risk 2.2). *Conclusions* ZOE pulpectomy is preferred to CH for the treatment of infected pulps in primary molars.

**KEYWORDS:** Baboon, Primary tooth, Pulpectomy.

## Introduction

For over 30 years pulpectomy has been a treatment recommended for the retention of primary teeth when a pulpotomy is not possible [Ranly and Garcia-Godoy, 2000; American Academy of Pediatric Dentistry, 2002]. Opinion varies, however, on which material to use as a root filling for such a pulpectomy. Coll and Sadrian [1996] studied factors influencing pulpectomy success in primary teeth and their effect on the succeeding tooth eruption and enamel formation after one visit zinc oxide-eugenol (ZOE) pulpectomies [Gould, 1972], a material they said was first described to fill root canals in the primary teeth 66 years earlier [Sweet, 1930]. They reviewed the records of 250 patients who had one or more ZOE

pulpectomies. Eighty-one cases (30 incisors and 51 molars) fulfilled inclusion criteria of a preoperative and at least two postoperative radiographs, extraction or exfoliation of the pulpectomised tooth and eruption of the successor. Coll and Sadrian [1996] reported a 77.7% success rate in the 81 teeth after follow up of 90.8 months, with enamel defects observed in only 18.7% of the succeeding teeth associated significantly with the amount of preoperative root resorption. These authors felt that the ZOE pulpectomy was not the source of enamel defects in succeeding teeth because the rates did not differ from the contralateral untreated controls. They noted that the pulpectomy success rate was influenced by the distance of the ZOE down the root canal. Teeth filled short of the apex, or completely to the apex, had a significantly greater success rate than those overfilled. Pulpectomised teeth were lost later than normal, about 36% needed tooth extraction.

The success rate in Coll and Sadrian's [1996] study is similar to that of the original study of Gould [1972] who suggested a one visit ZOE pulpectomy. In his investigation 39 primary molars filled with ZOE were

\*Medical Research Council/University of the Witwatersrand Dental Research Institute

\*\*Division of Restorative Dentistry, School of Oral Health Sciences,  
University of the Witwatersrand, Johannesburg, South Africa

\*\*\*Division of Child Dental Health, Leeds Dental Institute, Leeds, United Kingdom

E-mail: cleatonjonesp@dentistry.wits.ac.za

followed for an average of 16 months; 35 (89.7%) were successful but no mention of ZOE resorption or defects in the succeeding premolars was made.

A dissenting view is that of Holan and Fuks [1993] who compared pulpectomies using ZOE and KRI paste in primary molars. A 12 to 48 months follow-up of 78 pulpectomised teeth showed 84% success for KRI paste and 65% success for ZOE. Overfilling with ZOE produced twice the failure rate of KRI paste. These authors recommended KRI paste as preferred treatment for non-vital primary molars.

Another root filling material for primary teeth is calcium hydroxide (CH). Mani et al. [2000] carried out a clinical study in 60 primary mandibular molars using either ZOE or CH mostly by single visit pulpectomy. Clinical success rates were 83.3% and 86.7%, respectively. They felt that either material may be used.

The current study was an experimental comparison of ZOE and CH as root filling materials in primary molars with induced pulpitis in a non-human primate using the one visit technique of the Department of Paediatric Dentistry at Leeds Dental Institute, University of Leeds.

## Materials and methods

*Study design.* Prior to beginning the study ethics approval was obtained from the Animal Ethics Screening Committee of the University of the Witwatersrand (Clearance 98/36/4). Seventeen juvenile baboons (*Papio ursinus*) of unknown age, weighing 3-4 kg, with erupted primary molars and first permanent molars were the study animals. They were housed in the University's Central Animal Service in a purpose-built primate facility with controlled environment, feeding, and daily professional care. The sample size was determined by a combination of budget and ethics considerations to provide approximately 30 teeth in each of four treatment groups, two of which are reported in this study.

*Randomization and blinding.* ZOE and CH were allocated to teeth using a randomization block with eight holes, marked 55 to 85 to represent the primary molars in the four quadrants, and eight pegs, two marked for each of four treatments (two pulpotomy treatments were a separate experiment). For each baboon, the pegs were shuffled then placed into the numbered holes in clockwise sequential order from 55 to 85.

*Operative methods.* Each baboon was immobilized with an intramuscular injection of ketamine hydrochloride after which anaesthesia was induced

with intravenous thiopentone followed by insertion of a nasal endotracheal tube to maintain the airway. Anaesthesia was maintained with inhalation of halothane and oxygen in a semi-closed circuit with carbon dioxide absorber. Vital signs were electronically monitored throughout the anaesthesia.

Pulpitis was induced based on two reported methods [Mjör and Tronstad, 1972; Fuks et al., 1997] and was checked in a study of two baboons [Cleaton-Jones et al., 2002] that confirmed the pulpitis. The primary molars were isolated with rubber dam and an occlusal cavity was cut with a water-cooled high speed bur. A small pulpal exposure was then made in the floor of the cavity with a 1 mm diameter round bur. The cavity was then swabbed with 37% phosphoric acid and dried with cotton wool pellets. A small piece of fresh carious dentine or a piece of nutrient agar with a single 24-hour colony of *Streptococcus mutans*, grown at 37°C under anaerobic conditions in Tryptone Soy agar containing 5% horse blood, was placed over the exposure. The cavity was restored with a light-cured composite resin without etching (Z100®, 3M Dental Products, St Paul, Minnesota, USA).

Two weeks later the baboons were anaesthetised as before, the primary molars were isolated with rubber dam and the coronal pulp chamber was opened with a high speed, water-cooled bur. The coronal pulp was removed with a low speed round bur and haemostasis was obtained with saline and cotton-wool pellets. The root canals were identified and the pulps extirpated with barbed broaches (Kerr Dental, USA). The canals were then debrided with K-files (Nitiflex®, Dentsply Maillefer, Switzerland), rinsed with 0.9% sterile saline then dried with paper points. Slurries of pharmaceutical grade ZOE or CH were spun into the root canals with lentulo spirals (Dentsply Maillefer, Switzerland). All cavities were dressed with IRM® (Caulk Dentsply, Milford, Delaware, USA) and sealed with amalgam. Postoperatively the baboons were fed a soft diet of maize porridge plus veterinary protein-vitamin-mineral mix (PVM Products Ltd, South Africa) for seven days then returned to the standard laboratory diet of baboon cubes, protein-vitamin-mineral mix plus fruit of the day. A single dose of an intramuscular narcotic analgesic, buprenorphine (Temgesic®, Shering-Plough, South Africa) was given once the baboons had emerged from the general anaesthetic. Regular monitoring each day indicated that no further doses were required; need for analgesia was indicated by poor eating or depression. Ninety days later, each baboon was immobilized with ketamine and humanely killed with an intravenous overdose of pentobarbitone. The

thoracic aorta was cannulated and the right atrium of the heart was opened, followed by retrograde perfusion of the head with 1 L of 0.9% saline then 1 L of 10% buffered formol saline. When perfusion was completed the head was removed, soft tissue dissected off and the maxilla and mandible cut away from the skull with a motorized band saw. Each jaw was then trimmed with the band saw anterior to the canine and distal to the first permanent molar to produce a jaw quadrant block containing the experimental teeth. The jaw quadrants were then radiographed from the lateral aspect on occlusal films. Decalcification was in a mixture of sodium citrate (0.03M), formic acid (1.6N) and hydrochloric acid (0.65N), or in Shandon TBD-1 rapid decalcifier® (Shandon Inc., Pittsburgh, Pennsylvania, USA) depending on availability, over approximately one month with the end point monitored with radiographs. The specimens were processed into wax and serial sections of the quadrant block cut at 5 to 6 µm. Every tenth section was stained with haematoxylin and eosin and representative sections with a modified Gram stain [Brown and Brenn, 1931]. Cut sections were labelled with a sequential code and quadrant but not the treatment, to ensure blinding of the examiner during microscopy. The code was broken after assessment of the tissue responses.

*Assessment of responses.* The radiographs of the jaw quadrant blocks were examined for periapical radiolucencies. In each histological section the following tissue responses were looked for:

- within the root canal - any recognizable pulp and where this was situated, internal and external root

- resorption (other than that associated with normal tooth exfoliation), and Gram-stained bacteria;
- at the periapex - any abscess which was defined as a recognizable collection of acute or chronic inflammatory cells of any size. The radiographs of the jaw quadrant blocks were examined for periapical radiolucencies.

*Statistical analysis.* Fisher's exact test was applied for comparison of frequency data using InStat® [Version 3.02, GraphPad Software Inc, San Diego, California, USA]. A P value of <0.05 was considered to be statistically significant.

## Results

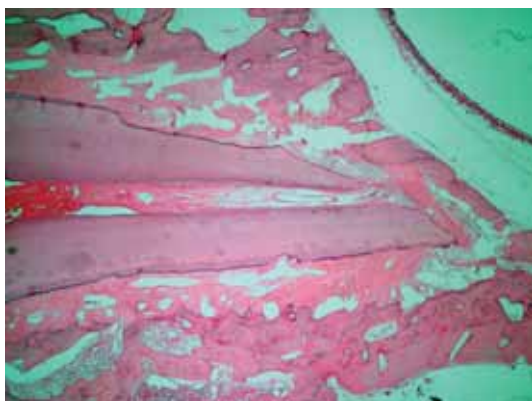
Twelve ZOE and 10 CH pulps did not bleed when the coronal pulp was opened; one tooth was excluded from the study because of an apical abscess pointing into the buccal sulcus when pulpectomy was scheduled. This was to ensure standardization in the study. Each baboon gained approximately 1 kg during the 90 day post-pulpectomy, which is the expected normal weight gain for their size, and all ate the standard laboratory diets without obvious discomfort.

Six of the 77 pulpectomised teeth were not included in the histological assessment - there were two exfoliations and in one tooth the cavity preparation had extended through the crown into the furcation in the ZOE teeth, as well as three exfoliations in the CH teeth. Typical tissue responses were checked with two experienced oral pathologists.

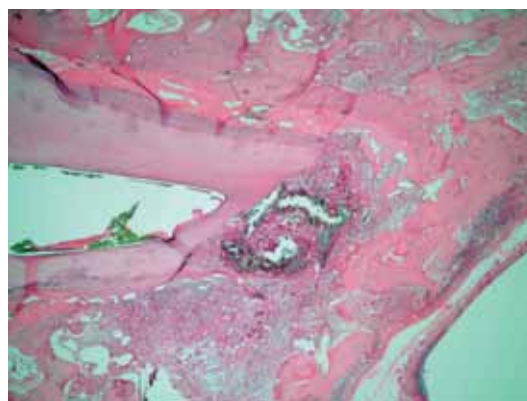
Frequencies of tissue responses are listed in Table 1. No recognisable pulp was seen in 89% of the ZOE

Variable	Zinc oxide-eugenol		Calcium hydroxide	
	n	%	n	%
Number of teeth	38		33	
Recognizable pulp:				
none	34	89	27	82
only at apex	3	8	3	9
root canal and apex	1	3	3	9
External root resorption	4	11	8	24
Presence of bacteria	2	5	6	18
Periapical abscess	9	24	17	52
Periapical abscess on radiograph	6/9	6/17		
Periapical abscess and bacteria in pulp	1/9	5/17		
Periapical abscess and no bacteria in pulp	8/9	12/17		

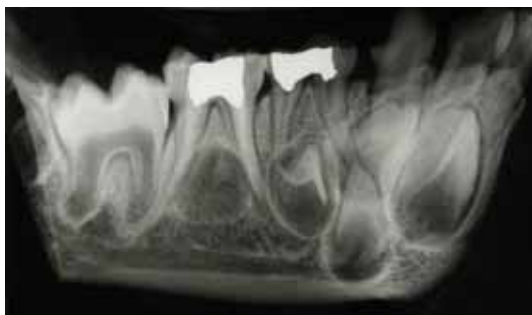**TABLE 1** - Frequencies of observations for zinc oxide-eugenol versus calcium hydroxide for pulpectomy in primary baboon teeth.



**FIG. 1** - Viable pulp tissue in the root canal at the apex of zinc oxide-eugenol treated primary tooth. Haematoxylin and eosin x 20.



**FIG. 2** - Periapical abscess after calcium hydroxide root canal filling in a primary tooth. Haematoxylin and eosin x 20.



**FIG. 3** - Radiograph of excised jaw quadrant showing an apical abscess at the mesial root of the second primary molar partly obscured by overlapping tooth germs. There is also widening of the periodontal ligament at the mesial and distal apices of the first primary molar.

and 82% of the CH teeth. When tissue was seen, this was almost always at the tooth apex indicating successfully extirpated pulps (Fig. 1). External root resorption, other than that normally part of exfoliation, was uncommon but the rate in CH teeth was twice that in ZOE teeth. Bacteria were seen more frequently in CH teeth than ZOE teeth. Periapical abscesses (Fig. 2) were present in over half of the CH teeth and a quarter of the ZOE teeth; in both groups bacteria were not commonly seen in the abscess. It was not possible to see all the histological abscesses on the radiographs, in spite of the clarity of the radiographs without soft tissue, because of the size of the abscess and overlapping of developing teeth. An example of an abscess that was seen on a radiograph is shown in Figure 3.

Fisher's exact probability test showed a statistically significant higher prevalence of periapical abscesses in the CH treated group ( $P=0.03$ , relative risk 2.2).

## Discussion

This study has shown a statistically significant higher prevalence of periapical abscesses in teeth filled with CH compared with ZOE. In an earlier study in two baboons to test the pulpitis induction method used in the current study, periapical abscesses were seen in half of the teeth [Cleaton-Jones et al., 2002]. As the rate of periapical abscesses in the CH group was the same as in the induction study [Cleaton-Jones et al., 2002] but that in the ZOE teeth was a quarter of the induction rate, there is a suggestion that ZOE is superior to CH. The higher success rate may also have been influenced by filling to the apex only, as Holan and Fuks [1993] showed clearly that overfilling with ZOE is detrimental to periapical healing. Tchaou et al. [1996] exposed standard bacterial cultures to 10 root filling materials or combinations of these. Included in this study were ZOE and CH alone. ZOE was more inhibitory than CH which had surprisingly little effect on bacteria in the agar diffusion test used. The current study supports these observations.

Ranly and Garcia-Godoy [2000] cautioned that ZOE is resistant to foreign body giant cells and not very antibacterial once it has set, something of importance in the root canals of primary teeth with their many accessory canals. They preferred KRI paste and a mixture of iodoform and CH.

Andreassen et al. [2002] were concerned that long-



term calcium hydroxide as a root canal dressing may increase the risk of root fracture. They compared the fracture strength of immature sheep tooth roots filled with CH and root canals filled with saline. There was a marked decrease in fracture strength with immersion in saline and for teeth treated with calcium hydroxide so that the fracture strength would be halved in about one year. The weaknesses of the Andreasen et al. [2002] study are that it was carried out in sheep and that the comparison was to saline filled roots and not to other root canal fillings.

Should primary teeth be root filled? This is a question posed by clinicians given that a proportion of pulpectomised teeth may retain inflammation at the periapex of teeth. In the latter instance inflammation and prolonged irritation are believed to be causal for dentigerous cysts [Grundy et al., 1984; Benn and Altini, 1996]. This suggests that a treatment associated with inflammation should not be done. Primary teeth have a limited period in the mouth so that inflammation should disappear once the tooth is lost. The current study has shown a high prevalence of periapical abscesses but clinical success could not be judged. In everyday human practice clinical signs and symptoms determine success. In baboons this is not possible to determine in the same way but normal weight gain, eating and an apparent lack of pain would suggest that there had been clinical success.

Are experimental observations in animal models directly applicable to humans? While it may be argued that this is questionable for some species, Pascon et al. [1991] consider non-human primates as the best animal model for endodontic studies. We agree with this view.

## Conclusion

This study has shown that after experimental induction of pulpitis in baboon primary molars followed by one visit pulpectomy, zinc oxide-eugenol was associated with significantly fewer periapical abscesses than calcium hydroxide.

## Acknowledgements

We are most grateful to the staff of the Central Animal Service of the University of the Witwatersrand for their professional help and to Professors M. Altini and H. Coleman for advice on the tissue reaction diagnosis. This study was supported by a Wellcome Trust Collaborative Research Initiative Grant.

## References

- American Academy of Pediatric Dentistry. Guidelines for pulp therapy for primary and young permanent teeth. *Pediatr Dent* 2002;24(special issue):86-90.
- Andreasen JO, Farik B, Munksgaard EC. Long-term calcium hydroxide as a root canal dressing may increase risk of root fracture. *Dent Traumatol* 2002 Jun;18(3):134-7.
- Benn A, Altini M. Dentigerous cysts of inflammatory origin. A clinicopathologic study. *Oral Surg Oral Med Oral Pathol Oral Radiol Endod* 1996 Feb;81(2):203-9.
- Brown JH, Brenn L. A method for the differential staining of gram-positive and gram-negative bacteria in tissue section. *Bull Johns Hopkins Hosp* 1931;48:69-73.
- Cleaton-Jones P, Parak R, Setzer S, Williams S, Duggal M. Induction of pulpitis in baboon primary teeth with *Streptococcus mutans*. *J Dent Res* 2002;81(Spec Iss B):B246, abstract 119.
- Coll JA, Sadrian R. Predicting pulpectomy success and its relationship to exfoliation and succedaneous dentition. *Pediatr Dent* 1996 Jan-Feb;18(1):57-63.
- Fuks AB, Eidelman E, Cleaton-Jones P, Michaeli Y. Pulp response to ferric sulfate, diluted formocresol and IRM in pulpotomized primary baboon teeth. *ASDC J Dent Child* 1997 Jul-Aug;64(4):254-9.
- Gould JM. Root canal therapy for infected primary molar teeth: preliminary report. *ASDC J Dent Child* 1972 Jul-Aug;39(4):269-73.
- Grundy GE, Adkins KF, Savage NW. Cysts associated with deciduous molars following pulp therapy. *Aust Dent J* 1984 Aug;29(4):249-56.
- Holan G, Fuks AB. A comparison of pulpectomies using ZOE and KRI paste in primary molars: a retrospective study. *Pediatr Dent* 1993 Nov-Dec;15(6):403-7.
- Mani SA, Chawla HS, Tewari A, Goyal A. Evaluation of calcium hydroxide and zinc oxide eugenol as root canal filling materials in primary teeth. *ASDC J Dent Child* 2000 Mar-Apr;67(2):142-7, 83.
- Mjör IA, Tronstad L. Experimentally induced pulpitis. *Oral Surg Oral Med Oral Pathol* 1972 Jul;34(1):102-8.
- Pascon EA, Leonardo MR, Safavi K, Langeland K. Tissue reaction to endodontic materials: methods, criteria, assessment, and observations. *Oral Surg Oral Med Oral Pathol* 1991 Aug;72(2):222-37.
- Ranly DM, Garcia-Godoy F. Current and potential pulp therapies for primary and young permanent teeth. *J Dent* 2000 Mar;28(3):153-61.
- Sweet CA. Procedure for treatment of exposed and pulpless deciduous teeth. *J Am Dent Assoc* 1930;17:1150-3.
- Tchaou WS, Turng BF, Minah GE, Coll JA. Inhibition of pure cultures of oral bacteria by root canal filling materials. *Pediatr Dent* 1996 Nov-Dec;18(7):444-9.