

Multifocal osteomyelitis and abdominal abscessation in a warmblood foal

Multifocale osteomyelitis en abdominale abcesvorming bij een warmbloedveulen

¹L. Rasmussen, ¹K. Vanderperren, ²E. Paulussen, ²G. Van Loon, ¹J. H. Saunders, ¹E. Raes

¹ Department of Medical Imaging and Small Animal Orthopedics, Faculty of Veterinary Medicine, Ghent University, Salisburylaan 133, B-9820 Merelbeke

² Department of Internal Medicine and Clinical Biology of the Large Animals, Faculty of Veterinary Medicine, Ghent University, Salisburylaan 133, B-9820 Merelbeke

ABSTRACT

To the authors' knowledge, this is the first report, in which a simultaneous occurrence of *Salmonella*-associated multifocal osteomyelitis and intra-abdominal abscessation in a foal presenting with weight loss, diarrhea and fever is described. No evidence of failure of passive immune transfer had been present at birth. Radiographic examination revealed multifocal type P osteomyelitis. Bacterial culture of synovial fluid revealed a *Salmonella* spp. Antibiotic treatment was adjusted based on the sensitivity results; however without clinical improvement. The foal developed abscess formations within the left femoral region, and finally a Salter Harris type I fracture of the left femur. Euthanasia was elected based on this finding. Post-mortem computed tomography revealed a large mass within the caudal abdomen that extended into the left pelvic and hind limb region, as well as multifocal osteomyelitis.

Pathological examination identified the mass as a large abscess with multiple fistula tracts. *Salmonella* spp. was additionally cultured post mortem.

SAMENVATTING

Volgens de auteurs is dit de eerste casuïstiek waarin het simultane voorkomen wordt beschreven van multifocale osteomyelitis en abdominale abcesvorming veroorzaakt door *Salmonella* bij een veulen met gewichtsverlies, diarree en koorts. Er was geen falen van het passieve immuunsysteem na de geboorte van het veulen. Radiografisch onderzoek toonde multifocale osteomyelitis (type P). In de bacteriële cultuur van het gewrichtsvocht werd *Salmonella*-species geïdentificeerd. De antibioticatherapie werd afgestemd op de resultaten van het antibiogram, echter zonder klinische verbetering. Abscessen ontwikkelden zich verder in de linker dij en een Salter-Harrisfractuur type I van de linkerfemur werd vastgesteld. Er werd beslist om over te gaan tot euthanasie van het veulen. Postmortaal computertomografisch onderzoek toonde een grote massa in het caudale abdomen, die uitliep tot in de regio van het linkerbekken en achterbeen. Er werden eveneens multifocale osteomyelitis aangetoond.

Middels het pathologisch onderzoek werd de massa als een abces met verschillende fistelgangen geïdentificeerd. Postmortem bacteriologisch onderzoek toonde eveneens *Salmonella*-species aan.

INTRODUCTION

Osteomyelitis with or without associated septic arthritis is a serious orthopedic condition in foals. Septic arthritis is the primary differential diagnosis in any foal presenting with joint effusion and lameness.

Neonatal foals lack adaptive immunity and must obtain all of their antibodies from the ingestion of colostrum. Failure of passive immune transfer is the

primary cause of septicemia in foals (Raidal et al., 1996). Septic osteomyelitis is most often the result of hematogenous dissemination of bacteria (Firth, 1983; Hardy 2006). Bacterial infection usually arises from the umbilical region or the respiratory or gastrointestinal tract and may result in septicemia.

In young foals, transphyseal vessels connect and allow communication of the epiphysis and metaphysis blood supply. Closure of the transphyseal vessels

occurs approximately at seven to ten days of age. Hematogenous bacteria can locate in any of these three areas creating septic foci. A classification scheme for septic arthritis/osteomyelitis lesions in the foal has been described by Firth (1983) according to their location within joint and/or bone.

Type S (synovial) is defined as inoculation of the synovial membrane in one or more joints with no radiographic evidence of osteomyelitis, type E (epiphyseal) is defined as osteomyelitis of the subchondral bone, type P (physeal) is defined as osteomyelitis of the physis on the metaphyseal side of the growth plate, and type T is osteomyelitis of the small cuboidal bones in the tarsus or carpus (Firth, 1983).

Depending on an intra- or extra-articular location on the physis, bone inoculation can occur simultaneously with synovial inoculation.

Young foals suffer predominantly from infectious arthritis type S or E, whereas older foals more often suffer from type P infection (Firth, 1983; Hardy, 2006).

Previous studies have documented that the most common bacterial isolates from foals with septic arthritis/osteomyelitis are *Enterobacter* spp., *E. coli*, *Actinobacillus* spp., *Salmonella* spp. and *Streptococcus* spp. (Martens et al., 1980; Brewer et al., 1990; Vatis-tas et al., 1993).

Radiography is historically the most commonly used imaging modality in diagnosis of septic arthritis and osteomyelitis in horses (Schneider 1999). However, radiographic signs of osteomyelitis are only seen when 50–70% of the bone is demineralized (Wegener, 1991; Goodrich, 2006), resulting in a radiographic lag period of up to 21 days (Firth 1983; Roberts et al., 2010). This can cause a delay in diagnosis and prognostic information, as the detected radiographic changes may not accurately demonstrate the severity of the lesion.

Septic osteomyelitis is managed medically with appropriate antibiotics, and surgically when access to the site of infection is possible. The outcome is impacted by delays in treatment, concurrent illness and bacteria pathogenicity (Neil et al., 2010).

Described herein are the clinical and diagnostic imaging findings, as well as treatment and outcome of a case of multifocal osteomyelitis and abdominal abscessation in a foal.

CASE REPORT

A two-month-old warmblood filly was presented with a complaint of fever and weight loss for two days despite a good appetite. At presentation, there was no evidence of failure of passive immune transfer, and a SNAP foal test had been performed at birth (>8g/L). The foal was the third born out of the mare, with no history of complications regarding her past progeny. The foal had been treated by the referring veterinarian with flunixin meglumine, gentamicin and penicillin.

Clinical examination

On presentation, the foal was quiet but responsive. The body condition was below average (91 kg). Rectal temperature was 38.5°C, pulse rate 92 beats per minute, respiratory rate 24 breaths per minute and capillary refill time less than two seconds. The mucous membranes were pale, and the eyes appeared sunken.

Auscultation of the lungs revealed increased lung sounds on the left side compared to the right. Abdominal borborygmi were absent on the right side and decreased on the left. An umbilical hernia was present. Abdominal ultrasound revealed increased fluid content within the colon and cecum, consistent with diarrhea. The left hind metatarsophalangeal joint was distended and an arthrocentesis was subsequently performed. Blood was collected for hematological and biochemical analysis, which revealed an increased serum amyloid A (SAA) of 1040 µg/ml (normal 2.3 µg/ml).

Electrophoresis was not performed, as the total protein was normal. Hyperimmune plasma was not administered as the SNAP foal test at home and total plasma protein were within normal limits.

Synovial fluid from the left metatarsophalangeal joint yielded *Salmonella* spp. Similarly, bacterial blood culture was also positive for *Salmonella*. Sensitivity results indicated that the organism was susceptible to all antimicrobials against which it was tested (ampicillin-amoxycillin, amoxycillin-clavulanic acid, ceftiofur-cefquinome, fluoroquinolones, tetracyclin, doxycyclin, neo, kana, fram, paromomycin, gentamicin, amikacin, sulfonamide, trimethoprim and trimethoprim+sulfonamides). Treatment with ceftiofur (Excenel; intravenously (IV) (9d) followed by intramuscular (IM) (2d); 7.5 mg/kg BID) was initiated. Additional treatment with ketoprofen (ketofen; 2.2 mg/kg IV SID) was initiated at day 11, and changed to firocoxib (Equioxx; 0.1 mg/kg PO SID) at day 21. Antibiotic treatment was changed at 11d, 22d, 44d and 50d to amoxicillin (Amoxiclav; 20 mg per oral (PO) TID), doxycycline (Doxylin; 10 mg/kg PO BID), clarithromycin (Clarithromysine Sandoz; 7.5 mg/kg PO SID) and rifampicin (Rifadin; 5 mg/kg PO SID), respectively. The foal additionally received anti-ulcer therapy (Omeprazole 4 mg/kg po) for two weeks.

The changes in antibiotic treatment were based on a lack of improvement of the clinical signs and persisting fever, and antibiotics were consistently selected according to the antibiogram of the blood culture.

After two weeks at the hospital, the foal had deteriorated and became lethargic. Severe effusion of the right tarsus developed and an arthrocentesis was performed. The centesis revealed a total white blood cell count of 4.7×10^8 cells/dL (normal reference < 300 cells/dL) and a total protein of 38 g/dl (normal reference < 2.5 g/dL), consistent with infection (Schneider 1999). Regional perfusion was performed (Ceftiofur; 5 mg/kg) of the right hind limb, which improved the

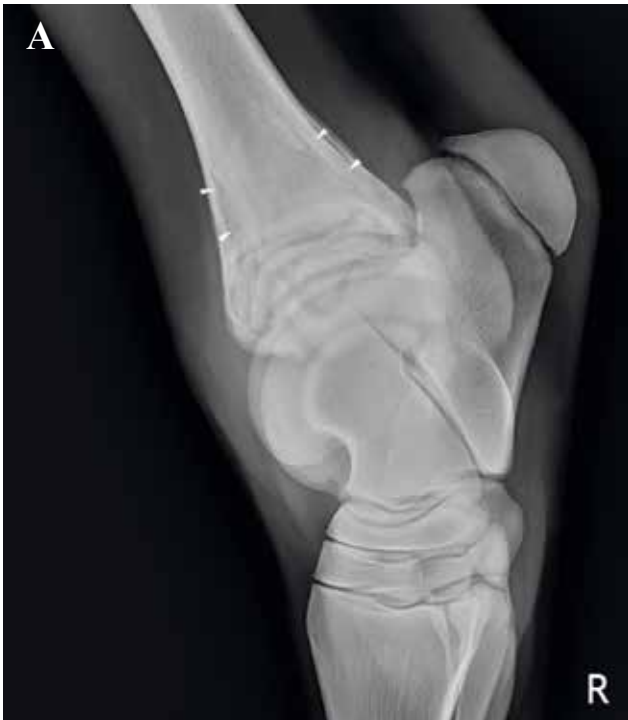

Figure 1A. Initial lateromedial radiographic examination of the right tarsus. Soft tissue swelling is present at the cranial aspect of the distal tibia. Ill-defined subcortical radiolucent zones are seen within the distal metaphysis of the tibia (arrowheads), as well as ill-defined, radiolucent areas within the distal physis.

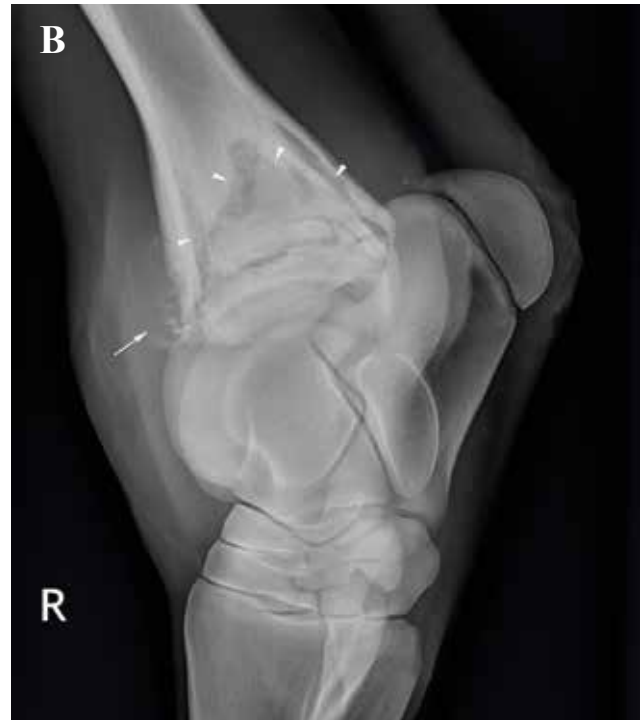

Figure 1B. Radiographic examination on day 36. There is an increased soft tissue swelling at the cranial aspect of the distal tibia. The radiolucent zones within the distal metaphysis are markedly more conspicuous and well-defined, creating a triangular shape (arrowheads). Irregular new bone formation is present at the craniodistal aspect of the tibia, extending into the adjacent soft tissues (arrow).

lameness short term. Three follow-up centeses were performed with progressive improvement of the values. However, after one month, the foal would no longer stand or get up unassisted.

At one and a half month after presentation, an abscess was detected adjacent to the left coxofemoral joint ultrasonographically. Repeated lavage of the abscess cavity was performed.

Diagnostic imaging

Radiography

No significant bony abnormalities were detected on the left metatarsophalangeal joint at the time of presentation. Lateromedial, dorsoplantar, dorsomedial-plantarolateral oblique and dorsolateral-plantaromedial oblique views were obtained of the right hind tarsus when joint effusion was first detected (Figure 1A). The examination showed moderate soft tissue swelling, most prominent at the level of the tibiotarsal joint and distal physis of the tibia. Ill-defined, periosteal new bone formation was present along the distal metaphysis of the tibia. Subcortical osteolysis was seen extending along the distal metaphysis of the tibia as well as diffuse radiolucent areas involving the distal physis. Based on the radiographic findings, a

diagnosis of osteomyelitis type P involving the distal physis of the tibia was made. Follow-up radiographic examinations of the right hind tarsus were made at 7d, 14d, 22d, 29d and 36d (Figure 1B).

The evolution of subsequent radiographic examinations included widening and increased demarcation of the subcortical radiolucent zones along the distal metaphysis with the appearance of a triangular zone of decreased opacity within the metaphysis, more pronounced appearance of the lucent areas within the physis, an increasing amount of ill-defined periosteal reaction and persisting soft tissue swelling. On day 22, radiographic examination of the left hind tarsus and both stifle joints was performed based on clinical findings. Radiographic findings of the left hind were similar to the initial examination of the right hind. Examination of the left stifle showed marked soft tissue swelling at the cranial aspect of the joint. Patchy radiolucent areas were detected within the subchondral bone of the lateral and medial trochlear ridges. The distal physis of the femur appeared widened. An ill-defined, triangularly shaped lucent zone surrounded by a sclerotic rim was present within the distal metaphysis of the femur. An irregularly outlined, linear radiolucent area was also detected adjacent to the proximal physis, within the proximal metaphysis of the tibia. No soft tissue swelling of the right stifle was

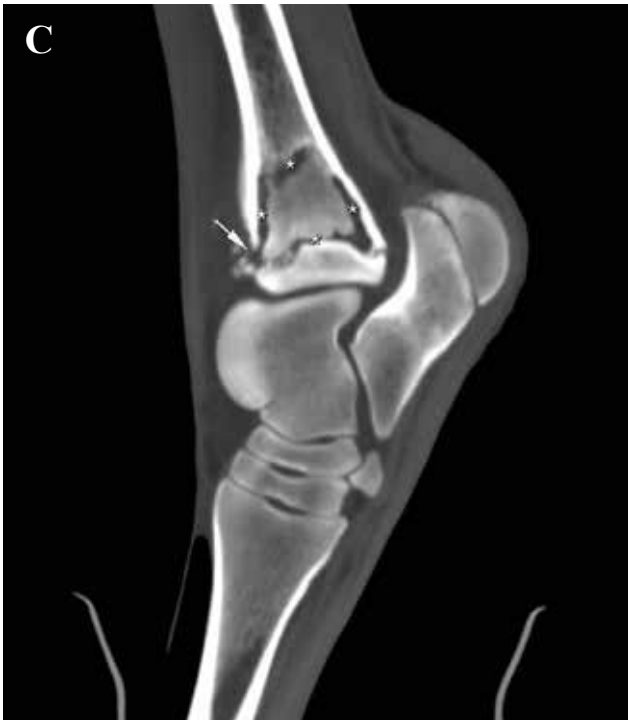

Figure 1C. Post-mortem computed tomographic image of the same limb. Well-defined, linear hypoattenuating zones are seen adjacent to the cortex of the distal metaphysis and within the distal physis of the tibia (asterisk symbols). The craniodistal tibial cortex is disrupted (arrow). The triangular, hypoattenuating zone within the distal metaphysis was consistent with pus accumulation found on gross pathology.

detected. Severe, ill-defined, radiolucent areas surrounded by sclerosis were present within the femoral trochlear ridges of the right hind. Radiolucent areas were also detected within the metaphysis and physis of the distal femur. A similar linear, radiolucent area adjacent to the proximal physis of the tibia was also seen in the right hind (Figure 2). A diagnosis of arthritis of the femoropatellar joint and osteomyelitis type E and P involving the distal femur and proximal tibia was made.

Radiographic re-evaluations of both stifles were performed at 29d and 36d. Progression of radiographic findings included increased soft tissue swelling (also involving the right stifle), increased conspicuity of the radiolucent areas within the metaphysis of the tibia, ill-defined radiolucent areas within the patella, subchondral bone lucencies within the femoral condyles, increased severity of the irregular outline and radiolucent areas of the femoral trochlear ridges. On subsequent radiographs several small, rounded gas opacities and ill-defined mineral opacities were detected within the caudal soft tissues of the left femoral region. Focal, ill-defined, mineral opacities were also seen at the cranial and caudal aspect of the proximal tibia.

Based on the radiographic findings, abscess for-

mation within the soft tissues of the femoral region was suspected, and an ultrasonographic examination was recommended.

Ultrasound

Multiple, diffuse, heterogeneous and hypoechoic areas containing hyperechoic foci (gas) were detected within the muscles and subcutaneous tissues adjacent to the left coxofemoral joint (abscess). A gas containing fistula tract could be followed extending under the left ilium. Additionally, the abscess extended distally to the level of the tibia. The bony surface of the proximal femur was markedly irregular.

Based on the ultrasound findings and the poor clinical progression of the foal, a radiographic examination of the pelvis was performed. The examination revealed a complete disruption of the proximal physis of the femur with caudal displacement of the distal femur in relation to the femoral head consistent with a Salter Harris type I fracture, suspected to be of pathologic origin (Figure 3).

Outcome

Despite prolonged therapy, the foal deteriorated clinically. Based on the severity and grave prognosis of the femoral fracture, euthanasia was elected.

Post-mortem computed tomography (CT)

A CT examination was performed post mortem for educational purposes. A large, ill-defined structure was detected within the left caudal abdomen, causing a mass effect on the surrounding structures (Figure 4A). The content was heterogeneous and hypoattenuating with a tissue density of approximately twenty

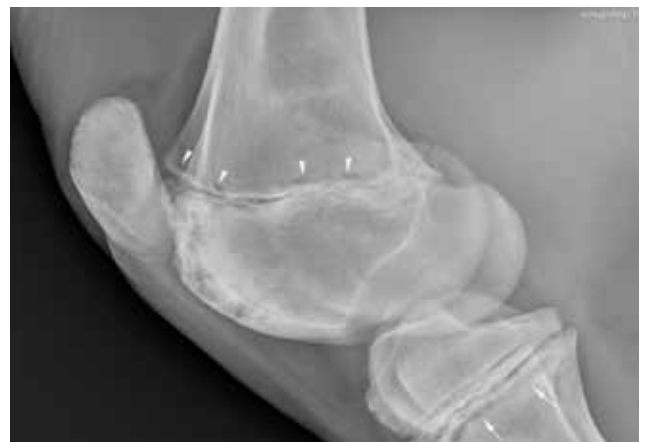

Figure 2. Lateromedial radiograph of the right stifle joint. Patchy radiolucent areas are detected within the lateral and medial trochlear ridges, and within the distal physis of the femur (arrowheads). An irregularly outlined, linear radiolucent area is also detected adjacent to the proximal physis of the tibia (arrows).

Hounsfield units (HU), consistent with cellular fluid. Several gas opacities and multifocal mineralization were present within the content. A fistula tract originated from the caudal aspect of the structure, extending under the axial aspect of the left ileal wing, and then in an abaxial direction to the lateral aspect of the left coxofemoral joint (Figure 4B). Multiple gas opacities were detected within the soft tissues caudal to the left femur; however, a clear connection could not be detected on the CT images. Given the post-mortem examination, contrast-enhanced CT was not possible.

Within the right tibia, well-defined, linear hypoattenuating zones were detected adjacent to the cortex of the distal metaphysis and within the distal physis creating a triangular demarcation of the medulla (Figure 1C). The hypoattenuating zones had a tissue density of approximately 60 HU compared to the 260 HU of the surrounding trabecular bone. The dorsal metaphyseal cortex was disrupted. Similar but less pronounced findings were present in the left tibia.

Several ill-defined, hypoattenuating areas were present within the trochlear ridges of the right femur (stifle joint). Multifocal, hypoattenuating zones were also present within the distal femoral physis. A linear hypoattenuating zone was detected within the proximal metaphysis of the tibia, immediately distal to the physis. A diffuse, patchy increase in attenuation of the epiphysis and metaphysis of the distal femur and proximal tibia was suggestive of mixed sclerosis and osteolysis. Similar abnormalities were seen within the left tibia and femur.

A complete disruption of the proximal physis of the femur was seen in the left limb. The femoral head was still present within the acetabulum; however, the femur was displaced in a caudoproximal direction. Multiple smaller bony fragments were seen at the level of the physis, surrounded by a hypoattenuating rim and with sclerosis of the adjacent bone indicative of sequestrum.

Pathology

A large encapsulated abscess of 25x21x35 was found at the level of the left kidney; however, no involvement of the kidney was seen. Several fistula tracts extended from the abscess. One fistula (1cm diameter) extended to the cranial aspect of the ileum wing, at the level of the tuber coxae, and ended in a round/oval shaped abscess of 12x5cm. An additional fistula tract extended distally between the quadriceps femoris muscle, and ended deeply within these muscles without a clear demarcation. Several abscess formations were seen including one abscess within the popliteal region, caudal to the left stifle joint, with a connection to the caudal aspect of the tibia, one abscess of 13x16 cm located at the medial aspect of the left stifle joint, with fistula tracts extending to the ventral aspect of the pelvis as well as the skin surface, and one abscess of 26x2-3 cm located dorsally to the

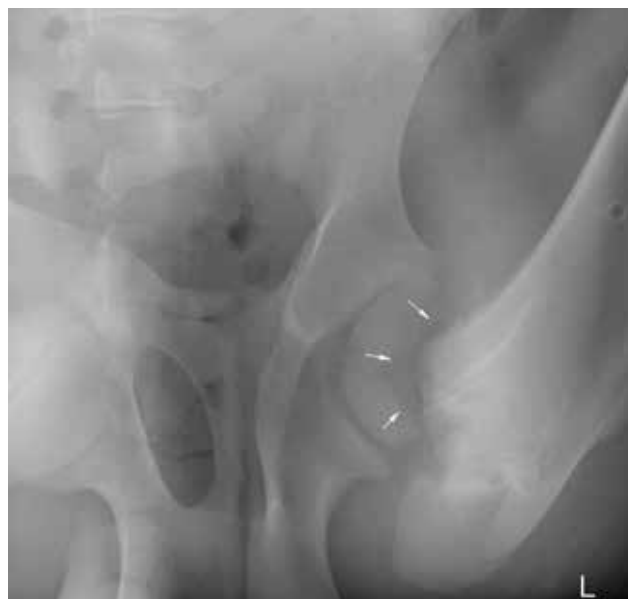

Figure 3. Ventrodorsal radiograph of the coxofemoral joints. There is a complete disruption of the proximal physis of the left femur consistent with a Salter-Harris type I fracture (arrows). The femoral head is still located within the acetabulum, however there is a caudal displacement of the distal femur in relation to the femoral head.

pelvis with two fistula tracts, one opening caudally to the semitendinosus (previous incision from surgical drainage). As suspected, a pathologic fracture involving the proximal physis of the left femur was found. The right tibiotarsal joint was severely distended with a large amount of viscous yellow fluid. The cartilage was normal. Sharply bordered accumulations of pus were seen within the trabecular bone of the metaphysis of both the left and right femur and tibia. The physis of the femur and tibia were similarly affected. Fifty millilitres of sero-hemorrhagic fluid were present within the abdomen. The iliac lymph nodes were enlarged. *Salmonella* spp. was additionally cultured post mortem from both the abscess and the sites of bone infection.

DISCUSSION

To the authors' knowledge, this is the first report describing a case of polyostotic hematogenous osteomyelitis and concurrent abdominal abscess formation in a foal with *Salmonella* spp. being the causative organism. In foals less than six months old, septic osteomyelitis most often involves the femur, distal phalanx and tibia (Niel et al., 2010). The isolation of *Salmonella* spp. from synovial fluid and multisystemic disease have been associated with an unfavorable prognosis for survival (Steel et al., 1999, Hardy, 2006; Vos et al., 2008). *Salmonella* spp. are Gram-negative bacteria that inhabit the intestinal tract and cause contamination of the environment by excretion of fecal material.

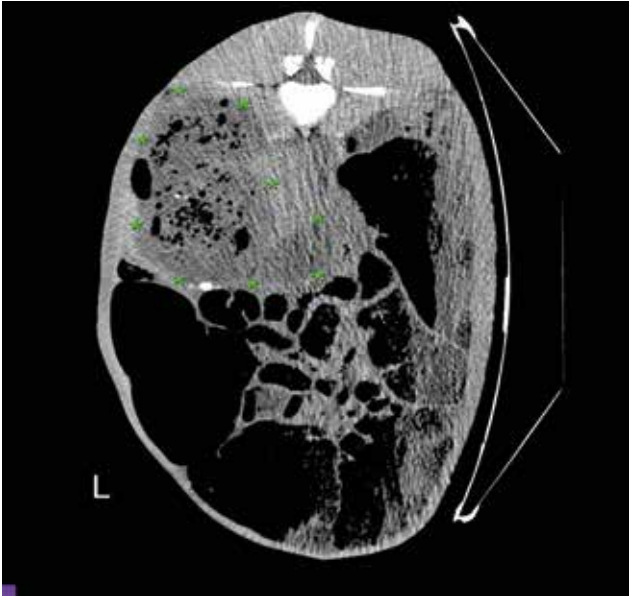


Figure 4A. Computed tomography images of the caudal abdomen. A large, ill-defined structure is seen within the left caudal abdomen (between asterisk symbols). The content is heterogeneous and hypoattenuating, and contains several gas opacities. This finding was consistent with a large intra-abdominal abscess.




Figure 4B. A fistula tract is seen extending from the caudal aspect of the abscess and underneath the ilial wing (between asterisk symbols). Multifocal, hyperattenuating mineralizations are also seen within the content.

The initial source of salmonellosis is frequently not identified. Potential sources of infection include consumption of contaminated food or water, contact with contaminated environmental surfaces, equipment or handlers, aerosol exposure and direct contact with shedding animals. Mares may be inapparent shedders and shed the bacteria at parturition, infecting newborn foals (Traub-Dargatz et al., 2007). Following oral infection, invasion of the enterocytes takes place, with progression into the mesenteric lymph nodes, from where *Salmonella* enter the blood circulation via efferent lymph vessels (Clarke et al., 1993).

Salmonella spp. infections can present in varying clinical forms in horses, such as asymptomatic infections, fever, anorexia and depression, severe acute diarrhea, acute septicemia or a combination of diarrhea and septicemia.

Septicemia is more common in foals and weanlings than adults, and sequelae, such as polyarthritis, osteomyelitis, omphalitis and meningoencephalitis can be seen (Niel et al., 2010; Smith, 1981). However, neonatal septicemia is usually associated with bacteria other than *Salmonella* spp., with *Enterococcus* reported as the most common isolate (Hollis et al., 2008; Wilson et al., 1989).

The most commonly documented bacterial isolate from abdominal abscesses in foals is *Rhodococcus equi* (Nay et al., 1996; Valdes et al., 2005; Reuss et al., 2009). In adult horses, *Streptococcus* is a common cause of abdominal abscesses; however, this does not appear to be documented in foals (Mair et al., 2011; Arnold et al., 2012; Berlin et al., 2013).

Treatment options for abdominal abscesses include long-term antimicrobials or surgery, including excision, drainage and lavage (Prades et al. 1989; Elce, 2006). However, the prognosis of survival for horses with intra-abdominal abscesses has been reported as guarded, with survival rates between 26% to 71% for discharge, and 19% for long-term survival (Rumbaugh et al., 1978; Pusterla et al., 2007; Arnold et al., 2012).

The foal in this case report did not respond well to the antibiotic treatment, although the antibiotic regime was changed several times during the treatment period, and despite the fact that no resistance to the antibiotics administered was recorded. Given the large size and encapsulation of the abscess, it is possible that an insufficient penetration of the antibiotic took place. Additionally, the virulence plasmids found in *Salmonella* spp. permit them to survive and multiply within phagocytic cells, and the intracellular location protects against many antimicrobial agents (Hirsh, 2004). Necrotic bone and vascular alterations associated with ischemia also protect bacteria from the host's defense mechanisms and affect penetration of systemic antimicrobials. The clinical findings, lymphocytosis and increased SAA consistent with septic inflammation and tissue damage were supportive of the diagnosis. Radiography confirmed the presence of osteomyelitis seen as lytic areas in multiple metaphyseal and physeal regions. Such bony lesions may not always be evident radiographically in the initial stages of infection, and may take weeks to be detected (Wegener et al., 1991). It is therefore important to

note that the absence of radiographic findings does not exclude the presence of infection.

Ultrasonography was useful in assessing and determining the extent and involved structures of the abscess within the soft tissues of the left hind limb. Ultrasound of the abdominal cavity would most likely have been useful in detecting the intra-abdominal abscess. However, a fluid filled colon and cecum were the only findings detected at the time of presentation, and at the time the femoral fracture was detected, further imaging was not elected due to the poor prognosis of this finding. Additionally, as described, abdominal abscessation as a sequela to Salmonella infection in foals is an unreported finding.

In comparison to x-rays, CT provides three-dimensional volume from a large series of two-dimensional radiographic images taken around a single axis of rotation, and is useful for diagnosis as well as surgical planning. In the present case, the CT provided more information regarding the extent and severity of the bony lesions than to the radiographs, and correlated well with the pathologic findings. Additionally, both the abdominal abscess and the major fistula tracts were detected.

In dogs weighing greater than 25 kg, CT detected more clinically significant lesions than ultrasound (Fields et al., 2012). Similar results have also been found in human medicine (van Randen et al., 2011).

Contrary to adult horses, thoracic and abdominal CT imaging of the foal is possible due to their small size, and should be considered as an additional imaging option in cases with suspicion of pathology of these regions.

In the present case, the multifocal limb involvement and associated findings within the gastrointestinal tract suggest a hematogenous inoculation of the bone. *Rhodococcus equi* should be considered a major differential in cases of polyarthritis and abscess formation; however, given the *Salmonella* spp. isolate and the lack of respiratory disease, it was less likely in the current case report.

The pathogen in this case report was a very aggressive form of Salmonella. Preventive measures are important, such as good hygiene rules in stables with multiple foals and consistent assessment of the immune transfer of foals after birth. Additionally, a good immune status in the dam is also important to prevent problems in foals.

REFERENCES

Arnold C.E., Chaffin M.K. (2012). Abdominal abscesses in adult horses: 61 cases (1993–2008). *Journal of the American Veterinary Medical Association* 241 (12), 1659-1665.

Berlin D., Kelmer G., Steinman A., Sutton G.A. (2013). Successful medical management of intra-abdominal abscesses in 4 adult horses. *Canadian Veterinary Journal* 54 (2), 157-161.

Brewer B.D., Koterba A.M. (1990). Bacteria isolated and susceptibility patterns in foals in a neonatal intensive care unit. *Compendium on Continuing Education for the Practising Veterinarian* 12, 1773–1780.

Clarke, R.C., Gyles, C.L. (1993) Salmonella. In: Gyles C.L., Thoen C.O. (editors). *Pathogenesis of Bacterial Infections in Animals*. Second edition, Iowa State University Press, Ames, Iowa, 133-153.

Elce Y.A. (2006). Infections in the equine abdomen and pelvis: Perirectal abscesses, umbilical infections, and peritonitis. *Veterinary Clinics of North America: Equine Practice* 22, 419-436.

Fields, E. L., Robertson, I. D., Osborne, J. A., Brown, J. C. (2012). Comparison of abdominal computed tomography and abdominal ultrasound in sedated dogs. *Veterinary Radiology Ultrasound* 53 (5), 513-517.

Firth E. (1983). Current concepts of infectious polyarthritis in foals. *Equine Veterinary Journal* 15, 5-9.

Goodrich L.R. (2006). Osteomyelitis in horses. *Veterinary Clinics of North America Equine Practice* 22, 389-417.

Hardy, J. (2006) Etiology, diagnosis, and treatment of septic arthritis, osteitis, and osteomyelitis in foals. *Clinical Techniques in Equine Practice* 5, 309-317.

Hirsh, D.C. (2004). Enterobacteriaceae: Salmonella. In: Hirsh D.C., MacLachlan N.J., Walker R.L. (editors). *Veterinary Microbiology*. Second edition, Blackwell Publishing, 69-74.

Hollis A.R., Wilkins P.A., Palmer J.E., Boston R.C. (2008). Bacteremia in Equine Neonatal Diarrhea: A Retrospective Study (1990–2007). *Journal of Veterinary Internal Medicine* 22, 1203-1209.

Mair T.S., Sherlock C.T. (2011). Surgical drainage and post-operative lavage of large abdominal abscesses in six mature horses. *Equine Veterinary Journal* 43, 123-127.

Martens R., Auer J. (1980). Haematogenous septic arthritis and osteomyelitis in the foal. *Proceedings of the American Association of Equine Practitioners* 26, 47–63.

Nay T.S. (1996). Extra-pulmonary *Rhodococcus equi* in a Thoroughbred foal. *Canadian Veterinary Journal* 37, 623–624.

Neil KM., Axon JE., Begg AP., Todhunter PG., Adams PL., Fine AE., Caron JP., Adkins AR. (2010). Retrospective study of 108 foals with septic osteomyelitis. *Australian Veterinary Journal* 88, 4-12.

Prades M., Peyton L., Pattio N. (1989). Surgical treatment of an abdominal abscess by marsupialisation in the horse: a report of two cases. *Equine Veterinary Journal* 21, 459-461.

Pusterla N., Whitcomb M.B., Wilson W.D. (2007). Internal abdominal abscesses caused by *Streptococcus equi* subspecies equi in 10 horses in California between 1984–2004. *Veterinary Record* 160, 589-592.

Raidal S. (1996). The incidence and consequences of passive transfer of immunity on a thoroughbred breeding farm. *Australian Veterinary Journal* 73, 201-206.

Reuss S.M., Chaffin M.K., Cohen N.D. (2009). Extrapulmonary disorders associated with *Rhodococcus equi* infection in foals: 150 cases (1987–2007). *Journal of the American Veterinary Medical Association* 235, 855-863.

Roberts B. L., Reimer J. M., Woodie J. B., Reed S. M. (2010). Case Report: Septic arthritis of the first and second cervical vertebral articulations with vertebral osteomyelitis in a foal caused by Salmonella. *Equine Veterinary Education* 22, 328-333.

Rumbaugh G.E., Smith B.P., Carlson G.P. (1978). Internal

- abdominal abscesses in the horse: a study of 25 cases. *Journal of the American Veterinary Medical Association* 172, 304-309.
- Schneider R.K. (1999). Synovial and osseous infections. In: Auer J.A., Stick J.A. (editors). *Equine Surgery*. Second edition, Saunders, Philadelphia, 727-736.
- Smith B.P. (1981). Equine salmonellosis: A contemporary view. *Equine Veterinary Journal* 13, 147-151.
- Steel, C.M., Hunt, A.R., Adams, P.L., Robertson, I.D., Chicken, C., Yovich, J.V., Traub-Dargatz J.L., Besser T.E. (2007) Salmonellosis. In: Sellon D. and Long M.T. (editors). *Equine Infectious Diseases*. First edition, Saunders, Philadelphia. P. 331-345.
- Valdes A., Johnson J.R. (2005). Septic pleuritis and abdominal abscess formation caused by *Rhodococcus equi* in a foal. *Journal of the American Veterinary Medical Association* 227, 960-963.
- Van Randen, A., Lameris, W., Van Es, W., van Heesewijk, H. P. M., van Ramshorst, B., ten Hove, W., Bouma, W. H., van Leeuwen, M. S., van Keulen, E. M., Bossuyt, P. M., Stoker, J., Boermeester, M. A. (2011). A comparison of the Accuracy of ultrasound and computed tomography in common diagnoses causing acute abdominal pain. *European Radiology* 21 (7), 1535-1545.
- Vatistas N.J., Wilson W.D., Pascoe J.R. (1993). Septic arthritis in foals: bacterial isolates, antimicrobial susceptibility and factors influencing survival. *Proceedings of the American Association of Equine Practitioners* 39, 286-287.
- Vos, N., Ducharme, N. (2008). Analysis of factors influencing prognosis in foals with septic arthritis. *Irish Veterinary Journal* 61, 102-106.
- Wegener W.A., Alavi A. (1991). Diagnostic imaging of musculoskeletal infection. Roentgenography; gallium, indium-labeled white blood cell, gammaglobulin, bone scintigraphy and MRI. *Orthopedic Clinics of North America* 22, 401-418.
- Wilson W.D., Madigan J.E. (1989). Comparison of bacteriologic culture of blood and necropsy specimens for determining the cause of foal septicemia: 47 cases (1978-1987). *Journal of the American Veterinary Medical Association* 195, 1759-1763.

Uit het verleden

EMERITUS: UITGEDIEND RENPAARD

In het oude Rome werden renpaarden buitengewoon hoog gewaardeerd en met respect behandeld. Stokslagen waren voorbehouden voor ezels, muilezels en muildieren. Paarden die niet langer meekonden, kregen op staatskosten een verzorgde oude dag. Ze werden ‘emeritus’ (uitgediend) genoemd. Later werd dat een betiteling van gepensioneerde militairen. Bij ons is dat nu een officiële titel voorbehouden aan gepensioneerde docenten en hoogleraren met een volledig voltooide loopbaan, vanaf 65 jaar. In Nederland is de titel ook in gebruik voor predikanten ‘op rust’. De betekenis van de term werd mede beïnvloed door bewuste contaminatie met ‘eminent’ (uitstekend).

Luc Devriese