



## Research Article

## Sugar Mill Effluent Induced Histological Changes in Kidney of *Channa punctatus*

Suman Prakash\* and Ajay Capoor

\*Department of Zoology, Agra College, Agra-282001, U.P., India.

**Abstract:** Sugar is everyday need of every human being. Sugar is produced from sugar mills situated in various parts of our country. Sugar mills produced a large amount of sugar with many types of byproducts which finally went into water sources (mainly rivers) as effluents. This effluent contains high amount of toxic elements with wide range of chemicals. This will definitely affect life of aquatic organisms like fishes in rivers. The present study is designed to carefully observe the histological changes produced by toxic substances present in Chhata sugar mill effluent in kidney of *Channa punctatus*.


**Keywords:** Sugar mill effluent, *Channa punctatus*, Kidney, Histology, Chhata sugar mill.

### 1. Introduction

Sugar mills are associated with effluent characterized by biological oxygen demand and suspended solids, the effluent is high in ammonium content. India is the largest producer of sugar in the world and per capita consumption of sugar in the country is 13.4/kilograms per annum, there are about 500 operating sugar mills, located mainly in the state of Uttar Pradesh, Maharashtra, Andhra Pradesh, Karnataka and Tamil Nadu. Our inland waters have become polluted mostly due to industrial growth, urbanization and unlimited exploitation of nature by various activities of human beings. Such, chemical pollution of surface water can create health risks, because these waterways are often used directly as drinking water sources or connected with shallow wells used for drinking water, in addition, waterways have important roles for washing and cleaning, for fishing and fish farming and for recreation. Such harmful chemicals may enter waterways from a point source or a non-point source, former type of pollution is due to discharges from a single source; such as an industrial site, while later type of pollution involves many small sources that combine to cause significant pollution. Sugar mills consume around 1,500-2,000 litres of water and generate about 1,000 litres of wastewater per tonne of cane crushed. The effluent is mainly floor washing

wastewater and condensate water, leakage in valves and glands of the pipeline add sugarcane juice, syrup and molasses in the effluent. The sugar mill effluent has a BOD of 1,000-1,500mg/litre, but appears relatively clean initially; however, after stagnating for some time it turns black and starts emitting foul odour. If untreated effluent is discharged in water courses, it depletes dissolved oxygen in water and makes the environment unfit for aquatic life. If untreated effluent is discharged on land, decaying organic solids, oil and grease clog the soil pores. For this study, Chhata Sugar Mill (Mathura) has been taken as a case study to justify the pollution standards. Chhata Sugar Mill was established in 1975 and the first production was started in 1977-78. It is situated at Agra-Delhi highway (NH-2), 84km from Agra on left side of the road. Initially, the capacity of mill was 1250 T.C.D. which was enhanced to 2500 T.C.D. in 1992 and is maintained till now. Chhata Mill produces sugar while many waste products are effluxed from this process.

Chhata Sugar Mill (Mathura) has been taken as a case study for this study purpose to justify the pollution standards. *Channa punctatus* (Bloch.) is an easy handling fish, it is easily available and can be maintained in laboratory aquaria. It is highly sensitive to less amount of any toxicant or pollutant, thus it is selected as a model for the present study.

\*Corresponding Author: Suman Prakash  0000-0001-9621-4182.  
E-mail: [dr123yadav@gmail.com](mailto:dr123yadav@gmail.com).  
Phone No.: +91-8445551690.

## 2. Material and Methods

### 2.1 Experimental Fish and its maintenance

The air-breathing teleost *Channa punctatus* (Bloch.) have been selected for the present investigation. Fishes were collected from Government Fish Farm, Laramada village, Agra and other local freshwater resources. The experiments were done at Research Laboratory of Zoology Department, Agra College, Agra. The experimental fishes *Channa punctatus* (Bloch.) were kept in clean large glass aquaria measuring 75cms X 37.5cms X 37.5cms. The water, used for keeping fishes, was stored before one week to remove unfavourable gases. Dechlorinated water was used throughout the experiment. Fishes were kept in aquaria at the temperature ranging from 30°C to 35°C. The experimental fishes were acclimatized to the laboratory conditions for one week prior to experiment. The water of aquaria was changed every alternate day. The fishes were fed on readymade fish food. The food was given daily two times and feeding was disrupted 24 hours prior to the experiment.

### 2.2 Experimental Chemical

Sugar mill effluents collected from Chhata Mill, Mathura which contains various organic and inorganic effluents was used for the histochemical experimentation. In order to estimate the LC<sub>50</sub>, the fishes of different experimental sets have been treated with different concentrations of Sugar mill effluent. Five concentrations 100ml/25L, 200ml/25L, 300ml/25L, 400ml/25L and 500ml/25L have been selected and for each concentration, the mortality number of fishes at different time intervals viz. 24 hrs, 48 hrs, 72 hrs and 96 hrs.

### 2.3 Tissue Collection and Histological Study

The control and experimental fish; *Channa punctatus* (Bloch.) were killed under light chloroform anesthesia. They were dissected carefully and the kidneys were taken out for histological examination accordingly. The tissue was fixed in the Bouin's solution. After washing and dehydration, the tissue was embedded in paraffin wax. The sections were cut at 5 microns and stained with haematoxylin and eosin (Humason, 1979). Sections were examined under trinocular research microscope and photomicrographs were taken.

## 3. Results and discussion

Kidneys are organs which filter wastes such as ammonia and urea from the blood and excrete them, along with water, as urine. Body fluids of freshwater fish are higher in ionic concentration than the surrounding water; a condition referred to as hyperosmotic. Maintaining such a concentration gradient requires removal and conservation of ions

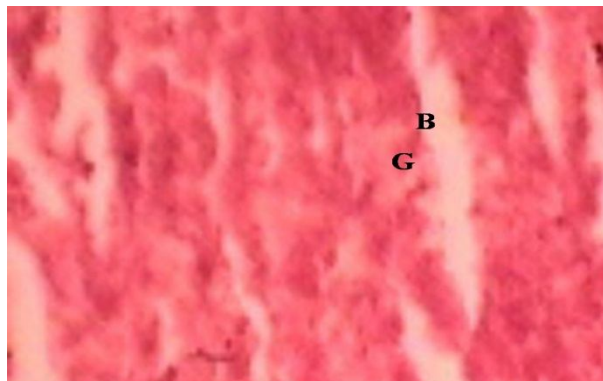
prior to excretion of "purified" water. This is accomplished in the kidney by filtration of blood through glomerular nephrons each comprising of a renal corpuscle and renal tubule. The renal corpuscle consists of a vascular glomerulus enclosed within the Bowman's capsule in which outer parietal and inner visceral epithelia create "Bowman's space" Bowman's capsule serves to isolate the glomerulus from the rest of the kidney.

The basic functional unit of the kidney is the nephron, of which there are more than a million within the cortex and medulla of normal kidney. Nephrons regulate water and solute within the cortex and medulla of the normal kidney. Nephrons regulate water and soluble matter; especially electrolytes, in the body by first filtering the blood under pressure and then reabsorbing some necessary fluid and molecules back into the blood while secreting out other unneeded molecules. Reabsorption and secretion are accomplished with both co-transport and counter-transport mechanisms established in the nephrons and associated collecting ducts.

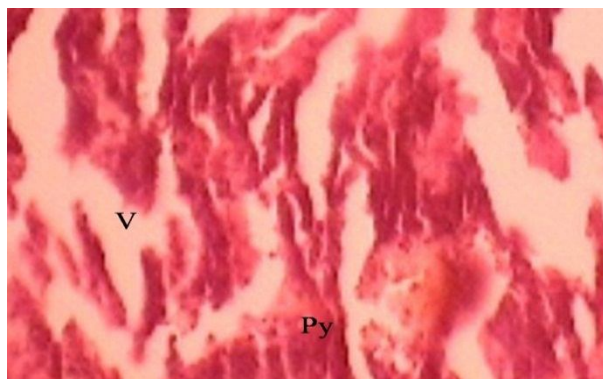
The renal tubules are structurally possessing six cytologically distinct regions. The Bowman's continues into the neck capsule maintaining the isolation of the glomerulus. In fatheads, the neck region is long and thin with a narrow lumen surrounded by ciliated cuboidal to low columnar epithelial cells. Cytoplasm of these cells stains slightly basophilic. The first proximal segment is covered by tall columnar epithelial cells with basal nuclei and slightly eosinophilic cytoplasm, an apical "brush border" of microvilli protrudes deeply into the lumen. The second proximal segment has a still taller columnar epithelium with more centrally located nuclei and a less marked brush border; numerous large mitochondria cause the cytoplasm to stain intensely eosinophilic. The intermediate segment is long well developed, it has a narrow lumen surrounded by cuboidal to short columnar epithelial cells with an inconspicuous brush border; staining is still strongly eosinophilic. The distal segment is lined with large, relatively clear columnar epithelial cells, nuclei are central and the brush border is reduced or nonexistent. The initial collecting duct is larger in diameter than the preceding distal segment; its columnar epithelium is lightly eosinophilic with basal nuclei and no brush border. Subsequent collecting tubule segments increase in diameter with their epithelium becoming pseudostratified and possessing few goblet cells. Larger collecting ducts incorporate layers of smooth muscle and connective tissue.

In the control slide of kidney, there is a clear vision of Bowman's capsule glomerulus and other renal structures (Plate-1a). In the early stage of treatment after 24 hrs, pyknosis and slight vacuolization have been observed with 25.75ml/25L sugar mill effluent treatment (Plate-1b). After 48hrs treatment, vacuolization and haemorrhage along with lipid

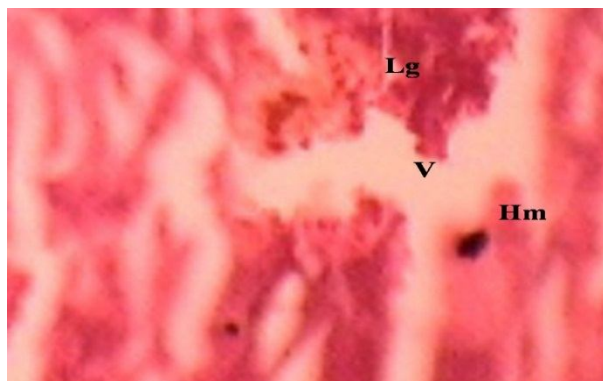
globules have been observed in the nephrons with dose of 25.75ml/25L sugar mill effluent treatment (Plate-1c). At 72hrs, there is not much difference with 48hrs as pyknosis, lipid globules and necrosis are clearly visible with 25.75ml/25L sugar mill effluent treatment (Plate-1d). Slide of 96hrs treatment with sugar mill effluent showed degeneration of cells, haemorrhage, edema, vacuolization and necrosis with 25.75ml/25L sugar mill effluent treatment (Plate-1e). It shows the worst condition with haemorrhage, necrosis, extensive vacuolization and edema with 25.75ml/25L sugar mill effluent treatment (Plate-1f).



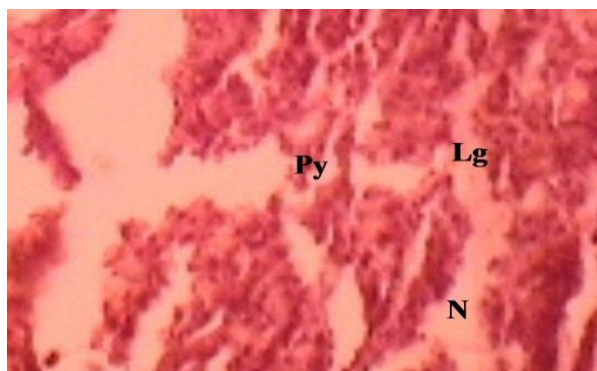
**Plate-1a. Control.**  
(B-Bowman's capsule; G-Glomerulus)



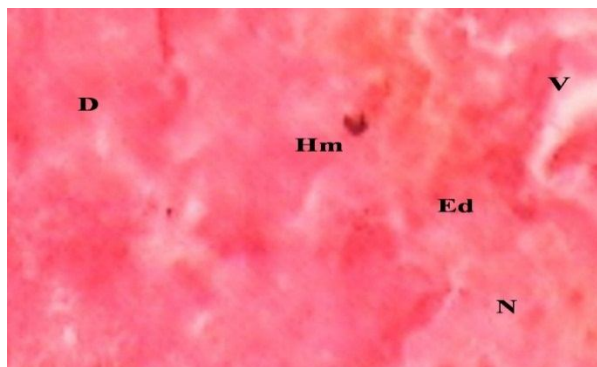
**Plate-1b. 24hrs treatment.**  
(V-Vacuolization; Py-Pyknosis)



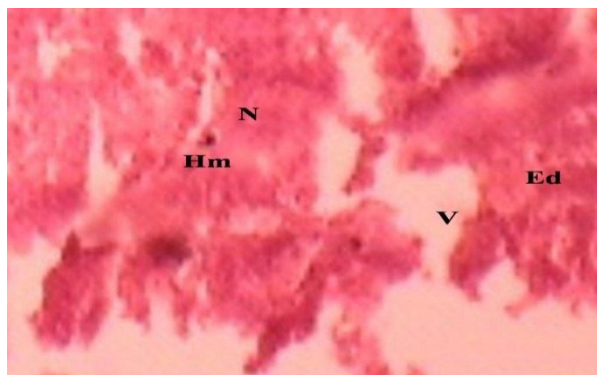
**Plate-1c. 48hrs treatment.**  
(Lg-Lipid globule; V-Vacuolization; Hm-Haemorrhage)



**Plate-1d. 72hrs treatment.**  
(Py-Pyknosis; Lg-Lipid globule; N-Necrosis)



**Plate-1e. 96hrs treatment.**  
(D-Degeneration; V-Vacuolization; Hm-Haemorrhage; Ed-Epithelial desquamation; N-Necrosis)



**Plate-1f. 1-week treatment**  
(N-Necrosis; Hm-Haemorrhage; Ed-Epithelial desquamation; V-Vacuolization)

Tissue changes in liver are linked with histological abnormalities of kidney and gill. Once absorbed, toxicant is transported by blood circulation to liver for transformation or storage, and if transformed in liver it may be excreted through the bile or pass back into the blood for possible excretion by kidney or gill, Lindstoma *et al.*, (1981).

Gupta and Dalela (1987) reported histological changes in kidney of *Notopterus notopterus* exhibiting degeneration and dissolution of epithelial cells of renal tubules, hypertrophy and necrosis following subtle

exposure to phenolic compounds. Similar observations were made by Csepai (1978) in *Cyprinus carpio* chronically exposed to Anthio 40 EC, Satox and Basuden 10G, the organochlorine and organophosphate compounds.

Interestingly, most of the alterations in the kidney of fish in the present study were seen in the tubular cells rather than in the glomeruli, which were spared. Moderate to marked cellular infiltrations comprised mostly of mononuclear cells were discernible in the interstitium, which might be explained as a defense mechanism in the fish to counter toxic metabolites.

Pathological changes attributable to cadmium poisoning were observed in the kidney of *Fundulus heteroclitus* after 12 hr exposure to 50mg/L of cadmium (Gardner and Yevich, 1970). The damage appeared limited to the proximal tubules of the kidney, many of the proximal tubules exhibited pink-staining granular casts with nuclear debris, and others showed various stages of degeneration, the tubular deterioration and the non-involvement of collecting tubules and glomeruli in *Fundulus heteroclitus* indicates a relation similar to that observed in higher vertebrate forms including humans on same exposure.

Banerjee and Bhattacharya (1994) observed histological changes in the anterior and posterior kidneys of snakehead fish *Channa punctatus* induced by 16.7 ppb mercuric chloride on 7, 28, 63, and 90 days exposure. Renal lesions consisted of minimal to mild multifocal, acute tubular epithelial degeneration, karyolysis, and dilation or shrinkage of Bowman's capsule and glomerulus. Observations of epithelial cell necrosis in the posterior kidney may be correlated with uptake of mercury and rapid elimination phases. Waite *et al.*, (1990) histologically evaluated whitefish, *Coregonus clupeaformis* and northern pike, *Esox lucius* which were exposed to uranium mine tailings. Histological findings showed that there were no significant differences in muscle, kidney, intestine and pancreas changes between the two studied species of fish, the authors concluded that the concentrations of radionuclides and other heavy metals in the tissues and environment had not caused histological changes in these fish.

Morphological kidney changes give the pathologist more specific information concerning the type and duration of toxicant exposure, segmental nephron damage is characteristic of some compounds, as are intra-nuclear inclusions. As the kidney contains a large amount of lymphoid tissue, this is an excellent opportunity for the pathologist to superficially view the immune system. In the present studies, it was noted that hyperplasia and inflammation of the kidney cells due to the presence of intoxicant reduce kidney function. Blockage of circulation in the major arteries of the kidney can occur. Migration of intoxicant molecule through the hematopoietic tissue of the kidney

contributes to reduced erythropoiesis and possibly renal failure.

There is scope for better recycling and reuse of water in sugar mills thereby minimizing water consumption and ultimately effluent quantity. The recycling and reuse of hot condensate water can reduce the water consumption to as low as 100-200 litres as against 1,500-2,000 litres per tonne of cane crushed. Proper housekeeping, periodic checking and maintenance of pipe joints, valves and glands further reduces the water consumption and effluent quantity. The effluents from the sugar industry can be properly treated.

## References

- [1]. Allen, P. (1994). Mercury accumulation profiles and their modification by interaction with cadmium and lead in the soft tissues of the cichlid *Oreochromis aureus* during chronic exposure. *Bull. Environ. Contam. Toxicol.*, **53**(5):684-92.
- [2]. Banerjee, S. and Bhattacharya, S. (1994). Histopathology of kidney of *Channa punctatus* exposed to chronic nonlethal level of elsan, mercury and ammonia. *Ecotoxicol. Environ. Saf.*, **29**(3):265-275.
- [3]. Csepai, F. (1978). Histological detectable dystrophies in the carps kidney exposed to chronic effect of some pesticides. *Magy. Allatorv. Lapja.*, **33**: 55-58.
- [4]. Gardner, G.R. and Yevich, P.P. (1969). Studies on the blood morphology of three estuarine cyprinodontiform fishes. *J. Fish. Res. Board Can.*, **26**:433-447.
- [5]. Gardner, G.R. and Yevich, P.P. (1970). Histological and hematological responses of an estuarine teleost to cadmium. *J. Fish. Res. Board Can.*, **27**:2185-2196.
- [6]. Gupta, A.K. and Dalela, R.C. (1987). Kidney damage in *Notopterus notopterus* (Pallas) following exposure to phenolic compounds. *J. Environ. Biol.*, **8**: 167-172.
- [7]. Hall, T.J., Haley, R.K., Borton, D.L., Walsh, A.H., and Wolke, R.E. (1992). Histopathology of Rainbow Trout after longterm exposure to biologically treated bleached kraft mill effluent in experimental stream channels. *Can. J. Fish. Aquat. Sci.*, **49**(5): 939-944.
- [8]. Humason, G.L. (1979). *Animal Tissue Techniques* (4<sup>th</sup> edition). W.H. Freeman and Company, San Francisco. 661 pp.
- [9]. Lindstoma-Seppa, P., Koivussri, V. and Hanninen D.O. (1981). Extrahepatic xenobiotic metabolism in North European freshwater fish. *Comp. Biochem. Physiol.*, **69**: 291.
- [10]. Waite, D.T, Joshi, S.R., Sommerstad, H., Wobeser, G., and Gajadhar, A.A. (1990). A toxicological examination of whitefish and northern pike exposed to uranium mine tailings. *Arch. Environ. Contam. Toxicol.*, **19**(4): 578-582.