


Received: 3 April 2017 | Revised: 6 September 2017 | Accepted: 20 October 2017

DOI: 10.1002/micr.30265

CASE REPORT**WILEY** **MICROSURGERY**

Reconstruction of a long defect of the ulnar artery and nerve with an arterialized neurovenous free flap in a teenager: A case report and literature review

Diogo Casal MD^{1,2}  | Diogo Pais MD, PhD^{1,2} | Eduarda Mota-Silva MSc³ |
Giovanni Pelliccia MD^{1,2} | Inês Iria MSc⁴ | Paula A. Videira MSc, PhD⁵ |
Maria Manuel Mendes MD¹ | João Goyri-O'Neill MD, PhD² |
Maria Manuel Mouzinho MD¹

¹Plastic and Reconstructive Surgery Department and Burn Unit, Centro Hospitalar de Lisboa Central, Lisbon, Portugal

²Anatomy Department, NOVA Medical School, Universidade NOVA de Lisboa, Lisbon, Portugal

³Physics Department, Faculdade de Ciências e Tecnologia, LIBPhys, Caparica, Portugal

⁴Molecular Microbiology and Biotechnology Unit|Drug Discovery Area; Faculdade de Farmácia, Universidade de Lisboa, Lisbon, Portugal

⁵UCIBIO, Life Sciences Department, Faculdade de Ciências e Tecnologia, Universidade NOVA de Lisboa, Caparica, Portugal

Correspondence

Diogo Casal, MD, Anatomy Department, Nova Medical School, Campo dos Mártires da Pátria, 130, 1169-056 Lisbon, Portugal.
Email: diogo_bogalhao@yahoo.co.uk

Funding information

The Program for Advanced Medical Education, which is sponsored by Fundação Calouste Gulbenkian, Fundação Champalimaud, Ministério da Saúde e Fundação para a Ciência e Tecnologia, Portugal.

Abstract

There is evidence that nerve flaps are superior to nerve grafts for bridging long nerve defects. Moreover, arterialized neurovenous flaps (ANVFs) have multiple potential advantages over traditional nerve flaps in this context. This paper describes a case of reconstruction of a long defect of the ulnar artery and nerve with an arterialized neurovenous free flap and presents a literature review on this subject. A 16-year-old boy sustained a stab wound injury to the medial aspect of the distal third of his right forearm. The patient was initially observed and treated at another institution where the patient was diagnosed with a flexor carpi ulnaris muscle and an ulnar artery section. The artery was ligated and the muscle was sutured. Four months later, the patient was referred to our institution with complaints of ulnar nerve damage, as well as hand pain and cold intolerance. Physical examination and ancillary tests supported the diagnosis of ulnar artery and nerve complete section. Surgery revealed an 8 cm hiatus of the ulnar artery and a 5 cm defect of the ulnar nerve. These gaps were bridged with a flow through ANVF containing the sural nerve and the lesser saphenous vein. The postoperative course was uneventful. Two years postoperatively, the patient had regained normal trophism and M5 strength in all previously paralyzed muscles according to the Medical Research Council Scale. Thermography revealed good perfusion in the right ulnar angiosome. The ANVF may be an expedite, safe and efficient option to reconstruct a long ulnar nerve and artery defect.

Abbreviations: ANVF, arterialized neurovenous flap; CNF, conventional nerve flap.

This is an open access article under the terms of the Creative Commons Attribution-NonCommercial-NoDerivs License, which permits use and distribution in any medium, provided the original work is properly cited, the use is non-commercial and no modifications or adaptations are made.

© 2017 The Authors. Microsurgery Published by Wiley Periodicals, Inc.

1 | INTRODUCTION

Vascular and nerve injuries to the upper limb are relatively frequent (Jabaley, 2006; Rosberg et al., 2005; Rosberg, 2004; Slutzky, 2006; Trehan, Model, & Lee, 2016). However, functional results after peripheral nerve repair are far from perfect, especially for late repairs or in cases of long nerve defects (Dahlin, 2006; Slutzky, 2006; Trehan et al., 2016). This, in turn, often results in permanent and significant social and economic devaluation of those affected (Broback et al., 1978; Dahlin, 2006; Rosberg, 2004; Rosberg et al., 2005).

There is mounting experimental and clinical evidence that nerve flaps are superior to nerve grafts for bridging long nerve defects (Trehan et al., 2016; Wood, Johnson, & Myckatyn, 2015). In fact, nerve flaps, having a blood supply of their own since the moment of nerve transfer, are less prone to central necrosis, fibrosis, and histological disorganization compared to nerve grafts, which depend initially on diffusion and subsequently on neoangiogenesis for survival (Desouches et al., 2005; Sinis et al., 2009; Taylor & Pan, 2014; Terzis, Skoulis, & Soucacos, 1995; Trehan et al., 2016).

Most literature refers to “conventional nerve flaps” (CNFs), that is to say to nerve segments pedicled on a given arterial and venous pedicle. However, CNFs entail laborious dissections, and sometimes cannot be raised due to local anatomical constraints (Hong & Taylor, 2006). To circumvent these limitations, in 1984, Townsend and Taylor (1984) suggested a new way of transferring nerve segments pedicled exclusively on their accompanying veins. In these nerve flaps, at least one of the veins was connected to a recipient site’s artery, whereas at least one of the other veins drained the flap’s venous blood. These flaps were named “arterialized neurovenous flaps” (ANVFs) (Townsend & Taylor, 1984). However, since then, ANVFs have been reported clinically only a few times in case reports or small case series (Casal et al., 2016).

In this paper, the authors describe a case report in which deferred reconstruction of a composite long arterial and nervous defect was performed with an ANVF in a teenage boy with an excellent functional outcome. Furthermore, the authors conducted a literature review on the use of ANVFs employed in the reconstruction of similar defects.

2 | CASE REPORT

A 16-year-old right-handed Portuguese teenage boy sustained a broken glass injury to the medial aspect of the distal third of his right forearm when the patient was inadvertently pushed against a window at school. The patient was initially observed and treated at another institution where the patient was diagnosed with a flexor carpi ulnaris muscle and an ulnar artery section. The artery was ligated and the muscle was sutured with horizontal 3/0 Vicryl® mattress sutures.

Four months later, the patient was referred to our institution for observation in the Plastic and Reconstructive Surgery outpatient clinic. The patient complained of hypoesthesia and paresthesia in the territory of the right ulnar nerve. Moreover, the patient referred exertional pain, as well as cold intolerance in the affected hand. Physical examination, revealed an ulnar claw, with paralysis and wasting of the intrinsic hand

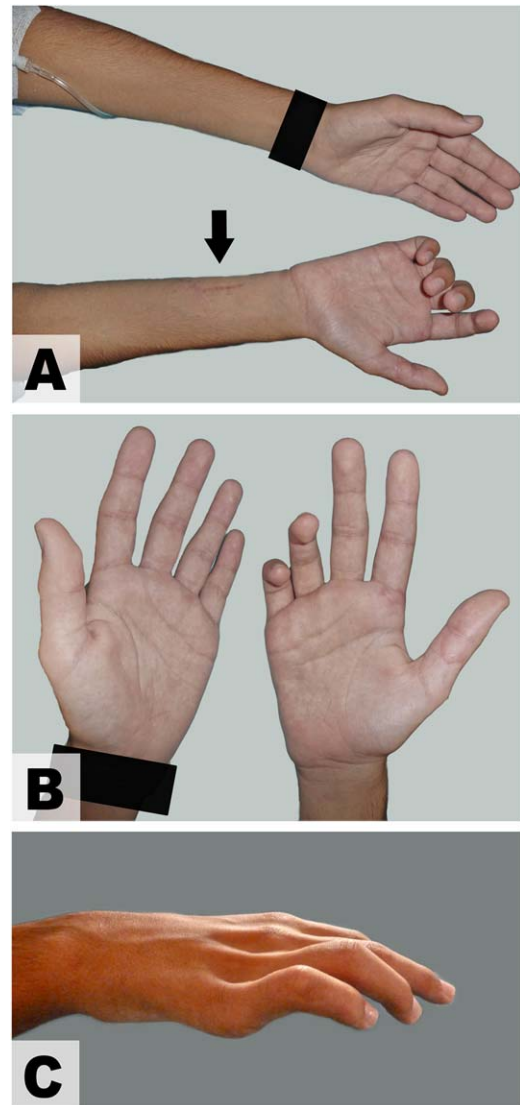


FIGURE 1 Photographs showing the preoperative appearance. A, A scar in the medial aspect of the distal third of the right forearm was visible (arrow) corresponding to the site of injury. B, Comparison of the hands showed marked atrophy of the right hand intrinsic muscles, particularly in the medial palmar region. C, An ulnar claw was evident due to atrophy of the intrinsic muscles supplied by the ulnar nerve

muscles dependent on the ulnar nerve (Figure 1). Allen’s test revealed a poorly perfused hand when pressing the radial artery at wrist level. Electroneurography was consistent with chronic ulnar neurotmesis at the distal forearm.

Surgical exploration of the lesion under tourniquet control, revealed interruption of the ulnar nerve and artery (Figure 2A). After debriding the fibrous tissue and removing the proximal stump’s neuroma using surgical magnifying loops, there was an 8-cm hiatus of the ulnar artery and a 5-cm defect of the ulnar nerve (Figure 2A).

These gaps were bridged with a flow through ANVF raised from the left lower leg (Figure 2B). This flap was composed of the sural nerve and of the lesser saphenous vein (Figure 2C). The flap comprised two branches of the sural nerve that were used to reconstruct the

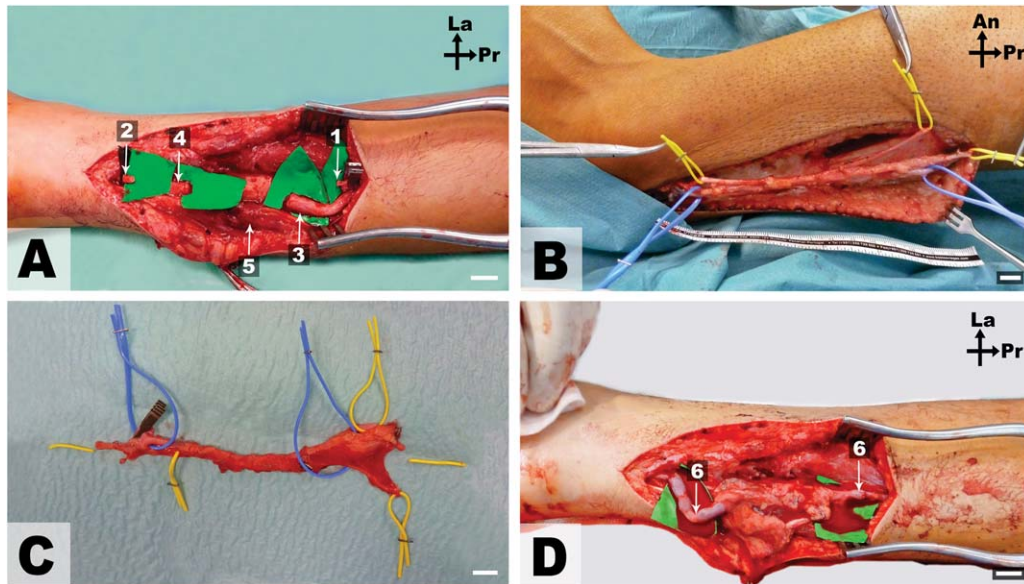


FIGURE 2 Photographs of the surgery. Scale bar = 1 cm; Pr, Proximal; Lat, Lateral; An, Anterior. 1, Proximal stump of the ulnar artery; 2, Distal stump of the ulnar artery; 3, Proximal stump of the ulnar nerve; 4, Distal stump of the ulnar nerve; 5, Flexor carpi ulnaris muscle. The yellow vessel loops were placed around two terminal branches of the sural nerve. The blue vessel loops were placed around the lesser saphenous vein. A, Intraoperative view of the ulnar neurovascular bundle after removing the fibrotic tissue and the proximal stump neuroma; B, View of the lesser saphenous/sural neurovenous flap *in situ* after dissection; C, Detailed *ex vivo* view of the lesser saphenous/sural neurovenous flap prior to inseting into the defect; D, View of the arterialized neurovenous flap after inseting the flap and performing the neural and vascular anastomoses

ulnar nerve according to its internal topographical anatomy at the distal forearm level (Figures 2D and 3). It was assumed that the motor component is medially placed whereas the sensory component is in the lateral aspect of the nerve (Davidge & Boyd, 2015; Wood et al., 2015). The ulnar artery hiatus was reconstructed with an inverted segment of the lesser saphenous vein included in the flap. Hence, blood flow in the ANVF was orthodromic. Vascular and neural anastomoses were performed with interrupted 9/0 Nylon stitches under the operating microscope.

In the flap's donor zone, the proximal stump of the sural nerve was stitched with a 6/0 Nylon suture to the belly of the lateral gastrocnemius muscle after creating a small window in the muscle fascia. The surgical wounds were closed in anatomical layers. The surgery's duration was 242 min.

After surgery, the patient's wrist was splinted for 15 days to prevent maximal extension and thus excessive tension on the vascular and nerve repairs. The patient was allowed to ambulate and freely use the patient's fingers immediately after surgery. The patient was discharged home 3 days after surgery. Postoperatively, the patient underwent an intensive physiotherapy program for one year. The patient was followed regularly at the outpatient clinic for 2 years. Five months after surgery, Tinell's sign could be observed at the wrist level. Intrinsic muscles innervated by the ulnar nerve started to show voluntary contraction at 8 months postoperatively. The patient referred gain of sensibility in the ulnar aspect of his hand 6 months after the surgical procedure. At the last follow up visit, the patient had regained normal trophism and M5 strength in all previously paralyzed muscles according to the Medical Research Council Scale, i.e., muscle strength was no

different from that observed in the opposite side (Figure 4A,C,D). Furthermore, according to this scale, his sensory recovery was S3 in the territory of the ulnar nerve, i.e., return of superficial cutaneous pain and tactile sensibility without over-response (Wang, Sunitha, & Chung, 2013). Two years after the last surgery, two-point discrimination in the hypothenar region was 5 and 7 mm in the palmar aspect of the fifth finger. At this time, the patient presented a relatively inconspicuous scar in the donor zone, as well as absence of limb edema (Figure 4E).

Since the last surgery, the patient denied either cold intolerance or exertional fatigue in the affected hand. Two years after this surgery, thermographic examination of the upper limbs was performed with a FLIR® E6 camera placed 25 cm above the hands (Sheena, Jennison, Hardwicke, & Titley, 2013). This exam revealed a symmetrical pattern with good perfusion throughout, including in the territory of the right ulnar angiosome (Figure 4A).

Two years after the last surgery, electroneuromyography confirmed reinnervation in the territory of the ulnar nerve.

3 | DISCUSSION

Oddly, although potentially advantageous, the reconstruction of nerve defects using ANVFs is rarely mentioned in the literature (Table 1) (Casal et al., 2016). Townsend and Taylor (1984) pioneered this field in 1984 with a seminal paper describing 13 lower limb cadaveric dissections, an histological study in the greyhound dog comparing axonal elongation in nerve grafts and ANVFs, and seven clinical cases. In this series, five combined nerve and arterial defects of the upper limb and two facial nerve lesions were successfully reconstructed using ANVFs

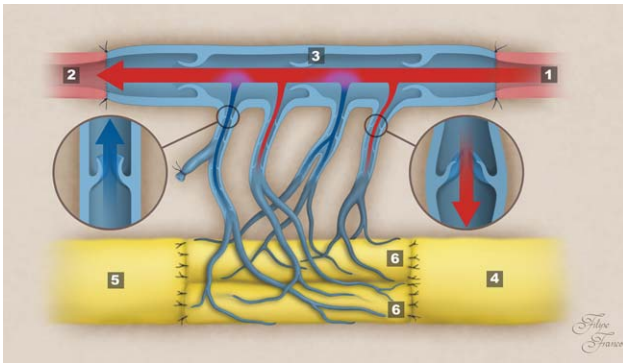


FIGURE 3 Schematic representation of the composition and vascular architecture of the lesser saphenous/sural neurovenous flap used to bridge the long arterial and nerve defect. The arrows indicate the direction of blood flow. 1, Proximal segment of the ulnar artery; 2, Distal segment of the ulnar artery; 3, Lesser saphenous vein in an inverted position used to bridge the vascular gap; 4, Proximal stump of the ulnar nerve; 5, Distal stump of the ulnar nerve; 6, Sural nerve cables used for the somatotopic reconstruction of the ulnar nerve

(Townsend & Taylor, 1984). The next year, Gu et al. described 14 clinical cases in which upper limb nerve defects over 10 cm in length associated with vascular injuries were reconstructed using ANVFs (Gu, Wu, Zheng, Li, & Xu, 1985). Most of these patients presented good results, although there were two vascular thrombosis of the ANVFs and there were two cases of absence of neurological recovery in patients with longstanding lesions (Gu et al., 1985). Since 1989, there were multiple papers describing the simultaneous reconstruction of nerve and skin defects using ANVFs associated with a skin paddle (Casal et al., 2016; Gu, Zhang, Chen, Yan, & Cheng, 1989; Hussmann, Bahr, Steinau, & Vaubel, 1996; Rose, 1989). In that same year, Rose et al. presented a

series of 14 ANVFs fabricated from the medial fibular nerve and from the dorsalis pedis venae comitantes that were effectively used to bridge digital nerve defects associated with significant local fibrosis (Rose, Kowalski, & Norris, 1989).

Since then, multiple papers have been published describing the use of ANVFs in virtually all anatomical regions. The largest of these series describe the use of several ANVFs to simultaneous reconstruct composite vascular and nerve defects of the upper limb, either occurring proximally at the arm level, or distally at the finger level (Hussmann, Bahr, Russell, Steinau, & Vaubel, 2003; Woo et al., 2007; Yan et al., 2012). Multiple variations in the composition of ANVFs were introduced, including tendon (Karacalar & Ozcan, 1994; Woo et al., 2007), deep fascia (Liu et al., 2014), bone (Hussmann et al., 1996; Patradul, Ngarmukos, Parkpian, & Kitidumrongsook, 1999), and/or the nail complex (Patradul et al., 1999). However, only a few authors have reported the use of ANVFs similar to that described in this paper for the reconstruction of arterial and nerve defects at the forearm level (Bullocks, Naik, Lee, & Hollier, 2006; Casal et al., 2016; Townsend & Taylor, 1984; Woo et al., 2007). Moreover, all these reconstructions were performed in adults. Consequently, as far as the authors could determine, this is the first report of an ANVF being used to reconstruct a composite long nerve and arterial defect in a pediatric patient. One reason to justify this may be that extensive vascular and nerve damage is increasingly rare in children and teenagers in most countries (Ciaramitaro et al., 2010; Lad, Nathan, Schubert, & Boakye, 2010). Moreover, these lesions are frequently associated with damage to other structures, namely the integumentary system, mandating reconstruction of concomitant tissue injuries with flaps containing muscle and/or skin paddles. Finally, having an incompletely understood physiology, ANVFs are often not the first reconstructive option for most surgeons (Casal et al., 2016; Trehan et al., 2016).

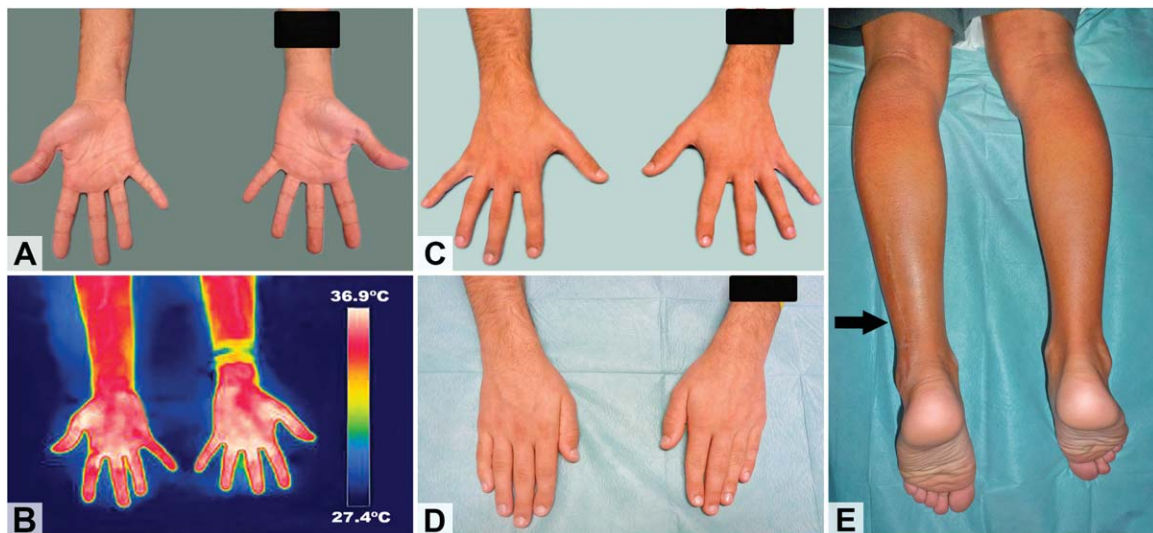


FIGURE 4 Appearance of the recipient and donor zones 2 years after surgery. A, Anterior view of the distal aspect of the upper limbs showed no evidence of atrophy of hand muscles. B, Infrared thermography of the anterior aspect of the forearms and hands showed good perfusion of the ulnar aspect of the right hand. C, Posterior view of the forearms and hands showed absence of ulnar claw in the right hand, as well as good finger abduction. D, Posterior view of the hands demonstrated adequate finger adduction. E, Posterior view of the lower legs and feet showed a relatively inconspicuous scar in the donor zone (arrow), as well as absence of limb edema

TABLE 1 Summary of the studies reporting unconventional perfusion flaps including nerves for reconstructive purposes

Author	Year	n	Age (years)		M:F	Defect location	Defect origin	Flap(s) donor site(s)	Flap composition	Outcomes	Complications
			Mean	Min-max							
Townsend and Taylor	1984	7	33.2	20-54	4:3	HN; F; HF	Tu; B; Tr	L	nv	Five combined nerve and arterial defects of the upper limb and 2 facial nerve lesions were reconstructed with good results	0
Gu	1985	14	30.8	20-54	10:4	F	Tr	L	nv	Fourteen clinical cases of upper limb nerve defects over 10 cm in length associated with vascular injuries were successfully reconstructed; 12 patients presented significant neurological recovery	14.2% vascular anastomosis thrombosis
Gu	1989	4	29.8	17-54	3:1	F; L; HF	SC	F; L	S; sne	Skin and nerve hand defects were reconstructed with success in 3 out of 4 cases	25% FTN
Rose	1989	1	38	38	1:0	HF	SC	n/a	S; sne	Skin and nerve digital defects were reconstructed with success in one patient	0
Rose	1989	14	29	18-55	9:1	HF	Tr	Ft	nv	Fourteen digital nerve defects in poorly vascularized tissues were reconstructed with good results in 10 patients	0
Karacalar	1994	13	23.9	12-35	11:2	HF	n/a	F	S; st; sne	Three skin and sensory digital defects were successfully reconstructed with innervated AVFs	15.4% FTN
Hussman	1996	69	47	n/a	n/a	HN; F; L; HF	B; CM; Tr; Tu	F; L; Ft	S; stnb; sc	Multiple cases involving integumentary and nerve defects were successfully reconstructed with AVFs	18.8% FTN
Woo	1996	12	36.2	18-59	11:1	HF	B; Tr; SC	F; L	S; sne	Nine cases of complex hand defects were successfully reconstructed in 9 patients with AVFs	25% FTN
Kayikcioglu	1998	8	28.4	19-41	8:0	HF	Tr	HF	S; sne	Seven out of eight digital pulp defects were successfully reconstructed including two cases of simultaneous skin and	12.5% FTN

(Continues)

TABLE 1 (Continued)

Author	Year	n	Age (years)		M:F	Defect location	Defect origin	Flap(s) donor site(s)	Flap composition	Outcomes	Complications
			Mean	Min-max							
Patradul	1999	10	25.3	6-47	4:5	HF	Tr	Ft	S; stnb	Successful distal finger reconstruction, including the nail complex, in 9 out of 10 patients. There was a case of simultaneous skin, tendon, bone and nerve reconstruction	10% FTN
Takeuch	2000	2	23.5	21-26	2:0	HF	Tr	Ft	Sne	Two innervated AVFs from the dorsum of the foot were successfully used to provide a sensate covering of degloved fingers in two patients. Nearly full range of motion of the fingers was obtained	0
Murata	2001	7	39	20-57	6:0	HF	Tr	HF	S; sne	Seven venous flaps from the dorsum of the hand, including 3 sensate flaps, were successfully used to reconstruct digits	14.2% SpN
Hussmann	2003	70	47.4	7-78	n/a	HN; F; L; HF	Tu; B; Tr; CM	F; L; Ft	S; stnb; sc	Multiple cases involving integumentary and nerve defects were successfully reconstructed with AVFs	18.6% FTN
Nakazawa	2004	4	41	20-71	n/a	L	CM	L	S; sne	Four cases of extensive contractures of the palm were successfully reconstructed using large AVFs, including a sensate flap	0
Woo	2007	154	35.7	16-65	112:40	HF	B; Tr	F; L; Ft; HF	S; st; sne	154 cases of AVFs were used successfully in 92.9% of cases to reconstruct upper limb defects, including 8 sensate flaps. Innervated AVFs allowed an average static two-point discrimination of 10 mm, ranging from 8 to 15 mm	7.1% FTN
Davami	2012	18	30.6	15-40	18:0	HF	Tr	HF	Sne	Sensate AVFs were used successfully in 18 patients to reconstruct the dorsum of the fingers	5.6% SpN

(Continues)

TABLE 1 (Continued)

Author	Year	n	Age (years)		M:F	Defect location	Defect origin	Flap(s) donor site(s)	Flap composition	Outcomes	Complications
			Mean	Min-max							
Yan	2012	27	n/a	n/a	n/a	HF	Tr	F	S; sne	Twenty-seven AVFs were successfully used in the reconstruction of finger pulp defects in 23 patients, including 15 sensate flaps and 12 insensate flaps. Almost all the flaps in the sensate group obtained normal sensation, while most cases of the insensate group only achieved protective sensation.	0
Yu ³⁶	2012	6	24.5	n/a	5:1	HF; Ft	B; Tr	Ft	S; sne	Five skin defects of the hands, and one defect of the dorsum of the foot were successfully reconstructed with AVFs, including a sensate flap	0
Giesen	2014	14	37.1	16-58	11:3	HF	Tu; Tr; i; O	F	S; st; sne	Fourteen defects of the hand were reconstructed with AVFs including 5 innervated flaps; one of the latter suffered complete necrosis	14.2% FTN; 7.1% AR
Liu	2014	11	31	17-44	7:4	HF	Tr	F	Sne	Eleven innervated AVFs were used to successfully reconstruct digital defects. In 4 cases, AVF's vascular pedicle was used to effectively revascularize fingers	0

n, number of patients in each series; M, male; F, female; AVF, arterialized venous flap.

Defect location and flap donor site: F, forearm; L, leg; Ft, foot; HN, head and neck; HF, hand and fingers; T, thigh.

Defect origin: B, burn and its sequelae; I, infection; CM, congenital malformation; SC, scar contracture; Tr, trauma; Tu, tumor; O, others.

Flap composition: nv, nerve and vein; s, skin with its appendages and subcutaneous tissue; sb, skin and bone; sc, skin and cartilage; sne, skin and nerve; st, skin and tendon; stnb, skin, tendon, nerve and bone.

Complications: AR, anastomosis revision; FTN, full thickness necrosis; I, infection; MN, marginal necrosis; SpN, superficial necrosis.

Comparatively to CNFs, ANVFs, as the one used in this patient, have the significant merit of being easy to raise and tailor due to the constant proximity of superficial veins to superficial nerves (Taylor & Pan, 2014; Trehan et al., 2016). Furthermore, the architecture of the ANVF used in this case, also allowed the simultaneous reconstruction of the ulnar artery and nerve (Figure 3). The inclusion of two terminal branches of the sural nerve made possible to reconstruct the ulnar nerve in a somatotopic fashion. It is well established that in the distal aspect of the forearm, the ulnar nerve is composed of a motor branch centrally located between the ulnarly-placed dorsal cutaneous branch and the radially-placed palmar sensory component (Davidge & Boyd, 2015). This topographical nerve reconstruction may have played a significant role in the full recovery presented by the patient. This is stark contrast with the poor results generally observed with ulnar nerve reconstruction even in the distal portion of the upper limb (Barrios, Amillo, de Pablos, & Canadell, 1990; Meek, Coert, & Robinson, 2005; Taylor & Pan, 2014; Trehan et al., 2016). Nevertheless, the authors must concede that one of the factors responsible for the good functional outcome was the young age of the patient (Trehan et al., 2016).

The patient presented a positive Tinnel's sign at the wrist level five months after surgery. Roughly, this corresponded to an average axonal growth of 1.3 mm/day (i.e., the fastest axons elongated around 200 mm in approximately 150 days). This value is similar to that generally reported in ideal conditions with nerve grafts and conventional nerve flaps at the patient's age (Boyd & Fox, 2015; Sulaiman & Gordon, 2013; Wilbourn, 2015). In fact, it has been estimated that in optimal repair conditions axonal growth can occur at a speed of 1–3 mm per day (Boyd & Fox, 2015; Sulaiman & Gordon, 2013; Wilbourn, 2015).

Similarly to what has been described by other authors, no significant donor site morbidity was observed in this patient.

CNFs are generally considered superior to nerve grafts for reconstructing long and thick nerve defects, particularly in regions of relative ischemia, such after radiotherapy, intense fibrosis subsequent to extensive trauma or in the particular case of prior deep burns (D'Arpa et al., 2015; Taylor & Pan, 2014; Trehan et al., 2016; Wood et al., 2015). However, the utility of ANVFs in these situations is still based on scarce experimental data, anecdotal case reports and small case series. The good results obtained in this case report lend support to the use of ANVFs for reconstructing long nerve defects in teenagers. Notwithstanding, further experimental and clinical studies are warranted to confirm or dismiss these findings.

Overall, this case report suggests that the arterialized sural nerve/lesser saphenous neurovenous flap may be an expedite, safe, and efficient option to reconstruct a long ulnar nerve and artery defect in the forearm of teenagers.

ACKNOWLEDGMENTS

The authors are very grateful to Mr. Filipe Franco for the illustrative drawing in Figure 3.

CONFLICT OF INTEREST

The authors have no conflicts of interest to declare.

AUTHORS' CONTRIBUTIONS

D. C., M. Mendes, and M. Mouzinho participated in the care of the patient. DC, DP, EMS, II, GP, and JGO collected the data and drafted the manuscript. All authors have read and approved the manuscript.

DECLARATIONS

Consent for publication

Written informed consent was obtained from the patient for publication of this case report and any accompanying images. A copy of the written consent is available for review by the Editor-in-Chief of this journal.

ORCID

Diogo Casal MD  <http://orcid.org/0000-0002-5537-9340>

REFERENCES

- Barrios, C., Amillo, S., de Pablos, J., & Canadell, J. (1990). Secondary repair of ulnar nerve injury. 44 cases followed for 2 years. *Acta Orthopaedica Scandinavica*, 61, 46–49.
- Boyd, K. U., & Fox, I. K. (2015). Nerve repair and grafting. In: S. E. Mackinnon (Ed.), *Nerve surgery*, 1st ed. (Vol. 1, pp. 75–100). New York: Thieme.
- Brobback, L. G., et al. (1978). Clinical and socio-economical aspects of hand injuries. *Acta Chir Scandinavica*, 7–8, 455–461.
- Bullocks, J., Naik, B., Lee, E., & Hollier, L. Jr. (2006). Flow-through flaps: A review of current knowledge and a novel classification system. *Microsurgery*, 26, 439–449.
- Casal, D., Cunha, T., Pais, D., Videira, P., Coloma, J., Zagalo, C., ... O'Neill, J. G. (2016). Systematic review and meta-analysis of unconventional perfusion flaps in clinical practice. *Plastics & Reconstructive Surgery*, 138, 459–479.
- Ciaramitaro, P., Mondelli, M., Logullo, F., Grimaldi, S., Battiston, B., ... Cocito, D. (2010). Traumatic peripheral nerve injuries: Epidemiological findings, neuropathic pain and quality of life in 158 patients. *Journal of Peripheral Nervous Systems*, 15, 120–127.
- D'Arpa, S., Claes, K. E. Y., Stillaert, F., Colebunders, B., Monstrey, S., & Blondeel, P. (2015). Vascularized nerve "grafts": Just a graft or a worthwhile procedure? *Plastic & Aesthetic Research*, 2, 183–194.
- Dahlin, L. B. (2006). Nerve injury and repair: From molecule to man. In Slutsky, D. J., Hentz, V. R. (Eds.), *Peripheral nerve surgery: Practical applications in the upper extremity* (pp. 1–22). Philadelphia: Elsevier.
- Davidge, K. M., & Boyd, K. U. (2015). Ulnar nerve entrapment and injury. In S. E. Mackinnon (Ed.), *Nerve surgery* (Vol. 1, pp. 251–288), 1st ed. New York: Thieme.
- Desouches, C., Alluin, O., Mutaftschiev, N., Dousset, E., Magalon, G., Boucraut, J., ... Decherchi, P. (2005). Peripheral nerve repair: 30 centuries of scientific research. *Revue Neurologique*, 161, 1045–1059.
- Gu, Y. D., Wu, M. M., Zheng, Y. L., Li, H. R., & Xu, Y. N. (1985). Arterialized venous free sural nerve grafting. *Annals of Plastic Surgery*, 15, 332–339.
- Gu, Y. D., Zhang, G. M., Chen, D. S., Yan, J. G., & Cheng, X. M. (1989). Arterialized free flap. Report of four cases. *Chinese Medical Journal (England)*, 102, 140–144.
- Hong, M. K., & Taylor, G. I. (2006). Angiosome territories of the nerves of the upper limbs. *Plastic & Reconstructive Surgery*, 118, 148–160.

- Hussmann, J., Bahr, C., Russell, R. C., Steinau, H. U., & Vaubel, E. (2003). Experimentelle und klinische Erfahrungen mit der Stromumkehr. *Journal Der Deutschen Gesellschaft Für Plastische Und Wiederherstellungschirurgie*, 24, 24–29.
- Hussmann, J., Bahr, C., Steinau, H. U., & Vaubel, E. (1996). Indications for arterialization of tissue. *Langenbecks Arch Chir Suppl Kongressbd*, 113, 1164–1166.
- Jabaley, M. E. (2006). Primary nerve repair. In D. J. Slutsky & V. R. Hentz (Eds.), *Peripheral nerve surgery: Practical applications in the upper extremity* (pp. 23–38.). Philadelphia, USA: Churchill Livingstone.
- Karacalar, A., & Ozcan, M. (1994). Free arterialized venous flap for the reconstruction of defects of the hand: New modifications. *Journal of Reconstructive Microsurgery*, 10, 243–248.
- Lad, S. P., Nathan, J. K., Schubert, R. D., & Boakye, M. (2010). Trends in median, ulnar, radial, and brachio-plexus nerve injuries in the United States. *Neurosurgery*, 66, 953–960.
- Liu, Y., Jiao, H., Ji, X., Liu, C., Zhong, X., Zhang, H., . . . Cao, X. (2014). A comparative study of four types of free flaps from the ipsilateral extremity for finger reconstruction. *PloS One*, 9, e104014.
- M. A. F. & Wilbourn, A. J. (2015). The electrodiagnostic examination with peripheral nerve injuries. In S. E. Mackinnon (Ed.), *Nerve surgery*, 1st ed. (Vol. 1, pp. 59–74). New York: Thieme.
- Meek, M. F., Coert, J. H., & Robinson, P. H. (2005). Poor results after nerve grafting in the upper extremity: Quo vadis? *Microsurgery*, 25, 396–402.
- Patradul, A., Ngarmukos, C., Parkpian, V., & Kitidumrongsook, P. (1999). Arterialized venous toenail flaps for treating nail loss in the fingers. *Journal of Hand Surgery Britain*, 24, 519–524.
- Rosberg, H. E. e. L. D. (2004). Epidemiology of hand injuries in a middle-sized city in southern Sweden—A retrospective study with an 8-year interval. *Scandiva Journal of Plastic & Reconstructive Surgery & Hand Surgery*, 38, 347–355.
- Rosberg, H. E. S. C. D. L. B. (2004). Prospective analysis of costs, arm function and health status using DASH and SF36 in patients with and forearm trauma of varying severity (HISS). *Scandinavian Journal of Plastic & Reconstructive Surgery & Hand Surgery*, 30, 360–369.
- Rosberg, H. E., Carlsson, K. S., Höjgård, S., Lindgren, B., Lundborg, G., Dahlin, L. B. (2005). Injury to the human median and ulnar nerves in the forearms—Analysis of costs for treatment and rehabilitation of 69 patients in southern Sweden. *Journal of Hand Surgery (British)*, 1, 35–39.
- Rose, E. H. (1989) Small flap coverage of hand and digit defects. *Clinics in Plastic Surgery*, 16, 427–442.
- Rose, E. H., Kowalski, T. A., & Norris, M. S. (1989). The reversed venous arterialized nerve graft in digital nerve reconstruction across scarred beds. *Plastics & Reconstructive Surgery*, 83, 593–604.
- Sheena, Y., Jennison, T., Hardwicke, J. T., & Titley, O. G. (2013). Detection of perforators using thermal imaging. *Plastic & Reconstructive Surgery*, 132, 1603–1610.
- Sinis, N., Kraus, A., Papagiannoulis, N., Werdin, F., Schittenhelm, J., Meyer-mann, R., . . . Schaller, H. E. (2009). Concepts and developments in peripheral nerve surgery. *Clinical Neuropathology*, 28, 247–262.
- Slutsky, D. J., Hentz, V. R. (2006). *Peripheral nerve surgery: Practical applications in the upper extremity*. Churchill Livingstone: Elsevier.
- Sulaiman, W., & Gordon, T. (2013). Neurobiology of peripheral nerve injury, regeneration, and functional recovery: From bench top research to bedside application. *Ochsner Journal*, 13, 100–108.
- Taylor, G. I., & Pan, W. R. (2014). The angiosome concept. In P. Dodwell (Ed.), *The angiosome concept and tissue transfer*, 1st ed. (Vol. 1, pp. 354–395). Florida: Quality Medical Publishing, Inc.
- Terzis, J. K., Skoulis, T. G., & Soucacos, P. N. (1995). Vascularized nerve grafts. A review. *International Angiology: A Journal of the International Union of Angiology*, 14, 264–277.
- Townsend, P. L., & Taylor, G. I. (1984). Vascularised nerve grafts using composite arterialised neuro-venous systems. *British Journal of Plastic Surgery*, 37, 1–17.
- Trehan, S. K., Model, Z., & Lee, S. K. (2016). Nerve repair and nerve grafting. *Hand Clinics*, 32, 119–125.
- Wang, Y., Sunitha, M., & Chung, K. C. (2013). How to measure outcomes of peripheral nerve surgery. *Hand Clinics*, 29, 349–361.
- Woo, S. H., Kim, K. C., Lee, G. J., Ha, S. H., Kim, K. H., Dhawan, V., & Lee, K. S. (2007). A retrospective analysis of 154 arterialized venous flaps for hand reconstruction: An 11-year experience. *Plastics & Reconstructive Surgery*, 119, 1823–1838.
- Wood, M. J., Johnson, P. J., & Myckatyn, T. M. (2015). Anatomy and physiology for the peripheral nerve surgeon. In S. E. Mackinnon & A. Yee (Eds.), *Nerve surgery*, 1st ed. (Vol. 1, pp. 1–40). New York: Thieme.
- Yan, H., Gao, W., Zhang, F., Li, Z., Chen, X., & Fan, C. (2012). A comparative study of finger pulp reconstruction using arterialised venous sensate flap and insensate flap from forearm. *Journal of Plastic, Reconstructive & Aesthetic Surgery: JPRAS*, 65, 1220–1226.

How to cite this article: Casal D, Pais D, Mota-Silva E, et al. Reconstruction of a long defect of the ulnar artery and nerve with an arterialized neurovenous free flap in a teenager: A case report and literature review. *Microsurgery*. 2018;38:209–217. <https://doi.org/10.1002/micr.30265>