



Letter to the Editor

Unusual Presentation of *Tinea Corporis* Associated With the Use of a Microneedling Device

Nélia Margarida Martins da Cunha, MD;
Sara Leite de Azevedo Campos, MD; and
Ana Isabel Pina Clemente Fidalgo, MD

Editorial Decision date: April 18, 2017.

Microneedling devices have been increasingly used by medical practitioners for skin rejuvenation and scar treatment, and some devices are also available for patient use at home.¹ Reported side effects include pain, transient erythema, edema, bruising, pin-point bleeding and crusting, postinflammatory hyperpigmentation, and tram track scarring, the severity of which often depends on the needle length.^{2,3} Local hypersensitivity reactions have also been reported in 4 patients.^{4,5} Although the *stratum corneum* barrier is disrupted, there are no reports of associated infections to the knowledge of the authors. Herein, we report a case of an extensive *tinea corporis* with a bizarre distribution pattern associated with the use of a microneedling device.

A 26-year-old woman, otherwise healthy, presented to us in February 2014 with an itchy dermatosis evolving for one week and affecting both arms and both legs. On examination (Figure 1), multiple annular erythematous plaques of 0.5 to 2 cm in diameter and elevated borders were observed on the anterior and posterior aspects of both forearms, the anterior aspect of both thighs, and the abdomen. Lesions on the forearms and thighs had emerged simultaneously and corresponded with sites where she had been using a microneedling device weekly at night for 3 weeks prior to the appearance of the dermatosis. The device was a dermaroller with 540 stainless steel microneedles of 0.5 mm length, and had been recommended to her by a dermatologist to treat old traumatic linear scars present on those areas. After the microneedling, she applied rosehip oil to her skin. The patient assured us she had carefully cleaned the skin beforehand, and the device before and

after the procedure, using 70% ethanol. She said she had not used the device over any kind of previously existing inflammatory skin lesion.

The differential diagnoses considered were *tinea corporis*, *granuloma annulare*, and *erythema multiforme minor*. A cutaneous biopsy was performed and superficial scrapings were collected for mycological examination. A potassium hydroxide examination was positive for fungus, and the culture identified *Microsporum canis* as the causative agent. Subcorneal hyphae were seen on histology (Figure 2).

The patient was effectively treated with oral terbinafine, 250 mg *per os* daily for one month, and topic serctoconazol, twice daily until complete resolution. At a three-week follow up, partial resolution was observed (Figure 3), with complete resolution at the five-week follow up. Upon further questioning, the patient recalled that her cat, who often slept on her bed, had experienced tail desquamation and hair loss for 2 weeks before the onset of her dermatosis. Hence, she was also advised to seek a veterinary consultation for the cat. Unfortunately, we were not able to obtain a mycological examination of the cat's skin.

Drs Cunha and Campos are Residents, Dermatology Department, Hospital de Santo António dos Capuchos—Centro Hospitalar de Lisboa Central, Lisboa, Portugal. Dr Fidalgo is a dermatologist in private practice in Lisboa, Portugal.

Corresponding Author:

Dr Nélia Margarida Martins da Cunha, Alameda de Santo António dos Capuchos, 1169-050 Lisboa, Portugal.
E-mail: nelia.margarida.cunha@gmail.com

Aesthetic Surgery Journal
2017, Vol 37(7) NP69–NP72
© 2017 The American Society for
Aesthetic Plastic Surgery, Inc.
This is an Open Access article
distributed under the terms of the
Creative Commons Attribution-
NonCommercial-NoDerivs licence
(<http://creativecommons.org/licenses/by-nc-nd/4.0/>), which
permits non-commercial repro-
duction and distribution of the
work, in any medium, provided
the original work is not altered or
transformed in any way, and that
the work is properly cited. For
commercial re-use, please contact
journals.permissions@oup.com
DOI: 10.1093/asj/sjx086
www.aestheticsurgeryjournal.com

OXFORD
UNIVERSITY PRESS

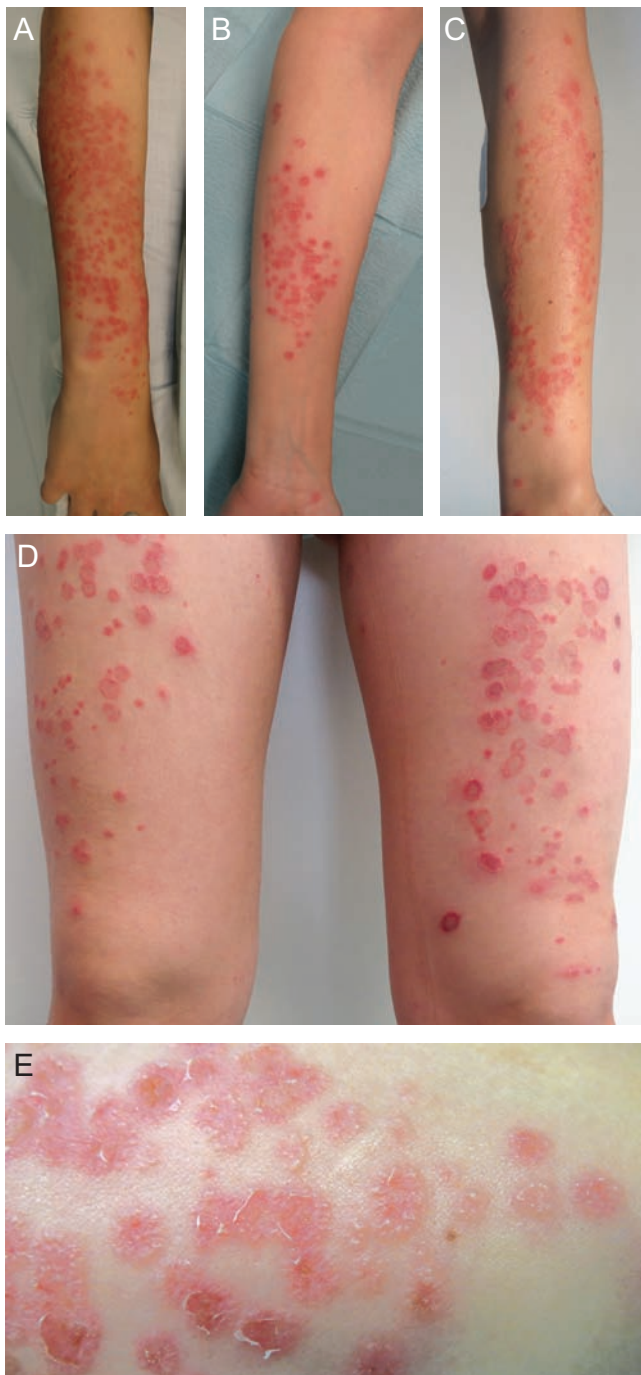

Figure 1. This 26-year-old woman presented to us with multiple annular erythematous plaques of 0.5 to 2 cm in diameter and elevated borders on both forearms, both thighs, and abdomen. The pictures, taken on the occasion she presented, show the posterior aspect of the right forearm (A), the anterior (B) and posterior (C) aspects of the left forearm, and the anterior aspect of both thighs (D). A close up of the lesions can be observed (E).

Considering the patient's anamnesis and this unusual pattern of *tinea corporis*, with simultaneously arising lesions in the sites where the microneedling device was applied, we can consider that the disruption of the epidermis by the microneedles facilitated the infection of multiple sites when in contact with the infected cat and/or bed linen. Microneedling dramatically increases the skin's permeability to therapeutic and cosmeceutical substances by creating reversible microchannels in the skin.^{6,7} This enhanced permeability was shown to be optimal at 5 minutes after microneedling with 1 mm long needles, and drastically reduced after 30 minutes.⁶ Similarly, while open, these microchannels may facilitate the access of microorganisms or deleterious substances.⁶ The exact depth of needle penetration and the effects on skin permeability with the device used by the patient may differ from those results due to a higher density of shorter needles and variations in the pressure used. Nevertheless, in superficial mycoses, fungi invade keratinized tissues, so even if the depth of the microchannels is eventually smaller, the disruption of the *stratum corneum* is sufficient to facilitate a fungal infection. As the procedure was performed by the patient, a less rigorous pre- and postprocedural care with the device cannot be excluded, and might be an important additional factor.

Microneedling is a minimally invasive procedure, with a low risk of complications.^{1,2,6,7} However, even if it remains relatively intact, the epidermis is indeed disrupted, and this may predispose to cutaneous infections. This case report emphasizes the critical need for standardized protocols for safe microneedling techniques, specific regulatory guidelines for home vs medical usage, and avoidance of inadvertent exposure to infectious agents in the treatment environment. We strongly advise that patients be informed of the appropriate care with homecare rollers and to avoid undue exposure to contaminants during the critical period for reestablishment of the skin's barrier system. These concerns should apply equally to motorized devices and treatments in medical facilities. Although microneedling is usually a safe procedure, technical expertise during the procedure and vigilant proactive aftercare are essential to obtain successful outcomes and should be mandatory.

Disclosures

The authors declared no potential conflicts of interest with respect to the research, authorship, and publication of this article.

Funding

The authors received no financial support for the research, authorship, and publication of this article.

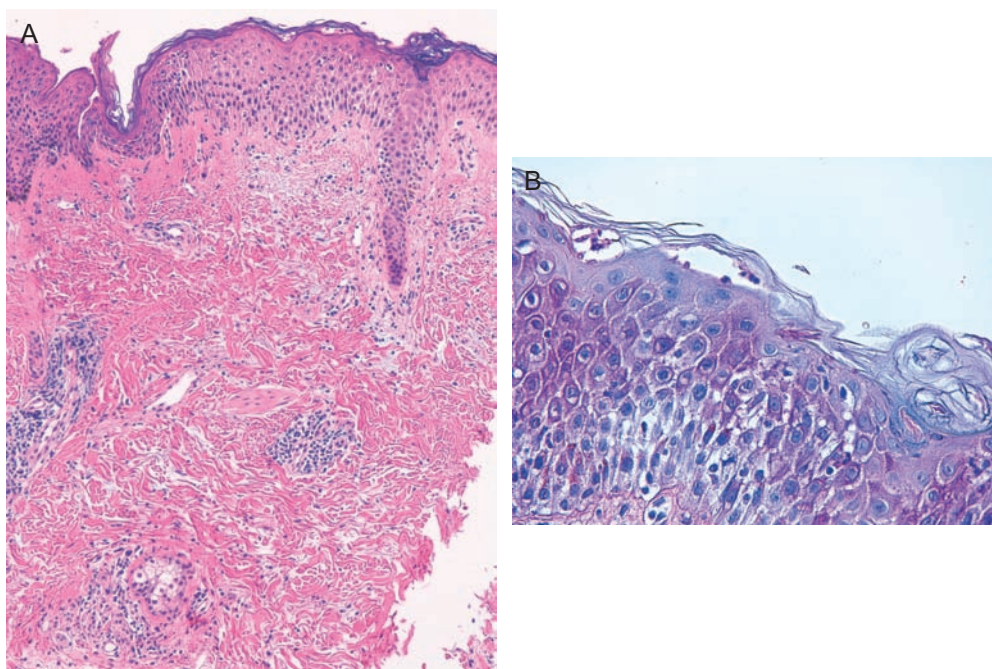


Figure 2. Histological examination of the skin biopsy, showing epidermal spongiosis, subcorneal neutrophils and hyphae, and a superficial perivascular lymphocytic infiltrate (A: hematoxylin-eosin stain, 100 × ; B: Periodic Acid-Schiff stain, 400 ×).

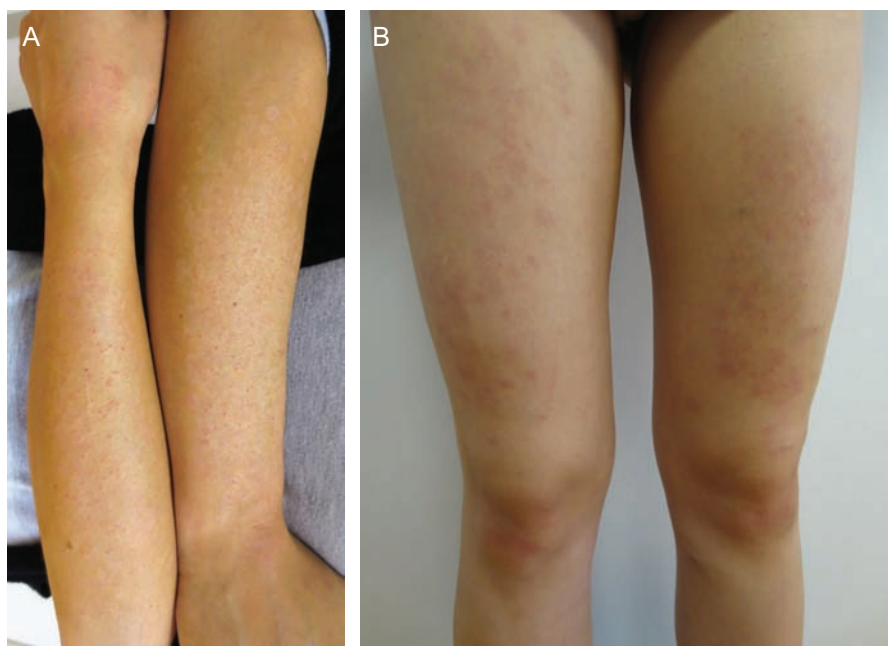


Figure 3. Posterior aspect of both forearms (A) and anterior aspect of both thighs (B) of the same patient 3 weeks after starting the treatment with terbinafine 250 mg *per os* daily and topical sertaconazol twice daily. Great improvement was observed. The patient continued terbinafine for one more week, and topical sertaconazol until complete resolution.

REFERENCES

1. Singh A, Yadav S. Microneedling: advances and widening horizons. *Indian Dermatol Online J.* 2016;7(4):244-254.
2. Cohen BE, Elbuluk N. Microneedling in skin of color: a review of uses and efficacy. *J Am Acad Dermatol.* 2016;74(2):348-355.
3. Pahwa M, Pahwa P, Zaheer A. "Tram track effect" after treatment of acne scars using a microneedling device. *Dermatol Surg.* 2012;38(7 Pt 1):1107-1108.
4. Soltani-Arabshahi R, Wong JW, Duffy KL, Powell DL. Facial allergic granulomatous reaction and systemic hypersensitivity associated with microneedle therapy for skin rejuvenation. *JAMA Dermatol.* 2014;150(1):68-72.
5. Yadav S, Dogra S. A cutaneous reaction to microneedling for postacne scarring caused by nickel hypersensitivity. *Aesthet Surg J.* 2016;36(4):NP168-NP170.
6. Sasaki GH. Micro-needling depth penetration, presence of pigment particles, and fluorescein-stained platelets: clinical usage for aesthetic concerns. *Aesthet Surg J.* 2017;37(1):71-83.
7. Few JW, Semersky A. Commentary on: Micro-needling depth penetration, presence of pigment particles, and fluorescein-stained platelets: clinical usage for aesthetic concerns. *Aesthet Surg J.* 2017;37(1):84-85.

Oxford Journals Collection

The *Oxford Journals Collection* includes highly cited, quality journals in the fields of Medicine, Life Sciences, Humanities, Law, Mathematics, Physical Sciences, and Social Sciences, offering access to content dating back to 1996.

Individual libraries and consortia can subscribe to the entire package, a subject subset, or a bespoke selection tailored to meet the needs of the library user.

Benefits for Libraries:

- Perpetual access to paid-for content
- Access available via IP address or remotely
- Mobile-optimized service

Pass this information on to your librarian and encourage them to visit academic.oup.com/journals/pages/librarians

academic.oup.com/journals

OXFORD
UNIVERSITY PRESS