

# **Retinal Pigment Epithelium Transplantation in Retinal Diseases**

**Fred Kuanfu Chen**

Institute of Ophthalmology, University College of London and  
Moorfields Eye Hospital NHS Foundation Trust

Supervisors: Doctor Lyndon Da Cruz and Professor Peter J. Coffey

Thesis submitted for the degree of Doctor of Philosophy (Ph.D.)  
University College of London

February 2011

I, Fred Kuanfu Chen, confirm that the work presented in this thesis is my own. Where information has been obtained with the help of others, I confirm that this has been indicated below and summarised by tables presented in Chapters 4, 5 and 6:

1. All surgical procedures including human autologous retinal pigment epithelium (RPE)-choroid graft, human macular translocation and human embryonic stem cell (hESC) derived-RPE transplant into the porcine animal model were performed by Dr. Lyndon Da Cruz (**Chapter 3, section 3.1.1**).
2. The protocol and ethics forms for the pilot study of autologous RPE-choroid graft in patients with inherited macular disease were written by Dr. Gurmit Uppal and Dr. Lyndon Da Cruz (**Chapter 3, section 3.1.1**). The protocol and ethics forms for the pilot study of autologous RPE-choroid grafts in patients with geographic atrophy were written by the author.
3. The protocol and ethics forms for the porcine experiments were written by Professor Peter Coffey (**Chapter 3, section 3.2.1**). The animals were cared for by the staff at Northwick Park Institute for Medical Research (NPIMR). Anaesthesia for the animal experiments was administered by the veterinary surgeons at NPIMR (**Chapter 3, section 3.2.5**).
4. The hESC derived-RPE used for the porcine experiments was grown by Dr Ahmad Ahmado (**Chapter 3, section 3.2.3**). Post-operative examinations and enucleation of the porcine globes were performed by the author. Fixation, sectioning and staining of the tissue were carried out by Dr Ahmad Ahmado and Dr. Jean Lawrence (**Chapter 3, sections 3.2.8, 3.2.9 and 3.2.10**). Pooled analysis of the post-operative course, gross anatomy and histological features were carried out by the author.
5. Electrophysiological tests were carried out by Dr Magella Neveu and interpreted by Professor Graham Holder, Dr Magella Neveu and Dr Anthony Robson of the Electrodiagnostic Department, Moorfields Eye Hospital (**Chapter 3, section 3.1.7**).

Fred Kuanfu Chen

Date

## **Abstract**

Age-related macular degeneration (AMD) and inherited macular diseases (IMD) are retinal disorders that can cause blindness through atrophy of the retinal pigment epithelium (RPE) or choroidal neovascularisation (CNV). RPE transplantation in severe forms of neovascular AMD has been performed with promising short-term outcomes. However, this approach has not been evaluated in atrophic types of AMD or IMD. Furthermore, the long-term outcomes of photoreceptors cell function rescue by RPE reconstruction in neovascular AMD is unknown. Current surgical techniques are complex with associated high complication rates. Therefore, other treatment approaches to reconstruct the RPE are required.

This thesis aims to examine whether long-term photoreceptor cell function rescue can be achieved through RPE reconstruction by investigating the outcomes of autologous RPE transplantation or full macular translocation in AMD and IMD. A further aim is to determine the feasibility of a new approach to reconstruct the RPE using human embryonic stem cell (hESC).

A prospective study of autologous RPE-choroid grafts in 9 patients with atrophic macular disease secondary to AMD or IMD demonstrated that submacular RPE graft can support retinal function and fixation. However, there was a high surgical and post-operative complication rates and the overall visual acuity and reading ability declined. Long-term follow-up demonstrated that the graft can maintain retinal function for over 2 years in some patients.

A retrospective review of long-term outcomes following autologous RPE-choroid grafts and full macular translocation in 12 and 40 patients with neovascular AMD, respectively, showed that rescue of retinal function beyond 2 years is possible. A visual acuity of 6/12 was achieved and maintained for over 2 years in 8% and 15% of patients who had patch graft and translocation, respectively. However, overall visual acuity outcomes were limited by delayed post-operative complications such as recurrent CNV and cystoid macular oedema.

A prospective porcine experiment showed that subretinal implant of hESC derived-RPE was feasible and human donor cell can survive in vivo for up to 6 weeks. However, there was significant loss of the hESC-RPE which may have occurred intra-operatively or during the first 2 weeks post-operatively. Macrophages were noted at the site of the graft suggesting some inflammatory and immunological responses to the human cells, polyester substrate or surgical trauma.

The work in this thesis has provided the proof of principle that reconstruction of the RPE can maintain retinal function in atrophic and neovascular macular diseases over the long-term. A novel approach using hESC-RPE on an artificial substrate may be a more feasible and safer alternative to current clinical techniques of RPE reconstruction.

## Publications related to this thesis

### Review articles presenting data from this thesis

- Da Cruz L, Chen FK, Ahmado A, Greenwood J, Coffey P. RPE transplantation and its role in retinal disease. **Progress in Retinal and Eye Research** 2007;26:598-635.
- Chen FK, Vugler AA, Coffey PJ, Da Cruz L. Prospects for successful retinal pigment epithelium transplantation in retinal diseases. **Ophthalmology International** 2009 Autumn 45-49.

### Original articles also presenting data from this thesis

- Chen FK, Uppal GS, Rubin GS, Webster A, Coffey PJ, Da Cruz L. Evidence of retinal function using microperimetry following autologous retinal pigment epithelium-choroid graft in macular dystrophy. **Investigative Ophthalmology and Visual Science** 2008;49:3143-50.
- Chen FK, Patel PJ, Uppal GS, Rubin GS, Coffey PJ, Aylward GW, Da Cruz L. A comparison of macular translocation with patch graft in neovascular age-related macular degeneration. **Investigative Ophthalmology and Visual Science** 2009;50:1848-55.
- Chen FK, Uppal GS, MacLaren RE, Coffey PJ, Tufail AT, Aylward GW, Da Cruz L. Long term visual and microperimetry outcomes following autologous retinal pigment epithelium choroid graft for exudative age-related macular degeneration. **Clinical Experimental Ophthalmology** 2009;37:275-285.
- Chen FK, Patel PJ, Coffey PJ, Tufail A, Da Cruz L. Increased fundus autofluorescence in neovascular age-related macular degeneration is associated with outer segment shortening in macular translocation model. **Investigative Ophthalmology and Visual Science** 2010;51:4207-12
- Chen FK, Patel PJ, Uppal GS, Tufail A, Coffey PJ, Da Cruz L. Long-term outcomes following full macular translocation surgery in neovascular age-related macular degeneration. **British Journal of Ophthalmology** 2010;94:1337-43
- Wickham L, Chen FK, Lewis GP, Uppal G, Neveu MM, Wright G, Robson AG, Webster AR, Grierson I, Hiscott P, Coffey P, Holder GE, Fisher SK, Da Cruz L. Clinicopathological case series of 4 patients with inherited macular disease. **Investigative Ophthalmology and Visual Science** 2009;50:3553-61.

### Original articles presenting works extended from this Thesis

- Chen FK, Patel PJ, Webster AR, Coffey PJ, Tufail A, Da Cruz L. Nidek MP1 is able to detect subtle decline in function in inherited and age-related atrophic macular disease with stable visual acuity. **Retina** 2010;31:371-379 (see **Appendix 1** for reprint).
- Chen FK, Patel PJ, Xing W, Crossland MD, Bunce C, Rubin GS, Da Cruz L. Intrasession repeatability in fixation stability assessment using the Nidek MP-1. **Ophthalmic and Vision Science** 2011 June [Accepted on 23<sup>rd</sup> Jan 2011].
- Chen FK, Patel PJ, Xing W, Bunce C, Egan C, Tufail AT, Coffey PJ, Rubin GS, Da Cruz L. Test-retest variability of microperimetry using the Nidek MP1 in patients with macular disease. **Investigative Ophthalmology and Visual Science** 2009;50:3463-3472 (see **Appendix 1** for reprint).

- Carr A-J, Vugler A, Lawrence J, Chen LL, Ahmado A, Chen FK, Semo M, Gias C, Da Cruz L, Moore HD, Walsh J, Coffey PJ. Molecular characterization and functional analysis of phagocytosis by human embryonic stem cell-derived RPE cells using a novel human retinal assay. **Molecular Vision** 2009;15:283-295 (see **Appendix 1** for reprint).

### **Conference oral presentations presenting data from this thesis**

- Chen FK, Ahmado A, Vugler A, Lawrence J, Coffey P, Da Cruz L. Reconstruction of the retinal pigment epithelium: An evolution of surgical approach and outcomes. 41<sup>st</sup> Annual Scientific College Congress, The Royal Australian and New Zealand College of Ophthalmologists. *Clin Exp Ophthalmol* 2009;37(S1):A52. **The 41<sup>st</sup> Annual Scientific Congress (2009) of the Royal Australia and New Zealand College of Ophthalmologists, Brisbane, Australia.**
- Chen FK, Uppal GS, Webster AR, Balaggan KS, Neveu M, Milliken A, Holder GE, Coffey PJ, Rubin GS, Da Cruz L. Autologous RPE choroid transplantation in inherited macular dystrophy. *IOVS* 2007;48:ARVO E-Abstract 6026, **The 2007 Annual Meeting of the Association for Research in Vision and Ophthalmology, Fort Lauderdale, USA.**
- Chen FK, Coffey PJ, Webster AR, Holder GE, Rubin GS, Da Cruz L. One year outcomes of autologous RPE choroids graft in inherited macular dystrophy. *Clin Exp Ophthalmol* 2007;35(S1):A36-A56. **The 39<sup>th</sup> Annual Scientific Congress (2007) of the Royal Australia and New Zealand College of Ophthalmologists, Perth, Australia**

### **Conference poster presentations presenting data from this thesis**

- Chen FK, Patel PJ, Xing W, Bunce C, Egan C, Tufail A, Coffey PJ, Rubin GS, Da Cruz L. Reliability of Nidek MP1 in Fixation Test and Retinal Sensitivity Measurement in Patients With Macular Disease. **The 2009 Annual Meeting of the Association for Research in Vision and Ophthalmology**, Fort Lauderdale, USA.
- Chen FK, Uppal GS, MacLaren R, Tufail A, Aylward GW, Da Cruz L. Long term functional and structural outcomes of macular translocation and autologous RPE choroids patch graft for treatment of exudative age-related macular degeneration. *IOVS* 2008;49:ARVO E-Abstract 4285. **The 2008 Annual Meeting of the Association for Research in Vision and Ophthalmology**, Fort Lauderdale, USA.

## **Acknowledgements**

There are many people who made this work possible. Firstly, a big thankyou to Lyndon Da Cruz for his inspiration, guidance, constant encouragement, constructive comments and advice on my clinical and research work. It has been a wonderful privilege to have worked with Lyndon over these years. I am also grateful to Professor Pete Coffey for his supervision, tireless efforts in obtaining funding, optimism and practical guidance.

My gratitude also goes to Gurmit Uppal (a previous M.D. student of Dr. Da Cruz) who passed on his knowledge and shared his valuable experience in clinical trials with me when I first started this research. Special thanks to the staffs at the Clinical Trials Unit: Tina Burman, Suzanne Cabral, Matthew Richardson, Wen Xing and Catey Bunce. The supports from Professor Gary Rubin on microperimetry and psychophysical outcomes were much appreciated. I thank Magella Neveu for helpful comments and advice on clinical electrophysiology. Many thanks also go to Jean Lawrence for her patience in teaching me techniques of tissue sectioning, immunohistochemistry and confocal microscopy. I am grateful for the support from the research team at Professor Pete Coffey's laboratory (Ahmad Ahmado, Carlos Gias, Anthony Vugler, Amanda Carr, Li Li Chen and Jasmyn Rybak-Rajewski), the staffs at Northwick Park Institute of Medical Research (Cathy Gray, Aaron Southgate and Jane Knight), Graham Nunn from theatre at Moorfields, Professor Alex Seifalian from Royal Free Hospital and Karen Cheetham from UCL Business who made the porcine experiments possible. There were many other people who helped me along the way including Praveen Patel, Louisa Wickham, Adnan Tufail, Catherine Egan and Andrew Webster.

I am indebted to the I-Cyte Project and the London Project to Cure Blindness for funding my research. I am also grateful for the Bausch and Lomb RANZCO scholarship, the Special Trustees of Moorfields Eye Hospital and the NIHR Biomedical Research Centre for Ophthalmology for providing support for travel to conferences and the infrastructure for clinical research at Moorfields Eye Hospital.

Most importantly, this thesis would not be possible without the love, encouragement, patience and sacrifices from my wife, Claire. I am grateful for our 2 precious children, Grace and Aidan, for keeping my feet on the ground and providing entertainment during my study breaks.

## List of Abbreviations

AMD	age-related macular degeneration
BDNF	brain-derived neurotrophic factor
bFGF	basic fibroblast growth factor
BM	Bruch's membrane
BSS	balanced salt solution
CF	counting fingers
CNTF	ciliary neurotrophic factor
CNV	choroidal neovascularisation
CS	contrast sensitivity
Cy	cyanine
DAPI	4'6-diamindino-2-phenylindole dihydrochloride
DTH	delayed-type hypersensitivity
ED-1	monoclonal anti-rat CD68 antibody (marker of macrophage)
ERG	electroretinography
ERM	epiretinal membrane
ES	embryonic stem
ETDRS	Early Treatment Diabetic Retinopathy Study
FAF	fundus autofluorescence
FITC	fluorescein isocyanate
GA	geographic atrophy
GDNF	glial cell line-derived neurotrophic factor
GFP	green fluorescent protein
hESC-RPE	human embryonic stem cell-derived retinal pigment epithelium
HLA	human leukocyte antigen
HM	hand motions
IPCV	idiopathic choroidal vasculopathy
iPS	induced pluripotent stem
LogCS	logarithm of contrast sensitivity
LogMAR	logarithm of minimal angle of resolution
LRAT	lecithin retinol acyltransferase
merTK	a receptor tyrosine kinase found in <i>monocytes</i> and tissues of <i>epithelial</i> and <i>reproductive</i> origin (Graham <i>et al.</i> 1994)
MHC	major histocompatibility complex

MMD	myopic macular degeneration
MP1	microperimeter 1
MPS	macular photocoagulation study
NDS	normal donkey serum
NEI VFQ	National Eye Institute Visual Function Questionnaire
OCT	optimal cutting temperature
OS	outer segment
PBS	phosphate-buffered saline
PED	pigment epithelial detachment
PEDF	pigment epithelial derived factor
PDT	photodynamic therapy
PKC	protein kinase C
PVR	proliferative vitreoretinopathy
RA	reading acuity
RAP	retinal angiomatous proliferation
RCS	Royal College of Surgeons
RD	retinal detachment
RPE	retinal pigment epithelium
RS	reading speed
SD	standard deviation
SD-OCT	spectral domain optical coherence tomography
SEM	standard error of mean
SLO	scanning laser ophthalmoscope
SST	submacular surgery trials
TAP	Treatment of Age-related macular degeneration with Photodynamic therapy
TEM	transmission electron microscopy
TD-OCT	time domain optical coherence tomography
TRITC	tetramethyl rhodamine isocyanate
VA	visual acuity
VEGF	vascular endothelial growth factor
VIP	Verteporfin In Photodynamic therapy



# Table of Contents

<b>Abstract</b> .....	<b>3</b>
<b>Publications related to this thesis</b> .....	<b>4</b>
<b>Acknowledgements</b> .....	<b>6</b>
<b>List of Abbreviations</b> .....	<b>7</b>
<b>List of Figures</b> .....	<b>13</b>
<b>List of Tables</b> .....	<b>15</b>
<b>Chapter 1 Introduction and overview</b> .....	<b>17</b>
1.1 <i>Natural history of atrophic macular disease</i> .....	18
1.2 <i>Retinal pigment epithelium and macular disease</i> .....	19
1.3 <i>Aims of the thesis</i> .....	21
1.4 <i>Overview of the thesis</i> .....	21
<b>Chapter 2 Background</b> .....	<b>23</b>
2.1 <i>History of RPE transplantation</i> .....	24
2.2 <i>Animal experiments on RPE transplantation</i> .....	24
2.2.1 <i>Source of donor cells</i> .....	25
2.2.2 <i>Transplantation techniques</i> .....	25
2.2.3 <i>Donor RPE attachment and integration</i> .....	33
2.2.4 <i>Immunology and rejection</i> .....	36
2.2.5 <i>The effect of RPE transplant on retina and choroid</i> .....	40
2.2.6 <i>Long-term outcomes</i> .....	45
2.2.7 <i>Summary of animal experiments</i> .....	46
2.3 <i>Human Trials in RPE Transplantation</i> .....	46
2.3.1 <i>Proof of principle</i> .....	46
2.3.2 <i>Source of donor cells</i> .....	47
2.3.3 <i>Patient selection for RPE transplantation</i> .....	50
2.3.4 <i>Surgical techniques</i> .....	52
2.3.5 <i>Intra-operative complication</i> .....	58
2.3.6 <i>Post-operative course and complication</i> .....	59
2.3.7 <i>Graft survival and function</i> .....	64
2.3.8 <i>Retinal structure and functional rescue</i> .....	69
2.3.9 <i>Summary of human trials</i> .....	80
2.4 <i>Aims and Hypotheses</i> .....	80
<b>Chapter 3 Materials and Methods</b> .....	<b>81</b>
3.1 <i>Clinical studies and design</i> .....	82
3.1.1 <i>Patient selection</i> .....	82
3.1.2 <i>Surgical procedures</i> .....	83
3.1.3 <i>Outcome measures and follow-up schedule</i> .....	86
3.1.4 <i>Visual acuity and contrast sensitivity tests</i> .....	89
3.1.5 <i>Reading ability test</i> .....	90
3.1.6 <i>Microperimetry</i> .....	91
3.1.7 <i>Electrophysiology</i> .....	96
3.1.8 <i>Quality of life questionnaire</i> .....	101
3.1.9 <i>Fundus confocal scanning laser ophthalmoscopy</i> .....	102
3.1.10 <i>Optical coherence tomography</i> .....	102
3.1.11 <i>Digital fundus photography and angiography</i> .....	103
3.2 <i>Animal experiment and design</i> .....	105
3.2.1 <i>Home Office approval</i> .....	105

3.2.2 Human embryonic stem cell lines.....	106
3.2.3 Derivation of RPE from hESC.....	107
3.2.4 Creation of hESC-RPE monolayer on a substrate .....	107
3.2.5 Preoperative medication and anaesthesia.....	108
3.2.6 Surgical procedure .....	108
3.2.7 Postoperative care and termination.....	109
3.2.8 Tissue preparation.....	111
3.2.9 Immunohistochemistry .....	113
3.2.10 Electron microscopy .....	113
<b>Chapter 4 Autologous RPE Transplantation in Atrophic Macular Disease .....</b>	<b>116</b>
4.1 Background .....	117
4.2 Aims.....	117
4.3 Specific Methodology .....	118
4.3.1 Genotyping of dystrophy patients.....	118
4.3.2 Data collection and statistical analysis .....	118
4.4 Results .....	119
4.4.1 Recruitment rate and screening failures.....	119
4.4.2 Baseline patient features .....	119
4.4.3 Feasibility and safety outcomes .....	122
4.4.4 Functional outcomes.....	123
4.4.5 Structural outcomes .....	140
4.4.6 Structure-function correlation.....	141
4.5 Discussion .....	147
4.5.1 Recruitment and eligibility criteria .....	147
4.5.2 Feasibility and safety outcomes .....	149
4.5.3 Functional assessments .....	152
4.5.4 Structural assessments .....	156
4.5.5 Future directions in patch graft surgery in atrophic disease.....	159
4.5.6 Strengths and limitations of the study.....	160
4.5.7 Clinical implications and conclusions .....	161
4.6 Contribution .....	162
<b>Chapter 5 Autologous RPE Transplantation in Neovascular Macular Disease .....</b>	<b>164</b>
5.1 Background .....	165
5.2 Aims.....	166
5.3 Specific Methodology .....	167
5.3.1 Peri-operative variables .....	167
5.3.2 Data collection and statistical analysis .....	167
5.4 Results .....	168
5.4.1 Full macular translocation long-term outcomes.....	168
5.4.2 Autologous RPE patch graft long-term outcomes .....	192
5.4.3 Comparison between translocation and patch graft .....	201
5.5 Discussions.....	212
5.5.1 Long-term outcomes in translocation .....	212
5.5.2 Long-term outcomes in patch graft.....	216
5.5.3 Comparison between translocation and patch graft .....	219
5.5.4 Strength and limitations of the study .....	222
5.5.5 Clinical implications and conclusions .....	223
5.6 Contribution .....	224
<b>Chapter 6 Human ESC-RPE Transplantation in Porcine Model .....</b>	<b>226</b>
6.1 Background .....	227
6.2 Aims.....	227
6.3 Specific Methodology .....	228

6.4 Results .....	228
6.4.1 Baseline features and surgical intervention .....	228
6.4.2 Surgical course and outcome .....	228
6.4.3 Tissue fixation and gross pathology .....	233
6.4.4 Donor cell survival and neuroretinal structure.....	235
6.4.5 Immunological and inflammatory response.....	235
6.5 Discussion .....	239
6.5.1 Feasibility and safety of hESC-RPE graft in porcine model.....	240
6.5.2 hESC-RPE cell survival and photoreceptor cell rescue .....	242
6.5.3 Inflammatory and immunological response.....	243
6.5.4 Implications for future directions in hESC-RPE graft surgery .....	244
6.5.5 Strengths and limitations of the study.....	249
6.5.6 Conclusions .....	251
6.6 Contribution .....	251
<b>Chapter 7 Conclusions.....</b>	<b>253</b>
7.1 Original aims.....	254
7.2 Summary of key findings and implications .....	254
7.3 Appraisal of strengths and limitations.....	255
7.3.1 Strengths of the Thesis.....	255
7.3.2 Limitations of the Thesis .....	255
7.4 Future work.....	256
<b>Bibliography .....</b>	<b>257</b>
<b>Appendix 1: Publications of works extended from this Thesis.....</b>	<b>291</b>
A. Use of microperimetry to study natural history of atrophic macular disease.....	291
B. Intra-session test-retest variability of microperimetry in macular disease.....	300
C. Use of surplus retina for functional assay of stem cell-derived RPE.....	309
<b>Appendix 2: RPE Transplantation in IMD Study Documents.....</b>	<b>322</b>
A. Study Protocol.....	322
B. Participant Information Sheet.....	326
D. Research Ethics Committee Approval .....	331
<b>Appendix 3: RPE Transplantation in Geographic Atrophy Study Documents.....</b>	<b>332</b>
A. Study Protocol.....	332
B. Participant Information Sheet.....	336
D. Research Ethics Committee Approval .....	341
<b>Appendix 4: Long-term Outcomes in Patch Graft Study Documents .....</b>	<b>343</b>
A. Study Protocol.....	343
B. Hospital Research Governance Approval.....	345
<b>Appendix 5: Translocation vs Patch Graft Study Documents.....</b>	<b>346</b>
A. Study Protocol.....	346
A. Hospital Research Governance Approval.....	347
<b>Appendix 6: Long-term Outcomes in Translocation Study Documents.....</b>	<b>348</b>
A. Study Protocol.....	348
B. Hospital Research Governance Approval.....	350

<b>Appendix 7: ERG outcomes in atrophic macular disease study .....</b>	<b>351</b>
<i>A: pattern and full-field ERG outcomes .....</i>	<i>352</i>
<i>B: multifocal ERG outcomes .....</i>	<i>361</i>

## List of Figures

Figure 2.1 Bromodine-deoxyuridine labelled human cells in rat subretinal space.....	29
Figure 2.2 Trans-sclero-choroidal injection of RPE cells .....	32
Figure 2.3 Photoreceptor rescue in the RCS rat model .....	41
Figure 2.4 Functional rescue after RPE graft in the RCS rat .....	44
Figure 2.5 Optokinetic reflex testing in rats .....	44
Figure 2.6 RPE transplantation surgical techniques.....	47
Figure 2.7 Equatorial autologous RPE-choroid graft: OCT .....	58
Figure 2.8 Equatorial autologous RPE graft: angiography.....	68
Figure 2.9 Equatorial autologous RPE graft: microperimetry .....	79
Figure 3.1 Autologous RPE-choroid patch graft in atrophic disease.....	84
Figure 3.2 Normal microperimetry examination printout .....	95
Figure 3.3 Normal PERG, full-field ERG and mfERG waveforms. ....	100
Figure 3.4 Non-invasive fundus imaging .....	104
Figure 3.5 Porcine pars plana vitrectomy and RPE patch transplantation .....	110
Figure 3.6 Preparation of hESC-RPE patch graft.....	112
Figure 3.7 Histology of normal porcine retina and choroid .....	114
Figure 3.8 Positive controls for T and B cells markers .....	114
Figure 4.1 RPE graft in atrophic disease: Neovascular complications .....	125
Figure 4.2 RPE graft in atrophic disease: VA outcomes at 1 and 2 years .....	127
Figure 4.3 RPE graft in atrophic disease: Reading outcomes at 1 year .....	130
Figure 4.4 RPE graft in atrophic disease: Fixation in patients 1 - 3 .....	131
Figure 4.5 RPE graft in atrophic disease: Fixation in patients 4 - 6 .....	132
Figure 4.6 RPE graft in atrophic disease: Fixation in patients 7 - 9 .....	133
Figure 4.7 RPE graft in atrophic AMD: Microperimetry in patients 1 and 5.....	134
Figure 4.8 RPE graft in atrophic AMD: Microperimetry in patients 6 and 8 .....	135
Figure 4.9 RPE graft in atrophic disease: graft perfusion.....	141
Figure 4.10 RPE grafts in atrophic disease: autofluorescence in patients 1 -3 .....	142
Figure 4.11 RPE grafts in atrophic disease: autofluorescence in patients 4 -6 .....	143
Figure 4.12 RPE grafts in atrophic disease: autofluorescence in patients 7 -9 .....	144
Figure 4.13 RPE grafts in atrophic disease: variation in retinal structure .....	145

<b>Figure 4.14 RPE grafts in atrophic disease: structure-function correlation.....</b>	<b>146</b>
<b>Figure 5.1 Visual acuity change after translocation: outcomes at 1 to 4 years .....</b>	<b>174</b>
<b>Figure 5.2 Macular translocation: serial microperimetry .....</b>	<b>178</b>
<b>Figure 5.3 Macular translocation: structural outcome of recurrent CNV.....</b>	<b>181</b>
<b>Figure 5.4 Macular translocation: functional outcome of recurrent CNV.....</b>	<b>183</b>
<b>Figure 5.5 Macular translocation: CMO associated with recurrent CNV .....</b>	<b>184</b>
<b>Figure 5.6 Macular translocation: isolated CMO responding to IVTA .....</b>	<b>186</b>
<b>Figure 5.7 Macular translocation: abnormal patterns of increased fundus AF .....</b>	<b>188</b>
<b>Figure 5.8 Macular translocation: well-delineated region of increased fundus AF.....</b>	<b>189</b>
<b>Figure 5.9 Macular translocation: curvilinear band of increased fundus AF.....</b>	<b>190</b>
<b>Figure 5.10 Macular translocation: OCT in regions of increased fundus AF.....</b>	<b>192</b>
<b>Figure 5.11 Visual acuity change after patch graft: outcomes at 1 to 4 years.....</b>	<b>194</b>
<b>Figure 5.12 Patch graft: fixation outcomes .....</b>	<b>195</b>
<b>Figure 5.13 Patch graft: serial microperimetry in patients 4 and 5.....</b>	<b>198</b>
<b>Figure 5.14 Patch graft: serial microperimetry in patients 7, 8, 9 &amp; 11 .....</b>	<b>199</b>
<b>Figure 5.15 Patch graft: serial fundus autofluorescence.....</b>	<b>201</b>
<b>Figure 5.16 Translocation versus patch graft: median visual acuity over 4 years .....</b>	<b>203</b>
<b>Figure 5.17 Translocation versus patch graft: mean change in visual acuity .....</b>	<b>206</b>
<b>Figure 5.18 Translocation versus patch graft: AF and OCT images.....</b>	<b>208</b>
<b>Figure 5.19 Translocation versus patch graft: structure-function correlation .....</b>	<b>210</b>
<b>Figure 6.1 Porcine transplantation: gross pathology .....</b>	<b>233</b>
<b>Figure 6.2 Cell survival and inflammatory response .....</b>	<b>237</b>
<b>Figure 6.3 CD8-positive cells .....</b>	<b>238</b>
<b>Figure 6.4 CD4-positive and CD79-positive cells.....</b>	<b>239</b>
<b>Figure 6.5 Interim UK regulatory route map for stem cell research.....</b>	<b>246</b>

## List of Tables

Table 2.1 Use of human RPE and non-RPE cells for subretinal transplantation.....	27
Table 2.2 Use of animal RPE and non-RPE cells for subretinal transplantation .....	28
Table 2.3 Publications of allogeneic and autologous RPE transplantation in human.....	48
Table 3.1 Functional outcome measures in atrophic macular disease study.....	87
Table 3.2 Structural outcome measures in atrophic macular disease study .....	88
Table 3.3 Conversion between Snellen fraction and logMAR.....	90
Table 3.4 Summary of electrophysiological testing protocol .....	98
Table 3.5 Summary of pig experiments.....	106
Table 4.1 RPE graft in atrophic disease: Baseline demographic features.....	120
Table 4.2 RPE graft in atrophic disease: Baseline clinical features.....	121
Table 4.3 RPE graft in atrophic disease: Surgical complications .....	124
Table 4.4 RPE graft in atrophic disease: VA, CS and Reading outcomes.....	128
Table 4.5 RPE graft in atrophic disease: Visual acuity outcomes.....	129
Table 4.6 RPE graft in atrophic disease: Contrast sensitivity outcomes.....	129
Table 4.7 RPE graft in atrophic disease: Retinal sensitivity over graft.....	136
Table 4.8 RPE graft in atrophic disease: Summary of pattern and full-field ERG.....	137
Table 4.9 RPE graft in atrophic AMD: NEI VFQ-25 and RAND 36-Item Health Survey .....	138
Table 4.10 RPE graft in atrophic AMD: NEI VFQ-25 and RAND 36-Item Health Survey .....	139
Table 4.11 Contribution list for the dry macular degeneration studies .....	163
Table 5.1 Macular translocation: demographic data .....	169
Table 5.2 Macular translocation: surgical outcomes .....	171
Table 5.3 Macular translocation: frequency distribution of visual acuity .....	173
Table 5.4 Macular translocation: frequency distribution of change in acuity .....	173
Table 5.5 Macular translocation: microperimetry outcomes .....	176
Table 5.6 Macular translocation: treatment of recurrent CNV.....	180
Table 5.7 Patch graft: microperimetry outcomes.....	196
Table 5.8 Translocation versus patch graft: baseline features of patients .....	204
Table 5.9 Translocation versus patch graft: visual acuity over 4 years.....	205
Table 5.10 Translocation versus patch graft: retinal functions from best cases.....	211
Table 5.11 Contribution list for the neovascular macular degeneration studies .....	225

<b>Table 6.1 Pig experiment: Baseline features .....</b>	<b>230</b>
<b>Table 6.2 Pig experiments 1 and 2: Surgical course and complications .....</b>	<b>231</b>
<b>Table 6.3 Pig experiments 3 and 4: Surgical course and complications .....</b>	<b>232</b>
<b>Table 6.4 Gross pathology and tissue processing .....</b>	<b>234</b>
<b>Table 6.5 Pig experiment: summary of cell survival and immune reaction .....</b>	<b>236</b>
<b>Table 6.6 Contribution list for the human to porcine xenotransplantation studies .....</b>	<b>252</b>



# **Chapter 1**

## **Introduction and overview**

The retina is a layer of neural tissue that lines the posterior segment of the eye. The macula is that central portion of the retina which provides high contrast visual acuity (VA), colour discrimination and reading ability. Diseases of the retina are the most common causes of childhood and adult visual loss in the developed countries (Klein *et al.* 1995; Attebo *et al.* 1996; Klaver *et al.* 1998; Krumpaszky *et al.* 1999; Munoz *et al.* 2000; Apte *et al.* 2001; Dimitrov *et al.* 2003). Among these blinding retinal disorders, the most common is age-related macular degeneration (AMD) which peaks in the 8<sup>th</sup> and 9<sup>th</sup> decade (Klaver *et al.* 1998) and contributes to more than half of blindness registration (Yong *et al.* 2006). In contrast, inherited dystrophy of the retina or macula is less common with a prevalence of 1 in 4,000 (Hamel 2006; Michaelides *et al.* 2003). However, they can lead to blindness during the 2<sup>nd</sup> or 3<sup>rd</sup> decade of life. Although the advent of anti-vascular endothelial growth factor (anti-VEGF) therapy has significantly reduced the impact of neovascular complications of AMD on visual loss (Brown *et al.* 2006; Kaiser 2006) and may become useful in certain retinal dystrophies (Querques *et al.* 2008), there are currently no treatment for the dry or atrophic form of these macular diseases.

### **1.1 Natural history of atrophic macular disease**

Visual loss in AMD can be due to geographic atrophy (GA) or choroidal neovascularisation (CNV). Although CNV may regress spontaneously or following a course of anti-VEGF therapy (Brown *et al.* 2006), chorioretinal atrophy may continue unabated to cover the entire posterior pole over 5 to 10 years (Sarks *et al.* 2006). At the end stage of dry degeneration, there is often a large central scotoma with loss of reading ability and impaired visual acuity (VA) ranging from 6/60 to counting fingers (CF) by using eccentric fixation (Shih *et al.* 2006; Wong *et al.* 2008).

Inherited retinal or macular dystrophy usually presents symmetrically and bilaterally. Patients often had a history of progressive loss of central, peripheral, colour, or night vision or any combinations of the above in the first 2 decades of life. Although VA can be variable at the end stage of macular dystrophy, many of these patients are affected by central or paracentral scotomata which often have significant impact on activities of daily living such as reading (Rotenstreich *et al.* 2003; Mori *et al.* 2001). In contrast, end stage retinal dystrophy often has very poor vision with only perception of motion or light due to loss of both central and peripheral visual fields (Hamel 2006).

The similarities in the natural histories of both atrophic AMD and some forms of inherited retinal degenerations are also mirrored by the loss of the retinal pigment epithelium (RPE), choriocapillaris and photoreceptor cells that characterise these conditions. These structures are interdependent and they constitute a functional unit that provides the transducing interface for visual perception (Strauss 2005).

## **1.2 Retinal pigment epithelium and macular disease**

The RPE is a neuroepithelium-derived, cellular monolayer that lies on Bruch's membrane (BM) between the photoreceptor outer-segments and the choriocapillaris. Optimal functioning of these layers is critical to sight (Custer and Bok 1975). Furthermore, the survival of the photoreceptor cell is dependent on the RPE and vice versa. The functions and characteristics of the RPE have been reviewed and documented extensively (Marmor and Wolfensberger 1998; Strauss 2005; Bharti *et al.* 2006). More recently, with the increased understanding of the molecular and cellular mechanisms of disease processes, most importantly inflammation and neovascularisation, the concept of healthy RPE as a therapeutic cell has emerged. The RPE forms the outer blood-retinal barrier and may play an important role in maintaining the relative immune privileged status of the subretinal space (Streilein *et al.* 2002). In terms of angiogenesis related factors, both pigment epithelial derived factor (PEDF) and VEGF are secreted by the RPE (Tanihara *et al.* 1997; Witmer *et al.* 2003; Zhao *et al.* 2006; Cai *et al.* 2006). The extra-cellular matrix, which can have an anti-angiogenic function, is also secreted by the RPE. This central importance of RPE to normal retinal structure and function explains the rationale and attraction of using RPE transplantation in the treatment of several types of retinal and macular dystrophies or degenerations.

RPE dysfunction can be the primary defect in inherited retinal and macular dystrophies. Examples of specific RPE disorders are the monogenic dystrophies that include those arising from mutations in lecithin retinol acyltransferase (*LRAT*) (Thompson *et al.* 2001; Ruiz *et al.* 2001), *RPE65* (Veske *et al.* 1999; Gu *et al.* 1997), cellular retinaldehyde-binding protein (*CRALBP*) (Maw *et al.* 1997), *merTK* (D'Cruz *et al.* 2000; Gal *et al.* 2000; Duncan *et al.* 2003; Tschernutter *et al.* 2006) or *bestrophin* (Sun *et al.* 2002; Marmorstein *et al.* 2000). Treatment of some of these dystrophies such as *RPE65*, *CRALBP* and the *merTK* dystrophies may well be achieved by gene therapy rather than cell transplantation (Vollrath *et al.* 2001; Acland *et al.* 2001; Acland *et al.*

2005; Tschernutter *et al.* 2005; Pang *et al.* 2006; Bainbridge *et al.* 2008; Maguire *et al.* 2008). Others however, such as Best's disease, where there is structural loss and damage to the RPE, will require repopulation of the cell layers with unaffected RPE cells. Although there are few primary RPE dystrophies there are many more photoreceptor dystrophies that lead to secondary RPE atrophy and dysfunctions. The observation of RPE atrophy in primary photoreceptor disorders shows that RPE transplantation may have a broader role than for treatment of diseases which have primary RPE dysfunction.

Possibly more important in visual morbidity is the role of the RPE in complex diseases such as AMD (Rymer and Wildsoet 2005; Nowak 2006). The RPE can be involved in both the active disease such as the inflammatory response or in the balance of factors that modulate eye growth and CNV formation (Tanihara *et al.* 1997; Witmer *et al.* 2003; Rymer and Wildsoet 2005; Zhao *et al.* 2006; Cai *et al.* 2006). Alternatively, the loss of RPE may be the manifestation of the degenerative aspect such as in geographic atrophy (GA) secondary to AMD. As such, RPE transplantation can theoretically be used in specific well-defined photoreceptor and RPE disease as well as more global multifactorial diseases involving the outer retina and choroid.

Reconstruction of the submacular RPE has been performed in animal disease models and human clinical trials. Current surgical approach used to reconstruct RPE in neovascular AMD include full macular translocation (Machemer and Steinhorst 1993; Eckardt *et al.* 1999) and autologous RPE-choroid graft (van Meurs and Van Den Biesen 2003). Short-term outcomes of translocation surgery have provided the proof of principle that visual function can be rescued by RPE transplantation (Toth *et al.* 2004; Mruthyunjaya *et al.* 2004). This is because rotation of the fovea to a region with healthier RPE is in effect a type of RPE transplantation. Although macular translocation has been carried out in patients with GA or adult foveomacular vitelliform dystrophy, the outcomes have been disappointing (Cahill *et al.* 2005a; Eckardt *et al.* 2004). It is not known if autologous RPE-choroid may be a better alternative to translocation in atrophic macular disease. Furthermore, the long-term outcomes of translocation and patch grafts are unknown. Given the surgical complexity of the current surgical approaches, alternative techniques of subretinal RPE graft need to be explored.

### 1.3 Aims of the thesis

The aims of this thesis are:

- (1) To examine and describe the feasibility and safety of autologous equatorial RPE-choroid transplantation in atrophic macular diseases and the short and long term visual function and graft survival.
- (2) To describe the long-term visual function and structural outcomes of autologous equatorial RPE-choroid transplantation and full macular translocation in neovascular AMD, and to compare the outcomes of the first 12 cases from each of these two techniques.
- (3) To examine and describe the feasibility, safety and survival of hESC-RPE patch transplantation into the subretinal space of the normal pig eye and to investigate the immunological reaction to subretinal xenograft.

### 1.4 Overview of the thesis

Following on from this introduction, **chapter 2** provides the background to RPE transplantation by reviewing the literatures on reconstruction of RPE in animal models and human trials. For both animal and human studies, the sources of donor cells are listed, surgical techniques are described and the structural, functional and immunological outcomes are summarised and discussed.

**Chapter 3** outlines the materials and methods used for the clinical studies (**chapters 4 and 5**) and animal experiments (**chapter 6**).

**Chapter 4** describes a prospective study of autologous RPE-choroid graft in atrophic macular disease. The primary outcome measure of the trial was to evaluate whether equatorial RPE-choroid can be harvested and delivered to the submacular space in patients with atrophic macular disease. The secondary outcome measure is intra- and post-operative complications. The exploratory outcome measures are VA, contrast sensitivity, reading ability, fixation stability, microperimetry, electrophysiology, quality of life questionnaire responses, features on fundus autofluorescence and optical coherence tomography and graft perfusion on fluoresceine and indocyanine green angiographies.

**Chapter 5** describes a retrospective study of patients with neovascular AMD who have undergone full macular translocation or autologous RPE-choroid patch graft. Since most of these patients had follow-up for over 2 years, the information will provide an insight into the ability of autologous RPE in maintaining foveal function. The primary outcome measure is the change in VA from pre-operative to the most recent follow-up visit. The secondary outcome measure is the rate of delayed post-operative complications. Microperimetry results are also examined to provide structure-function correlation as an exploratory analysis. The outcomes of the 12 patients who received autologous RPE-choroid graft are also compared and contrasted with the first 12 patients who had undergone full macular translocation.

**Chapter 6** describes a series of human-to-porcine xenograft experiments which examined the feasibility and safety of subretinal hESC-RPE transplantation. The pig eye is chosen as a model because of its anatomical resemblance to the human eye. RPE derived from hESC is used as the donor cell because these can be pre-made as a monolayer on a polyester substrate without the need to harvest autologous cells. In theory, the surgical technique of subretinal grafting a pre-made patch is much less complex than either full macular translocation or autologous RPE-choroid graft, and can be performed by any ophthalmologist trained in vitreoretinal surgery. The main outcome measures of the experiment are the success rate of grafting and post-operative complication rates. Survival of donor cell and immunological or inflammatory reaction are determined by immunohistochemistry and electron microscopy.

As **chapters 4, 5 and 6** deal with different types of surgical techniques and clinical indications, a brief introduction including review of the literature relevant to that chapter is provided at the beginning of the chapter. Methodology specific to the study or experiment are described within the relevant chapter. The results are then discussed within the context of prior literature. The findings described in these chapters and their significances are then brought together in the final concluding **chapter 7**.

# **Chapter 2**

## **Background**

## **2.1 History of RPE transplantation**

It is now over 20 years since the earliest works carried out in RPE transplantation were first published (Gouras *et al.* 1983; Gouras *et al.* 1985; Li and Turner 1988b; Lane *et al.* 1989). The potential for RPE transplantation in the treatment of retinal and macular diseases based on the published literature will be examined. The role of RPE transplantation in the context of other treatments such as gene therapy (Bainbridge *et al.* 2008; Maguire *et al.* 2008), anti-VEGF agents (Brown *et al.* 2006; Rosenfeld *et al.* 2006; Gragoudas *et al.* 2004), photodynamic therapy (PDT) (Michels and Schmidt-Erfurth 2001), angiostatic steroids (Russell *et al.* 2007), and the retinal prostheses (Terasawa *et al.* 2006; Yanai *et al.* 2007) will be put into perspective. The extensive literature on proof of principle in animal RPE transplantation will be explored first followed by a review of the clinical trials of RPE transplantation or translocation.

## **2.2 Animal experiments on RPE transplantation**

Prior to transplantation of the RPE into animal models, it was necessary to isolate and characterise the donor RPE. The human RPE was isolated from Bruch's membrane (BM), maintained in culture and its morphologic and metabolic features characterised in detail during the early 1980s (Flood *et al.* 1980; Boulton *et al.* 1982; Hu *et al.* 1982). By the late 1980s, RPE transplantation to the subretinal space had been reported by a few laboratories (Gouras *et al.* 1989; Sheedlo *et al.* 1989a; Lane *et al.* 1989). These and subsequent animal RPE transplantation studies examined five critical issues that are most relevant to clinical application:

1. What is the most suitable source of RPE for transplantation?
2. What is the best technique to harvest, prepare and deliver the RPE graft?
3. Will the donor RPE adhere to Bruch's membrane or its equivalent substrate?
4. Will the donor RPE with or without substrate evoke immunological rejection?
5. What are the effects of donor RPE on retina, visual function and choroid?
6. What is the long term outcome of RPE transplantation?



### **2.2.1 Source of donor cells**

The various cell sources for RPE or RPE-analogous cell transplantation are tabulated (see **Tables 2.1** and **2.2**). Relevant details of each are discussed within the review of animal experiments and human trials to follow. The table is not exhaustive but aims to illustrate the wide variety of cell types that have been examined for RPE transplantation and the associated literature. In contrast to experience in human RPE transplantation, the most compelling animal experiments that showed visual function rescue used xenogeneic cell sources. The ideal donor RPE will have the following features; (1) readily available and continuous source of cell supply, (2) ease of handling during delivery to the subretinal space, (3) adherence to the BM or its substrate, (4) ability to evade immunological rejection, (5) able to perform all the physiological functions of the macular RPE and (6) survival for the life time of the host.

### **2.2.2 Transplantation techniques**

The steps of any transplantation procedure must include harvesting of donor tissue or cells, may require *ex vivo* modification and ultimately surgical delivery into the host. Each of these steps is discussed separately below.

#### **2.2.2.1 Donor cell harvesting**

In early experiments of RPE allograft or xenograft, isolation of donor cells involved trypsin digestion of RPE cells from an enucleated eyecup. Dissected or debrided RPE cells were collected as sheets or suspension and finally concentrated by centrifuge (Flood *et al.* 1980; Mayerson *et al.* 1985). To harvest a monolayer of RPE, Tezel *et al.* (1997) and Ho *et al.* (1997) have described techniques of using dispase to separate RPE cells from its basement membrane, embedding the monolayer on gelatine with subsequent storage at 4°C or maintenance in culture.

In autologous RPE grafts, harvesting and implantation of the RPE were performed in the same eye at the same operation. Autograft harvesting techniques were first reported in human trials before they were investigated in animal models. Techniques of translocating RPE from one part to another part of the same eye have been described in pigs (Lane *et al.* 1989; Maaijwee *et al.* 2007b) and rabbits (Wongpichedchai *et al.* 1992; Phillips *et al.* 2003; Hu *et al.* 2008). The harvesting procedures described by Lane *et al.* (1989) and Wongpichedchai *et al.* (1992) were

based on a technique described by Peyman *et al.* (1975) for biopsy of sclero-chorio-retinal tissue in human. Similarly, the harvesting techniques described by Phillips *et al.* (2003) and Maaijwee *et al.* (2007b) in animal models were based on surgical procedures first reported in human; the autologous peripheral RPE cell suspension (Binder *et al.* 2002) and the autologous equatorial RPE-choroid grafts (van Meurs and Van Den Biesen 2003), respectively.

Techniques of harvesting RPE-analogous cells such as iris pigment epithelium, Schwann cell, marrow stromal cells, umbilical/placental stem cells, neural or retinal progenitor cells and embryonic stem (ES) cells can be found in the literatures listed in **Tables 2.1 and 2.2**. The generation of non-human primate stem cells through genomic reprogramming using somatic cell nuclear transfer (Byrne *et al.* 2007) and human induced pluripotent stem (iPS) cell line through viral transfection of master transcriptional regulators (Yu *et al.* 2007; Takahashi *et al.* 2007) have opened a new horizon for regenerative medicine as these can potentially provide autologous source of donor cells without the need to harvest the cells from the target tissue. In this thesis, the use of human ES cells derived RPE (hESC-RPE) as donor cells will be examined in a pig model (see chapter 7).

#### 2.2.2.2 Ex vivo modification

Several ex vivo modification of the RPE donor cells in animal experiments have been described and these included cell labelling, genetic modification, immortalisation and tissue engineering.

Donor RPE can be tracked with various markers incorporated into the cells prior to implantation. These include India ink (He *et al.* 1993), carbon particles (el Dirini *et al.* 1992), nuclear fluorescent dye (Wongpichedchai *et al.* 1992), tritiated thymidine (Gouras *et al.* 1985; 1992), 5-bromo-2-deoxyuridine (Ye *et al.* 1998; Gabrielian *et al.* 1999b; Lund *et al.* 2001a) (see **Figure 2.1**) and carboxyfluorescein diacetate succinimidyl ester (Cong *et al.* 2008).

**Table 2.1 Use of human RPE and non-RPE cells for subretinal transplantation**

Type of cell	References
Primary RPE cells	<p>Adult Homologous or heterologous Gouras <i>et al.</i> (1985), Peyman <i>et al.</i> (1991), He <i>et al.</i> (1993), Castillo <i>et al.</i> (1997), Tezel <i>et al.</i> (2007).</p> <p>Autologous Peyman <i>et al.</i> (1991), Stanga <i>et al.</i> (2001a), Binder <i>et al.</i> (2002), van Meurs and van Den Biesen (2003)</p>
Fetal/Childhood (homologous or heterologous)	<p>Suspension Algreve <i>et al.</i> (1994), Durlu and Tamai (1997), Castillo <i>et al.</i> (1997), Gabnolian <i>et al.</i> (1999b), Oganessian <i>et al.</i> (1999)</p> <p>Patch or sheet Bhatt <i>et al.</i> (1994), Sheng <i>et al.</i> (1995), Little <i>et al.</i> (1996; 1998), Berglin <i>et al.</i> (1997)</p>
Transformed RPE cells	<p>Genetically modified Lund <i>et al.</i> (2001a)</p> <p>Growth factor Ogata <i>et al.</i> (1999)</p> <p>Reporter-protein Labeled (GFP) Lai <i>et al.</i> (1999; 2000), Wang <i>et al.</i> (2002), MacLaren <i>et al.</i> (2007)</p>
Spontaneously transformed	<p>ARPE19 and D407 Dunn <i>et al.</i> (1996; 1998), Davis <i>et al.</i> (1995), Coffey <i>et al.</i> (2002), Girman <i>et al.</i> (2003; 2005), McGill <i>et al.</i> (2004), Wang <i>et al.</i> (2005a; 2005b), Pmilla <i>et al.</i> (2005), Sauve <i>et al.</i> (2006)</p>
Non-RPE cells	<p>Iris pigment epithelial cell Rezaei <i>et al.</i> (1997a; 1997b; 1997c), Thumann <i>et al.</i> (1998), Thumann <i>et al.</i> (2008)</p> <p>Schwann cell Lawrence <i>et al.</i> (2000), McGill <i>et al.</i> (2004), Wang <i>et al.</i> (2005b)</p> <p>Bone marrow stem cell Arnhold <i>et al.</i> (2006)</p> <p>Retinal progenitor cell Kumar and Dutt (2006)</p> <p>Neural progenitor cell Wang <i>et al.</i> (2008)</p> <p>Embryonic stem cell derived RPE Klimanskaya <i>et al.</i> (2004), Lund <i>et al.</i> (2006a), Vugler <i>et al.</i> (2008)</p> <p>Umbilical/Placental stem cell Lund <i>et al.</i> (Lund <i>et al.</i> 2006b)</p>

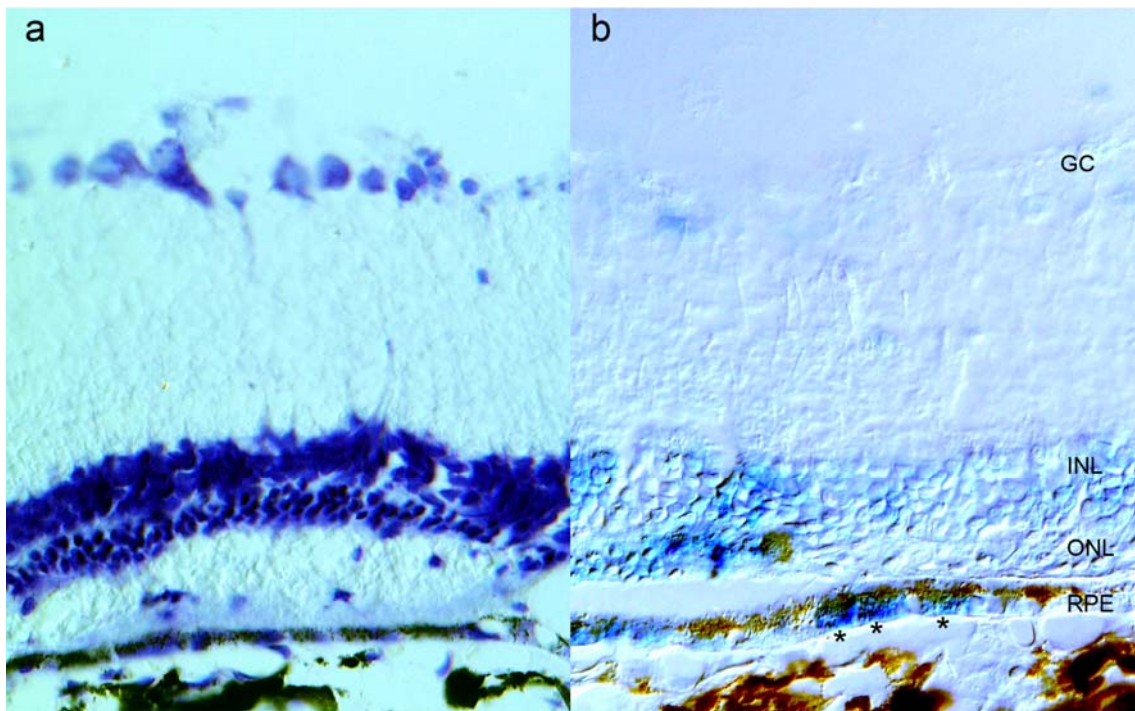
RPE; retinal pigment epithelium.

**Table 2.2 Use of animal RPE and non-RPE cells for subretinal transplantation**

Type of cell	References
Primary RPE cells	Rat (Li and Turner 1988b), Mice (Jiang <i>et al.</i> 1994), Rabbit (Lopez <i>et al.</i> 1987; Crafoord <i>et al.</i> 1999), Bovine (Dufu and Tamai 1997), Ferine (Wang <i>et al.</i> 2001; Wang <i>et al.</i> 2004), Porcine (Nicolini <i>et al.</i> 2000; Grisanti <i>et al.</i> 2002; Eurell <i>et al.</i> 2003; Wiencke <i>et al.</i> 2003; Del Priore <i>et al.</i> 2004)
	Porcine (Lane <i>et al.</i> 1989; Manjwee <i>et al.</i> 2006), Rabbit (Wongpichedchai <i>et al.</i> 1992; Phillips <i>et al.</i> 2003; Hu <i>et al.</i> 2008)
	Mice (Grisanti <i>et al.</i> 1997), Chick (Rizzolo 1991; Rizzolo and Heiges 1991), Rat (Li and Turner 1991), Porcine (Del Priore <i>et al.</i> 2003a; 2003b)
Transformed RPE cells	Rat (Saigo <i>et al.</i> 2004; Abe <i>et al.</i> 2005; Abe <i>et al.</i> 2008)
Non-RPE cells	Fetal/Embryonic/Infantile
	Genetically modified
	Iris pigment epithelial cell
	Bone marrow stem cell
	Retinal progenitor cell
	Neural stem and progenitor cell
Embryonic stem cell derived RPE	Monkey (Hanata <i>et al.</i> 2004)

RPE; retinal pigment epithelium.

Genes introduced into the donor RPE prior to transplantation have been shown to be expressed in the subretinal space (Osusky *et al.* 1995; Dunaief *et al.* 1995; Lai *et al.* 1999; Lai *et al.* 2000; Saigo *et al.* 2004; Abe *et al.* 2005). This can also be useful for tracking the fate of donor cells through expression of reporter gene products such as beta-galactosidase (Osusky *et al.* 1995; Dunaief *et al.* 1995) and green fluorescent protein (Lai *et al.* 1999; 2000; Hansen *et al.* 2003; Saigo *et al.* 2004; Abe *et al.* 2005). The advantages and disadvantages of these markers have been reviewed previously (Lund *et al.* 2001b). A more clinically relevant benefit of ex vivo genetic modification is the ability to insert genes for adhesion molecules receptors (integrin  $\alpha$  and  $\beta$ ), growth factors (BDGF or bFGF) or cytokines (TGF- $\beta$ 2 or interleukin-10) which may enhance cell adhesion, promote photoreceptor rescue and reduce immunogenicity of the donor cells (Fang *et al.* 2009; Saigo *et al.* 2004; Enzmann *et al.* 2001a).



**Figure 2.1 Bromodine-deoxyuridine labelled human cells in rat subretinal space**  
Persistence of transplanted hRPE7 cells can be tracked at 5 months after transplantation. (a) Cresyl violet staining showing retinal histology and presence of RPE cells associated with rescue of the outer nuclear layer. (b) Bromodine-deoxyuridine (BrdU) labelled hRPE7 cells incorporated into the RPE layer, marked with asterix, stained with anti-BrdU antibodies (Courtesy of Professor Pete Coffey). GC; ganglion cell, INL; inner nuclear layer, ONL; outer nuclear layer, RPE; retinal pigment epithelium.

Spontaneously immortalised RPE cell line such as D407 and ARPE-19 may also be useful in providing consistent and readily available cell source for animal experimentation (Davis *et al.* 1995; Dunn *et al.* 1996; 1998). However, there is recent evidence to suggest that ARPE-19 may not be optimal as it does not express *merTK* which is critical for photoreceptor outer segment phagocytosis (Vugler *et al.* 2008).

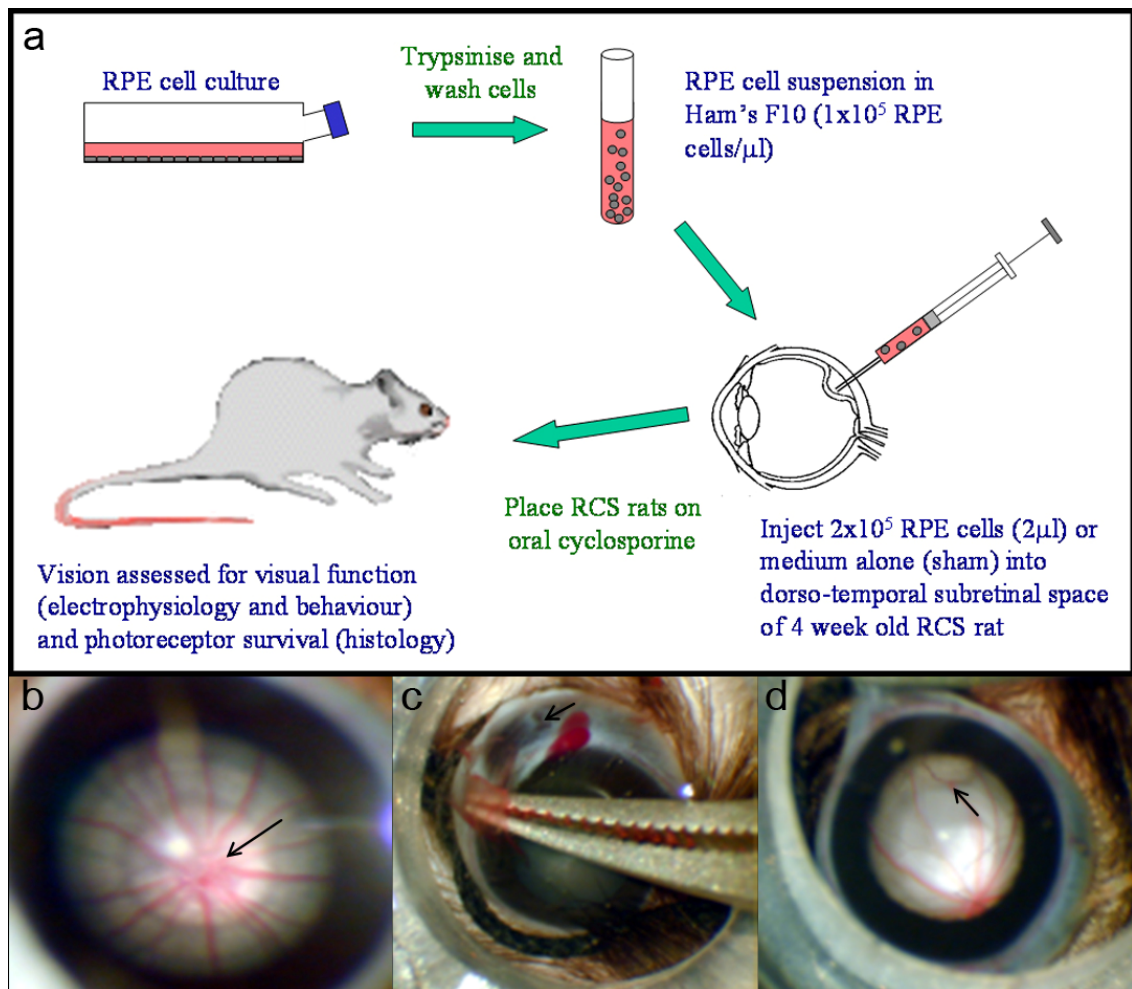
More recently, *ex vivo* bioengineering of cells on an extracellular matrix has been explored to enable delivery of RPE as a sheet rather than cell suspension. The rationale for using natural or artificial extracellular matrix support for delivery of RPE is that RPE attaches poorly to the host BM when it is damaged or absent following surgical extraction of CNV (Del Priore and Tezel 1998; Castellarin *et al.* 1998; Tezel *et al.* 1999) and the surface on which the RPE is cultured has marked impact on the growth and differentiation of the RPE (Campochiaro and Hackett 1993; Song and Lui 1990). Several coated or uncoated, biological or synthetic, substrates have been developed to mimic the function of BM and enable surgical handling of the RPE patch graft. Some of the supports that have been tried were derived from biological sources, allowing RPE to achieve a very good level of differentiation and a few of these were also well tolerated in the subretinal space. These biological substrates include lens capsule (Nicolini *et al.* 2000; Lee *et al.* 2002; Turowski *et al.* 2004), Descemet membrane (Thumann *et al.* 1997), Amniotic membrane (Capeans *et al.* 2003), collagen sheet (Bhatt *et al.* 1994; Thumann *et al.* 2009) and fibrinogen (Oganesian *et al.* 1999). To increase the stiffness and ease of handling of the graft, different groups have tried gelatine encasement of the RPE monolayer (Del Priore *et al.* 2003a; 2003b) or the lens capsule substrate itself (Kiilgaard *et al.* 2002), and ultraviolet cross-linking of the substrate (Bhatt *et al.* 1994). Among these, fibrinogen was found to be particularly inflammatory while other substrates were reported to be well tolerated in the short-term. However, stiff cross-linked collagen substrate did not allow RPE graft to conform to the shape of subretinal space (Bhatt *et al.* 1994). In contrast, gelatine encased anterior lens capsule was still too floppy and did not prevent curling of the substrate in the subretinal space (Kiilgaard *et al.* 2002). Other artificial membranes used for RPE delivery include polyether urethanes like Tecoflex® and Pellethane® which were found to support the growth of ARPE-19 cells to confluence and as a monolayer when the substrates were air/gas plasma treated (Williams *et al.* 2005). A similar result with good phagocytosis function of the RPE was achieved with Polydimethylsiloxane when air/ammonia gas treated (Krishna *et al.* 2007). Biodegradables have also been tried and include polylactoco-glycolic acid and (Hadlock *et al.* 1999; Giordano *et al.* 1997) poly lactic acid

(Thomson *et al.* 1996). Ultimately, whatever substrate is used must meet all the following conditions: (1) surgically easy to handle and transplant, (2) support reasonable differentiation of the RPE monolayer, (3) to be compatible with the host immune and visual system and ultimately for human use; (4) available as clinical-grade product. During the course of work for this thesis, our group has found a non-biodegradable substrate based on polyester. This material has been found to be easy to handle surgically and is able to support differentiation and growth of hESC-RPE as a monolayer. **Chapter 6** of this thesis will also examine how well pigs can tolerate subretinal implant of this polyester substrate.

#### 2.2.2.3 Delivery techniques

The first report of RPE transplantation described an open-sky technique where cultured, <sup>3</sup>H-thymidine-labeled, human RPE cells were transplanted on to denuded Bruch's membrane in owl monkeys without attempt to reattach the retina (Gouras *et al.* 1983; Gouras *et al.* 1985). Although donor RPE cells were seen attached to Bruch's membrane, the difficulty in reattachment of the retina was a major disadvantage of this technique.

Subsequent to the open sky technique, two types of closed-eye techniques of allogeneic RPE transplantation were developed to enable reattachment of the retina. The internal approach involved a pars plana entry with or without vitrectomy followed by a trans-retinal delivery of the cells with a pipette through a small retinotomy. This approach has been used for RPE graft in rabbits (Lopez *et al.* 1987; Brittis *et al.* 1987), rats (Gouras *et al.* 1989), pigs (Lane *et al.* 1989), cats (Wang *et al.* 2001), dogs (Verdugo *et al.* 2001) and monkeys (Sheng *et al.* 1995). The external approach involves dissection of the posterior or dorsal sclera and trans-sclero-choroidal injection of RPE cells into the subretinal space, thus avoiding vitrectomy and retinotomy (see **Figure 2.2**). This later technique has been used for RPE graft in rats (Li and Turner 1988b), rabbits (Wongpichedchai *et al.* 1992) and mice (Jiang *et al.* 1994). Wongpichedchai *et al.* (1992) describes a comparison of these two approaches in rabbit eyes. Although the external technique is most commonly used in small animal experiments, the internal approach is more appropriate in human RPE transplantation with current vitrectomy system. Nevertheless, the very large lens in the small rodent eye and the small vitreous cavity necessitate external approach in small animal models.



### Figure 2.2 Trans-sclero-chroidal injection of RPE cells

(a) A diagram outlining the overall process of RPE transplantation in rat using the external approach. (b) The optic nerve head (arrow) as seen through operating microscope. (c) A photograph showing a transcleral incision (arrow) after localised conjunctival peritomy. (d) A localised retinal detachment (arrow) after subretinal injection of RPE cells (Courtesy of Dr David Keegan).

Adding to the variety of approaches to access the subretinal space and RPE harvesting techniques is the different instrumentation for delivery of RPE cell suspension or sheet into the subretinal space. Blunt tipped needle (Li and Turner 1988a; 1988b) and glass cannula (Lopez *et al.* 1987; Lopez *et al.* 1989) have been used for delivering dissociated RPE cells or small patches of RPE sheet (Gouras *et al.* 1994; Berglin *et al.* 1997). Electronically motorised injector (Wongpichedchai *et al.* 1992) or manually controlled oil-hydraulic microinjection pump (Weichel *et al.* 2002) have been developed to allow controlled, slow and steady injection of the RPE cell suspension into the subretinal space.

Larger RPE patch grafts can be introduced into the eye and inserted into the subretinal space by using an explant injector where the carrier platform can be shielded



by an advancing protective flexible plastic cannula (Thumann *et al.* 2006). The design of the platform is similar to the aspiration-reflux spatula used by van Meurs in autologous RPE-choroid patch graft (Maaijwee *et al.* 2007b). In both instruments, opening(s) on the platform is connected to a syringe that allows direct control of attachment and release of the graft on the platform or spatula through aspiration and reflux at the plunger respectively. Alternatively, subretinal forceps could also be used to hold and insert the patch graft (Hu *et al.* 2008). Coupling of a motorised vibrator to the subretinal forceps has been shown to facilitate smooth release of the graft (Maaijwee *et al.* 2008b).

Once the graft is delivered into the subretinal space, survival of transplanted RPE depends on (1) donor cell attachment to BM and by implication, an adequate BM or equivalent substrate and (2) evasion of immune rejection and induction of immune deviation. These major obstacles to successful transplantation will be addressed separately in the next 2 subsections.

### **2.2.3 Donor RPE attachment and integration**

It is widely accepted that RPE cells must attach to a suitable substrate in order to avoid apoptosis (Tezel and Del Priore 1997; Tezel *et al.* 2004) or more specifically *anoikis*. The term, *anoikis*, refers to apoptosis triggered in response to lack of extracellular matrix binding. In other words, RPE cells are anchorage dependant. In the following sections, the effects of healthy, injured and diseased BM on the survival of RPE cell suspensions are discussed. The ability of transplanted substrate to support survival of RPE in autologous and allogeneic grafts will also be reviewed.

#### **2.2.3.1 Donor RPE cell suspension adhesion on Bruch's membrane**

In order for donor RPE cells to survive, they need to adhere to healthy BM within minutes or hours of subretinal transplantation. In the early animal experiments of RPE transplantation, exposure of the BM was initially achieved by hydraulic or mechanical debridement of the RPE cells. It was noted that during surgical detachment of the retina, patches of RPE were lifted off BM due to strong adhesion of the apical RPE to neural retina and BM was incompletely exposed. Therefore, EDTA wash was also used during bleb detachment to facilitate separation of the RPE basal plasma membrane from the RPE basement membrane layer of the BM (Wongpichedchai *et al.* 1992). In most animal experiments, the investigators have tried to preserve the BM by hydraulically

removing the RPE cells to ensure exposure of the RPE basement membrane. In vitro studies showed that this basal lamina layer of the Bruch's membrane provides the best substrate for RPE cell adhesions (Del Priore and Tezel 1998). Donor RPE cells can attach to undamaged BM within two hours of delivery (Gouras *et al.* 1985). These donor RPE cells can form tight junctions with adjacent cells, basal infoldings and apical processes that interdigitate with the outer segments of photoreceptors cells (Yamaguchi *et al.* 1992).

However, in current clinical indications of RPE transplantation, there may be pre-existing injury or age-related changes in the BM. An *ex vivo* system consisting of human BM explant has been developed for study of RPE adhesion to different layers of BM (Tezel *et al.* 1999). These types of studies have shown that age-related changes in the inner collagenous layer of Bruch's membrane can inhibit RPE cell repopulation of BM (Tezel *et al.* 2004), and indeed, aged submacular BM does not seem to support uncultured RPE attachment and differentiation altogether (Zarbin 2003). An in vivo rabbit study demonstrated that autologous RPE cell in suspension may adhere to BM damaged by a blunt, bent-tipped 30 g metal cannula and rescue outer retina and choriocapillaris at 30 days (Phillips *et al.* 2003). However, this method of injury to BM does not re-create the clinical scenario where BM and choriocapillaris are severely damaged during removal of CNV. Given the absence of basal lamina in choroidal stroma, it is unlikely that RPE cell suspension will adhere to choroidal bed in GA or after CNV excision and reproduce the BM and choriocapillaris from de novo. Therefore, it is likely that reconstruction of the BM and choriocapillaris is as important as replacement of RPE cells if 'maculoplasty' is to be successful in neovascular AMD and GA (Del Priore *et al.* 2006). This requirement has led to the development and use of RPE-substrate grafts.

#### 2.2.3.2 Use of substrate to enhance RPE adhesion and monolayer formation

A few studies have used rabbits and pigs to investigate the fate of donor cells when biological or artificial substrates were incorporated into the RPE graft. Bhatt and colleagues (1994) examined the effect of cross-linking collagen substrate on surgical handling and attachment of donor RPE in a rabbit xenotransplantation model. They found a monolayer of donor human fetal RPE remaining in the subretinal space despite absorption of the noncross-linked collagenous support. In contrast, when cross-linked collagen was used as a substrate, the donor cells were dispersed in the subretinal space, forming multiple layers on the substrate at 6 weeks. Using 3-dimensional carrier

systems, Oganessian *et al.* (1999) and Rezei *et al.* (2000) observed lateral migration of the donor human fetal RPE xenograft away from the spheroid or microsphere depot at 1 month postoperatively. Histology demonstrated intraretinal migration of the RPE when cross-linked fibrinogen carrier system was used (Oganessian *et al.* 1999). After 1 month, the donor human fetal RPE and the poly (DL-lactide-co-glycolide) polymer spheroid succumb to immunological rejection (Rezei *et al.* 2000). In a porcine model, Nicolini *et al.* (2000) showed survival of RPE on the anterior lens capsule that was allotransplanted with a confluent porcine RPE layer. Although they were not able to distinguish host from donor RPE, it appears that the capsule was able to support growth of the RPE in the subretinal space for 2 weeks. Del Priore *et al.* (2004) showed presence of donor cells by using Barr-body stain after allotransplantation of RPE into porcine subretinal space as a sheet encased in gelatine. These donor cells were seen at 4, 9 and 17 days as well as 1 and 3 months postoperatively. The authors hypothesised that the graft became folded in the subretinal space and donor cells adjacent to the RPE survived by attachment to the host BM and those which were on the inner portion of the graft degenerated and were phagocytosed by subretinal macrophage (Del Priore *et al.* 2004).

The use of autologous macular or equatorial RPE-choroid as the donor graft ensures that the RPE is transplanted as a monolayer and avoids the issue of rejection (Peyman *et al.* 1991; Stanga *et al.* 2002; van Meurs and Van Den Biesen 2003). However, the thick choroidal substrate requires vascularisation and perfusion to maintain the survival of the donor RPE and overlying photoreceptor cells. When these RPE-choroid patch grafts were translocated to mechanically debrided BM in pig and rabbit models, they were successfully revascularised from the underlying choroid by vertical bridging vessels (Maaijwee *et al.* 2007b; Hu *et al.* 2008). Interestingly, these vertical vessels can even grow through an intact BM as demonstrated by revascularisation of an inverted graft (Maaijwee *et al.* 2007b). These vascularised patch grafts supported survival of the donor RPE for up to 3 months. Since the graft was vascularised by 1 week, it is likely that inosculation (simple connection between the existing recipient choroidal bed and donor choroid patch vasculatures) plays a role in early graft perfusion. It remains to be determined if choroidal patch revascularisation involves vasculogenesis and angiogenesis as seen in skin grafts (Capla *et al.* 2006). More importantly, macular cone and rod photoreceptors may not survive during this period of outer retinal ischaemia when the choroid is undergoing vascular remodelling.

## 2.2.4 Immunology and rejection

The survival of donor cells does not only depend on graft integration, allogeneic and xenogeneic donor cells will also need to evade immune rejection by if they are to survive in the subretinal space. The subretinal space exhibit features of immune-privileged sites, characterised by the ability of foreign tissue to survive and induction of systemic immune deviation towards the foreign antigens expressed in the subretinal space (Streilein *et al.* 2002). Furthermore, there is evidence to suggest that the RPE (i.e. the donor tissue) may also be immune-privileged at different levels (Farrokh-Siar *et al.* 1999; Rezai *et al.* 1999; Rezai *et al.* 1997; Zamiri *et al.* 2004). The surgical procedure itself may trigger non-specific inflammatory response and the various chemokines and cytokines released during this initial response may undermine the immune-privileged features of the donor RPE. As with all differentiated cells, RPE constitutionally express class I major histocompatibility complex (MHC) antigens. However, class II MHC antigens and mRNA of various chemokines (e.g. RANTES and MCP-1), cytokines (e.g. interleukins 6, 8 and 15) and cytokine receptors may be induced after exposure to interferon- $\gamma$  and tumour necrosis factor- $\alpha$  (Hollborn *et al.* 2000; Enzmann *et al.* 2001b; Hollborn *et al.* 2001). In the following sections, the immunological reactions to RPE grafts in different animal models or combinations of donor-host discordance will be discussed separately as they may have different levels of immune privilege and immunogenic potentials.

### 2.2.4.1 RPE grafts into mice and rats hosts

The extent of immune privilege in the subretinal space of transgenic mice models has been investigated previously (Wenkel and Streilein 1998). Both cell-associated and soluble antigens injected into the subretinal space can actively suppress systemic delayed-type hypersensitivity (DTH) reaction, confirmed by adoptive transfer assay of splenocytes (Wenkel and Streilein 1998). Such immune deviation was abolished when the RPE was damaged by sodium iodate (Wenkel and Streilein 1998). This suggests that submacular space is unlikely to retain its immune privilege after RPE transplantation given that the host RPE can be damaged by the disease process or the surgery itself. Furthermore, despite evidence of persistence of immune deviation (failure to acquire DTH) to P815 tumour cells and soluble antigens in the subretinal space, the subretinal tumour graft was eliminated by an unknown mechanism after 2 weeks (Wenkel *et al.* 1999). This observation implies that the rejection process in subretinal space was not

induced by the T-cells that mediate donor-specific DTH (Wenkel *et al.* 1999). Unlike the anterior chamber, immune deviation induced by subretinal placement of antigen does not lead to immune privilege in the subretinal space. Although mice have been used for immunological studies, most transplantation experiments have been performed in rats. Below is a summary of previous works that have investigated immune reaction to allogeneic and xenogeneic RPE grafts into rat subretinal space.

RPE allograft can survive for up to 12 months in the RCS rats without immunosuppression (Li and Turner 1991). Donor RPE from Sprague-Dawley rats sustained outer nuclear layer for 6 months before age-related donor cell loss lead to gradual decline in the rescue effect (Li and Turner 1991). In contrast, Zhang and Bok (1998) demonstrated slow decline, during the first 2 months, in the ability of donor RPE allograft to rescue photoreceptors when there is mismatch in major histocompatibility complex (MHC) II or both MHC I and II between the recipient and the donor rats. The decline in rescue was accelerated when the host rat was challenged with donor spleen cells (Zhang and Bok 1998). Despite the lack of lymphocytes, Zhang and Bok (1998) concluded that systemic immunity to subretinal RPE allograft was the cause of delayed loss of RPE function.

Cow, pig and human donor RPEs have also been xenotransplanted into rat eyes. Although cryopreserved bovine RPE was not rejected in rat subretinal space at 3 months (Durlu and Tamai 1997), fresh porcine RPE was rejected by 2 months after grafting (Grisanti *et al.* 2002). The rejection process was accompanied by loss of outer nuclear layer thickness and infiltration of pigment-loaded, ED1-positive cells. These were probably resident macrophages from within the retina (Grisanti *et al.* 2002). Interestingly, there was no lymphocytic infiltration and the same graft was rejected when placed in subcutaneous tissue by a DTH response. Abe *et al.* (1999) demonstrated increased expression of interleukin 1 and 6 by xenografting cultured human RPE into rats. However, it is still not known what role these interleukins may play in immune rejection. Spontaneously immortalised human RPE cell line, ARPE-19 have also been shown to maintain outer nuclear layer and cortical visual function beyond 6 months in immunosuppressed RCS rats (Coffey *et al.* 2002). Inner retinal changes in the natural history of RCS rats have also been arrest for up to 10 months of age by early xenograft of ARPE-19 cells (Wang *et al.* 2005b). However, McGill *et al.* (2004) found that despite rescue of spatial vision in RCS rats by ARPE-19 cells, there is still gradual decline in vision which may be due to intrinsic properties of the graft or immune rejection. More recently, Wang *et al.* (2005b) demonstrated that ARPE-19 cells were

rapidly lost in the subretinal space of immunosuppressed RCS rats with only one fifth of the cells injected detectable in the subretinal space at 2 weeks. By 28 weeks, only 0.2% of the cells remained in the subretinal space. The mismatch between the declining number of grafted ARPE-19 cell and the persistence of anatomical and functional rescue raised the possibility that diffusible factors may be primarily responsible for the action of transplanted RPE (Wang *et al.* 2005b). Furthermore, degree of visual rescue cannot be used as a measure of graft survival.

#### 2.2.4.2 RPE grafts into rabbits and cats hosts

Rabbit models have also been used extensively to study immune rejection of RPE grafts. Activated and non-activated RPE allograft from pigmented to albino New Zealand rabbits are both associated with increased level of interleukin 6 in the vitreous during the first 2 weeks (Enzmann *et al.* 2000). Although the relationship between interleukin 6 and RPE graft rejection is unknown, serum interleukin 6 levels have been measured for identifying early local inflammatory reactions after liver transplantation (Kunz *et al.* 1998). Crafoord *et al.* (1999) showed that the RPE allograft rejection at 6 months in New Zealand white rabbits was characterised by dispersion of the melanin pigment in the subretinal space and throughout the neuroretina, phagocytosis of pigment by macrophage, Muller glial cells and host RPE, absence of lymphocyte, loss of the adjacent photoreceptor outer and inner segments, and reduced thickness of outer nuclear layer. Immunosuppression of these rabbits with cyclosporine did not prevent or reduce this inflammatory response (Crafoord *et al.* 2000). A more rapid rejection of porcine fetal RPE xenograft in rabbits was described by Del Priore *et al.* (2003a) with around 10% of the grafted cells detectable at 12 weeks even with triple immunosuppression using prednisone, cyclosporine-A and azathioprine. Similar to allograft rejection, porcine xenograft elicited a macrophage response in the absence of lymphocytes. There was also no vascular leakage on fluorescein angiography during rejection. Human fetal RPE xenograft transplanted as a monolayer sheet (Sheng *et al.* 1995) or cell suspension (He *et al.* 1993; Gabrielian *et al.* 1999b; Lai *et al.* 1999) into rabbits also induced macrophage migration within 1 to 3 months. Gabrielian *et al.* (1999b) demonstrated initial retinal glial cell response within the first 2 weeks at the site of human fetal xenograft and around the retinotomy. By 3 weeks, donor cell number has significantly reduced and by 4 weeks, both retina and choroid were involved in inflammatory response dominated by macrophages. In green fluorescent protein (GFP)-labelled human RPE xenograft to rabbits, local immunosuppression with intravitreal

cyclosporine delayed rejection (Lai *et al.* 2000). The use of intravitreal tacrolimus resulted in survival of cultured adult human RPE xenograft in rabbits for up to 1 year (Wang *et al.* 2002). Human fetal RPE on collagen, fibrinogen or biodegradable polymer as substrates induced choroidal inflammatory response when xenografted into rabbits. (Bhatt *et al.* 1994; Oganessian *et al.* 1999; Rezai *et al.* 2000). A short-term follow up study (7 days) in feline RPE allograft did not reveal any rejection (Wang *et al.* 2004).

#### 2.2.4.3 RPE grafts into pigs and monkeys hosts

Porcine RPE allograft induced infiltration of macrophage in the subretinal space of non-immunosuppressed pigs by 9 days but the graft was not rejected at 3 months (Del Priore *et al.* 2004). The authors suggested that these macrophages migrated into the subretinal space to clear the cell debris from degenerated RPE which did not have the opportunity to attach to the BM. Human fetal RPE xenograft to non-immunosuppressed monkeys have revealed 30% to 60% rate of rejection depending on the site of graft (Berglin *et al.* 1997). Interestingly, foveal grafts were rejected more often than extramacular grafts and rejection occurred in one subretinal location and not in another of the same or contralateral eye (Berglin *et al.* 1997).

#### 2.2.4.4 Approaches to reduce immune rejection

The role of the host immune system in limiting the success of allogeneic or xenogeneic transplants cannot be overemphasized and graft rejection remains a major obstacle to successful RPE transplantation. Modification of the donor cell to reduce its immunogenicity and immune modulation of the host animal may minimise graft loss due to rejection. Factors that may influence rejection includes histocompatibility matching (Zhang and Bok 1998), culture and cryopreservation of donor cells (Durlu and Tamai 1997; Valtink *et al.* 1999a), cytokine-induced immune activation of the donor RPE (Kohen *et al.* 1997; Enzmann *et al.* 2000), donor RPE cell transfection with genes expressing immunosuppressive cytokines (Enzmann *et al.* 2001b), graft tissue architecture as a monolayer sheet or a cell suspension (Wenkel and Streilein 2000), type of substrate used to support the tissue (Bhatt *et al.* 1994; Gabrielian *et al.* 1999a; Rezai *et al.* 2000; Kiilgaard *et al.* 2002), break down in blood-retinal barrier due to disease and surgery (Wenkel and Streilein 1998), local or systemic immunosuppression (Crafoord *et al.* 1999; Lai *et al.* 2000; Lund *et al.* 2001a; Wang *et al.* 2002; Del Priore *et al.* 2003a) and donor-specific challenge (Jiang *et al.* 1994).

### 2.2.5 The effect of RPE transplant on retina and choroid

The aim of RPE transplantation is to retard or restore visual loss. This is primarily achieved through restoration of photoreceptor cell function although there may be indirect beneficial effect through choroidal and retinal circulations. The Royal College of Surgeons (RCS) rat, an animal model of RPE dystrophy (Mullen and Lavail 1976), has been used extensively for *in vivo* experiments to demonstrate the prove of principle and mechanism of visual rescue in RPE transplantation. This dystrophic strain of rat has a recessive defect in the *merTK* gene (D'Cruz *et al.* 2000) which results in failure of RPE to phagocytose shed rod outer segments (Bok and Hall 1971). The consequences of this mutation include accumulation of subretinal debris, death of rod and later cone photoreceptor cells, secondary inner retinal degeneration, retinal vascular changes and central adaptive modulation in neural circuit. Each of these secondary changes has been shown to be prevented or reversed by RPE transplantation in the RCS rat (see **Figure 2.3**) (Li and Turner 1988a; Seaton *et al.* 1994; Lund *et al.* 2001a; Coffey *et al.* 2002; Wang *et al.* 2005a).

#### 2.2.4.1 Photoreceptor cell rescue

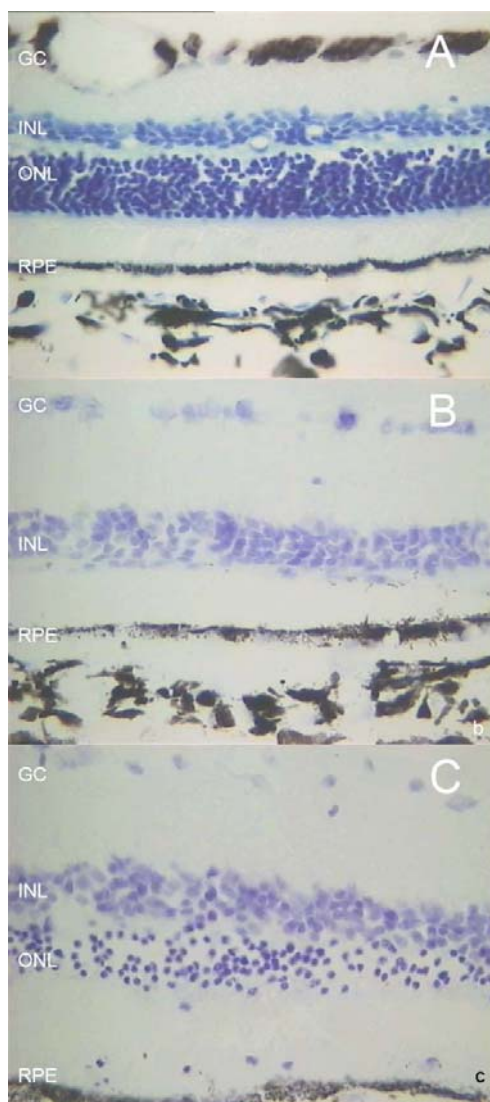
The first subretinal RPE grafts in RCS rats demonstrated preservation of the thickness of the outer nuclear layer, outer plexiform layer, and outer and inner segments of the photoreceptors (Li and Turner 1988a). Further more, the outer segment debris zone was reduced with increased number of phagosomes in the transplanted RPE cells (Li and Turner 1988a; Lopez *et al.* 1989). These rescued photoreceptor cells regenerated outer segments at normal rate (Lavail *et al.* 1992; Lin *et al.* 1996), expressed visual pigment, membrane  $\text{Na}^+/\text{K}^+$  ATPase (Sheedlo *et al.* 1989b) and two synaptic components in the plexiform layers (Sheedlo *et al.* 1993a) and the outer segments were surrounded by the interphotoreceptor matrix (Lavail *et al.* 1992). Similar but much more transient photoreceptor rescue was seen after subretinal injection of saline (Silverman and Hughes 1990; Li and Turner 1991; Faktorovich *et al.* 1990).

Despite histological evidence of rescued photoreceptors with the necessary components for phototransduction, initial attempts at full-field electroretinography (ERG) failed to detect any corneal or vitreal responses to light stimulus after RPE graft (Gouras *et al.* 1989; Yamamoto *et al.* 1993). These findings may be due to inadequate number of grafted RPE cells and hence rescued photoreceptors to generate a full field response. A later study was able to demonstrate corneal ERG response in RCS rats that



had received RPE graft as small sheets in a larger area of subretinal space (Jiang and Hamasaki 1994). Corneal ERG after RPE transplantation in RCS rats has since been reported by another group (Sauve *et al.* 2004; Pinilla *et al.* 2005; Sauve *et al.* 2006). These reports demonstrated a correlation between b-wave amplitude and field area rescued (Sauve *et al.* 2004), and the relationship between cone/rod ratio in the b-wave and the number of cone rescued (Pinilla *et al.* 2005). Light- and dark-adaptation study of collicular sensitivity demonstrated that only the cone threshold was prevented from deterioration after RPE graft (Girman *et al.* 2005).

The disparity between anatomical (Coffey *et al.* 2002) and functional (Girman *et al.* 2005) rod rescue raises intriguing questions regarding photoreceptor-donor RPE interaction (see below). One explanation for the lack of rod rescue is that cones are able to depend on Muller cells to recycle visual pigments (Mata *et al.* 2002) and hence are less dependent on RPE function (Girman *et al.* 2005).



**Figure 2.3 Photoreceptor rescue in the RCS rat model**

(A) Histology of retinal architecture in non-dystrophic rat, (B) RCS dystrophic rat with sham subretinal injection showing no significant rescue of outer nuclear layer (ONL) and (C) hRPE7 transplantation showing rescue of the outer nuclear layer (Courtesy of Dr David Keegan). Ganglion cell (GC) and inner nuclear layers (INL) and the retinal pigment epithelium (RPE) are seen in all three slides.

#### 2.2.4.2 Visual pathway rescue

The function of the post photoreceptor visual pathway after RPE transplantation has been evaluated by electrophysiological and psychophysical measurements. Intraretinal and ganglion cell electrode recording by Yamamoto *et al.* (1993) demonstrated evidence of activity in bipolar and ganglion cells in response to light in the region of retina adjacent to the graft. Relative retinal sensitivity in the area of graft preservation has also been examined by electrode recording of single- and multi-unit receptive fields over the surface of the superior colliculus of RCS rats that received subretinal RPE allograft. The central to peripheral field loss in RCS rats was shown to be limited by subretinal RPE allograft (Sauve *et al.* 1998) and xenograft from immortalised human RPE cell lines (Lund *et al.* 2001a; Sauve *et al.* 2002). Electrophysiological preservation of central visual pathway by RPE xenograft has been correlated with changes in retinal morphology (i.e. outer nuclear layer rescue, see **Figure 2.4**) and full-field ERG in the RCS rats (Lund *et al.* 2001a; Sauve *et al.* 2002; Sauve *et al.* 2004). In RCS rats that received spontaneously or trans-genetically modified human RPE xenograft with extended life span, single-unit electrophysiological responses to light stimuli have also been recorded in the primary visual cortex, area 17 (Coffey *et al.* 2002). The ability of these neurons in tuning into a range of specific stimulus parameters such as orientation, direction of movement, contrast sensitivity, spatial and temporal frequencies and complex centre-surround interactions, similar to those found in the normal rats, confirms the ability of human RPE to restore complex visual function in RCS rats (Coffey *et al.* 2002; Girman *et al.* 2003).

Non-invasive psychophysical testing, ranging from simple visual reflexes to complex visual tasks, have been used to assess the integrity of the visual system after RPE graft. Whiteley *et al.* (1996) demonstrated some but incomplete preservation of pupillary light reflexes. By using a water escape paradigm, Little *et al.* (1998) demonstrated that RCS rats that received human fetal RPE had shorter swimming pathway and time, implying an ability to see and use light as a clue for finding the escape platform. Visual acuity testing by optokinetic head-tracking to moving stripes and two-choice pattern discrimination test of vertical and horizontal stripes has also demonstrated the ability of immortalised RPE xenograft in preserving cortical visual functions for long durations (Lund *et al.* 2001a; Coffey *et al.* 2002) (see **Figure 2.5**). Using the visual water task under high luminance to measure grating acuity, (McGill *et al.* 2004) have also demonstrated the ability of ARPE19 subretinal graft in preserving cone mediated vision in these RCS rats.

#### 2.2.4.3 Effects on retinal and choroidal vasculature

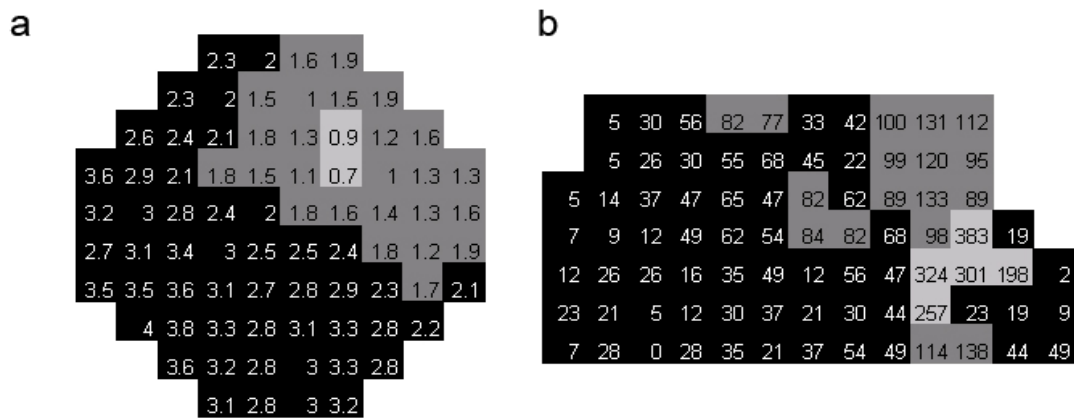
The effects of RPE grafts extend beyond retinal and visual pathways. Seaton and colleagues (1992) demonstrated that implanted RPE cells can maintain the density and architecture of the deep retinal vasculature. Further more, in animals that had lost photoreceptors already, RPE graft not only prevented but also induced involution of retinal neovascularisation (Seaton *et al.* 1994). In a rabbit model of RPE autograft, Majji and De Juan E Jr (2000) demonstrated the ability of autotransplanted RPE suspension in maintaining choriocapillaris as well as photoreceptors. It was concluded that formation of a monolayer on healthy Bruch's membrane was essential for maintaining the differentiated state of RPE and preserving adjacent choriocapillaris and photoreceptors.

#### 2.2.4.4 Mechanisms of retinal function rescue

Although the mechanism of photoreceptor rescue by donor RPE is unknown, evidence points toward two types of interaction: (1) direct contact between RPE and photoreceptors or (2) indirect interaction through diffusible factors released by donor RPE. Electron microscopic studies suggested cell contact as a requirement for photoreceptor rescue (Lavail *et al.* 1992). Reduced outer segment debris zone in RCS rats correlated with increased phagocytic activity of the donor RPE (Li and Turner 1988a; Gouras *et al.* 1989). On the other hand, evidence of rescue extending beyond the grafted area (Lin *et al.* 1996; Sauve *et al.* 2002), photoreceptor rescue by basic fibroblast growth factor (bFGF) (Faktorovich *et al.* 1990), intravitreal RPE graft (Castillo, Jr. *et al.* 1997) and Schwann cell grafts (Lawrence *et al.* 2000; Wang *et al.* 2005b) suggest that diffusible factors such as ciliary neurotrophic factor (CNTF), glial cell line-derived neurotrophic factor (GDNF), brain-derived neurotrophic factor (BDNF) or bFGF, may be involved in cell rescue.

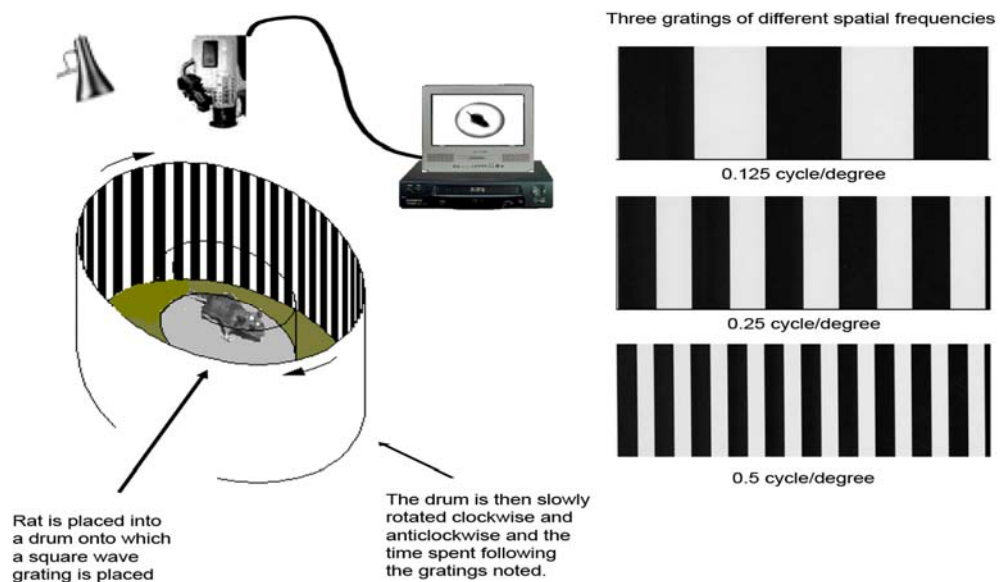
Variables that have been shown to positively affect the rescue of photoreceptors following RPE allograft transplantation include younger donor age (Sheedlo *et al.* 1993b), higher number of donor cells and fresh rather than cultured cells (Li and Turner 1991). Durlu and Tamai (1997) demonstrated photoreceptor rescue in RCS rats receiving cryopreserved bovine RPE xenograft. Fresh human fetal (Little *et al.* 1996), juvenile or adult (Castillo, Jr. *et al.* 1997) RPE as a xenograft has been shown to support photoreceptor survival and visual function (Little *et al.* 1998). Both spontaneously immortalised RPE and genetically modified RPE with extended lifespan have the ability to restore visual field and cortical visual function (Lund *et al.* 2001a). Although efficacy

of xenogeneic RPE grafts has been well documented, there has been no study which directly compares the efficacy of allogeneic to xenogeneic RPE grafts.



**Figure 2.4 Functional rescue after RPE graft in the RCS rat**

A comparison of retinal sensitivity and histological maps following ARPE-19 transplantation in a dystrophic RCS rat. The figure shows (a) the retinal sensitivity map from electrode recording at the superior colliculus and (b) the corresponding outer nuclear layer cell count in the retina. The grey scale coding indicates the corresponding retinal and superior collicular areas. The highest sensitivity correlates to the area of ARPE-19 transplantation (Courtesy of Professor Pete Coffey).



**Figure 2.5 Optokinetic reflex testing in rats**

A diagram showing the various aspects of visual acuity testing based on the optokinetic reflex. A rotating drum is used with three different square-wave grating frequencies. The animal is placed inside the rotating drum which stimulates head turning in the test animal. The highest frequency grating that stimulates head turning indicates the visual acuity (Courtesy of Professor Pete Coffey).

Genes introduced into the donor RPE prior to transplantation have been shown to be expressed in the subretinal space (Osusky *et al.* 1995; Dunaief *et al.* 1995; Lai *et al.* 1999; Lai *et al.* 2000; Saigo *et al.* 2004; Abe *et al.* 2005). For example, Abe and colleagues (2005) demonstrated that BDNF-transfected RPE grafts resulted in significant photoreceptor rescue in both grafted and non-grafted areas. Genetically transduced donor RPE may serve as a vehicle for genetic therapy in addition to cellular therapy in retinal degeneration (Ogata *et al.* 1999).

### **2.2.6 Long-term outcomes**

Animal experiments of RPE graft have not consistently demonstrated sustained rescue of photoreceptors and visual function. Delayed decline in visual function after RPE graft may be due to a combination of three mechanisms: (1) changes in the post-photoreceptor visual pathway independent of photoreceptor rescue, (2) photoreceptor dysfunction or degeneration independent of RPE graft function or survival, and (3) dysfunction or loss of donor RPE cells.

Progressive degenerative and reactive changes in the bipolar, horizontal, amacrine, ganglion and Muller glial cells, neuronal migration and retinal neovascularisation were prevented and reversed by RPE graft in RCS rats for 9 months (Wang *et al.* 2005a). Further down stream, cortically mediated vision and visual responsiveness in the superior colliculus have remained comparable to normal controls even when RPE graft did not restore the complete complement of photoreceptors in RCS rats (Sauve *et al.* 2002; Coffey *et al.* 2002). Also, delayed loss of photoreceptor has not been reported to occur when the donor RPE remains present in RCS rats. These findings suggest that donor RPE loss is the major cause of late-onset visual loss.

As discussed in **Section 2.2.4**, immunological rejection of RPE xenograft may occur in rat and rabbit models within weeks. However, photoreceptor rescue in rats was found in areas without donor RPE and was extended for long durations even when a minority of donor cells survived (see **Figure 2.1**). The mechanism for this may be related to the indirect rescue effect described in **section 2.2.5**. However, ultimately, retinal function will decline as the entire population of donor cells are lost to rejection. Currently, immune response poses a major obstacle to the long-term survival of the donor RPE.

### **2.2.7 Summary of animal experiments**

The preceding literature review has provided evidence that RPE transplantation can rescue retinal function based on the structural and functional outcomes in the RCS rat. However, many questions remain. Although the superiority of phenotypic features of stem cell derived RPE over immortalised RPE cell lines has been shown *in vitro*, we do not know if this can be translated into its ability to rescue photoreceptor *in vivo*. Furthermore, despite demonstration of proof of principle using subretinal injection of RPE cell suspension in rat eye; this delivery technique is not clinically useful due to absence of healthy BM in various retinal diseases. Further studies in feasibility and safety of RPE patch graft delivery are required as there is currently only 1 study using patch graft in a large animal model (Del Priore *et al.* 2004).

### **2.3 Human Trials in RPE Transplantation**

Since the first case report of human homologous and autologous RPE transplantation for the treatment of neovascular AMD (Peyman *et al.* 1991), several other techniques of RPE translocation or transplantation have been published (see **Table 2.3**). The major milestones in the development of the techniques of human RPE transplantation are summarised in the timeline in **Figure 2.6**. Most of the human trials have involved patients with neovascular AMD since there is evidence to support that loss of the RPE occurs during and after excision of CNV (Del Priore *et al.* 2006); these are the demonstration of RPE cells on surgically removed CNV (Lopez *et al.* 1991; Grossniklaus *et al.* 1994; Nasir *et al.* 1997), the failure of spontaneous RPE repopulation to resurface the excision bed adequately (Hsu *et al.* 1995; Rosa *et al.* 1996) and enlarging RPE defect months after surgical excision of CNV (MacLaren and Aylward 2005). The corollary of this, that RPE reconstruction under the macula restores vision, has also been shown. The most compelling evidence is from the data on clinical outcome following macular translocation.

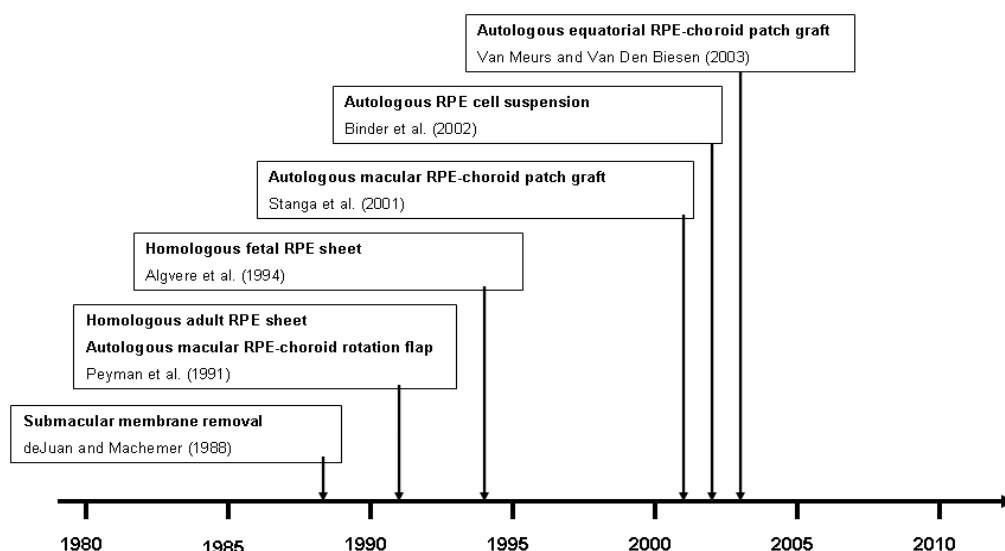
#### **2.3.1 Proof of principle**

Although macular translocation with 360° retinotomy for neovascular AMD (Machemer and Steinhorst 1993) is not strictly RPE transplantation, it is functionally similar; by virtue of moving the neural retina, the RPE-choroid that comes to lie under the fovea is different and can be viewed as essentially transplanted. There is now an extensive

literature showing reversal of VA loss, restoration of reading ability and improvement in health-related quality of life (QOL) within 1 year following translocation surgery in neovascular AMD (Pertile and Claes 2002; Lai *et al.* 2002; Aisenbrey *et al.* 2002; Mruthyunjaya *et al.* 2004; Fujikado *et al.* 2002; Toth *et al.* 2004; Cahill *et al.* 2005b) and in myopic CNV (Fujikado *et al.* 2001; Sawa *et al.* 2008). However, visual rescue in the long-term may not be sustained (Aisenbrey *et al.* 2007; Baer *et al.* 2008). Despite the uncertain long-term outcome, translocation still represents a gold standard of retinal rescue to which RPE transplant needs to be compared to. This review of human RPE transplantation will (1) identify the source of donor RPE used, (2) explore the key issues in case selection, (3) describe the various surgical techniques (see **Table 2.3**), (4) discuss general issues of post-operative care and complication, and (5) summarise the outcomes of RPE graft, i.e. graft survival and visual function.

### 2.3.2 Source of donor cells

Both allogeneic and autologous RPE cells have been used in human transplantation. Early studies of allogeneic adult or fetal RPE graft had poor functional outcome due to graft rejection and fibrosis despite immunosuppression (Peyman *et al.* 1991; Algvere *et al.* 1999; Weisz *et al.* 1999). However, Tezel and colleagues showed that allogeneic adult RPE sheet encased in gelatine survived for 12 months when triple immunosuppression was given for 6 months post-operatively (Tezel *et al.* 2007).



**Figure 2.6 RPE transplantation surgical techniques**

This figure shows a timeline (from year 1980 to 2010) showing the development of human RPE transplantation techniques in relation to the first submacular surgery reported in 1988. In the early 1990's, allogeneic RPE grafts were used and later, throughout early 2000's, various techniques of autologous RPE grafts were described.

**Table 2.3 Publications of allogeneic and autologous RPE transplantation in human**

Techniques	Publications	Number of cases reported	
		Neovascular AMD	Atrophic Disease
<b>Allogeneic adult RPE</b>	Peyman <i>et al.</i> (1991)	1	0
	Del Priore <i>et al.</i> (2001), Tezel <i>et al.</i> (2007)*	1, 12	0
	Valtink <i>et al.</i> (1999b)	7	0
<b>Allogeneic fetal RPE</b>	Algvere <i>et al.</i> (1994; 1996; 1997; 1999)*	5, 5, 5, 7	0, 8, 8, 9
	Weisz <i>et al.</i> (1999)	0	1
<b>Autologous macular RPE-choroid patch graft</b>	Peyman <i>et al.</i> (1991)	1	0
	Stanga <i>et al.</i> (2002), MacLaren <i>et al.</i> (2005)*	9, 4	0, 0, 0
	Yepez and Arevalo (2003)	5	0
	Angunawela <i>et al.</i> (2005)	1	0
<b>Autologous RPE cell suspension graft</b>	Binder <i>et al.</i> (2002; 2004)	14, 39	0, 0
	van Meurs <i>et al.</i> (2004)	7	0
	Krebs <i>et al.</i> (2008)	68	0
<b>Autologous equatorial RPE-choroid patch graft with paramacular retintomy</b>	van Meurs and Van Den Biesen (2003)	6	0
	Maaijwee <i>et al.</i> (2007a; 2008a; 2008c; 2008d)*	83, 6, 48, 31	0, 0, 0, 0
	Bindewald <i>et al.</i> (2004)	1	0
	Joussen <i>et al.</i> (2006)	42	3
	Heussen <i>et al.</i> (2008)	30	0
	Joeres <i>et al.</i> (2008)	29	0
	Treumer <i>et al.</i> (2007a; 2007b)*	9, 9	1, 1
	MacLaren <i>et al.</i> (2007)	12	0
	Joussen <i>et al.</i> (2007), Caramoay <i>et al.</i> (2010)*	0	12, 10
Chen <i>et al.</i> (2008)	0	5	
<b>Autologous large RPE-choroid patch graft with peripheral 180° retinotomy</b>	van Meurs (2005)	NR	0
	Petersen <i>et al.</i> (2008)	12	0
	Ma <i>et al.</i> (2009)	21	0
	Gibran <i>et al.</i> (2009)	4	0
	Cereda <i>et al.</i> (2010)	13	0
	Degenring <i>et al.</i> (2010)	12	0

NR; not reported

\*same senior author, possibly the same patients with longer follow-up

The use of autologous RPE for maculoplasty avoids the issue of immune rejection. However, this approach is based on the assumption that the RPE away from the lesion is healthy and unaffected by the macular disease process. However, psychophysical, histological and epidemiological observations suggest that pathology of neovascular AMD may extend beyond the macula (Brown *et al.* 1986; Green and Enger 1993; Knudtson *et al.* 2004). More recently, the association between AMD and systemic complement factor dysfunction provides further evidence that disease process in AMD may be more widespread (Scholl *et al.* 2008). A more obvious concern for donor RPE health is in the treatment of atrophic macular disease. Studies have found frequent peripheral reticular degeneration of the RPE in patients with atrophic AMD (Lewis *et al.* 1985; Sunness *et al.* 1999b). Furthermore, patients with AMD may also have full



field ERG abnormality, suggesting generalised photoreceptor cell dysfunction (i.e. a retinal dystrophy with macular involvement) and abnormal peripheral RPE (Michaelides *et al.* 2005). This raises the question of whether autologous macular, paramacular or even equatorial RPE should be used as a source of donor cells for maculoplasty in eyes affected by AMD and IMD. Several long term studies which examined donor RPE function following the use of macular, paramacular and equatorial sources of RPE may provide clues on whether autologous sources are suitable.

MacLaren *et al.* (2005) reported long-term survival of macular RPE-choroid graft in 4 patients although they had loss of fixation and autofluorescence signal over the grafts after 5 years. Although the authors concluded that delayed loss of photoreceptors may account for the poor long term outcome, RPE dysfunction cannot be excluded. This is a likely possibility since the donor RPE is from the macular region, the site of pathology in AMD. Van Meurs and Van Den Biesen (2003) described a modified technique in which equatorial RPE-choroid was used to reconstruct submacular RPE defect. The same group reported slightly higher rate of vision stabilization and improvement after RPE graft in the 11 patients who were followed for 4 years (Maaijwee *et al.* 2007a). Reports of long-term outcomes after macular translocation, which uses paramacular RPE, are conflicting. Baer *et al.* (2008) reported no de novo drusen, atrophy or de novo CNV under the translocated fovea after 2 years in 56 patients. Aisenbrey *et al.* (2007) showed visual decline from de novo GA under the translocated fovea in 25 of 90 patients after a mean follow up of 38 months. Another complicating issue is that atrophic retina may also induce atrophy of the underlying RPE as shown in long term outcomes of macular translocation for the treatment of GA (Cahill *et al.* 2005a). Therefore, it remains to be determined if paramacular and equatorial RPE are equally capable of maintaining macular photoreceptor cell function. This issue will be explored further in **Chapter 5** of this thesis where the long term outcome of autologous RPE-choroid patch graft is compared to that of macular translocation in neovascular AMD.

The enthusiasm of allogeneic RPE grafts in the last decade has been overtaken by the promising long term outcomes of autologous RPE grafts. However, the technique of translocating autologous equatorial RPE-choroid patch to the macula has not gained widespread acceptance. One limitation of this approach is the complex surgical steps required in harvesting equatorial RPE. The use of immortalised RPE cell lines (such as ARPE19 or D407) or RPE derived from stem cells (such as ES or iPS cells) will avoid

this extra surgical step. However, these cell sources have not yet been used in human clinical trials.

### **2.3.3 Patient selection for RPE transplantation**

RPE transplantation has been performed in both neovascular and atrophic macular diseases and the key issues in case selection will be discussed separately for each indication. However, for both, the health of equatorial or peripheral retina-RPE-choroid will also need to be considered when planning autologous RPE graft.

#### **2.3.3.1. Neovascular macular disease**

As stated earlier, the vast majority of RPE transplantation in human has been performed for the purpose of restoration of RPE-Bruch's membrane-choriocapillaris complex defect created by surgical removal of CNV in AMD. As these grafts were performed at a time when the only treatment available were laser photocoagulation and PDT, common inclusion criteria used were large subfoveal occult or minimally classic CNV, pigment epithelial detachment (PED), RPE rip (Maaijwee *et al.* 2008a), large submacular haemorrhage (Gibran *et al.* 2009), retinal angiomatous proliferation (RAP) (Krebs *et al.* 2008) or any lesions that failed to respond to PDT or laser. Even with the promising result from the use of anti-VEGF agents in neovascular AMD (Gragoudas *et al.* 2004; Brown *et al.* 2006; Rosenfeld *et al.* 2006; Brown *et al.* 2009), surgical removal of CNV and RPE transplantation remains an option for patients who are losing vision despite anti-VEGF therapy or have AMD lesion subtypes that makes them ineligible for receiving anti-VEGF therapy. To date, only 1 case of CNV secondary to presumed ocular histoplasmosis syndrome has received RPE transplantation following CNV removal (van Meurs *et al.* 2004). Preoperative factors that may influence patient selection include duration of symptoms, foveal function, lesion size and subtypes and status of the donor RPE in the same eye in autologous grafts (see above).

From the 2 largest series of RPE transplantation using autologous equatorial RPE-choroid grafts, visual outcome was found to be unrelated to duration of disease and baseline VA (Joussen *et al.* 2006; Maaijwee *et al.* 2007a). This may be due to error in patient recollection of the duration of symptom, poor relationship between VA and potential photoreceptor cell reserve and lack of power from the small sample size in these series. In contrast, shorter symptom duration, better pre-operative fixation stability have been shown to predict favourable outcome in patients undergoing macular translocation (Fujii *et al.* 2002b; Uppal *et al.* 2007). Since RPE graft is similar to

macular translocation in that both are rescue procedures, most clinicians would presume that once foveal photoreceptor cells are lost as indicated by the presence of subfoveal RPE atrophy or disciform scar, RPE transplantation would not be beneficial in restoring high quality central vision unless it is combined with photoreceptor cell replacement.

The 2 large series of autologous RPE-choroid grafts, however, found that lesion subtypes may predict visual outcome. Jousseaume and colleagues (2006) reported that classic, occult and massive subretinal haemorrhage tends to have better visual outcome than vascularised PED or RAP lesions. In contrast, Maaijwee and colleagues showed that patients with predominantly classic and occult lesions had significantly better postoperative VA at 1 year than those with minimally classic or hemorrhagic ( $\geq 50\%$  blood) lesions. This lack of consistency may be due to inadequate power from the small sample size and other confounding factors such as health of equatorial RPE-choroid and intraoperative trauma (Maaijwee *et al.* 2008c). In theory, classic CNV with recent visual decline would imply healthier and greater reserve of foveal photoreceptors for rescue by RPE transplantation and hence better outcome.

Two other lesion subtypes of neovascular AMD may also need to be identified during case selection as they will have impact on surgical approach. CNV membranectomy in RAP may lead to macular hole and haemorrhage due to strong adhesion between the retina and CNV tissue due to the retino-choroidal anastomotic vessel (Shimada *et al.* 2005; MacLaren *et al.* 2007; Krebs *et al.* 2008). Idiopathic polypoidal choroidal vasculopathy (IPCV) may not be suitable for autologous RPE-choroid graft because equatorial choroid may also be affected by the subRPE and intra-choroidal vascular abnormalities (Yannuzzi *et al.* 1998).

#### 2.3.3.2. Atrophic macular disease

Atrophic macular disease is a heterogeneous group of disorder which can be inherited, acquired or both. The most common cause is AMD whereas in younger patients, either retinal or macular dystrophy may result in macular dysfunction and subsequent atrophy (Holder 2001). Regardless of underlying aetiology, most atrophic macular diseases are characterised by bilateral progressive and irreversible central visual loss. Although their presentations can be asymmetrical, with loss of vision in one eye followed by the second eye many months or years later, the ultimate VA tends to be similar in both eyes. The exact pathophysiology of GA in AMD and IMD are unknown. However, in a subset of dystrophies, linkage to several genes expressed in the photoreceptor cells suggest a possible sequence of event: abnormal outer segments and their interaction with retinal

pigment epithelial (RPE) cells leading to RPE cell death with subsequent choriocapillaris atrophy and photoreceptor cell loss (Kaplan *et al.* 1993; Allikmets *et al.* 1997; Hoyng *et al.* 1996; Felbor *et al.* 1997). In some of these patients, the macular lesion may resemble GA secondary to AMD, where photoreceptor cell loss is also thought to be due to either primary RPE cell death or impaired choroidal perfusion (Sakamoto *et al.* 1995; Friedman *et al.* 1995; McLeod *et al.* 2002).

There is currently no effective treatment for patients with atrophic macular disease although allogeneic and autologous RPE transplantation have been performed in atrophic AMD (Gouras and Algvere 1996; Algvere *et al.* 1999; Jousseaume *et al.* 2006; 2007) and macular translocation, which in principal is a form of RPE reconstitution, has been performed in a patient with adult vitelliform macular dystrophy with limited improvement in reading ability postoperatively (Eckardt *et al.* 2004). Optimal timing for intervention in atrophic macular disease remains controversial because: (1) progression is slow, (2) endpoint is difficult to define, (3) there is an unknown risk to benefit ratio of the procedure and (4) late stage diseases may not benefit from a photoreceptor rescue approach. Previous trials of RPE transplantation for atrophic AMD have used VA (Algvere *et al.* 1997) or loss of reading (newspaper print size) ability (Jousseaume *et al.* 2007) as inclusion/exclusion criteria. Using VA as an end point, Jousseaume and colleagues (2007) reported high rate of VA loss despite survival of the graft.

As there is lack of literature regarding RPE transplantation in atrophic macular diseases, this thesis will examine, in a clinical trial, the use of autologous equatorial RPE-choroid graft in these conditions. In particular, microperimetry outcomes will be used to determine if grafted RPE is able to maintain retinal function.

### **2.3.4 Surgical techniques**

Autologous RPE transplantation requires a more complex procedure than allogeneic RPE graft due to the extra surgical steps in harvesting donor cells within the same eye. The following sections will review the current surgical techniques, beginning with general issues in donor cell harvesting and preparation of the submacular space. Then the specific details of allogeneic and autologous RPE grafting techniques will be discussed separately.

#### **2.3.4.1. Donor cell and submacular space preparation**

Allogeneic RPE grafts harvested from both human adult and fetus have been delivered as sheet, or microaggregate in patients with neovascular or atrophic AMD. Peyman

(1991) described harvesting technique of donor RPE sheet from a fresh adult globe enucleated for severe eye trauma. RPE allograft has also been harvested as sheets from fetus of 13 to 20 weeks of gestation by dissection and maintained in tissue culture for 2-7 days (Algvere *et al.* 1994; Gouras *et al.* 1994). Fresh fetal RPE in the form of microaggregate in suspension (Gouras and Algvere 1996; Algvere *et al.* 1997) or sheet in small fragments (Castillo, Jr. *et al.* 1995; Weisz *et al.* 1999) also been prepared and transplanted into patients with AMD. Adult cadaveric (death to enucleation time of 7.5 hours) RPE has been harvested, treated with dispase, encased in porcine gelatin matrix on its basal surface for transplantation within 24 hours of gelatin solidification (Tezel *et al.* 1997; Del Priore *et al.* 2001). Over 99% of the RPE cells on the gelatin matrix were confirmed to be viable with a calcein and ethidium homodimer based assay (Del Priore *et al.* 2001). In contrast, cultured, HLA-typed, cadaveric RPE that have been stored through cryopreservation, have also been transplanted (Valtink *et al.* 1999a). At least 461 cell cultures have been prepared and 116 fully typed and well-differentiated cell cultures are stored in the cell bank set up by Valtink *et al.* (1999a).

In order to harvest autologous cells for RPE transplantation, it is important to have access to the donor cells by ensuring good visibility and clearance of vitreous gel around the harvesting site. Visibility can be optimised by removing any lenticular or vitreous opacity. Phacoemulsification and intraocular lens implant can be performed at the time of RPE transplantation (Binder *et al.* 2002; 2004). Chandelier or infusion line light sources allow bimanual manipulation of the graft. Separation of the posterior hyaloid from retina often needs to be induced in eyes with AMD (van Meurs 2005). The peripheral vitreous base may need to be thoroughly shaved to minimise the impact of anterior proliferative vitreoretinopathy (PVR). Peeling of epiretinal membrane and internal limiting membrane prior to membrane extraction have also been reported. This may prevent posterior PVR (or epiretinal membrane) and re-opening of the retinotomy. Four techniques of autologous RPE transplantation have been described (see **Figure 2.6**): submacular RPE-choroid pedicled flap rotation (Peyman *et al.* 1991), submacular RPE-choroid free graft transposition (Stanga *et al.* 2001a), submacular injection of suspension of RPE cells from the peripheral fundus (Binder *et al.* 2002), and translocation of equatorial RPE-choroid patch graft to submacular space (van Meurs and Van Den Biesen 2003).

The technique of submacular CNV removal is based on that described by Thomas and Kaplan (1991) and Thomas *et al.* (1994). Variations of this technique of CNV removal have also been described to allow easier access to the submacular space.

Peyman and co-workers (1991) described submacular CNV removal with RPE transplantation through a 250-degree (8 to 9-clock-hour) arc retinotomy just outside the temporal arcades. Following membrane removal, 1 patient received autologous pedicled RPE flap rotation and another had allogeneic RPE patch transplantation. Yopez and Arevalo (2003) described a technique involving inferior 140-degree (4 to 5-clock-hour) peripheral retinotomy for access to submacular RPE. van Meurs (2005) advocated a temporal 10 clock-hour retinotomy at the ora serrata (flap-over approach) for removal of massive subretinal haemorrhage which extends to the equator.

#### 2.3.4.2 Allogeneic RPE transplantation

Delivery techniques described for homologous RPE graft usually require a small pipette for injection of the graft through a small or even self-sealing retinotomy. The size and location of RPE allograft delivered by injection is determined by the area of induced macula detachment. Allogeneic RPE cells have been transplanted to subfoveal (Algvere *et al.* 1997) or extramacular regions (Weisz *et al.* 1999). The advantage in delivery of the graft as a suspension is that the procedure is relatively easy to perform. However, efflux of RPE cells into the vitreous cavity, non-adherence to Bruch's membrane, incorrect apical-basal orientation and failure to form a monolayer are significant disadvantages of this delivery technique. Small patches of RPE can be delivered into the eye, as semi-rolled up sheet within a micropipette or cannula, through the retinotomy to subfoveal or extrafoveal locations (Weisz *et al.* 1999; Algvere *et al.* 1994; Gouras and Algvere 1996). Both fetal RPE sheets and adult gelatin encased RPE patches spontaneously unfold in the subretinal space (Algvere *et al.* 1994; Del Priore *et al.* 2001). Monolayer sheets of organised, correctly orientated RPE may improve graft viability and survival. However, due to folding and contraction of the graft, multi-layering with incorrect orientation of the RPE can still occur in the subretinal space even when it is grafted as a monolayer.

Except for the large retinotomy used by Peyman *et al.* (1991), none of the allogeneic RPE graft performed had laser to the macular retinotomy. Weisz *et al.* (1999) did not use any endotamponade, Del Priore *et al.* (2001) used air tamponade, Algvere *et al.* (1994; 1997) used gas (SF<sub>6</sub> or C<sub>3</sub>F<sub>8</sub>) or silicon oil (5,700 centistokes) tamponade and Peyman *et al.* (1991) used silicon oil (12,500 centistokes) together with an encircling band and 360-degree peripheral laser.

#### 2.3.4.3 Autologous RPE transplantation

The 4 approaches to autologous RPE-choroid graft will be described separately. The earliest attempts used macular RPE-choroid as a rotation flap or free graft (Peyman *et al.* 1991; Stanga *et al.* 2001b).

Through the macular retinotomy for removal of the membrane, a macular RPE-choroid flap or graft can be created using a vertical scissors. A large extramacular retinotomy used by Peyman (1991) allowed easier access to submacular RPE enabling a large RPE-choroid flap to be fashioned and repositioned under the fovea. Similarly, Yopez and Arevalo (2003) described a technique for easier access to submacular RPE-choroid graft transposition via a large inferior retinotomy with perfluorocarbon assisted retinal detachment. Through a standard macula retinotomy, Stanga *et al.* (2001a) reported the use of vertical scissors to cut a triangular patch of RPE and choroid from the edge of the membrane excision bed and repositioned it centrally to a subfoveal location, all in one continuous procedure operating in the submacular space. This technique was successful in maintaining the correct orientation of the graft (RPE facing up) in seven out of eight patients. In the first patient of this series (Stanga *et al.* 2001a), the RPE-choroid pedicle flap was not rotated far enough to a subfoveal location. In contrast, Angunawela *et al.* (2005) reported successful subfoveal placement of a RPE-choroid pedicle flap that remained vascularised after 4 years. Heavy liquid has been used (Stanga 2001) to stabilise the RPE-choroid graft and to expel subretinal fluid through the retinotomy. Endotamponade with silicone oil has been described (Peyman *et al.* 1991; Stanga *et al.* 2001a; Yopez and Arevalo 2003).

Two techniques of harvesting suspension of RPE cells from the peripheral fundus have been described (Binder *et al.* 2002; Binder *et al.* 2004; van Meurs *et al.* 2004). Binder *et al.* (2002; 2004) described a technique of using a subretinal pic to create a retinotomy nasal to the optic disc and induce a nasal retinal detachment by subretinal infusion of Ringer's or balanced salt solution (BSS) plus. A bent, blunt 20 G vitreoretinal cannula was then inserted in the subretinal space to mobilize RPE cells over an area of 2 to 4 disk diameters. The freed, dissociated, RPE cells were aspirated by an assistant who controlled the microsyringe connected to the cannula. Instead of retinotomy, van Meurs *et al.* (2004) harvested peripheral RPE through an inferior retinectomy. Three weeks preoperatively, argon green laser photocoagulation retinopexy was performed to isolate the inferior peripheral retina. Following lensectomy (if phakic), vitrectomy and inferior retinectomy, a modified bent 21 gauge aspiration cannula with an 8-O nylon loop was used to simultaneously scrap RPE off the Bruch's

membrane and aspirate the free RPE cells. Once removed from the eye, the RPE was either re-injected, unmodified, back into submacular space (Binder *et al.* 2002), or centrifuged with (van Meurs *et al.* 2004) or without (Binder *et al.* 2004) autologous serum, diluted with BSS plus solution (Binder *et al.* 2004), and then re-injected into the submacular space. Cell counts and viability testing were performed on the samples to assess if further harvesting was needed and the quality of harvested RPE cells. Poly-L-lysine was injected in the submacular space by van Meurs *et al.* (2004) to promote adhesion of the RPE cells to Bruch's membrane. Lowering of bottle height (Binder *et al.* 2002) and perfluorocarbon bubble (Binder *et al.* 2004; van Meurs *et al.* 2004) were used to reduce reflux during submacular injection of the RPE cell suspension. The retinotomies (Binder *et al.* 2004) and the retinectomy (van Meurs *et al.* 2004), if needed, received further laser. Air, gas or silicone oil endotamponade were used and patients were instructed to posture supine for 24 hours (van Meurs *et al.* 2004) or 1 hour followed by prone positioning (Binder *et al.* 2002; 2004) for a few days.

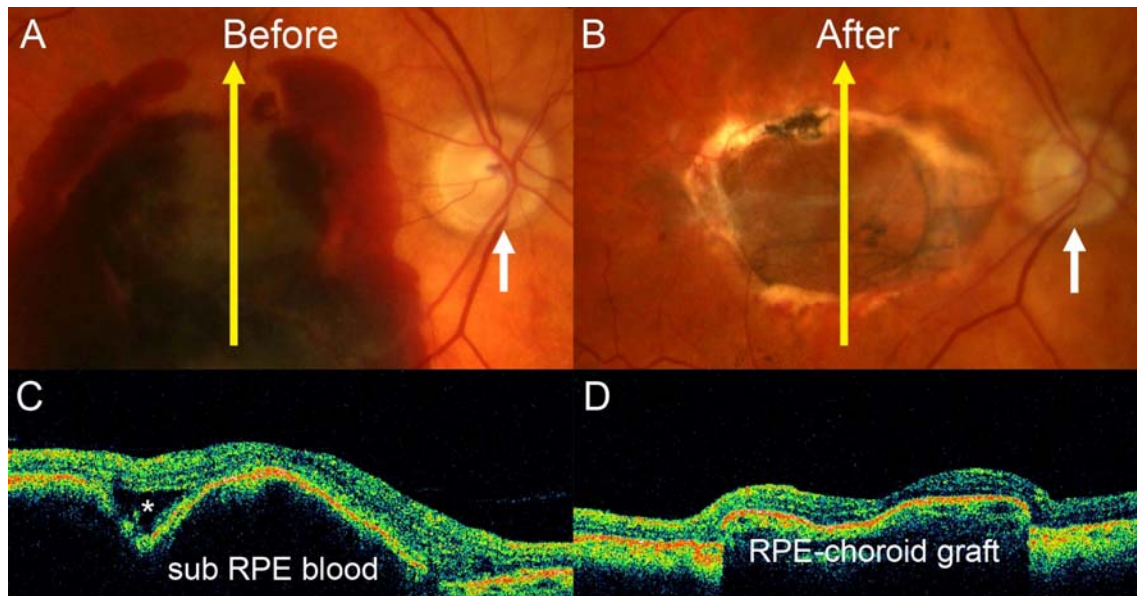
The technique of harvesting RPE-choroid patch graft from the equator followed by submacular insertion as initially described by van Meurs and van den Biesen (2003) has been used by several European groups. Briefly, following complete vitrectomy, a donor site is selected in the superior midperiphery, avoiding the vortex veins. Heavy retinochoroidal burns (chalky white), using endodiathermy (van Meurs and Van Den Biesen 2003; Jousseaume *et al.* 2006), diode laser (MacLaren *et al.* 2007) or green Nd:YAG laser (Treumer *et al.* 2007a), are placed around a 1.5 x 2 mm circle (Treumer *et al.* 2007a) or a 2-3 mm square (van Meurs and Van Den Biesen 2003; Jousseaume *et al.* 2006; MacLaren *et al.* 2007) to mark the donor site of RPE-choroid patch graft and to prevent choroidal haemorrhage (Treumer *et al.* 2007a). A patch of retina-RPE-choroid within the diathermy or laser mark is then cut out and separated from the sclera. Treumer *et al.* (2007a) reported removal of the retina before harvesting of the RPE-partial thickness choroid patch. Several approaches to choroid patch harvesting have been described. van Meurs (2005) makes an initial full thickness choroid incision and use a long spatula to sweep under the patch prior to cutting the rest of the graft. This releases any attachment between the choroid and sclera allowing clean release of the full-thickness RPE-choroid graft from the sclera when it is cut around. An alternative method is to cut around the graft with vertical scissors and then release the graft from sclera with horizontal, serrated curved scissors. Once the patch is harvested, the retina may spontaneously detach or peeled with a forceps. Since the RPE-choroid patch has a tendency to roll up into a half cylinder with RPE on its convex side, parallel to the limbus, bimanual



technique is usually required to load the graft onto a customised aspirating-reflux spatula (DORC Surgical Instruments, Netherlands) or grasp the graft with a partially closing subretinal forceps. Treumer *et al.* (2007a) reported that curling of the patch may be reduced by preparing a round rather than square RPE-choroid patch. The graft is then inserted through the retinotomy. Once the entire graft is submacular, heavy liquid is injected over the macula to flatten the detachment. The surgical assistant then pushes the plunger of the aspirating-reflux spatula to release the grip on the graft. As the macula collapse on the graft, the spatula or forceps are withdrawn. Major drawbacks of the current technique in RPE-choroid graft delivery are (1) damage to RPE as the graft is inserted through the retinotomy, (2) premature collapse of the macula before the graft is advanced to subfoveal location, (3) entanglement between the choroid side of the graft and the spatula or forceps preventing smooth release of the graft and (4) folding of the graft after its release in the submacular space. Some of these issues have been addressed by creating larger retinotomy along the temporal raphe, use of modified aspirating-reflux spatula with separate subretinal infusion cannula to inflate the subretinal space and attaching a vibrating device to the subretinal forceps (Maaijwee *et al.* 2008b). A clinical illustration of the anatomical outcomes of this technique can be seen in **Figure 2.7**.

van Meurs (2005) described a modification of the equatorial patch graft technique where a temporal 180° peripheral retinotomy was created instead of a small paramacular retinotomy. The aim was to facilitate removal of extensive submacular haemorrhage and enable harvesting of a larger equatorial RPE-choroid graft. Further reports using similar technique have been published recently (Petersen *et al.* 2008; Gibran *et al.* 2009; Ma *et al.* 2009; Degenring *et al.* 2010). Briefly, the technique involved the following steps: (1) creating a 180° temporal retinotomy, (2) flapping the nasal retina over the disc to expose submacular RPE, (3) removal of submacular tissue and blood clot, (4) harvesting of a large temporal equatorial/paramacular RPE-choroid patch graft, (5) transposition of the patch graft to cover the submacular RPE defect, (6) stabilisation of the graft on the submacular defect and (7) reattach the temporal retina. This technique avoids the disadvantages of a small macular retinotomy which are: limited access to remove large clots, greater trauma during insertion of the patch graft, damage to potential eccentric fixation locus, and posterior PVR. However, there are also several drawbacks of this approach including: prolonged surgical time, increased surgical trauma related to inducing a large temporal retinal detachment, technical difficulty in keeping the temporal retina folded over the disc, need for heavy liquid to

facilitate translocation of the large patch graft and high risk of post-operative retinal detachment due to the extensive retinotomy.



**Figure 2.7 Equatorial autologous RPE-choroid graft: OCT**

(A, B) Colour fundus photographs and (C, D) Stratus optical coherence tomography (OCT) scans of a patient with large haemorrhagic pigment epithelial detachment with subretinal fluid (\*) before and after autologous retinal pigment epithelium (RPE) - choroid patch graft. The yellow arrow shows the location and direction of the OCT scan and the white arrow points to the optic nerve head.

#### 2.3.4.4 Ex vivo donor RPE assessment and modification

Except for transposition of macular RPE-choroid patch (Stanga *et al.* 2002), all other techniques of RPE transplantation provide opportunity for ex vivo examination of the graft and genetic modification. Results of cell count and viability examination have been reported by Binder *et al.* (2002; 2004) and van Meurs *et al.* (2004) in autologous RPE suspension graft. *Ex vivo* genetic modification by a self-inactivating lentiviral vector can be performed within 30 minutes of immersion of the graft in vector suspension, within the time frame of submacular surgery. The infective potential of the transduced graft can also be eliminated by the washing procedure described by MacLaren *et al.* (2007).

#### 2.3.5 Intra-operative complication

No intra-operative complications were reported in any of the reported RPE allograft cases except for iatrogenic retinal break (Tezel *et al.* 2007). This may reflect the ease of subretinal delivery of cells through a micropipette. In Stanga's series of submacular RPE-choroid flap rotation and graft transposition (2001a), two had unsuccessful

grafting. In one patient the flap was non-subfoveal and in another, the graft was placed up side down. van Meurs *et al.* (2004) reported 2 cases of reflux of RPE graft from the retinotomy despite the use of perfluorocarbon bubble to tamponade. In the same series, one patient required silicone oil for post-operative tamponade as the preoperative barrier laser was ineffective in preventing extension of induced inferior retinal detachment. Other intra-operative complications following autologous equatorial RPE-choroid graft included partly folded graft and inadequate positioning of patches (van Meurs *et al.* 2006; Maaijwee *et al.* 2007a), failure to release graft from forceps inversion of graft (Joussen *et al.* 2006; Maaijwee *et al.* 2007a), loss of graft through sclerostomy (Maaijwee *et al.* 2007a), damage to papillomacular bundle (Maaijwee *et al.* 2007a), subretinal haemorrhages from donor and recipient choroidal beds (Joussen *et al.* 2006; Maaijwee *et al.* 2007a), strong CNV-retina adhesions (Joussen *et al.* 2006; Maaijwee *et al.* 2007a; MacLaren *et al.* 2007) and iatrogenic peripheral retinal break (Joussen *et al.* 2006).

### **2.3.6 Post-operative course and complication**

The post-operative care of patients receiving autologous grafts is similar to that of any vitreoretinal surgery. However, immunosuppression is required when allogeneic grafts are used. Phakic eyes filled with silicone oil will require a second procedure with or without cataract extraction. The main vision threatening complications following autologous or allogeneic grafts are intraocular haemorrhage, retinal detachment (RD) with or without proliferative vitreoretinopathy (PVR) and disease recurrence (i.e. CNV or GA). Increasingly, optical coherence tomography (OCT) and fundus autofluorescence (AF) have been used to monitor the status of retina and RPE following transplant. Structural and functional outcomes related to the graft and retina will be discussed in subsequent sections.

#### **2.3.6.1 General postoperative management**

Following fetal or adult allogeneic RPE graft, immunosuppression with a short course of oral steroid (60 mg per day of prednisolone for 1-2 weeks), within 2 weeks of graft (Algvere *et al.* 1994), or a 6-month course of cyclosporine and azathioprine with or without systemic steroid (Del Priore *et al.* 2001; Tezel *et al.* 2007) have been used. However, allogeneic RPE graft in GA has been performed without the use of post-operative immunosuppressant (Algvere *et al.* 1997; Algvere *et al.* 1999; Weisz *et al.* 1999). Tezel *et al.* (2007) described the frequent systemic work up, including blood

count, hepatic and renal function and serum drug levels, required in patients receiving triple immunosuppression.

Eyes with silicon oil endotamponade generally had oil removed, at the earliest, 2 months following the procedure unless RD occurred. In elderly phakic patients, cataract formation was common following vitrectomy. This can be addressed at the time of RPE transplantation by performing phaco-vitrectomy with (Binder *et al.* 2002; 2004) or without implant (van Meurs 2005) or alternatively, at the time of silicone oil removal. Post-operative acute intraocular pressure rise related to steroid response or pupillary block have also been reported (Binder *et al.* 2002; 2004; Tezel *et al.* 2007; Maaijwee *et al.* 2007a).

#### 2.3.6.2 Intraocular haemorrhage

Early (< 6 months) and late (> 6 months) post-operative intraocular haemorrhage after RPE transplantation are common. Early post-operative subretinal haemorrhage, within the first 3-6 months, was reported in 50%, 43%, 25%, 11% and 8% of the case series by Heussen *et al.* (2008), Jousseaume *et al.* (2006), MacLaren *et al.* (2007) and Maaijwee *et al.* (2007a) and Jousseaume *et al.* (2007) respectively. However, Stanga *et al.* (2002) and Treumer *et al.* (2007a) did not report occurrence of early subretinal haemorrhage. Jousseaume *et al.* (2006) reported that early post-operative haemorrhage was more common in patients taking anti-platelet agents or after removal of an occult membrane, and less common if Densiron® was used for tamponade. Maaijwee *et al.* (2007a) reported that 6 of the 9 patients with early post-operative haemorrhage were on anticoagulant. Subretinal haemorrhage may be found between the graft and the choroidal bed or the graft and the neuroretina or both. Visual loss from early subretinal haemorrhage may not be reversible as a result of several pathological processes: toxicity of the blood to overlying neuroretina (MacLaren *et al.* 2007), graft failure from absence of revascularization, subretinal fibrosis (Binder *et al.* 2002), or fibrous encapsulation of the graft (Jousseaume *et al.* 2006). Although small amount of subretinal haemorrhage can be managed conservatively, massive subretinal haemorrhage may require clot evacuation and re-grafting of the RPE choroid patch (Jousseaume *et al.* 2006). Regardless of whether the patch is re-grafted or reperfused, visual prognosis remains poor after large early post-operative subretinal haemorrhage (Jousseaume *et al.* 2006). Suprachoroidal and vitreous cavity haemorrhage have been reported (Binder *et al.* 2004; Jousseaume *et al.* 2006; Maaijwee *et al.* 2007a). Despite vitreous washout and drainage of suprachoroidal

haemorrhage in one case, severe pre- and sub-retinal fibrosis developed (Joussen *et al.* 2006).

Spontaneously resolving late post-operative subretinal haemorrhage, unrelated to recurrent CNV, has been reported (van Meurs and Van Den Biesen 2003; MacLaren *et al.* 2007). Although fluorescein and ICG angiographies may help to rule out CNV, it may be difficult to interpret these due to coexisting progressive RPE staining and cystoid macular oedema.

#### 2.3.6.3 Retinal detachment and proliferative vitreoretinopathy

Post-operative RD following graft usually occurs within 6 months. The rate of RD after RPE graft is variable depending on the surgical technique and complexity. Although allogeneic RPE cell suspension grafts were not complicated by RD, probably because of the use of small retinotomy and micropipette to inject the cells (Algvere *et al.* 1999; Weisz *et al.* 1999), 1 of 5 patients developed RD after fetal allogeneic patch graft (Algvere *et al.* 1994). However, RD developed in 3 of 12 patients (25%) who received adult allogeneic RPE patch graft and one of these progressed to inoperable PVR (Tezel *et al.* 2007). One of the 9 patients (11%) who received submacular RPE-choroid graft developed RD (Stanga *et al.* 2002). Four of the 39 (10%) patients who received RPE suspension graft developed RD secondary to reopening of the retinotomy (Binder *et al.* 2004). The van Meurs and van Den Biesen's (2003) technique, however, had variable RD rates ranging from 8 to 42% (Joussen *et al.* 2006; Joussen *et al.* 2007; Treumer *et al.* 2007a; Maaijwee *et al.* 2007a; MacLaren *et al.* 2007; Heussen *et al.* 2008). Detachments following autologous equatorial RPE-choroid graft were usually attributable to PVR and tractional re-opening of the retinotomies.

The development of PVR following patch grafts may be related to the release of RPE cells into the vitreous during donor cell harvesting, insertion of the graft through a small macular retinotomy, manipulation of the graft in the submacular space and later, continued release of RPE from the residual RPE or choroid bed at the donor site post-operatively. The risk of RD via reopening of the macular retinotomy may be increased by traumatic enlargement of retinotomy, persistent submacular fluid and poor chorioretinal adhesion around the retinotomy due to RPE atrophy and lack of barrier laser (MacLaren *et al.* 2007). On the other hand, the risk of RD via reopening of the donor site may be increased by larger and more posterior donor retinectomy (close to vascular arcade) as preretinal membranes tend to start in the macular region. Anteriorly located donor site may also be susceptible to reopening as vitreous base contraction may

occur from anterior PVR. In view of these possible mechanisms of PVR, there several modifications of the surgical technique have been suggested.

The ideal location of donor site should be half way in between the superior arcade and the posterior edge of the superior vitreous base, i.e. the equator. Choice of the size of the donor graft is a balance between, (1) the number of RPE cells and the surface area of the choroid to form vascular connection in a large donor patch, and (2) ease of submacular insertion of the graft and lesser risk of PVR (smaller retinectomy and retinotomy) from a smaller donor patch. Thorough removal of dispersed intravitreal RPE cells may reduce the rate of PVR. A relatively low rate (8%) of RD, reported by Maaijwee *et al.* (2007a) in a case series of 84 patients was thought to be related to the use of superior rather than inferior harvesting site and painstaking removal of hyaloid facilitated by the use of chandelier illumination and triamcinolone staining. Yopez and Arevalo (2003) reported the use of heparin and 5-fluoro-uracil (Asaria *et al.* 2001) as prophylactic measure against PVR. Interestingly, short-term tamponade did not seem to increase the rate of RD as it occurred in only 7 of 23 (30%) eyes with SF6 versus 10 of 22 (45%) eyes with silicon oil tamponade in the series reported by Joussem and colleagues (Joussem *et al.* 2006).

Macular pucker or pre-retinal membrane (ERM) was also common (17 to 24%) after RPE transplantation (van Meurs *et al.* 2004; Joussem *et al.* 2006; Treumer *et al.* 2007a). The mechanism of ERM formation is probably similar to that of PVR and relates to the paramacular retinotomy. Previous reports described peeling of ERM +/- ILM at the the time when silicon oil was removed or subsequent revision surgery (Joussem *et al.* 2006; Maaijwee *et al.* 2007a). However, these studies did not describe the impact of peeling on patients' the visual symptoms.

#### 2.3.6.4 Persistence and recurrence of disease

In addition to early haemorrhage and RD, visual loss may also occur due to disease persistence and recurrence. In neovascular AMD, incomplete removal of the CNV complex leads to persistent residual CNV which is usually seen within the first 1-3 months. Recurrent CNV may occur through a defect in RPE, especially when this is located near the fovea and this usually manifest after 3-6 months. These are common after submacular surgery. Following laser photocoagulation or surgical removal of subfoveal CNV from AMD, persistent or recurrent CNV may be seen in around 50% of patients during the first 2-3 years (MPS Group 1994b; Hawkins *et al.* 2004). Even with full or limited macular translocation, recurrent CNV can still occur in 25 to 35% within

the first 1-2 years respectively (Baer *et al.* 2008; Fujii *et al.* 2002a). In atrophic macular disease, development of RPE atrophy or even CNV over the recipient site may be considered as disease recurrence.

Algvère and colleague (1999) reported CNV at recipient sites between 1 and 2 years following allogeneic fetal RPE transplant in 3 of 5 patients with GA receiving small patch grafts. Tezel *et al.* (2007) attributed the development of fibrosis and haemorrhage around the graft in 2 patients, within 1 month after discontinuation of immunosuppression, to immune rejection rather than recurrent CNV. It may also be possible that the late leakage, haemorrhage and fibrosis are due to recurrent CNV. For autologous RPE suspension, 2 cases (5%) of recurrent CNV were reported in Binder's (Binder *et al.* 2004) prospective series of 39 patients at 3 and 12 months. However, recurrence was not reported in her earlier pilot study of 14 patients over 2 years (Binder *et al.* 2002) nor in van Meurs's (2004) case series of 8 patients over 3 to 16 months of follow up. Recurrent CNV was not reported in case series of autologous equatorial RPE-choroid graft with short term follow up (MacLaren *et al.* 2007; Jousseaume *et al.* 2006; Jousseaume *et al.* 2007). However, Jousseaume *et al.* (2006) described early development of fibrosis and haemorrhage around the patch graft in 19 of 45 (42%) eyes. Heussen *et al.* (2008) reported recurrent CNV in 11 of 30 (37%) patients between 6 and 12 months following autologous RPE-choroid graft and Treumer *et al.* (2007a) reported 1 of 10 (10%) patients with recurrent CNV after patch graft for atrophic AMD. In the largest series of patch graft, Maaijwee *et al.* (2007a) reported recurrent CNV in 11 of 85 patients (13%) after 2-27 months. Despite treatment with either laser photocoagulation or intravitreal anti-VEGF agent, most patients had visual decline (Maaijwee *et al.* 2007a; Heussen *et al.* 2008). The mechanism of visual loss is unclear since subfoveal growth of the recurrent CNV is usually prevented by the patch graft (Heussen *et al.* 2008). Although recurrence of GA has not been reported following autologous equatorial RPE-choroid patch graft at 6-12 months, longer term follow up is required since recurrent GA following translocation occurred late (Cahill *et al.* 2005a; Khurana *et al.* 2005).

#### 2.3.6.5 Other ocular and systemic complications

Post-operative serous macular detachment and cystoid macular oedema unrelated to CNV has also been reported (van Meurs and Van Den Biesen 2003; Jousseaume *et al.* 2006; Joeres *et al.* 2008). In a case series of 29 patients, Joeres *et al.* (2008) found that 14 eyes had normal retinal structure preoperatively on time-domain OCT. Among these, 7

retained normal appearance but the rest became oedematous (2), atrophic (2), or both atrophic and oedematous (2), and 1 developed a macular hole. Retinal oedema over graft may be related to traction from ERM, delayed donor RPE dysfunction or perifoveal capillary incompetence. Other ocular complications reported include macular hole, optic atrophy, glaucoma, vein occlusion and artery occlusion (Maaijwee *et al.* 2007a; Jousseaume *et al.* 2007; Joeres *et al.* 2008).

Systemic complication may occur in the setting of immunosuppression. One patient died from congestive cardiac failure at 114 days after allogeneic RPE patch graft (Del Priore *et al.* 2001). Three of 12 patients receiving immunosuppression after allogeneic grafts had to discontinue their medications due to adverse reactions prior to 6 months (Tezel *et al.* 2007). One patient in MacLaren's (2007) series had post-operative acute myocardial infarct which required intensive care unit admission. This was thought to be related to the anaesthesia for the procedure itself.

### **2.3.7 Graft survival and function**

Short term survival of donor RPE depends on how the cells were delivered. As cell suspension, the RPE will need to attach to a suitable basement membrane to prevent apoptosis (Tezel and Del Priore 1997). Autologous RPE-choroid patch graft, however, requires establishment of choroidal perfusion through vascular re-connection with adjacent or underlying choroid at the recipient site. Longer term survival of donor RPE largely depends on their sources. Allogeneic graft faces the barrier of immunological rejection within the first 6 months whereas autologous equatorial RPE may not be able to support foveal cone functions for long durations. Furthermore, delayed patch graft ischaemia may lead to late visual loss. The study of donor RPE survival and integration during the first months after grafting has been facilitated by the use of silicone oil as tamponade. Graft survival, structure and perfusion have been studied directly using AF imaging, OCT and high-speed ICG angiography, and indirectly through mapping of the preferred retinal locus for fixation and microperimetry. The following sections will address RPE survival in allogeneic grafts, autologous cell suspension grafts and autologous RPE-choroid patch grafts respectively.

#### **2.3.7.1 Allogeneic RPE suspension and patch grafts**

As discussed above, a short course of oral steroid (Algvere *et al.* 1994), or a 6-month course of cyclosporine and azathioprine with or without systemic steroid (Del Priore *et al.* 2001; Tezel *et al.* 2007) have been used for immunosuppression in patients receiving



allogeneic grafts. RPE allograft survival after delivery as cell suspension is difficult to evaluate. Algvere *et al.* (1994) have reported increased pigmentation in the macular region as a sign of cell adherence and growth. Although no specific features on autofluorescence imaging or angiography have suggested RPE suspension graft survival, improvement in retinal sensitivity on microperimetry may reflect rescued photoreceptor by viable donor RPE (Weisz *et al.* 1999). However, given the poor adhesion of uncultured adult, fetal and immortalised RPE cell lines to aged or damaged human BM (Zarbin 2003; Del Priore and Tezel 1998; Tezel *et al.* 2004), it is unlikely that cell suspension graft would have survived (see below). On the other hand, fetal and adult allogeneic RPE patch grafts appear to survive while the patient was immunosuppressed (Algvere *et al.* 1994; Tezel *et al.* 2007). There has been no OCT study of the structure allogeneic grafts.

Immune rejection is a significant barrier to long-term graft survival in allograft. It was proposed that the loss of immune privilege in the subretinal space following membrane removal was the cause of patch allograft rejection in all 7 patients with neovascular AMD in the study by Algvere *et al.* (1999). Interestingly, these grafts maintained visual function during the first month. Between 1 and 3 months, macular oedema, fluorescein leakage and graft depigmentation occurred, followed by progression to fibrous encapsulation after 3 months (Algvere *et al.* 1994). In contrast, extrafoveal fetal RPE patch allografts in GA were not rejected after 30 months with the exception of one case which was rejected within 6 months. In this patient, the graft was placed adjacent to the retinotomy; a site of damaged blood retinal barrier. Subfoveal fetal RPE allograft as a cell suspension in atrophic AMD was rejected after 12 months. Similarly, in 2 patients with RPE rip, the fetal RPE suspension allograft was also rejected within 6 months. Algvere *et al.* (1999) concluded that rejection is common but not inevitable and the risk factors for rejection include CNV removal, larger number of cells transplanted and proximity of transplant to fovea or retinotomy. As described previously, 2 of 12 patients from Tezel and colleagues' series (2007) developed fibrosis and haemorrhage around the graft within 1 month of discontinuing immunosuppression. The authors attributed this to graft rejection given the temporal relationship.

Other evidence of immune activation is the presence of autoreactive lymphocytes (against retinal antigens) in a patient who received RPE allograft. However, it was not possible to determine if the surgical procedure or the transplantation was the cause (Weisz *et al.* 1999). Histological examination of the eye at 2 – 3 months after adult allogeneic RPE patch graft did not demonstrate excessive

inflammatory cell infiltrate (Del Priore *et al.* 2001). As the mechanism of RPE allograft rejection is unknown, current immunosuppressive regime will only be empirical until the mechanism of RPE rejection is understood.

#### 2.3.7.2 Autologous RPE suspension and patch grafts

Survival of autologous RPE suspension on damaged BM after subretinal injection has been difficult to demonstrate. Binder and colleagues (Binder *et al.* 2004; Krebs *et al.* 2008) were unable to provide evidence of cell survival following autologous RPE suspension graft although they showed visual improvement in some patients. Although the authors suggested the use of an *in vivo* donor RPE marker to determine if these RPE cells survived, absence of donor RPE will not be a unexpected given previous *ex vivo* experiments have demonstrated poor adhesion of uncultured adult, fetal and immortalised RPE cell lines to aged or damaged human BM (Zarbin 2003; Del Priore and Tezel 1998; Tezel *et al.* 2004). Since cells are unlikely to have survived on damaged BM, the Long-term survival of submacular injection of peripheral RPE cell suspension becomes unlikely.

Early survival and function of RPE-choroid patch grafts depends on minimal surgical trauma to the RPE during harvesting and delivery and early perfusion of the graft. Factors that may impact on late equatorial RPE-choroid graft function include; size of the patch, ability of equatorial RPE cell to maintain foveal cones, primary photoreceptor cell dysfunction and delayed graft ischaemia.

Surgical trauma to donor RPE may occur during harvesting of donor RPE, loading of the graft on instruments, insertion through retinotomy and release of the graft and withdrawal of instruments. Electron microscopic examination of the RPE-choroid donor patch demonstrated intact Bruch's membrane but patchy loss of RPE or RPE cells with avulsed apical membrane (MacLaren *et al.* 2007). Placement of folded or even inverted graft significantly reduces the ability of the patch graft in supporting photoreceptor cells (Stanga *et al.* 2002; van Meurs *et al.* 2006; Jousseaume *et al.* 2006). Further evidence of the importance of surgical trauma in relation to outcome was provided by Maaijwee and colleagues (Maaijwee *et al.* 2008c).

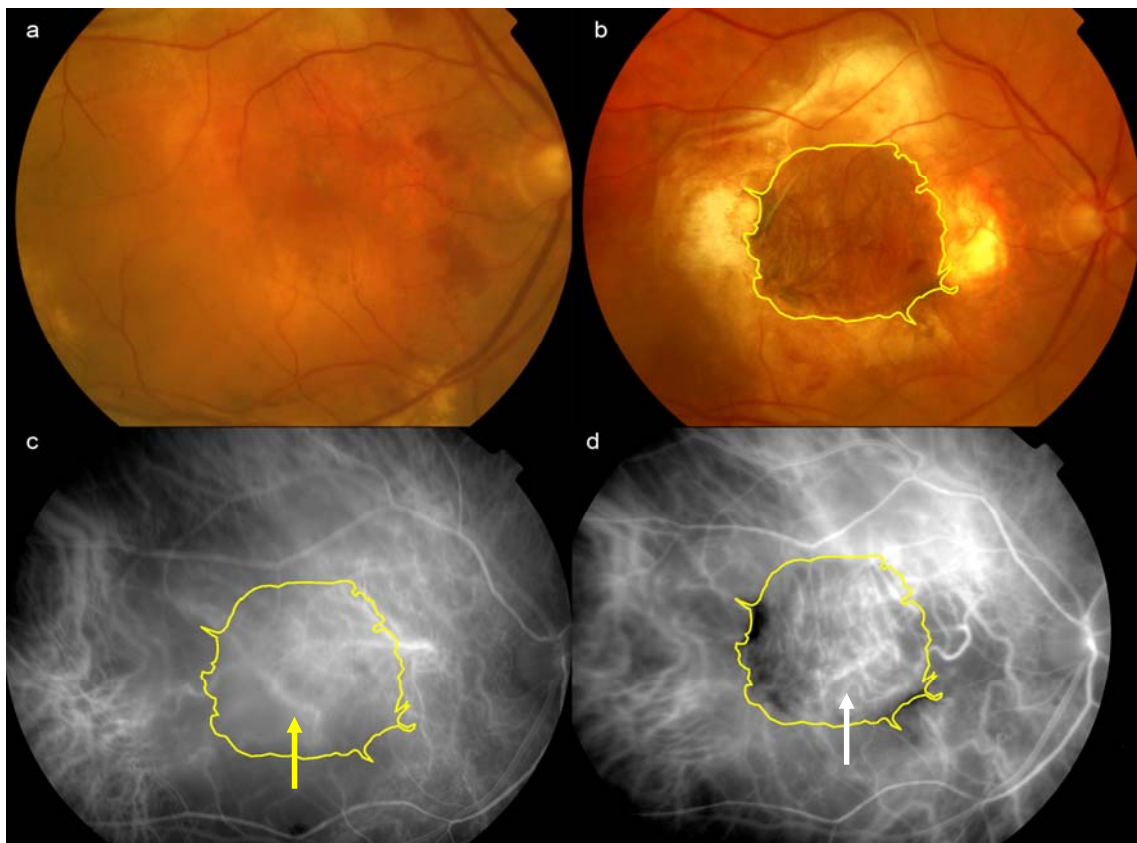
Graft perfusion has been detected as early as 1 week to as late as 4 months after patch graft using either early frames of FFA or high-speed ICG angiography (Jousseaume *et al.* 2006; Treumer *et al.* 2007a; Maaijwee *et al.* 2008d). It has also been shown that reconnection of vascular channels between the patch and the recipient choroidal bed can occur at the edge of the graft (see **Figure 2.8**). Jousseaume *et al.* (2006), on the other hand,

reported that the patch is perfused from the underlying choroid. Serial ICG angiography demonstrated initial reconnection of vascular channels and later remodelling of the RPE-choroid patch vasculature (Joussen *et al.* 2006). It is not known if there is ingrowth of underlying or adjacent choroidal vessels into the patch graft and recruitment of marrow-derived endothelial progenitor cells, similar to that found in skin graft integration (Capla *et al.* 2006). The process from initial connection to complete graft revascularisation may take up to 3 weeks (Joussen *et al.* 2006).

Failure of the graft to revascularise can be due to (1) separation of the graft from adjacent or underlying choroid by haemorrhage or (2) absence of choroid vessels around the graft. Absence of medium sized choroidal vessels may occur in areas affected by GA or following excision of CNV, previous repeated photodynamic therapy or possibly previous repeated anti-VEGF therapy. It is now generally accepted that a pedicle of choroid is not necessary for RPE-choroid patch survival as was suggested by Yopez and Arevalo (2003). With time, ischaemic RPE-choroid graft becomes encased in fibrous tissue. If the patch was only partially vascularised, the avascular portion of the graft may undergo fibrosis. The reported rates of failure to revascularise ranged from 6 to 11% (van Meurs 2005; Joussen *et al.* 2006; MacLaren *et al.* 2007; Treumer *et al.* 2007a; Maaijwee *et al.* 2008d). In Joussen's series (2006), 4 patients with failed graft vascularisation received a second RPE choroid patch, and 1 of these remained non-perfused. Revascularisation rate in patients with GA is similar to those in patients with neovascular AMD with only 2 of 12 patients demonstrated incomplete or absence of graft perfusion (Joussen *et al.* 2007). These 2 patients did not have intentional damage to BM prior to insertion of the grafts. Once perfused, the patch remained vascularised during the entire follow up period except for one case reported by Joussen *et al.* (2006) where patch perfusion had reduced at 6 months in a patient with GA. It is important to note that presence of vascularisation or autofluorescence signal do not always correlated with visual function (Joussen *et al.* 2006). Furthermore, a non-perfused graft (and presumably, dying RPE cells) may retain autofluorescence signal (derived from peripheral photoreceptors) for as long as 6 weeks after transplantation (Joussen *et al.* 2006; Treumer *et al.* 2007a). Conversely, a vascularised graft may also lose its autofluorescence signal years later due to possible delayed photoreceptor (MacLaren *et al.* 2005) or RPE cell death.

Long-term equatorial RPE-choroid graft survival has not been well characterised. Although there has been no study which correlated equatorial RPE cell function to outcome, it has been assumed that patients with peripheral degenerative

changes and those with full-field ERG abnormality may not benefit from autologous RPE-choroid patch graft. Following submacular RPE-choroid flap rotation or graft reposition, Stanga *et al.* (2002) noted development of fibrosis around the graft and lack of visual improvement after 10 months. Although they attributed these to primary graft failure from poor revascularization, long term (4-5 years) follow up on 4 of the 9 patients revealed that the grafts were in fact perfused. MacLaren *et al.* (2005) concluded that the failure of visual improvement and progressive visual loss may in fact be due to a primary progressive photoreceptor cell death rather than primary or secondary graft failure. It was proposed that the insult of surgery or continuation of natural history of the disease led to progressive photoreceptor cell loss. Joeres *et al.* (2008) used OCT To study the structure graft in 29 patients and found a trend that eyes with thinner grafts had better VA than those with thicker grafts at 6 months. Also, despite the significant undulation of the graft surface, most patient did not complain of metamorphopsia (Joeres *et al.* 2008).



**Figure 2.8 Equatorial autologous RPE graft: angiography**

Colour fundus photographs and indocyanine green angiographies (a, c) before and (b, d) after autologous RPE-choroid patch graft, showing intrinsic vascular filling pattern (white arrow) within the graft which is significantly different from the corresponding region (yellow outline) in the preoperative angiogram (yellow arrow), suggesting perfusion of the transplanted choroid.

### **2.3.8 Retinal structure and functional rescue**

There is clinical evidence to suggest that the removal of the RPE-CNV complex and reconstruction of the RPE and sub-RPE defect with healthy donor RPE can restore retinal structure and function. Restoration of retinal structure has been reported using optical coherence tomography (OCT) in trials of autologous RPE-choroid patch graft (MacLaren *et al.* 2005; 2007; Joeres *et al.* 2008). Various measures of retinal function including distance visual acuity (VA), reading ability, microperimetry and electrophysiology have been used to demonstrate reversal of visual loss or stabilisation of vision. The following sections will examine each outcome measure in relation to natural history and outcomes following different techniques of surgery for neovascular and atrophic macular diseases.

#### 2.3.8.1 Retinal structure

OCT is an indispensable tool in the management of neovascular AMD as it allows detailed visualisation of pathology within the choroid, sub-RPE space, sub-retinal space, retina and vitreoretinal interface. Although there is no natural history data on OCT outcomes in untreated AMD, histological studies and clinical examinations of end stage AMD or disciform scars suggest that retinal thickness is likely to reduce due to loss of outer nuclear layer. Interestingly, subretinal fluid and serous pigment epithelium detachment may also spontaneously resolve.

Several studies have demonstrated restoration of foveal contour and resolution of intraretinal oedema or subretinal fluid following autologous RPE-choroid graft (MacLaren *et al.* 2005; Maaijwee *et al.* 2007a; MacLaren *et al.* 2007). In case series of 29 patients, Joeres *et al.* (2008) found 14 patients with macular oedema preoperatively. Following autologous equatorial RPE-choroid graft, 4 had normal retinal structure. The remaining 10 eyes had persistent oedema alone (3), atrophy (2), mixture of atrophy and oedema (4) or developed a macular hole (1). They also found that normalisation of retinal structure did not always correlate with improved VA.

Data on OCT outcomes following RPE graft is scarce. Interpretation of current evidence is complicated by the possibility of missed pathology in time-domain OCT and the uncertain correlation between structural features seen on OCT and retinal function.

### 2.3.8.2 Visual acuity

The most commonly used measure of visual function outcome is the best-corrected distance VA. Measurements on the Snellen and the Early Treatment Diabetic Retinopathy Study (ETDRS) charts have been converted into logarithm of minimal angle of resolution (logMAR) for reporting outcomes. However, mean change in VA and proportion with VA gain or loss across different studies are not comparable due to differences in assigning logMAR values to VA measurements when the ETDRS chart could not be read from 1 metre. The following paragraphs will summarise the natural history in neovascular and atrophic macular diseases, and in these context, review the VA outcomes following allogeneic and autologous RPE grafts.

Results from the untreated controlled arms of clinical trials, such as the macular photocoagulation study (MPS) and submacular surgery trials (SST), and meta-analysis have provided data on the natural course of VA for over 3 years in patients with subfoveal CNV (MPS Group 1994a; Hawkins *et al.* 2004; Wong *et al.* 2008). It is apparent from these reports that VA outcome in neovascular AMD may be dependent on the duration of symptom, and location, size and composition of the CNV. Other features such as serous or haemorrhagic PED, RPE rip and subretinal haemorrhage may also significantly alter the natural course of VA (Braunstein and Gass 1979; Avery *et al.* 1996). In eyes with subfoveal CNV, those with classic only features tend to have a worse presenting vision and a more rapid decline in VA during the first 2 years than those with occult only CNV. In the meta-analysis by Wong and colleagues (2008), the mean VA loss in neovascular AMD was 1 line at 3 months, 3 lines at 1 year and 4 lines at 2 years from a baseline of 0.64 logMAR (~6/24 Snellen). One study showed that VA continues to decline even at 4 years with a mean loss of over 6 lines in either classic only or occult only eyes (Maguire 1999). However, there is limited information on the natural history of patients presenting with very poor initial VA (< 3/60) since these patients are usually excluded from randomised trials of new therapy. The VA outcome in this group of patients may also be dependent on the duration of visual loss and other parameters such as fixation pattern (see below). This is highly relevant to surgical trials because many patients in the initial cohort who underwent subfoveal CNV removal with RPE graft were not eligible for conventional therapy due to poor VA as a result of disciform scar, RPE rip or large submacular haemorrhage.

The natural history of VA change in GA has been reported by Sunness *et al.* (1997). Although doubling of visual angle can occurred in 20-50% of eyes over 2 years, a later study demonstrated that improvement in VA also occurred in the worse seeing

eye when the better seeing eye lost vision (Sunness *et al.* 1997; 2000) Therefore, one should be cautious when interpreting VA outcomes in uncontrolled case series. Furthermore, VA outcomes should be interpreted in conjunction with other measures of visual function such as fixation locus and stability (see below).

There is some evidence that allogeneic graft can support fixation although only for short duration. The first reported allogeneic RPE graft, described by Peyman *et al.* (1991), had counting fingers (CF) vision at 2 feet, pre- and post-operatively due to fibrous encapsulation of the graft from presumed graft rejection. In Algvere and Gouras' (1994; 1997; 1999) series of 5 patients with neovascular AMD, mean VA declined 0.96 to 1.26 logMAR at 3 months. Although fixation on the patch was shown in 2 patients on microperimetry at 1 month, visual loss occurred between 1 and 3 months, coinciding with development of graft failure. In the same series, an overall VA loss also occurred in the 9 patients with atrophic AMD who received allogeneic fetal RPE grafts either as cell suspension or monolayer sheet (Algvere *et al.* 1999). Severe visual loss occurred in 3 of these 9 patients due to development of CNV 1-2 years after the graft. In the series by Tezel *et al.* (2007), mean VA declined from 0.84 to 1.00 logMAR over 12 months following adult allogeneic RPE graft although this was not statistically significant. The absence of VA benefit was also supported by the lack of fixation over graft in any of the 12 patients post-operatively.

Amongst the various techniques of autologous RPE graft, the most compelling evidence of VA rescue came from case series on the use of equatorial RPE-choroid as autograft. The earlier techniques of autologous RPE grafts had disappointing VA outcomes. Peyman *et al.* (1991) demonstrated doubling of visual angle with VA improved from CF at 5 feet to 3/60 although fixation was on the graft was not reported. In Stanga's series (2002) of 9 patients with submacular RPE-choroid autograft, VA did not improve, with pre-operative VA ranging from CF to 6/30 and post-operative VA ranging from hand motions (HM) to 6/30 after 1-2 years. Furthermore, in those with uncomplicated postoperative course loss of fixation and VA occurred over time (MacLaren *et al.* 2005). At 4-5 years, only one patient had stable VA whereas the remaining 3 patients had further loss. This was thought to be due to continuing photoreceptor death rather than graft RPE dysfunction (MacLaren *et al.* 2005).

Binder *et al.* (2002; 2004) demonstrated, in 2 prospective studies, that VA can improve after autologous RPE cell suspension transplants. In the feasibility and safety pilot study, she reported improvement of 2 or more lines in 8 of the 14 eyes (57%) after 12 months of follow up (Binder *et al.* 2002). In this group of patients, most were

primary CNV (13), most had mixed classic and occult (10, remaining 2 had classic only and 2 had occult only), all had angiographic growth of lesion 3-9 months previously, substantial visual decline and baseline VA ranging from CF to 6/15 (6 out of 14 had VA  $\leq$  6/60). The initial sizes of the lesions ranged between 1.02 and 8.24 mm in maximum diameter (mean = 4.59 mm). To further evaluate functional benefit of RPE suspension transplant, Binder *et al.* (2004) performed RPE grafts in 39 eyes and compared the outcomes of these with 14 eyes that had undergone CNV removal alone. This group of patient is different from those in the pilot study in that most had occult membrane with minimal classic areas (50 out of 53; 94%). The baseline VA range was not reported. The initial size of the lesions ranged from 3.1 to 10.1 mm (median = 6.0 mm). Similar to the pilot study, VA improved 2 or more lines in 21 of the 39 eyes (54%) at 12 months. In the control group, mean VA improved during the first 6 months and then deteriorated by 12 months. Overall, the net change was a gain of 1 line in the control group and 2 lines in the transplanted group. In a larger series of 68 patients (28 had RAP lesion) using the same technique, Krebs *et al.* (2008) reported no significant change in mean VA (from 1.02 to 1.06 logMAR) at 12 months. van Meurs *et al.* (2004), however, was unable to demonstrate a visual benefit from a his technique of cell suspension transplant in 8 patients with pre-operative VA ranging from CF to 6/120 due to minimally classic CNV larger than 2 disc diameters, with or without submacular blood. Post-operative VA ranged from HM to 6/120 after 3 to 16 months of follow up. Because of the severe complications encountered and only modest visual gain in those without complication, the authors have abandoned this technique in favour of autologous equatorial RPE-choroid graft (van Meurs and Van Den Biesen 2003).

In the original description of autologous equatorial RPE-choroid graft, van Meurs and van Den Biesen (2003) reported that 67% had gained 3 or more lines from a baseline mean VA of 1.10 logMAR. At longer follow of 12-24 months, 8 of 18 (44%) patients maintained this improvement (van Meurs 2005). All these patients had minimally classic subfoveal lesions larger than 1 disc diameter with or without submacular blood. In a report of the long-term outcome by the same group, at 36 and 48 months, 4 of 24 (17%) and 2 of 11 (18%) patients had VA of 6/24 or better (Maaijwee *et al.* 2007a). However, these encouraging results have not been reproduced by other groups. Joussem *et al.* (2006) reported an overall visual decline, with only 7% of the 45 patients had VA gain of 3 lines or more. The mean (range) baseline VA in this cohort was 0.85 (0.3-1.6) logMAR and the mean lesion size was 4.2 mm excluding the 3 lesions larger than 10 mm (Joussem *et al.* 2006). The majority had PED (16) or occult



only lesions (14). Post-operatively, the mean (range) VA declined by three and a half lines to 1.2 logMAR (0.4 logMAR to PL). Significant proportion of patients (31%) had severe visual loss immediately after surgery. By 6 months, 20% and 18% had VA of CF or worse and 6/24 or better, respectively. Overall, 7% of eyes had 3 or more lines of gain in VA. Smaller case series of this technique in patients with neovascular AMD reported a wide range of rates of 3 line VA gain over 6-12 months varying from 17 to 70% (Fawzy *et al.* 2006; Treumer *et al.* 2007a; MacLaren *et al.* 2007; Heussen *et al.* 2008). However, if patients who had post-operative complication were excluded from analysis, the mean change in VA would have been a gain of 2-3 lines. The proportions of the types of lesion treated were different between the three groups of investigators. Treumer *et al.* (2007a) reported outcomes in patients with massive submacular haemorrhage (5), large occult only CNV (3), PED (1) and geographic atrophy (1). Pre-operative mean (range) VA was 1.4 (0.7-1.8) logMAR. Fawzy *et al.* (2006) reported outcomes in patients with massive submacular haemorrhage (5), occult only CNV (11), classic only CNV (2), mixed CNV (1) PED (4) and rupture of RPE (2). Pre-operative VA ranged from 0.3 to 1.4 logMAR. Heussen *et al.* (2008) included eyes with classic CNV (1), mixed CNV (1), RAP lesion (1), RPE rip (2), massive submacular haemorrhage (5), occult CNV (7) and the majority had PED (13). The mean baseline VA was 0.8 logMAR. MacLaren *et al.* (2007) reported outcomes in patients with occult CNV (10) with or without haemorrhagic PED, serous PED or RPE rip, minimally classic (1) and large classic CNV (1) not responding to previous PDT or too large for re-treatment. Their pre-operative VA ranged between 6/15 and 4/60 (mean of 0.82 logMAR).

In summary, there is good evidence that VA can improve in neovascular AMD treated with CNV removal and RPE graft. However, it is difficult to compare results from different case series due to varied case mix and different methods of VA assessment. Without a control group, these studies were unable to conclude that RPE transplantation could improve visual outcome.

### 2.3.8.3 Reading ability

Reading ability is quantified by near acuity, critical print size and maximum reading speed. Near acuity is more commonly measured with charts that require word rather than letter recognition. This accounts, in part, the disparity between the near and distance acuity reported by Lovie-Kitchin and Bailey (1981). Reading speed increases as the print size enlarge until the critical print size is reached where the speed reaches a

maximum (Legge *et al.* 1985b). Many factors can influence the maximum reading speed, including contrast threshold (Legge *et al.* 1992; Crossland *et al.* 2005b), size of scotoma (Sunness *et al.* 1996; Ergun *et al.* 2003), location of eccentric fixation in relation to the scotoma (Rayner *et al.* 1980; Fine and Rubin 1999; Nilsson *et al.* 2003; Sunness and Applegate 2005) and fixation stability (Crossland *et al.* 2004a). Reading ability following RPE graft has been assessed by using the Jaeger chart (Binder *et al.* 2002; 2004), Radner reading chart (Joussen *et al.* 2006; Kirchhof *et al.* 2006) or the Pepper reading test (Tezel *et al.* 2007). Reading speed and acuity have also been used to document visual outcomes following macular translocation surgery (Eckardt *et al.* 1999; Fujikado *et al.* 2002; Abdel-Meguid *et al.* 2003; Mruthyunjaya *et al.* 2004; Toth *et al.* 2004)

Although the natural course of reading ability in neovascular AMD has been reported in the untreated controls of clinical trials such as the MPS group (Crossland *et al.* 2004a; MPS Group 1994c), TAP and VIP study groups (Bressler 2001; Blumenkranz *et al.* 2002; Bressler *et al.* 2004b; Pieramici *et al.* 2006), and the SST research group (Bressler *et al.* 2004a; Hawkins *et al.* 2004), they are not comparable due to different methodologies. In atrophic AMD, Sunness and Applegate (2005) reported that 74% of patients continued to lose speed of reading as GA enlarges over time after 4 years. The VA range of these patients at entry was between 6/24 and 6/60.

Currently, there is only anecdotal evidence that demonstrates restoration of reading ability by RPE graft. Reading speed did not improve after allogeneic RPE graft (Tezel *et al.* 2007). Using autologous RPE cell suspension transplant, 7 of the 14 patients achieved reading acuity of Jager 1 to 10 print size where as only 3 could read the chart pre-operatively (Binder *et al.* 2002). However, this result was not reproduced in a larger prospective study of 39 patients where only 10% had reading acuity in the same range post-operatively (Binder *et al.* 2004). In Joussen's series (2006) of autologous equatorial RPE-choroid graft, 31 of 45 had reading ability pre-operatively but only 13 (7%) were able to read post-operatively. However, a trend was noted for patients without intra-operative or post-operative complications and those with mixed classic and occult CNV to have better postoperative reading acuity. Heussen *et al.* (2008) reported improvement in Radnar reading test in some patients between 6 and 12 months but interpretation of reading ability outcome is difficult due to incomplete data set during follow up. In a group of 12 patients with GA, Joussen *et al.* (2007) demonstrated gain of reading ability in 2 of 3 patients and loss of reading ability in 3 of 9 patients after autologous equatorial RPE-choroid graft.

In summary, it is not clear from most reports whether the gain in reading ability is clinically meaningful. Even if the improvement is beyond the test-retest variability of reading test, it is important to determine if the change is due to rescue of function by the transplanted RPE or to central adaptation and eccentric fixation. Despite the uncertainties, recovery of reading ability in some of these patients may become the main drive for further development and refinement of the technique of RPE transplantation.

#### 2.3.8.4 Microperimetry and visual field

From the above discussion, it is apparent that the reported VA and reading ability outcomes have not been convincing in demonstrating rescue of retinal function by RPE transplantation. This is because loss of retinal sensitivity within fovea leads to development of central scotoma and shifting of fixation from the centre of fovea to one or more extrafoveal loci where retinal sensitivity still remains (Fujii *et al.* 2003; Crossland *et al.* 2004a). Such eccentric locus (or loci) of fixation can sometimes support reasonable distance acuity and reading ability. Although the shift in the preferred retinal locus can lead to loss of fixation stability and reduced re-fixation accuracy (Schuchard 2005), adaptation and training can also improve VA and reading ability independent of graft function (Nilsson *et al.* 2003).

Macular sensitivity, preferred retinal locus and fixation pattern can be studied by conventional automated perimeter or microperimetry through the Rodenstock scanning laser ophthalmoscope (SLO) (Mainster *et al.* 1982; Timberlake *et al.* 1982) or the Nidek MP1 (Midena *et al.* 2004). The SLO microperimetry is no longer in production and the Nidek MP1 has been shown to produce comparable result when compared with SLO (Rohrschneider *et al.* 2005) and conventional automated perimetry (Springer *et al.* 2005). Macular sensitivity has been studied using the 10-2 perimetry (Stanga *et al.* 2001a; Binder *et al.* 2004), the SLO microperimeter (Algvere *et al.* 1994; Algvere *et al.* 1999; Weisz *et al.* 1999; Joussem *et al.* 2006; Joussem *et al.* 2007; Heussen *et al.* 2008) and the Nidek MP1 (van Meurs 2005; Treumer *et al.* 2007a; Treumer *et al.* 2007b; Maaijwee *et al.* 2007a; MacLaren *et al.* 2007). Fixation locus and stability have been evaluated by fixation target of OCT (van Meurs and Van Den Biesen 2003), fixation rod (van Meurs and Van Den Biesen 2003), Foerster cross (Joussem *et al.* 2006), cross-pattern fixation target or single-point flashing light in the Zeiss confocal laser scanning ophthalmoscope (Stanga *et al.* 2001a), Rodenstock SLO fundus perimetry (Algvere *et al.* 1994; Weisz *et al.* 1999; Joussem *et al.* 2006; Kirchhof *et al.* 2006) and the Nidek

Micro Perimetry 1 (van Meurs 2005; Treumer *et al.* 2007b; Treumer *et al.* 2007a; Maaijwee *et al.* 2007a; MacLaren *et al.* 2007).

Retrospective studies using microperimetry to document natural history in neovascular AMD have been reported by Fujii *et al.* (2003) and Midena *et al.* (2004). Prospective studies on development of macular scotoma, eccentric fixation and loss of fixation stability in neovascular and atrophic AMD have also been reported by Fujii *et al.* (2003), Crossland *et al.* (2004a; 2005a) and Sunness *et al.* (1996; 2005). These studies demonstrated enlargement of scotoma and shift in fixation locus. In general, the pattern of enlargement is unpredictable although in GA, pattern of junctional AF signal may predict loss of retinal sensitivity (Scholl *et al.* 2004). Although the topographical variation in retinal sensitivity may be informative, there is no data on the test-retest variability of microperimetry to aid interpretation of change in sensitivity or fixation stability over time.

Algvere *et al.* (1994) demonstrated that foveal fixation was supported by allogeneic RPE patch until the onset of graft rejection between 1 and 3 months in neovascular AMD. Four of 5 eyes had retinal function over the patch at 1 month but this was lost due to rejection. When graft rejection was not seen, as in those with geographic atrophy or severe RPE degeneration, there was no change in fixation after transplantation. In atrophic AMD, retinal sensitivity did not change over the RPE allograft (Algvere *et al.* 1999). Interestingly, Weisz *et al.* (1999) reported “spotty” perception of SLO microperimetry stimulus at 8 months over transplanted area that previously had no perception of the stimulus.

Although 7 of the 9 patients in Stanga’s series had fixation on the patch at 12 to 32 months following submacular RPE-choroid translocation (Stanga *et al.* 2002), MacLaren *et al.* (2005) reported that all 4 patients examined at 5 to 6 years after the graft had lost foveal fixation. Central retinal sensitivity was present when tested by 10-2 perimetry within the first year of graft (Stanga *et al.* 2002). Binder *et al.* (2002) reported 3 of the 18 (17%) patients gaining foveal fixation at 12 or more months in her pilot study of autologous RPE cell suspension transplant. In her second report on the same technique, Binder *et al.* (2004) found no difference in mean defect on central 10-degree static threshold perimetry between those who received and those who did not receive RPE transplantation. In van Meurs’ series of cell suspension transplant (2004), 3 patients had fixation within the edge of CNV extraction bed and 3 had fixation outside the CNV extraction bed.

The first report of autologous equatorial RPE-choroid patch graft demonstrated fixation over the patch graft at 7-14 months after transplantation in 4 out of the 6 (67%) patients (van Meurs and Van Den Biesen 2003). At 12 – 24 months, 12 of the 18 (67%) patients still had fixation over the graft (van Meurs 2005). In a larger series of 84 eyes, 62 (74%) had fixation on the graft as assessed by slit lamp biomicroscopy at follow up between 1 and 4 years. Joussem *et al.* (2006) and Treumer *et al.* (2007a) however, reported lower rates of post-operative foveal fixation, 42% (8 out of 19) and 50% (5 out of 10), at 6 and 12 months respectively. Joussem *et al.* (2006) reported that eyes with stable fixation preoperatively were more likely to maintain stable fixation after surgery and a weak correlation exist between visual acuity, fixation locus and stability. Heussen *et al.* (2008) reported that only 3 of 11 eyes with poor VA (<6/60) had fixation on the patch but did not state the locus of fixation in those with good VA. Both MacLaren *et al.* (2007) and Joussem *et al.* (2007) reported that fixation on the patch was possible for 1 or more year but the rate of achieving fixation over the graft was not given. It is difficult to compare the fixation outcomes between these studies since preoperative fixation behaviour was not characterised fully and different techniques of measuring fixation were used.

Joussem *et al.* (2006) demonstrated that the retina overlying the graft was able to detect light stimuli. Areas of retina overlying fibrosis or haemorrhage had a relative or absolute scotoma. Retina overlying a CNV of greater than 1 mm<sup>2</sup>, areas of RPE atrophy or no AF signal had absolute scotoma. Treumer *et al.* (2007a) demonstrated that if retinal sensitivity over the patch graft was not present within 3 months of grafting, it was not achieved during the 6 to 12 months of follow up. Further more, MacLaren *et al.* (2007) reported that topographic variability in retinal sensitivity in the area overlying the graft may be accounted for, in part, by the extent of graft choroid perfusion. In geographic atrophy, patch graft did not improve sensitivity of the retina that was overlying on atrophic RPE (Joussem *et al.* 2007). **Figure 2.9** shows that both AF and graft perfusion are necessary but not sufficient for restoration of retinal sensitivity. Comparison with pre-operative microperimetry is critical in determining if absence of sensitivity over graft was due to surgical trauma or pre-existing pathology.

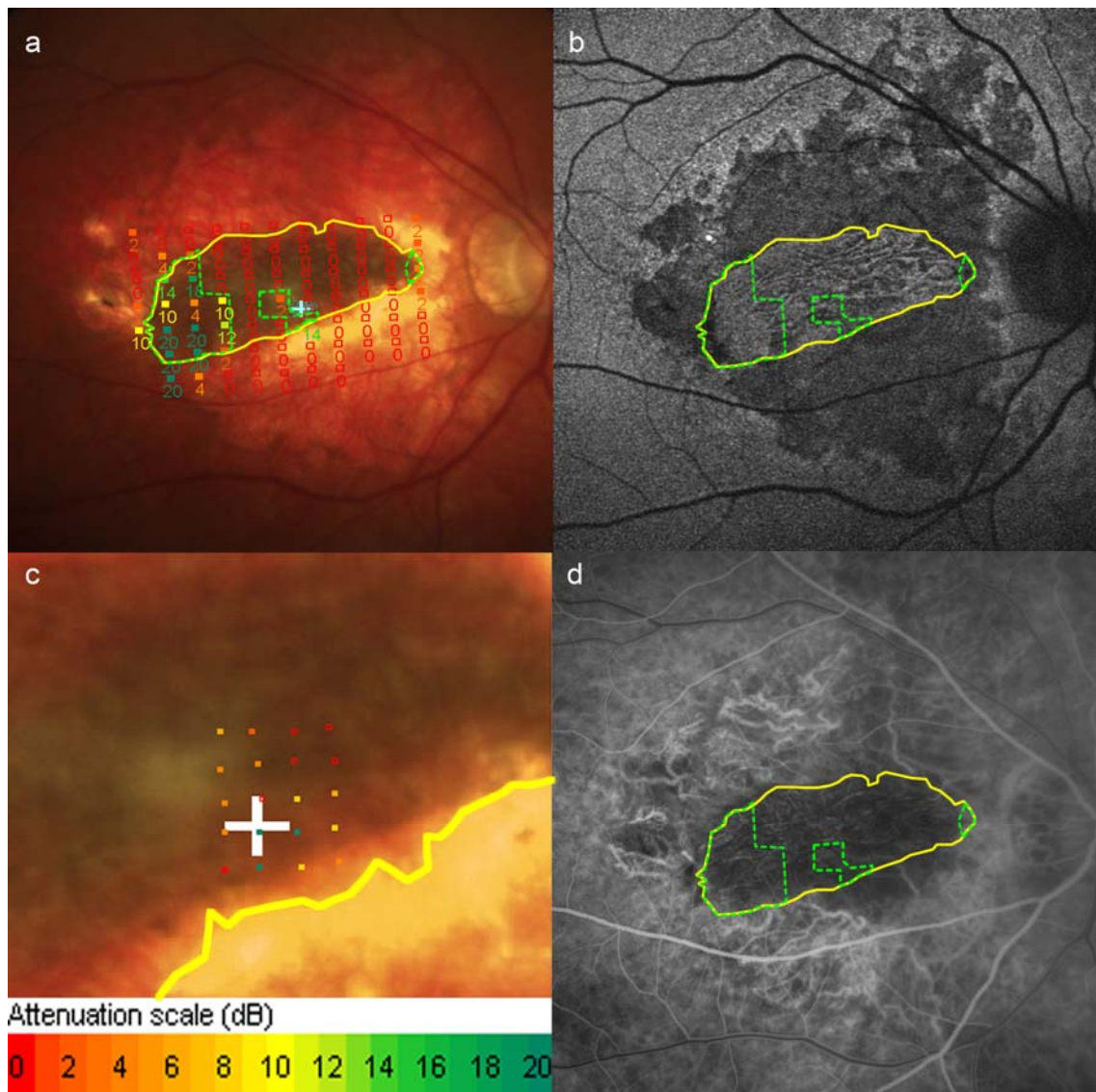
In summary, there is compelling evidence that RPE patch graft is able to support foveal cone function to maintain stable fixation in some patients. However, there has been no report, as yet, which demonstrated that RPE graft can improve or restore retinal sensitivity over an area of absolute scotoma present pre-operatively (Joussem *et al.* 2006).

#### 2.3.8.5 Electrophysiology

VA, reading ability and microperimetry are psychophysical tests which are prone to variability due to learning and fatigue. Electrodiagnostic tests are objective and are able to study, in isolation, photopic or scotopic, inner or outer retinal, and localised macular or generalised retinal responses to light. Full-field ERG is not useful in assessing localised macular function rescue by RPE graft since full-field response can be normal even in eyes with severe macular damage. Multifocal ERG allows assessment of macular function by recording focal ERG signals simultaneously at multiple retinal loci within the macula over a brief period of time (Sutter and Tran 1992). Pattern ERG, an older technique, provides information on the macular retina as a whole but does not provide topographic information on variation in retinal function within the macula. These modalities have been used in the setting of AMD in early detection, monitoring of treatment and predicting visual outcomes (Feigl *et al.* 2005; Obata *et al.* 2006; Neveu *et al.* 2006). There is limited prospective data on the change in multifocal or pattern ERG with exudative or atrophic AMD (Neveu *et al.* 2006). Current models of multifocal ERG system can be combined with an SLO for continuous monitoring of fixation and allow accurate overlay of individual response traces on fundus image. This will enable spatial correlation between electrophysiological responses and retinal pathology to be made (Jurklies *et al.* 2002; Kondo *et al.* 1997; Poloschek *et al.* 2003; Bellmann *et al.* 2004; Glybina and Frank 2006).

Currently, there is only 1 prospective study of RPE transplantation which examined the electrophysiology outcome. Binder *et al.* (2004) demonstrated higher mean a-wave and b-wave amplitudes in the multifocal ERG wave forms in the transplanted group than the control group after 12 months. During the first 3 months, increased amplitudes were attributed to reduction of macular oedema and metabolic or trophic support from the transplanted RPE. The control group demonstrated progressive deterioration of the amplitude during the 12 months follow up period.

The use of video-monitored multifocal ERG in patients undergoing RPE graft may enable correlation, in multiple areas of the graft, between choroidal flow, AF signal, retinal thickness, retinal sensitivity and localised electrophysiological response.



**Figure 2.9 Equatorial autologous RPE graft: microperimetry**

A postoperative case of autologous equatorial RPE-choroid transplantation (yellow outline) in a patient with inherited macular disease. (a) Microperimetry using Nidek MP1 showing retinal sensitivity map over the graft. Red open squares denote no vision. Colour scale squares with numbers denote increasing sensitivity based on decibel scale in label c. (b) Autofluorescence image showing areas of homogenous autofluorescence within the graft. Areas with retinal sensitivity on microperimetry are outlined. (c) A close up of microperimetry result showing sensitivity at the fovea. (d) Choriocapillary perfusion on fluorescein angiography within the graft.

#### 2.3.8.6 Other measures of outcome

Other measures of visual functions include contrast sensitivity (CS), chromatic sensitivity and Vernier- or hyper-acuity. Tezel *et al.* (2007) reported no improvement in CS following allogeneic RPE graft. Jousseaume *et al.* (2006) reported that all patients had improvement of distortion following autologous equatorial RPE-choroid graft. Quality of life (QOL) questionnaire has also been used to measure outcome following RPE

graft. Unlike macular translocation (Cahill *et al.* 2005b), vision-specific QOL as measured by the National Eye Institute Visual Function Questionnaire (NEI-VFQ) after autologous equatorial RPE-choroid graft has not been shown to correlate with VA outcomes (Heussen *et al.* 2006).

### **2.3.9 Summary of human trials**

In summary, human trials of autologous RPE grafts in neovascular AMD have demonstrated retinal function rescue with encouraging long-term outcomes. There is limited clinical data on allogeneic RPE grafts due to lack of availability of adult and fetal RPE cell sources and inability to prevent allograft rejection. However, several issues regarding autologous grafts remain unanswered. Can autologous equatorial RPE-choroid graft be performed safely in atrophic macular disease? How do we reliably measure and monitor long-term retinal function rescue by RPE transplantation in atrophic macular disease if VA does not reflect disease progression or graft function? In neovascular AMD, it is still not clear how translocation of the RPE compares to translocation of the the fovea in their long-term visual outcomes. Despite the promising visual outcomes at 1 year from each type of approach, do we know if paramacular and equatoridal RPE-choroid can maintain foveal function beyond 2 years?

## **2.4 Aims and Hypotheses**

The aim of this thesis was to investigate the outcomes of autologous RPE transplantation in AMD and IMD in order to provide proof of principal of short- and long-term photoreceptor cell function rescue. These data will be used for the purpose of proposing a novel surgical technique of hESC derived-RPE transplantation.

The overall hypothesis of this thesis is that autologous RPE transplantation by either RPE-choroid graft or macular translocation can maintain retinal function for over 2 years in patients with atrophic or neovascular macular disease.

The clinical studies were designed to specifically investigate the following hypotheses:

1. Autologous RPE-choroid graft can support retinal function at 1 year and maintain this for at least 2 years in atrophic AMD and IMD.
2. Autologous RPE choroid graft and full macular translocation can support retinal function for at least 2 years in neovascular AMD.
3. Human ESC derived-RPE transplantation is a simpler and safer alternative technique of reconstructing RPE than the current surgical approaches.



# **Chapter 3**

## **Materials and Methods**

### **3.1 Clinical studies and design**

The methodology described below refers to two prospective pilot studies (**Chapter 4**) and two retrospective case series (**Chapter 5**).

The atrophic macular disease studies (**Chapter 4**) consist of 2 prospective single-centre, single-surgeon clinical trials approved by the hospital Research Governance and the Local Research Ethics Committees (**Appendices 2 and 3**). The design and conduct of these studies followed the tenets of the Declaration of Helsinki. Informed consent was obtained from each patient after the experimental nature of the study had been explained.

The neovascular macular disease studies (**Chapter 5**) were retrospective case-series approved by the hospital Research Governance (**Appendices 4, 5 and 6**). The tenets of the Declaration of Helsinki were followed. All patients gave informed consent for these procedures to be carried out as part of previous clinical trials approved by the Local Research Ethics Committee or as routine care.

#### **3.1.1 Patient selection**

Inclusion and exclusion criteria for the prospective and retrospective study are listed below.

##### **3.1.1.1 Atrophic macular disease study**

For the atrophic disease study, patients with macular atrophy due to AMD or IMD were included.

In the atrophic IMD study the inclusion criteria were: (1) A diagnosis of inherited macular or retinal dystrophy with macular involvement, (2) VA of 6/36 (0.8 logMAR) or less in the study eye, (3) recent visual acuity of 6/12 or better within past 12 months in treatable eye, (4) over 25 years old, (5) fit for surgery and able to consent to surgery, and (6) fundus AF imaging and full-field ERG results suggestive of a localised macular disorder (i.e. normal mid-peripheral autofluorescence and presence of rod and cone full-field ERG responses).

For the atrophic AMD study the inclusion criteria were: (1) A diagnosis of dry AMD, (2) VA of 6/24 (0.6 logMAR) or less in the study eye, (3) evidence of recent loss of reading ability in the past 12 months in the study eye, (4) Over 50 years old, (5) fit for surgery and able to consent to surgery, (6) FAF imaging and full-field ERG results suggestive of a localised macular disorder.

For both studies, the exclusion criteria are: (1) inability to give informed consent, (2) inability to complete follow-up programme, (3) unfit for local or general anaesthetic, (4) inability to complete follow-up programme and (5) any other concurrent corneal, retinal or neurological pathology affecting central vision.

#### 3.1.1.2 Neovascular macular disease study

All patients with neovascular AMD who had undergone surgery with the intention of macular translocation or autologous RPE-choroid patch graft from January 2003 to December 2008 at Moorfields Eye Hospital were eligible. None of these patients were eligible to receive photodynamic therapy (available from September 2003) or intravitreal anti-VEGF agent (available in the NHS from August 2008) according to the National Institute of Clinical Excellence (NICE) guidelines. The first 12 cases from each group were chosen for comparison as the cases are matched in terms of surgical learning curves.

### 3.1.2 Surgical procedures

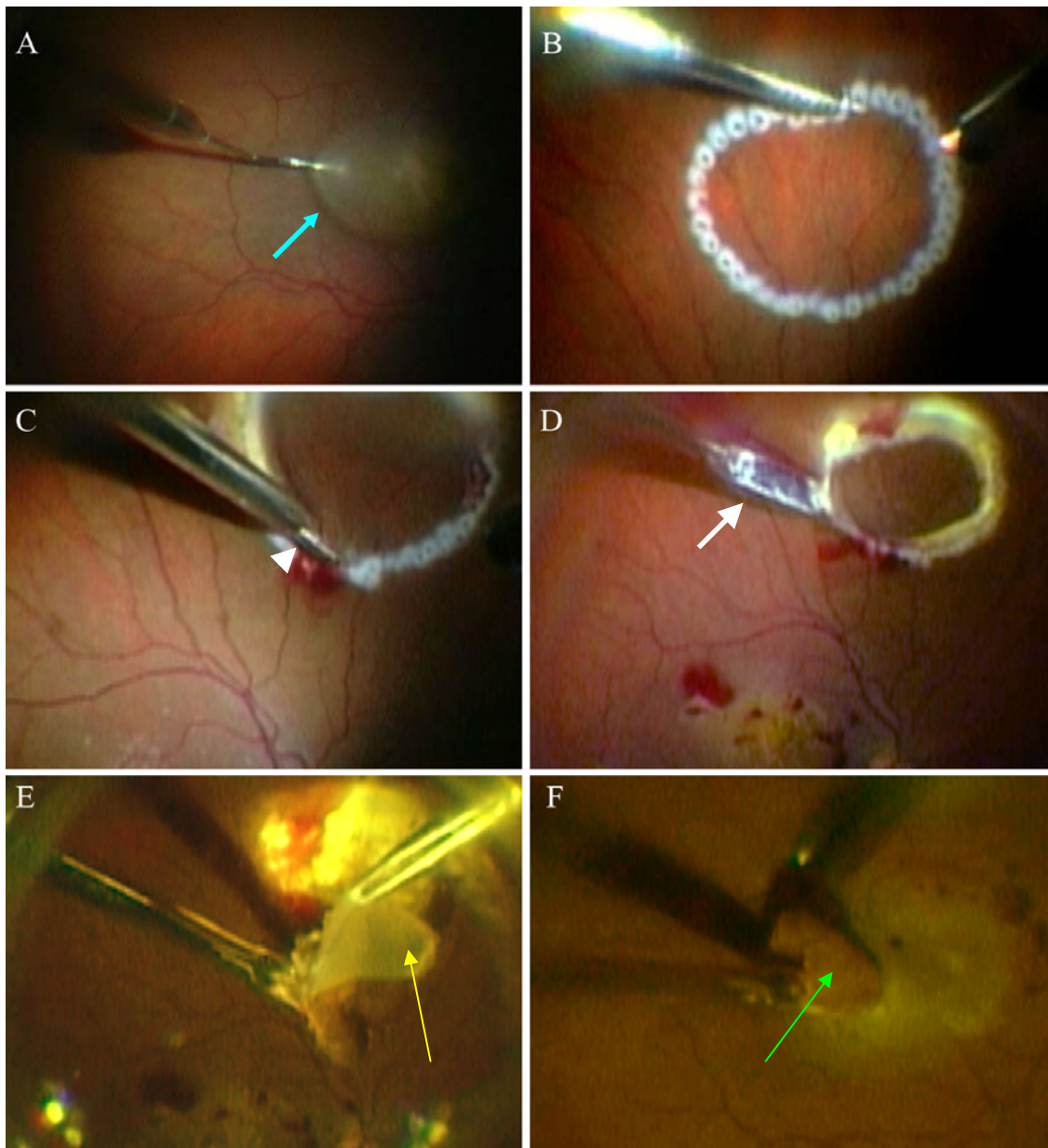
The surgical technique of autologous equatorial RPE-choroid patch graft in atrophic macular disease, and autologous RPE equatorial RPE-choroid patch graft and full macular translocation in neovascular macular disease are described below.

#### 3.1.2.1 Autologous equatorial RPE-choroid patch graft in atrophic macular disease

For atrophic macular disease, the technique is similar to that described by van Meurs and van den Biesen (2003) for neovascular AMD with the exception of the need to removal of CNV. All 9 patch grafts were carried out by Mr L. Da Cruz of Moorfields Eye Hospital.

A 3 port pars plana vitrectomy was performed followed by macular detachment through 1 or more punctuate retinotomies. Endodiathermy was applied to delineate a 3- to 4-mm circular region in the superior equatorial retina, which was subsequently cut out as a full-thickness RPE-choroid patch graft after removal of the overlying sensory retina by peeling (see **Figure 3.1**). The graft was gripped on the choroidal surface with a customised aspirating cannula designed by van Meurs (DORC Surgical Instruments, Zuidland, The Netherlands). A 5-ml syringe attached to the end of the cannula was used to create a sufficiently strong vacuum aspiration force to hold the graft. The graft was slid through the macular retinotomy into the subfoveal space. Gentle reflux of the syringe released the graft once in position. A 3- to 4-mm diameter perfluoro-n-carbon

heavy liquid bubble (Perfluoron, Alcon Laboratories Inc., Fort Worth, Texas, USA) was used to hold the graft during 2 to 4 further manipulations to ensure the graft unfolds correctly at a subfoveal position. Retinopexy was not applied to the macular retinotomy and the eye was filled with 1300 centi-stoke silicone oil (Oxane, Bausch and Lomb, Rochester, U.S.A.).



**Figure 3.1 Autologous RPE-choroid patch graft in atrophic disease**

Following pars plana vitrectomy, (A) the macula is detached (blue arrow) using a subretinal cannula. (C) The superior equatorial region is marked by endodiathermy and (D) full-thickness retina-choroid patch is cut out using a segmentation scissors (white arrow head). (E) The patch is loaded onto a specialised aspiration-reflux spatula (white arrow) and (E) the surplus retina (yellow arrow) is peeled and discarded. The RPE-choroid patch graft has a tendency to curl around the spatula due to its elasticity. (F) The patch graft (green arrow) is then inserted through an enlarged retinotomy into the submacular space.

After a minimum of 2 months, patients underwent phacoemulsification cataract surgery combined with silicone oil removal, performed by Mr L. Da Cruz, the author or one of the vitreoretinal fellows at Moorfields Eye Hospital.

#### 3.1.2.2 Autologous equatorial RPE-choroid patch graft in neovascular macular disease

For neovascular disease, the surgical technique of patch graft was similar to that described by van Meurs and Van Den Biesen (2003). Of the 12 patch grafts, 3 were performed by Mr G. W. Aylward and 9 were performed by Mr L. Da Cruz.

Briefly, after a complete 3 port pars plana vitrectomy, a superior equatorial donor site was chosen and delineated with contiguous argon laser photocoagulation. The CNV was removed through a superonasal or superotemporal macular retinotomy. The graft was cut out with vertical scissors and the overlying retina peeled with forceps. Using a custom made aspirating-reflux spatula (DORC, Netherlands), the graft was inserted into the submacular space and manipulated to a subfoveal location. The bleb retinal detachment was then flattened with perfluoro-n-octane heavy liquid (Perfluron, Alcon Laboratories Inc., Fort Worth, Texas, USA) and exchanged for silicone oil.

After a minimum of 2 months, patients underwent phacoemulsification cataract surgery combined with silicone oil removal. These were performed by Mr L. Da Cruz, Mr G. W. Aylward or one of the vitreoretinal fellows at Moorfields Eye Hospital.

#### 3.1.2.3 Full macular translocation in neovascular macular disease

For macular translocation in neovascular AMD, the surgical technique was similar to that described previously (Eckardt *et al.* 1999; Toth and Freedman 2001). All translocations were performed by a single surgeon (Mr L. Da Cruz, Moorfields Eye Hospital).

A phacoemulsification with intraocular lens (IOL) implant was performed; followed by vitrectomy, detachment of the posterior hyaloid and vitreous base shaving. Retinal detachment was induced using a flexible dual bore 41-gauge cannula (1270.0.100, Synergetics, St Louis, Missouri, USA) and extended to total detachment by 2 or 3 air-fluid exchanges. After creating a 360° retinotomy with the vitreous cutter, the temporal retina was flapped over the disc nasally, using Eckardt's ring-end forceps (1286-QM, DORC, Netherlands) to allow removal of the CNV and any subretinal blood. A small bubble of perfluoro-n-octane heavy liquid (Perfluron, Alcon Laboratories Inc., Fort Worth, Texas, USA) was then placed onto the disc to flatten the posterior pole. The Tano stiff diamond dusted membrane scraper (20.07. Synergetics, St

Louis, Missouri, USA) was used to grip the retinal surface and rotate the fovea away from the RPE defect. The entire vitreous cavity was filled with perfluorocarbon liquid followed by 360° endolaser retinopexy. The perfluorocarbon liquid was then directly exchanged for silicone, using a technique similar to that described by Li and Wong (2007).

Two months after translocation. Counter-rotation surgery was performed (Mr J. Lee or J. Acheson, Moorfields Eye Hospital) in combination with removal of silicone oil (Vitreoretinal Fellow, including myself in some cases) if the retina was flat. Counter-rotation involved 3 or 4 muscles depending on the angle of incyclotorsion. For excyclo-rotation of the globe, the superior oblique was disinserted, the medial rectus was repositioned inferiorly, the inferior oblique was advanced to the superior edge of lateral rectus and the lateral rectus was repositioned superiorly.

#### 3.1.2.4 Management of post-operative complications and follow-up schedule

Re-operation including repair of retinal detachment, removal of residual silicone oil, surgical iridotomy for pupil block and cataract extraction were performed by Mr L. Da Cruz. Proliferative vitreoretinopathy with retinal break was treated by membrane peeling, with or without retinectomy and gas or oil tamponade (Mr Lyndon Da Cruz). Intravitreal injections of anti-VEGF agents or steroid for treatment of macular oedema or recurrent CNV were performed by the retina fellows at Moorfields Eye Hospital.

For both the prospective and retrospective studies, all patients had a 6 and 12 month evaluation. The primary endpoint was at 6 months. Thereafter, patients were routinely followed 4 to 6 monthly. The 6 to 12 month outcomes have been published previously for the first 27 and 12 patients who underwent full macular translocation and RPE-choroid patch graft for neovascular AMD, respectively (MacLaren *et al.* 2007; Uppal *et al.* 2007).

### 3.1.3 Outcome measures and follow-up schedule

#### 3.1.3.1 Atrophic macular disease study

For the prospective trials, the **primary outcome measure** was surgical feasibility, i.e. the proportion of patients in whom submacular placement of the autologous RPE-choroid graft was achieved. **Secondary outcome measures** were intra-operative and post-operative complication rates, and macular function and structure.

Post-operative complication was assessed on slit-lamp examination including applanation tonometry and fundus biomicroscopy. Any pathology detected was further investigated and documented with various imaging modalities (see below).

Functional outcomes were measured using 3 types of clinical tests: psychophysical tests, electrophysiological recordings and questionnaires-based assessment (see **Table 3.1**). The main functional outcome measure was best-corrected distance VA. Other psychophysical measures included CS, reading ability and microperimetry (to provide information on fixation characteristics and retinal sensitivity). Objective assessment using electrophysiological techniques included full-field ERG, pattern ERG and multifocal ERG. Questionnaire used in the pilot study assessed visual function or general health related quality of life.

Detailed macular structure assessments were based on OCT scans, fundus AF image, and fundus photographs and angiographies in addition to fundus biomicroscopy. These imaging modalities complement fundus examination to provide further information on the status of outer retinal structures (in particular, outer nuclear layers and photoreceptor inner and outer segments), the presence of RPE and choroidal perfusion (see **Table 3.2**).

For the two clinical trials, functional and structural outcomes were assessed at baseline and again at 6 months post-operatively. If silicone oil was still in-situ at 6 months, formal assessment was delayed until 3 months after removal of oil. Quality of life questionnaire was administered at baseline and repeated after 12 months postoperatively.

**Table 3.1 Functional outcome measures in atrophic macular disease study**

<b>Psychophysical tests</b>	<b>Electrophysiological tests</b>	<b>QOL Questionnaires</b>
<u>Letter chart</u>	<u>Macular responses</u>	<u>Visual function-related</u>
Visual acuity	Pattern ERG	25-item National Eye Institute
Contrast sensitivity	Multifocal ERG	Visual Function
Reading ability		Questionnaire
	<u>Global retinal responses</u>	
<u>Microperimetry</u>		<u>General health-related</u>
Fixation locus	Full-field ERG	RAND 36-Item Health
Fixation stability		Survey <sup>TM</sup>
Retinal sensitivity		

ERG; electroretinogram, RAND; Research and Development Corporation, QOL; quality of life

**Table 3.2 Structural outcome measures in atrophic macular disease study**

Photoreceptor cells	Retinal pigment epithelium	Choroidal and retinal vasculature and perfusion
Optical coherence tomography (OPL, ONL, and HRB)	Fundus examination Fundus autofluorescence Optical coherence tomography (HRB)	Fundus biomicroscopy Indocyanine green angiography Fluorescein angiography

HRB; highly reflective band, ONL; outer nuclear layer, OPL; outer plexiform layer

### 3.1.3.2 Neovascular macular disease study

For the retrospective studies, the **primary outcome measure** was the mean change in VA of the operated eye from pre-operative to the most recent follow-up visit. **Secondary outcome measures** included the proportions of patients who gained 3 lines of VA (0.3 logMAR) or more, the median VA and proportions of patients who achieved a VA (logMAR) of 0.30, 0.70 or 1.00 or better (Snellen VA of 6/12, 6/30 or 6/60 or better) at the 1 year and the most recent visits.

**Exploratory analyses** were also conducted in a subset of patients to identify the causes of delayed visual loss and examine structure-function correlation in detail. These include:

1. The rate and causes of visual loss (> 0.2 logMAR decline in VA) after 1 year in those patients who achieved a VA of 1.00 logMAR or better.
2. The change in fixation stability and retinal sensitivity on serial microperimetry in the subset of patients with good VA outcomes or fixation on the patch graft. The retinal sensitivity change was examined in conjunction with features on serial fundus AF and OCT images.
3. A comparison of the difference in the change in VA at 1, 2 3 and 4 years between the first 12 patients from the macular translocation cohort and the 12 patients from the autologous RPE-choroid graft cohorts, respectively.
4. A comparison of microperimetry and macular AF from the 3 best cases (those with the best VA) of the 12 patients in each cohort as described above.

For structural outcome, all pre- and post-operative clinical documentation, fundus photographs, fundus angiographies, OCT and fundus AF images were reviewed to determine the occurrence of postoperative complications such as retinal detachment, intraocular haemorrhage, macular oedema, recurrent CNV and RPE atrophy.



### 3.1.4 Visual acuity and contrast sensitivity tests

All patients underwent refraction by optometrists at Moorfields Eye Hospital. Refracted VA and CS were measured by either the author or one of the hospital optometrists. Best-corrected distance VA was measured using a standardised protocol on the back illuminated ETDRS charts 1 and 2 (Lighthouse Low Vision Product, New York, NY, USA) for right and left eyes, respectively, starting at 4 metres (Ferris, III *et al.* 1982). The charts were mounted on a light box with an average luminance of 150 cd/m<sup>2</sup>. With the appropriate refractive correction in place for the study eye and occlusion of the fellow eye, the patient was instructed to read from the top of the chart and stopped only if 4 or more mistakes were made in a line. If less than 15 letters were read at 4 metres, the patient was moved forward to read at 1 metre from the chart after adding +0.75 D to the spherical prescription. The patient was stopped from read further when 6 lines were read at 1 metre. To calculate the letter score at 1 metre, 30 was added to the number of letters read at 4 meters. However, if less than 15 letters were read at 4 meters, letter scores from 4 metres was added the letter score from 1 metre (stopping at 6 lines). **Table 3.3** shows how letter score was converted to the logMAR unit (Holladay 2004). For patients who could not see any letter from 1 metre, but could only count fingers or only perceive hand motions at 30 cm, VA was assigned 1.98 or 2.28 logMAR respectively as recommended by Lange and colleagues (2009).

CS was measured using a standardised protocol on the wall mounted Pelli-Robson contrast sensitivity charts (Clement Clarke Inc., Columbia, OH, USA) at 1 metre with chart luminance of 80-120 cd/m<sup>2</sup> (Pelli *et al.* 1988). The right eye was tested followed by the left eye on charts 1 and 2 respectively with +0.75D added to the spherical prescription. The patient was asked to name each letter on the chart starting with the high contrast letters on the upper left-hand corner. The test was stopped when the patient failed to correctly identify 2 or more letters correctly in a triplet. The letter-by-letter scoring was used to minimise test-retest variability (Elliott *et al.* 1990). Letter score was converted to logCS by assigning 0.05 logCS to each letter read except for the first line.

For retrospectively studies, some of the VA measurements were performed on the Snellen chart from 6 metres in the vitreoretinal clinic. Snellen VA fractions were converted to their equivalent measures in logMAR (see **Table 3.3**).

**Table 3.3 Conversion between Snellen fraction and logMAR**

ETDRS Letters at 1 metre	Snellen Fractions at 6 metres	logMAR
85	6/6	0.00
76	6/9	0.18
70	6/12	0.30
61	6/18	0.48
55	6/24	0.60
46	6/36	0.78
35	6/60	1.00
20	3/60	1.30
11	2/60	1.48
0	1/60	1.80
0	CF	1.98*
0	HM	2.28*

CF; counting fingers at 2 feet, ETDRS; early treatment for diabetic retinopathy study, HM; hand motions, logMAR; logarithim of minimum angle of resolution, NPL; no perception of light.

\*LogMAR equivalents for counting finger vision and hand motion perception were based on the results from the study by Lange *et al.* (2009)

### 3.1.5 Reading ability test

Reading ability was measured using the MNRead acuity charts (Lighthouse Low Vision Product, USA) at 25 centimetres (Legge *et al.* 1989). All reading tests were carried out by the author. The patient wore distance correction with a +4.00 D added to the trial frame and occluder to the fellow eye. Testing was performed in a well lit room with chart luminance of 100 cd/m<sup>2</sup> and the patient seated. Patients were instructed to read the sentence aloud as each sentence was uncovered. A stop watch was used to record the time taken to read each sentence. Words which were read incorrectly were marked. RA is a measure of the smallest print that can be read. The following formula (3.1) was used to calculate RA when the chart was read from 25 cm:

$$RA = 1.6 - (\text{sentences} \times 0.1) + (\text{errors} \times 0.01) \quad (3.1)$$

Reading rate increases as the print size increase from RA (Legge *et al.* 1985a; Legge *et al.* 1985b). However, when the critical print size (CPS) is reached, the reading rate remains constant at around the maximum reading speed (MRS). The reading speed (RS) in words per minute for each sentence can be calculated from the formula (3.2):

$$RS = 60 \times (10 - \text{errors}) / (\text{time in seconds}) \quad (3.2)$$

In the presence of a plateau of RS, the MRS is defined as the mean of 3 highest reading speeds at the plateau and CPS is defined as the smallest print size that supports at least 90% of the MRS.

### **3.1.6 Microperimetry**

Microperimetry and fixation test were performed by the author using the Nidek MP 1 (NAVIS software version 1.7.2; Nidek Technologies, Padova, Italy) microperimeter (Midea *et al.* 2004). This technique allows quantitative and qualitative assessments of retinal sensitivity and fixation characteristics and examination of their relationships with specific fundus structures. It is, therefore, a subjective test of retinal function but also allows direct structure-function correlation.

The Nidek MP 1 allows the operator to view the fundus on the computer monitor as it is imaged in real time by an infrared (IR) fundus camera (768 x 576 pixels resolution; 45° field of view). Fixation target and stimuli are projected on to a liquid crystal display within the instrument for the subject to see. The operator can also view the stimulus and fixation target as part of the retinal image on the computer monitor. Background luminance is set on 4 apostilb (1.27 cd/m<sup>2</sup>). Stimulus intensity may be varied in 1 dB (0.1 log) step scale from 0 to 20, where 0 dB represents the brightest luminance of 400 apostilb (127 cd/m<sup>2</sup>). MP1 also provides an automated tracking system to compensate for any eye movement.

At the beginning of each examination, an infrared retinal image is captured and frozen to allow retinal areas with high contrast to be chosen for tracking. This reference landmark is tracked every 40 ms (25 Hz). The stimulus position on the display is then corrected according to the actual location of the fundus to allow sensitivity threshold testing at the same retinal locus during the microperimetry examination. A CCD colour camera within MP1 also enables acquisition of digital colour retinography (1392 x 1040 pixels resolution; 45° field of view; Xenon flash) at the end of the examination. Both the microperimetry map and fixation scatter plot can be overlaid onto this colour fundus

image through automated or manual registration of two reference retinal landmarks. Fundus AF image, angiography and reconstructed en-face image from OCT scans can also be imported into the software for overlay of microperimetry data.

Slit lamp examination, and fundus photography and angiography were avoided prior to microperimetry examination. In all patients, pupils were dilated with one drop each of tropicamide 1% and phenylephrine 2.5%. The non-tested eye was patched during the test and the room light was switched off to avoid glare. Fixation and retinal sensitivity testing procedures are outlined below.

### 3.1.6.1 Fixation test

In general, a red or white cross spanning 2° was used as the fixation target during fixation test. The patient was instructed to look for a cross target and remain looking at the centre of target while position of the fundus was tracked for 30 seconds. Fixation analysis considers three aspects: (1) stability, (2) eccentricity from the center of fovea and (3) number of preferred retinal locus.

Stability can be quantified by calculation of the bivariate contour ellipse area (BCEA) as proposed by Steinman (1965) or by the proportion of fixation points within a set distance from the gravitational center of all fixation points as proposed by Fujii *et al.* (2003)

The BCEA method is based on the assumption that eye movements during fixation generate a bivariate normal distribution in x and y axis (coronal plane). This area corresponds to a preset proportion of the region on retinal surface where the patient uses to fixate on the center of the target. Equation 3.3 is used to calculate the area:

$$BCEA = 2k\pi\sigma_H\sigma_v(1 - \rho^2)^{1/2} \quad (3.3)$$

where  $\sigma_H$  is the standard deviation of point location in the x axis,  $\sigma_v$  is the standard deviation of point location over the y axis and  $\rho$  is the product-moment correlation of these two position components. The constant,  $k$ , is related to the preset proportion of the retinal region used for fixation,  $P$ , by equation 3.4:

$$P = 1 - e^{-k} \quad (3.4)$$

Similar to previous studies, fixation stability was calculated with  $P = 0.68$  ( $k = 1.14$ ). The BCEA is expressed in minarc<sup>2</sup>. Although global BCEA has been widely used, it

validity has been questioned due to non-Gaussian distribution of the fixation loci and closely located multiple PRL (Timberlake *et al.* 1982; Crossland *et al.* 2004b; Reinhard *et al.* 2007; Tarita-Nistor *et al.* 2008).

The second method of quantifying fixation stability was originally described by Fujii *et al.* (2003); eyes with more than 75% of the fixation points located within the 2° diameter circle are classified as having stable fixation. If less than 75% of the fixation points are located within 2° diameter circle, but more than 75% of the fixation points are located within 4° diameter circle, they are classified as having relatively unstable fixation. If less than 75% of fixation points are located within 4° diameter circle, the fixation pattern is described as being unstable.

In patients with macular scotoma involving the fovea, they adapt by using non-foveal retina for fixation and reading. This alternative eccentric position on the retina is called preferred retinal locus or PRL (Timberlake *et al.* 1987). A classification of eccentricity of PRL (also used by Nidek MP1) is one that has been described by Fujii *et al.* (2003) Predominantly central fixation is defined by more than 50% of fixation points within the 2° diameter centered at the fovea. Eyes with poor central fixation had more than 25% but less than 50% of the fixation points within the central 2° diameter whereas those with predominant eccentric fixation had less than 25% of the preferred fixation within the same region. The location of fovea is often difficult to identify. However, using spectral domain OCT and fundus overlay, the centre of fovea can be estimated based on the surface contour and internal retinal structures of the OCT scan and then marked on the colour fundus image. Once this image is imported into the NAVIS software and registered with the fixation map, the eccentricity of PRL can be classified.

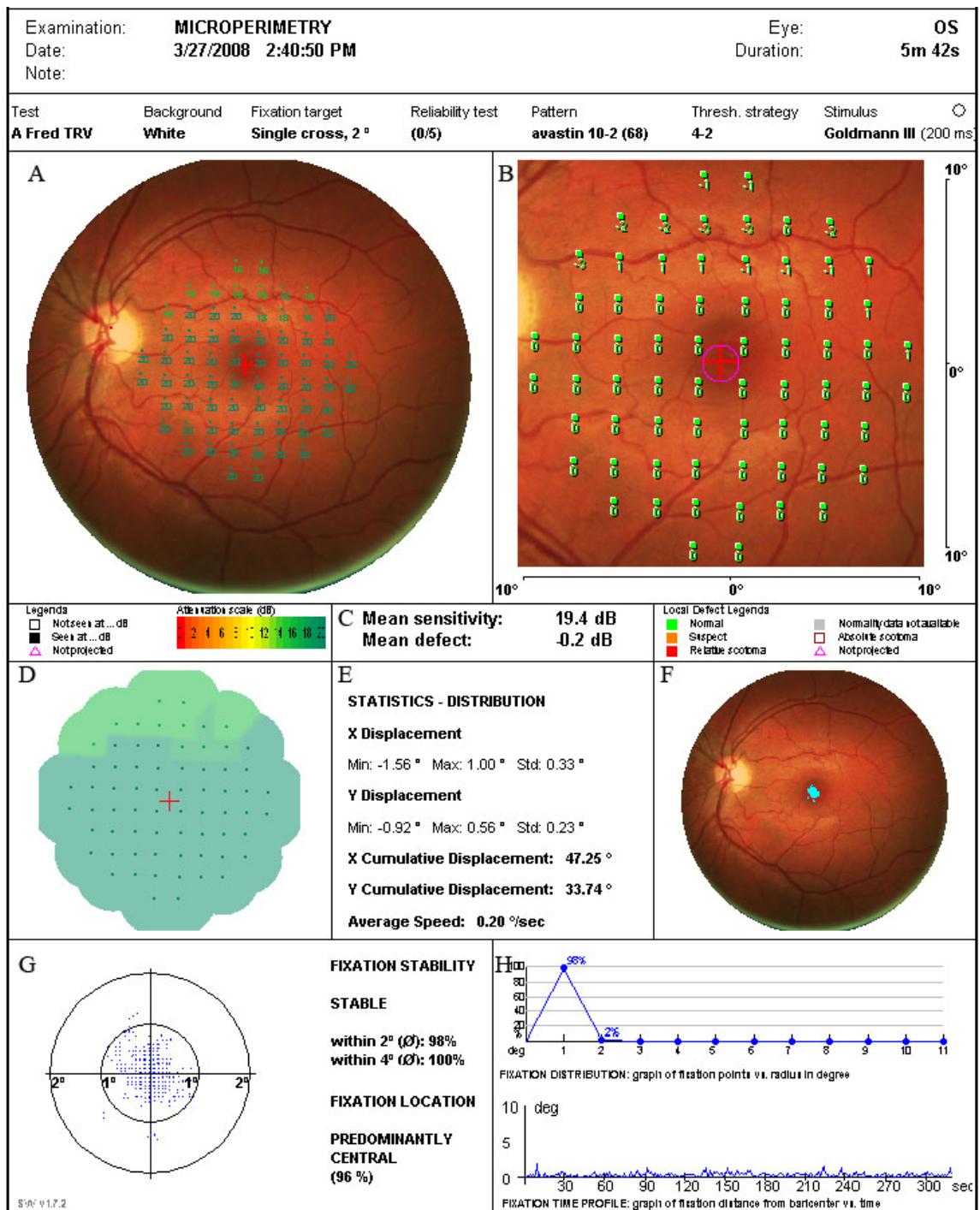
Change in location of PRL can be measured by comparing the fixation map across visits using the onboard NAVIS software. PRL may shift due to disease progression, natural adaptation or fixation training (Crossland *et al.* 2005a; Deruaz *et al.* 2006; Tarita-Nistor *et al.* 2008). Many patients develop more than 1 PRL used for different lighting conditions, target size, visual tasks and other unknown factors (Lei and Schuchard 1997; Duret *et al.* 1999; Crossland *et al.* 2004b; 2005a; Reinhard *et al.* 2007; Sullivan *et al.* 2008). PRLs which are far from each other can be seen readily on the fixation scatter plot.

### 3.1.6.2 Retinal sensitivity test

For microperimetry, 4-2 strategy was used as recommended by Convento and Barbaro (2007) to reduce testing time. The stimulus size was set at either Goldman III (area of 4

mm<sup>2</sup>, diameter of 26 min arc or 0.4 degrees) or V (area of 64 mm<sup>2</sup>, diameter of 104 min arc or 1.6 degrees) and the duration at 200 ms. Two types of test grids were used. To test retinal sensitivity over the graft specifically, the polygon setting was chosen to allow manual selection of the test region and density of the test grid. To measure the overall macular function, standardised test grids covering the central 20° were used; either the 68-loci grid similar to the 10-2 program of Humphrey automated perimeter or the 76-loci grid (macula 20°) available with the software. The “activate pre-test” and “eccentric pattern” options were selected to enable appropriate starting threshold as determined by 4 pre-selected test loci in each quadrant and manual centering of the testing grid. In eyes with unstable and eccentric fixation, the algorithm recommended by Sunness *et al.*, was used for predicting the location of foveal center (1999a). The refinement and recheck option were not used.

The Nidek MP1 onboard software provides an analysis output after the operator determines the location of the fovea (see **Figure 3.2**). Absolute retinal sensitivity is displayed for the individual 68 test loci and as an average for the central 20°; mean or macular sensitivity. The software also compares the absolute sensitivity to a normative database derived from 180 healthy volunteers stratified into 6 age groups to calculate the deviation (in dB) from normal (Convento and Barbaro 2007). The local deviation from normal is shown in the local defect map and the average deviation for the central 20°, mean or macular deviation is also displayed. Loci with sensitivity within 2 standard deviations (SD) were classified as normal. Those between 2 and 3 SD, between 3 SD and 0 dB seen, and 0 dB not seen, were categorised as ‘suspect’, ‘relative scotoma’ and ‘dense scotoma’ respectively. The local defect map also provides colour-coded information on the severity of sensitivity loss in one of the 4 categories (Convento and Barbaro 2007).



**Figure 3.2 Normal microperimetry examination printout**

This is a normal microperimetry in a 31 year old subject. The printout displays (A) the retinal sensitivity map, (B) the local defect map, (C) the mean sensitivity and mean defect in decibel (dB), (D) the colour coded sensitivity map, (E) summary statistics of fixation performance during microperimetry, (F) fixation loci plot in relation to fundus image, (G) fixation loci plot in relation to gravitational centre of all loci and (H) graphical display of fixation stability.

### 3.1.7 Electrophysiology

The electroretinogram (ERG) waveforms are generated by the retina in response to a light stimulus. The various types of ERG responses are determined by the vector summation of the electrical currents, arising from synaptic junctions and ion channels of the photoreceptor cells, the various neuronal cells and the Müller cells, relative to the position of the recording electrodes. The ERG, therefore, allows objective measurement of various aspects of retinal function.

Electrophysiological testing was performed by the department of electrophysiology at Moorfields Eye Hospital. Results were interpreted by Professor Graham Holder, Dr Anthony Robson and Dr Magella Neveu from the same department. The pattern ERG (PERG), multifocal ERG (mfERG) and full-field ERG were recorded under conditions which incorporated the international standards and guidelines published by the International Society of Clinical Electrophysiology of Vision (ISCEV) (Bach *et al.* 2000; Marmor *et al.* 2003; Marmor *et al.* 2004; Holder *et al.* 2007; Hood *et al.* 2008). First, the PERG was recorded with the patient optimally refracted. The patient's eyes were then dilated for the recording of the full-field and multifocal ERGs. The responses were recorded binocularly using gold foil corneal electrodes referenced to surface electrodes at the ipsilateral outer canthi. The ground electrode was positioned on the forehead.

#### 3.1.7.1 Pattern ERG

The PERG response is recorded to a reversing black and white checkerboard pattern stimulus. This is projected onto central retina without net change in stimulus luminance (see **Figure 3.3A**). PERG is clinically useful to objectively (1) distinguish optic nerve from macular dysfunction and (2) detect and quantify the severity of macular involvement in generalised retinal dysfunction (Holder 2001).

The PERG was evoked by a high contrast checkerboard reversal pattern (check size of 45 minarc) covering a field of 15° x 11°, at a rate of 4.5 reversals per second, with 98% contrast and a mean luminance of > 80 cd/m<sup>2</sup>. The amplifier gain was set to 200 x 10<sup>3</sup> and band pass filtered (1-100 Hz). The patient was asked to fixate on a red central fixation target and fixation was monitored using CCTV (closed circuit television). The PERG waveform was analysed in terms of the amplitude of the P50 and N95 components and the latency of the P50 component. The P50 component was of particular interest in assessment of patients receiving RPE transplant as it is partly driven by elements distal to the ganglion cells (Holder 2001).



### 3.1.7.2 Full-field ERG

The full-field ERG is a mass response of the retina to a lumance stimulus. Under dark adapted (scotopic) condition, a bright flash stimulus generates an ERG waveform which consists of an early negative wave (the a-wave) which is largely generated from the rod photoreceptor cells (Breton *et al.* 1994; Hood and Birch 1993b) and a later but larger positive wave (the b-wave) which arises from post-phototransduction activity (Knapp and Schiller 1984). A dim flash stimulus in scotopic condition generates the “rod specific ERG” which screens for rod system dysfunction (see **Figure 3.3B**). A bright flash stimulus is required to generate the “bright flash ERG” which consists of an a-wave and a b-wave and this measures function of the photoreceptor cells (a-wave) and inner retina (b-wave). Under light adapted (photopic) conditions the rod system is suppressed and cone system function is assessed using a 30 Hz flicker stimulus (30 Hz flicker ERG) and a 2 Hz stimulus (single flash photopic ERG). These ERG responses are generated primarily by the ON- and OFF- bipolar cells (Bush and Sieving 1996). Similar to the bright flash ERG, the b-wave of the single flash photopic ERG is generated from the inner retina (Heynen and van Norren 1985; Bush and Sieving 1994). However, the a-wave component of the bright flash ERG has a small contribution from the cone photoreceptor cells as well as the cone OFF-bipolar cells (Bush and Sieving 1994; Hood and Birch 1993a).

For full-field ERG testing, the patients’ pupils were dilated with phenylephrine 2.5% and tropicamide 1% and the patient was dark adapted for 20 minutes. An extended ERG protocol was recorded which incorporated the ISCEV standards: (1) the rod-specific ERG response to a dim white flash, (2) the bright flash ERG response to a standard white flash, and after 10 minutes of light adaptation to a rod-suppressing background illumination, (3) the 30Hz flicker ERG and (4) the single flash photopic ERG. At Moorfields Eye Hospital, responses to flash intensities other than those specified by ISCEV standards were also recorded (see **Table 3.4**). The amplifier gain was set to  $2 \times 10^3$  or  $5 \times 10^3$  and band pass filtered (0.5 to 3,000 Hz). The sampling interval was 0.5 ms and analysis time was 200 ms (100 ms for photopic ERGs). The patient was asked to look straight ahead, refrain from blinking and keep their lids wide open. The ERG components were analysed in terms of the amplitudes of the a-wave and b-wave as well as the implicit time of these components measured from the onset of the flash.

Full-field ERG was performed to detect subclinical pathology in the peripheral and equatorial retina. To ensure that autologous equatorial RPE is relatively healthy, we excluded patients with severe generalised retinal dysfunction. Furthermore, the ERG is used to objectively assess the effects of surgery on cone and rod system function in patients who may not have detectable generalised retinal dysfunction.

**Table 3.4 Summary of electrophysiological testing protocol**

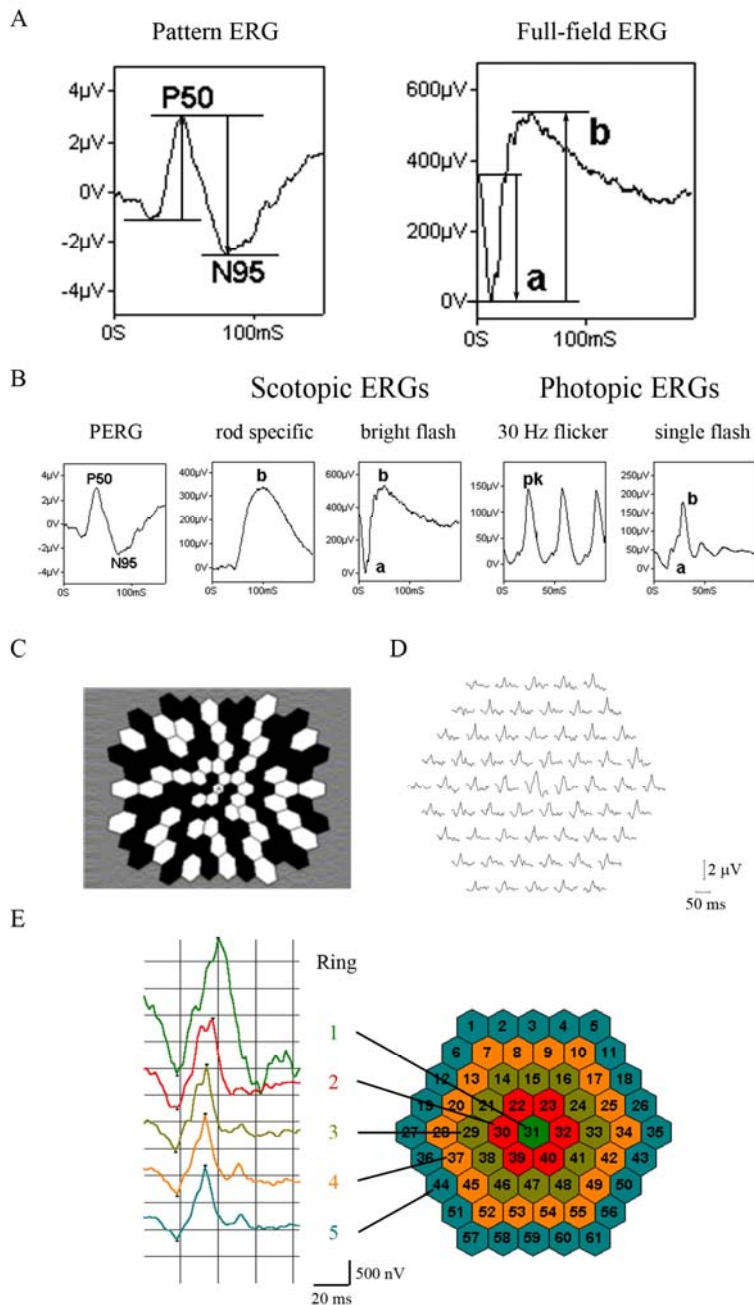
ISCEV ERG	Step	Flash Colour	Flash Intensity cd/s/m <sup>2</sup>	Stimulus Interval (seconds)
<b>Dark adapt for 20 minutes</b>				
<b>Rod response</b>	1	white	0.0010	2
	2	white	0.0022	2
	3	white	0.0120	5
	4	red	0.20	2
	5	red	0.30	2
	6	white	0.14	10
	7	white	0.50	10
	8	white	1.30	10
<b>Maximal</b>	9	white	3.00	15
	10	white	4.43	15
<b>Bright flash</b>	11	white	11.5	20
<b>Light adapt for 10 minutes</b>				
<b>(background light at 25 cd/m<sup>2</sup>)</b>				
<b>Cone flicker</b>	12	white	3.0	
<b>Single flash</b>	13	white	3.0	

cd; candela, ERG; electroretinography, ISCEV; International Society of Clinical Electrophysiology of Vision, m; metre, s; second

### 3.1.7.3 Multifocal ERG

The mfERG is an array of localised cone-driven ERG signals that are recorded under photopic conditions (see **Figure 3.3C**). The responses are a mathematical extraction of local signals derived from the correlation between a pseudo-random sequence of flashing hexagonal elements (see **Figure 3.3C**) and the continuous ERG response recorded at the cornea (Sutter and Tran 1992). Although the waveform of the mfERG response (first-order kernel) resembles the conventional ERG, the peaks are designated by n1 and p1 instead of the a-wave and b-wave (Hood *et al.* 2008).

The mfERG was recorded and analysed using the RETIscan System version 3.1 (Roland Consult, Wiesbaden, Germany) with the patient fully dilated and a +3.00 D lens was added to the patient's refraction (if present) for recording. The stimulus used consisted of an array of 61 flashing hexagons, displayed on a computer monitor, covering a visual field of 56.9°, at a viewing distance of 33 cm. Patients were asked to fixate on the centre of a large cross-hair fixation target which was centred on the central hexagon. Patients who could not see the fixation target clearly were asked to maintain fixation on the assumed centre of the cross-hair. Patient fixation was monitored by direct observation. The stimulus-distortion factor was set to 4 to compensate for differences in cone density across the retina, from centre to periphery. The amplifier gain was set to  $100 \times 10^3$  or  $200 \times 10^3$ , and band-pass filtered (5–300 Hz). Eight trials were recorded for each mfERG session, and the average recording time for each trial was between 1 and 2 minutes. The total duration of a recording session was approximately 20 minutes or less. These techniques are similar to those used in previous studies (Bellmann *et al.* 2004; Neveu *et al.* 2006). Quantitative analyses were performed with the RETIscan system software. The n1 and p1 components of the first-order kernels were considered for mfERG evaluation (Hood and Zhang 2000). The 61 local mfERG responses were grouped into 5 concentric ring groups (see **Figure 3.3E**) of equal eccentricity centred on the fovea. These groups were defined as follows: ring 1 (central hexagon), from 0° to 2.1° eccentricity; ring 2, from 1.4° to 6.7° eccentricity; ring 3, from 5.7° to 12.0° eccentricity; ring 4, from 9.5° to 19.8° eccentricity; ring 5, from 15.1° to 28.5° eccentricity. For each ring group, the traces were averaged and the peak amplitude and the implicit time of p1 and n1 from each ring were analysed. Results of peak amplitude and implicit time were compared with normative values ranging between the 5th and the 95th percentiles. Information gained from mfERG was used to complement microperimetry results by objectively quantifying retinal function rescue in RPE transplantation.



**Figure 3.3 Normal PERG, full-field ERG and mfERG waveforms.**

Schematic diagrams of (A) pattern electroretinography (PERG) and bright flash ERG waveforms. PERG response consists of the P50 and N95. The P50 is generated from both the ganglion cells and cells distal to them in the central retina whereas the N95 is predominantly generated from the ganglion cells. The bright flash ERG response consists of the a-wave and b-wave. The a-wave is generated from photoreceptor cells and the b-wave is generated in the inner retina. (B) Composite of waveforms showing PERG and 4 types of full-field ERG recordings as recommend by the International Society of Clinical Electrophysiology of Vision (ISCEV). Under scotopic condition, the rod specific and bright flash ERG are recorded and under photopic conditions, the 30Hz flicker and single flash ERGs are recorded. (C) The mfERG stimulus pattern with 61 white and black elements. (D) First-order kernels were extracted for each locus. (E) The 5 concentric ring groups used for analysis. The n1 and p1 waves are cone pathway responses. The peak amplitude and the peak times are analysed for each ring group.

### 3.1.8 Quality of life questionnaire

To provide additional information on outcomes of surgical intervention, patients' perception of quality of vision (QOV) and health-related QOL were also assessed using the 25-item National Eye Institute Visual Function Questionnaire (NEI VFQ-25) and the RAND 36-Item Health Survey (version 1.0). Both of these were administered by the author or the research co-ordinator, before and approximately 1 year after surgery.

The NEI VFQ-25, a vision-targeted measure of QOL, consists of 25 of the 51 questions in the previous longer version of the questionnaire (Mangione *et al.* 1998; Mangione *et al.* 2001). The answer for each item was converted to a score ranging from 0 to 100 and the scores from item(s) that contribute to each of the 12 subscales were averaged to give the subscale scores. These 12 subscales can be grouped into 3 categories. The first category is a general health subscale (1 item) that was not used because the RAND 36-Item Health Survey was also administered to all patients. The second category contains 5 subscales that address patients' perception of their QOV, including (1) general vision (1 item), (2) difficulty with distance tasks (3 items), (3) difficulty with near tasks (3 items), (4) peripheral vision (1 item), and (5) colour vision (1 item) subscales. The remaining 6 subscales; (1) dependency (3 items), (2) role limitations (2 items), (3) mental health (4 items), (4) social function (2 items), (5) driving (2 items), and (6) ocular pain (2 items) subscales are incorporated into the third category which assess patients' perception of vision specific QOL. Reliability and validity of the NEI VFQ-25 has been reported (Mangione *et al.* 2001).

The RAND 36-Item Health Survey (version 1.0), a measure of general health QOL, consists of the 36 questions identical to the Medical Outcome Study 36-Item Short-Form Health Survey (Ware, Jr. and Sherbourne 1992) but has a different scoring method (Hays *et al.* 1993). The answer for each item was converted to a score ranging from 0 to 100 and the scores from items that contribute to each of the 8 subscales were averaged to give the subscale scores. These 8 subscales are: (1) physical functioning (10 items), (2) role limitations due to physical health (4 items), (3) role limitations due to emotional problems (3 items), (4) energy/fatigue (4 items), (5) emotional well-being (5 items), (6) social function (2 items), (7) pain (2 items), and (8) general health (5 items). Included in the questions is also a single item that provides indication of patient's perception of change in health during the previous 12 months. Reliability and validity of the RAND 36-Item Health Survey has been reported (Bousquet *et al.* 1994).

### 3.1.9 Fundus confocal scanning laser ophthalmoscopy

Fundus AF was captured by using a scanning laser ophthalmoscope – the Heidelberg Retina Angiograph II (HRA II) or the Spectralis OCT+HRA (Heidelberg Engineering GmbH, Dossenheim, Germany). These were performed by the author or one of the medical photographers at Moorfields Eye Hospital. A series of 5 to 15 images over a 30° or 45° fields were acquired and then aligned and averaged with the image analysis software provided with HRA II (Heidelberg Eye Explorer, Heidelberg Engineering GmbH, Dossenheim, Germany). Fundus AF images were descriptively analysed for distribution, pattern and intensity of AF signals in the macular region. Low and high AF signals were interpreted in conjunction with clinical features and findings on OCT and fundus angiography (Schmitz-Valckenberg *et al.* 2008). A normal AF image is shown in **Figure 3.4**. Note the lack of AF signal over the disc and blocking of AF signals by haemoglobin within the retinal vasculature and macular xanthophylls at the foveal centre.

### 3.1.10 Optical coherence tomography

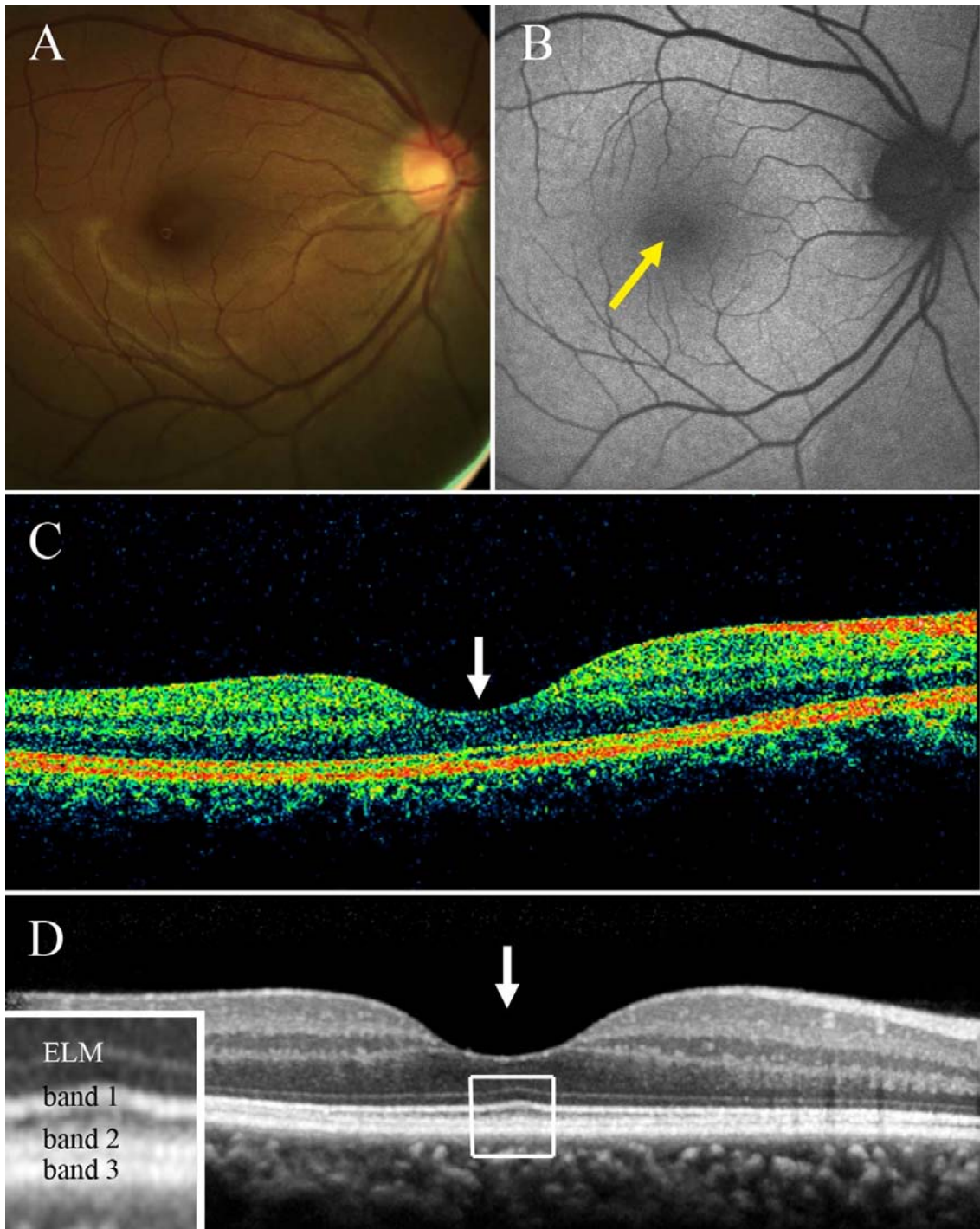
Both time- and spectral-domain optical coherence tomography (OCT) were used during the course of the studies (see **Figure 3.4**). These were performed by the author or one of the medical photographers at Moorfields Eye Hospital. For the time-domain Stratus OCT™, software version 4.0 (Carl Zeiss Meditec, Inc., Dublin, CA, USA), the 6 radial-line scan protocol was used to obtain 6 mm B-scans consisting of 512 A scans each, centred at the fovea. Three types of spectral-domain OCT instruments were used during the study. For SOCT Copernicus, software version 1.35 (Optopol Technology Sp. z o.o., Zawiercie, Poland), a raster-line scan protocol was used to cover an area of 6 x 6 mm (120 x 530 axial scans, vertical x horizontal). For Topcon 3D-OCT 1000, software version 2.12 (Topcon, Tokyo, Japan), a raster-line scan protocol was also used to cover an area of 6 x 6 mm (512 x 126 axial scans, vertical x horizontal). Centre point foveal thickness was measured manually using the caliper provided by the on-board software. A subset of patients also had simultaneous fundus AF imaging and SD-OCT scanning using Spectralis®. Integrated eye tracking capability (TruTrack™) within the Spectralis® enables pixel to pixel registration between the fundus AF image and the SD-OCT line-scan that was acquired simultaneously. To enhance signal to noise ratio, 30 to 100 single-line OCT frames were averaged during simultaneous fundus AF and SD-OCT imaging. In each eye, several OCT line-scans through separate regions with increased AF were obtained to examine the retinal architectural correlates to regions of

abnormal AF signals. The 3 highly reflective bands (see **Figure 3.4**) in the outer retina were interpreted as suggested by Drexler and colleagues (2001; 2003)

Presence of epiretinal membrane, intraretinal cysts, retinal thickening, retinal atrophy (loss of outer plexiform layer and the interface between inner and outer segment of the photoreceptor cell layer), subretinal fluid, RPE layer irregularity or thickening and full-thickness macular hole were recorded.

### **3.1.11 Digital fundus photography and angiography**

Digital colour photography, and fluorescein and indocyanine green (ICG) angiography (TRC-50 IA/IMAGE net H1024 system, Topcon, Tokyo, Japan) were performed by the medical photographers at Moorfields Eye Hospital. Five ml of 2g/ml sodium fluorescein and 5 ml of 5mg/ml ICG were injected intravenously for fundus angiographies. Early fluorescein images were examined for choriocapillaris flush. Early ICG images were examined for intrinsic vascular pattern within the graft. Late ICG images were examined for leakage from choroidal polyps and/or associated branching vascular network. Baseline lesion characteristic and size in disc area were graded by an independent masked observer (Dr PJ Patel, Moorfields Eye Hospital) according to the MPS criteria (MPS Group 1991).



**Figure 3.4 Non-invasive fundus imaging**

(A) Colour fundus photograph, (B) Fundus autofluorescence image, (C) time domain optical coherence tomography (OCT) scan and (D) spectral domain OCT scan through the foveal centre (white arrows pointing towards the foveal dip) of the right eye of a healthy 32 year old subject. Reduced autofluorescence signal at the foveal centre (yellow arrow, B) is due to absorption of excitation light by the macular xanthophylls. The faint reflective line and the 3 highly reflective bands (bottom left insert) at the level of outer retina represent the external limiting membrane (ELM), the interface of inner and outer segment of photoreceptor layer (band 1), the interdigitation between the tips of the outer segments and the apical microvilli of the pigment epithelium (band 2) and the retinal pigment epithelium (band 3). Anterior to the ELM is the hyporeflective outer nuclear layer.



### 3.2 Animal experiment and design

The pig was chosen as the recipient for RPE transplantation because the anatomy and physiology of the pig eye is similar to that of the human eye. The pig eye has a large vitreous cavity relative to the lens, thus allowing the use of modern vitrectomy surgical approach. The pig retina is holangiotoxic with a specialised region, area centralis, dorsal to the disc which is devoid of large blood vessels and contains high density of cones (Gerke Jr *et al.* 1995; Chandler *et al.* 1999). Furthermore, full-field and mfERG of the pig eye have been characterised (Rosolen *et al.* 1999; Kyhn M.V. *et al.* 2007) and the distribution of the 2 types of cones has been reported (Hendrickson and Hicks 2002). Recent works in porcine cell mediated immune system (Gerner *et al.* 2008; Piriou-Guzylack and Salmon 2008) and pharmacology of cyclosporine (Cibulskyte *et al.* 2005; 2007a; 2007b) may also enhance our interpretation of the outcomes of subretinal xenotransplantation. The pathophysiological changes following bleb retinal detachment (Jackson *et al.* 2003; Lewis *et al.* 2005; Iandiev *et al.* 2006; Hollborn *et al.* 2008), RPE debridement (Del Priore *et al.* 1995; Kiilgaard *et al.* 2007) and choroidal neovascularisation (Kiilgaard *et al.* 2005; Lassota *et al.* 2006; 2007; 2008) in pigs have been studied extensively. The availability of porcine model of retinitis pigmentosa (Petters *et al.* 1997; Tso *et al.* 1997) will also facilitate proof of principal experiments of retinal cell replacement therapy in a large animal model.

Seven to 9 week old female domestic pigs were used. The left eyes were operated and the right eyes served as controls with the exception of 1 pig which had bilateral surgery. A series of 4 experiments were carried out as summarised in **Table 3.5**.

#### 3.2.1 Home Office approval

This study was reviewed and approved by the Animals (Scientific Procedures) Inspectorate of the UK Home Office Animals Scientific Procedures Division in November 2007 (565-07: cellular therapy for eye disease). The abstract can be found on the webpage:

<http://scienceandresearch.homeoffice.gov.uk/animal-research/publications-and-reference/001-abstracts/abstracts2-2007/>

All procedures were performed by personal licence holders, in accordance with the Animals (Scientific Procedures) Act 1986.

**Table 3.5 Summary of pig experiments**

<b>Experiment</b>	<b>Number of animals</b>	<b>Immuno-suppression</b>	<b>Purpose</b>	<b>Dates of surgery</b>
<b>1</b>	3	Yes	Surgical feasibility	December, 13-14 <sup>th</sup> 2007
<b>2</b>	6	Yes/No	Long term survival	April, 3 <sup>rd</sup> -4 <sup>th</sup> 2008
<b>3</b>	7	Yes/No	Short term survival and immunology	November, 12-13 <sup>th</sup> 2008
<b>4</b>	5	No	Control study and immunology	December, 4 <sup>th</sup> 2008

### **3.2.2 Human embryonic stem cell lines**

Once removed from cryopreservation, hESC line (Shef-1), from Sheffield University, was maintained for up to 74 passages with media changes every 2 days. This cell line was maintained in flasks coated with 0.1% gelatine and seeded with mitomycin C-inactivated CF-1 mouse embryonic fibroblast (MEF) feeders as described previously (Draper and Andrews 2002). Cells were maintained in basic hESC medium: high glucose (4.8g/L) KnockOut™ Dulbecco's modified Eagle's medium (KnockOut™ D-MEM, Invitrogen) with 20% KnockOut™ serum replacement (KnockOut™ SR, Invitrogen), 1% non-essential amino acid solution, 1mM L-Glutamine (Invitrogen), 4ng/ml human bFGF (Invitrogen) and 0.1mM β-mercaptoethanol (Sigma). Cells were split regularly (1:4) in order to maintain colonies of undifferentiated hESCs, This was assessed by staining for stem cell markers such as the stage-specific embryonic antigens; globo-series glycolipids (SSEA-3 and SSEA-4) and the keratin sulphate-related antigens (TRA-1-60 and TRA-1-81), as described previously (Adewumi *et al.* 2007). Routine screening at the University of Sheffield confirmed the hESCs used in the present study (Shef-1) to be karyotypically normal (46, XY). Cell culture and feeding were performed by the senior research staff members at Professor Pete Coffey's laboratory at the UCL Institute of Ophthalmology.

### **3.2.3 Derivation of RPE from hESC**

The generation of RPE from hESC has been described previously (Vugler *et al.* 2008) and was performed by the senior research staff members at Professor Pete Coffye's laboratory at the UCL Institute of Ophthalmology.

Briefly, hESC-RPE were reliably formed when hESC colonies were allowed to become superconfluent on a MEF density of  $6 \times 10^3$  (experiment 1 and 2) or  $9$  (experiment 3 and 4)  $\times 10^3$  per  $\text{cm}^2$ . When the individual colonies grew to confluence (approximately 10 days post-passage) the medium was changed daily using basic hESC medium minus bFGF. After 1-2 weeks of the daily feeding regime, pigmented foci can be observed in the superconfluent hESC culture. These pigmented foci were excised mechanically using the tip of a glass Pasteur pipette and a microsurgical crescent blade. This approach was only possible when individual pigmented focus was greater than 1 mm in size. During this procedure, the surrounding non-pigmented material was dissected away meticulously to avoid harvesting undifferentiated cells and thus risk of tumour formation.

For the patch grafts used in pigs 2, 4, 5, 6, 7 and 8, the pigmented blob of cells were transferred onto the substrate directly as a "blob" for further expansion (see below). For pig 9, the pigmented cells were washed with dissociation solution containing trypsin and then re-seeded onto the substrate for further differentiation (see below). For the remaining 8 pigs (11 to 17 and 22), the pigmented cells isolated from the flask were placed in a culture dish coated with growth factor reduced Matrigel™ (BD Biosciences, diluted 1:30, coated at 37°C for 30 minutes using  $200 \mu\text{l} / \text{cm}^2$ ). A total of 10 pigmented foci were placed in each dish and the hESC-RPE was allowed to expand on Matrigel for up to 35 days (5 weeks) in basic hES cell medium minus bFGF (media changes every 2-3 days). These cells were also washed with dissociation solution containing trypsin and then re-seeded onto the substrate for further differentiation (see below).

### **3.2.4 Creation of hESC-RPE monolayer on a substrate**

The artificial substrate for delivery of hESC-RPE as a monolayer is a type of polyester with pre-specified porosity and thickness. The substrate was first coated with growth factor reduced Matrigel™ (BD Biosciences, diluted 1:30, coated at 37°C for 30 minutes using  $200 \mu\text{l} / \text{cm}^2$ ). To avoid growth of hESC-RPE on both sides of the substrate, the polycarbonate membrane within the 6.5 mm Transwell® Insert (Corning®, Acton, MA, USA) was cut out and replaced by the substrate by gluing it onto the insert using a low

viscosity silicone elastomer sealant (Kwik-Cast™ & Kwik-Sil™, World Precision Instruments, Inc., FL. USA). The “blob” or dissociated hESC-RPE harvested from the flask (with MEF feeders) or the dish (coated with Matrigel™) was then re-seeded onto the substrate within the insert at a density of approximately  $300 - 400 \times 10^3$  cells/cm<sup>2</sup>. After 4 weeks, these cells achieved full differentiation and were sufficiently adherent to the substrate for use in the porcine transplantation studies. The hESC-RPE monolayer on the substrate within the modified Transwell Insert was then transferred at 37°C to the operating theatre on the day of surgery.

### **3.2.5 Preoperative medication and anaesthesia**

All pigs were pre-medicated with intramuscular injection of 1.5 ml (1 mg/kg) of xylazine (Rompun, Bayer, UK), 1.5 ml (5 mg/kg) of ketamine (Vetalar; Parke Davis Ltd, Gwent, UK) and 4 mg/kg of carbrofen (Pfizer). Following endotracheal intubation, general anaesthesia was maintained by artificial ventilation with isoflurane 2.5 - 3% (Aerrane, Baxter Health Care Ltd, Berkshire, UK) in combination with 2L/min of NO<sub>2</sub> and 5L/min of oxygen. The stroke volume (400ml/stroke) and respiratory frequency (20/min) were kept constant during the experiment. Oxygen saturation, pulse rate and rectal temperature were monitored. Venous blood was then taken from the jugular vein prior under general anaesthesia. All drug administration and anaesthesia were performed by the research assistants or manager at the Northwick Park Institute of Medical Research (NPIMR).

The pupil was dilated with 3 drops of 1% cyclopentolate and 3 drops of 2.5% phenylephrine (Minims™; Chauvin Pharmaceuticals Ltd, Romford, UK). Prophylactic intramuscular ampicillin LA (Intervet UK Ltd, Milton Keynes, UK), 5.75 ml, was given prior to surgery.

### **3.2.6 Surgical procedure**

The periorbital skin was cleaned with povidone iodine 10% (Videne, Ecolab Ltd, Leeds, UK) and a sterile drape (BD Visitec™ Visidrape™, Alcon Laboratories Inc., Fort Worth, Texas, USA) was placed around the surgical field. Lateral canthotomy was performed after clamping the lateral canthus with a straight artery forceps. Self retaining retractors were used as lid speculum. Localised peritomies and 3 sclerostomies at 2 mm from the limbus were made (see **Figure 3.5**). The pig underwent a three-port pars plana vitrectomy using the 20-gauge system (Accurus, Alcon Laboratories Inc., Fort Worth, Texas, USA) and an indirect wide-angle viewing system (Oculus BIOM 3m, Oculus

Optikgerate GmbH, Wetzlar, Germany). Posterior vitreous detachment was induced and extended up to the major retinal vessels. Then, a localised bleb retinal detachment was created by injecting compound sodium lactate (Hartmann's solution, Baxtor Healthcare Ltd, Thetford, Norfolk, UK) under the nasal retina near the visual streak by using a dual bore 41-gauge cannula (1270.0.100, Synergetics, St Louis, Missouri, USA). The retinotomy was enlarged with disposable 20-gauge vertical scissors (707.25, DORC, Netherlands). The sclerostomy for delivery of the graft was also enlarged with the MVR blade whilst the graft was prepared.

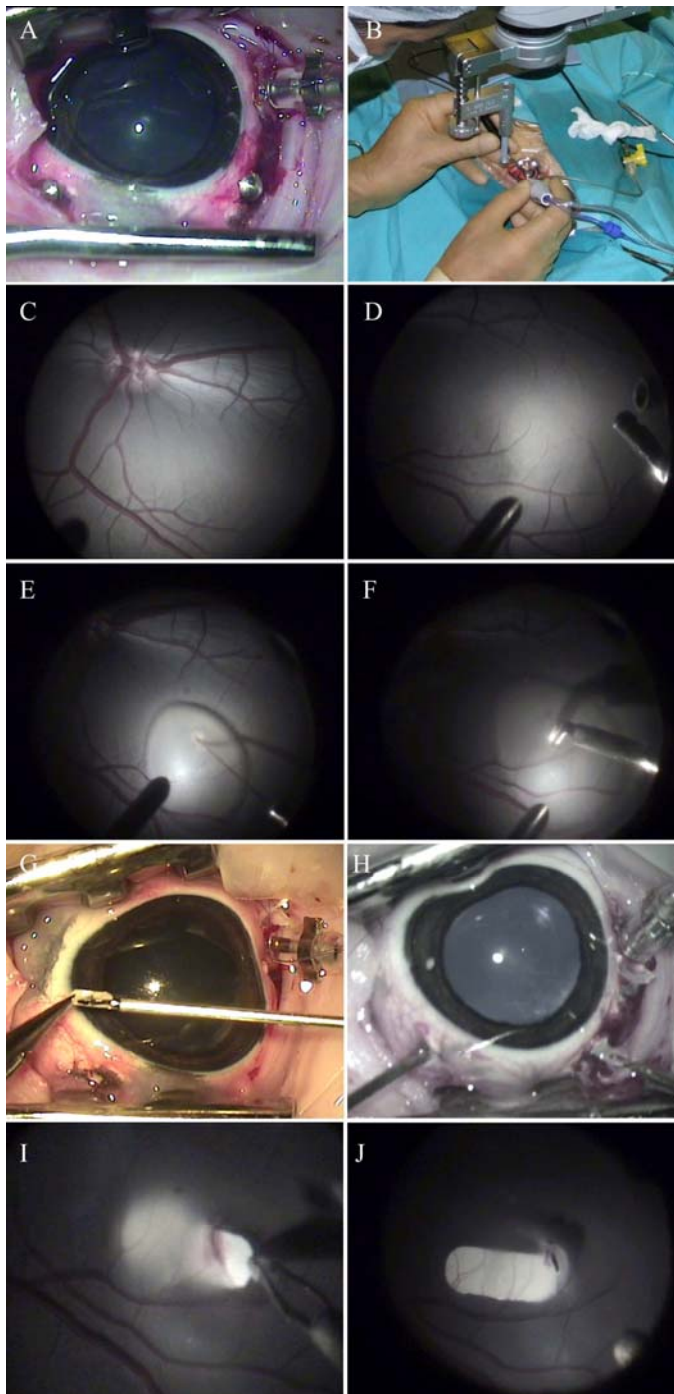
The hESC-RPE on the substrate was cut out from the insert and laid on a sterile surface ensuring the monolayer of cells was facing up. A customised membrane punch (see **Figure 3.6**) was then used to cut a 1 x 3 mm patch graft with rounded edges (see **Figure 3.6**). Under dissecting microscope, the graft was grasped along the long edge using disposable mini-end-grasping forceps (Alcon Grieshaber AG, Switzerland) ready for delivery. This was performed by Dr Ahmado, PhD student at Professor Peter Coffey's laboratory.

Prior to insertion of the graft into the eye, the infusion line was pinched to temporarily stop the outflow fluid jet stream through the sclerostomy while the graft was inserted into the eye. Once inside the globe, the graft was first engaged at the retinotomy and nudged into the subretinal space with the forceps (see **Figure 3.5**). Once the graft was stable within the bled detachment, fluid-to-air exchange was performed using disposable 20-gauge back-flush instrument (1281-AD, DORC, Netherlands) to aspirate the subretinal fluid and reattach the retina under air. The sclerostomies were closed with 7-0 coated polyglactin 910 sutures (Vicryl W 9561, Ethicon, Livingston, Scotland, UK). One drop each of chloramphenicol 0.5% and atropine sulphate 1% (Minims™; Chauvin Pharmaceuticals Ltd, Romford, UK) one 1 cm of betamethasone eye ointment (Betnesol, UCB Pharma Ltd, Slough, UK) was applied to the conjunctival sac at the end. All surgical procedures were performed by Mr Lyndon Da Cruz and assisted by the author. Equipments and instruments required for vitrectomy surgery and wide-angle viewing system at NPIMR were partly arranged by the author.

### **3.2.7 Postoperative care and termination**

Selected pigs (see chapter 7) were given oral cyclosporine (650 mg per day) starting 24 hours before surgical procedure. In these animals, oral immunosuppression with cyclosporine was given for a maximum of 2 weeks postoperatively. All pigs received topical dexamethasone 0.1% (Maxidex, Alcon Laboratories Inc., Fort Worth,

Texas, USA) and chloramphenicol 0.5% (Minims™; Chauvin Pharmaceuticals Ltd, Romford, UK) 4 times a day and then tapered over 4 weeks. Cycloplegia was achieved with cyclopentolate 1 % (Minims™; Chauvin Pharmaceuticals Ltd, Romford, UK) twice a day for 1 week. All drops were administered by the staff at NPIMR and documented in a drug chart.



**Figure 3.5 Porcine Pars plana vitrectomy and RPE patch transplantation**

(A) Three port pars plana approach was used. (B) Indirect wide-angle viewing system allowed visualisation of the (C) left porcine fundus from the surgeon's perspective (bottom is superior retina and right side is nasal retina). (D) Vitrectomy was performed and the tips of the vitrectomy cutter and the infusion cannula can be seen nasally. (E) Bleb detachment was performed in the region of relatively avascular visual streak followed by (F) enlargement of the retinotomy. (G) A sham patch graft was held by intraocular forceps and (H) inserted through the supranasal sclerostomy. (I) Inside the eye, the patch was inserted through the retinotomy into the (J) subretinal space.

All pigs underwent postoperative examination by the author. The pigs were sedated with 1.5 ml (1 mg/kg) of xylazine (Rompun, Bayer, UK), 1.5 ml (5 mg/kg) of ketamine (Vetalar; Parke Davis Ltd, Gwent, UK) and isoflurane (2-3%) via a mask. At 1 week, intraocular pressure was measured with an applanation tonometer (Tono-Pen® XL, Reichert, Inc. Depew, NY, USA). External eye and retina were examined using indirect funduscopy (Heine Sigma 100, Heine Optotechnik, Herrsching, Germany) through a 20 D lens and dilated pupils under sedation.

All pigs also had blood taken prior to termination at 2 days, 7 days, 14 days, 4 weeks and 6 weeks. Following phlebotomy and examination, the pigs were euthanised using 20ml of pentobarbital sodium (Abbott Laboratories, North Chicago, IL, USA). The left eye of all 22 pigs were enucleated after termination at 1-2 hours, 2 days, 7 days, 14 days, 4 weeks and 6 weeks after surgery. The non-operated fellow eyes were also enucleated in some pigs to serve as a control. In one animal, splenectomy was also performed for control of CD4 antibody.

### **3.2.8 Tissue preparation**

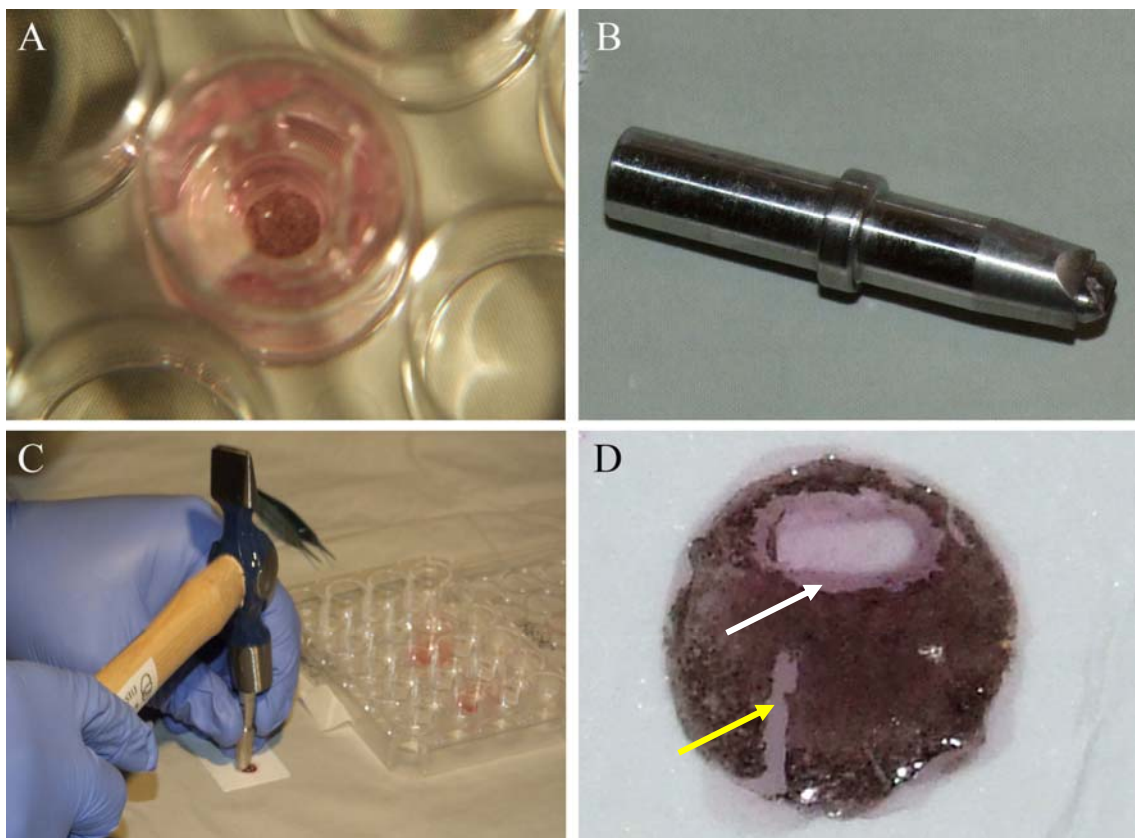
The enucleated globes were punctured at the peripheral cornea to allow penetration of 4% paraformaldehyde in 0.1 M phosphate buffer. Within 3 hours of enucleation, the cornea, lens and vitreous were removed and the remaining posterior eye-cup was photographed before and after 2-3 times of wash with PBS. The posterior eye-cup was then cut into halves. In 10 of 22 eyes, the globe was cut so that the patch graft was also cut in half using a cryostat blade. For pig 11, each eye was bisected so that each contains a whole patch. Pigs 18 and 19 had bisection of the globe so that each of the 2 eye-cup fragments contained the area of control bleb detachment without the patch. The segments were immediately processed for either light microscopy (immunohistochemistry) or electron microscopy.

The eye-cup fragments containing the whole or half of the patch were marked and left in 30% sucrose/PBS overnight at 4°C for immunohistochemistry. For the 10 other segments containing half or whole of a patch, 1% paraformaldehyde and 3% glutaraldehyde in 0.08M cacodylate buffer (Karnowsky solution) were used to fix the tissue for 72 hours.

For immunohistochemistry, the tissue was transferred from sucrose to be embedded in optimal cutting temperature (OCT) media (Tissue Tek®, VWR, Leicestershire, UK) in dry ice/acetone slurry and stored at -80°C. The eye cup fragments were sectioned at 14 µm on a cryostat (Leica CM1850, Leica Microsystems Nussloch

GmbH, Nußloch, Germany) and mounted on charged glass slides (VWR, Lutterworth, Leicestershire, UK). These were dried for at least an hour in a cool current of air before wrapping in foil and stored at  $-80^{\circ}\text{C}$ .

For electron microscopy, the tissues were post-fixed in 1% osmium tetroxide in cacodylate buffer, dehydrated in a graded series of alcohols and epoxypropane prior to embedding in Araldite CY212 resin (Agar Scientific, Standsted, UK) for six hours without rotation (to minimise dissociation of the patch from the retina and choroid) and then cured overnight in a  $60^{\circ}\text{C}$  oven. Semi-thin ( $1\mu\text{m}$ ) sections for light microscopy and ultra-thin ( $70\text{nm}$ ) sections for transmission electron microscopy (TEM) were cut using a Reichert-Jung Ultracut E microtome (Leica Microsystems Nussloch GmbH, Nußloch, Germany), fitted with a diamond knife. All tissue cutting and sections were performed by Drs Ahmad Ahmado and Jean Lawrence from Professor Peter Coffey's research group.



**Figure 3.6 Preparation of hESC-RPE patch graft**

(A) Human embryonic stem cell derived retinal pigment epithelium (hESC-RPE) monolayer is re-seeded onto a polyester membrane in a 96 well. (B) A customised punch is used to create a  $1\times 3$  mm size graft. (C) The  $1\times 3$  mm patch graft is cut out by the punch with the help of a hammer. (D) The remaining polyester patch contains a monolayer of hESC-RPE except where the forceps was used to grasp the membrane (yellow arrow) and a rim surrounding the defect in the membrane where the patch graft was cut out (white arrow).



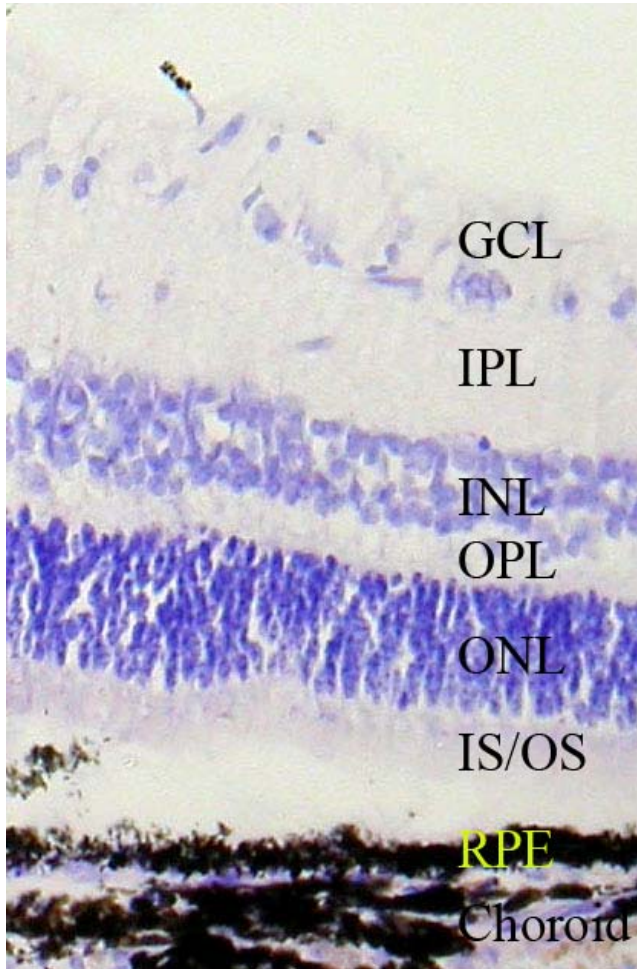
### 3.2.9 Immunohistochemistry

Sections were blocked in 0.3% triton in PBS plus 5% donkey serum (Jackson ImmunoResearch) for 1h before overnight incubation at room temperature in a humidified chamber, in primary antibodies (see **Table 3.6**) diluted in 0.3% triton X-100/PBS plus 1% donkey serum. After washing, sections were incubated at room temperature in appropriate fluorescent donkey secondary antibodies (FITC and TRITC, pre-adsorbed to various species, Jackson ImmunoResearch) diluted 1:200 in PBS plus 2% donkey serum. Cell nuclei were visualised with DAPI (4',6-diamidino-2-phenylindole dihydrochloride, Sigma; 1:5,000, Sigma Chemical Co., Poole, Dorset, UK) followed by washing in PBS and mounting in Vectashield (Vector Laboratories Ltd., Peterborough, UK). Immunologically stained sections were examined using the Zeiss confocal microscope and LSM Image Browser software. Immunohistochemical staining and titration of antibody concentration were performed by Dr Jean Lawrence from Professor Peter Coffey's research group. Images were taken by Drs Jean Lawrence and Anthony Vugler from the same research group. Images were collated by the author for further analysis. An example of normal porcine retina on cresyl violet stain is shown in **Figure 3.7**.

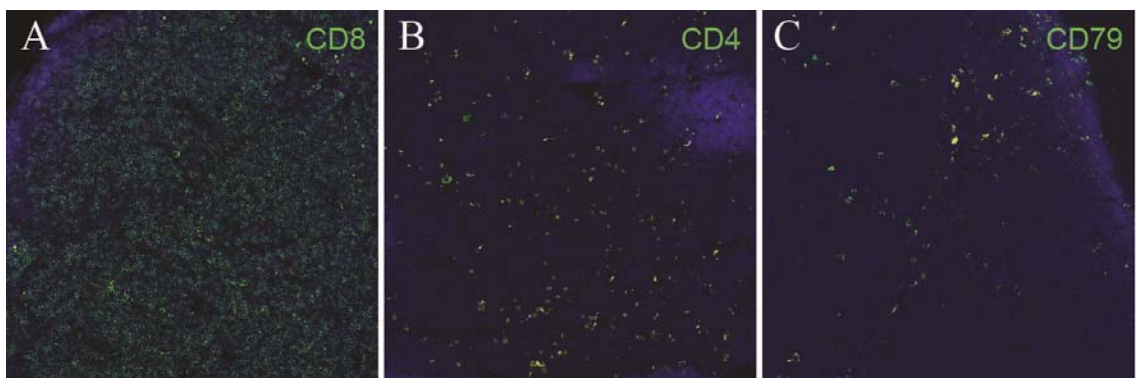
Positive and negative controls were also performed. **Figure 3.8** shows positive controls for T (CD4 and CD8) and B (CD79) lymphocyte antibodies using spleen harvested from one of the animals. Macrophage antibody stained cells with large pigment clumps. These cells did not stain for human markers or RPE specific cell markers. Negative controls with no primary antibodies demonstrated only autofluorescent macrophages. There was prominent non-specific background staining when anti-rabbit secondary antibodies were used with anti-CD3 and anti-GFAP primary antibodies.

### 3.2.10 Electron microscopy

Semi-thin sections were stained with alcoholic toluidine blue. Ultra-thin sections were contrasted by sequential staining with saturated uranyl acetate in 50% ethanol followed by lead citrate and viewed and photographed in a TEM (JEOL 1010 TEM, JEOL Ltd., Tokyo, Japan) operating at 80kV. The electron micrographs were taken by Dr Jean Lawrence from Professor Peter Coffey's research group. Images were collated by the author for analysis.



**Figure 3.7 Histology of normal porcine retina and choroid**  
 Cresyl violet stain of the normal pig neuroretina and choroid showing ganglion cell layer (GCL), inner plexiform layer (IPL), inner nuclear layer (INL), outer plexiform layer (OPL), outer nuclear layer (ONL) inner segment and outer segment (IS/OS) and retinal pigment epithelium (RPE).



**Figure 3.8 Positive controls for T and B cells markers**  
 Immunohistochemistry demonstrated (A) CD8-positive (B) CD4-positive and (C) CD79-positive cells within the porcine spleen when stained with fluorescent (FITC) donkey anti-mouse antibodies.

**Table 3.6 Antibodies used for staining target cells.**

<b>Antibody</b>	<b>Target</b>	<b>Raised in</b>	<b>Source</b>	<b>Dilution</b>
TRA-1-85	Human Ok <sup>a</sup> blood group antigen	Mouse	Prof Peter Andrews, Sheffield	1:10
PCNA	Human nucleus	Mouse	Chemicon/Millipore	1:500
GFAP	Reactive astrocytes and Muller cells	Rabbit	DAKO	1:500
CRALBP	RPE/Muller cells	Mouse	Thermo Scientific	1:1000
Bestrophin	RPE	Mouse	Chemicon/Millipore	1:1000
RPE65	RPE	Mouse	Chemicon/Millipore	1:500
Pmel17	RPE: immature melanosomes	Mouse	DAKO	1:100
Ki67	Proliferating cells	Rabbit	Vector	1:2000
Ki67	Proliferating cells	Mouse	DAKO	1:50
Macrophage antibody	Pig and other species Macrophages	Mouse	Abcam	1:100
CD79a	Pig B cells	Mouse	AbD Serotec	1:100
Pig CD8a	Pig T cells: Cytotoxic T cells including NK	Mouse	Thermo Scientific	1:10
Pig CD4a	Pig T cells: CD4 T helper	Mouse	AbD Serotec	1:10
CD3	Pig T cells	Rabbit	Sigma Aldrich	1:1000

CD; cluster of differentiation, CRALBP; cellular retinaldehyde binding protein, GFAP; glial fibrillary activation protein, PCNA; proliferating cell nucleus antigen, Pmel 17, premlanosome 17; RPE65, retinal pigment epithelium specific protein 65kDa; SLA; swine leukocyte antigen, TRA-1-85, specific epitope on the protein basigin/CD147.

## **Chapter 4**

# **Autologous RPE Transplantation in Atrophic Macular Disease**

## 4.1 Background

There is currently no effective treatment for patients with acquired or inherited atrophic macular disease. These conditions are characterised by progressive decline in macular function that often spares the fovea (and hence maintaining normal VA) until late in the disease process. Although their presentations are often asymmetrical, with sequential loss of VA separated by many months or years, VA in each eye tends to become equally impaired as paracentral scotomata expand and coalesce to form a ring, and then later, a large central scotoma.

The exact pathophysiology of macular RPE atrophy in IMD and AMD is not yet fully elucidated. However, the characteristic RPE atrophy and linkage to genes expressed in the photoreceptor cells in IMD suggest a possible sequence of event: abnormal outer segments and their interaction with RPE leading to RPE cell death with subsequent choriocapillaris atrophy and photoreceptor cell loss (Kaplan *et al.* 1993; Allikmets *et al.* 1997; Hoyng *et al.* 1996; Felbor *et al.* 1997). In some of these patients, the macular lesion resembles GA of AMD, where photoreceptor cell loss is also thought to be due to either primary RPE cell death or impaired choroidal perfusion (Sakamoto *et al.* 1995; Friedman *et al.* 1995; McLeod *et al.* 2002). Histological study of eyes with GA of AMD also showed intact inner retinal structures despite extensive loss of outer nuclear layer and RPE (Kim *et al.* 2002). These observations suggest that preservation of the outer retina using RPE transplantation may restore or maintain visual function because there is no primary inner retinal degeneration. The proof of principle for this approach comes from studies on the anatomical and functional outcomes of RPE transplantation in the RCS rat model and full macular translocation in neovascular AMD (see **Chapter 2**).

## 4.2 Aims

In this chapter, the results of 2 clinical trials examining the use of autologous equatorial RPE-choroid patch graft in patients with atrophic IMD and AMD, respectively, are presented to answer the following questions:

1. What is the recruitment rate and what are the reasons for screening failures for entry into the trials of autologous equatorial RPE-choroid patch graft in atrophic IMD or AMD?

2. Is it feasible and safe to perform autologous equatorial RPE-choroid patch graft in patients with atrophic IMD or AMD?
3. What are the functional and structural outcomes following autologous equatorial RPE-choroid patch graft in patients with late stage atrophic IMD or AMD?

### **4.3 Specific Methodology**

#### **4.3.1 Genotyping of dystrophy patients**

In addition to the investigations outlined under **Section 3.1**, IMD patients recruited to this study were offered the opportunity for genetic testing. Four of the 5 patients agreed to genotyping and their bloods were taken after counselling. Samples were sent for genetic analysis at the regional molecular genetics laboratory, Manchester, UK. Screening for Sorsby fundus dystrophy (SFD) was carried out by bi-directional sequencing of the exon 5 and intron 4/exon 5 splice acceptor site of the tissue inhibitor of metalloproteinases-3 (TIMP-3) gene. Peripherin/*RDS* gene abnormalities were sought using bi-directional sequencing of the entire coding sequence of rhodopsin including intron/exon boundaries. Further samples were also sent to Asper Biotech, Tartu, Estonia to look for variations in *ABCA4* using an arrayed primer extension genotyping array chip.

#### **4.3.2 Data collection and statistical analysis**

Data were collated and analysed by the author. All patients referred for consideration of autologous RPE-choroid patch graft were recorded in a log book. The reasons for not meeting eligibility, as documented in the medical charts, were noted.

Baseline demographic and clinical features, intraoperative course and postoperative complications were tabulated. Functional outcomes including VA, CS and reading ability at baseline, 6, 12, 18 and 24 months were presented in graphs and tables where available. Results of microperimetry tests (fixation characteristics and retinal sensitivity), electrophysiological studies and questionnaires (NEI VFQ-25 and the RAND 36-Item Health Survey) before and after surgery were described in figures, tables and **Appendix 7**. OCT features of the choroid, patch graft and the overlying neuroretina were described. Pre- and postoperative fundus AF images and angiographies were analysed.

Structure-function correlations were explored qualitatively by importing fundus AF, colour photographs and angiographies, captured within a 3 month window of the microperimetry test, into the NAVIS software provided by the Nidek MP1. Co-registration or overlay of microperimetry maps onto these images allowed correlation between function (retinal sensitivity or fixation loci/stability) and structure (perfusion, AF and retinal structure on OCT).

## **4.4 Results**

### **4.4.1 Recruitment rate and screening failures**

A total of 23 patients with IMD were referred for consideration of autologous RPE-choroid graft between August 2005 and April 2008 (33 months period, referral rate of ~8 per year). Full-field ERG demonstrated generalised retinal dysfunction in 7 and the remaining 16 only had macular dysfunction as revealed by the PERG. At the time of referral, 19 had results of genetic testing. Of these, 5 had peripherin/*RDS* mutations, 6 had disease-associated *ABCA4* sequence variants and the remaining 8 had no mutations detected.

Five patients (22% of referral) were enrolled into the study (4 with macular dystrophy and 1 with retinal dystrophy). The remaining 18 patients had Snellen VA that was better than 6/36 and therefore were not eligible despite large areas of parafoveal atrophy. Although Snellen VA was worse than 6/36 in the enrolled IMD cohort, 3 of the 5 patients had better BCVA when the ETDRS chart was used (see **Table 4.1**). Functionally, these patients were considered to be worse than 6/36 because they only had a very small central island of vision detected on microperimetry.

A total of 9 patients with GA secondary to AMD were referred for consideration of autologous RPE-choroid graft between April 2007 and December 2007 (9 month period, referral rate of ~12 per year). Of these, 4 patients (44% of referral) were enrolled and 5 were not eligible due to relatively good VA in 4 patients and lack of recent decline in vision in 1 patient.

### **4.4.2 Baseline patient features**

All 5 patients in the IMD group had evidence of intact subfoveal RPE on angiography and fundus AF imaging, and fixation at the fovea on slit lamp examination. However, only 2 of 4 patients with preoperative microperimetry demonstrated ability to use the fovea for the fixation task. The remaining 2 patients used non-foveal retinal loci for fixation. In contrast, all 4 patients with atrophic AMD had subfoveal GA and therefore,

they were fixating eccentrically; placing the preferred retinal locus nasal (patients 6-8) or temporal to the GA (patient 9) in their right eyes.

Patient 2 had a family history of retinal dystrophy suggestive of dominant inheritance. He had an R172W mutation in the peripherin/*RDS* gene associated with normal implicit time but reduced cone amplitude, similar to that described previously in a large cohort of patients with RDS dystrophy (Downes *et al.* 1999). He also had the characteristic peripapillary atrophy and increased, speckled, fundus AF pattern surrounding the area of atrophy (Downes *et al.* 1999). Patients 1 and 5 had autofluorescent basal laminar drusen. They had no history of renal disease and renal functions were normal. Patient 7 had calcified drusen within the area of GA. None of the patients had yellow subretinal flecks typically seen in Stargardt disease and fundus flavimaculatus, or yellow submacular vitelliform lesions characteristic of Best disease or adult vitelliform macular dystrophy. Other demographic and clinical data at baseline are summarised in **Tables 4.1** and **4.2**.

**Table 4.1 RPE graft in atrophic disease: Baseline demographic features**

Patient No.	Age (yrs)	Sex	Side	Duration of visual loss (months)	VA in study eye (logMAR)	VA in fellow eye (logMAR)
1	52	M	R	6	0.76	1.10
2	45	M	L	3	0.44	1.00
3	41	M	L	6	0.32	0.78
4	45	M	R	12	0.84	0.78
5	66	F	L	6	0.60	1.00
6	51	M	R	36-48	1.64	0.90
7	89	F	R	12-24	0.94	2.28
8	68	F	R	12-24	0.70	1.40
9	74	M	R	12	0.80	0.68

F, female; L, left; logMAR, logarithm of minimum angle of resolution; M, male; R, right; VA, visual acuity.



**Table 4.2 RPE graft in atrophic disease: Baseline clinical features**

<b>Patient No.</b>	<b>Lens opacity</b>	<b>Retinal diagnosis</b>	<b>Specific Features</b>	<b>Pattern ERG</b>	<b>Full-field ERG</b>	<b>Genetic diagnosis</b>
1	None	Macular dystrophy	AFD	Undetectable	Normal	NA
2	None	Cone dystrophy	PPA	Undetectable	Cone loss	RDS R172W
3	None	Macular dystrophy	Bull's eye	Subnormal	Normal	NA
4	None	Macular dystrophy	Bull's eye	Undetectable	Normal	NA
5	None	Macular dystrophy	BLD	Subnormal	Normal	NA
6	IOL, no PCO	Geographic atrophy	None	Subnormal	Normal	NA
7	IOL, no PCO	Geographic atrophy	Calcified drusen	Normal	Normal	NA
8	None	Geographic atrophy	None	Subnormal	Normal	NA
9	Mild NS	Geographic atrophy	None	Undetectable	Rod dysfunction	NA

AFD; autofluorescent drusen, BLD; basal laminar drusen, ERG; electroretinography, IOL; intraocular lens, logMAR; logarithms of minimal angle of resolution, NA; not available, NS; nuclear sclerosis, PCO; posterior capsular opacification, PPA; peripapillary atrophy, PPA; peripapillary atrophy.

#### 4.4.3 Feasibility and safety outcomes

The key surgical steps for autologous patch graft are: (1) induction of posterior vitreous detachment and vitrectomy, (2) creation of bleb detachment and retinotomy in the macular region, (3) preparation of the autologous RPE-choroid patch graft from the superior equatorial region, (4) transfer and delivery of the autologous patch graft from the donor site to the submacular space and (5) sealing of the retinotomy / retinal break, and closure of the sclerostomies / peritomies.

Standard technique of pars plana vitrectomy and induction of vitreous detachment were able to be carried out in all patients. Two patients had intraoperative entry site retinal breaks. Bleb detachment in the macular region required several punctate retinotomies in most patients due to strong adherence between retina and RPE in the areas of RPE atrophy. One patient developed a full-thickness macular defect during bleb detachment. It was possible to harvest autologous RPE-choroid patch grafts from the superior equatorial region in all 9 patients. However, the patch graft had a tendency to contract and wrap around the spatula after removal of the overlying retina. Delivery of the patch graft required enlargement of the retinotomy in all patients. Submacular release of the patch graft from the spatula was unreliable. In one patient, reflux of air bubbles into the submacular space during release of the graft caused subretinal haemorrhage. In other patients, re-insertion of the patch graft was necessary due to failure of the spatula to release the graft in the submacular space. Because of its elasticity, the patch graft tended to form an elongated shape with folded edges when released in the submacular space. Contraction of the graft also led to wrinkled appearance on the surface of the RPE-choroid patch. Most patients had 2 or more subretinal manipulations of the patch graft in an attempt to unfold its edges without success. All 9 patients received silicone oil tamponade. A list of intra-operative complications for each patient can be found in **Table 4.3**.

Postoperative complications included retinal detachment, raised intraocular pressure, cataract and neovascularisation. Three patients (33%) developed retinal detachment prior to removal of silicone oil. A total of 6 detachment repair procedures were performed (1 patient had 1, 1 patient had 2 and 1 patient had 3). The retina was flat in all patients without silicone oil tamponade at the most recent follow-up visit. High intraocular pressure was found in 2 patients within the 1<sup>st</sup> week which was controlled medically. Cataract developed in 4 (patients 1, 5, 8 and 9) of 7 phakic patients and they were extracted at the time of oil removal (3 patients) or after 2 years (1 patient). Some degree of epiretinal membrane was present in all patients although 3 of these caused

significant retinal traction and macular pucker. One patient required 1 additional operation to extract residual oil bubble after the initial removal of oil surgery. In 2 patients, the macular retinotomy used for insertion of the patch graft remained open.

Patient 2 developed a stable intraretinal neovascularisation on the nasal border of the graft that was not associated with subretinal fluid, exudates or haemorrhage during the 24 months of follow-up (see **Figure 4.1**). Extensive subretinal fibrosis developed in patient 9 due to intra-operative submacular haemorrhage. Two patients developed choroidal neovascularisation (see **Figure 4.1**). One of these is currently receiving intravitreal ranibizumab.

Two patients who had re-operations for PVR retinal detachment also developed recurrent ocular pain due to scleritis. Their symptoms were controlled with a course of oral non-steroidal anti-inflammatory drugs. One patient (patient 6) developed iris neovascularisation at 16 months, related to anterior retinal ischaemia secondary to extensive retinectomy. This patient currently remains on aqueous suppressant for raised IOP. A list of postoperative complications can be found in **Table 4.3**.

#### **4.4.4 Functional outcomes**

Functional assessments consist of psychophysical measurements of retinal functions (i.e. VA, CS, reading ability, and microperimetry), electrophysiological testing and questionnaires regarding quality of life and vision.

The median VA (logMAR) declined from 0.76 at baseline to 1.34 and 1.08 at 6 and 12 months, respectively (Friedman test,  $p = 0.003$ ). The mean (SD) change in VA (logMAR) was +0.59 (0.37) and +0.30 (0.37) at 6 and 12 months, respectively. The median CS (logCS) declined from 1.05 at baseline to 0.75 and then returned to 1.05 at 6 and 12 months, respectively (Friedman test,  $p = 0.081$ ). VA and CS outcome are shown in **Tables 4.4, 4.5 and 4.6** and as box plots in **Figure 4.2**.

At baseline, 2 of 9 patients were unable to read the largest print text (1.5 logMAR) on the MNRead chart. These 2 patients (patients 1 and 5, see **Figure 4.3**) gained reading ability postoperatively but only one had subjective improvement. Of the remaining 7 patients, severe decline in reading acuity ( $>0.8$  logMAR loss) was found in 4 patients at 6-12 months. **Figure 4.3** illustrates the reading speed profile at various text sizes pre- and post-operatively in all 9 patients. Reading speed profiles for 2 patients with early IMD and early AMD were also included in **Figure 4.3** for comparison.

**Table 4.3 RPE graft in atrophic disease: Surgical complications**

Patient No.	Intraoperative complications	Postoperative complications
1	none	Cataract (removed at ROSO)
2	intra-operative retinal break	Macula-on RD, cataract (removed at 27 months)
3	none	None
4	intra-operative retinal break	Epi-retinal membrane
5	enlargement of retinotomy	Cataract (removed at ROSO), residual oil, open retinotomy, CNV
6	subretinal heavy liquid	Macula-on RD x 2, epi-retinal membrane, scleritis, rubeosis, raised IOP
7	submacular haemorrhage	Epi-retinal membrane, CNV
8	macular hole	Cataract (removed at ROSO)
9	submacular haemorrhage	Macula-off RD x 3, raised IOP, cataract (removed at ROSO), scleritis, open retinotomy.

CNV; choroidal neovascularisation, IOP; intraocular pressure, RD; retinal detachment, ROSO; removal of silicone oil.

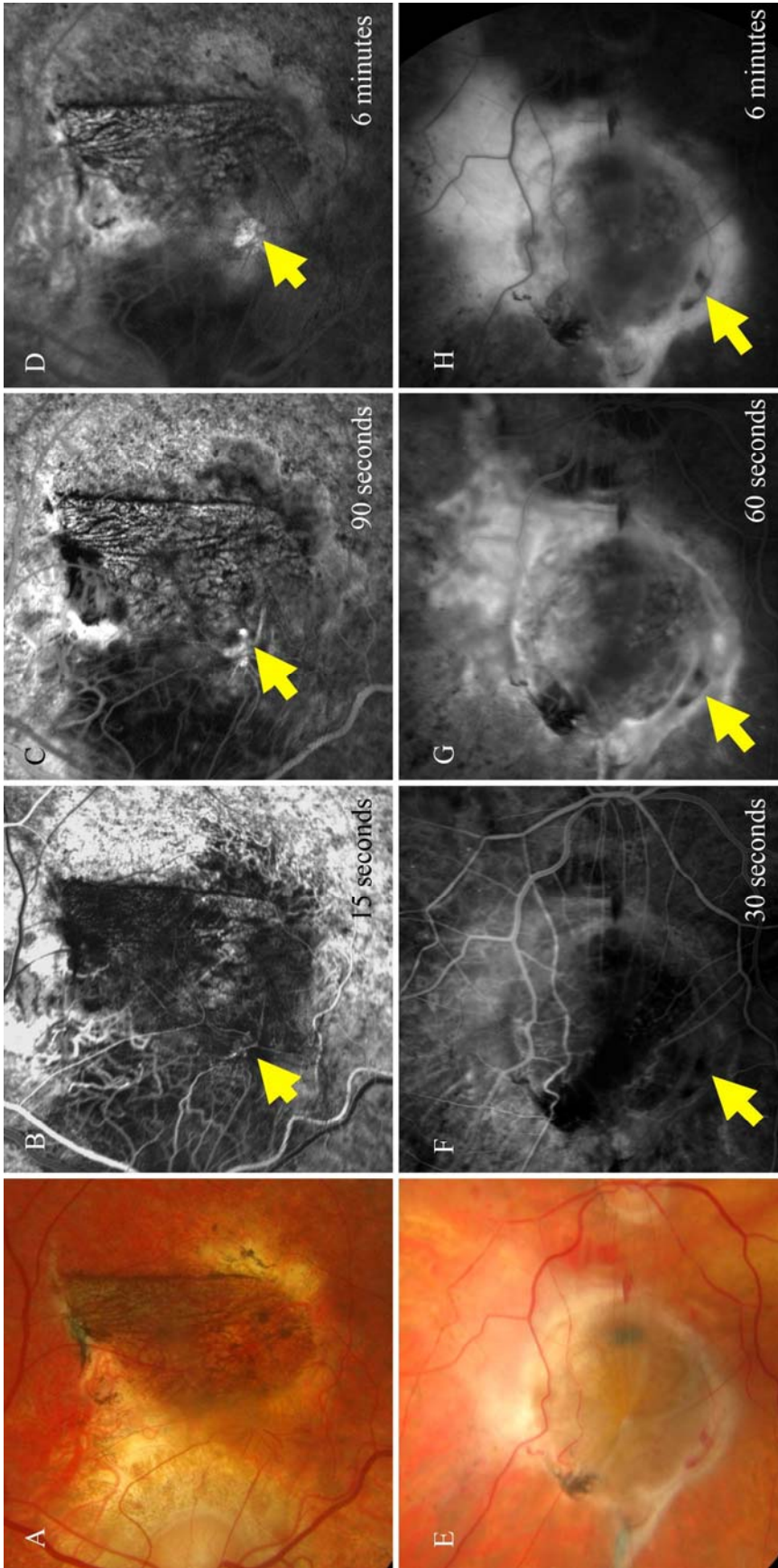


Figure 4.1 RPE graft in atrophic disease: Neovascular complications  
 Colour photographs and angiographies of patients 2 and 7 demonstrating neovascular complications following graft. (A) Patient 2 had an abnormal vascular structure nasal to the graft. (B-D) Fluorescein angiography demonstrated increasing intensity and area of hyperfluorescence with time arising from retinal vasculature (yellow arrows). (E) Patient 7 had subretinal haemorrhage associated with subretinal fibrosis. (F-H) Fluorescein angiography demonstrated choroidal neovascularisation superior and inferior (yellow arrows) to the graft.

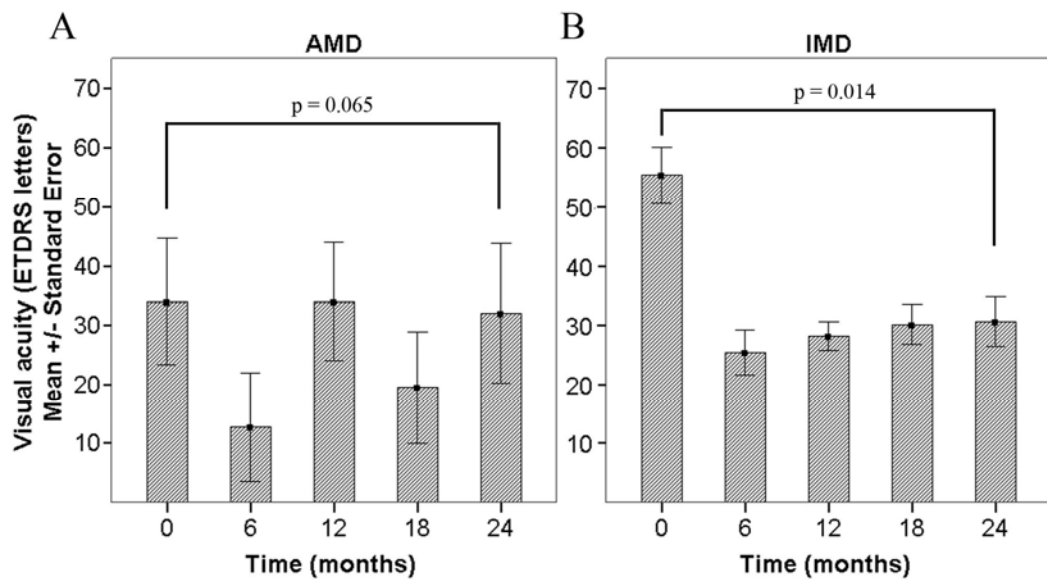
Fixation on the patch graft was found in 2 patients (see **Figure 4.4 and 4.5**). One of these developed an alternative locus of fixation when tested again at 16 months. The other patient developed fixation on the graft at 29 months because the alternative fixation locus (outside the graft) was affected by the development of CNV. In the other 6 patients, the grafts were placed under the preferred retinal loci but the patch grafts were unable to support fixation (see **Figures 4.4, 4.5 and 4.6**). In 1 patient, the graft was misplaced (away from fixation locus) due to intra-operative complication and the fixation locus remained unchanged.

Preoperative microperimetry was available for comparison in 8 patients. Accurate follow-up post-operative microperimetry was not possible due to distortion of retinal vascular landmarks and significant image registration error at the time of the follow-up microperimetry. A common feature in the pre-operative microperimetry was the presence of dense central scotoma surrounded by a rim of reduced retinal sensitivity or a central island of vision surrounded by a ring scotoma. Patient 1 was unable to have pre-operative microperimetry. Post-operatively, there was retinal sensitivity present over the inferotemporal portion of his graft and at the fovea (located adjacent to the inferior edge of the graft, **Figure 4.7**). The sensitivity over the inferotemporal region of the graft and at the fovea was maintained above 10 dB (with Goldmann V target) when re-examined at 38 months. Patient 5 had retinal sensitivity over the superior half of the graft at 9 months which was maintained at 29 months (see **Figure 4.7**). Patients 6 and 8 had retinal sensitivity over the temporal portion of the graft. Some retinal sensitivity was also detected over the graft in patients 2, 3 and 4 but none was detected over the grafts in patients 7 and 9. In the 8 patients with pre-operative microperimetry, it was noted that the area of dense scotoma enlarged following graft. **Table 4.7** summarises the findings of microperimetry.

Electrophysiological studies, including pattern ERG, full-field ERG and mfERG, were performed in all patients pre-operatively. A summary of the results of pattern ERG and full-field ERG are shown in **Appendix 7** and **Table 4.8**. Overall, surgical procedure induced both cone and rod system dysfunction with cone system more severely affected than rod system. This was shown in the more marked delay and reduction of amplitude in the 30 Hz flicker as well as some reduction in the b-wave amplitude of rod-specific ERG. Peak time delay and reduction in the a-wave amplitudes of the bright flash and photopic ERGs suggest dysfunction at the level of photoreceptor cells. Multifocal ERG also showed deterioration particularly in rings 3 to 5. In 2 of 3

patients with a second postoperative electrodiagnostic test, there was evidence of partial recovery of peripheral cone function on full-field and mfERG.

The NEI VFQ-25 and the RAND 36-Item Health Survey questionnaires were completed by 8 of 9 patients before and after surgery. The median score and medium change in scores for each subscales in the categories of quality of vision (5 subscales), vision specific QOL and general health QOL (8 subscales) are shown in **Tables 4.9** and **4.10** for IMD and AMD respectively. In these cohorts, reduction in peripheral and colour vision subscale scores were noted. Interestingly, despite loss of visual function, there was improvement in the mental health and role dependency subscales scores in the IMD and AMD groups respectively.



**Figure 4.2 RPE graft in atrophic disease: VA outcomes at 1 and 2 years**

Bar charts showing the mean visual acuity (VA) letter scores with standard error for mean before and at 6, 12, 18 and 24 months after patch graft. (A) VA in patients with dry age-related macular degeneration (AMD) showed slight decline which was not statistically significant ( $p = 0.065$ , Friedman test). (B) VA in patients with inherited macular dystrophy (IMD) showed statistically significant decline at 6 to 24 months ( $p = 0.014$ , Friedman test).

**Table 4.4 RPE graft in atrophic disease: VA, CS and Reading outcomes**

Visual function	Atrophic IMD (n = 5)			Atrophic AMD (n = 4)		
	Baseline	6 month	12 month	Baseline	6 month	12 month
Median VA (logMAR)	0.60	1.12	1.10	0.87	1.72	0.98
Median CS (logCS)	1.25	0.90	1.20	0.83	0.38	0.75
Median RA (logMAR)	0.90	1.19	1.41	1.07	N/A	1.45
Median MRS (wpm)	47	41	23	63	N/A	8

AMD; age-related macular degeneration, CS, contrast sensitivity; IMD; inherited macular disease, logCS; logarithm of contrast sensitivity, logMAR; logarithm of minimum angle of resolution, MRS; maximum reading speed, N/A; not available, RA; reading acuity, VA; visual acuity, wpm; words per minute.



**Table 4.5 RPE graft in atrophic disease: Visual acuity outcomes**

Patient Number	VA (logMAR)				
	Baseline	6 months	12 months	18 months	24 months
1	0.76	1.10	1.10	0.96	1.00
2	0.44	1.40	1.32	1.36	1.40
3	0.32	1.34	1.08	N/A	N/A
4	0.84	1.00	1.06	1.04	1.04
5	0.60	1.12	1.12	1.02	0.92
6	1.64	1.98	1.54	1.56	1.98
7	0.94	1.46	1.06	N/A	N/A
8	0.70	0.92	0.90	0.92	N/A
9	0.80	1.98	0.58	2.28	N/A

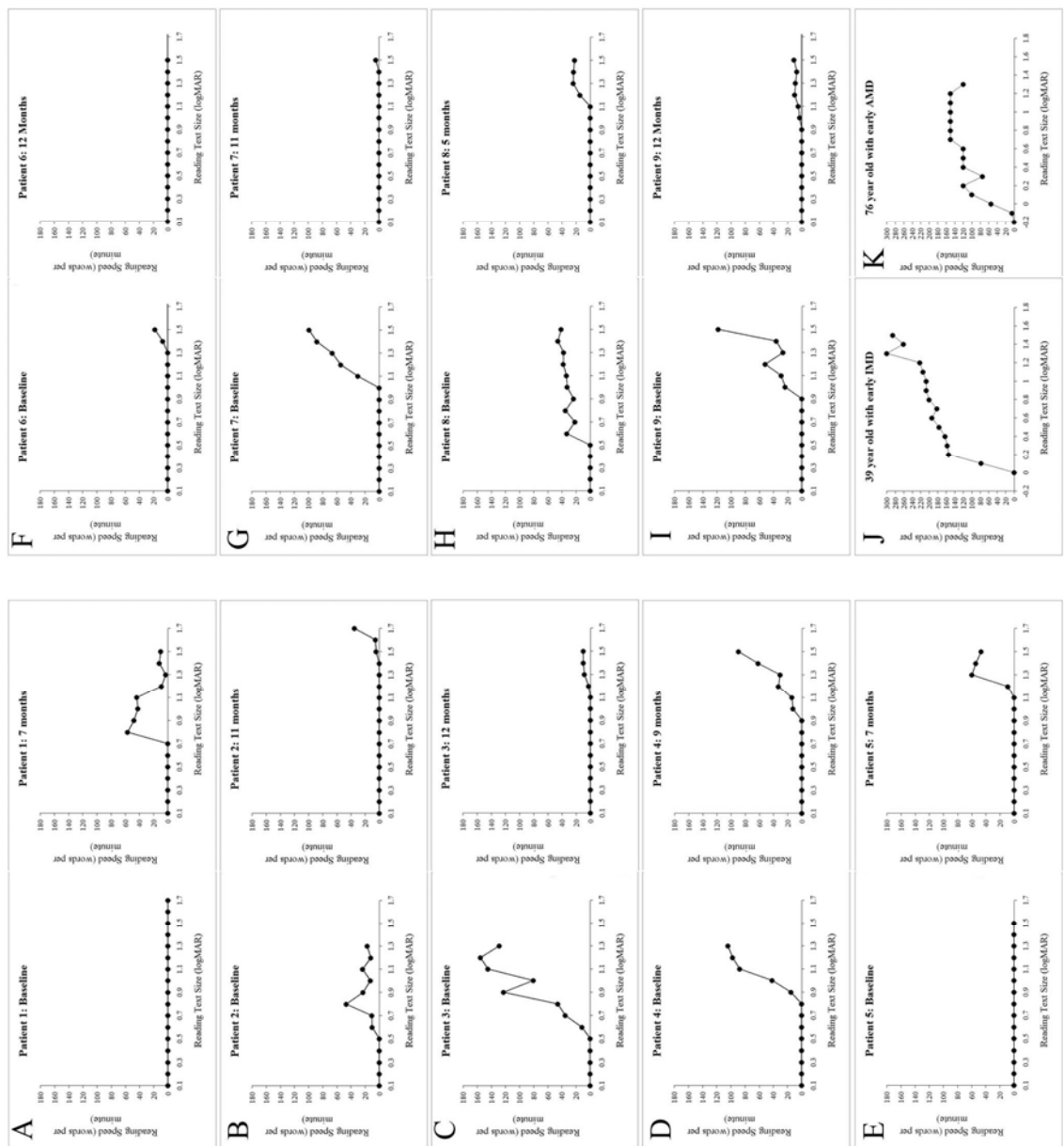
logMAR, logarithm of minimum angle of resolution; N/A, not available; VA, visual acuity.

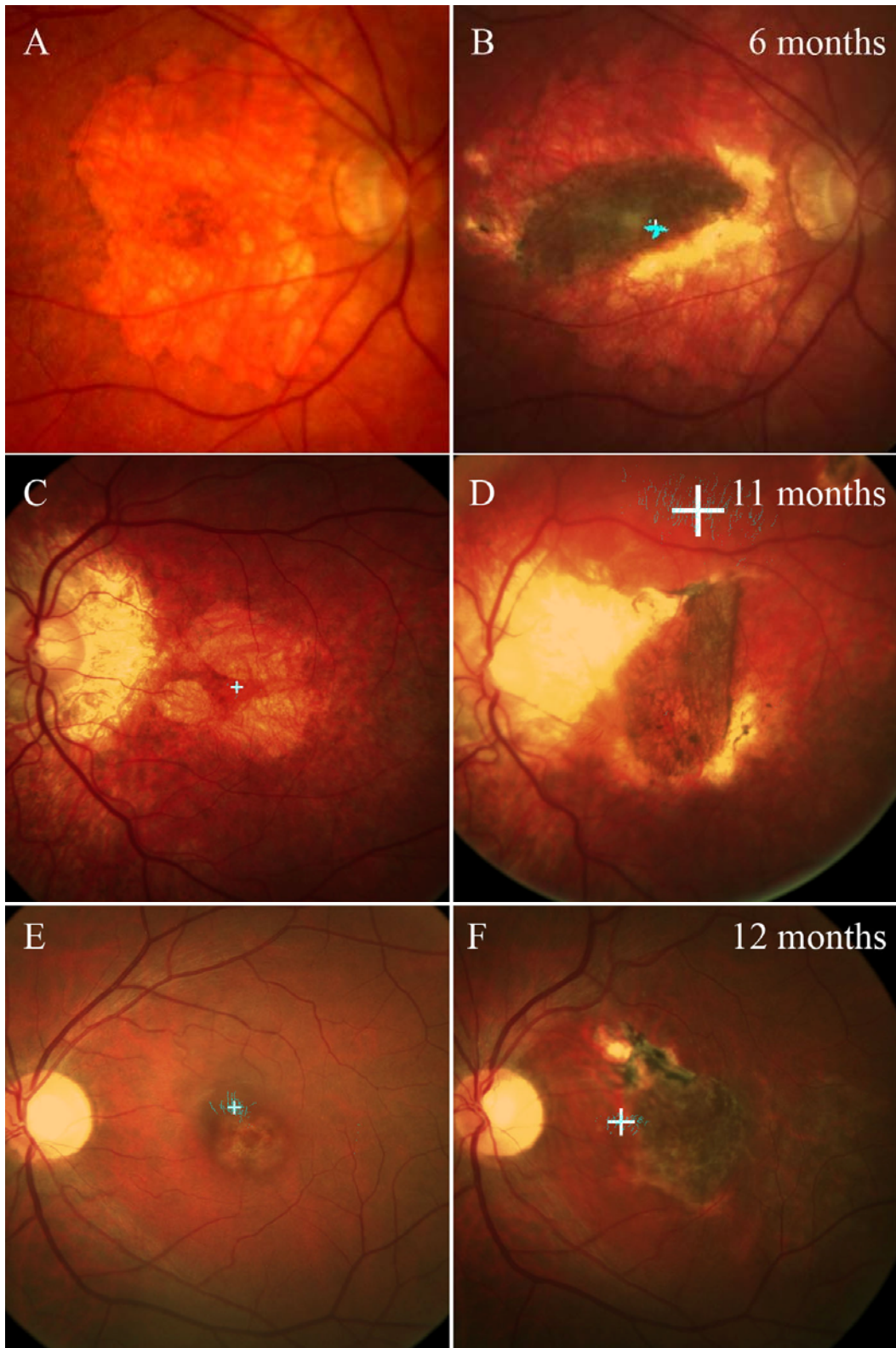
**Table 4.6 RPE graft in atrophic disease: Contrast sensitivity outcomes**

Patient Number	CS (logCS)				
	Baseline	6 months	12 months	18 months	24 months
1	1.20	1.05	0.75	N/A	N/A
2	0.60	0.15	0.90	N/A	N/A
3	1.65	0.90	1.20	N/A	N/A
4	1.50	1.05	1.20	N/A	N/A
5	1.25	0.75	1.35	N/A	N/A
6	0.00	0.00	0.00	N/A	N/A
7	1.05	0.75	0.75	N/A	N/A
8	0.75	1.35	1.35	N/A	N/A
9	0.90	0.00	N/A	N/A	N/A

CS, contrast sensitivity; logCS, logarithm of contrast sensitivity; N/A, not available.

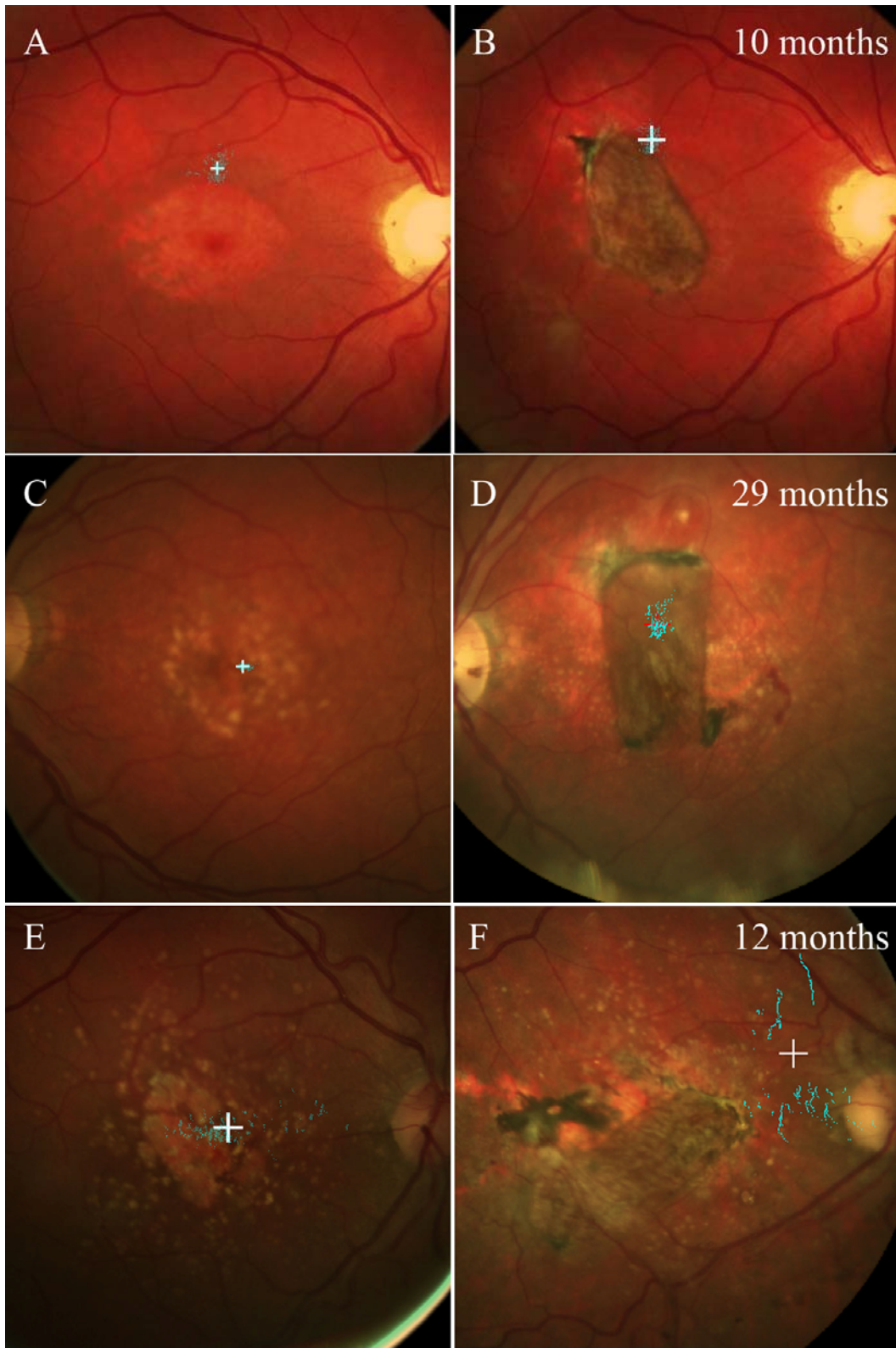
**Figure 4.3 RPE graft in atrophic disease: Reading outcomes at 1 year**  
 Reading speed plot against reading test size showing pre- and post-operative reading abilities in (A-E) inherited macular disease and (F-I) atrophic age-related macular degeneration cohorts. Reading speeds for a (J) 39 and (K) 76 year old subjects with early IMD and early AMD, respectively





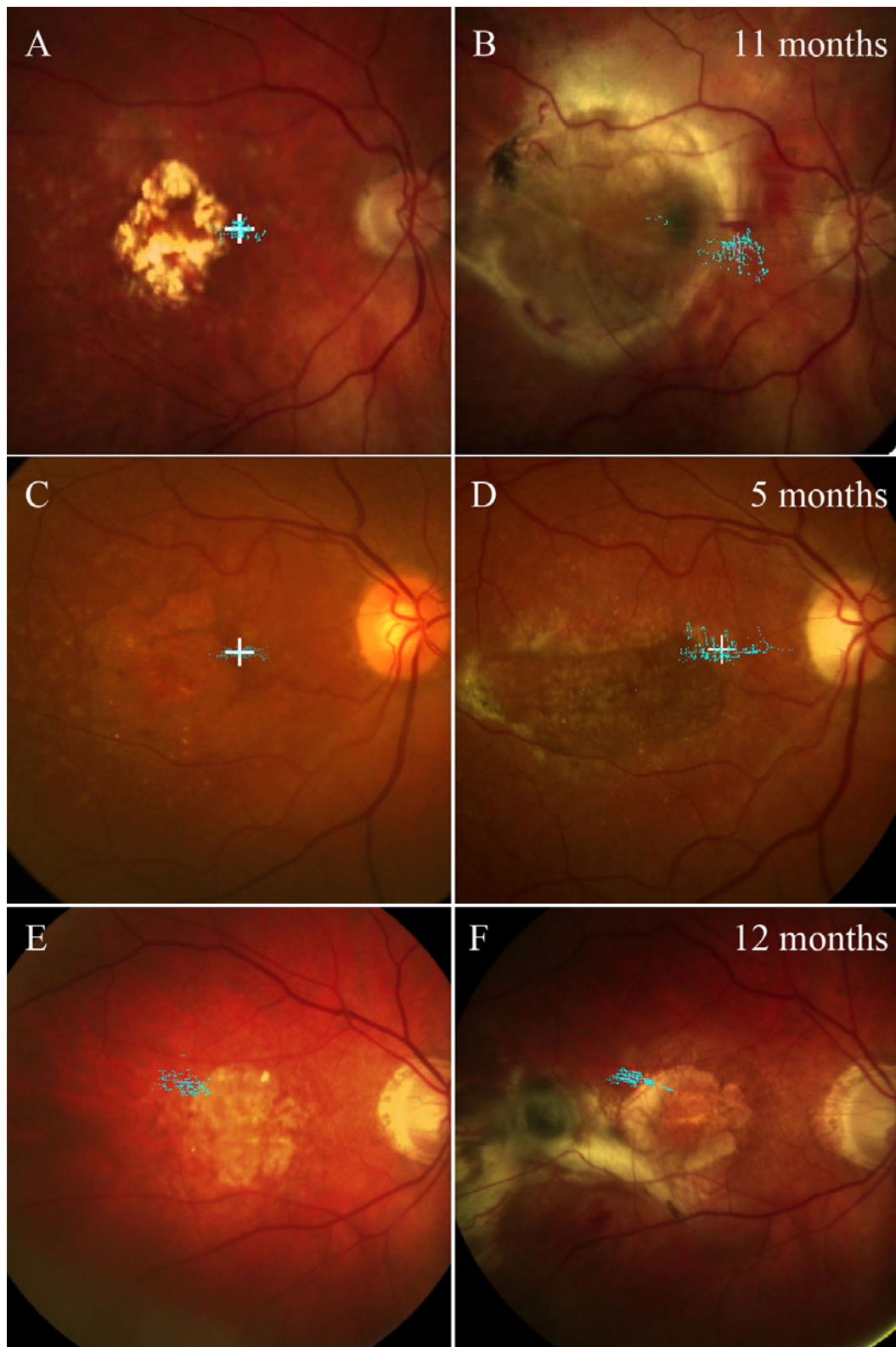
**Figure 4.4 RPE graft in atrophic disease: Fixation in patients 1 - 3**

Pre- and post-operative fixation tests in patients 1, 2 and 3. (A, B, microperimetry not available at baseline) Patient 1 was fixating at the fovea pre- and postoperatively. (C, D) Patient 2 lost foveal fixation despite placement of graft under the fovea. (E, F) The preoperative eccentric fixation locus in patient 3 was displaced nasally by the insertion of the patch graft.



**Figure 4.5 RPE graft in atrophic disease: Fixation in patients 4 - 6**

Pre- and post-operative fixation tests in patients 4, 5 and 6. (A, B) The preoperative eccentric fixation locus in patient 4 was displaced superiorly by the insertion of the patch graft. (C, D) Patient 5 lost foveal fixation but established eccentric fixation on the patch graft at 29 months. (E, F) The preoperative eccentric fixation locus in patient 6 was displaced nasally by the insertion of the patch graft.

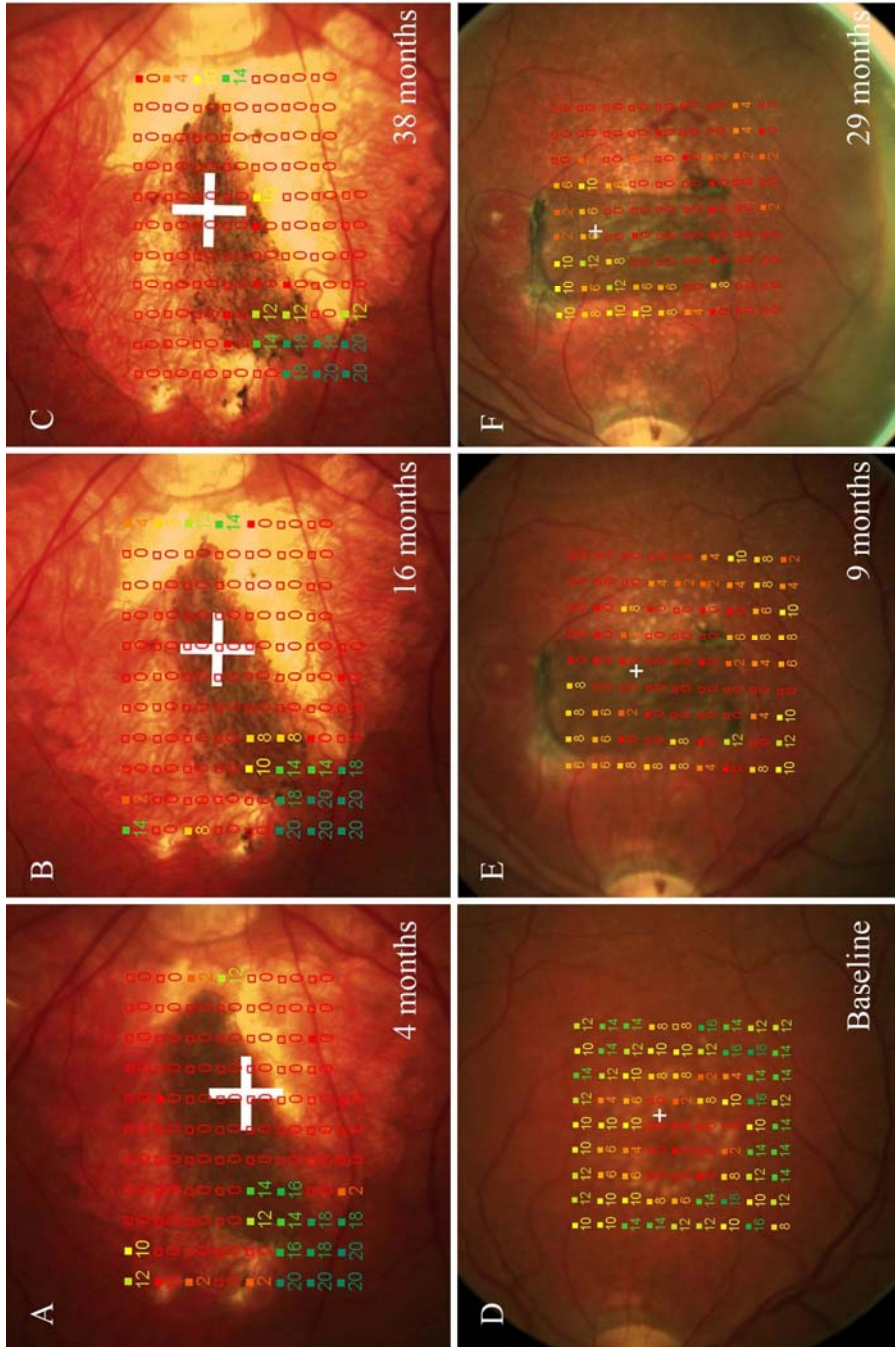


**Figure 4.6 RPE graft in atrophic disease: Fixation in patients 7 - 9**

Pre- and post-operative fixation tests in patients 7, 8 and 9. (A, B) The preoperative eccentric fixation locus in patient 7 was displaced nasally by the insertion of the patch graft. (C, D) The preoperative eccentric fixation locus in patient 8 was displaced nasally by the insertion of the patch graft. (E, F) Patient 9 remained fixating at a similar eccentric locus after misplacement of patch graft.

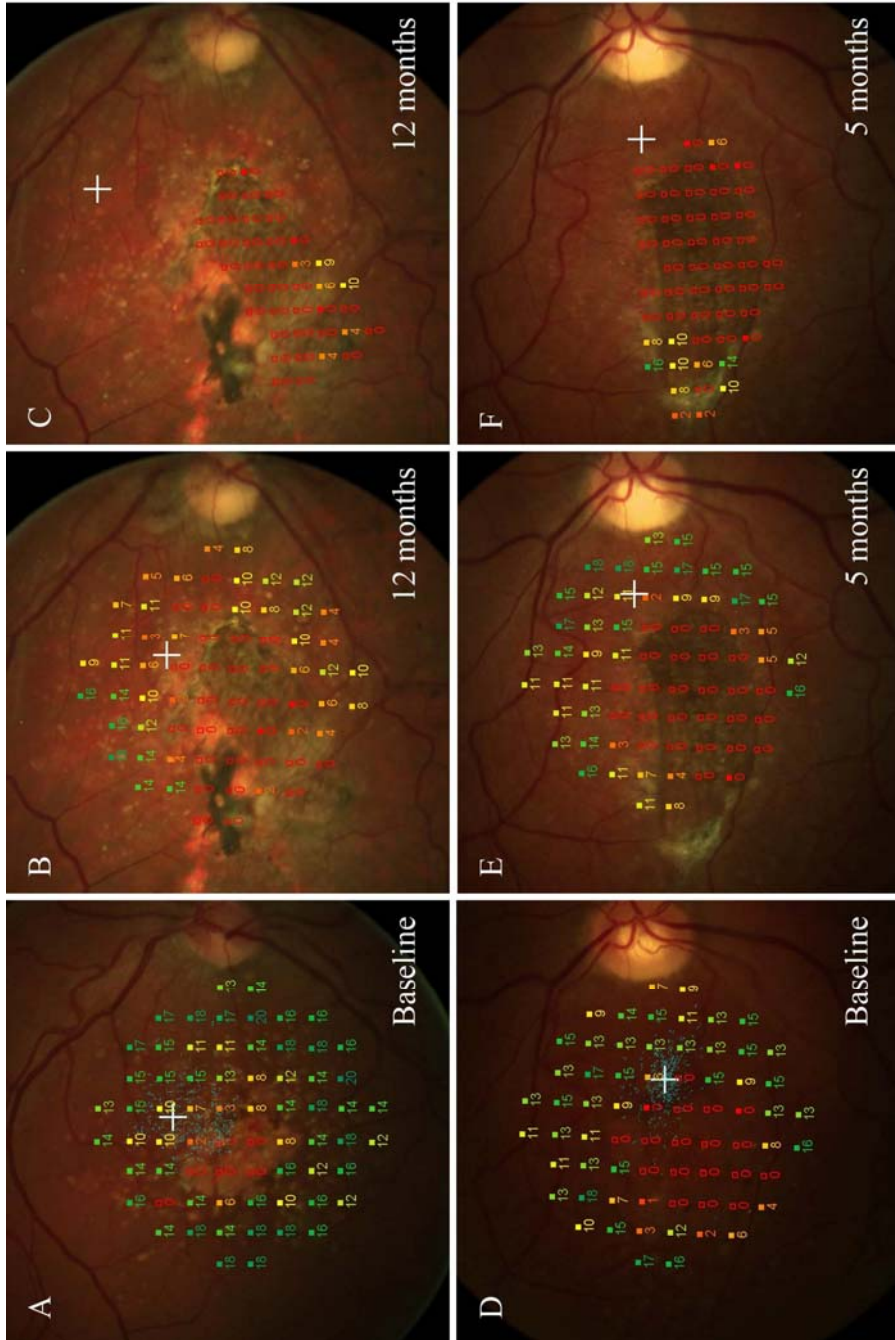
**Figure 4.7 RPE graft in atrophic AMD: Microperimetry in patients 1 and 5**

(A, B, C) Patient 1 had retinal sensitivity (12-18 dB) over the inferotemporal region and the inferior edge of graft which was maintained between 4 and 38 months. (D) Patient 5 had a small dense central scotoma at baseline. (E) At 9 months, retinal function was still present over the superior portion of the patch graft. (F) By 29 months, there was a reduction in sensitivity inferior and temporal to the graft due to development of a choroidal neovascular membrane.



**Figure 4.8 RPE graft in atrophic AMD: Microperimetry in patients 6 and 8**

(A) Patient 6 had had a small dense central scotoma at baseline. (B, C) At 12 months, there was retinal sensitivity over the infero-temporal portion of the graft but there was also enlargement of the dense scotoma. (D) Patient 8 had a small dense central scotoma at baseline. (E, F) At 5 months, retinal function was present over the temporal portion of the graft.



**Table 4.7 RPE graft in atrophic disease: Retinal sensitivity over graft**

Patient No.	Baseline		Initial follow-up visit within 12 months		Most recent follow-up visit	
	Mean RS (dB)* (min, max, number of test loci)	Time (month)	Mean RS (dB) (min, max, number of test loci)	Time (month)	Mean RS (dB) (min, max, number of test loci)	Time (month)
1	NA	6	2.5 (0, 20, n = 24)	6	1.1 (0, 9, n = 20)	38
2	1.0 (0, 10, n = 57)	6	1.3 (0, 14, n = 20)	6	0.0 (0, 0, n = 20)	33
3	11.0 (0, 20, n = 27)	3	1.6 (0, 14, n = 27)	3	1.0 (0, 6, n = 27)	12
4	4.5 (0, 20, n = 22)	6	1.2 (0, 14, n = 22)	6	0.0 (0, 0, n = 22)	24
5	6.5 (0, 18, n = 24)	9	3.4 (0, 12, n = 31)	9	2.5 (0, 8, n = 31)	29
6	11.7 (0, 16, n = 12)	-	NA	-	0.5 (0, 4, n = 12)	12
7	6.4 (0, 16 n = 33)	9	0.0 (0, 0, n = 28)	9	0.0 (0, 0, n = 28)	11
8	3.2 (0, 16, n = 19)	5	0.8 (0, 8, n = 19)	5	1.0 (0, 12, n = 26)	26
9	NA	-	NA	-	0.0 (0, 0, n = 12)	12

max; maximum, min; minimum, n; number of test loci, NA; not available, RS: retinal sensitivity.

\*Preoperative median retinal sensitivity was calculated from responses over the area of retina which subsequently receives autologous RPE-choroid graft. Preoperative images were registered with postoperative images to allow examination of equivalent areas of retina for comparative analysis.



**Table 4.8 RPE graft in atrophic disease: Summary of pattern and full-field ERGs in the study eye**

Patient No.	Macular dysfunction (PERG response)		Rod system dysfunction (Rod-specific b wave response)		Cone system dysfunction (30 Hz flicker response)		Follow-up ERG (month)
	Before	After	Before	After	Before	After	
1	Yes (#)	Yes (#)	No	Yes (↓↓)	No	Yes (↓↓)	23, 35
2	Yes (#)	Yes (#)	No	Yes (↓↓)	No	Yes (↓↓↓)	6, 20
3	Yes (↓↓)	Yes (#)	No	Yes (?)	No	Yes (↓)	8
4	Yes (#)	Yes (#)	No	Yes (↓↓)	No	Yes (↓↓)	6, 17
5	Yes (↓↓)	Yes (↓↓)	No	Yes (?)	No	Yes (↓↓)	7
6	Yes (↓↓)	Yes (↓↓)	No	Yes (↓)	No	Yes (↓)	23
7	No	Yes (#)	No	Yes (↓)	No	Yes (↓↓)	9
8	Yes (↓↓)	Yes (↓↓)	No	Yes (?)	No	Yes (↓)	6
9	Yes (#)	NA	Yes (↓)	NA	No	NA	NA

ERG, electroretinography; NA, not available; PERG, pattern electroretinography.

Key: ?; suspicious, ↓; mild dysfunction, ↓↓; moderate dysfunction, ↓↓↓; severe dysfunction, #; undetectable

**Table 4.9 RPE graft in atrophic IMD: NEI VFQ-25 and RAND 36-Item Health Survey**

<b>Quality of Life and Vision Subscales</b>	<b>Preoperative score</b>	<b>Postoperative score</b>	<b>Difference in score</b>
	<b>median (range)</b>	<b>median (range)</b>	<b>median (range)</b>
NEI VFQ-25 Composite score	62.5 (56, 69)	59.5 (33, 65)	-3 (-27, 0)
<b>Quality of vision (NEI VFQ-25)</b>			
General vision	50 (40, 60)	30 (20, 60)	-10 (-40, 0)
Difficulty with near tasks	42 (25, 50)	29 (25, 42)	-4.5 (-25, 0)
Difficulty with distance tasks	46 (42, 50)	50 (33, 58)	+4 (-17, +16)
Peripheral vision	100 (75, 100)	75, (25, 100)	-12.5 (-75, 0)
Colour vision	87.5 (50, 100)	62.5 (50, 75)	-12.5 (-50, 0)
<b>Vision specific QOL (NEI VFQ-25)</b>			
Dependency	62.5 (50, 83)	62.5 (25, 92)	+4 (-33, +9)
Role limitations	50 (50, 63)	50 (0, 75)	-6.5 (-50, +25)
Mental health	41 (13, 81)	63 (19, 94)	+22 (-19, +38)
Social function	50 (50, 63)	44 (25, 75)	-6 (-25, +12)
Driving	0 (0, 67)	0 (0, 0)	0, (-67, 0)
Ocular pain	94 (75, 100)	94 (63, 100)	+6 (-37, +13)
<b>General health QOL (RAND 36 Item)</b>			
Physical functioning	90 (90, 100)	97.5 (80, 100)	+2.5 (-10, +10)
Physical health	100 (25, 100)	87.5 (0, 100)	-12.5 (-25, 0)
Mental health	90 (80, 96)	88 (72, 100)	+2 (-16, +4)
Energy/fatigue	72.5 (55, 85)	62.5 (60, 85)	-12.5 (-20, +30)
Emotional well being	100 (100, 100)	100 (0, 100)	0 (-100, 0)
Social functioning	100 (62.5, 100)	100 (37.5, 100)	0 (-25, 0)
Pain	100 (100, 100)	85 (67.5, 100)	-15 (-32.5, 0)
General health	82.5 (80, 90)	65 (60, 70)	-17.5 (-30, -10)

NEI VFQ-25; National Eye Institute-25 Item Visual function questionnaire, QOL; quality of life.

**Table 4.10 RPE graft in atrophic AMD: NEI VFQ-25 and RAND 36-Item Health Survey**

<b>Quality of Life and Vision Subscales</b>	<b>Preoperative score</b>	<b>Postoperative score</b>	<b>Difference in score</b>
	<b>median (range)</b>	<b>median (range)</b>	<b>median (range)</b>
NEI VFQ-25 Composite score	35 (16,51)	25.5 (12, 53)	-2 (-19, +2)
<b>Quality of vision (NEI VFQ-25)</b>			
General vision	30 (20, 40)	30 (20, 60)	0 (-20, +40)
Difficulty with near tasks	21 (0, 33)	16.5 (0, 33)	0 (-9, 0)
Difficulty with distance tasks	8 (8, 58)	8 (0, 25)	-4 (-33, 0)
Peripheral vision	87.5 (25, 100)	50 (0, 75)	-37.5 (-75, +25)
Colour vision	37.5 (0, 100)	12.5 (0, 100)	-12.5 (-25, 0)
<b>Vision specific QOL (NEI VFQ-25)</b>			
Dependency	4 (0, 42)	4 (0, 50)	+4 (-8, +8)
Role limitations	12.5 (0, 25)	25 (0, 50)	+12.5 (-25, +50)
Mental health	12.5 (0, 63)	15.5 (0, 50)	-3.5 (-19, +19)
Social function	31.5 (25, 38)	31.5 (0, 50)	-0.5 (-25, +13)
Driving	0 (0, 0)	0 (0, 0)	0 (0, 0)
Ocular pain	75.5 (50, 100)	81.5 (13, 88)	-12.5 (-37, +25)
<b>General health QOL (RAND 36 Item)</b>			
Physical functioning	67.5 (40, 95)	17.5 (5, 85)	-40 (-70, +5)
Physical health	50 (25, 100)	0 (0, 50)	-37.5 (-100, 0)
Mental health	88 (60, 96)	52 (48, 64)	-36 (-48, +4)
Energy/fatigue	70 (40, 70)	37.5 (15, 50)	-32.5 (-55, +10)
Emotional well being	66.7 (0, 100)	0 (0, 0)	-66.7 (-100, 0)
Social functioning	100 (75, 100)	18.8 (0, 100)	-81.3 (-100, +25)
Pain	60 (20, 70)	22.5 (10, 60)	-28.8 (-47.5, 0)
General health	80 (60, 85)	72.5 (60, 85)	-5 (-15, +10)

NEI VFQ-25; National Eye Institute-25 Item Visual function questionnaire, QOL; quality of life.

#### 4.4.5 Structural outcomes

Structural assessments consist of angiography to demonstrate graft vascularisation and perfusion, fundus AF imaging to indirectly detect RPE-photoreceptor cell interaction, and OCT to visualise retinal and choroidal structures.

Two of the 9 patients declined further angiographies postoperatively since they developed severe nausea and vomiting during fluorescein dye injection preoperatively. The remaining 7 patients demonstrated early hyperfluorescence (fluorescein) and distinct intrinsic vascular patterns (indocyanine green) within the patch graft (see **Figure 4.9**). The 2 patients who developed postoperative CNV demonstrated increasing intensity and area of hyperfluorescence in the region of the CNV lesions.

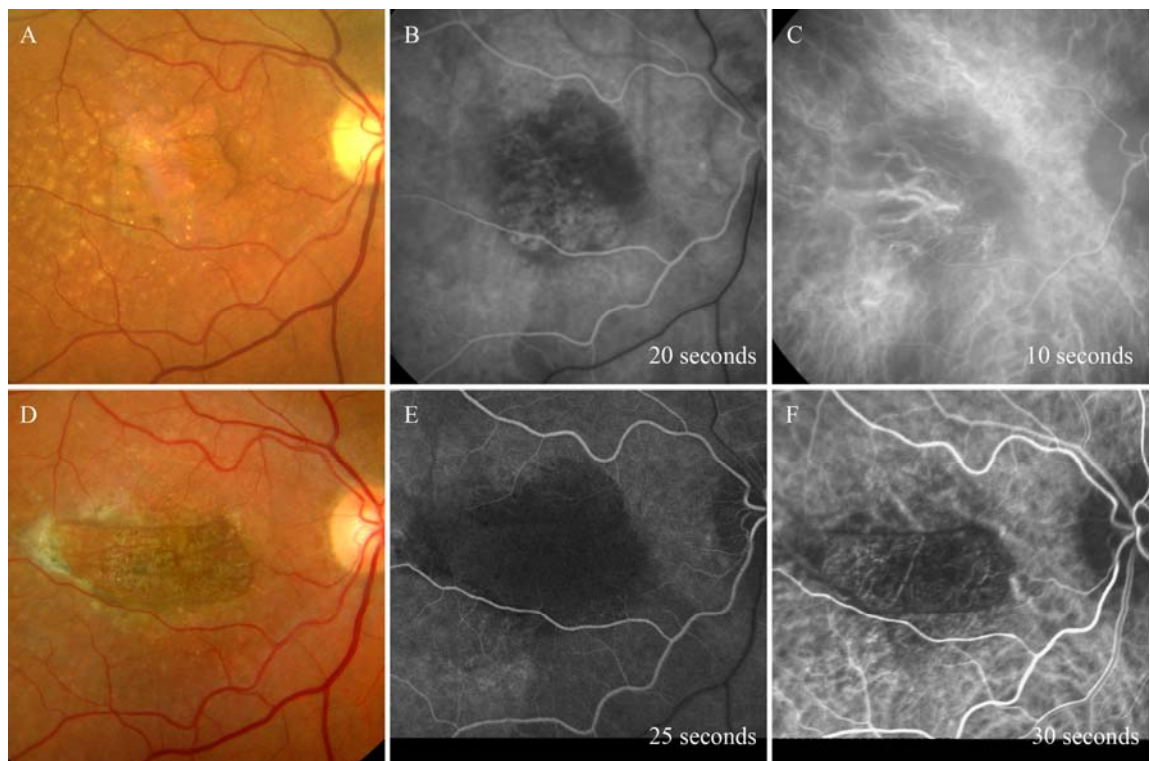
Fundus AF imaging was performed in all patients although the qualities of the images varied considerably. AF signal was present over all 9 grafts to varying degrees with patients 4 and 9 demonstrating the least graft AF intensity. The remaining 7 grafts had homogenous pattern of AF signals over a small portion of the patch (see **Figures 4.9, 4.10** and **4.11**). Heterogeneous linear pattern of AF signal in the remaining portion of the patch grafts corresponded to the pigmentary changes and wrinkling of the graft surface. The region surrounding the graft showed variable increased and decreased AF signals. Reduced AF signal was associated with RPE atrophy, subretinal fibrosis, or masking by pigmentary hyperplasia and thick epiretinal membrane (see **Figures 4.11B** and **4.12B**). Increased AF signal was found at the junctional zone surrounding RPE atrophy and at the sites of macular retinotomies that remained open (see **Figures 4.11D** and **4.12F**).

OCT scan was performed in all patients pre- and postoperatively. The majority of scans had motion artefacts and segmentation errors even with the new generation spectral-domain OCT scanner. Although artefacts precluded accurate registration between the fundus image and the OCT scans, most scan sets had adequate B scan quality to allow qualitative analysis of the inner and outer retinal structures. A feature common to all patient was the prominent irregular elevation of the highly reflective band that represents the wrinkled RPE layer of the patch graft. In some scans, hyporeflective circular structures within the choroid of the patch graft could be seen (SOCT Copernicus and Spectralis HRA+OCT). The retina over the graft had varied appearance (see **Figure 4.13**). Cystic changes were frequently seen within the retina over the graft regardless of retinal thickness (see **Figure 4.13**). In some patients, cysts were associated with retinal thinning while in others, there was associated retinal thickening or oedema. Using the Spectralis OCT, it was possible to visualise outer

nuclear layer over some portions of the patch graft suggesting rescue of the photoreceptor cells by the autologous RPE graft (see **Figure 4.13**).

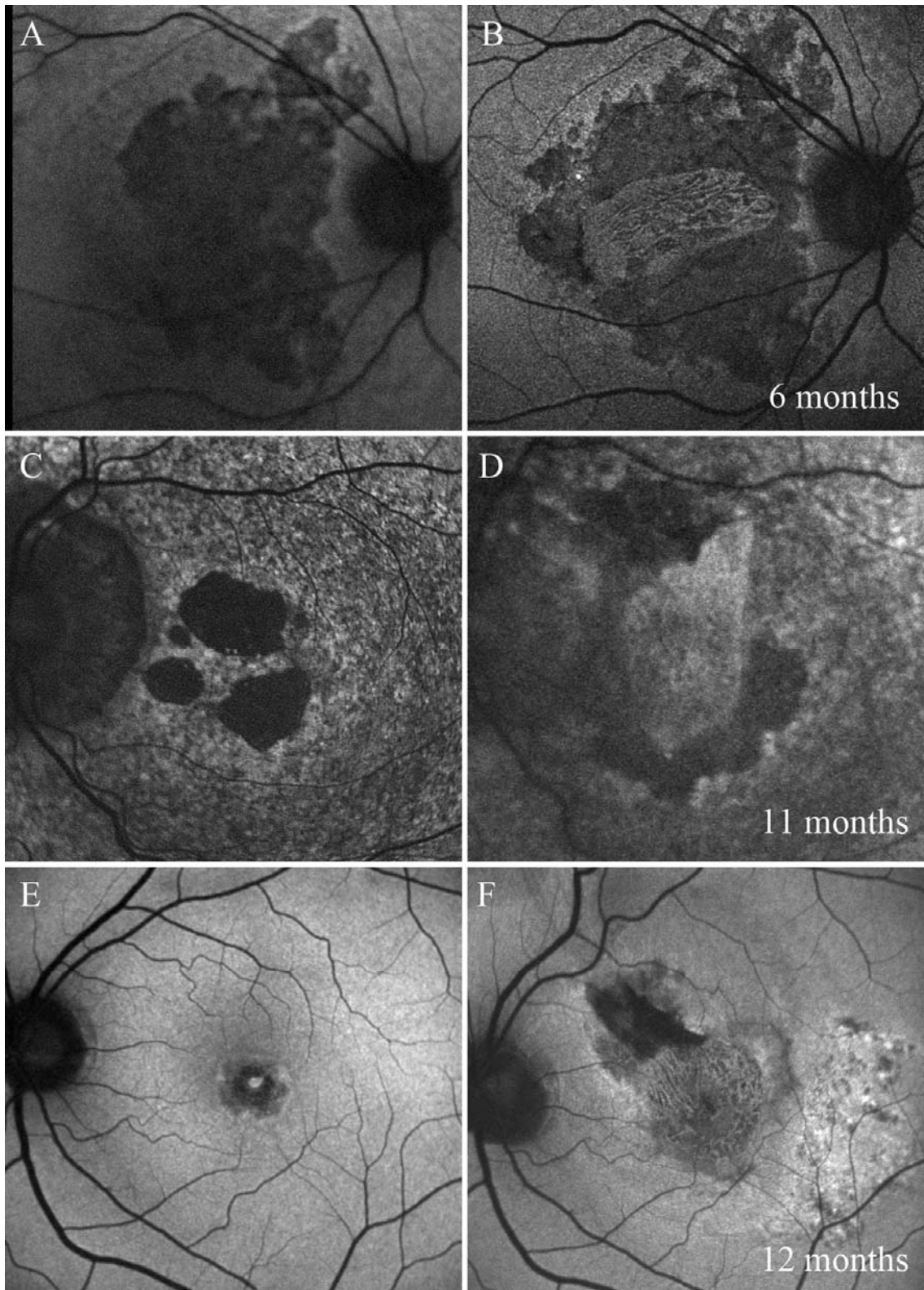
#### 4.4.6 Structure-function correlation

Retinal sensitivity was generally found over the part of the graft closest to the retinotomy. This portion of the graft also tended to have better choriocapillaris perfusion and more uniform AF signal (see **Figure 4.14**). However, these features were not sufficient to predict function. Raster B scans from spectral-domain OCT showed intact outer retinal structures in areas with retinal sensitivity on microperimetry (see **Figure 4.14**). However, outer retinal structure was not always easy to distinguish especially in the presence of retinal cysts.

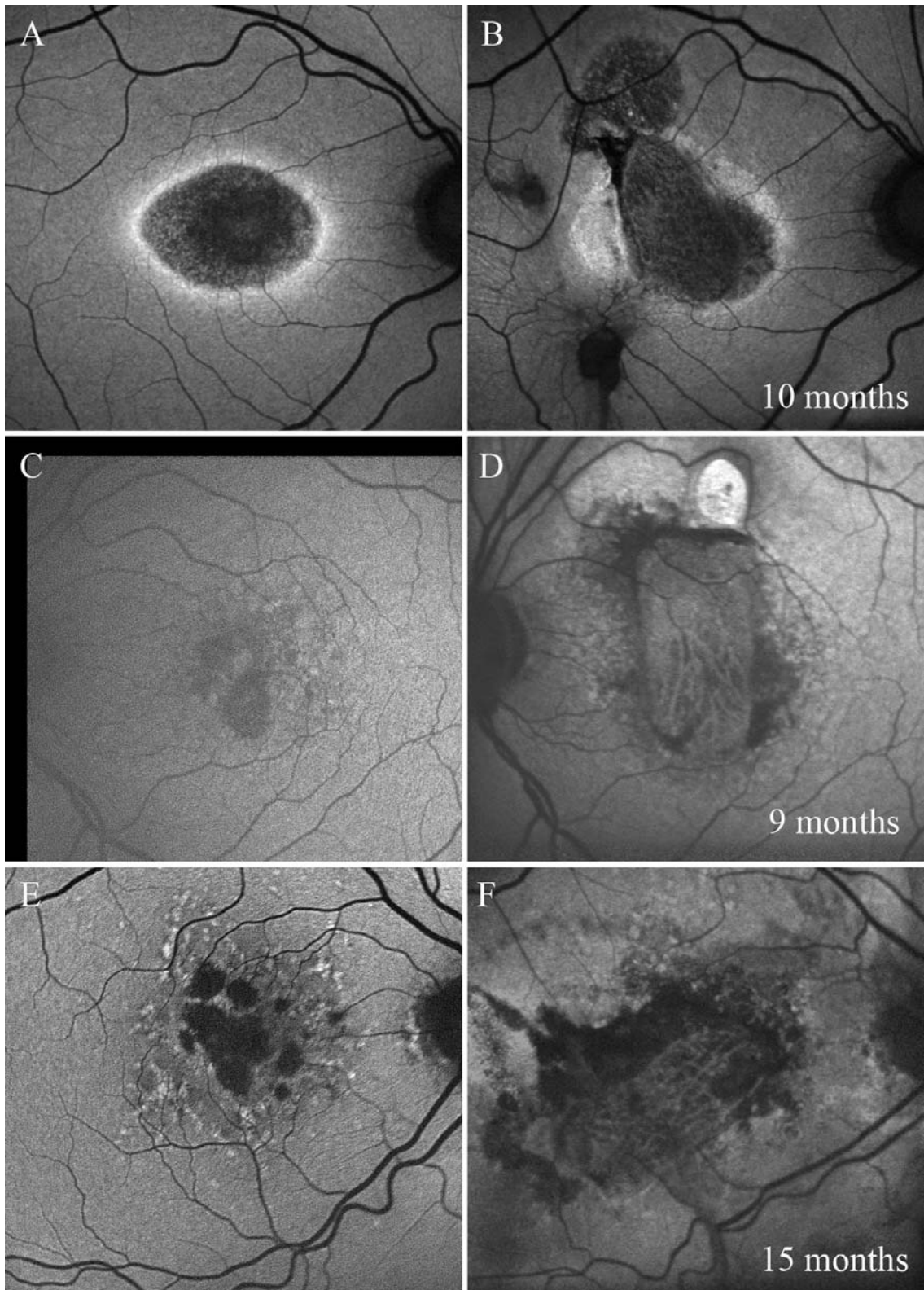


**Figure 4.9 RPE graft in atrophic disease: graft perfusion**

Fundus photographs and angiographies of patient 6 (A-C) at baseline and (D-F) at 5 months postoperatively. (B, E) Early phase fluorescein angiography showed choriocapillaris perfusion in the temporal portion of the graft. (C) Indocyanine green angiography showed distinct choroidal vascular pattern within the graft, different from the recipient choroidal bed. (F) The graft choroidal vessels are also most prominent at its temporal portion.

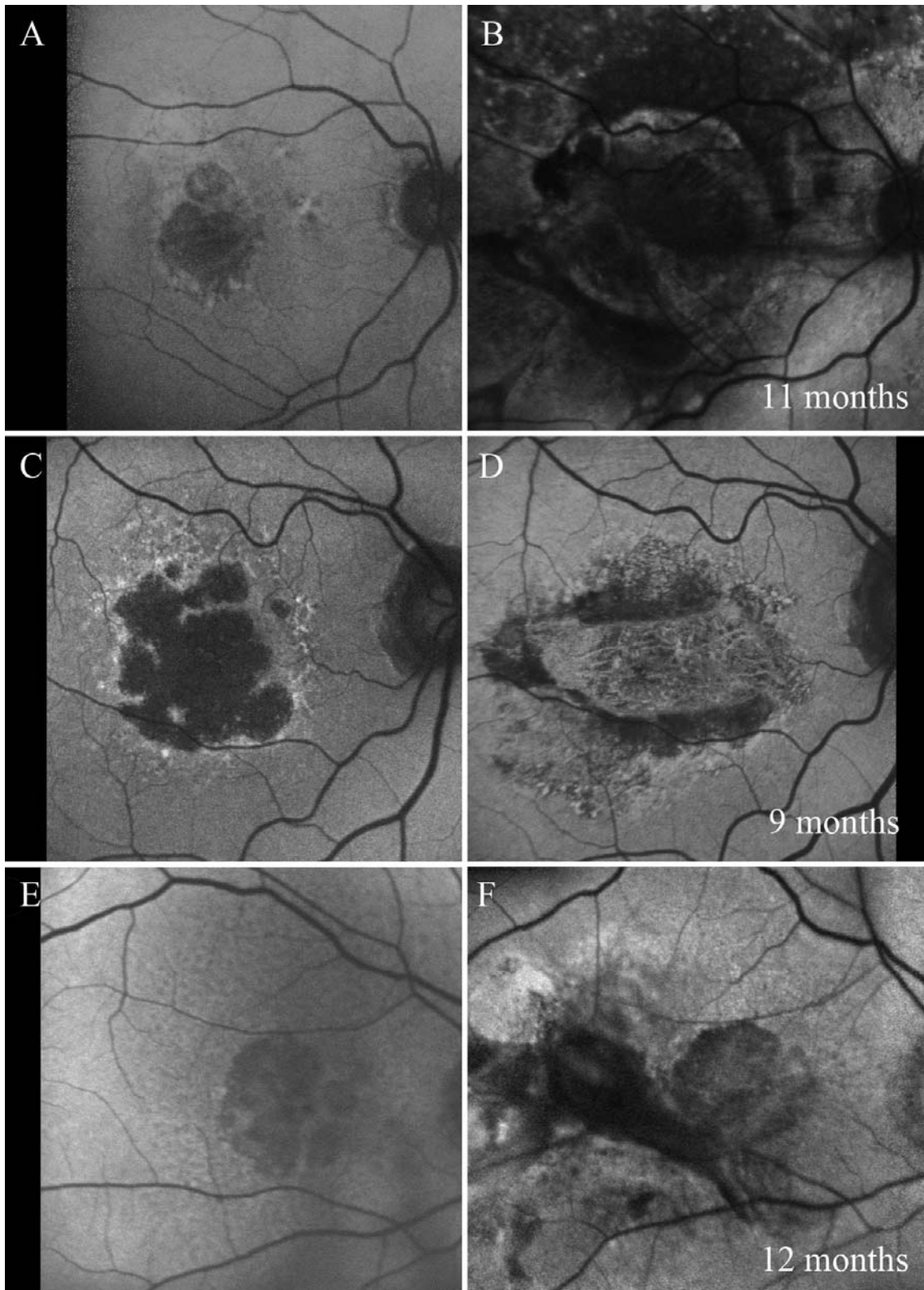


**Figure 4.10 RPE grafts in atrophic disease: autofluorescence in patients 1 -3**  
Fundus autofluorescence (AF) images before and after autologous RPE-choroid graft in (A, B) patients 1, (C, D) patient 2 and (E, F) patient 3. Graft AF signal is present over all 3 grafts. Note that there is RPE atrophy (dark areas) in the regions where the macular retinotomies were created in each of the 3 patients.



**Figure 4.11 RPE grafts in atrophic disease: autofluorescence in patients 4 -6**

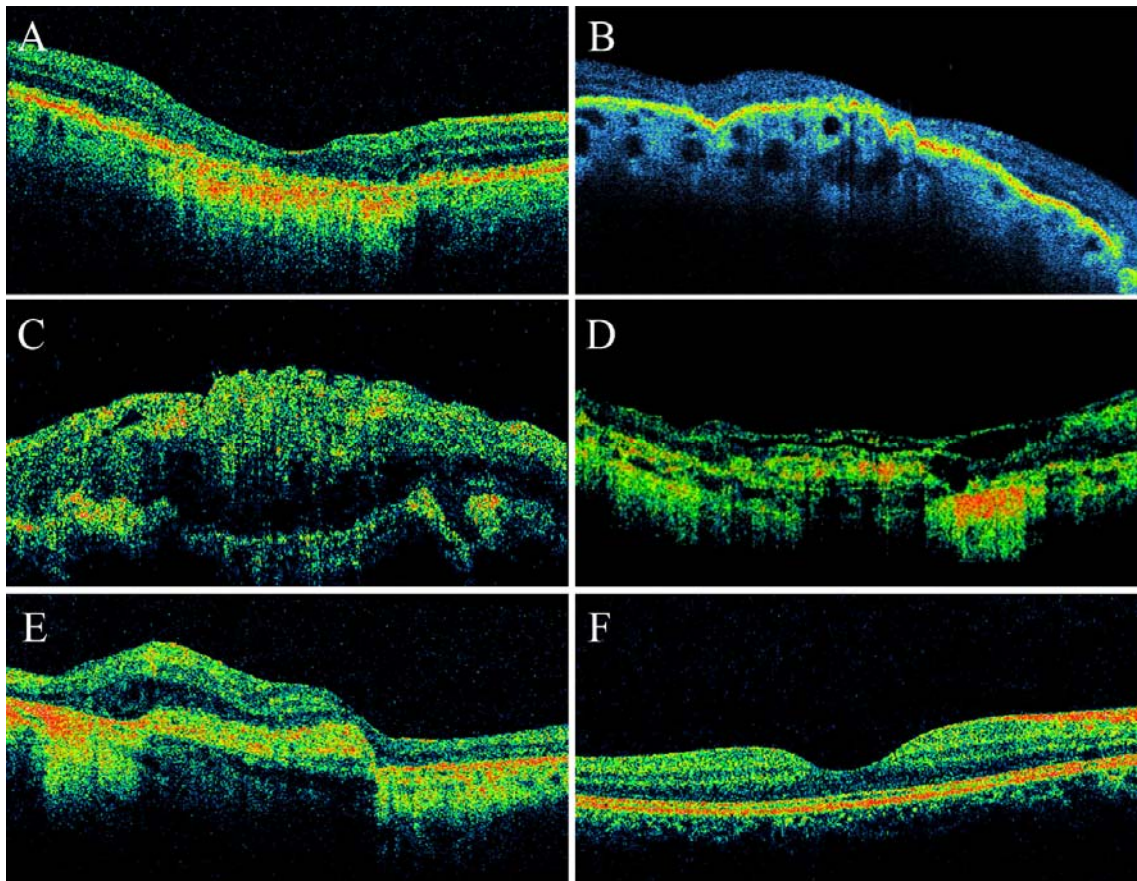
Fundus autofluorescence (AF) images before and after autologous RPE-choroid graft in (A, B) patients 4, (C, D) patient 5 and (E, F) patient 6. (B) In patient 4, graft AF signal is weak and the small area without AF signal inferotemporal to the graft is due to masking by epiretinal membrane. (D, F) AF is present over the region of the graft in patients 5 and 6. (D) There is a round area of increased AF superior to the graft in patient 5 corresponding to the macular retinotomy that did not close postoperatively.



**Figure 4.12 RPE grafts in atrophic disease: autofluorescence in patients 7 -9**

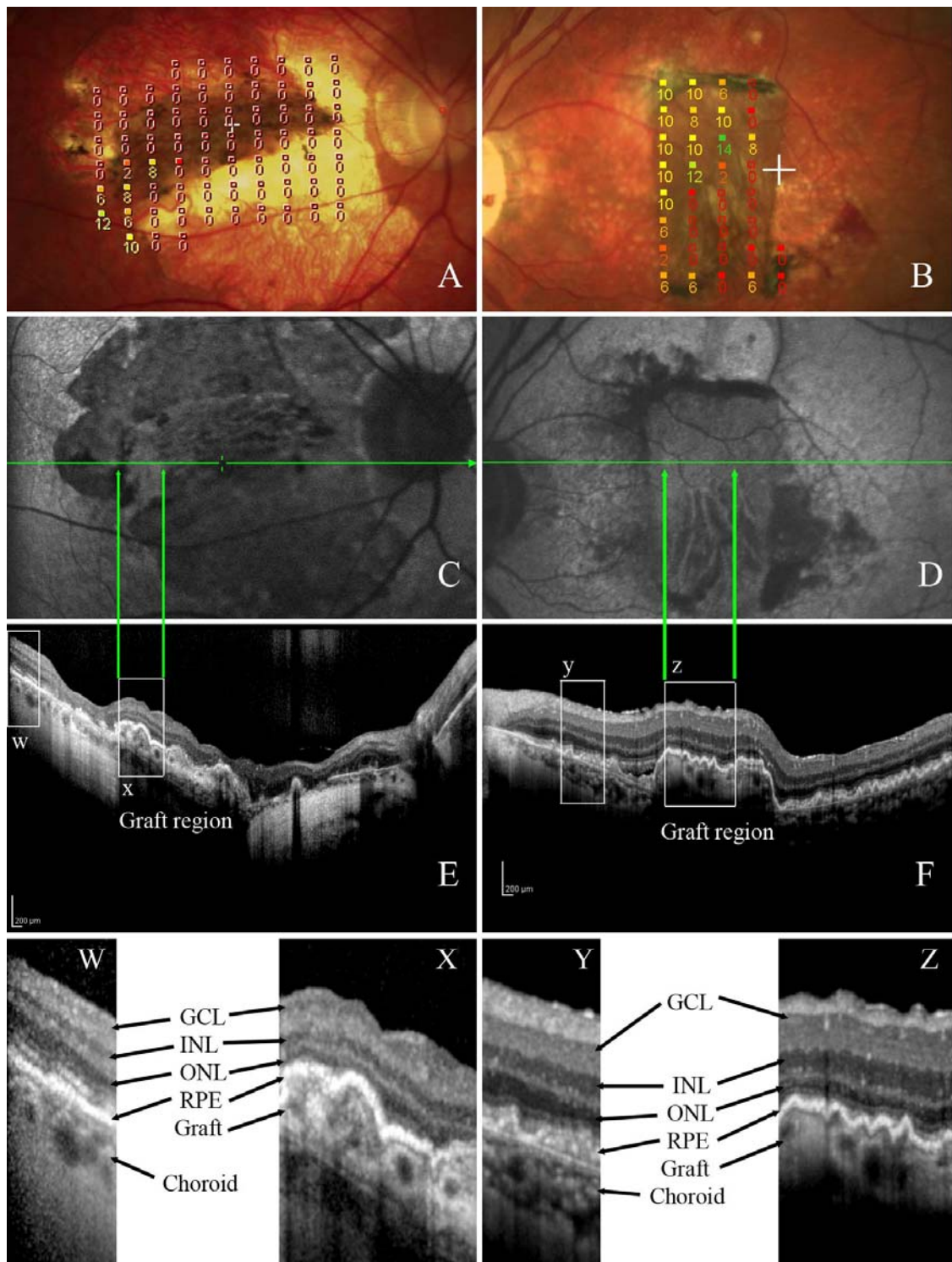
Fundus autofluorescence (AF) images before and after autologous RPE-choroid graft in (A, B) patients 7, (C, D) patient 8 and (E, F) patient 9. Graft AF signal is weak in patient 7 (B) due to masking by thick epiretinal membrane. (D, F) AF is present over graft in patients 8 but is only very faint in patient 9, temporal to the pre-existing geographic atrophy. (F) There is a round area of increased AF signal superotemporal to the graft in patient 9 corresponding to the region of macular retinotomy that did not close postoperatively.





**Figure 4.13 RPE grafts in atrophic disease: variation in retinal structure**

(A) Preoperative optical coherence tomography (OCT) images of patient 9 showed outer retinal atrophy typically seen in atrophic macular diseases. (B) At 1 week, choroidal vessels could be visualised as circular hyporeflective areas within the graft choroidal tissue in patient 8. (C) Retinal thickening and epiretinal membrane associated with oedematous cystic changes over the graft in patient 7 at 11 months. (D) Retinal atrophy and epiretinal membrane associated with atrophic cystic change in patient 1 at 38 months. (E) Retinal oedema adjacent to foveal atrophy over the graft in patient 2 at 24 months. (F) OCT scan of the authors' right eye showing normal retinal structures.



**Figure 4.14 RPE grafts in atrophic disease: structure-function correlation**

(A) Microperimetry map in patient 1 demonstrates retinal sensitivity over the temporal portion of the graft at 45 months. (B) Microperimetry map in patient 5 demonstrates retinal sensitivity over the superior portion of the graft at 26 months. (C, D) Spectralis optical coherence tomography (OCT, through the green lines) with fundus autofluorescence imaging in the region with retinal sensitivity over the graft allows structure-function correlation. (E, F) OCT shows rescue of outer nuclear layer by the RPE patch graft. Segments of the OCT scan were enlarged to illustrate that all layers of the retina were preserved over the patch graft (boxes X and Z) as compared with regions unaffected by RPE atrophy (boxes X and Y). Abbreviations: GCL, ganglion cell layer; INL, inner nuclear layer; ONL, outer nuclear layer; RPE, retinal pigment epithelium.

## 4.5 Discussion

These results demonstrated that autologous RPE-choroid patch graft can be performed in patients with atrophic macular diseases. However, there was significant intra- and postoperative complications which contributed to an overall loss of central visual function following graft. Nevertheless, microperimetry demonstrated retinal sensitivity supported by autologous RPE graft in 7 of the 9 patients. In 2 of these patients, the natural preferred retinal loci were over the patch, implying good quality of retinal function supported by the graft.

Although this is a preliminary study and consists of only 9 patients, the extensive data collected can be used to guide the design of possible future trials exploring novel therapies in atrophic macular disease. The results and implications for future clinical trials will be discussed in the following 4 sections: (1) recruitment and eligibility criteria, (2) feasibility and safety outcomes, (3) functional assessments and (3) structural assessments.

### 4.5.1 Recruitment and eligibility criteria

The aim of the exclusion/inclusion criteria was to identify patients who have noted recent decline in visual function so that patch graft may prevent visual loss prior to photoreceptor cell death.

Over the course of the atrophic disease study, 32 patients were referred for consideration of RPE patch graft because they had subjective decline in vision. Nine (28%) were enrolled into the study and the remaining 23 were excluded because their VA were better than the entry criteria. There were 2 important issues arising from the use of VA to determine disease progression. First, there's significant disagreement between Snellen and ETDRS VA measurement. Second, VA tends to remain stable despite progression of atrophic disease and subjective decline in visual function.

Falkenstein *et al.* (2008) reported that VA measured on Snellen charts was on average 2 lines worse than that measured with the ETDRS charts. In a subset of 30 patients who had Snellen VA of 6/60, the corresponding mean ETDRS VA was 0.68 logMAR (~6/30); a discrepancy of around 3 lines. Therefore, the author's observation of mismatch between Snellen and ETDRS VA in patients with atrophic macular disease is consistent with the study by Falkenstein *et al* (2008). Such discrepancy may be related to the non-standardised testing method and conditions (i.e. variable testing distance and reduced or non-uniform Snellen chart luminance). Another reason for the

discrepancy between Snellen and ETDRS VA may be related to the small island of central vision in some patients with atrophic macular disease. In the ETDRS chart, there are 5 letters per row. In contrast, there are only 1, 2 and 3 letters on the 6/60, 6/36 and 6/24 lines respectively. A patient with a small central island of vision may not be able to locate these larger letters on a Snellen chart and yet is more likely to find at least 1 of the 5 letters on the ETDRS chart with equivalent letter size. The ETDRS chart has now been accepted as a standard for all clinical trials. The author has therefore collaborated in further studies during the course of this Thesis to validate the test-retest variability of VA measured on the ETDRS chart using standardised protocol in a cohort of AMD patients during the course of this thesis (Patel *et al.* 2008).

Some of the patients who were not eligible for transplantation were monitored by the author over a course of 1-2 years. It was noted that the majority of these patients had subjective decline in visual performance that was not reflected in any change in VA. Further examination of their FAF images showed definite enlargement of RPE atrophy. A retrospective review (see **Appendix 1**) of serial microperimetry in 9 of these patients with stable VA but enlarging RPE atrophy on FAF imaging showed statistically significant decline in the mean retinal sensitivity in the loci adjacent to dense scotoma (defined as loci where brightest stimulus was not detected) over 6-12 months (Chen *et al.* 2010). During the same time interval, there was no significant decline in mean retinal sensitivity or fixation stability. At the same time, a separate study also described a similar method of analysing serial microperimetry using peri-lesional sensitivity change to detect disease progression over 2 years (Meleth *et al.* 2010). Future cell transplantation studies may need to consider the use of serial microperimetry rather than VA to identify those patients with the most rapid functional decline.

In retrospect, it becomes apparent that by setting the VA cut off at 6/36 and 6/24 for the IMD and AMD cohorts respectively, this study was only able to recruit patients with advanced disease; characterised by extensive loss of photoreceptor cells. Future trials investigating novel rescue therapies in atrophic diseases will need to consider the limitation of using reduced VA as entry criterion. However, this restriction is difficult to overcome especially if the novel therapy has potential risk to sight. The recent reports of high predictive values of certain fundus AF patterns around atrophic regions in dry AMD may help to identify high risk patients earlier in the disease process and therefore enable earlier experimental intervention (Holz *et al.* 2007). In future studies, other measures of disease progression, such as increase in dense scotoma size, decline in peri-

lesional retinal sensitivity or loss of cone using microperimetry or AOSLO, should be documented to help with patient selection in RPE transplantation.

#### **4.5.2 Feasibility and safety outcomes**

It is uncommon for patients with GA or IMD to undergo vitrectomy surgery. Although macular translocation has been performed on a handful of such patients, submacular surgery in eyes with atrophic macula has not been described previously. Therefore, feasibility and safety of submacular surgery in these patients were considered as important outcome measures.

##### **4.5.2.1 Feasibility of patch graft technique in atrophic disease**

The first and the last of the 5 surgical steps in autologous RPE-choroid patch graft can be considered to be standard components of most vitrectomies. Separation of the posterior hyaloid was achieved in all 9 patients. The need for multiple exchanges of intraocular instruments through the sclerostomy explains the high rate of entry site breaks (22%). Retinopexy of entry site breaks and donor site retinotomy were necessary. However, it was chosen not to perform retinopexy around the macular retinotomies because of extensive pre-existing RPE atrophy in the macular region and high likelihood of spontaneous closure under oil tamponade.

Several punctate retinotomies were required to create separation between atrophic retina and Bruch's membrane due to strong chorioretinal adhesion in regions of RPE atrophy. One patient developed a macular hole during bleb detachment due to severe foveal atrophy. Similar difficulty in bleb detachment has been described previously in patients with GA (Joussen *et al.* 2007). It is anticipated that bleb detachment will be easier to achieve in patients enrolled into future studies that recruit subjects with early disease and no RPE atrophy.

Preparation of the autologous RPE-choroid patch was possible in all patients. This step is associated with significant risk of bleeding especially when intraocular pressure drops during exchange of instruments. Frequent exchange was necessary because of the need for 2 types of scissors to cut out the RPE-choroid patch, a spatula to hold or grip the graft and a pair of forceps to remove the surplus retina. Timing of removing surplus retina had impact on the stability of the graft over the spatula. Early removal of the surplus retina tended to allow the graft to contract and its edge to curl around the spatula. Delaying removal of the retina until the graft is loaded on the spatula may prevent excessive curling but can lead to choroidal bleed and intraocular fluid

current within the vitreous cavity during exchange of instruments. Both peeling of the surplus retina and intraocular fluid current can potentially damage the RPE on the patch graft (MacLaren *et al.* 2007). Such trauma could be avoided if a readily available RPE patch graft was pre-loaded on a protective delivery device. Another problem of harvesting autologous RPE patch is the continued release of RPE from the donor site. This may lead to formation of PVR membrane adjacent to the donor site, leading to tractional opening of the donor site retinotomy and hence retinal detachment (as seen in patient 2). Furthermore, inferior PVR membrane may develop leading to inferior tractional detachment, retinal shortening and the need for extensive inferior retinectomy to reattach the retina (as seen in patient 6). During the course of this study, fresh surplus retina was kept with each patient's consent for further studies. We examined the histology of retina from patients in inherited dystrophy (Wickham *et al.* 2009) and used retina from patients with AMD as a bio-assay for assessing function of stem cell derived RPE *in vivo* (Carr *et al.* 2009a).

The most difficult step of this technique was the delivery of the patch graft into the submacular space. Once the macular retinotomy is made, enlargement was required to enable insertion of the graft. The enlarged retinotomies closed in all except 2 patients. One of these went on to develop recurrent retinal detachments due to failure to close the retinotomy. The location and size of the retinotomy may have impact on patient's choice of eccentric fixation and the amount of frictional trauma to the RPE. Furthermore, to minimise photoreceptor cells loss, laser retinopexy around the retinotomy was not performed and the bleb detachment was kept inflated whilst the graft was pushed into the subretinal space. Although the aspirating-reflux spatula designed by van Meurs (2003) was able to grip the graft, the main short-comings of this device was its inability to release the graft reliably. The elasticity of the choroid also led to folding of the edges of the graft around the elongated shaped spatula resulting in an effectively smaller graft. The under surface of the spatula also caused RPE loss at the site of graft insertion and may lead to choroidal trauma and bleed.

The approach to RPE-choroid graft delivery has been modified since the initial description in 2003. Van Meurs described the use of large temporal raphe linear retinotomy to avoid damage to the superior paramacular region (IOVS 2008;49:E-Abstract 4904). This may be beneficial in patients without foveal function due to inherited macular disease as they tend to displace the central scotoma to the superior visual field, i.e. placing the preferred retinal loci superior to the region of atrophy (Sunnness *et al.* 1996). However, for the right eyes of patients with GA from AMD, this approach

may not be suitable since the majority of patients tends to displace the central scotoma to the right of fixation in the visual field space and hence placing the preferred retinal loci near the temporal raphe (Sunness *et al.* 1996). Petersen *et al.* (2008) described the use of temporal 180° retinotomy near the ora to enable direct translocation of paramacular or equatorial RPE-choroid patch graft. Although this may avoid retinotomy related frictional damage to the graft surface, the technique is more complex with a greater risk of PVR. To facilitate release of the patch graft, Maaijwee and colleague (Maaijwee *et al.* 2008b) described the use of an electric vibrator (from a mobile phone) attached to subretinal forceps and more recently Knulst *et al.* (2009) described a micro-scale thermal tissue gripper that enables reliable release of tissue in fluid phase. However, it has yet to be shown that these instruments lead to better surgical and functional outcomes.

#### 4.5.2.2 Post-operative complications

The post-operative complications seen following RPE-choroid graft in this group of patients are similar to those described previously in patients with neovascular AMD (Joussen *et al.* 2006; MacLaren *et al.* 2007).

Intra-operative and continued post-operative release of RPE cells from the mid-peripheral RPE donor site into the vitreous cavity may contribute to the formation of PVR membrane and ERM leading to donor site break, opening of the donor macular retinotomy, retinal detachment and macular pucker. Retinal detachment occurred in 3 of 9 patients. These were related to retinal break near the donor site, inferior PVR and re-opening of macular retinotomy, respectively. The high rate of detachment is comparable to that reported by Joussen and colleagues (2007) in which 5 of the 12 patients had post-operative retinal detachment. The high rate of detachment was the main reason for termination of the clinical trial before enrolment of 10 patients from each arm of the trial.

CNV developed in 2 patients and confirmed on angiography at 11 and 26 months respectively. Both of these patients were at risk because they were greater than 50 years of age and one of these also had contralateral neovascular AMD. The patch graft prevented centripetal growth of the CNV. However, in patient 5, there was subretinal fluid extending from temporal edge of the graft, around the inferior edge and to the nasal border of the graft. In this patient, development of CNV led to a shift in eccentric fixation from outside the graft to directly over the patch.

Complications after routine posterior segment surgery such as cataract, residual oil and glaucoma were also seen. Unfortunately, 2 patients developed post-operative scleritis which may be related to the multiple procedures required for retinal detachment repair. It is not known if prolonged exposure of the bare internal scleral surface (at the donor site) to intraocular silicone oil may also predispose the eye to recurrent scleritis.

#### **4.5.3 Functional assessments**

The purpose of RPE transplantation is to prevent further degeneration of the outer retina. Functionally, this can be shown by demonstrating stability of visual acuity, reading ability, retinal sensitivity, ERG responses and score in questionnaires exploring quality of life. Each of these outcome measures, alone, is unable to provide a complete picture of the status of retinal and visual function. However, most clinical trials have chosen VA as a primary endpoint. As discussed previously, VA may not be a suitable primary endpoint for treatment trials involving patients with atrophic macular disease just as VA is not considered as appropriate primary outcome measure in studies of glaucoma treatment. In both diseases, the aims of the therapy are to prevent loss of VA. This tends to occur late in the disease process. In the following paragraphs, limitations of each of the endpoint measure will be discussed.

##### **4.5.3.1 Acuity, contrast sensitivity and reading tests**

Distance VA declined in all patients after graft although the overall decline tended to be greater in those with IMD. The decline in VA at 6 months was followed by slight improvement at 12 months. This remained stable for up to 2 to 3 years after the graft. The partial recovery of VA loss at 6 months may be explained by adaptation to another preferred retinal locus (see next section). Similarly, there was a general trend for reduction in CS although this was reversed by 12 months.

Reading ability improved in 2 and declined in 7 patients. Interestingly, improvement in near visual function was found to be greater than distance VA following macular translocation (Eckardt *et al.* 1999; Fujikado *et al.* 2002; Mruthyunjaya *et al.* 2004). This discordance was attributed to reduction of the scotoma size. Improvement in reading ability and decline in distance VA in patient 5 may be explained by the enlargement of visual span as fixation shifts from the small foveal central island to the edge of central scotoma (Sunness *et al.* 1997). Alternatively, this patient's poor reading performance pre-operatively may be due to factors related to perceptual span, eye movement or motivation (Robbins and McMurray 1988; Bullimore



and Bailey 1995). Another possibility is the greater test-retest variability in reading assessment using the MNRead charts in patients with macular diseases compared to those without (Subramanian and Pardhan 2009).

Despite the overall loss of acuity and reading ability, this study has been successful in demonstrating the proof of principle in RPE transplantation. This paradox can be understood when VA outcome is examined in conjunction with microperimetry findings.

#### 4.5.3.2 Microperimetry tests

Microperimetry demonstrated convincing evidence that RPE graft can rescue retinal function. The patch graft supported retinal sensitivity in 7 patients. Two of these also used the patch to support fixation. These findings suggest that VA may not be a suitable primary endpoint in trials involving atrophic disease. The 2 patients with no sensitivity over graft had severe epiretinal membrane and graft fibrosis, respectively.

In some of these 7 patients, the area of highest sensitivity was near the edge of the graft. This may be an artefact due to tracking error or stray light from reflection of the light stimulus. However, correlation between preserved photoreceptor cell layer on OCT and retinal sensitivity in the same region provides evidence that the intact outer retinal structures supported the edge of the graft may be contributing to function. Although photoreceptor cells were rescued over the patch graft, these regions were not chosen as the preferred retinal locus for fixation in all patients. Several reasons may explain this observation: (1) retinal sensitivity was not as high as other retinal loci (outside the graft) which can potentially provide a better VA or CS, (2) quality of vision supported by graft may be poor due to metamorphopsia arising from irregular graft surface and, (3) the region of retinal function rescue by the graft did not have the horizontal span for reading task. It is important to note that all patients had large central or paracentral scotoma and therefore had no photoreceptor cells to rescue in large portions of the macular region even before the graft.

Comparison between pre and postoperative microperimetry maps was not possible because of widespread distortion in retinal vasculature landmarks induced by grafting. However, it was the impression of the author that the size of scotoma appeared to have enlarged after patch graft. Quantification of the change in scotoma size was not possible because the preoperative microperimetry testing grids used were too small for comparison with postoperative microperimetry maps. Enlarged scotoma may be related to a combination of (1) mechanical or photic injury during submacular surgery, (2)

ischaemic or hypoxic injury during the 1<sup>st</sup> week after surgery while the graft was not yet vascularised and (3) natural history of atrophic disease progression.

Follow-up microperimetry at 2-3 years in selected patients showed an overall decline in retinal sensitivity over the patch. In view of the small sample size, lack of a control group and the potential test-retest variability of retinal sensitivity measurements in patients with macular disease, it is difficult to interpret these findings.

Future studies using microperimetry as a trial end point will benefit from improvement in the onboard NAVIS software and testing strategies of the Nidek MP1. Shortening of testing time may improve reliability. An increase in the range of stimulus brightness (from 20 to 40 dB) will allow more precise mapping of the absolute scotoma. The ability to import pre-captured fundus image which has already being co-registered with OCT to identify the foveal centre will enable more accurate centralisation of testing grid.

#### 4.5.3.3 Electrophysiological studies

Similar to VA measures, electrophysiology testing demonstrated that patch graft led to a general reduction in macular and retinal function.

Full-field ERG demonstrated vulnerability of the cone and, to a lesser extent, rod systems to patch graft surgery. This was the case in both IMD and AMD patients. The reduced cone and rod system function is likely to be at the level of photoreceptors since a-wave amplitude was also reduced. Significant reduction in full-field ERG has also been reported following macular translocation, which is a more complex procedure that involves 360° retinectomy and total retinal detachment (Luke *et al.* 2001). The reasons for the decline after graft may include: (1) pre-existing photoreceptor cell dysfunction and vulnerability to the insult of surgery, (2) laser and harvesting of autologous RPE-choroid destroys a significant portion of the retina (Schuurmans *et al.* 1977), (3) prolonged surgery with photic toxicity, (4) prolonged silicone oil tamponade, (5) post-operative retinal detachment (Hamasaki *et al.* 1969) and (6) disease progression. None of these factor would have made a major contribution to the reduction in ERG based on previous animal experiment findings (Wallenten *et al.* 2008; Mackiewicz *et al.* 2007). Interestingly, 3 patients had a follow-up full-field ERG after the frist post-operative test and partial recovery of cone system ERG response abnormalities was noted in 2 of these. This peripheral cone system recovery is also mirrored in the change in peripheral rings of the multifocal ERG (see below)

Pattern ERG was undetectable in 4 patients pre-operatively and of the remaining 5 with detectable responses, 2 of these became undetectable after graft (patient 3 and 7) probably due to disease progression and iatrogenic damage to the macular photoreceptors. Interpretation of multifocal ERG was complicated by the use of different preferred retinal loci before and after surgery in most patients and the inability of the ERG operator to monitor fixation during testing. Also, the size of central hexagon is relative large in comparison to the graft so that functional gain or decline in small regions (e.g. 1 disc area) cannot be detected reliably by the multifocal technique. Most patients had noisy tracings pre- and pos-operatively in the central and paracentral hexagons. However, loss of recordable baseline mfERG waveform in the central hexagon is probably related to significant iatrogenic injury to the macular cones. Bleb detachment of the macula has been shown not to affect mfERG in a large animal model (Kyhn *et al.* 2008). However, the same cannot be assumed in patients with subclinical or clinical atrophic macular disease. Patient 1 had improvement in these central rings but it may have been artefactual since the size of his central island of vision was less than a third of the disc area. This patient later developed another preferred fixation locus temporal to the graft. The improved paracentral response may reflect this shift in fixation locus. The delayed recovery of peripheral cone function, as seen on multifocal and full-field ERG is difficult to explain. Long-term follow-up ERGs will be needed to confirm these findings.

Although full-field ERG was feasible to perform in this group of patients, the wide inter-individual variation, test-retest variability and lack of robust normative database in elderly patients over age of 80 makes its interpretation difficult. Eccentric viewing, which occurred in most of these patients, complicates the interpretation of mfERG. Therefore, in future studies of patch graft, it will be essential to monitor fixation during mfERG. Furthermore, smaller hexagon in the stimulus array will be needed to detect changes within a smaller region of the retina. Advances in multimodal imaging technique combining smaller mfERG stimulus size, optical coherence tomography and scanning laser ophthalmoscope imaging may allow more accurate and reliable correlation between graft perfusion, RPE function, intraretinal architecture and retinal function after patch graft (Dudgeon *et al.* 2007).

#### 4.5.3.4 Quality of life questionnaires.

At baseline, there was a trend for worse quality of vision and vision-related quality of life in patients with AMD compared to IMD. Both near and distance tasks were more

difficult for patients with AMD. They also had more role limitations, poorer mental health and social functions, and greater dependency on others. This may also be a reflection on the lower scores on the general health related quality of life questionnaire. In general, the AMD group had a perception of poorer physical health.

Comparing post- to pre-operative scores, there was a trend for patients to have worse peripheral and colour visions following patch graft surgery. This is in keeping with the findings from full-field ERG where both scotopic and photopic responses declined. The decline in peripheral vision was particularly marked in the AMD group probably because 2 of 4 patients developed retinal detachments. Despite overall decline in retinal function, there was improvement in mental health in the IMD group and a trend for lesser role limitations in the AMD group. These observations highlight the importance of having a control group in future trials so that such improvements in quality of life are not attributed solely to treatment effect. In the general health questionnaires, there were no major changes in the IMD group but patients in the AMD group had a trend for declining social functioning, physical and mental health as well as emotional well-being.

Due to the variability of the responses, this pilot study had insufficient power to draw conclusions from the questionnaire results (Mangione *et al.* 2001). Future trials using the 25-Item National Eye Institute Visual Function Questionnaire may use the results from this study to perform power calculation so that adequate sample sizes are used for detection of meaningful change in the subscale scores (Mangione *et al.* 2001).

#### **4.5.4 Structural assessments**

Functional success of autologous RPE transplantation depends on integration of the patch graft with the underlying choroidal bed and survival of the RPE layer. These can be demonstrated on fundus angiography and AF imaging. OCT can also demonstrate vascular structures within the choroid of the patch graft and rescue of the outer nuclear layer over the graft. During the course of the study, the time-domain OCT (StratusOCT) was replaced by several types of spectral-domain OCT scanners. Clinical trials that report structural outcomes in therapies for macular diseases often use the central macular thickness as an endpoint measure. However, this is not a suitable endpoint for this trial since some patients do not have clearly identifiable foveal features due to severe atrophy and the region of outer nuclear layer rescue is not necessarily located at the fovea. In the following paragraphs, the structural outcomes will be

summarised and the limitation of each of the endpoint measure will be discussed further.

#### 4.5.4.1 Fundus angiography

Similar to that observed in the series described by Jousseaume and colleagues (2007), ICG angiography demonstrated perfusion of the patch graft despite clinical evidence of choroidal atrophy in the area directly underneath the graft. The evidence of graft perfusion came from the differences in the pattern of ICG filling in the macular region before and after grafting.

Intentional and unintentional surgical trauma to the Bruch's membrane during insertion of the graft may have promoted connection of choroidal vessel between recipient site and the graft. Damage to the Bruch's membrane may incite inflammatory response which aid proliferation of endothelial cells at the interface, between the residual choriocapillaris at the recipient site and the large choroidal vessels of the under surface of the patch graft. Experiment in normal pigs has demonstrated bridging vessels between the recipient choroidal bed and the choroid graft as early as 1 week, even if the Bruch's was not intentionally damaged and when the graft was placed upside down (Maaijwee *et al.* 2007b). Similarly, transplanted partial thickness autologous RPE-choroid patch in rabbits were perfused by 1 week after grafting (Hu *et al.* 2008). Unfortunately, angiographies were not performed in patients until 5-12 months after grafting. Therefore it is not known how early these grafts became perfused in this cohort of patients.

#### 4.5.4.2 Graft autofluorescence

Fundus AF imaging demonstrated varying patterns and intensities of AF Signal over the patch graft. Linear pattern was commonly seen and this is related to the irregular ridges on the surface of the graft and the linear RPE hyper-pigmentation. Contraction of the elastic patch graft after it is released in the submacular space is likely to contribute to the ridges over the surface of the graft. Homogenous AF signal on the portion of the graft adjacent to the retinotomy (patients 1, 5 and 8 are good examples) implies that the linear patterns of AF may also arise from abrasive trauma during insertion of the patch through the retinotomy.

Absolute intensities of the patch graft are difficult to interpret due to confounding factors such as lens and other media opacities. However, significant reduction in patch graft AF signal in 3 patients was worth noting. Patient 4 has low AF

signal at the distal portion of the graft which seems to follow the oval shape of the original Bull's eye lesion. The loss of signal is most likely to be related to trauma during insertion of the patch rather than absence of outer segment interaction with the graft RPE. Patient 7 has large areas of low autofluorescence signal over the patch due to masking effect from the ERM. Patient 9 has minimal autofluorescence signal due to submacular haemorrhage and trauma to the graft at the time of transplantation. Most grafts also had pigmentation at the edge of the graft which masked autofluorescence signal.

The autofluorescence pattern outside the region of the graft did not seem to change significantly except for slight enlargement of the hypo-autofluorescent regions related to atrophy expansion. Given the limitations of FAF imaging, future studies need to explore the use of adaptive optics scanning laser ophthalmoscope (AOSLO) to image grafted RPE (Morgan *et al.* 2009). However, it may not be feasible to use AOSLO in these patients due to the irregularity of the RPE monolayer on the graft and the frequently observed cystic change within the overlying retina.

#### 4.5.4.3 Optical coherence tomography

OCT demonstrated that intraretinal architecture was usually abnormal over the graft. This is not surprising since most of the macular region was affected by retinal atrophy even before patch grafting. Specifically, the most common features were intraretinal cystic change and outer nuclear layer and photoreceptor cell segments loss.

Most patients had some degree of intraretinal cystic change accompanied by distortion of retinal surface due to ERM. Another cause of cystic change may be related to failure of RPE pump function. In the 2 patients with CNV adjacent to the graft, the intraretinal cystic change and subretinal fluid are most likely to be related to leakage from the CNV rather than traction from ERM.

Most scans of retina over the graft showed disorganised outer retinal structures with reduced outer nuclear layer thickness and no clear hyper-reflective line that correspond to the inner segment/outer segment junction. Occasional areas with intact outer retinal structures tended to localise at the portion of the graft closest to the retinotomy. Presence of outer nuclear layer and intact inner segment/outer segment junction over the graft is consistent with the hypothesis that photoreceptor cells can be rescued by RPE transplantation. Histological studies in rabbits also showed that the outer segments can regenerate over 3 months when autologous RPE-choroid patch graft was used to reconstruct a pre-existing defect in the RPE that was created 2 weeks prior

to transplant (Hu *et al.* 2008). In the same study, histology demonstrated intact outer nuclear layer but absence of outer and inner segments, and choriocapillaris 2 weeks after RPE debridement. Without autologous RPE patch graft, the outer nuclear layer was lost after 3 months. Unfortunately, spectral domain OCT was not available during the early phase of the trial. Therefore it was not possible to study the early rescue effect of transplanted RPE on degenerating photoreceptor cells.

Future clinical studies of RPE transplantation may explore the use of AOSLO to image cone mosaic before and after grafting (Liang *et al.* 1997). However, it should be noted that AOSLO imaging will not identify cone photoreceptors cells without inner and outer segments since image acquisition depends on the presence of their wave-guiding properties (Yoon *et al.* 2008). Therefore, AOSLO may not be able to identify cone mosaic during the first few of weeks after RPE cell transplantation.

#### **4.5.5 Future directions in patch graft surgery in atrophic disease**

There are 3 components of the current patch graft approach that require further modifications. These areas are: (1) the use of alternative sources of cells such as RPE derived from human embryonic stem cell (hESC) or induced pluripotent stem cell (iPSC), (2) the use of specialised delivery device that can protect the graft from intraocular fluid current and frictional trauma at the sites of sclerostomy and retinotomy, and (3) the use of pharmacological adjunct and visco-elastic substances to enable atraumatic bleb detachment and maintenance of submacular space during graft insertion.

Alternative RPE sources need to be explored because autologous equatorial RPE may be diseased in patients with macular disease and harvesting of autologous RPE-choroid patch increases the risk of surgical complications. Although this trial excluded patients with obvious abnormalities of peripheral fundus AF and ERG evidence of severe generalised retinal dysfunction, histological examination of the surplus retina removed from 4 of the 5 patients with IMD demonstrated abnormalities in the cone or rod photoreceptor inner and outer segments (Wickham *et al.* 2009). This suggests that current clinical tools cannot exclude the possibility of generalised primary photoreceptor cell disease and therefore secondary peripheral RPE dysfunction in a patient with clinical evidence of isolated macular disease. There are also histological evidence of photoreceptor cells degeneration in regions with preserved RPE in patients with GA from AMD. Given that some patients with AMD may have the Y420H variant of the complement factor H gene (Haines *et al.* 2005; Edwards *et al.* 2005; Klein *et al.*

2005; Zarepari *et al.* 2005; Hageman *et al.* 2005) and that local production of CFH may be implicated in the pathogenesis of AMD, autologous source of RPE may not be a suitable long-term option for treatment of GA. Alternative sources of RPE derived from hESC or iPSC with genetic modification should be explored.

The current patch delivery device is relatively small and is able to hold and release patch grafts through manual control of a fluid-filled syringe. Further modifications are required to enable delivery of a larger sized pre-made patch graft. The ideal device will be made from disposable material and packaged with the pre-made patch graft ready for implant. It will have a protective cover around the patch graft to minimise loss of RPE due to fluid current or friction at the sclerostomy and retinotomy. The release of the graft will need to be simple and reliable. Such device is currently being developed.

Currently, the macula is detached by infusing the same fluid as the intraocular infusion; Hartmann's solution. Adhesion between atrophic retina and bare Bruch's membrane appeared to be stronger than that between photoreceptor cells and RPE. Future studies will need to explore pharmacological agents that may be added to the fluid used for bleb detachment to reduce retinal-Bruch or retinal-RPE adhesion. The use of sodium hyaluronate (a natural component of vitreous) to maintain bleb detachment may enable less traumatic delivery of the graft and more controlled manipulation of the patch within the submacular space. Sodium hyaluronate is available commercially as Healon® and is approved for use within the eye. It has been used to temporarily detach the retina in animal models of retinal detachment and subretinal visual prosthesis implant (Cook *et al.* 1995; Schanze *et al.* 2006).

#### **4.5.6 Strengths and limitations of the study**

The strengths of the study were its prospective design and the detailed functional and structural assessments. Furthermore, the procedure was carried out by a single surgeon who already had experience in the technique of autologous patch graft. Therefore, the effect of surgical learning curve was unlikely to confound the results of the studies.

The prospective design of the studies enabled extensive and detailed pre- and post-operative examination of retinal function and structure. The use of microperimetry provided the most compelling evidence of functional rescue whereas standard visual acuity, quality of life questionnaire and electrophysiological testings were not useful for demonstrating the rescue effect of RPE transplantation. However, these investigations were important for safety assessment.



The main limitation of the study was the use of moderately reduced VA as an entry criterion. This resulted in low recruitment rate and enrolment of patients late in the disease process. The early termination of the study due to high operative complication rates also resulted in a small sample size. Because of these limitations, it was not possible to determine the factors that contribute to the varying degrees of functional rescue.

Another limitation of the studies was the evolving technology and the steep learning curve in obtaining the various outcome measures during the course of these trials. During the course of the autologous RPE graft trials, OCT technology has evolved from the time-domain StratusOCT to various SD-OCT scanners. Each of the SD-OCT scanners differs in their user interface and quality of image acquired. The superior quality of OCT image from the more recently available Spectralis® enabled detailed structure function correlation.

Lastly, an intrinsic limitation of psychophysical outcome measure is test-retest variability. Prior to commencement of the clinical trials, there was little information on the variability of reading ability test (MNRead) and microperimetry test (Nidek MP1). More recently, studies have demonstrated larger variability in reading ability measurement among patients with poor vision compared to those with normal vision (Subramanian and Pardhan 2006; 2009). Similarly, there is also evidence to suggest significant intra-examiner, intra-session test-retest variability in microperimetry among patients with macular disease (Chen *et al.* 2009).

#### **4.5.7 Clinical implications and conclusions**

This study showed that it is possible for retinal function to be maintained over autologous RPE-choroid graft for a prolonged period in patients with atrophic macular disease. However, the high operative complication rate and poor visual outcomes raise concerns regarding the safety of autologous RPE-choroid patch grafts. Based on these findings, we postulate that the poor visual outcomes may be due to choice of late cases, pre-existing retinal or RPE dysfunction, surgical insult to the remaining macular photoreceptors and the transplanted RPE and genetically pre-determined late primary photoreceptor cell loss. Therefore, current technique of autologous RPE-choroid graft cannot be recommended for patients with acquired or inherited macular atrophy.

## **4.6 Contribution**

Author's contribution to the works presented in this chapter are summarised in **Table 4.11**. As a spin off from the work on RPE patch graft, the author also published a novel method of analysing serial microperimetry which will be useful for future clinical trials using retinal sensitivity as one of the core outcome measures (see **Appendix 1**).

**Table 4.11 Contribution list for the dry macular degeneration studies**

Contribution category	Details of contribution
1	<p>Conception and design <b>Author:</b> <u>drafted protocol, patient information and ethics application form for the dry AMD study. The author was not involved in setting up the inherited macular dystrophy study since study commenced before author started the thesis</u> GSU: drafted protocol, draft patient information sheet, draft ethics application form for the inherited macular dystrophy study LDC: approval of all study documents</p> <p>Preoperative data acquisition <b>Author:</b> <u>examined all 32 potentially eligible patients and performed their ETDRS VA, OCT, FAF and microperimetry. Author also performed preoperative baseline tests on patients 5 to 9</u> GSU: recruited 5 patients for this study and performed their baseline reading and microperimetry tests LDC: examined all 32 patients referred for patch graft and counselled all 9 patients prior to enrollment MMN: performed all electrodiagnostic tests Optometrist: performed all refractions</p> <p>Surgical procedure <b>Author:</b> <u>assisted in patch graft in patient 5 to 9 and removed the silicone oil in 3 of these patients</u> LDC: performed patch graft in all 9 patients 90%), GSU: assisted in patch graft in the patients 1 to 4</p> <p>Postoperative data acquisition and analysis <b>Author:</b> <u>examined all 9 patients post-operatively and performed their ETDRS VA, Pelli-Robson CS, reading test, microperimetry, quality of life questionnaires, FAF imaging, OCT and interpreted angiography and electrodiagnostics tests.</u> GSU: examined first 4 patients post-operatively LDC: examined all 9 patients post-operatively MMN: performed all electrodiagnostic tests Optometrist: performed all refractions</p>
2	<p>Writing <b>Author:</b> <u>wrote the entire chapter</u></p> <p>Revising <b>Author:</b> <u>revised the entire chapter</u> LDC: read the chapter and made suggestions PJC: read the chapter and made suggestions</p>
3	<p>Statistical analysis <b>Author:</b> <u>performed all statistical analysis</u> CB: supervised statistical analysis</p> <p>Funding PJC and LDC: obtained funding for the London Project to Cure Blindness</p> <p>Administrative and technical support <b>Author:</b> <u>arranged all post-operative visits and created all the graphs and figure montage from the image database</u> TB: arranged correspondence between ethics committee and research governance</p>

CB; Catey Bunce (statistician), CS; contrast sensitivity, ETDRS; Early Treatment Diabetic Retinopathy Study, FAF; fundus autofluorescence, GSU; Gurmit S Uppal (research fellow), LDC; Lyndon Da Cruz (supervisor), MMN; Magella M Neveu (electrophysiologist), OCT; optical coherence tomography, PJC; Peter J Coffey (supervisor), TB; Tina Burman (research co-ordinator), VA; visual acuity.

## **Chapter 5**

# **Autologous RPE Transplantation in Neovascular Macular Disease**

## 5.1 Background

Neovascular AMD, characterised by leakage of fluid or haemorrhage from CNV, can lead to acute and permanent central visual loss. Recent advances in intravitreal anti-VEGF therapies have shown promise in the treatment of these lesions with over one third of patients gaining 3 or more lines of VA at 12 month and maintained at 2 years after initiation of monthly or variable-frequency injections (Brown *et al.* 2006; Rosenfeld *et al.* 2006; Brown *et al.* 2009; Lalwani *et al.* 2009). However, the role of this therapeutic modality in patients with large submacular haemorrhage, pigment epithelial detachment or retinal pigment epithelial (RPE) rip is uncertain because VEGF blockade does not restore or rejuvenate the diseased RPE-choroid. Large surgical case series of macular translocation or autologous RPE-choroid graft and a pilot randomised controlled trial of translocation versus PDT, have shown visual function rescue in patients with neovascular AMD undergoing reconstruction of the submacular RPE (Eckardt *et al.* 1999; van Meurs and Van Den Biesen 2003; Toth *et al.* 2004; Uppal *et al.* 2007; Gelisken *et al.* 2007; Maaijwee *et al.* 2008a).

Previous reports showed that autologous RPE-choroid grafts harvested from within the macular region supported retinal function but this was not maintained after 5 years (Stanga *et al.* 2002; MacLaren *et al.* 2005). Aisenbrey *et al.* (2007) reported the long-term outcomes (mean follow up of 38.2 months) following macular translocation with three quarters of eyes not losing 3 or more lines. However, these authors were concerned with the ability of extra-macular RPE-choroid in maintaining foveomacular function in the long-term. Maaijwee *et al.* (2007a) reported VA stabilisation and improvement after RPE-choroid graft in the 11 patients who were followed for 4 years. However, they did not provide perimetric evidence of retinal function rescue by the graft. Assumption of long-term rescue cannot be made for several reasons. The source of RPE to be positioned under the fovea in full macular translocation is located at the vascular arcade (paramacula) if the macula is rotated  $>45^\circ$  around the disc. In contrast, RPE outside the vascular arcade (equatorial), where it is populated predominantly by rods, is chosen for harvesting of autologous RPE-choroid graft. Several studies have found topographic differences in the RPE gene expression and Bruch's membrane composition (Ishibashi *et al.* 2004; Bowes *et al.* 2006; van Soest *et al.* 2007; Kociok and Jousen 2007; Chong *et al.* 2005). Therefore, it is likely that there may also be topographic differences in RPE function and its ability to maintain the metabolic and functional requirements of the cone photoreceptor cells.

In previous studies, VA has been used as a marker for retinal function rescue after surgical intervention. However, VA is a measure of retinal function at the fixation locus and is therefore not necessarily equivalent to the ability of the patch graft in supporting central visual field. Alternative methods of assessing rescue of retinal function are (1) to determine the preferred retinal locus in relation to the graft and quantify fixation stability, and (2) to measure local retinal sensitivity over the region of the graft using a fundus-controlled perimeter (i.e. microperimeter) such as the Nidek MP1. Several groups have previously demonstrated, using microperimetry, that retinal function over the graft may be preserved for up to 20 months postoperatively (Joussen *et al.* 2006; MacLaren *et al.* 2007; Treumer *et al.* 2007b; Heussen *et al.* 2008). However, the long-term outcome of translocation surgery and autologous RPE-choroid graft as documented by microperimetry has not been characterised in detail.

## 5.2 Aims

In this chapter, the results of 3 retrospective studies examining long-term outcomes of RPE reconstruction in neovascular AMD are presented to answer the following questions:

1. What is the long-term functional and structural outcomes following full macular translocation in neovascular AMD?
2. What is the long-term functional and structural outcomes following autologous equatorial RPE-choroid patch graft in neovascular AMD/
3. How does the long-term functional and structural outcomes in the first 12 patients of the translocation cohort compare to the outcomes from the first 12 patients of the RPE-choroid graft cohort?

## **5.3 Specific Methodology**

### **5.3.1 Peri-operative variables**

The baseline demographic features and duration of symptoms were recorded. Pre-operative angiographies were retrieved from the electronic image database (ImageNet, Topcon, Tokyo, Japan) and graded independently according to the Macular Photocoagulation Study criteria (MPS Group 1991) by an experienced observer (Dr P. Patel, Locum Medical Retina Consultant). Intra-operative and early post-operative courses were reviewed. For macular translocation, the angle of foveal rotation, and the degree of cyclotorsion before and after counter-rotation surgery as measured on double Maddox rod were recorded. For patch graft, intra-operative complication and course were scored according to the system described by Maaijwee and colleagues (2008c). The outcomes of repair of post-operative retinal detachments and frequency of post-operative macular pucker due to dense epiretinal membrane (ERM) were also recorded.

### **5.3.2 Data collection and statistical analysis**

Data were analysed and graphs were constructed using SPSS for Windows, version 14.0 (SPSS Inc., Chicago, IL, USA). For all statistical comparisons, a p value of less than 0.05 was considered statistically significant.

For long-term outcomes, the mean, standard deviation (SD), median, interquartile range (IQR) and proportions were used to describe VA and retinal sensitivity measures in the subgroups. Wilcoxon signed ranks and McNemar tests were used to compare median VA and proportion of patients with a 0.3 logMAR (3 lines) gains or VA of 0.7 logMAR (Snellen equivalent of 6/30) or better for each group separately at the 1 year time point and the final visit.

For the comparison of long-term outcomes, baseline characteristics were compared between the macular translocation and patch graft groups using the Fisher's exact test (gender, lesion type) and the Mann-Whitney U test (age, duration of symptoms, lesions size, VA and CS). The change in VA and CS at 1, 2, 3 and 4 years between the 2 groups were compared using the independent sample t-test. The change in VA and CS between preoperative and follow up visits were analysed using the Friedman test.

## 5.4 Results

### 5.4.1 Full macular translocation long-term outcomes

#### 5.4.1.1 Patient characteristics

A total of 40 consecutive patients underwent surgery with the intention of full macular translocation during a 6 year period from 2003 to 2008. The mean (range) follow-up duration was 38 (12-67) months. Thirty-two patients (80%) were followed for 24 months or longer, 24 patients (60%) for 36 months or longer and 10 patients (25%) for 48 months or longer. Two patients had died.

The median age of the cohort at the time of surgery was 77 years and of these, 24 were female and 21 out of 40 had surgery to the right eye. The median (range) duration of symptom was 7 (2 to 32) weeks. Thirteen had predominantly CNV lesion and half had submacular haemorrhage. There was a trend for shorter duration of symptom and larger predominantly haemorrhagic lesions referred for surgery in recent years (see **Table 5.1**). Half of the patients had predominantly haemorrhagic lesion. An overall reduction in the number of cases referred for translocation during 2007 and 2008 coincided with the years during which anti-VEGF agents became available.



**Table 5.1 Macular translocation: demographic data**

	<b>2003-2004</b>	<b>2005</b>	<b>2006</b>	<b>2007-2008</b>	<b>Entire cohort</b>
Number of patients	10 (3, 7)	12	10	8 (5, 3)	40
Median age	72.0	77.5	81.5	78.0	76.5
M:F	2:8	6:6	4:6	4:4	16:24
R:L	4:6	7:5	5:5	5:3	21:19
Median (range)	8.5	9.0	7.2	3.3	7.0
symptom duration in weeks	(4 – 32)	(5 – 16)	(2 – 10)	(2 – 6)	(2 -32)
Lesion features†					
RPE rip	1	2	2	2	7
Blood	3	5	6	6	20
CNV	6	5	2	0	13
Median (range)	7	10	9	20	10
lesion size (DA)	(4 – 40)	(2 – 37)	(3 – 41)	(9 – 49)	(2 – 49)
Previous Rx for CNV	1 had prior PDT x 1	None	None	None	None
Median VA (logMAR)	0.89	0.70	0.80	1.14	0.80
% with VA of 1.0 logMAR or better	60%	92%	90%	50%	75%

CNV, choroidal neovascularisation; DA, disc area; F, female; L, left; logMAR, logarithms of minimum angle of resolution; M, male; PDT, photodynamic therapy; R, right; RPE, retinal pigment epithelium; Rx, treatment.

† Predominant lesion (lesions with angiographic evidence of tear of the RPE are categorized under RPE rip regardless of CNV or blood components).

#### 5.4.1.2 Surgical outcomes

Translocation was combined with phacoemulsification and intraocular lens (IOL) implant in 36 patients. Intra-operative coughing and chorioretinal adhesion at the macula precluded translocation of the macula in 1 and 2 patients, respectively. In the remaining 37 patients, the fovea was rotated superiorly with the exception of 1 patient who had an inferior rotation of the fovea. The median (range) estimated angle of rotation was 50° (45-80°). Among these 37 patients, 2 patients did not have excision of CNV and subsequently received PDT. Of the other 35, 2 had residual active CNV (increasing haemorrhage and subretinal fluid) detected within first 2 months. One of these was left to fibrose due to poor visual potential and the other was treated with PDT.

Postoperative retinal detachment occurred under oil in 6 patients (15%) and 4 of these had reattachment surgery prior to counter-rotation. The remaining 2 underwent counter-rotation without removal of oil. The median (range) angle of cyclotorsion, as measured with double Maddox rod, was 35° (12-80°) prior to counter-rotation. Combined removal of oil with counter-rotation was performed in 35 of 37 patients who had foveal rotation (see above). Of these 35, 2 (6%) had subsequent retinal detachments which were repaired and 4 had further vitreous washout for residual oil (3 patients) or vitreous haemorrhage (1 patient). Of the remaining 2 who did not have oil removed at the time of counter-rotation, 1 developed total retinal detachment following counter-rotation and the other had further repair which was successful after subsequent removal of oil. Overall, a total of 8 (20%) patients in this cohort developed retinal detachment, all within the first 6 months. One patient still had oil in situ at the last follow-up. Dense ERM causing macular pucker developed in 9 patients (23%). Among these, 3 had prior postoperative retinal detachments, 2 went on to develop total retinal detachments and 2 underwent ERM peel without improvement in VA.

Following the initial counter-rotation procedure (37 patients), the median angle of torsion was 7.5° of under-correction (ranging from 10° of over correction to 45° of under correction). A total of 4 patients had significant diplopia requiring revision of counter-rotation surgery and 1 other patient required botulinum toxin injections of the contralateral extraocular muscles. One patient developed pan-uveitis at 10 months with culture-negative vitreous biopsy. Post-operative complications following translocation are summarised in **Table 5.2**.

**Table 5.2 Macular translocation: surgical outcomes**

<b>Surgical outcome (number of patients)</b>	<b>2003-2004 (N = 10)</b>	<b>2005 (N = 12)</b>	<b>2006 (N = 10)</b>	<b>2007-2008 (N = 8)</b>	<b>Entire cohort (%)</b>
Macula translocated	8	12	9	8	37 (93%)
Residual CNV	6	0	1	0	7 (18%)
Retinal detachment	3	0	2	3	8 (20%)
Dense ERM (onset, month)	5 (at < 12 m)	1 (at < 12 m)	1 (at < 12 m)	2 (at < 12 m)	9 (23%)
Median residual Torsion (number of patient needed additional CRS)	5° under-corrected (2)	10° under-corrected (2)	10° under-corrected (0)	3° under-corrected (0)	7.5° under-corrected (4, 10%)
Recurrent CNV (onset, month)	2 (at 6 and 21 m)	3 (at 5, 11 and 19 m)	2 (at 10 and 23 m)	2 (at 5 and 8 m)	9 (23%)
Isolated clinical CMO (onset, month)	0	4 (at 3, 3, 8 and 13 m)	1 (at 8 m)	0	5 (13%)
Full-thickness macular hole (onset, month)	1 (at 25 m)	1 (at 13 m)	0	0	2 (5%)

CMO, cystoid macular oedema; CNV, choroidal neovascularisation; ERM, epiretinal membrane; CRS, counter-rotation surgery, m; months.

### 5.4.1.3 Long-term functional outcomes

#### **Visual acuity**

The median (IQR) VA (logMAR) at baseline, 1 year and the final visits (n = 40) were 0.80 or 6/38 (0.60 to 1.23), 0.70 or 6/30 (0.50 to 1.16) and 0.78 or 6/36 (0.50 to 1.58), respectively. There was no significant change in VA from pre-operative to the final visit (Wilcoxon signed ranks test,  $p = 0.71$ ). The number of patients with a VA of 0.70 logMAR (6/30) or better was 14 (35%) at baseline. This increased to 21 (52%) at 1 year and 17 (43%) at the final visit. Similarly, 30 (75%), 29 (72%) and 27 (68%) of eyes had a VA of 1.00 logMAR (6/60) or better at baseline, 1 year and the final visit (see **Table 5.3**).

VA improved by a mean (SD) of 0.06 (0.64) logMAR at 1 year and then declined by a mean (SD) of 0.05 (0.63) logMAR at the final visit. At 1 year, 12 (30%) gained 3 or more lines of VA and 7 (18%) lost 3 or more lines of VA. At the final visit, 10 (25%) gained 3 or more lines of VA and 13 (33%) lost 3 or more lines of VA (see **Table 5.4**).

Separate analyses were performed in each of the 4 subgroups within the translocation cohort separately over the various time points (see **Figure 5.1**). There was no significant change in postoperative VA from the pre-operative visit in any of the cohort except for the 1 year outcome within the earliest cohort (2003-2004) which had an overall improvement in VA (mean of 0.35 logMAR or 3.5 lines). This was not maintained at 2, 3 and 4 years (see **Figure 5.1**).

A subset of the cohort, the first 32 cases (2003-2006), was further examined. Their median (IQR) VA (logMAR) at baseline, 1 and 2 years were 0.80 (0.60 to 1.00), 0.70 (0.50 to 1.00) and 0.78 (0.44 to 1.10), respectively. There was no significant change between the baseline and the 2 year BCVA (Wilcoxon signed rank test,  $p = 0.530$ ). Among the 32 patients, 24 (75%) achieved a BCVA of 6/60 or better at 1 year. At the last observation (mean of 43 months), 6 of these (25%) had 2-line decline in BCVA after achieving 6/60 at 12 months. The causes of delayed visual loss in these eyes were recurrent CNV (3 patients), CNV complicated by macular hole (1 patient), isolated CMO complicated by macular hole (1 patient) and macular pucker (1 patient).

**Table 5.3 Macular translocation: frequency distribution of visual acuity**

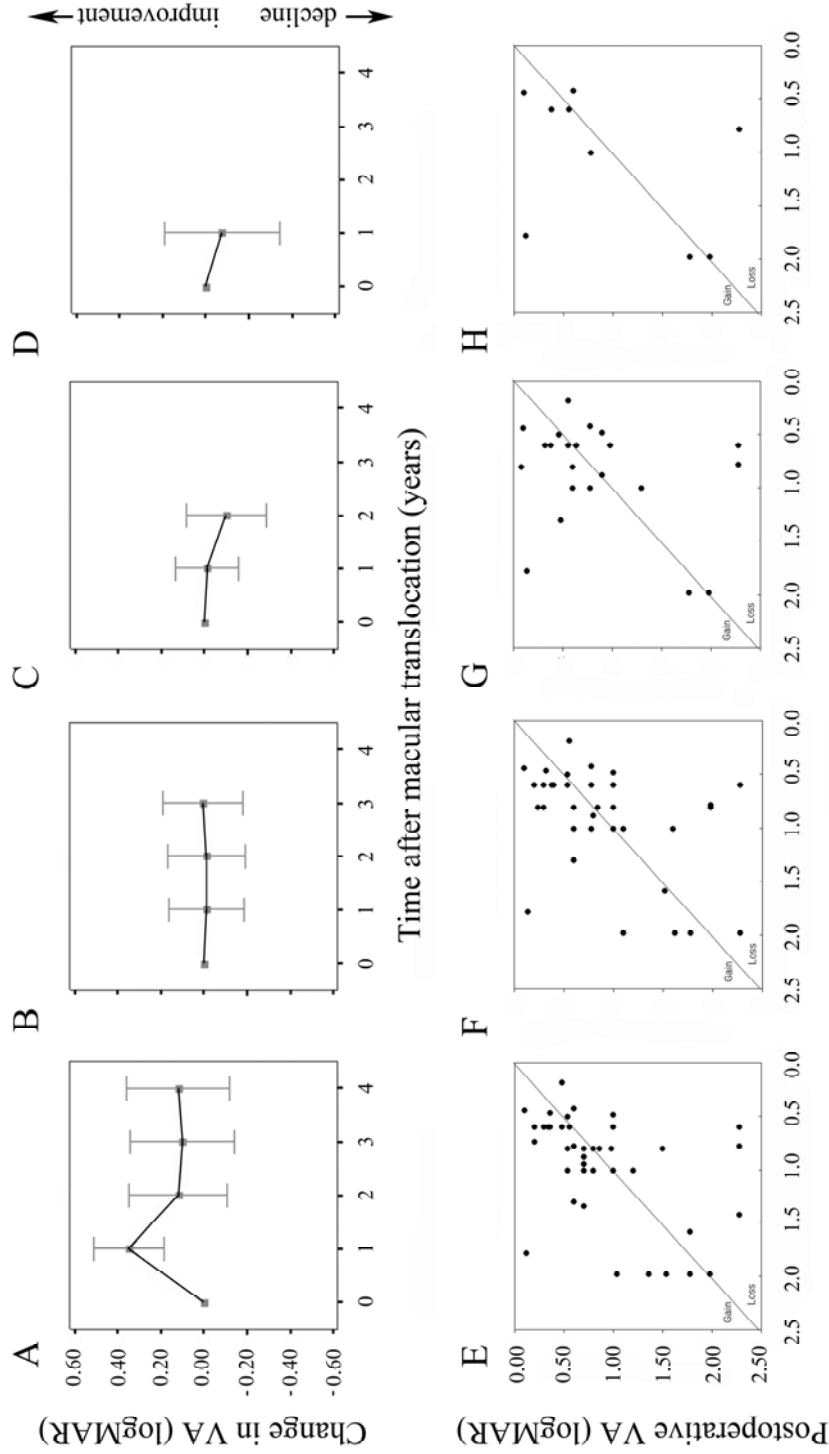
Visual Acuity	At Baseline	At 1 Year	At Final Visit
<b>Visual Acuity (logMAR)</b>			
Mean (95% CI)	0.96 (0.80 to 1.12)	0.90 (0.70 to 1.09)	1.01 (0.79 to 1.23)
Median (min, max)	0.80 (0.18 to 2.28)	0.70 (0.10 to 2.28)	0.78 (0.12 to 2.28)
<b>No. of Patient (%)</b>			
6/12 or better	1 (2%)	5 (12%)	6 (15%)
6/30 or better, worse than 6/12	13 (33%)	16 (40%)	11 (28%)
6/60 or better, worse than 6/30	16 (40%)	8 (20%)	10 (25%)
Worse than 6/60	10 (25%)	11 (28%)	13 (32%)

CI, confidence interval; max, maximum; min, minimum.

**Table 5.4 Macular translocation: frequency distribution of change in acuity**

Visual Acuity	Baseline to 1 year	1 year to Final	Baseline to Final
<b>Visual Acuity Change (logMAR)</b>			
Mean (95% CI)	0.06 (-0.12 to 0.25)	-0.11 (-0.20 to -0.02)	-0.05 (-0.25 to 0.15)
Median (min, max)	0.14 (-1.68 to 1.66)	-0.02 (-1.18 to 0.58)	-0.01 (-1.68 to 1.60)
<b>No. of Patient (%)</b>			
≥ 6-line improvement	5 (12.5%)	0 (0%)	5 (12.5%)
≥ 3-line to < 6-line improvement	7 (17.5%)	1 (2.5%)	5 (12.5%)
≥ 1-line to < 3-line improvement	11 (27.5%)	5 (12.5%)	7 (17.5%)
< 1-line change	6 (15%)	19 (47.5%)	6 (15%)
≥ 1-line to < 3-line deterioration	4 (10%)	5 (12.5%)	4 (10%)
≥ 3-line to < 6-line deterioration	3 (7.5%)	8 (20%)	8 (20%)
≥ 6-line deterioration	4 (10%)	2 (5%)	5 (12.5%)

CI, confidence interval; max, maximum; min, minimum.



### **Microperimetry**

From the subset of 21 patients who were followed for 3 or more years, 4 maintained a VA of 6/12 or better. Of these, 2 had a microperimetry test within the first year and a similar test grid used for follow-up examination at 35 or 41 months. Two other patients had their first microperimetry tests performed at 20 and 28 months and follow-up microperimetry at 48 and 47 months respectively. For comparison, the change in microperimetry 3 patients who developed recurrent CNV was also examined.

Of the 4 patients who maintained a VA of 6/12 or better, 2 had decline in retinal sensitivity in the inferior paracentral macular region which correlated with expansion of atrophy from previous CNV excision site. Of the 3 patients with recurrent CNV, 1 had stable VA with inferior paracentral retinal sensitivity decline, 1 had decline in VA with superior paracentral retinal sensitivity decline, and 1 had decline in VA and retinal sensitivity in all regions. A summary of results is shown in **Table 5.4** and **Figure 5.2**.

**Table 5.4 Macular translocation: microperimetry outcomes**

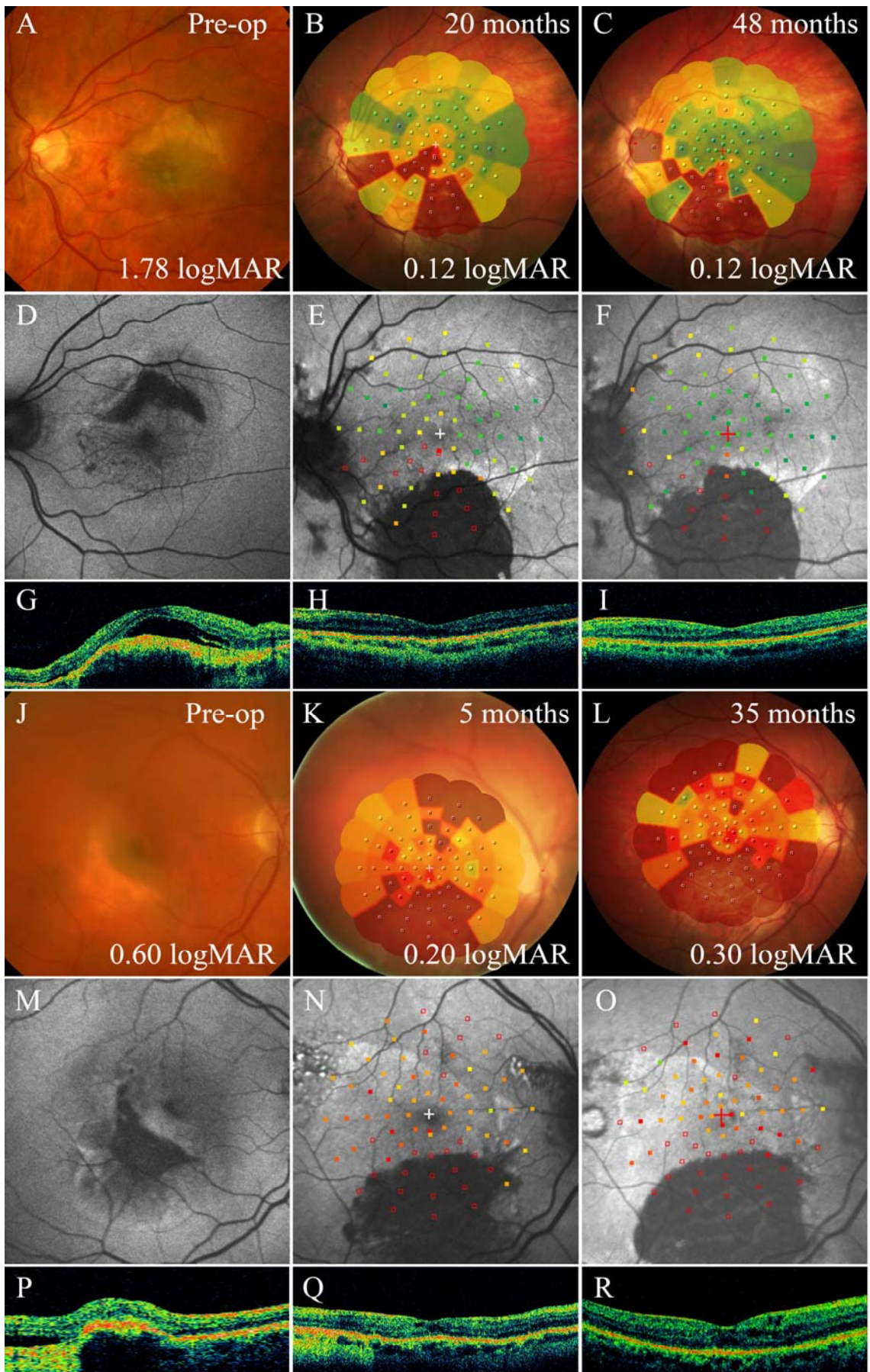
Patient ID	Patient age and Lesion type	First MP				Final MP				Postoperative complications	Time points for the 2 MP tests (months)
		VA (logMAR)	MRS (dB)	CMS (dB)	PMS (dB)	sPMS (dB)	iPMS (dB)	VA (logMAR)	MRS (dB)		
3†	74, CNV	0.10	14.5	14.0, 14.7	15.2, 13.7	0.30	14.8	14.7, 14.8	16.3, 12.5	Mac-on RD	28, 47
9†	69, CNV/Rip	0.12	10.2	10.2, 10.2	13.2, 5.8	0.12	11.1	13.3, 10.0	12.1, 7.0	None	20, 48
10	71, CNV	0.20	8.3	10.9, 7.0	9.8, 4.2	<b>0.56*</b>	<b>4.0*</b>	<b>3.8*, 4.2*</b>	6.3, 1.8	CNV and FMH	1.5, 38
15	74, Hem	0.52	5.1	0.8, 7.3	12.4, 2.3	<b>0.90*</b>	<b>2.7*</b>	<b>0.5, 3.9*</b>	6.0, 1.6	CNV	5, 38
17	61, CNV	0.74	9.8	8.2, 10.6	10.7, 10.0	0.46	8.7	7.8, 9.1	12.2, 5.4	CNV	3, 36
18†	61, Hem	0.30	14.1	13.2, 14.6	14.5, 14.2	0.12	13.6	15.0, 12.9	13.8, 11.2	CME and rCRS	4, 41
21†	76, CNV/Rip	0.20	3.1	3.4, 2.9	3.9, 1.2	0.30	2.9	3.6, 2.5	4.3, 0.3	None	5, 35

CNV, choroidal neovascularisation; CME, cystoid macular edema; CMS, central macular sensitivity; dB, decibel; Hem, hemorrhagic lesions; iPMS, inferior paracentral macular sensitivity; logMAR, logarithm of minimum angle of resolution; Mac on RD, macular on retinal detachment; MP, microperimetry; PMS, paracentral macular sensitivity; rCRS, revision counter-rotation surgery; RS, retinal sensitivity; sPMS, superior paracentral macular sensitivity; VA, visual acuity.

† Patients with visual acuity of 20/40 or better for 3 or more years.

\* Sensitivity decline exceeding test-retest variability (Chen et al. 2009).





Attenuation scale (dB)



□ Not seen at ... dB

■ Seen at ... dB

△ Not projected

### **Figure 5.2 Macular translocation: serial microperimetry**

Serial microperimetry, autofluorescence images and optical coherence tomography (OCT) scans in patients 9 (A-I) and 21 (J-R) showing long-term rescue of retinal function. (A, D, G) Patient 9 presented with a retinal pigment epithelium (RPE) rip with subretinal fluid and visual acuity (VA) of 1/60. (B, E, H) At 20 months after translocation, VA was approximately 6/9, mean central macular sensitivity was 10.2 dB with dense scotoma inferior to the fovea at the site of RPE defect, foveal autofluorescence was intact, well-defined hyper-autofluorescence was present in the macular region and small intraretinal cysts were noted at the level of inner nuclear layer. (C) At 4 years VA remained at around 6/9 and central macular sensitivity increased by 3.1 dB to 13.3 dB. (F, I) Autofluorescence imaging showed a slight enlargement of the RPE defect from CNV excision but no change to the hyper-autofluorescent region in the macula and intraretinal cysts in the inner nuclear layer. (J, M, O) Patient 21 presented also presented with an RPE rip with subretinal fluid and visual acuity (VA) of 6/24. (K) At 5 months after translocation, VA was 6/9 and the mean central macular sensitivity was only 3.4 dB with a dense scotoma superior and inferior to the fovea. (N) The scotoma was seen over RPE defect inferiorly but not superior to fovea. (N) Autofluorescence image showed foveal hypo-autofluorescence, no autofluorescence at the CNV excision site and well-defined hyper-autofluorescence in the macula. (Q) OCT scan showed a small intraretinal cyst at the level of inner nuclear layer. (C) At around 3 years, VA was 6/12 and central macular sensitivity remaining at 3.6 dB. (O) Autofluorescence image showed slight enlargement of the RPE defect from CNV excision but no change to the size of hyper-autofluorescent region in the macula. (R) OCT scan showed persistence of intraretinal cysts in the nuclear and ganglion cell layers.

#### 5.4.1.4 Long-term structural outcomes

##### **Choroidal neovascularisation**

Recurrent CNV developed in 9 patients; 6 during the first year and 3 during the second year (see **Table 5.6**, **Figures 5.3 and 5.4**). No recurrent CNV was seen after 2 years in the 23 patients who were followed for 3 to 5 years. All CNV recurred at the edge of the previous CNV excision site within the macular region except for 1 patient who had *de novo* CNV (unrelated to the excision site) nasal to the fovea. From the onset of CNV, these patients were followed for 7 to 43 (mean of 26) months. Recurrent CNV was treated in all but one eye using either PDT, anti-VEGF agent, intravitreal triamcinolone or a combination of these measures (see **Table 5.6**). The mean VA (logMAR) at baseline and the last observation for these 9 patients were 0.59 (Snellen: 6/24) and 0.73 (Snellen: 6/33), respectively. Structural outcome after anti-VEGF therapy varied from total resolution of the oedema and subretinal fluid to persistent intraretinal cystic change, exudates and haemorrhage despite repeated anti-VEGF agent injections (see **Figure 5.3 and 5.4**).

##### **Cystoid macular oedema**

CMO was observed in 38 patients at some stage post-operatively on angiography, SD-OCT or both. Twenty-one of these were associated with other lesions such as macular pucker (7 patients), residual CNV (3 patients), recurrent CNV (9 patients, see **Figure 5.5**), pan-uveitis (1 patient) or residual subretinal perfluorocarbon liquid (1 patient). The remaining 17 had isolated CMO with varying degrees of severity and duration (see **Figure 5.6**). Twelve of these were only detected on angiography or SD-OCT. These subclinical CMO may resolve within a few months or persist for over 4 years. The remaining 5 patients had clinical cystoid changes. The mean VA (logMAR) at baseline and the last observations for these patients were 0.72 (Snellen: 6/30) and 0.60 (Snellen: 6/24), respectively.

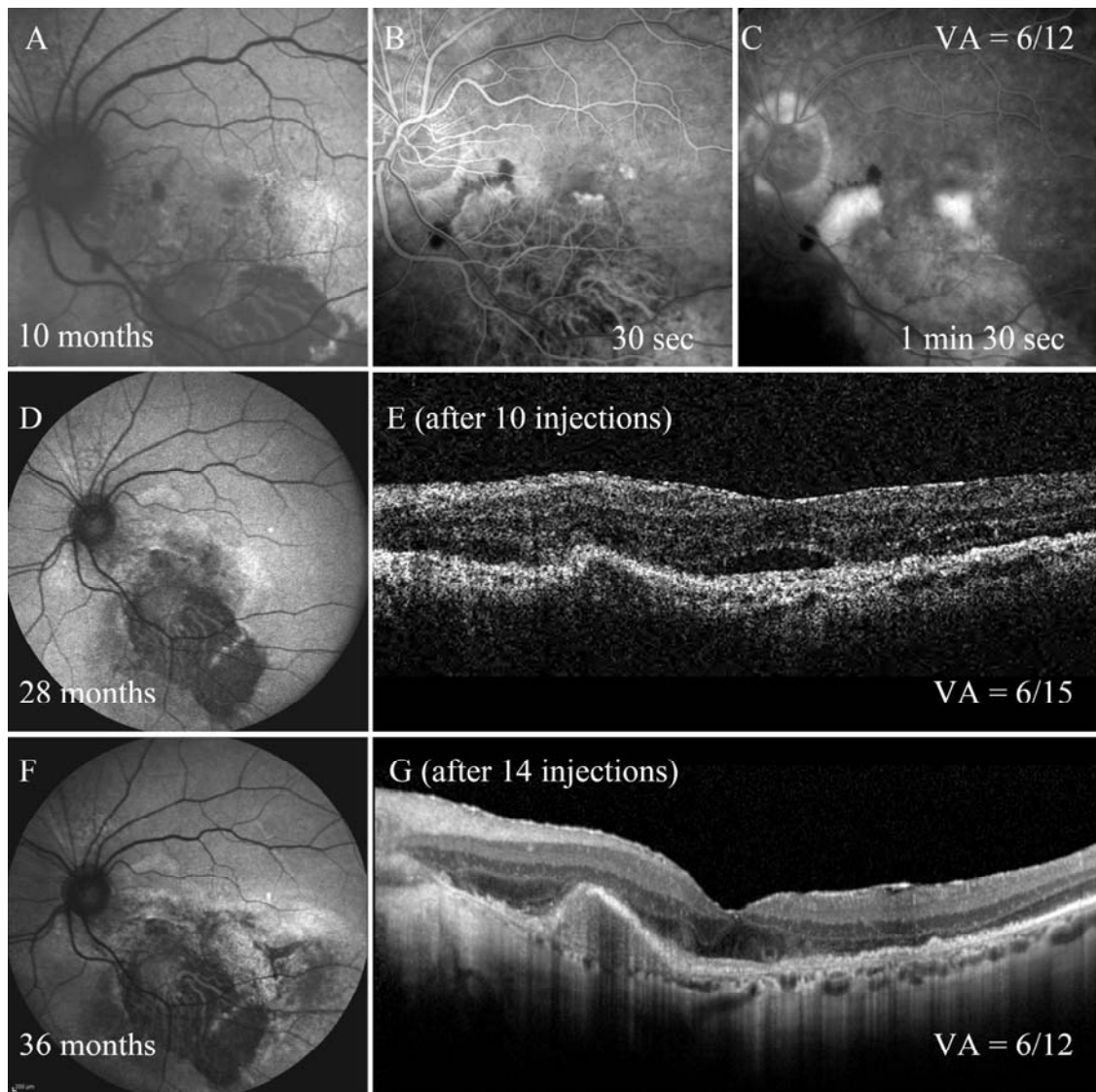
Of the 5 patients with clinical cystoid change in the macula, 1 had spontaneous partial resolution which led to improvement of VA (logMAR) from 0.8 (at 1 year) to 0.0 (after 2 years, patient 18), 1 was treated with topical steroid and non-steroidal anti-inflammatory drops but went on to develop a full-thickness macular hole, and 3 patients received 2 or more intravitreal injections of triamcinolone with temporary resolution of oedema and transient improvement in VA (median: 0.48 and 0.56 logMAR at 1 and 2 years respectively, see **Figure 5.6**).

Follow-up SD-OCT scans at 2 or more years were available in 18 patients. In those with clinical CMO within first 2 years, follow-up SD-OCT demonstrated large intraretinal cysts for up to 36 months. Follow-up SD-OCT in patients with subclinical CMO also demonstrated persistence of the small intraretinal cysts for 36 to 60 months (see **Figures 5.2**).

**Table 5.6 Macular translocation: treatment of recurrent CNV**

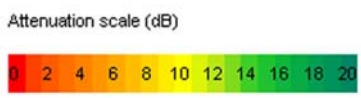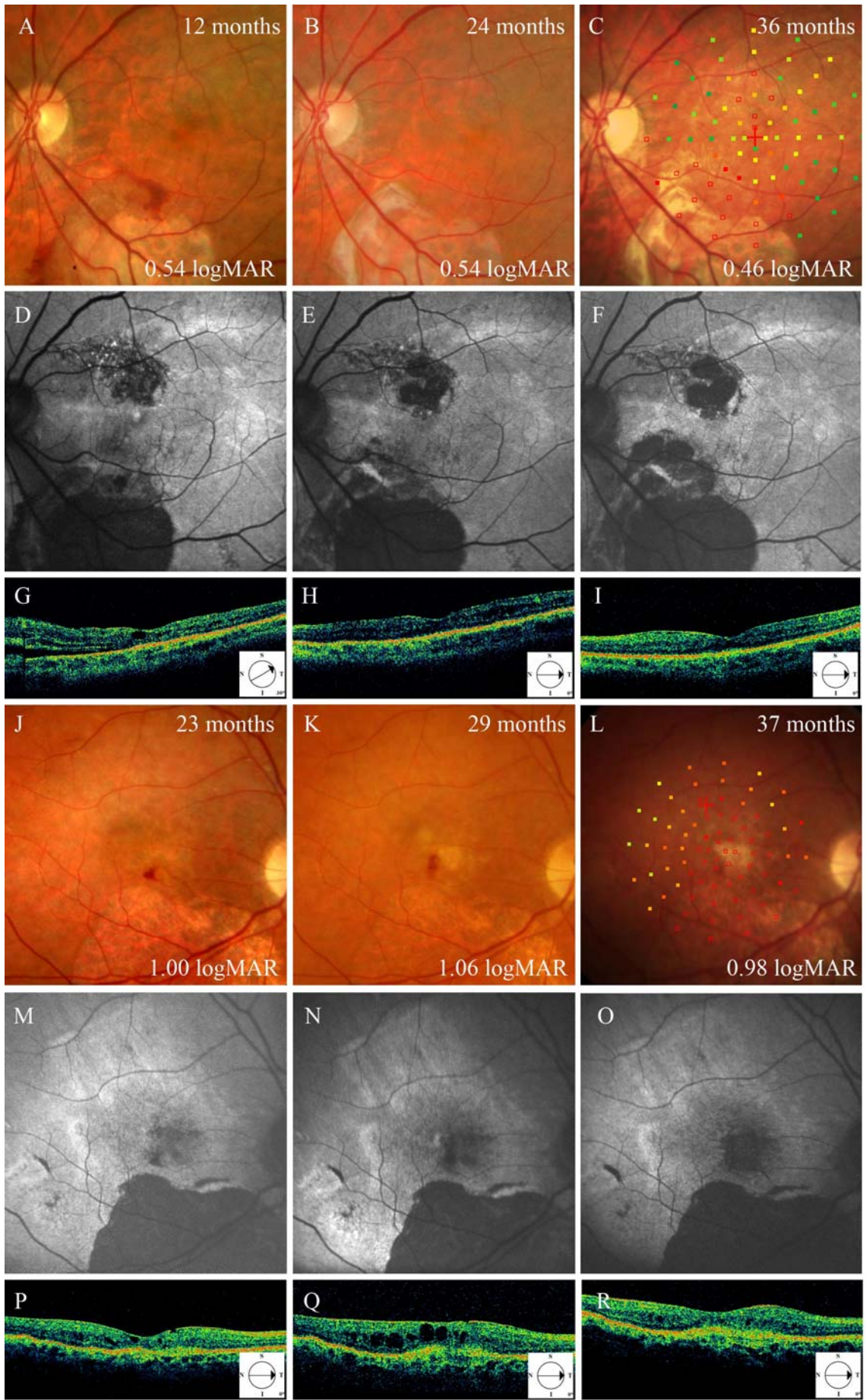
<b>Patient No.</b>	<b>Age and Lesion type</b>	<b>VA at recurrence (Time of onset)</b>	<b>Site of CNV</b>	<b>PDT (start time point)</b>	<b>Anti-VEGF (start time point)</b>	<b>Other treatment (start time point)</b>	<b>Final VA (logMAR, follow-up in months)</b>
7	84, CNV	1.02 (6 m)	Excision	X 4 (6 m)	3x R (24 m)	No	0.78 (32 m)
10	71, CNV	0.20 (21 m)	Excision	No	No	MH repair (30 m)	0.56 (49 m)
13	88, Haem	0.60 (18 m)	Excision	No	3x B (20 m)	No	0.78 (48 m)
15	74, Haem	0.52 (5 m)	Excision	X 3 (6 m)	4x B (16 m)	3x IVTA (29 m)	1.00 (48 m)
17	61, CNV	0.60 (11 m)	Excision	No	3x B (14 m)	No	0.46 (43 m)
24	76, CNV	1.00 (23 m)	De novo, juxtafoveal	No	4x R (32 m)	No	1.00 (41 m)
28	81, Haem	0.30 (10 m)	Excision	No	3x B (10 m) & 12x R (17 m)	No	0.30 (38 m)
34	70, Haem	0.30 (5 m)	Excision	No	8x R (16 m)	No	0.70 (28 m)
38	72, Haem	0.78 (8 m)	Excision	No	2x R (14m)	No	1.00 (15 m)

B; bevacizumab, CNV; predominantly choroidal neovascularisation, Haem; predominantly haemorrhagic lesion, IVTA; intravitreal triamcinolone acetonide, m; month(s), MH; macular hole, PDT; photodynamic therapy, R; ranibizumab.



**Figure 5.3 Macular translocation: structural outcome of recurrent CNV**

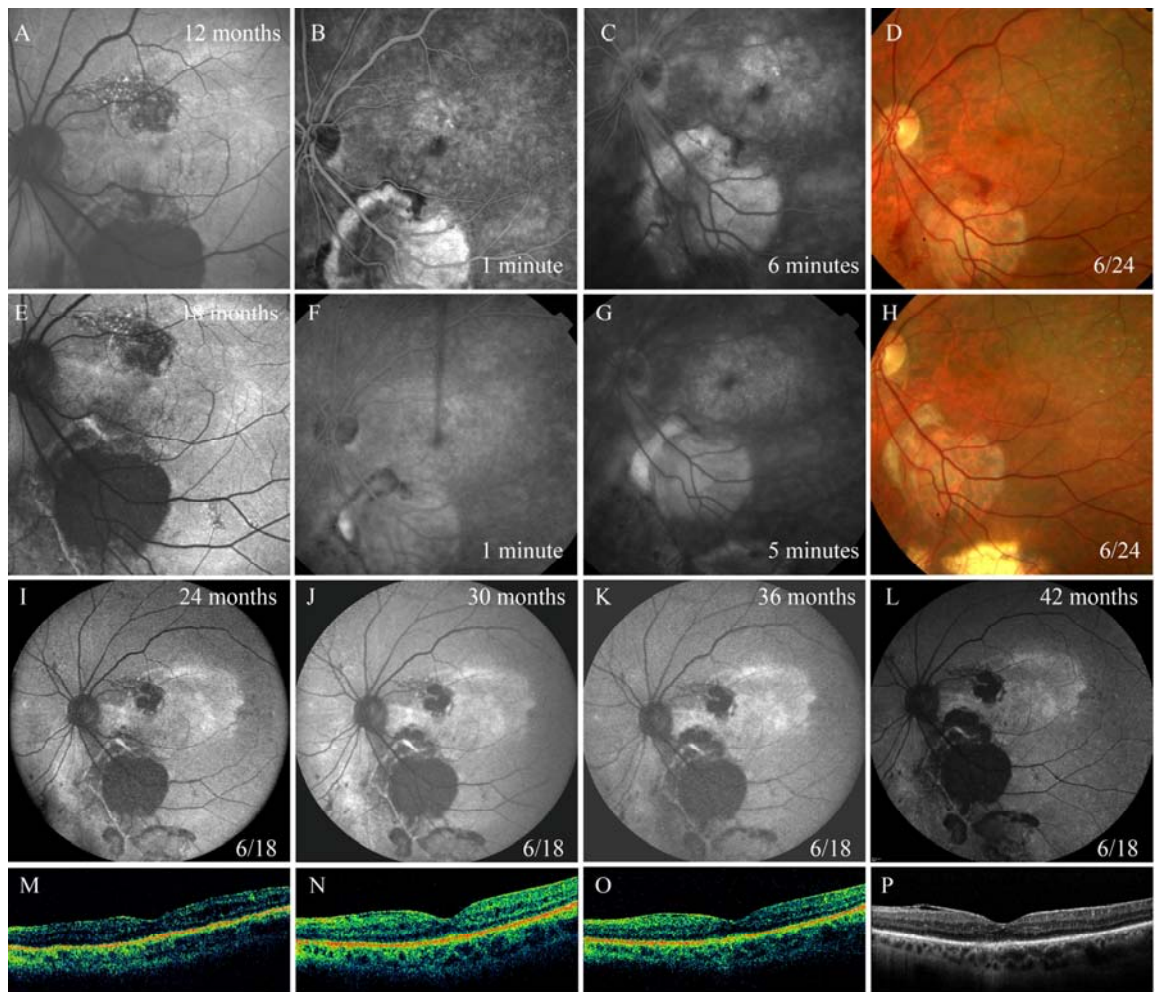
Patient 28 had juxtafoveal and extrafoveal recurrent choroidal neovascularisations (CNV) at 10 months post-translocation. He received 3 intravitreal injections of bevacizumab followed by 12 injections of ranibizumab to maintain a visual acuity of 6/12. (A) Fundus autofluorescence image and (B, C) fluorescein angiography showed recurrence of CNV at 10 months. (D) Fundus autofluorescence image and (E) optical coherence tomography (OCT) scan at 28 months showed expansion of RPE atrophy at the site of recurrence and persistent subfoveal fluid. (F) Fundus autofluorescence image and (G) OCT scan at 36 months showed continued expansion of RPE atrophy at new sites of CNV recurrence and resolution of subfoveal fluid.



- Not seen at ... dB
- Seen at ... dB
- △ Not projected

**Figure 5.4 Macular translocation: functional outcome of recurrent CNV**

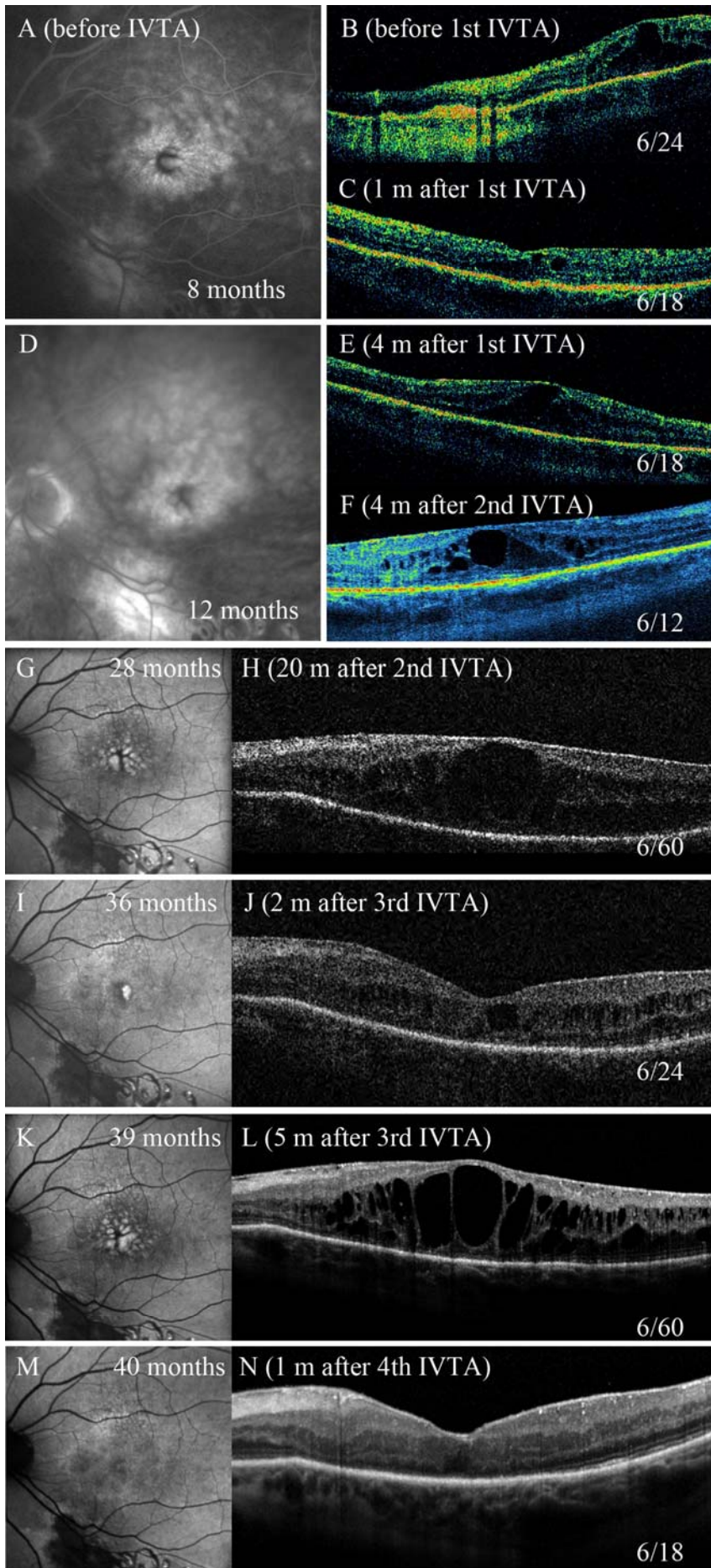
Microperimetry, autofluorescence images and optical coherence tomography (OCT) scans in patients 17 (A-I) and 24 (J-R) showing the effect of recurrent choroidal neovascularisation (CNV) on retinal structure and function. (A, B, C) Colour fundus photographs of patient 17 at around 1, 2 and 3 years showed new CNV at the superonasal edge of previous CNV excision site with haemorrhage which resolved into a disciform scar after 3 injections of bevacizumab during the second year. (C) Microperimetry showed dense scotoma over the area of CNV recurrence. (D, E, F) Serial autofluorescence images showed a single small round hyper-autofluorescence at the fovea corresponding to cystoid change on OCT. There was also well-defined hyper-autofluorescent region in the macula and increasing size of the RPE defect superior to the fovea which has progressed inferiorly to involve the centre of fovea. (G, H and I) Serial OCT scans showed resolution of intraretinal cyst after treatment. (J, K, L) Colour fundus photographs of patient 24 at around 2, 2.5 and 3 years showed development of retinal haemorrhage and recurrent juxtafoveal CNV which regressed to a disciform scar after 3 injections of bevacizumab during the third year. (M, N, O) Serial autofluorescence images showed increasing size of the hypo-autofluorescent lesion nasal to the fovea, persisting well-defined hyper-autofluorescent region in the macula. Note that the recurrent CNV was separated from the RPE defect at the site of old CNV. (G, H and I) Serial OCT scans showed development of intraretinal cyst which partially resolved after treatment.



**Figure 5.5 Macular translocation: CMO associated with recurrent CNV**

Patient 18 had extrafoveal recurrent choroidal neovascularisation (CNV) at 12 months post-translocation associated with cystoid macular oedema. (A) Fundus autofluorescence, (B, C) fluorescein angiography and (D) colour fundus photograph showed new haemorrhage and leak at the supra-nasal border of the excision site and cystoid macular oedema. Six months later (E) fundus autofluorescence, (F, G) fluorescein angiography and (H) colour fundus photograph showed a disciform scar and persistence of CMO despite 3 injections of bevacizumab. Small intraretinal cystic change remained and RPE atrophy progressed despite inactive CNV at (I, M) 24, (J, N) 30, (K, O) 36 and (L, P) 42 months. His visual acuity was maintained at 6/18 for over 3 years.





### **Figure 5.6 Macular translocation: isolated CMO responding to IVTA**

Patient 23 had persistent cystoid macular oedema (CMO) from 8 months and received a total of 4 intravitreal injections of triamcinolone to maintain a visual acuity of 6/18 at 40 months after translocation. (A) Late phase angiography and (B) optical coherence tomography (OCT) showed CMO at 8 months. After the first injection, (C) cystoid changes had partially resolved. However, (D, E) intraretinal cysts re-accumulated at 4 months after steroid injection. Again, by (F) 4 and (G, H) 20 months, CMO had re-established after the second injection. Fundus autofluorescence and OCT imaging showed increase in retinal thickening, intraretinal cystic change and focal hyper-autofluorescence at (I, J) 2 and (K, L) 5 months after the third injection and (M, N) rapid anatomical and acuity response to steroid within 1 month of the fourth injection.

### **Fundus autofluorescence features**

Fundus AF images from 5 of the 40 patients were excluded from further analysis because the macula was not translocated due to technical issues (3 patients) or post-operative total retinal detachment which precluded fundus AF imaging (2 patients). From the remaining 35 patients, a total of 133 fundus AF images were reviewed. Each patient had an average (range) of 4 (1-8) post-operative AF images. These fundus AF images were taken between a mean of 13 and 36 months post-operatively; the earliest was at 2 months and the latest was at 67 months.

Broadly, there were 2 types of changes: (1) decreased fundus AF due RPE atrophy or masking by ERM, and (2) increased fundus AF due to RPE lipofuscin accumulation or unmasking through reduction of macular or visual pigments.

### **Decreased AF and expansion of pigment epithelial atrophy**

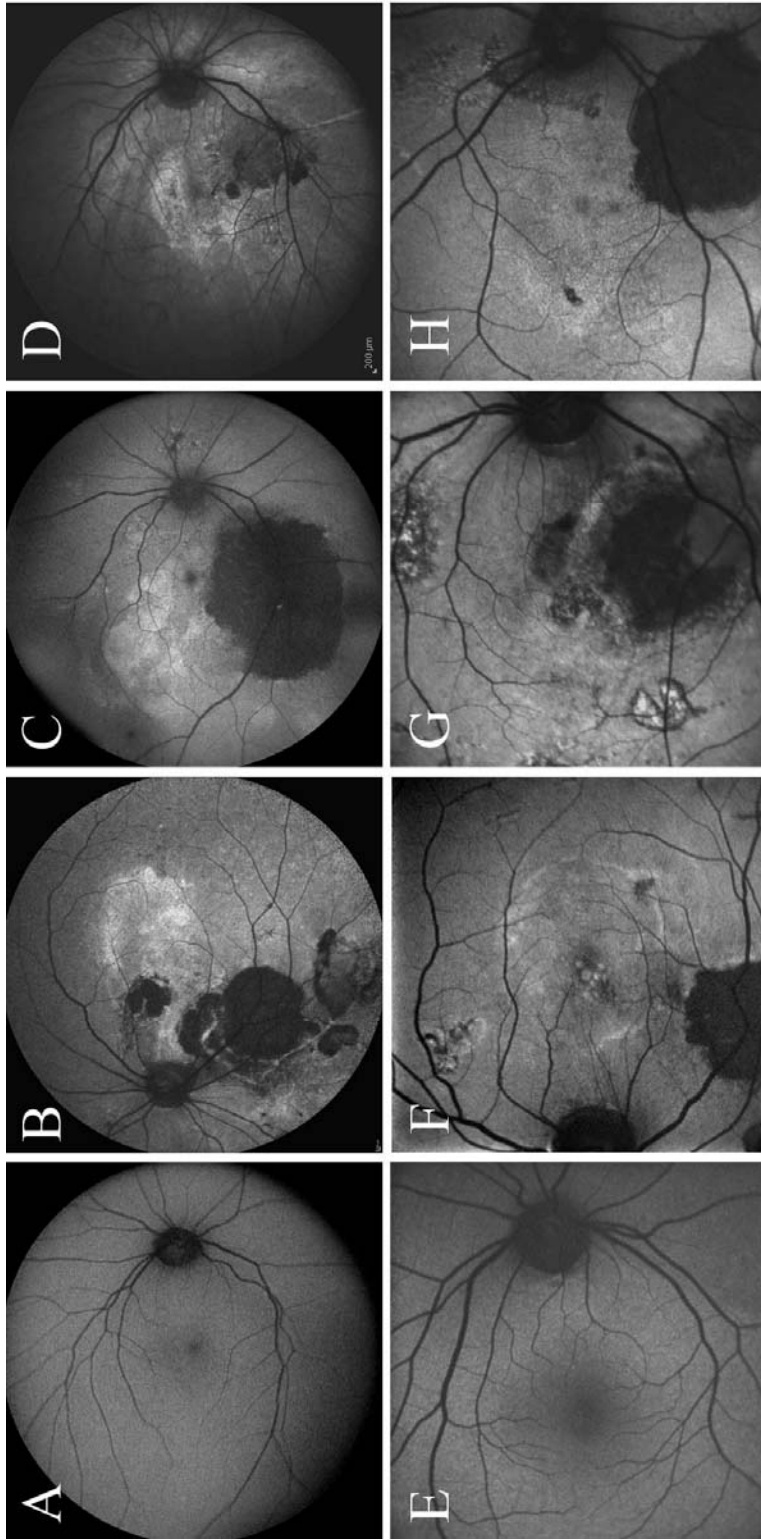
Among the 35 patients with gradable AF images, 2 patients had extensive RPE atrophy. In these 2 patients, there was no typical increased AF at the rim of the extensive atrophy as seen in geographic atrophy. Foveal AF was reduced due to masking by dense ERM (3 patients), expansion of parafoveal RPE defect (3 patients) and isolated small foveal RPE defect (3 patients). Subsequently, in some of the remaining 24 patients, reduced foveal AF developed as a result of subfoveal expansion of recurrent CNV or parafoveal RPE defect (5 patients), or development of de novo subfoveal CNV or RPE atrophy (3 patients). Development of postoperative subfoveal RPE atrophy, in association with recurrent CNV or expansion of parafoveal atrophy led to a decline in the median VA (logMAR) from 0.83 (Snellen: 6/40) at 1 year to 1.07 (Snellen: 6/70) at the last observation. However, expansion of RPE atrophy without CNV was not a primary cause of delayed loss of VA.

### **Increased AF and shortening of outer segment**

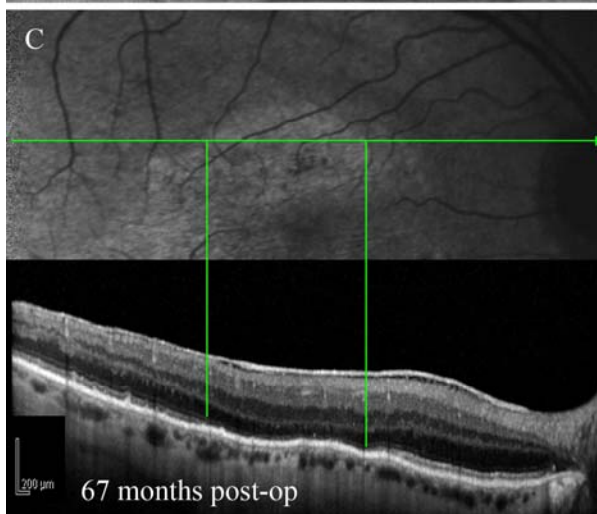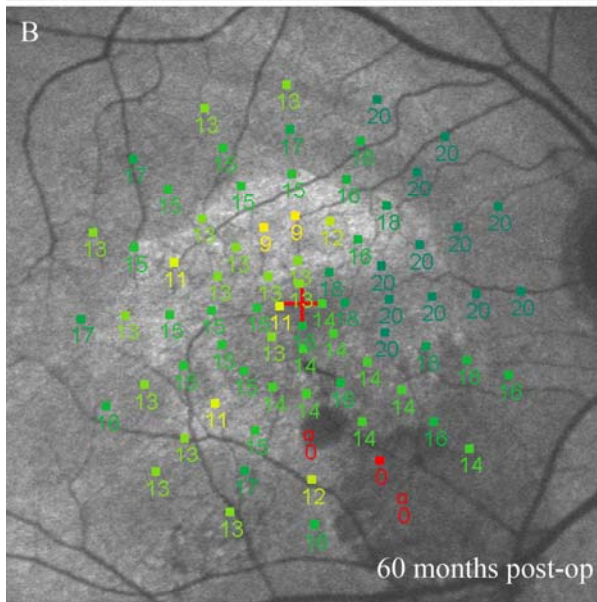
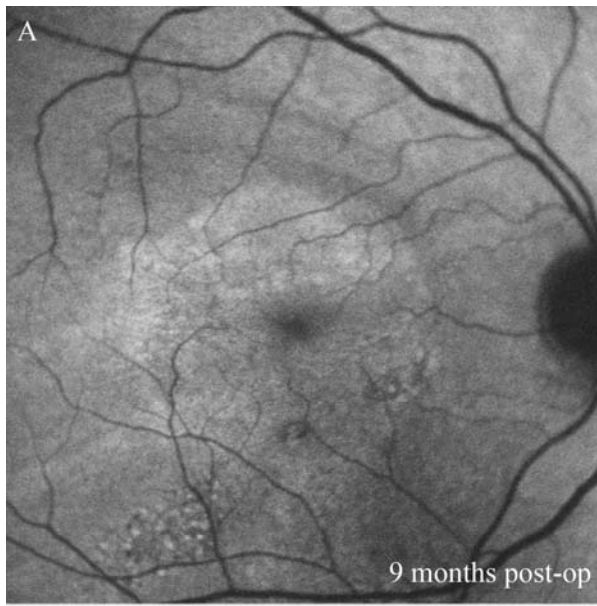
Fundus AF demonstrated increased AF in parafoveal regions in 33 patients. Increased AF change was also noted in parafoveal regions in the 33 patients without extensive RPE atrophy (see **Figure 5.7**). These could be categorized into 3 patterns of change: well-delineated homogenous increased AF patches (17 patients, see **Figure 5.8**), curvilinear increased AF bands (4 patients, see **Figure 5.9**) and poorly demarcated speckled increased AF (12 patients) which can be an isolated macular change or associated with cystoid macular oedema and recurrent CNV. The location and distribution of increased AF did not change at 2 to 5 years of follow-up.

Among the 21 haemorrhagic lesions, 7 patients had the homogenous increased AF regions, 1 had curvilinear increased AF band, 1 had extensive atrophy, 9 had speckled AF pattern and 3 were excluded because of total retinal detachment or unsuccessful translocation. Among the 19 CNV or RPE rips, 10 had homogenous increased AF regions, 3 had curvilinear increased AF band, 1 had extensive atrophy, 3 had speckled AF pattern and 2 were excluded because of unsuccessful translocation. Chi square test showed that the difference in the distribution of the various patterns of AF was not statistically significant between the groups of patients with haemorrhagic and the CNV/rip subtypes ( $p = 0.20$ ).

Simultaneous fundus AF with SD-OCT was available for review in 20 patients. Both homogenous patches and curvilinear bands of increased AF co-registered with varying degrees of loss of the outer retinal architecture on SD-OCT. They all shared a common feature: loss of the line which corresponds to the so called “interface of the inner and outer segment of the photoreceptor cell layer” (IPRL) with or without (1) absence of the external limiting membrane and (2) reduction of outer nuclear layer thickness (see **Figure 5.10**). Speckled increased AF lesions co-registered with variable features including small intraretinal cystic change at the level of outer nuclear layer, loss of IPRL or even intact outer retinal structures.

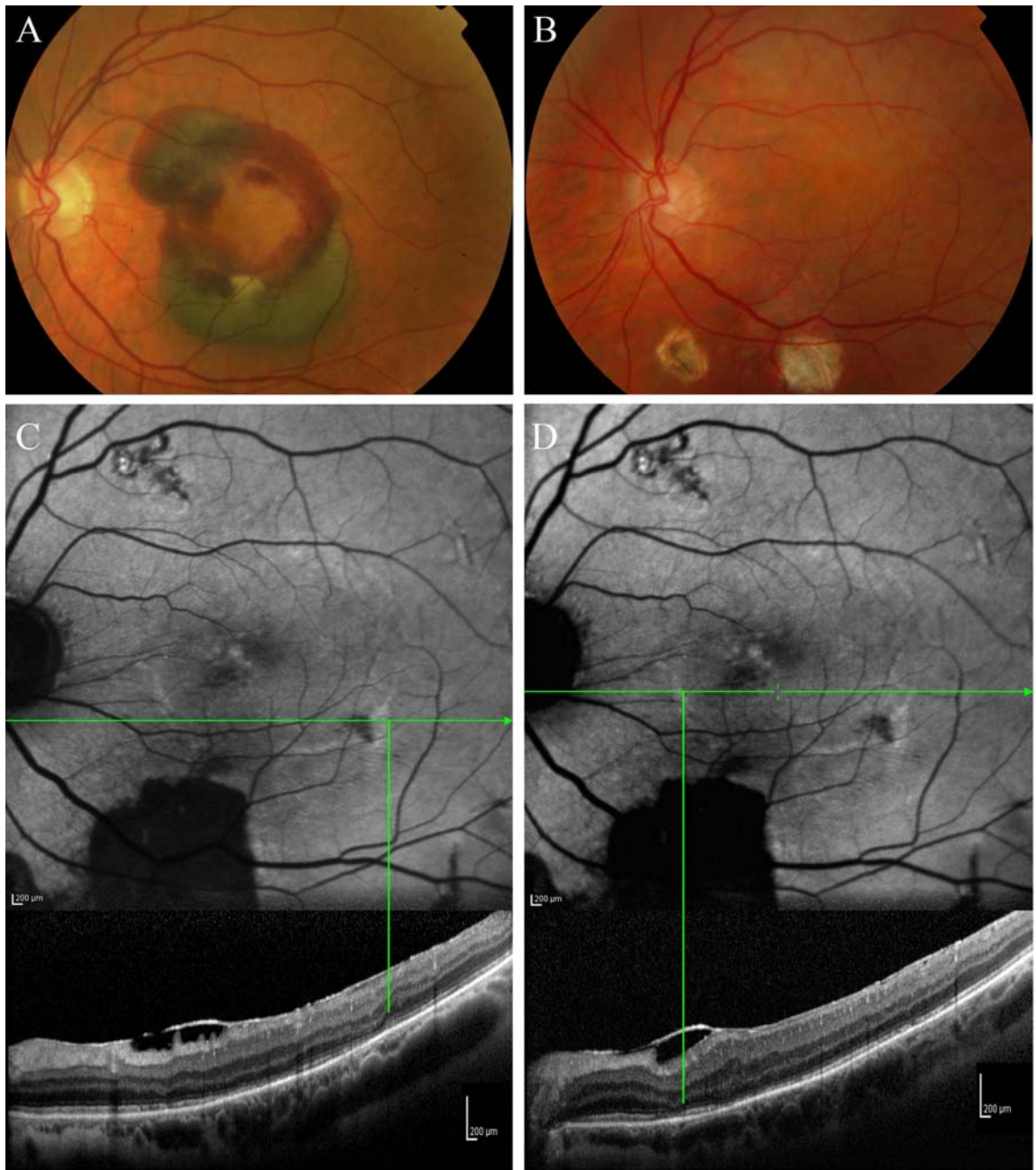


**Figure 5.7 Macular translocation: abnormal patterns of increased fundus AF.** (A, E) Normal macular and perimacular patterns of autofluorescence (AF) for comparison with abnormal patterns of AF seen in post-translocation eyes. (B, C and D) Well-delineated region or patch of increased AF in the parafoveal region. (F) Curvilinear bands of increased AF in the parafoveal region. (G, H) Speckled increased AF in the parafoveal region.

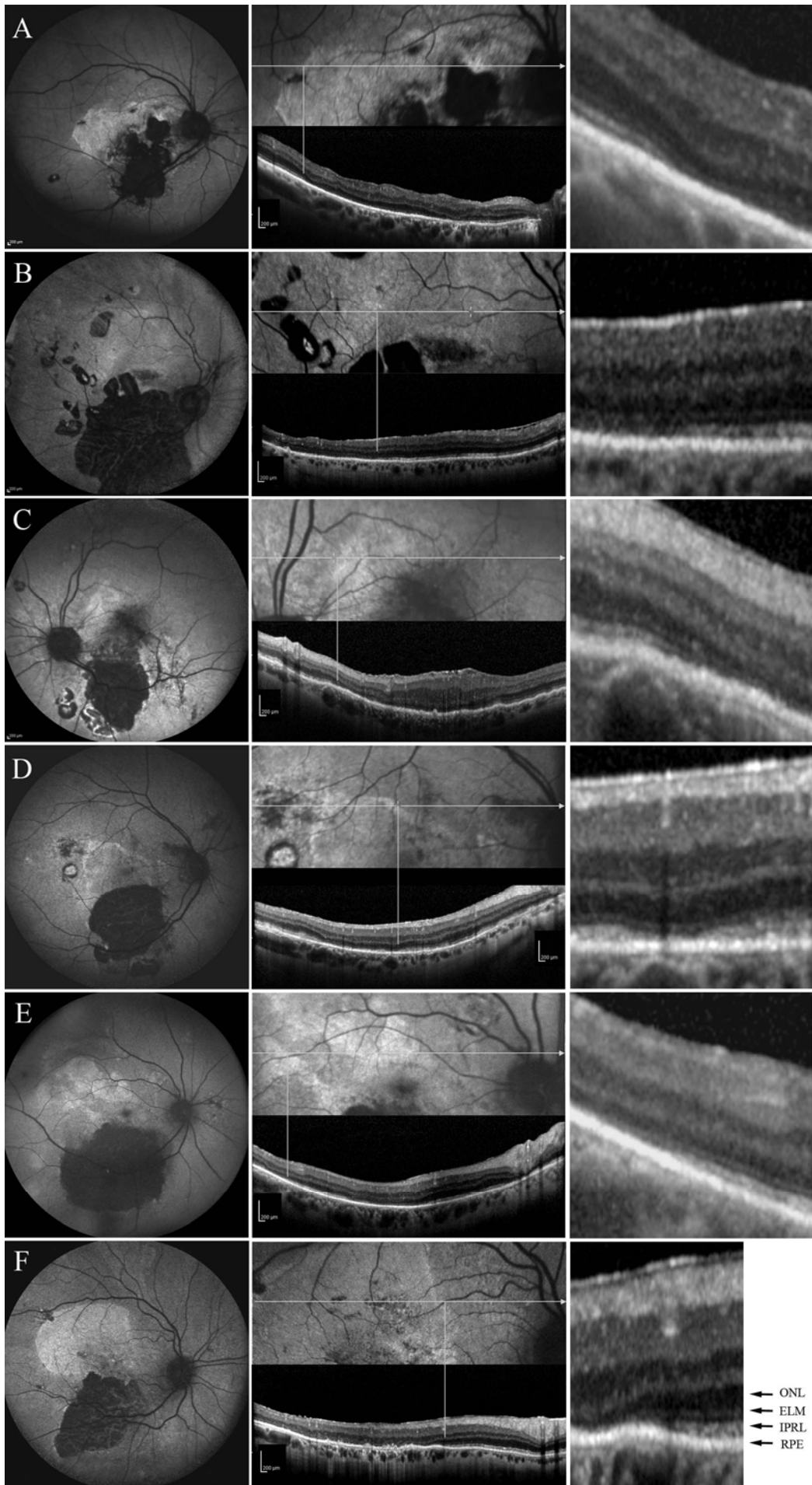


**Figure 5.8 Macular translocation: well-delineiated region of increased fundus AF**

(A) Well-delineiated increased AF at 9 months post-translocation. (B) This did not change even at 5 years and microperimetry showed subnormal retinal sensitivity in the region of increased AF. (C) Simultaneous fundus AF and SD-OCT showed loss of the bright line corresponding to the interface of inner and outer segments of the photoreceptor cell layer. Note that the external limiting membrane in the region of increased AF is closer to the RPE.



**Figure 5.9 Macular translocation: curvilinear band of increased fundus AF**  
 (A) Submacular haemorrhage complicating age-related macular degeneration. (B) Same patient after macular translocation showed no obvious fundus features in the parafoveal region. (C and D) At 4 years post-translocation, bands of increased autofluorescence (AF) correlated with loss of the line corresponding to the interface of inner and outer segments of the photoreceptor cell layer. The epiretinal membrane seen on optical coherence tomography (OCT) was not clinically visible and is unlikely to have masked autofluorescence signal from the retinal pigment epithelium.



### **Figure 5.10 Macular translocation: OCT in regions of increased fundus AF**

Six examples from 6 patients showing co-registration between isolated loss of the interface of inner and outer segments of the photoreceptor cell layer (IPRL) in the optical coherence tomography (OCT) section and region of increased AF supporting the hypothesis that increased AF relates to the loss of visual pigment located in the outer retina. (A) The (IPRL) dips into the RPE as the fundus AF increased. (B) The IPRL re-appears as the fundus AF returned to normal intensity. (C) The IPRL dips into RPE at the junction of increased AF. (D) Band of increased AF corresponded to region of IPRL fusing with the RPE layer. (E) The IPRL re-appears as the fundus AF returned to normal intensity. (F) The IPRL and outer nuclear layer re-appears as the fundus AF returned to normal. The normal architecture of outer retina on spectral domain OCT consists of the following layers: outer nuclear layer (ONL), external limiting membrane (ELM), interface of inner and outer segments of the photoreceptor cell layer (IPRL) and retinal pigment epithelium (RPE).

## **5.4.2 Autologous RPE patch graft long-term outcomes**

### 5.4.2.1 Patient characteristics

A total of 12 consecutive patients underwent autologous RPE-choroid patch grafts during a 1 year period from between 2004 and 2005. The mean (range) follow-up duration was 44 (26-61) months. All patients (100%) were followed for 24 months or longer, 11 (92%) patients for 36 months or longer, and 5 patient (42%) for 48 months or longer. Two patients had died.

The median age at the time of surgery was 78 years and of these, 4 were female and half had surgery to the right eye. The median (range) duration of symptoms was 5 (2 to 6) weeks. Eight had predominantly CNV lesion, 2 had submacular haemorrhage and 2 had mature or fibrosed CNV.

### 5.4.2.1 Surgical outcomes

Patch graft was performed in 11 phakic eyes. Nine of 12 patients had CNV removed in 1 piece, 11 of 12 had insertion of graft in 1 move, 3 of 12 had no submacular manipulation and 5 of 12 had 2 or more manipulations of the graft and none had significant submacular choroidal haemorrhage. One patient had intraoperative giant retinal tear. Combined phacoemulsification (11 of 12), removal of oil and IOL implant was performed at a median of 17 weeks after patch graft. However, in 3 patients, oil was re-injected for repair of retinal detachment and then removed at 6 and 22 months later in 2 of 3 patients, respectively.



Post-operative retinal detachment occurred in 4 patients and they underwent a total of 6 retinal detachment repairs. One other patient had inferotemporal u-tear with limited subretinal fluid which was treated with laser retinopexy, No further retinal detachment occurred after 1 year although 1 patient still had oil tamponade. Overall, a total of 5 (42%) patients in this cohort developed retinal detachment, all within the first 6 months.

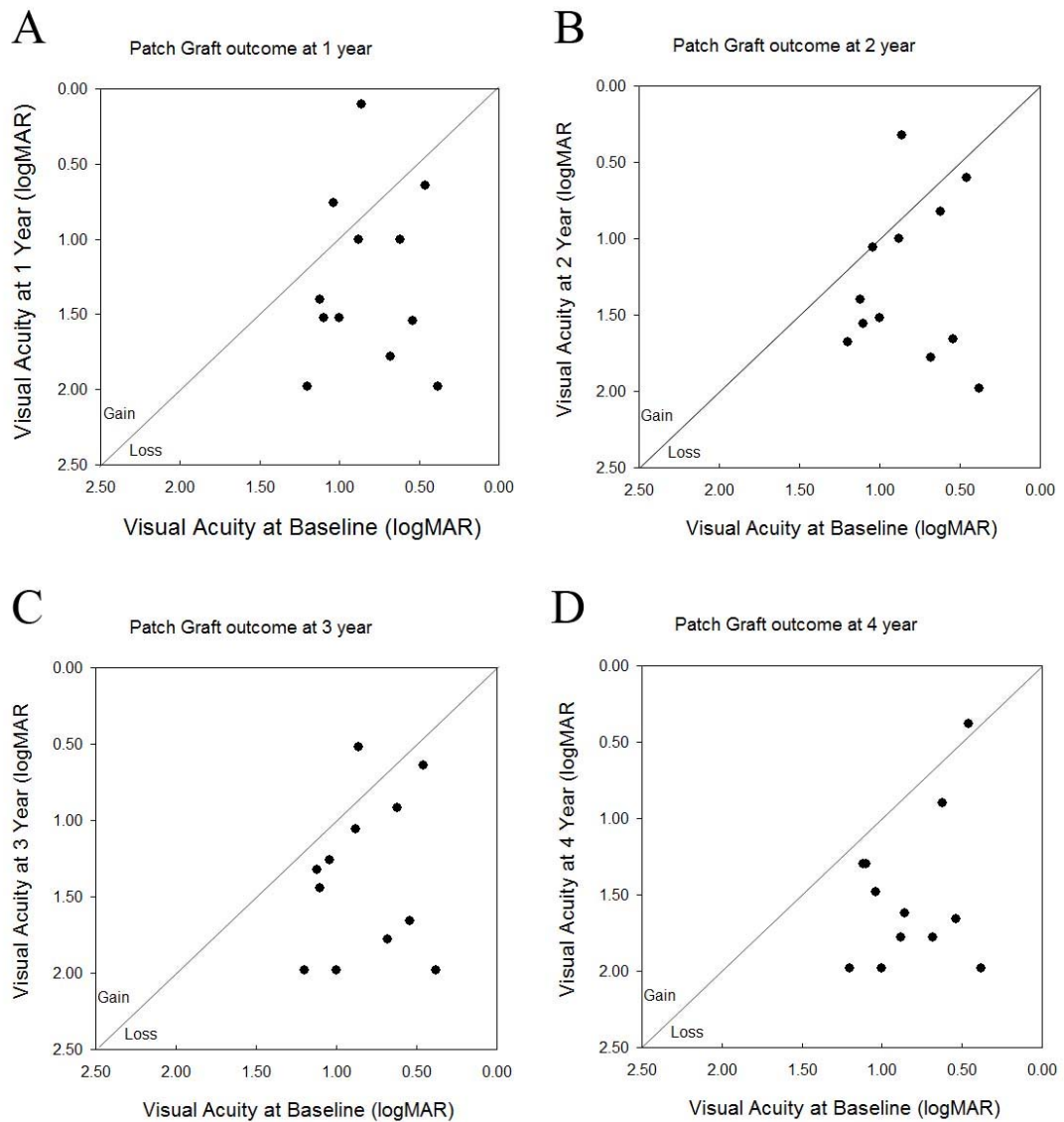
#### 5.4.2.2 Long-term functional outcomes

##### **Visual acuity**

The median (IQR) VA (logMAR) at baseline, 1 year and the final visits (n = 12) were 0.87 or 6/45 (0.56 to 1.09), 1.46 or 2/60 (0.82 to 1.72) and 1.64 or 1/60 (1.30 to 1.93), respectively. There was significant decline in VA from the pre-operative to the final visit (Wilcoxon signed ranks test,  $p = 0.003$ ). The number of patients with a VA of 0.70 logMAR (6/30) or better was 5 (41%) at baseline. This declined to 2 (16%) at 1 year and 1 (8%) at the final visit (McNemar test,  $p = 0.13$ ). Similarly, 8 (67%), 5 (42%) and 2 (17%) of eyes had a VA of 1.00 logMAR (6/60) or better at baseline, 1 year and the final visit, respectively.

VA declined by a mean (SD) 0.45 (0.63) logMAR at 1 year and 0.68 (0.50) logMAR at the final visit. At 1 year, 1 (8%) patient gained 3 or more lines of VA and 7 (59%) lost 3 or more lines of VA. At the final visit, none had gained 3 or more lines of VA and 8 (67%) lost 3 or more lines of VA (see **Figure 5.12**).

Within the cohort of 12 patients, 5 (42%) achieved a VA of 1.00 logMAR or better at 1 year but 3 of these (60%) had a 2 or more lines ( $\geq 0.20$  logMAR) decline in VA after 1 year. The cause of delayed visual loss in these eyes was macular oedema associated with recurrent CNV.



**Figure 5.11 Visual acuity change after patch graft: outcomes at 1 to 4 years**

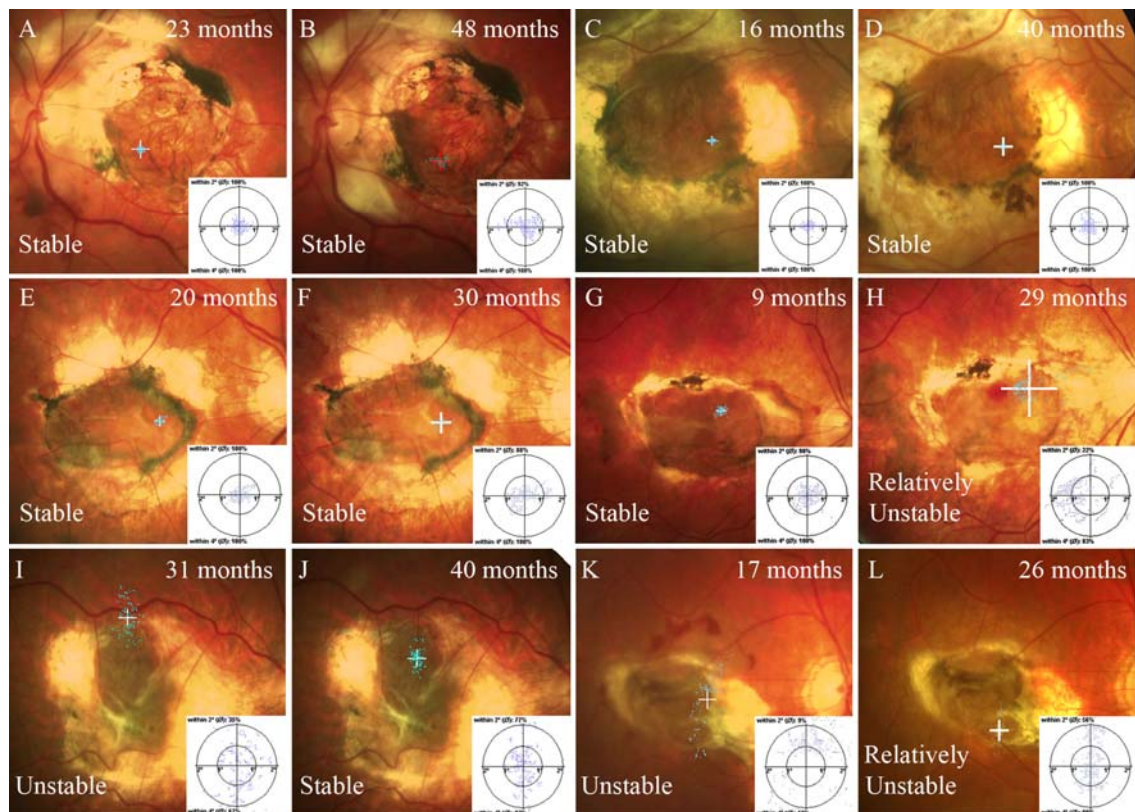
Scatter plots showing relationship between the baseline and the (A) 1, (B) 2, (C) 3 and (D) 4 year visual acuity outcomes following RPE-choroid patch graft. Data loci above the slant solid line represent patients with improvement in visual acuity compared to baseline.

### Microperimetry

Six patients (4, 5, 7, 8, 9 and 11) demonstrated fixation over the graft (see **Figure 5.12**). They had the baseline microperimetry tests at various time points ranging from 9 to 31 months post-operatively. The most recent follow-up microperimetry tests were performed between 26 and 48 months post-operatively. Using a small (1-2°) cross fixation target, it was found that fixation stability declined in 1 patient (from stable to unstable) and improved in another 2 (from unstable to relatively unstable or stable) during follow-up (see **Table 5.7** and **Figure 5.12**). However, mean sensitivity over the graft declined (loss of 0.1 to 8.4 dB) and dense scotoma over the graft enlarged

(increment of 1 to 13 test loci) in all 6 eyes tested (see **Table 5.7, Figures 5.13 and 5.14**).

All 6 patients with fixation over the graft had postoperative complications (see **Table 5.7**). Decline in fixation stability and VA in patients 4 and 8 were associated with the development of atrophic macular cysts or cystoid macular oedema at the locus of fixation (see **Table 5.7, Figures 5.13 and 5.14**).



**Figure 5.12 Patch graft: fixation outcomes**

Fixation stability change in 6 patients whose grafts supported fixation. Inserts show percentage of fixation locus within 2° and 4° of gravitational centre of all fixation loci during a 30 second recording. (A, B) Patient 4 had stable fixation stability despite loss of acuity at 48 months. (C, D) Patient 5 had stable fixation for up to 40 months. (E, F) Patient 7 had stable fixation for up to 30 months despite recurrent CNV supratemporal to the graft. (G, H) Patient 8 had decline in stability due to cystoid macular oedema secondary to recurrent CNV temporal to the graft. (I, J) Patient 9 had improvement in fixation stability at extrafoveal locus on the patch at 40 months. (K, L) Patient 11 had improvement in fixation stability also at extrafoveal locus on the patch at 26 months.

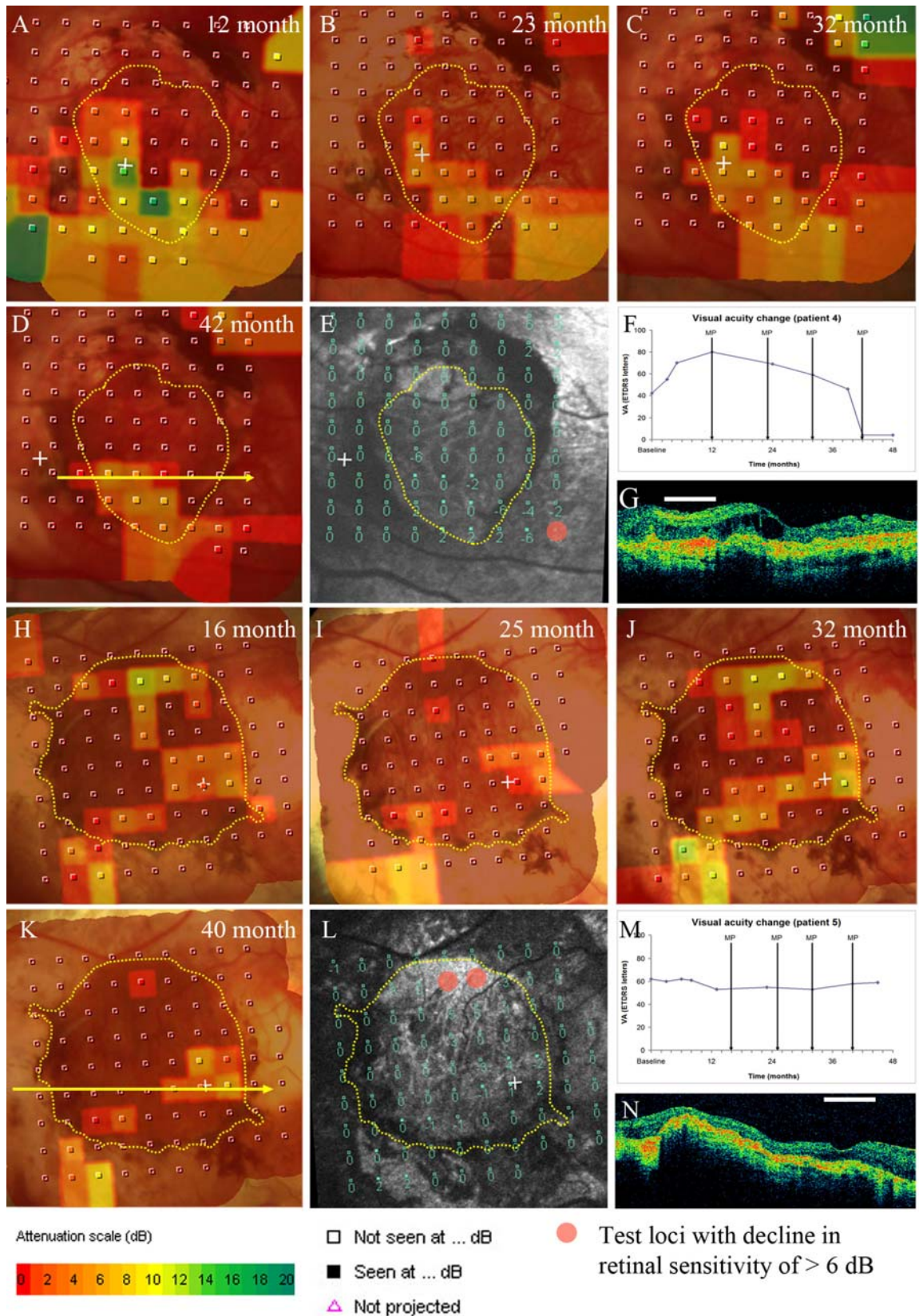
**Table 5.7 Patch graft: microperimetry outcomes**

Patient ID	Number of Test loci over graft <sup>†</sup> , stimulus size *	First MP				Second MP				Early and late postoperative complications	Time points for the 2 MP tests (months)
		VA (logMAR)	Fixation stability	Mean RS <sup>†</sup> (dB)	DSS <sup>†</sup> (bci)	VA (logMAR)	Fixation stability	Mean RS <sup>†</sup> (dB)	DSS <sup>†</sup> (loci)		
4	21, V	0.32	Stable	1.8	12	1.62	Stable	1.2	15	CNV, CMO, AMC	23, 42
5	35, III	0.64	Stable	1.4	20	0.54	Stable	0.6	27	CNV	16, 40
7	19, III	1.00	Stable	0.4	14	1.00	Stable	0.3	18	EGH, CNV, CMO, ERM	20, 30
8	18, V	0.68	Stable	9.2	1	1.22	Relatively unstable	0.8	14	EGH, CNV, CMO, SRF	9, 29
9	19, III	0.82	Unstable	2.4	9	0.92	Stable	1.7	10	RD, ERM, CMO	31, 40
11	13, III	1.54	Unstable	1.5	11	1.56	Relatively unstable	0.6	12	EGH, CNV, ERM, CMO	17, 26

\* Equivalent Goldmann perimetry target size.

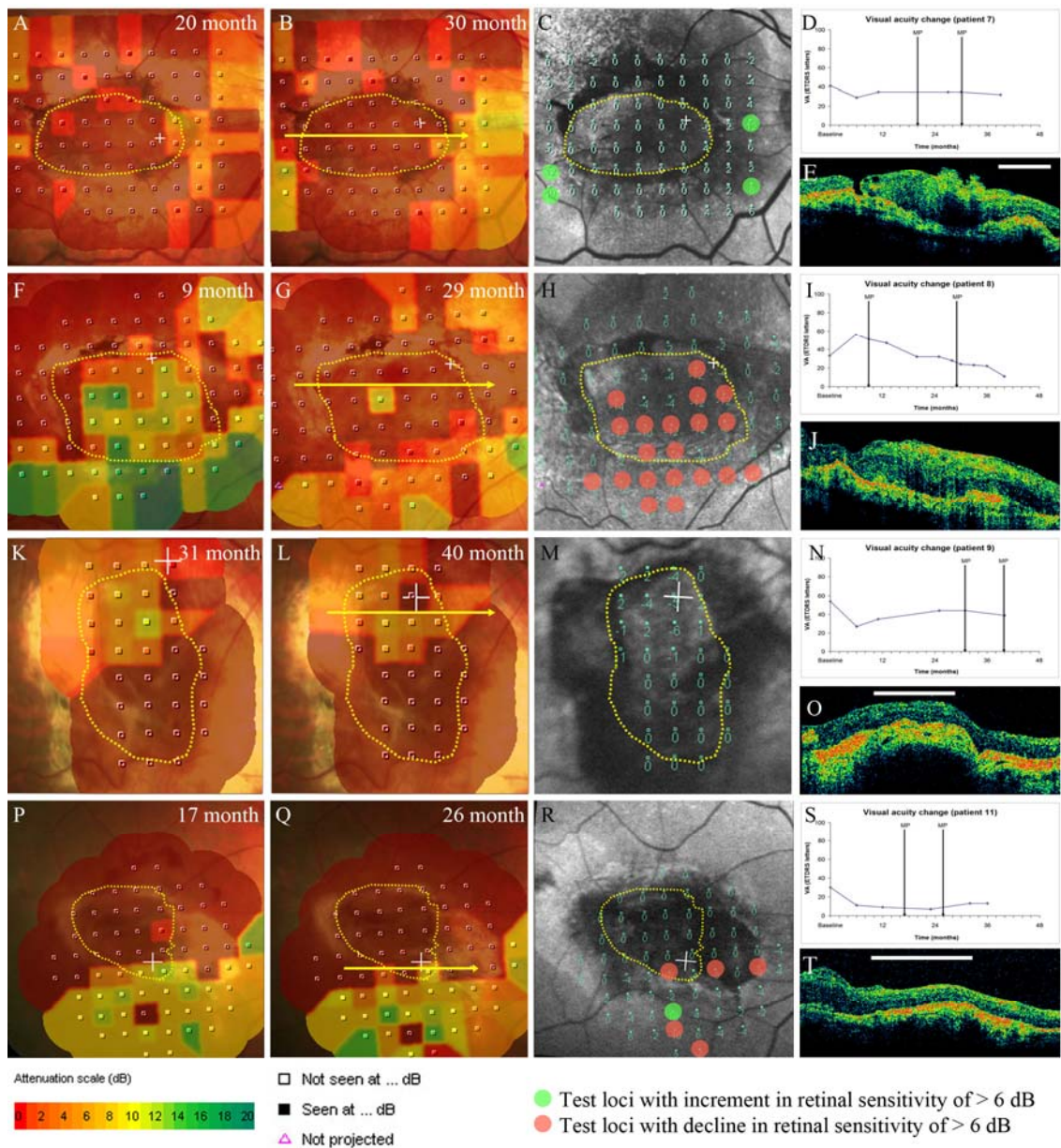
<sup>†</sup>Test loci over the graft were selected for calculation of mean retinal sensitivity and dense scotoma size.

AMC, atrophic macular cysts; CNV, choroidal neovascularisation; CMO, cystoid macular oedema; dB, decibel; DSS, dense scotoma size; EGH, early graft haemorrhage; ERM, epiretinal membrane; logMAR, logarithm of minimum angle of resolution; MP, microperimetry; RD, retinal detachment; RS, retinal sensitivity; SRF, subretinal fluid; VA, visual acuity.



**Figure 5.13 Patch graft: serial microperimetry in patients 4 and 5**

Microperimetry tests are displayed as interpolated maps and differential maps on the autofluorescence image taken around the time of the most recent microperimetry. Borders of the grafts are marked and loci with greater than 6 dB increment (green) or decline (pink) are highlighted on the differential map. (A, B, C and D) In patient 4, the mean retinal sensitivity (Goldmann V size stimulus) over the graft decline from 5.3 dB at 12 months to 1.8, 1.8 and 1.2 dB at 23, 32 and 42 months, respectively. (E) Local retinal sensitivity change between 23 and 42 months overlaid on autofluorescence image. (F) Visual acuity (VA) at corresponding time points over 4 years showed steady decline between 1 and 3 years and rapid decline after 3 years. (G) Optical coherence tomography through fixation loci showed foveal cyst which may explain the rapid decline in VA after 3 years and intact retinal structure in the nasal macula (region marked by white bar) corresponding to regions with retinal sensitivity. (H, I, J and K) In patient 5, the mean retinal sensitivity (Goldmann III size stimulus) over the graft declined from 1.4 dB at 16 months to 0.2 dB then improved to 2.3 dB and again declined to 0.6 dB at 25, 32 and 40 months, respectively. (L) Local retinal sensitivity change between 16 and 40 months overlaid on autofluorescence image. (M) VA change over 3 years at corresponding time points. (N) Optical coherence tomography through fixation locus showed a smooth foveal depression with intact outer retinal structures in the foveal region.



**Figure 5.14 Patch graft: serial microperimetry in patients 7, 8, 9 & 11**

Microperimetry tests are displayed as interpolated maps and differential maps on the autofluorescence image taken around the time of the most recent microperimetry. Borders of the grafts are marked and loci with greater than 6 dB increment (green) or decline (pink) are highlighted on the differential map. (A-E) The graft in patient 7 supported retinal sensitivity (Goldmann III size stimulus) and stable visual acuity (VA) over its nasal region which was associated with presence of autofluorescence signal and outer retinal structures (marked by white bar) in the same region at 20 and 30 months. (F-J) Patient 8 had marked loss of retinal sensitivity (Goldmann V size stimulus) and VA due to cystoid macular oedema between 9 and 29 months. (K-O) Patient 9 had retinal sensitivity (Goldmann III size stimulus) over superior half of the graft associated with homogenous pattern of autofluorescence signal and intact outer retinal structures in the same region at 31 and 40 months. (P-T) Patient 11 had retinal sensitivity (Goldmann III size stimulus) over the inferior pole of the graft and stable but poor VA associated with faint autofluorescence signal and intact outer retinal structures in the same region at 17 and 26 months.

#### 5.4.2.3 Long-term structural outcomes

##### **Recurrent choroidal neovascularisation**

Five patients (42%) had recurrent CNV, extending peripherally from the edge of the graft, occurring between 6 and 28 months postoperatively. Although none of these invaded the patch graft, some were associated retinal thickening with cystoid macular changes over the graft. None of these patients received further treatment for the CNV as they were not threatening fixation.

##### **Cystoid macular oedema**

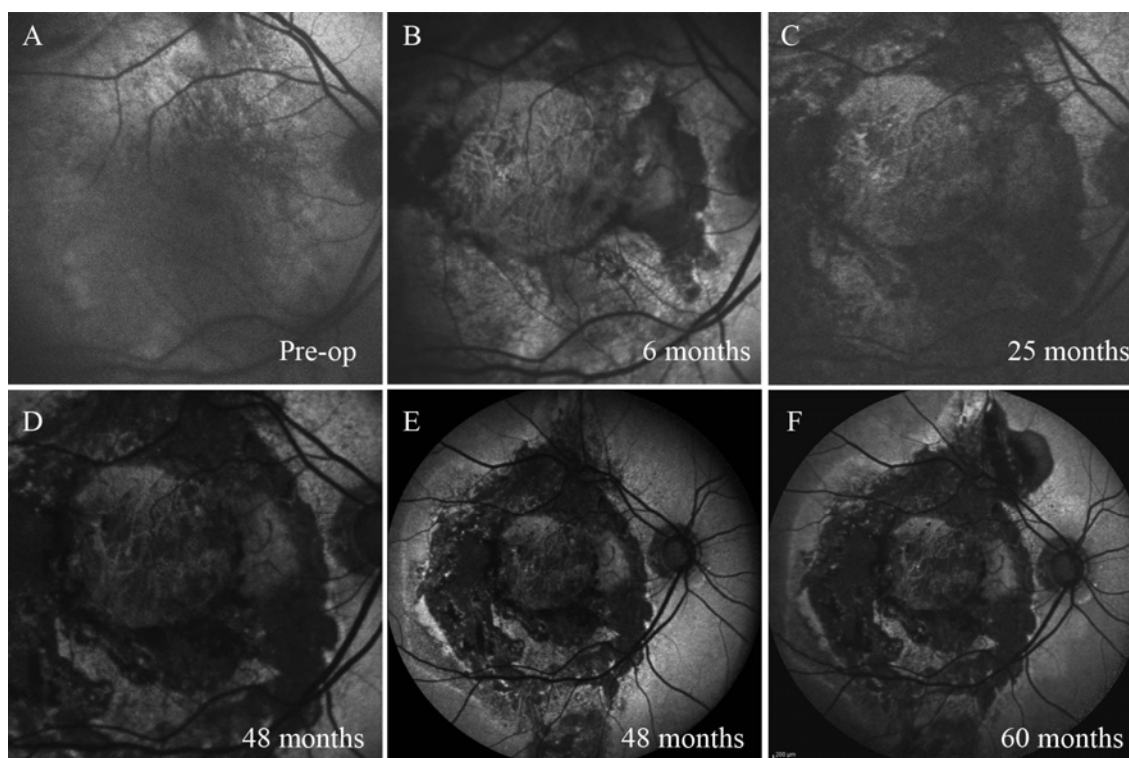
All 12 patients had some degrees of intraretinal cystic change over the patch graft accompanied by variable retinal atrophy or thickening (see **Figures 5.13** and **5.14**). This was accompanied by ERM in 8 patients and CNV in 5 patients. None of the patients received treatment for their CMO given the poor visual potential in some of these patients and mild degree of cystoid change in others.

SD-OCT through regions over the graft with retinal sensitivity showed intact outer plexiform and nuclear layers (see **Figures 5.13** and **5.14**). In areas without retinal sensitivity, retinal thickness was either reduced with loss of the reflective bands representing the plexiform layers (retinal atrophy) or thickened accompanied by intraretinal cysts (cystoid macular oedema).

##### **Fundus autofluorescence features**

Fundus AF signal was observed over the graft in the 10 patients examined after 1 year (18 – 48 months). Patchy areas of reduced autofluorescence over the graft corresponded to masking by RPE hyperplasia and subretinal fibrosis. Regions of the graft with homogenous AF signal did not necessarily predict retinal sensitivity. Although there was no significant loss of graft autofluorescence over time, the surrounding area with reduced autofluorescence signal enlarged during follow-up due to either progressive RPE atrophy or fibrosis of CNV (see **Figure 5.15**).





**Figure 5.15 Patch graft: serial fundus autofluorescence**

(A) Preoperative and (B-F) postoperative serial fundus autofluorescence images through 5 years demonstrating enlargement of RPE atrophy surrounding the patch graft. There's a recurrent CNV superonasal to the graft which bled between 4 and 5 years postoperatively.

### 5.4.3 Comparison between translocation and patch graft

#### 5.4.3.1 Case-mix matching of baseline features

Baseline features of the first 12 patients in the translocation cohort and the 12 patients in the patch graft cohort were comparable (see **Table 5.8**).

The median age for the translocation and patch graft groups were 72 and 78 respectively ( $p = 0.05$ ). Distribution of gender was not significantly different between the 2 groups ( $p = 0.1$ ). The duration of symptom prior to surgery in the translocation group was longer compared to the RPE graft group, mean of 11 and 5 weeks ( $p < 0.001$ ). Six and eight patients in the translocation and patch graft groups, respectively, had  $> 50\%$  of the lesion component comprising of CNV. There was a large variation in the size of lesion, ranging from 4 to 46 disc areas with the median size being 8 and 17 disc areas in the translocation and the graft group respectively ( $p = 0.4$ ).

There was no significant difference in the baseline median VA (logMAR) between the MT (0.90) and the patch graft groups (0.87),  $p = 0.44$ . All patients had foveal fixation pre-operatively as determined on the slit lamp (Uppal *et al.* 2007).

#### 5.4.3.2 Visual acuity comparison

The median (range) follow-up duration was 48 (32-64) and 43 (26-53) months in translocation and patch graft groups respectively. A summary of VA over 4 years are shown in **Table 5.9**.

**Figure 5.16** is a series of box plot showing the distribution in VA at the various time points for each group. The median VA (logMAR) in the translocation group improved from 0.90 at baseline to 0.60, 0.69, 0.69 and 0.58 at 1, 2, 3 and 4 years respectively (Friedman test,  $\chi^2$  (df = 4, n = 12) = 10.7,  $p = 0.03$ ). In contrast, the median VA (logMAR) for the patch graft group deteriorated from 0.87 at baseline to 1.46, 1.46, 1.38 and 1.64 at 1, 2, 3 and 4 years respectively (Friedman test,  $\chi^2$  (df = 4, n=12) = 19.0,  $p = 0.001$ ).

A comparison of change in VA between translocation and patch graft groups at 1, 2, 3 and 4 years showed significant difference (independent sample t-test) at all time points with mean differences of 0.79, 0.63, 0.72 and 0.88 logMAR at the respective follow-up visits (see **Figure 5.17**).

#### 5.4.3.3 Structural outcome comparison

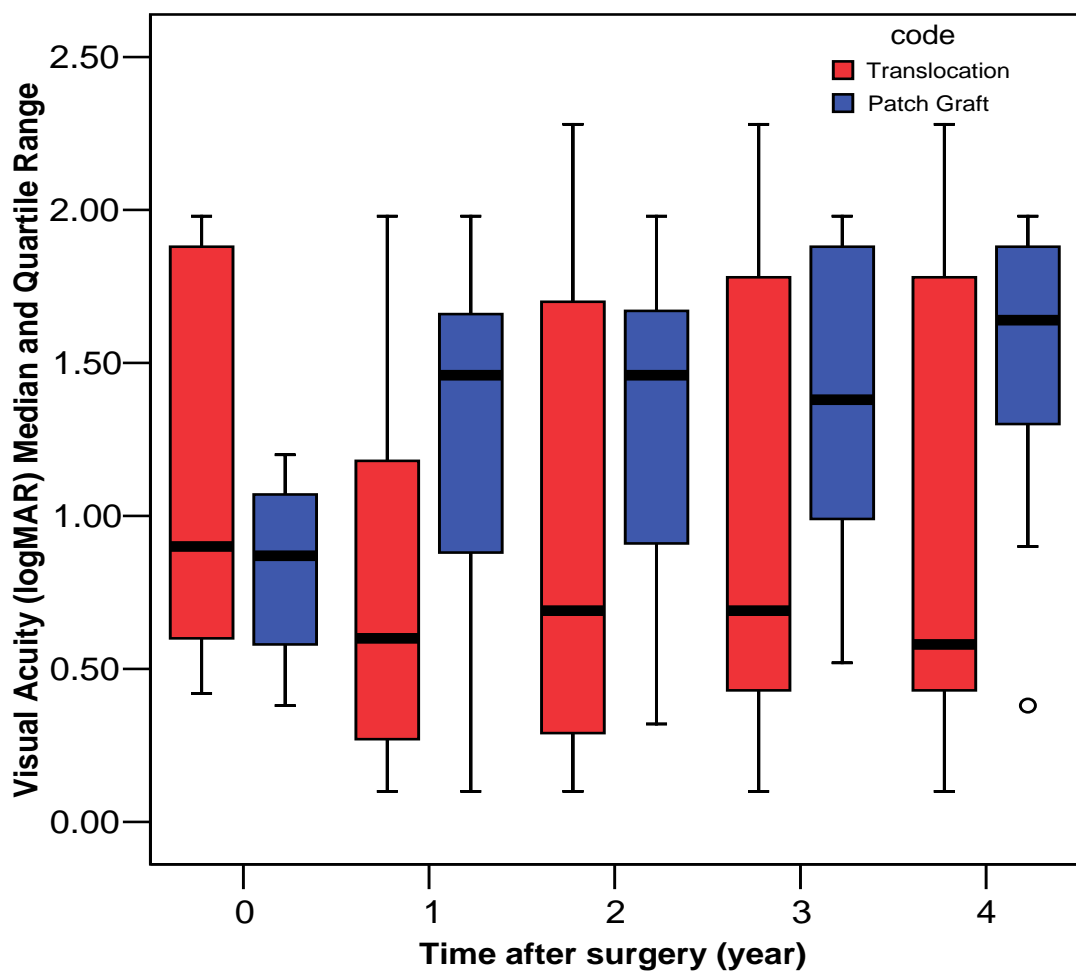
All 24 patients had postoperative serial OCT and FAF imaging for correlation with clinical findings.

In the translocation group, clinical and OCT assessments of the macula at 1 year revealed no retinal thickening, intraretinal cysts, subretinal fluid or subretinal tissue in 6 of 12 eyes. However, 1 developed a full-thickness macular hole and 2 showed small intraretinal cystic changes on OCT after 2 years. In the other 6 eyes, large intraretinal cysts were present. Of which, 2 had insufficient or no foveal rotation, 2 were related to CNV detected at 2-3 months following translocation and 2 were associated with dense epiretinal membrane which developed at 6-7 months following translocation. In these last 2 patients, oedema did not resolve despite peeling of the membranes. Overall, 4 patients had residual or recurrent CNV; all detected within the first 3 months.

In the patch graft group, all patients had disruption of outer retinal structure on OCT associated with irregular RPE surface of the graft (see **Figure 5.13 and 5.14**). Although foveal depression was seen in 6 patients, all 12 patients had cystic changes in

the retina over the graft accompanied by varying amount of atrophy and thickening. Overall, 5 patients developed recurrent CNV (2 within 1 year and 3 after 1 year). None of the recurrent CNV invaded the RPE graft. All grafts also had focal hyperpigmentation which became darker over time. Donor sites were free from any CNV during follow up.

The intensity of autofluorescence at the foveal region did not appear to change over time but the size of RPE defect (at the inferior arcade after translocation or surrounding the entire patch graft) enlarged (see **Figure 5.18**). Loss of autofluorescence around the graft was prominent in all cases of patch graft (see **Figure 5.18**).



**Figure 5.16 Translocation versus patch graft: median visual acuity over 4 years**  
 A box plot showing distribution of visual acuity at baseline, 1, 2, 3 and 4 years following macular translocation (blue) and autologous retinal pigment epithelium-choroid patch graft (green). Thick horizontal line represents the median. The upper and lower boundaries of the box represent quartile range and the whiskers represent minimum and maximum values.

**Table 5.8 Translocation versus patch graft: baseline features of patients**

<b>Baseline features</b>	<b>Translocation</b>	<b>Patch graft</b>	<b>Statistics (p-value)</b>
<b>Number of patients</b>	12	12	-
<b>Age (years)</b>			
Median (min, max)	72 (57, 95)	78 (73, 91)	0.05 †
<b>Gender (number)</b>			
Male, Female	3, 9	8, 4	0.1 ‡
<b>Predominant lesion type</b>			
CNV (classic, mixed, occult)	6 (0, 0, 5)	8 (0, 4, 4)	0.7 ‡
Non-CNV (blood, fibrosis)	6 (5, 1)	4 (2, 2)	
<b>Total lesion size (DA)</b>			
Median (range)	8.4 (3.6, 40.4)	17.4 (5.1, 46.6)	0.41 †
<b>Duration of symptoms (weeks)</b>			
Median (min, max)	10.5 (4, 32)	5.0 (2, 6)	0.00 †
<b>Baseline VA (logMAR)</b>			
Median (min, max)	0.90 (0.42, 1.70)	0.87 (0.38, 1.20)	0.44 †
<b>Surgery dates</b>			
Range	May 2003 to April 2005	August 2004 to June 2005	-

CNV, choroidal neovascularization; CS, contrast sensitivity; DA, disc area; MAR, minimal angle of resolution; max, maximum; min, minimum; MT, macular translocation; RPE, retinal pigment epithelium; SD, standard deviation; VA, visual acuity.

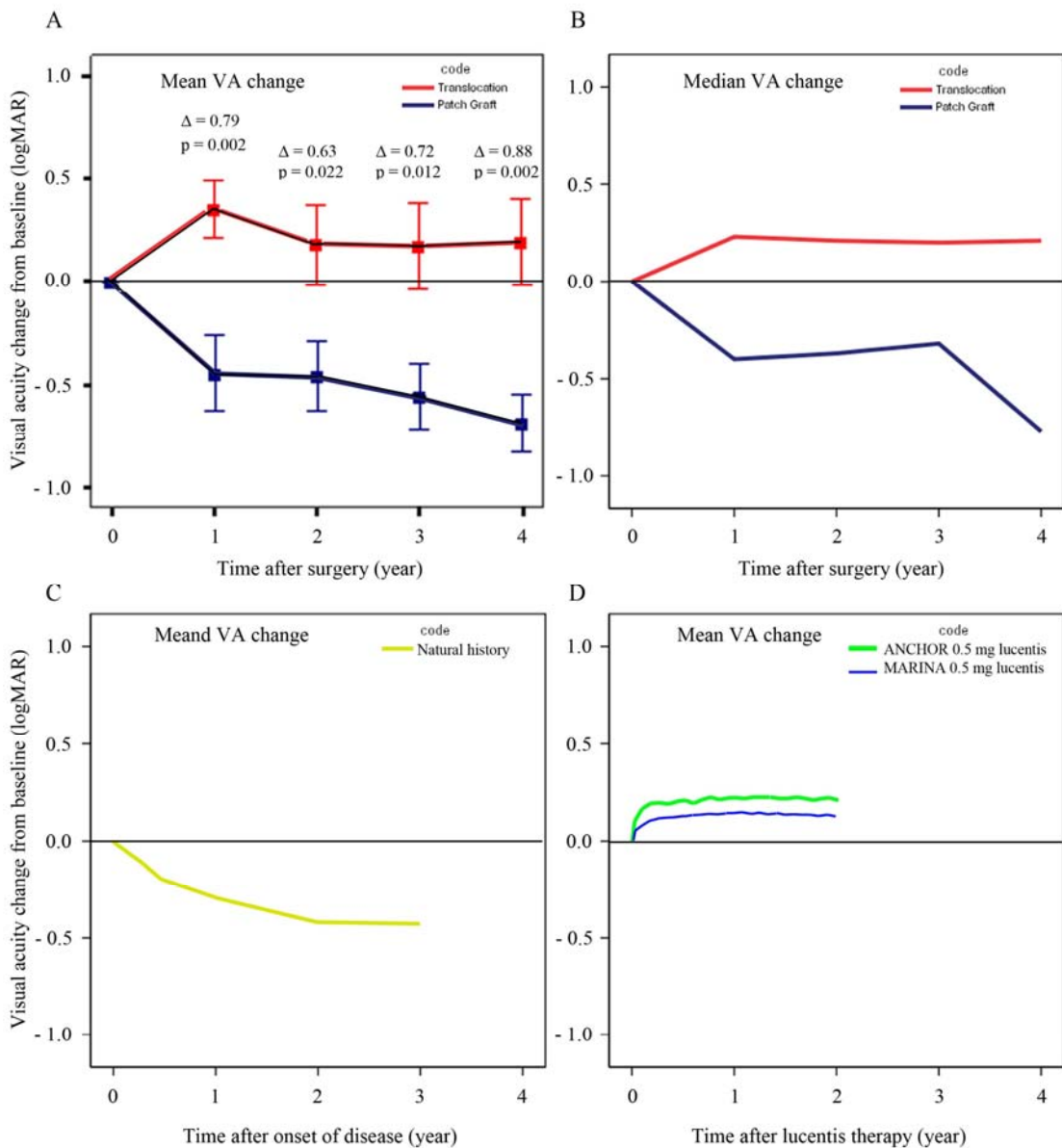
† Mann-Whitney U test, ‡ Fisher's exact test

**Table 5.9 Translocation versus patch graft: visual acuity over 4 years**

Patient	Visual acuity (logMAR)					Follow-up (months)
	Baseline	1 year	2 year	3 year	4 year	
MT01	1.98	1.36	1.78	1.78	1.78	60
MT02	1.98	1.98	2.28	1.98	1.98	64
MT03	0.44	0.10	0.10	0.10	0.10	60
MT04	0.42	0.60	0.78	0.78	0.60	60
MT05	1.98	1.78	1.62	1.78	1.78	54
MT06	0.78	0.60	1.98	2.28	2.28†	43
MT07	1.00	1.00	1.10	0.78†	0.78†	32
MT08	0.60	0.34	0.38	0.38	0.38	49
MT09	1.78	0.12	0.14	0.14	0.12	48
MT10	0.60	0.20	0.20	0.56	0.56	49
MT11	1.30	0.60	0.60	0.48	0.48†	38
MT12	0.80	0.80	0.60	0.60	0.54	48
PG01	1.12	1.40	1.40	1.32	1.30†	42
PG02	0.46	0.64	0.60	0.64	0.38	53
PG03	0.68	1.78	1.78	1.78	1.78†	45
PG04	0.38	1.98	1.98	1.98	1.98†	40
PG05	0.86	0.10	0.32	0.52	1.62	48
PG06	1.00	1.52	1.52	1.98	1.98†	36
PG07	0.88	1.00	1.00	1.06	1.78	53
PG08	1.04	0.76	1.06	1.26	1.48†	42
PG09	0.62	1.00	0.82	0.92	0.90	49
PG10	0.54	1.54	1.66	1.66†	1.66†	26
PG11	1.10	1.52	1.56	1.44	1.30	48
PG12	1.20	1.98	1.68	1.98	1.98†	37

MT; macular translocation, PG; patch graft

† Last-observation carried forward

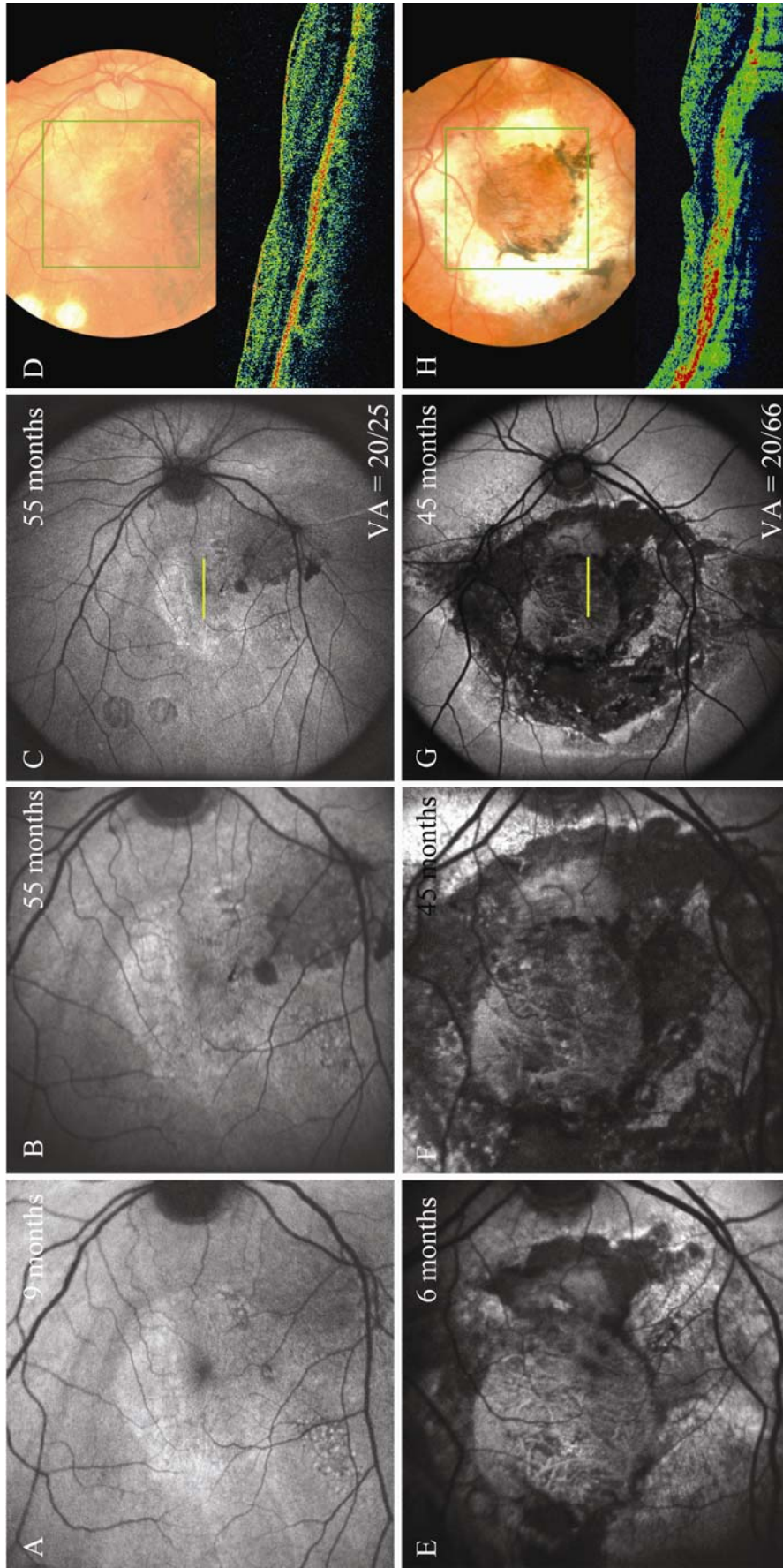


**Figure 5.17 Translocation versus patch graft: mean change in visual acuity**

(A) Line graph showing mean visual acuity (VA) change and error bars representing standard error of mean, from baseline to 1, 2, 3 and 4 years following macular translocation (red) and autologous retinal pigment epithelium-choroid patch graft (blue). (B) Line graph showing median of change in VA at 1, 2, 3 and 4 years following translocation (red) and patch graft (blue). (C) Line graph showing mean change in VA after diagnosis of neovascular AMD based on meta-analysis of untreated cohort (Wong *et al.* 2008). (D) Line graph showing mean change in VA after monthly injection of 0.5 mg lucentis in the ANCHOR (green line) and the MARINA (light blue line) trials (Brown *et al.* 2009; Rosenfeld *et al.* 2006). Positive value on y-axis represents an improvement in VA. Note that the y-axis scales are identical in all 4 graphs to aid comparison.

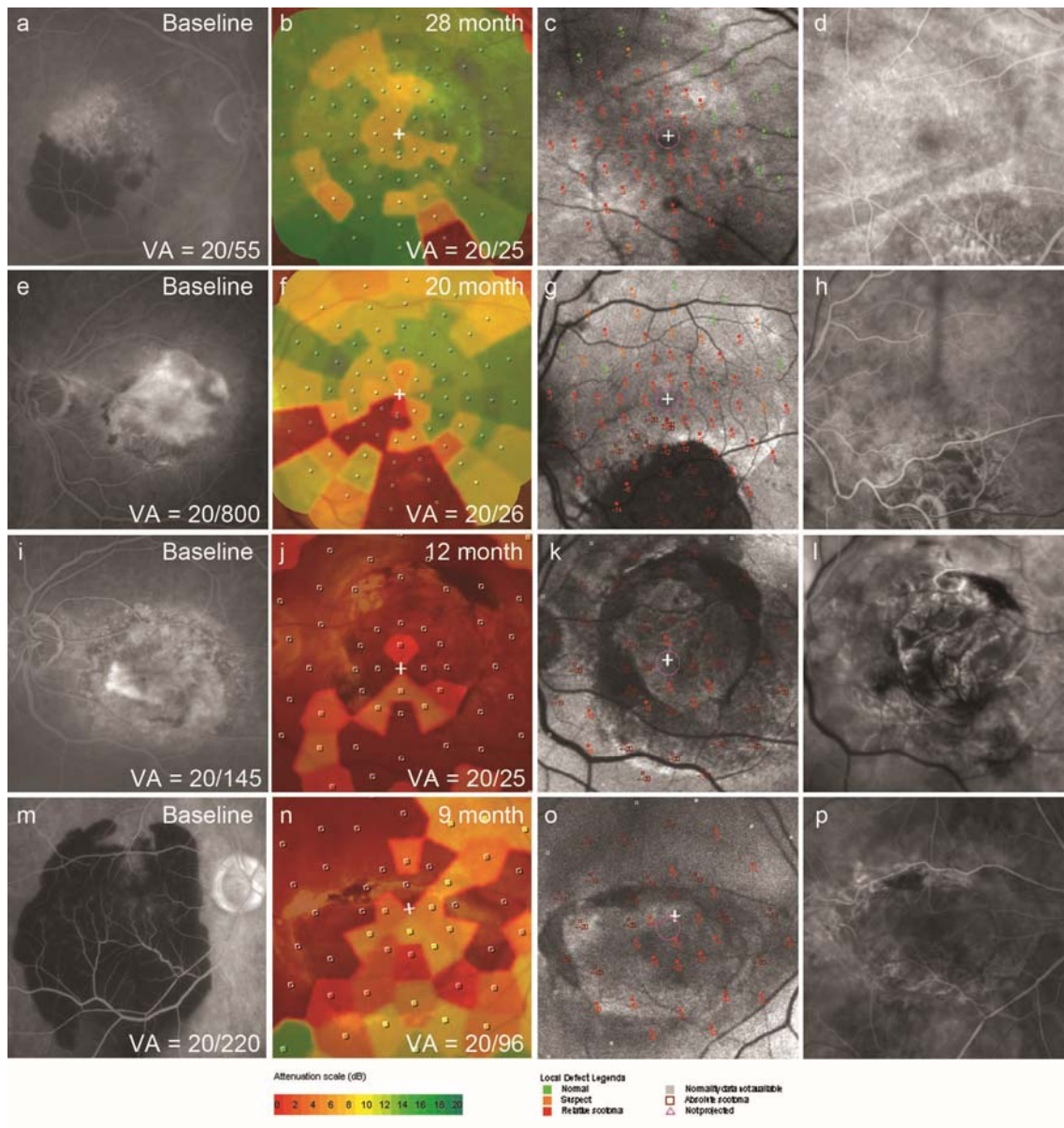
#### 5.4.3.4 Microperimetry outcome comparison

**Table 5.10** summarises the outcomes from the 3 best cases of each group. **Figure 5.19** shows that after translocation, dense scotoma was present only in the region where CNV was removed (dark areas on fundus autofluorescence image) but relative scotoma (below 3 standard deviation of the normal retinal sensitivity in NAVIS software database of the Nidek MP1) was widespread. In contrast, there was extensive dense scotoma after patch graft; even over parts of the graft and the surrounding areas, despite intact graft autofluorescence (see **Figure 5.19**).



**Figure 5.18 Translocation versus patch graft: AF and OCT images**  
 Serial autofluorescence images, colour fundus photograph and optical coherence tomography (OCT) through the fovea from patients MT03 (A-D) and PG05 (E-H). Yellow line in C and G indicates where the OCT is taken. Note the increasing size of area with no autofluorescence over time and the large area of atrophy surrounding the patch graft at 45 months in patient PG05 (G).





**Figure 5.19 Translocation versus patch graft: structure-function correlation**

Pre and post-operative images from patients MT03 (a – d), MT09 (e – h), PG04 (h – k) and PG08 (l – o). Visual acuity (VA) is shown in bottom right corner and microperimetry colour codes are shown at the bottom of the figure. Preoperative fluorescein angiography (FA) of patient MT03 at 2 minutes showed subfoveal occult choroidal neovascularisation (CNV) with subretinal haemorrhage (a). Postoperative microperimetry (using size Goldmann III, 200 ms white stimulus) at 28 months showed good retinal sensitivity in the macular region (b). Total deviation plot superimposed on autofluorescence (AF) image showed relative scotoma in central macula, dense scotoma over area of RPE defect but normal sensitivity (green) superonasally (c). Postoperative FA showed normal choroidal flush under the macula at 30 seconds (d). Preoperative FA of MT09 at 90 seconds showed subfoveal occult CNV with superior RPE rip (e). Postoperative microperimetry at 20 months showed retinal sensitivity present in the macular region (f). Total deviation plot superimposed on AF image showed relative scotoma in the majority of macular region and dense scotoma over area of RPE defect (g). Postoperative FA showed normal choroidal flush under the macula at 15 seconds (h). Preoperative FA of PG04 at 1 minute showed subfoveal minimally classic CNV (i). Postoperative microperimetry at 12 months showed a central island of sensitivity in the region of the graft (j). Total deviation plot superimposed on AF image showed dense ring scotoma surrounding an island of relative scotoma over the graft (k). Postoperative FA shows uneven choroidal flush in some areas of the graft at 20 seconds (l). Preoperative FA of PG08 at 2 minutes showed subfoveal massive subretinal haemorrhage (m). Postoperative microperimetry at 9 months showed retinal sensitivity in the nasal region of the graft (n). Total deviation plot superimposed on AF image showed relative scotoma over the graft but no area with normal sensitivity (o). Postoperative FA showed uneven choroidal flush in some areas of the graft at 30 seconds (p).

**Table 5.10 Translocation versus patch graft: retinal functions from best cases**

ID	Baseline		Follow up time point (months)	Visual function		Fixation stability*		Retinal sensitivity†	
	Predominant lesion features (size, DA)	VA (logMAR), symptom duration (weeks)		VA (logMAR)	CS (logCS)	% within 2 degrees	BCEA (min arc <sup>2</sup> )	10°, MS (min, max, dB), number of loci	20°, MS, MD (dB), number of loci
MT03	CNV, occult (9)	0.44, 6	28	0.10	1.65	100	470	14 (10, 18), 24	14.4, -4.8, 72
MT08	CNV, occult (4)	0.60, 12	24	0.38	1.50	100	598	5.0 (0, 10), 26	NA
MT09	CNV, occult (7)	1.60, 6	20	0.12	1.65	100	637	10 (0, 16), 24	9.6, -7.0, 72
PG04	CNV, occult (12)	0.86, 3	12	0.10	0.90	99	1794	0.8 (0, 4), 16	0.8, -17.3, 40
PG05	CNV, occult (47)	0.46, 6	16	0.64	1.05	100	627	1.0 (0, 5), 21	0.8, -16.2, 61
PG08	Haemorrhagic (27)	1.04, 2	9	0.68	1.05	98	2711	3.3 (0, 8), 16	3.9, -14.9, 37

\* All using 1 degree white cross over 30 second recording at rate of 25Hz or every 40 milliseconds.

† All using Goldmann III size, 200 ms stimulus and 4-2 strategy. Number of test loci also shown. BCEA, bivariate contour ellipse area; CS, contrast sensitivity; DA, disc area; MAR, minimal angle of resolution; max, maximum; min, minimum; MD, mean deviation; MS, mean sensitivity; MT, macular translocation; NA, not available; PG, patch graft; VA, visual acuity.

## 5.5 Discussions

### 5.5.1 Long-term outcomes in translocation

In this series of 40 consecutive patients, the long-term change in VA and its relationship to late post-operative complications was examined using detailed macular imaging techniques (SD-OCT and fundus AF) and functional assessment (microperimetry). At a mean follow-up of 3 years, 25% of patients still had a 3-line gain in VA and the median acuity was maintained at 6/36 with 68% of patients achieving 6/60 or better. However, a quarter of patients who were able to see 6/60 or better at 1 year, VA declined by greater than 2 lines primarily as a result of recurrent CNV.

#### 5.4.1.1 Long-term functional outcomes

The natural history of neovascular AMD is poor with only about 20% and 30% of the eyes being able to see 6/30 and 6/60 or better, respectively, after 3 years (Wong *et al.* 2008). The use of anti-VEGF agent has dramatically improved this outcome with up to 80% of the eyes maintained at VA of better than 6/60 at 2 years (Brown *et al.* 2006; Brown *et al.* 2009). The contrast between natural history of neovascular AMD and outcome of lucentis therapy can be seen in **Figure 5.17**. Previous large series showed that full macular translocation can also achieve a VA of 6/60 or better in over 80% of eyes at 1 year even in patients with lesion types which may not benefit from anti-VEGF therapy (Pertile and Claes 2002; Mruthyunjaya *et al.* 2004; Gelisken *et al.* 2007). However, recent reports raised concerns over long-term outcomes since (1) subfoveal expansion of the RPE atrophy was found in 61% of the eyes accompanied by VA loss and (2) recurrent CNV may occur after 1 year to threaten foveal function (Aisenbrey *et al.* 2007; Baer *et al.* 2008; Luke *et al.* 2009).

The 1 year VA outcome in this series is similar to that reported from other series (Pertile and Claes 2002; Mruthyunjaya *et al.* 2004; Gelisken *et al.* 2007). The long-term follow-up results suggest that VA can be maintained by paracentral RPE-choroid for 2 to 5 years following macular translocation. More detailed analysis of patients who had achieved a VA of 6/60 (25 of 32, 78%) at 1 year showed that the majority (84%) remained stable with longer follow-up. This suggests that in most patients, individual paramacular RPE cell can adapt to the metabolic demand of over 20 cones even though, prior to translocation, it supported only 1 or 2 cones and over 20 rods of the paramacular outer retina (Gao and Hollyfield 1992). However, some patients did lose VA (16%) or retinal sensitivity due to expansion of atrophy or recurrence of CNV after

1 year. Furthermore, there were persistent intraretinal cystoid changes and increased autofluorescence in the parafoveal region which did not seem to affect retinal function. Microperimetry in the subset of the cohort (patients 3, 9, 18 and 21) who maintained a VA of 6/12 or better beyond 3 years demonstrated stable mean macular sensitivity post-operatively. However, all 4 patients had improvement in the superior paramacular sensitivity and decline in the inferior paramacular sensitivity. This may be related to expansion of RPE atrophy at the site of previous CNV excision. During the course of this study, it was noted that there was no data on the test-retest variability of retinal sensitivity measurement on Nidek MP-1 in patients with macular disease. Therefore, the author subsequently conducted a prospective test-retest variability study examining intra-session agreement of retinal sensitivity measurements in 50 patients with macular disease (Chen *et al.* 2009). The coefficients of repeatability for individual test loci and the entire test grid (68 loci) were 5.6 and 1.8 dB, respectively. For paramacular region, the coefficient of repeatability was 1.9 dB but can be as high as 2.3 dB (upper bound of the 95% confidence interval, see **Appendix 1**).

#### 5.5.1.2 Pigment epithelium atrophy

A significant proportion (33%) developed subfoveal atrophy after translocation and there was a trend for poorer final VA in these patients. A much lower frequency of subfoveal RPE atrophy (10%) was reported by Sawa *et al.* (2008) in a group of myopic patients who underwent translocation. The higher rates of RPE atrophy in our series (using fundus AF) and the report by Aisenbrey *et al.* (61% when angiography was used) may be related to the older age group (mean of 75 years rather than 60 years) of patients and hence more widespread dysfunction in the RPE (Aisenbrey *et al.* 2007; Sawa *et al.* 2008). Expansion of atrophy in AMD has been observed in disciform lesions and after laser photocoagulation or submacular surgery to ablate or remove CNV (Dastgheib *et al.* 1993; Castellarin *et al.* 1998; Sarks *et al.* 2006). Even with an initially intact RPE following removal of type II CNV, RPE atrophy may appear after 18 months (MacLaren and Aylward 2005). The cause for delayed atrophy is unknown but may be related to changes in choroidal vasculature, primary RPE-Bruch's membrane disease or RPE cell death driven by the neurosensory retina. The latter theory has also been proposed as the cause of GA recurrence after translocation in atrophic AMD (Cahill *et al.* 2005a; Khurana *et al.* 2005). This underlies the importance of large angle rotation to move the fovea as far away from the edge of damaged RPE as possible. However, in patients with massive submacular haemorrhage or RPE rip, translocation may not be an

option since RPE beyond the arcades may also be damaged. In these cases, the use of equatorial autologous RPE-choroid patch graft with or without large retinotomy to extract the clot may be another option to restore submacular RPE-photoreceptor interaction (van Meurs and Van Den Biesen 2003; Gibran *et al.* 2009).

#### 5.5.1.3 Recurrent choroidal neovascularisation

The rate of CNV recurrence following macular translocation ranged from 8 to 56% within 1 to 2 years (Pertile and Claes 2002; Abdel-Meguid *et al.* 2003; Mruthyunjaya *et al.* 2004; Uppal *et al.* 2007; Gelisken *et al.* 2007; Gelisken *et al.* 2007; Baer *et al.* 2008; Luke *et al.* 2009). In previous case series of translocation, these lesions were treated by re-excision of the CNV, laser photocoagulation or PDT with poor outcome. We showed that with anti-VEGF therapy and frequent monitoring, reasonable VA can be maintained (median of 6/36). However, microperimetry and AF imaging showed that there was enlargement of paracentral scotoma due to RPE cell loss at the site of CNV recurrence. This indicates that early recognition and initiation of treatment are critical to limit the extent of RPE damage and loss of retinal function. Almost all reported cases of recurrent CNV occurred at the foveal edge of the RPE defect created by the CNV excision. Baer *et al.* postulated that the fovea signals the recurrence of CNV. However, they did not report any case of CNV arising *de novo* from under the translocated fovea. Our 1 case of *de novo* occult CNV and the 1 case of *de novo* classic subfoveal CNV described by Pertile *et al.* are unusual. The rarity of *de novo* CNV or GA developing at the paramacular RPE under the relocated fovea may be related to the thicker and less porous elastic layer of Bruch's membrane or anti-angiogenic factors produced by the RPE-choroid outside the macular region (Steele *et al.* 1993b; Chong *et al.* 2005; Semkova *et al.* 2006; Bhutto *et al.* 2006). In order to reduce the recurrent CNV, the fovea needs to be rotated as far away from the defect as possible or the submacular defect needs to be reconstructed by using healthier RPE such as those derived from stem cells (Lund *et al.* 2006; Vugler *et al.* 2008).

#### 5.5.1.4 Cystoid macular oedema

There are 2 groups of patients with post-operative CMO. One group had CMO associated with traction (ERM) or leak (CNV). The other had isolated idiopathic CMO which tended to be subclinical and may resolve spontaneously or persist for years. This higher rate of post-translocation isolated CMO compared to the previous study may be related to the longer follow-up in our series and the use of dense raster scan protocol of

SD-OCT to detect small cysts which may be missed by radial scans (Terasaki *et al.* 2003). The chronic cystoid change is unlikely to be due to postoperative uveitis alone since it persisted for many years in some patients without clinical signs of inflammation. Terasaki and colleagues found a 70% incidence rate of CMO and proposed that VEGF, carried within the translocated fovea and/or produced by the surrounding RPE, may also contribute to persistence perifoveal leakage. However, other mechanisms may also be responsible since we observed persistence of cystoid change in the foveal region despite resolution of leakage from extrafoveal recurrent CNV following anti-VEGF therapy. Another possible mechanism for the development of chronic CMO is non-specific vascular or RPE decompensation secondary to severe surgical trauma since macular translocation is one of the most invasive vitreoretinal procedures.

#### 5.5.1.5 Increased parafoveal autofluorescence

Increased AF may be related to increased concentration of fluorophores within the RPE resulting from excessive metabolic demand of the foveo-macular photoreceptors on paramacular RPE; analogous to that seen in the junctional zones of geographic atrophy. This is supported by the rare observation in our study of intact IPRL on SD-OCT, in the region of speckled pattern of increased AF surrounding areas of reduced AF. However, a much more common observation in this study was the exact co-registration between missing IPRL and speckled or homogenous patterns of increased AF on simultaneous SD-OCT with AF imaging.

Increased AF may be an unmasking effect. This phenomenon has been described in full-thickness macular holes, cystoid macular oedema and retinal bleaching experiments using short-wavelength fundus AF (McBain *et al.* 2008; Wakabayashi *et al.* 2008; Bessho *et al.* 2009; Theelen *et al.* 2008). Masking occurs because of absorption of the short-wave excitation light (488 nm) within the neuroretina by luteal pigments (i.e. lutein and zeaxanthin within the plexiform and nuclear layers) or visual pigments (i.e. blue cone and rod opsins within the outer segments of photoreceptor cell layer). Evidence of unmasking effects leading to increased AF were illustrated by the following 2 observations; (1) small round lesions within the foveal region co-registered with cystic change on SD-OCT (consistent with the findings from 2 previous reports on AF features of cystoid macular oedema (McBain *et al.* 2008; Bessho *et al.* 2009), and (2) well-delineated increased AF patches co-registered with loss of the reflective line that corresponds to the so-called IPRL on SD-OCT. Although the precise histological correlate of a missing IPRL line is unknown, close examination of the SD-OCT images

showed that IPRL line may have merged with the RPE line. If Drexler was correct in his guide to the analysis of the reflective bands in the outer retina and that this interpretation can be applied to a post-translocation eye, then the fusion between the 2 hyper-reflectively lines corresponding to the IPRL and the RPE may be interpreted as shortening of the outer segment. Following from this, a corresponding reduction in visual pigment in these regions may explain the relatively increased AF. Further evidence to support possible unmasking effect is the observation of reduced outer nuclear layer thickness in regions of increased AF in some patients and the subnormal retinal sensitivity as demonstrated on microperimetry.

Shortening of the outer segments of photoreceptor cells is a non-specific response to various genetic and acquired insults to the outer retina (Marc *et al.* 2003). Animal models have shown that development of CNV can lead to shortening of outer segments and loss of outer nuclear layer thickness (Baffi *et al.* 2000). Similarly, short-term retinal detachment can also lead to shortening of outer segment which persists even after the retina is reattached (Fisher *et al.* 2005). Detachment, however, cannot explain the observed outer segment shortening since the entire retina was detached during macular translocation surgery whereas the increased AF changes are limited to the parafoveal region. Furthermore, translocation experiment in monkeys showed that reattached retina had misaligned but normal length of the outer segment (Fang *et al.* 2004). Although we did not specifically examine the degree of matching between the distributions of increased AF regions and the pre-operative lesion, the parafoveal distribution of increased AF suggest that loss of outer segment is likely to be related to its interaction with subretinal fluid, blood and/or CNV tissue prior to translocation. The incomplete restoration of outer segment length even after 5 years may be due to permanent injury to the mechanisms of outer segment renewal as a result of interaction with toxic substances released by the CNV and/or continued unfavourable environment provided by paramacular RPE for complete outer segment regeneration. These patchy changes in outer segment morphology may explain previous findings of abnormal focal electroretinography and microperimetry within the relocated macula (Chieh *et al.* 2008; Terasaki *et al.* 2004).

### **5.5.2 Long-term outcomes in patch graft**

Long-term follow-up of the initial cohort of 12 patients who underwent autologous RPE patch graft (MacLaren *et al.* 2007) showed that VA, fixation stability and retinal sensitivity can be maintained beyond 4 years. However, there was a gradual decline in



VA and retinal function as measured using microperimetry. At a median follow-up of over 3 years, none of these patients gained 3 lines of acuity and only 2 of 12 (18%) had a VA of 6/60 or better. The late loss of vision coincided with the appearance of cystic retinal changes with or without retinal atrophy, macular oedema, RPE atrophy or CNV recurrence from the edge of the graft.

#### 5.5.2.1 Long-term functional outcomes

Maaijwee *et al.* (2007a) reported the visual outcomes in a cohort of 83 patients who were followed for 2 to 4 years. They found the mean VA (logMAR) improved from 0.95 at baseline to 0.89 at 1 and 2 years, 0.79 at 3 years and 0.74 at 4 years. (n = 84, 45, 24 and 11 patients, respectively). They also showed, with a Kaplan-Meier plot that the percentage of eyes losing < 3 ETDRS lines was 70-80% at 1 year and stabilised at around 40-50% at 2 to 4 years. Interestingly, the earliest cases of the entire cohort had a much better outcome with 82% (2 out of 11) losing less than 3 lines at 4 years. In their series, 19 out of 84 (23%), 6 out of 45 (13%), 4 out of 24 (17%) and 2 out of 11 (18%) eyes had VA of 6/24 or better at 1, 2, 3 and 4 years. In comparison, our result showed an overall decline in VA with similar percentages of eyes having lost less than 3 lines of acuity (50% at 2 years and 33% at 4 years). Although the results of the 12 cases are poorer than the earliest cases of van Meurs series, they are similar to the outcome of the entire cohort of 84 patients. A comparable result was seen despite higher rates of retinal detachment (42% compared to 8%) and recurrent CNV (42% compared to 13%). Furthermore, the proportion of patients in this cohort achieving a VA of 6/60 is no greater than natural history (Wong *et al.* 2008). The similarity between outcome of patch graft and natural history is shown in **Figure 5.17**.

Fixation over graft may be considered a sign of success as it indicates that the translocated RPE is able to support central visual function. Using various techniques to study fixation, previous studies have also shown 40 to 74% of eyes achieving fixation over the graft (van Meurs and Van Den Biesen 2003; Jousseaume *et al.* 2006; Treumer *et al.* 2007a; Treumer *et al.* 2007b; Maaijwee *et al.* 2007a; Heussen *et al.* 2008). Similar to that reported by Maaijwee and colleagues (2007a), it was found that fixation stability may worsen or improve during follow-up. The reason for worsening of fixation stability may be related to delayed cystic change or atrophy whereas improvement in stability may be related to adaptation to eccentric fixation and viewing (Crossland *et al.* 2005a; Crossland *et al.* 2004a).

Treumer *et al.* (2007b) reported microperimetry outcome in 5 of 10 patients during the first and second year (< 20 months). They found that the mean sensitivity improved by 2 or more dB in 2 eyes and lost 2 dB in 1 eye. In the Moorfields series, all 6 patients had a decline in mean retinal sensitivity but only 1 had significant change (> 2 dB loss) due to CMO over the graft associated with recurrent CNV (patient 8). However, loss of 6 or more dB in local retinal sensitivity at some point over the graft was noted in all tested eyes. This loss in local retinal sensitivity may be due to primary retinal atrophy, progressive dysfunction of the grafted RPE or test-retest variability in microperimetry (Convento and Barbaro 2007). Nevertheless, the results showed that some residual retinal sensitivity can be maintained over the graft for more than 3 years in some cases. The demonstration of structures which correspond to outer plexiform and nuclear layers on SD-OCT in regions over the graft where there is retinal sensitivity is consistent with the extensive literature which support photoreceptor cell rescue by RPE transplantation (da Cruz *et al.* 2007). Fundus AF signal, from the fluorophores within the RPE, is an indirect measure of outer segments renewal and lipofuscin clearance (von Ruckmann *et al.* 1995; Delori *et al.* 1995). The loss of retinal sensitivity over regions of the graft where AF signals remain may be explained by a combination of (1) prolonged retention of lipofuscin within the translocated equatorial RPE, (2) pre- or intra-operative loss of photoreceptor cells and (3) postoperative retinal atrophy (patient 4) or oedema (patient 8).

#### 5.5.2.2 Long-term structural outcomes

Late postoperative complications were common. Although retinal detachment did not occur after 12 months, some degree of ERM was present in the majority which may represent mild forms of proliferative vitreoretinopathy. It is not known if peeling of the ERM or ILM may have improved the overall outcome. However, the VA outcome was not superior in a previous series where the ILM was frequently peeled at the time of removal of oil (Maaijwee *et al.* 2007a). By using SD-OCT (in 9 patients) or TD-OCT (in 3 patients), it was possible to detect retinal atrophy associated with cystic change within the retina over all patch grafts. The high rate of cystic change compared to previous studies may be related to use of dense raster B-scan instead of the 6 radial B-scan protocols (Joeres *et al.* 2008). Intraretinal cysts over the graft may occur as a consequence of traction from ERM, leakage from recurrent CNV, compromised RPE, leaky perifoveal retinal capillaries, graft ischaemia, retinal atrophy or RPE atrophy (causing retinal cysts). Even with fluorescein and indocyanine green angiographies, it

was difficult to determine the contribution of each process to the intraretinal cystic change. Patchy loss of autofluorescence signal over the graft was related to pigmentation and fibrosis as previously reported (Schmitz-Valckenberg *et al.* 2008; Maaijwee *et al.* 2007a). The enlarging rim of absent AF signal (due to progressive RPE atrophy or fibrosis of recurrent CNV) surrounding the graft is of particular concern as this may compromise choice of preferred retinal locus if foveal fixation over the graft is lost.

### **5.5.3 Comparison between translocation and patch graft**

A comparison of outcomes of translocation versus patch graft showed that in the best cases, both procedures can restore foveal function in patients with neovascular AMD; achieving near-normal levels of VA (0.10 logMAR). However, the long-term visual and structural outcomes of translocation surgery appear to be superior compared to patch graft. This difference does not appear to be related to the case-mix or the surgical learning curves.

#### **5.5.3.1 Case-mix characteristics**

Factors that have been proposed to determine visual outcomes after translocation are preoperative features such as fixation stability, VA, duration of symptom and lesion composition, and operative variables such as surgical experience and learning curve (Oyagi *et al.* 2004; Wong *et al.* 2004; Mruthyunjaya *et al.* 2005; Toth and Freedman 2001; Abdel-Meguid *et al.* 2003; Uppal *et al.* 2007). Similarly, outcomes of patch graft have also been shown to be related to lesion composition and intraoperative course (Maaijwee *et al.* 2007a; Maaijwee *et al.* 2008c). The baseline features of the 2 groups are unlikely to explain the superior outcome following translocation in our cohort. Regardless of the specific preoperative prognostic factors, timing has been proposed as the most critical determinant since both translocation and patch graft are rescue procedures that require presence of viable photoreceptors (Uppal *et al.* 2007). In the Moorfields' cohorts, the baseline VA, fixation and lesion composition were similar between the 2 groups; however, the shorter duration of symptoms in the patch graft group would have favoured a better outcome. A wide range of total lesion size was found in each group and the median lesion size for the patch graft group was larger than that of the translocation group. However, this was not statistically significant. Furthermore, previous studies have reported that lesion size was not a predictor of VA

outcome in either translocation or patch graft (Mruthyunjaya *et al.* 2005; Maaijwee *et al.* 2007a).

### 5.5.3.2 Surgical course and learning curves

Although only the first 12 cases were chosen, including all intra- and postoperative complications arising from surgical learning curves, the surgical outcomes of translocation and patch graft are similar to previously reported larger case series of each technique.

Aisenbrey *et al.* (2007) reported a 75% rate of less than 3 line loss at 3 years (similar to results from our group) in a subset of 52 patients from a cohort of 90 patients. However, they showed a gradual loss of VA from a median of 1.00 logMAR at baseline to 1.20 logMAR at final examination after translocation. In contrast, the median VA of these first 12 cases improved from 0.90 to 0.69 logMAR at 3 years. The difference may be related to the high rate (61%) of secondary geographic atrophy (GA) in their study (Aisenbrey *et al.* 2007). Although secondary GA was not observed within the first three years after translocation, the sharp drop in survival (defined as less than 3 line loss) as shown in the Kapan-Meier plot in their report suggest that GA may occur later (Aisenbrey *et al.* 2007). Early postoperative complication is unlikely to explain the difference given the rates of retinal detachment (25%), macular oedema (50%) and recurrent CNV (8%) in the 12 cases are similar to those published previously (Eckardt *et al.* 1999; Ohji *et al.* 2001; Aisenbrey *et al.* 2002; Pertile and Claes 2002; Abdel-Meguid *et al.* 2003; Terasaki *et al.* 2003; Mruthyunjaya *et al.* 2004).

Maaijwee *et al.* (2007a) reported the 1 to 4 year outcome in a cohort of 83 patients with slightly poorer pre-operative VA (0.95 logMAR) than our group (0.87 logMAR). As discussed in previous section, the low post-operative VA in these 12 patients may be related to the high rates of retinal detachment (42%), graft haemorrhage (50%) and macular edema (50%), similar to that reported in previous larger series of patch graft (Joussen *et al.* 2006; Heussen *et al.* 2008; Joeres *et al.* 2008). Review of the surgical notes, it was found that 5 patients required 2 or more submacular manipulation of the graft. It is difficult to compare the scores of intra-operative course in the 12 patients with that reported by Maaijwee *et al.* (2008c) because their study was prospective and included a larger number of cases.

Given that the case-mix is similar and the surgical learning curves are matched, the difference in outcome may be explained by other factors. As discussed below,

factors related to surgical trauma, source of RPE and choroidal perfusion may explain the better outcome in translocation compared to patch graft.

#### 5.5.3.3 Trauma related to surgical approach

Surgical trauma to macular photoreceptors and donor RPE can occur during translocation and patch graft. Both techniques require mechanical retinal detachment (by subretinal injection or retinal peeling) at (1) the recipient site to allow removal of CNV complex and (2) the donor site, to enable translocation of the macula or the RPE-choroid patch. Trauma to photoreceptors and RPE occur during induced detachment because of disruption to the strong adhesive bond between these two layers. RPE damage after harvesting of RPE graft has been demonstrated by electron microscopy (MacLaren *et al.* 2007). Further insult to the RPE and photoreceptor cells is likely to occur during insertion and manipulation of the graft in the submacular space (Maaijwee *et al.* 2008c). In contrast, rotation of macula under heavy liquid is a much more controlled maneuver and is likely to be less traumatic than graft insertion. The microperimetry results showed contrasting patterns of scotoma which may reflect differences in the extent of iatrogenic damage to macular photoreceptor cells. After translocation, a large scotoma inferior to the fovea was found to correspond to the area of RPE defect created by CNV excision. However, in the patch graft patients, the ring scotoma in the absence of large areas of RPE defect may be related to surgical trauma to the macular photoreceptors during graft insertion and manipulation. Although the remaining central island of vision over the graft can maintain stable fixation and high spatial resolution, it does not provide the necessary horizontal visual span for reading tasks (Sunness *et al.* 1997). Furthermore, should the central island of vision be lost, the alternative retinal fixation locus may be pushed much further away from the fovea since there is no adjacent functioning retina. Damage to the RPE and retina may also occur during silicone oil tamponade although both had similar duration of oil in situ (Tafoya *et al.* 2003; Gonvers *et al.* 1986). Overall, the patch graft technique may be more traumatic to macular photoreceptor cells and RPE compared to translocation. However, surgical trauma alone may not be the only explanation for the difference in outcome.

#### 5.5.3.4 Source of retinal pigment epithelium

The source of RPE in translocation is located at the vascular arcade (paramacula) when the macula is rotated 45° around the disc. In contrast, RPE outside the vascular arcade (equatorial) is chosen for harvesting of autologous RPE-choroid graft. Several studies

have found topographic differences in the RPE gene expression and Bruch's membrane composition (Ishibashi *et al.* 2004; Bowes *et al.* 2006; van Soest *et al.* 2007; Kociok and Jousen 2007; Chong *et al.* 2005). Therefore, it is likely that there may also be topographic differences in RPE function and that equatorial RPE may not be as suitable as paramacular RPE in providing long-term support for foveal cones. This is consistent with our findings of the delayed cystic degeneration or cystoid macular edema over the RPE graft. However, the late occurrence of *de novo* GA following translocation suggests that even paramacular RPE may not be an ideal substitute for submacular RPE in patients with AMD (Aisenbrey *et al.* 2007).

#### 5.5.3.5 Choroidal and patch graft perfusion

A major difference between the 2 types of surgical modalities is that in translocation, perfused retina is rotated onto perfused choroid whereas in patch graft technique, the RPE-choroid patch is a free graft which may not become perfused for several days after the procedure. During these first few days, the underlying damaged choroidal bed may not provide enough metabolic support for the outer retina through the entire thickness of the patch graft. Evidence of first vascular connection between the graft and choroidal bed in a pig model is 1 week (Maaijwee *et al.* 2007b). Clinically, perfusion of the graft can be visible on fluorescein or indocyanine green angiography in some patients at 1 week (Maaijwee *et al.* 2008d; Treumer *et al.* 2007a). Although most grafts are perfused by 1 month, it may be delayed for as long as 3 months (Jousen *et al.* 2006). Graft reperfusion may depend on (1) the vascularity of the wound bed, which may be compromised by prior PDT or during removal of CNV, and (2) the presence of pro-angiogenic factors, which can be reduced by prior anti-VEGF therapy. Both of these factors are not relevant in translocation. While graft perfusion is being established in the first few days, ischemic damage to the outer retina is likely to compromise visual outcome. Despite this limitation, one advantage of patch graft is that it appears to resist invasion by recurrent CNV. This may be related to the thicker and less porous elastic layer of equatorial Bruch's membrane or anti-angiogenic factors produced by the equatorial RPE-choroid (Steele *et al.* 1993a; Chong *et al.* 2005; Bhutto *et al.* 2006; Semkova *et al.* 2006).

#### 5.5.4 Strength and limitations of the study

The strength of the study was the inclusion of consecutive patients undergoing translocation or autologous grafts in a single institution. A total of 52 patients with

neovascular AMD were identified to have undergone surgery for translocation or patch graft. This is still the largest cohort of patient followed for the longest duration in the published literature. All patients were been examined by the author at least once during follow-up visits and their ocular status were documented in detail. The availability of microperimetry results from many of these patients offered unique opportunity to study then long-term function rescue of photoreceptor cells by paramacular or equatorial RPE.

The main limitation was the retrospective design and therefore various outcome measures were not available in all patients. Furthermore, the sample size was not large enough for additional statistical analysis of factors that may predict visual outcomes.

Despite these limitations, the detailed functional tests and macular imaging in some patients allowed the relationship between photoreceptor layer structures and retinal sensitivity to be explored. In future studies, *in vivo* cellular imaging using AOSLO to visualize RPE and cones mosaic may provide more information on the interaction between paramacular RPE and foveal photoreceptors (Liang *et al.* 1997; Roorda *et al.* 2007).

The comparison study was also limited by the small sample size (12 versus 12). However, it was possible to show that case-mix and learning curves were unlikely to contribute to the difference in outcome. The lesser surgical trauma, use of paramacular RPE and immediate submacular choroidal perfusion may explain the superior outcome following translocation. The difference in outcome was further supported by detailed microperimetry which revealed that normal fixation stability (BCEA of <1200 minarc<sup>2</sup>) and a retinal sensitivity of greater than 10 dB within the central 10° can be achieved consistently after translocation but not after patch graft (Steinman 1965; Rohrschneider *et al.* 1995; Crossland and Rubin 2002).

### **5.5.5 Clinical implications and conclusions**

Both translocation and patch graft techniques are options for patients with neovascular AMD who are otherwise, ineligible for or non-responders of anti-VEGF therapy. Although both types of approaches can rescue foveal function, these data suggest that translocation with 360° retinotomy is able to achieve superior long-term visual outcome compared to patch graft in the cohort of patients studied. On the whole, the visual outcome after patch graft (as described by van Meurs) may not be any different from natural history. Furthermore, it seems that the mean VA gain following translocation is comparable to that observed after monthly anti-VEGF therapy. Although the patient characteristic in the ANCHOR and MARINA studies are very different from those

reported in this chapter, the expected outcome for untreated disease in both groups is likely to be similar. This raises an interesting question of whether 2 to 3 operations (day procedures) within a 6 month period; a minimal requirement for translocation, is more economical than 15-24 anti-VEGF injections over 2 years for the treatment of patients presenting with second eye affected by neovascular AMD. However, regardless of whether health economics calculation predicts a better cost-benefit ratio for translocation surgery compared with anti-VEGF therapy, from the author's experience of counselling patients with acute neovascular AMD, most patients would prefer to have a quick intravitreal injection of anti-VEGF agents every month than to undergo 2 or more major eye operations which still carry significant risk of blinding complications.

Therefore, macular translocation would be recommended in preference to patch graft as an option for treatment of second eyes with acute neovascular AMD unsuitable for anti-VEGF agents. However, expansion of pre-existing RPE atrophy and recurrence of CNV within the first 2-3 years may threaten loss of visual function in a minority of patients after translocation. Hence, close post-operative monitoring during the first 2 years is necessary to enable early treatment of recurrent CNV and prevention of delayed visual loss.

## **5.6 Contribution**

Author's contribution to the work presented in this chapter are summarised in **Table 5.11**. The author conducted further studies in microperimetry in view of lack of the data on repeatability whilst serial microperimetry was analysed. The result of a prospective study examining the intra-session test-retest variability of retinal sensitivity measurements was published and that of fixation stability is being reviewed. The reported coefficients of repeatability for microperimetry will be useful for future clinical trials using retinal sensitivity as one of the core outcome measure (see **Appendix 1**).



**Table 5.11 Contribution list for the neovascular macular degeneration studies**

Contribution category		Details of contribution
1	Conception and design	<b>Author:</b> <u>drafted protocol and ethics application forms for the 2 retrospective studies and the comparative study between patch graft and macular translocation</u> LDC: approval of all study documents
	Data acquisition	<b>Author:</b> <u>examined all 52 patients who underwent patch graft or macular translocation. Also performed all their ETDRS VA, Pelli-Robson CS, OCT and FAF imaging. Author performed serial microperimetry on 6 patch graft patients and 6 translocation patients. All clinical records were reviewed by the author</u> LDC: performed all surgical procedures
	Data analysis and interpretation	<b>Author:</b> <u>analysed and interpreted all clinical documentation, fundus imaging and microperimetry results</u> LDC: supervised interpretation of results CB: supervised statistical analysis
2	Writing	<b>Author:</b> <u>wrote the entire chapter</u>
	Revising	<b>Author:</b> <u>revised the entire chapter</u> LDC: read the chapter and made suggestions PJC: read the chapter and made suggestions
3	Statistical analysis	<b>Author:</b> <u>performed all statistical analysis</u> CB: supervised statistical analysis
	Funding	<b>Author:</b> <u>obtained a scholarship from Bausch &amp; Lomb (\$10,000)</u> PJC and LDC: obtained funding for the London Project to Cure Blindness
	Administrative and technical support	<b>Author:</b> <u>arranged all post-operative visits and created all the graphs and figure montage from the image database</u> TB: arranged submission of forms to research governance

CB; Catey Bunce (statistician), CS; contrast sensitivity, ETDRS; Early Treatment Diabetic Retinopathy Study, FAF; fundus autofluorescence, LDC; Lyndon Da Cruz (supervisor), OCT; optical coherence tomography, PJC; Peter J Coffey (supervisor), TB; Tina Burman (research co-ordinator), VA; visual acuity.

## **Chapter 6**

# **Human ESC-RPE Transplantation in Porcine Model**

## 6.1 Background

Photoreceptor cell rescue by macular translocation and RPE graft have provided the proof of principle in cell replacement therapy for retinal diseases. However, as **chapters 4 and 5** demonstrated, these techniques have not been used widely because of the complexity of the surgical procedure and the high postoperative complication rates. For RPE reconstruction to become a clinically feasible therapy on a larger scale, a simpler and safer surgical technique must be developed. One approach is to deliver a pre-made monolayer of healthy RPE on a bio-compatible substrate into the subretinal space. Using sources other than autologous RPE to derive the donor cells avoids the extra surgical manouvres in harvesting autologous RPE for patch grafting or creation of 360° retinotomy and total retinal detachment for translocation. Other advantages of using allogeneic cells are that cell lines without known genetic defects that may affect RPE cell function can be chosen and there is opportunity to manipulate the donor RPE *in vitro* to enhance its survival and function *in vivo*.

Allotransplantation of adult or fetal RPE has been performed in the past without evidence of significant functional rescue (Peyman *et al.* 1991; Algvere *et al.* 1994; Gouras and Algvere 1996; Algvere *et al.* 1997; Algvere *et al.* 1999; Weisz *et al.* 1999; Del Priore *et al.* 2001; Tezel *et al.* 2007). This may have been due to (1) anoikis of RPE related to cell suspension delivery, or (2) RPE graft rejection characterised by fibrous encapsulation of the small RPE sheets delivered into the subretinal space. Transplantation of the RPE cells on a substrate has been explored as a way to improve its survival in the subretinal space. Many of these substrates were shown to be inappropriate as they (1) did not support RPE growth and differentiation, (2) were difficult to handle surgically, (3) were insufficiently porous for RPE to exchange metabolite with the choroid or (4) induced inflammation and fibrous reaction in the subretinal space.

To address the two critical issues of (1) donor cell integration and (2) protection from immune rejection, this chapter investigates the use of RPE derived from human embryonic stem cells (hESC-RPE) in a porcine model.

## 6.2 Aims

In this chapter, the results of the 4 porcine experiements are presented to to answer the following questions:

1. Is it feasible to perform subretinal transplantation of hESC-RPE on a polyester substrate in the normal porcine eye?
2. What is the fate of xenografted hESC-RPE, the supporting polyester substrate and the photoreceptor cells overlying the graft following transplantation?
3. What are the inflammatory and immunological responses to the bleb detachment, polyester substrate, matrigel coating and the hESC-RPE?

### **6.3 Specific Methodology**

This has been described in **chapter 3.2**.

### **6.4 Results**

#### **6.4.1 Baseline features and surgical intervention**

A total of 21 pigs were operated in 4 separate sessions of experiments (see **Table 6.1**). The age of the pigs ranged from 7 to 9 weeks. These were all female domestic pigs with either blue or brown irides. The baseline weight ranged between 20 and 34 kg (median; 23).

All pigs had intraocular surgery in the left eye. Amongst the 21 vitrectomies performed, 2 had bleb detachment only, 4 had subretinal polyester substrate implant (1 coated with Matrigel™ and 3 uncoated), 2 had subretinal limbal fibroblast on coated polyester substrate and 13 had subretinal hESC-RPE on coated polyester substrate.

#### **6.4.2 Surgical course and outcome**

The surgical steps for hESC-RPE graft are similar to autologous RPE-choroid graft (see description in **Section 4.4.3**) with the exception of the need to harvest autologous RPE. The procedure can be divided into the following 5 key steps: (1) induction of posterior vitreous detachment and vitrectomy, (2) creation of bleb retinal detachment and retinotomy, (3) preparation of the hESC-RPE graft from the modified Transwell® Insert at the bench top, (4) transfer and delivery of the graft from the bench top to the subretinal space and (5) sealing of the retinotomy / retinal break, and closure of the sclerostomies / peritomies.

Posterior vitreous detachment was induced in all 21 eyes using the vitreous cutter at maximum aspiration. During vitrectomy, 1 had lens touch, 1 developed suprachoroidal haemorrhage and 1 developed retinal detachment. Bleb detachment was achieved consistently using the 41G cannula and the retinotomies were successfully

enlarged using vertical scissors. Two eyes had limited bleeding from the retinotomy sites.

A patch graft was able to be cut out using the customised punch. However, several animals required more than 1 patch graft to be cut out from the modified Transwell® Insert due to significant loss of the hESC-RPE monolayer during punch of the graft, handling of the patch or insertion of the graft into the eye. In 6 of the 12 (50%) animals that received hESC-RPE, there was shifting of the hESC-RPE monolayer over the substrate when the graft was being pushed into the subretinal space. Of these 6, 4 had to be explanted due to significant loss of the hESC-RPE. These animals received a second graft which was inserted without further complication. All animals had air-fluid exchange which allowed the bleb detachment to flatten. Sclerostomies and peritomies were closed without any complication.

Overall, there was no surgical complication in 10 of 21 eyes. All pigs recovered from general anaesthesia except for animal numbers 11 (planned euthanasia) and 16. Pig number 16 had cardiorespiratory arrest within an hour following surgery and therefore was excluded from further analysis. Summaries of operative course and postoperative complications are shown in **Tables 6.2** and **6.3**.

At the time of termination, fundus examination showed attached retina in 8 of 20 animals. There was variable amount of pigmentation seen over the graft with some depigmentation surrounding the patch. The fundus was not visible in the remaining 12 animals due to lens opacity (2 eyes), vitreous cavity air bubble (3 eyes) and varying degrees of vitreous blood and fibrin strands (7 eyes). The range of intraocular pressure was 10 to 28 mmHg across all time points. The choroidal haemorrhage and retinal detachment encountered intraoperatively had resolved spontaneously when the animals were examined prior to euthanasia.

Animals were euthanised at the following time points: 2 hours (1 pig), 2 days (2 pigs), 1 week (4 pigs), 2 weeks (4 pigs), 4 weeks (3 pigs) and 6 weeks (6 pigs).

**Table 6.1 Pig experiment: Baseline features**

<b>Pig No.</b>	<b>Wt (kg), Age (wk)</b>	<b>Date of surgery</b>	<b>Type of transplant received</b>	<b>CYA given</b>	<b>Duration of survival</b>
1	34, 9	12/12/2007	PS	+	29 days
2	34, 9	13/12/2007	PS + MC + hESC (blob)	+	28 days
3	34, 9	13/12/2007	PS + MC	+	28 days
4	20, 7	02//04/2008	PS + MC + hLF	-	43 days
5	23, 7	02//04/2008	PS + MC + hLF	+	43 days
6	22, 7	02//04/2008	PS + MC + hESC (blob)	-	43 days
7	20, 7	03//04/2008	PS + MC + hESC (blob)	+	42 days
8	23, 7	03//04/2008	PS + MC + hESC (blob)	-	42 days
9	24, 7	03//04/2008	PS + MC + hESC (dr-s)	+	42 days
11	32, 9	12/11/2008	PS + MC + hESC (dr-s)	-	60-120 min
12	23, 7	12/11/2008	PS + MC + hESC (dr-s)	-	15 days
13	23, 7	12/11/2008	PS + MC + hESC (dr-s)	+	2 days
14	23, 7	12/11/2008	PS + MC + hESC (dr-s)	-	7 days
15	23, 7	13/11/2008	PS + MC + hESC (dr-s)	+	7 days
16	23, 7	13/11/2008	PS + MC + hESC (dr-s)	-	deceased
17	23, 7	13/11/2008	PS + MC + hESC (dr-s)	+	14 days
18	30, 9	04/12/2008	None	-	7 days
19	30, 9	04/12/2008	None	-	14 days
20	30, 9	04/12/2008	PS	-	7 days
21	30, 9	04/12/2008	PS	-	14 days
22	30, 9	04/12/2008	PS + MC + hESC (dr-s)	-	2 days

CYA; cyclosporine A, PS, polyester substrate; dr-s, dissociated then re-seeded; hESC, human embryonic stem cell; MC, matrigel® coating, +, yes, -, no.

**Table 6.2 Pig experiments 1 and 2: Surgical course and complications**

Pig	Intraoperative complication	Postoperative examination			
		IOP	Anterior segment	Vitreous	Fundus
1	Lens touch	18	Cataract	NV	NV
2	Suprachoroidal haemorrhage	16	Clear	Blood, Fibrin	NV
3	None	14	Clear	Clear	No RD, white patch graft clearly seen
4	2 patches required, 1 removed and analysed	13	Cataract	Blood, Fibrin	NV
5	2 patches required, 1 lost and not found	10	Clear	Blood, Fibrin	NV
6	RPE on patch shifted	17	Clear	Clear	No RD, Faint pigment over graft
7	RD, retinotomy bleed, RPE on patch shifted	14	Conjunctival granuloma	Clear	No RD, Diffuse dense pigment over graft
8	RPE on patch shifted	13	Clear	Clear	No RD, Diffuse dense pigment over graft
9	None	14	Clear	Clear	No RD, diffuse pigment on graft

RD; retinal detachment, NV; no view.

**Table 6.3 Pig experiments 3 and 4: Surgical course and complications**

Pig	Intraoperative complication	Postoperative course			
		IOP	Anterior segment	Vitreous	Fundus
11	Retinal break, retinotomy bleed, loss of hESC-RPE	-	Clear	Air	NV
12	2 patches required, 1 removed and analysed	12	Clear	Blood, Fibrin	NV
13	None	28	Clear	Air	NV
14	Loss of cell over patch	14	Clear	Clear	No RD, retinal fold over patch graft, no pigment on graft
15	None	15	Clear	Blood, Fibrin	NV
16	None		postoperative cardiac arrest on same day (Air in eye) Enucleated and fixed 3 hours post-mortem		
17	None	15	Clear	Blood	NV
18	None	15	Clear	Blood	No RD
19	None	9, 19	Clear	Clear	No RD, white punctuate mark
20	None	10	Clear	Blood	NV
21	None	19, 13	Clear	Clear	No RD, ERM, pigment developed over patch
22	Loss of cell over patch, 2 patches used	19	Clear	Air	NV

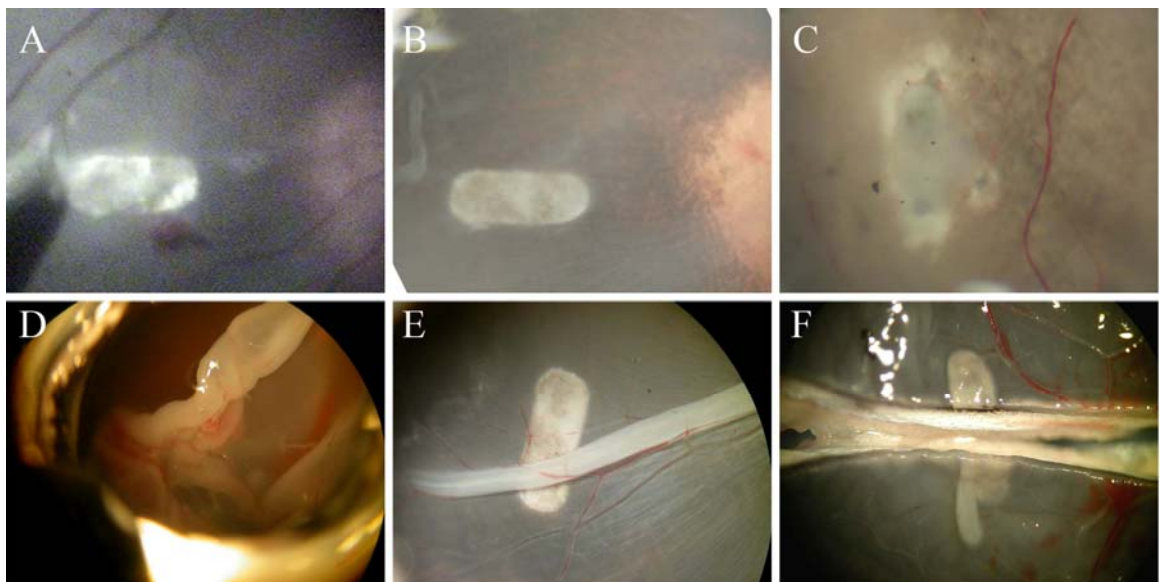
RD; retinal detachment, NV; no view.



### 6.4.3 Tissue fixation and gross pathology

Gross pathological features and the type of tissue processings are summarised in **Tables 6.4** and illustrated in **Figure 6.1**. After removal of the anterior segment, retinal detachment was noted in 9 of 20 eyes (see **Figure 6.1**). However, 8 of these were related to fixation artefact. Of the 11 eyes with attached retina, 6 had retinal folds. The polyester substrate was found in the subretinal space in 16 of the 18 animals that received a patch graft. One of these also had another graft (lost during surgery) in the vitreous base, adjacent to the ciliary body. In the remaining 2 animals, the graft was found within the vitreous cavity. Of the 12 animals that had subretinal hESC-RPE patch graft on gross examination of the eye cups, 3 had focal, 5 had patchy and 4 had diffuse pigmentation on the substrate. Four eyes also had pigmentation changes in the surrounding RPE.

Sectioning of the posterior cup induced further retinal detachments in 3 eyes which previously had attached retina. Tissue preparation of the eye from pig 22 also led to loss of the patch graft precluding further analysis of donor cell survival. A total of 19 eyes were processed for light microscopy and 9 of these were also processed for electron microscopy.



**Figure 6.1 Porcine transplantation: gross pathology**

(A) Intra-operative view of the RPE graft during air-fluid exchange in animal number 9. (B) The gross appearance of the graft in animal number 9 at 6 weeks (anterior segment has been removed). (C) The gross appearance of the graft from animal number 7 at 6 weeks showing pigmentary alteration around the patch. (D) Rhegmatogenous retinal detachment in animal number 15. (E) A large retinal fold across the graft in animal number 14. (F) Sectioning of the graft in animal 17 led to artefactual retinal detachment.

**Table 6.4 Gross pathology and tissue processing**

Pig No.*	Gross pathological features						Tissue processing		
	VC	RD	RF	Location of graft	Pigment on graft	Pigment change	artefact	LM	EM
1	-	A	-	SR	-	-	-	+	-
2	-	-	-	SR	F	-	-	+	-
3	-	-	Large	SR	-	-	-	+	-
4	-	A	-	VC	N/A	-	-	-	-
5	-	-	Large	SR + VC	F	-	+	+	+
6	-	-	-	SR	F	-	-	+	-
7	-	-	-	SR	D	+	-	+	+
8	-	-	-	SR	D	+	-	+	+
9	-	-	-	SR	D	-	-	+	+
11	Air	A	-	SR	D	+	-	+	+
12	-	A	-	SR	P	-	-	+	+
13	Air	A	-	SR	P	-	-	+	-
14	-	-	Large	SR	P	-	+	+	+
15	Blood	R	-	VC	N/A	-	-	+	-
17	-	-	Small	SR	P	-	+	+	+
18	-	A	-	N/A	N/A	-	-	+	-
19	-	A	-	N/A	N/A	-	-	+	-
20	-	-	Small	SR	-	-	-	+	-
21	-	-	Small	SR	F	-	-	+	-
22	Air	A	-	SR	P	+	+	+	+

A, artefactual retinal detachment; D, diffuse pigmentation; F, focal pigmentation; N/A, not applicable; P, patchy pigmentation; R, rhegmatogenous retinal detachment; RD, retinal detachment; RF, retinal fold; SR, subretinal space; VC, vitreous cavity

\* Animal number 10 was not used for transplantation study and animal 16 did not survive anaesthesia and are therefore excluded from further analysis.

#### **6.4.4 Donor cell survival and neuroretinal structure**

Human cell was identified in the subretinal space in 50% (6 of 12 eyes) of animals that received hESC-RPE (summarised in **Table 6.5**). At the 2-hour and 2-day time points, there was a monolayer of pigmented human cells lining the surface of the substrate (see **Figure 6.2**). On electron microscopy, these cells were polarized; displaying apical microvilli and melanosomes (see **Figure 6.2**). However, between 1 and 2 weeks, there was a significant reduction in the number of pigmented human cells. By 6 weeks, only 2 of 4 animals had surviving human cells. Cell survival was not directly related to cyclosporine administration. These surviving cells expressed CRALBP and Bestrophin. There was no evidence of uncontrolled donor cell division or tumour formation on Ki67 staining.

The outer nuclear layer was intact over the patch at 2 hours, 2 days 1, 2 and 6 weeks. Inner and outer photoreceptor segments could be identified at the earlier time points. In the 3 control eyes that received substrate without cells, there was loss of the outer nuclear layer over the graft. Strong GFAP reactivity was present at every time point, even at 2 hours postoperatively.

#### **6.4.5 Immunological and inflammatory response**

Inflammatory response was characterized by the predominant presence of macrophages adjacent to the patches. At 2 hour post-surgery, macrophage was not detected. By 2 days, there were occasional small autofluorescent (yellow/red) cells. Some of these reacted with anti-porcine macrophage antibody (see **Figure 6.2**). By 7 days, there were some larger, rounded pigment-laden cells on the patches as well as the smaller autofluorescent cells. These pigmented cells did not stain with CRALBP or RPE65 and were occasionally faintly autofluorescent but did not react with the anti-porcine macrophage antibody that is available. Electron microscopy These cells were present at all time points from 7 days postoperatively. Small autofluorescent macrophages were also present in animals which received the patch implant without hESC-RPE.

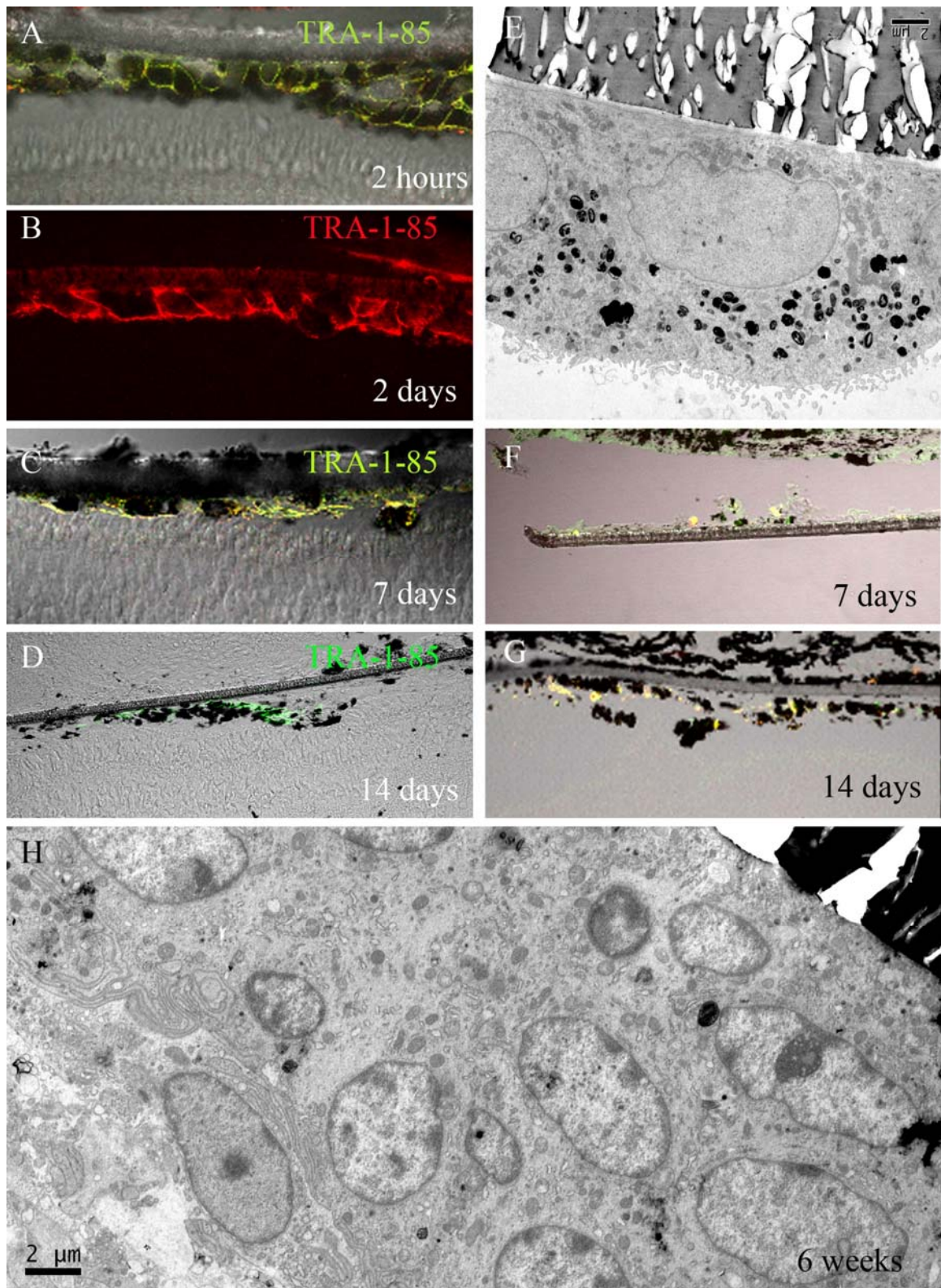
CD8-positive (cytotoxic T) cells were detected in 3 animals; they were present in the neural retina in one; at 2 weeks, and in the choroid in another at 6 weeks. This animal also had multinucleated giant cells (see **Figure 6.3**). CD8-positive cells were also detected in other animals but did not show evidence of retinal infiltration or vascular cuffing. CD4-positive (T helper) cells were also detected in 2 animals both at the 2 weeks time point. In the same animals, CD79-positive cells (B lymphocytes) were also detected in the neurosensory retina (see **Figure 6.4**).

**Table 6.5 Pig experiment: summary of cell survival and immune reaction**

Time	Pig No.	CYA given	Location of the graft in section	Human cells	Macrophage-like cells	Lymphocytes infiltrates
2 hours	11	-	SR	+	-	-
2 days	13	+	SR	+	SA	CD8
	22	-	SR, Lost	N/A	N/A	N/A
7 days	18*	-	No graft	-	-	-
	20**	-	SR	-	SA	-
	15	+	VC	-	LP	-
	14	-	SR	+	SA, LP	-
2 weeks	19*	-	No graft	-	N/A	N/A
	21**	-	SR	-	N/A	N/A
	17	+	SR	-	SA, M	CD4, CD79‡
	12	-	SR	+	LP	CD4, CD8, CD79‡
4 weeks	1**	+	SR	-	N/A	N/A
	3**	+	SR	-	N/A	N/A
	2	+	SR	N/A	N/A	N/A
6 weeks	4***	+	VC	N/A	N/A	N/A
	5***	-	SR	N/A	SA, M	N/A
	7	+	SR	+	N/A	N/A
	9	+	SR	N/A	M	N/A
	6	-	SR	N/A	SA, LP, M	N/A
	8	-	SR	+	LP, M	CD8†

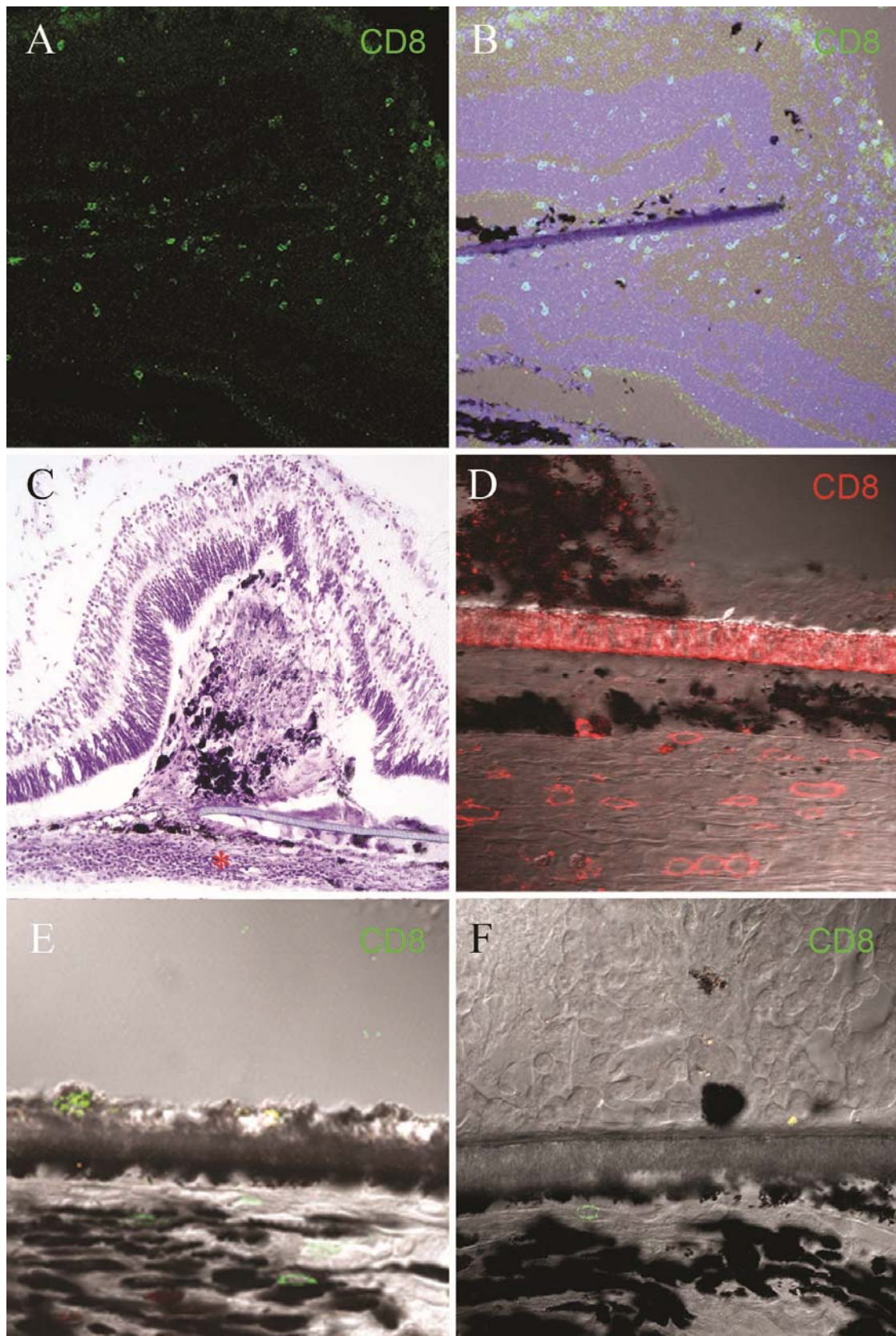
SA, small autofluorescent macrophage-like cells; LP, large pigmented macrophage-like cells; M, macrophage that reacted with specific macrophage antibodies; N/A, not available; SR; subretinal, VC; vitreous cavity, +; yes, -; no.

\* control animals with bleb detachment only; \*\* control animals with sham patch; \*\*\* control animals with sham patch with fibroblast; † located in choroid, ‡ located in retina



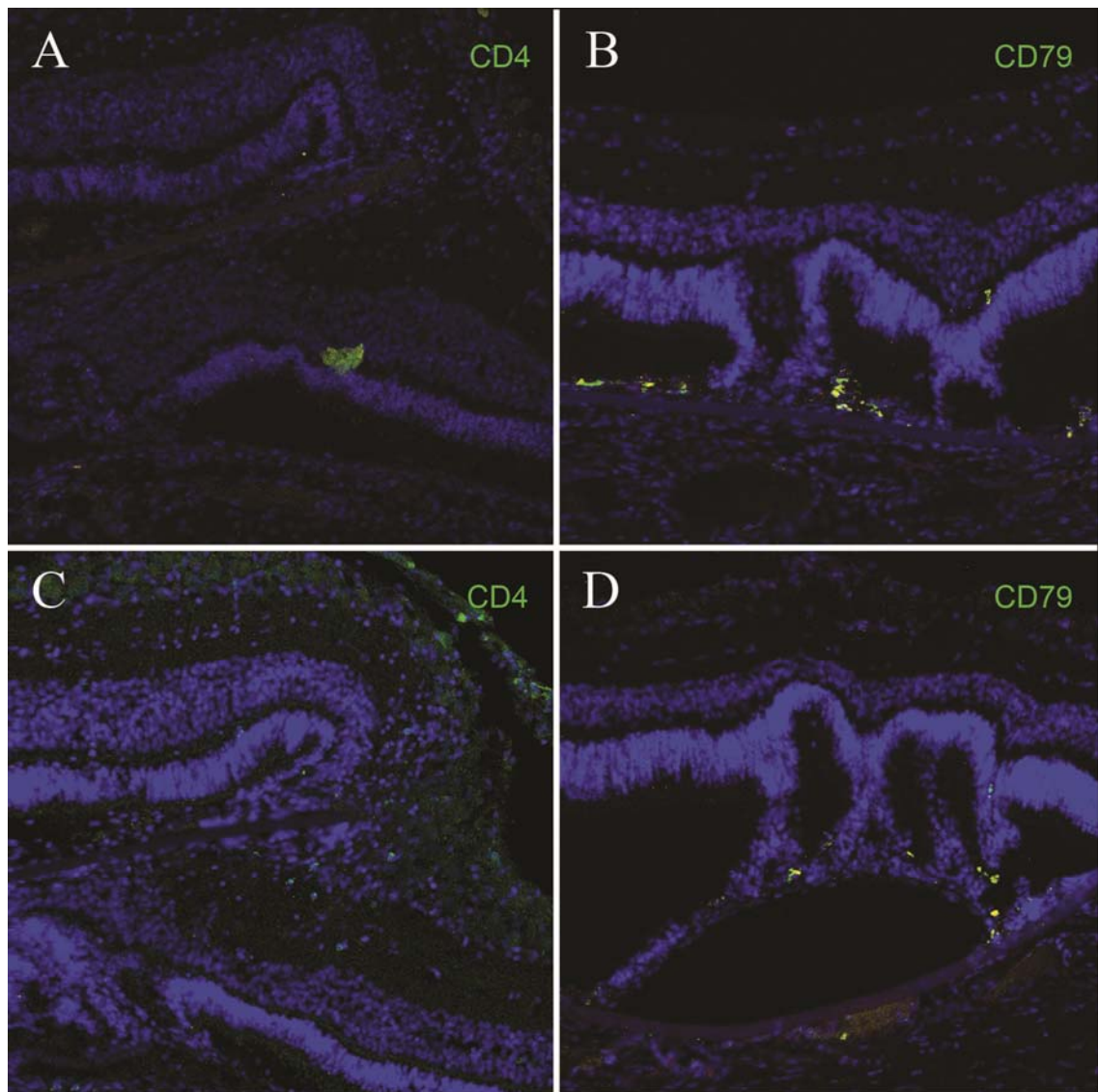
**Figure 6.2 Cell survival and inflammatory response**

Pigmented human cells are found (FITC or TRITC) on polyester substrate at (A) 2 hours, (B) 2 days, (C) 7 days and (D) 14 days. (E) These human pigmented cells appear to be polarized with apical microvilli on electron microscopy. Small autofluorescent cells (probably host macrophages) are found in eyes which received (F) polyester substrate alone and (G) human cells on substrate at 14 days. (H) At 6 weeks, large multinucleated giant cells were seen adjacent to the substrate on electron microscopy.



**Figure 6.3 CD8-positive cells**

CD8-positive (cytotoxic) T cells were detected in (A, B) the retina in one animal at 2 weeks (FITC) and in (C, D) the choroid (marked with red asterix) in one animal at 6 weeks (TRITC). There were also occasional CD8-positive cells in other animals detected at (E) 2 days and (F) 2 weeks (FITC).



**Figure 6.4 CD4-positive and CD79-positive cells**

CD4-positive (helper) T cells were detected (FITC) in the retina at 2 weeks in (A) a non-immunosuppressed and (B) an immunosuppressed animal. CD79-positive (B) cells were detected (FITC) in the retina at 2 weeks in (A) a non-immunosuppressed and (B) an immunosuppressed animal.

## 6.5 Discussion

In animal experimental studies and human clinical trials, replacement of diseased RPE or RPE defect by cell transplantation has been shown to restore and maintain visual function (Li and Turner 1988a; Machemer and Steinhorst 1993; van Meurs and Van Den Biesen 2003). However, the potential benefits of current techniques of RPE reconstruction are overshadowed by their complexity, use of aged RPE cells that may carry genetic mutation, and the high post-operative complication rates (see **Chapters 4**

**and 5).** To enable simpler and safer surgical approach in reconstructing the RPE, sources other than autologous RPE need to be explored.

Previous studies have demonstrated outer nuclear layer and visual function rescue with no signs of early graft rejection using hESC-RPE cell suspension in immuno-suppressed RCS rats and ELOVL4 mice (Lu *et al.* 2009; Lund *et al.* 2006; Vugler *et al.* 2008). However, hESC-RPE cell suspension injection in human will not be successful due to poor adhesion and anoikis of the RPE on aged and damaged Bruch's membrane (Del Priore and Tezel 1998; Tezel *et al.* 1999; Tezel *et al.* 2004). Therefore, a series of experiments was designed to explore feasibility and outcomes of delivering hESC-RPE as a monolayer supported by an artificial substrate into the subretinal space of a pig eye. The pig eye was chosen because of its anatomical similarity to the human eye (large vitreous cavity relative to the lens), thus allowing the use of current standard vitreo-retinal surgical instruments.

The results showed that subretinal transplantation of patch graft is feasible with low complication rates. Donor cells can survive for up to 6 weeks although there is significant loss of cells at the time of transplantation and 1-2 weeks after surgery. Loss of donor cells was accompanied by increasing number of large pigmented cells and small autofluorescent host macrophage.

### **6.5.1 Feasibility and safety of hESC-RPE graft in porcine model**

The pig has been used as a model for subretinal transplantation of allogeneic anterior lens capsule (Nicolini *et al.* 2000; Kiilgaard *et al.* 2002), allogeneic retinal progenitor cells (Warfvinge *et al.* 2005; Warfvinge *et al.* 2006; Klassen *et al.* 2007; Klassen *et al.* 2008), allogeneic full-thickness neuroretinal sheet (Ghosh and Arner 2002; Ghosh *et al.* 2004; Engelsberg and Ghosh 2007; Ghosh *et al.* 2007), allogeneic porcine RPE sheets (Del Priore *et al.* 2004), autologous porcine RPE-choroid grafts (Lane *et al.* 1989; Maaijwee *et al.* 2007b), and implantation of retinal prosthesis (Schwahn *et al.* 2001; Montezuma *et al.* 2006; Gekeler *et al.* 2007). However, delivery of hESC-RPE into porcine eye using modern vitreoretinal surgical instruments has not been reported. Therefore, feasibility and safety of patch graft delivery into the subretinal space were considered to be important outcome measures.

#### **6.5.1.1 Feasibility of hESC-RPE delivery technique**

The standard vitrectomy technique was feasible in the porcine eye. However, canthotomy and tissue retractors were necessary for pars plana access due to the small



palpebral fissure and the stiff eyelids in these 2-3 month old animals. Similar to previous reports, the current series of experiments demonstrated the feasibility of pars plana vitrectomy, creation of bleb retinal detachment and enlargement of the retinotomy in the porcine eye. Future studies will need to explore the use of viscoelastic substance to maintain the subretinal space while the graft is inserted through the retinotomy.

Although these experiments demonstrated the possibility of creating a small 1 x 3 mm patch graft from a modified Transwell® Insert with a simple punch device and delivering the patch into the subretinal space using a pair of commercially available intraocular forceps, there was significant loss of pigmented cells during these processes.

Loss of donor RPE cells may have occurred during the these 6 stages of the procedure: (1) removal of the polyester membrane from the Transwell® Insert, (2) punching of the graft from the membrane, (3) grasping of the patch graft by forceps, (4) insertion of the graft into the eye through a sclerostomy, (5) exposure of the graft to fluid current within the vitreous cavity and (6) insertion of the graft into the subretinal space through a retinotomy. It is likely that these sequential and cumulative insults to the patch graft contributed to the visible movement of the pigmented cells over the graft during insertion of the patch into the retinotomy. Furthermore, a third (4 of 12) of these grafts lost almost all pigmented cells.

There are 2 ways to reduce donor cell loss during transfer and delivery of the graft. Firstly, the patch can be preloaded on a device (i.e. cells cultured on a substrate that is already prepackaged as part of the delivery device) which also protects the hESC-RPE during passage of the graft through the sclerostomy, vitreous cavity and retinotomy. The handle of the delivery device will also need to occlude the sclerostomy port to prevent leak and hence fluid current within the vitreous cavity. Secondly, the strength of hESC-RPE adhesion to the substrate can be enhanced by coating the substrate with adhesion molecules (such as laminin, collagen and fibronectin) in optimised concentrations. There are relatively few surgical tools designed for delivery of sheets of cells into the subretinal space in comparison to the number of surgical instruments described for the purpose of removing subretinal tissue and subretinal injection of cell suspensions (Ghosh and Arner 2002; Aramant and Seiler 2002; van Meurs and Van Den Biesen 2003; Del Priore *et al.* 2004; Maaijwee *et al.* 2008b; Thumann *et al.* 2006). However, none of these devices would be suitable for the purpose of patch graft delivery since they do not offer protection of the graft during insertion through the sclerostomy and retinotomy and they are unable to deliver large grafts which will be necessary in human transplantation. The hESC-RPE used in this

study has been shown to produce essential components of basal lamina such as collagen IV, laminin and fibronectin similar to mature RPE *in vivo* (Vugler *et al.* 2008). Further work is required to determine if modification of substrate coating may enhance adhesion of these cells to the polyester substrate.

#### 6.5.1.2 Postoperative complications

Despite the absence of retinopexy around the retinotomy and the use of air as tamponade, only 1 of 20 animals developed a rhegmatogenous retinal detachment. The 5% rate may be an underestimate since 9 of 21 animals were followed for more than 4 weeks. In the animal with rhegmatogenous detachment, the retinotomy was open with pre-retinal fibrotic reactions simulating proliferative vitreoretinopathy.

The true rate of detachment following hESC-RPE patch graft is probably higher than previous porcine transplantation studies which reported detachment rates of: 3% (1 of 38 eyes) in 4-6 months old normal domestic pigs that received allogeneic RPE encased in gelatine (Del Priore *et al.* 2004), 8% (2 of 24 eyes) in 1.5-3 months old normal Yorkshire/Hampshire pigs that received neuroretinal sheet (Ghosh and Arner 2002; Engelsberg and Ghosh 2007) and 0% (none of the 75 eyes) in 3-4 months old normal Danish Landrace pigs that received retinal progenitor cell suspensions (Warfvinge *et al.* 2005; Warfvinge *et al.* 2006; Klassen *et al.* 2007; Klassen *et al.* 2008). The higher rate of detachment in patch grafting may be related to the large retinotomy and could be reduced if retinopexy is applied and longer-acting tamponade is used.

#### 6.5.2 hESC-RPE cell survival and photoreceptor cell rescue

Similar to a previous study in the RCS rat, this experiment showed that human cells can survive for 6 weeks *in vivo* but they are detected in only 50% of the animals that received hESC-RPE (Vugler *et al.* 2008). Survival was not related to the use of cyclosporine. Loss of donor cell in the subretinal space occurred after 1-2 weeks coinciding with the onset of macrophage infiltration (see below). There was no evidence of continuing cell division to suggest teratoma formation in any of the 20 animals.

The substrate used to support hESC-RPE remained flat and did not fold in the subretinal space unlike other supporting materials used for RPE cell sheet grafts (Nicolini *et al.* 2000; Del Priore *et al.* 2004). In the majority of animals, the substrate was located in the subretinal space, separating the host RPE from the neuroretina. Migration of patch out of the retinotomy occurred in 3 animals. This is likely to have occurred soon after surgery due to short duration of tamponade by air and lack of

retinopexy at the retinotomy. The polyester substrate used in this study is already compliant with the current Good Manufacturing Practices and can be readily used in human.

Photoreceptor rescue was demonstrated over the patch graft that had hESC-RPE but not over sham grafts (i.e. without hESC-RPE). It cannot be assumed that this observation translates to functional rescue by hESC-RPE. Further studies using multifocal ERG recordings to examine localised retinal function (Kyhn M.V. *et al.* 2007) or immunohistochemical technique to detect light induced nuclear expression of c-Fos in the inner nuclear layer (Carr *et al.* 2009b) may provide further information on whether hESC-RPE transplant and lead to functional rescue in a porcine model.

### **6.5.3 Inflammatory and immunological response**

At 2 hours and 2 days after graft, there were no signs of inflammatory reaction. However, by 1 week, there were small autofluorescent pigmented host macrophages in both control/sham patch and hESC-RPE grafted eyes. By 2 weeks, larger pigmented host non-RPE cells were present. These are likely to represent macrophages which have phagocytosed donor cells since these cells are not seen in eyes which did not receive hESC-RPE. Lymphocytic infiltrate was not a prominent feature although in some animals, CD8-positive (cytotoxic) and CD4-positive (helper) T cells were seen in the neuroretina or choroid of eyes that received hESC-RPE from 2 weeks postoperatively. Similarly, CD79-positive (B) cells were also seen within the neuroretina.

These observations are similar to that reported previously in allo- and xeno-transplantation into non-immunosuppressed animals. Del Priore *et al.* (2004) demonstrated predominant presence of macrophage-like cells in the subretinal space from 9 days after porcine allogeneic RPE graft. Grisanti *et al.* (2002) demonstrated large pigmented ED-1 positive cells within the neuroretina of RCS rats at 12 weeks after receiving fresh porcine RPE suspension. They also did not detect a prominent lymphocytic response unlike the animals which received subcutaneous or anterior chamber xenografts. Despite oral cyclosporine, a similar macrophage response was seen even in eyes which only received sham patch. The following section describes a possible sequence of event that leads rejection of the hESC-RPE.

Surgical trauma of vitrectomy and disruption of the blood retinal barrier by retinotomy may activate and induce migration of macrophage into the subretinal space. These macrophages may be derived from microglial cells residing within the neural retina or circulating monocytes from the blood. The former is more likely in the light of

a recent report which showed that autofluorescent perivascular cells in the retina have scavenger activity and may be important in maintaining blood retinal barrier (Mendes-Jorge *et al.* 2009). The subretinal space displays features of an immunoprivileged site which includes protection of allograft from rejection and induction of systemic immune deviation to antigens placed at the site (Streilein *et al.* 2002). However, this is not absolute, particularly in the setting of surgical injury and, more relevant, disease such as AMD. Compounding the unfavourable subretinal environment, hESC-RPE itself as a tissue may not have absolute immune privilege. Studies on undifferentiated hESC showed that they may be relatively immune privileged with no HLA class II expression and low levels of HLA class I and co-stimulatory molecules (Drukker *et al.* 2002; Li *et al.* 2004; Grinnemo *et al.* 2006; Robertson *et al.* 2007). However, differentiated hESC-RPE can express HLA class I and induced to express HLA class II molecules by interferon gamma. The combination of subretinal macrophage and activation of hESC-RPE by cytokines released during surgical trauma may lead to cell-mediated or cytotoxic immune reaction, as demonstrated by the presence of CD8-positive T cells, and eventual hESC-RPE rejection.

The finding of a predominantly macrophage response without lymphocytic infiltrate is encouraging. This is because inhibition of macrophage response can be achieved pharmacologically using glucocorticoid-type agents and antimicrobial drugs such as rifampicin or tetracyclines which may directly act on these scavengers (Zetterlund *et al.* 1998; Mlambo and Sigola 2003; Yrjanheikki *et al.* 1998). Although cyclosporine alone did not prevent donor cell loss, it may have a role in enhancing anti-macrophage effect of glucocorticoid-like agents by suppressing subsequent cell-mediated immune responses.

#### **6.5.4 Implications for future directions in hESC-RPE graft surgery**

The porcine experiments have provided some evidence of feasibility in using hESC-RPE to reconstruct submacular RPE in a clinical setting. However, there remain 3 major challenges to overcome before the current hESC-RPE grafting technique can be translated into clinical practice. These are (1) the low efficiency of producing a pure population of mature or well differentiated RPE from hESC, (2) the trauma to the cells on the graft during creation of the patch, transfer and implantation of the graft into the subretinal space and (3) loss of hESC-RPE associated with macrophage infiltration. In order to understand the requirements for further animal studies in refining the technique of subretinal hESC-RPE graft, it is critical to take a step back to examine the

translational research route map that has been set out by the various Competent Authorities which issue licenses, and monitor and regulate the institutions involved in this type of experiment to ensure compliance with the EU Directives.

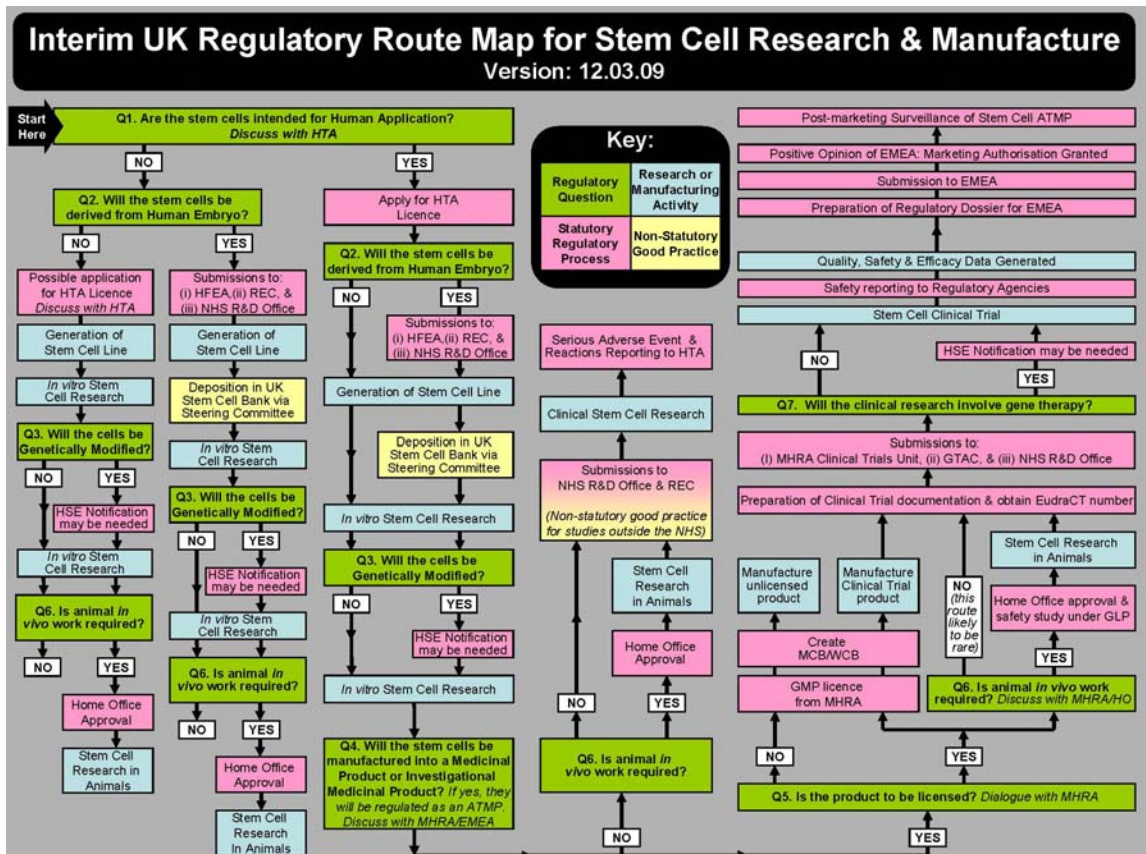
Human ESC-derived tissue or cells for clinical use is considered as an Advanced Therapy Medicinal Product (ATMP) under the Medicines and Healthcare products Regulatory Agency (MHRA) of the British Government. The Regulations that govern ATMP came into force on 30<sup>th</sup> December 2007 and was applied from 30<sup>th</sup> December 2008 (EC 1394/2007). The new regulatory framework considers that the Human Tissue Authority (HTA) has the role of regulating the donation, procurement and testing of tissue and cells that are to be used as ATMP. The MHRA (Competent Authority for medicinal products and medical devices), however, is responsible for the subsequent stages of ATMP development, including manufacturing, storage, distribution, clinical trials and pharmacovigilance. The key requirements for translation of the current use of hESC-RPE in animal studies into a phase I clinical trial of hESC-RPE transplantation can be broadly classified into 2 areas as suggested by the Gene Therapy Advisory Committee (GTAC) of the Department of Health (see **Figure 6.5**): (1) statutory regulatory processes (**Section 6.5.4.1**) and (2) research or manufacturing activity (**Section 6.5.4.2**).

#### 6.5.4.1 Statutory regulatory processes

Even before the hESC could be considered to be used for derivation of RPE and clinical transplantation, several statutory regulatory processes have already begun. The Human Fertilisation and Embryology Authority (HFEA) would have given licence to clinics which carry out human embryo research and storage. Once the stem cells are harvested from embryo for the intention of human application, a licence from HTA would have been required for derivation and storage of the specific tissues or cells. If genetic modifications of these cells are required, the Health & Safety Executive (HSE) will also need to be notified.

When the hESC-RPE is to be considered as a licensed medicinal product, it will be treated as an ATMP under the MHRA. The definition of ATMP given by HTA is as follows:

“ATMPs are innovative, regenerative therapies which combine aspects of medicine, cell biology, science and engineering for the purpose of regenerating, repairing or replacing damaged tissue/cells.”



**Figure 6.5 Interim UK regulatory route map for stem cell research**

This route map is taken from the Gene Therapy Advisory Committee website (<http://www.dh.gov.uk/ab/GTAC/index.htm>) posted in March 2009. This reference tool has been developed by the Department of Health with the support of the Gene Therapy Advisory Committee, Health & Safety Executive, Home Office, Human Fertilisation & Embryology Authority, Human Tissue Authority, Medicines & Healthcare products Regulatory Agency, Medical Research Council, NHS Blood & Transplant Authority, Scottish National Blood Transfusion Service, Advisory Committee on the Safety of Blood, Tissues & Organs, & the UK Stem Cell Bank. Abbreviations: ATMP; Advanced Therapy Medicinal Product, EMEA; European Medicines Evaluation Agency, GM; genetic modification, GTAC; Gene Therapy Advisory Committee, GLP; Good Laboratory Practice, GMP; Good Manufacturing Practice, HSE; Health & Safety Executive, HO; Home Office, HTA; Human Tissue Authority, HFEA; Human Fertilisation and Embryology Authority, IMP; Investigational Medicinal Product, MCB; Master Cell Bank, MP; Medicinal Product, MHRA; Medicines and Healthcare products Regulatory Agency, REC; Research Ethics Committee, WCB; Working Cell Bank.

The process of approval for hESC-RPE as an ATMP is likely to involve several parallel steps including (1) animal *in vivo* experiments under conditions of GLP which will also require approval from the Home Office of UK, (2) obtaining a GMP Licence to create a master cell bank and working cell bank and (3) preparation of clinical trial documentation and obtain a clinical trial number.

The porcine experiment may be used as a model for the animal *in vivo* experiment if the MHRA requires further animal studies to ensure safety and efficacy. It may be sufficient to use the RCS rat model to demonstrate efficacy of hESC-RPE in photoreceptor cell rescue since there is currently no known porcine model of RPE dystrophy. Laser or chemical ablation of the RPE in the porcine eye is likely to cause concurrent photoreceptor cell loss and therefore is not a suitable model. The use of sham patch may be adequate to serve as controls providing the host RPE do not grow over the substrate.

The autologous RPE trials described in **Chapter 4** may also form the basis for the initial phase I clinical trial. Using similar outcome measures, this initial study can determine the safety and efficacy of hESC-RPE transplantation. The additional requirements for a phase I hESC-RPE transplantation clinical trial are: (1) MHRA application for the use of ATMP, (2) a EudraCT number for the investigation of a medicinal product and compliance with EU Directive 2001/20/EC and (3) application to GTAC (instead of the local research ethics committee). HSE notification may also be required if genetically modified cells are used.

#### 6.5.4.2 Research and manufacturing activity

In parallel with the statutory regulatory processes, research and manufacturing activities need to occur to ensure the success of translating stem cell therapy into the clinics. Much work has been done in refining the protocol of generating RPE-like cells from various hESC lines.

Several groups have now reported derivation of cells resembling RPE from hESCs (Klimanskaya *et al.* 2004; Lund *et al.* 2006; Lu *et al.* 2009; Vugler *et al.* 2008; Carr *et al.* 2009a; Gong *et al.* 2008; Osakada *et al.* 2009; Idelson *et al.* 2009). These RPE-like cells (hESC-RPE) have been shown to form a pigmented hexagonal monolayer, expressing epithelial and junctional markers, enzymes required for visual cycle, ion channels, RPE-specific transcriptional and growth factors, and retinaldehyde-binding and melanosome-associated proteins. They have also been shown to be more similar to mature adult RPE than existing RPE cell lines such as ARPE-19 and foetal

RPE cells (Lu *et al.* 2009; Carr *et al.* 2009a). *In vitro* stem cell research is critical but alone, is not enough to provide information required for translation into clinical use. There are now several publications which have begun to address the issues of safety and efficacy of hESC-RPE transplantation in animals. *In vivo* data are likely to be critical for licensing of hESC-RPE as an ATMP by the MHRA.

Animal studies have shown that hESC-RPE can also phagocytose photoreceptor outer segments after subretinal transplantation (Lund *et al.* 2006; Vugler *et al.* 2008; Carr *et al.* 2009a; Idelson *et al.* 2009). Furthermore, visual function was rescued in the RCS rat and possibly in the *Elovl4* mice (human orthologues are found in retinitis pigmentosa and Stargardt's disease, respectively) after GMP or non-GMP compliant hESC-RPE transplantation (Lund *et al.* 2006; Lu *et al.* 2009; Vugler *et al.* 2008; Idelson *et al.* 2009). In animal studies, hESC-RPE has been shown to survive in rats for up to 30 weeks without tumour formation (Vugler *et al.* 2008; Lu *et al.* 2009). The work from this thesis also demonstrated that hESC-RPE can also survive in xenogeneic setting using a porcine animal model. Importantly, none of the animal studies (including NIH III immune deficient mice) to date have reported tumour formation from the transplanted hESC-RPE.

Despite the various protocols that have been reported to derive RPE from hESC, this remains an inefficient process. Some of the hESC may remain in undifferentiated state and some differentiated hESC are less pigmented than mature RPE. This variable maturation of hESC-RPE poses 2 problems: low yield of well-differentiated RPE production and contamination by potentially tumorigenic hESC. Further understanding of embryogenesis of the RPE will help to identify nutritional and growth factors (e.g. nicotinamide and Activin A) that may enhance the rate and proportion hESC becoming pigmented (Idelson *et al.* 2009). Isolation of pigmented cells from non-pigmented hESC derivative is currently performed mechanically. This may lead to contamination of the cells chosen for transplantation by undifferentiated hESC. The use of magnetic-activated or fluorescence activated cell sorting may improve purity of pigmented cell harvesting (Fong *et al.* 2009). Further work in these areas is currently underway.

Having produced the hESC-RPE patch graft with high efficiency and minimal hESC contamination, the aim will be to deliver this into the subretinal space with minimal loss of the donor cell and the least damage to host photoreceptor cells and RPE. There are 2 approaches to delivery hESC-RPE: suspension injection or patch graft insertion. The use of suspension subretinal injection will only be feasible at an earlier stage of macular disease when the BM is not damaged (Francis *et al.* 2009). This is an



unlikely situation for a phase I clinical trial of hESC-RPE transplantation. The initial trial will most likely to involve patients with large RPE tears where there is no underlying BM for cell attachment. In this situation, a customised delivery device will be needed to protect the graft from damage during insertion through the sclerostomy and retinotomy. Results from the porcine experiments demonstrated that a pair of intra-ocular forceps is inadequate to protect the cells since many of the hESC-RPE were lost or shifted when the graft was placed in the subretinal space. A new delivery device incorporating a protective covering is currently being developed. Further *in vitro* and *in vivo* work will be required to validate this new delivery system.

Once the graft is placed in the subretinal space with minimal loss of the donor cells, survival of hESC-RPE is under threat by the host immune system. The data presented in this chapter indicated that macrophage infiltration is likely to be responsible for the loss of donor cells. Further *in vivo* work is required to demonstrate that an alternative immunosuppressive and anti-inflammatory regime can stop the macrophage activation and allow longer term survival of the grafted cells. There is now some evidence that high dose systemic steroid can prolong hESC-RPE survival in the RCS rat model (unpublished results). Further studies in the porcine model are currently underway.

#### **6.5.5 Strengths and limitations of the study**

The main strength of the animal experiment was its prospective design and the consistency in methodology. For example, all surgical procedures were performed by the same experienced surgeon (Mr L. Da Cruz) using the same vitrectomy machine and surgical instruments. The surgeon has the experience in patch grafting as he has previously performed a similar surgical procedure in 18 human subjects with atrophic or neovascular macular disease (see **Chapters 4 and 5**). All animals were cared for by the same staff at the same research institution and given the same postoperative eye drops. All enucleations were performed by the author using the same technique and all tissue processing and staining were performed by Drs Lawrence and Ahmado.

One of the limitations of this study was the sequential nature of 4 separate animal experiments at different times (December 2007, then April, November and December 2008). From the outcomes of the initial feasibility study (3 animals terminated at 4 weeks), a medium-term (6 animals terminated at 6 week) study was designed and conducted 3 months later. However, the low cell survival rate at 6 weeks led to 2 other separate studies designed to examine the early (< 2 weeks) cell survival

and immunological reactions to hESC-RPE (8 animals) versus sham (4 animals) transplantation. Such study design was necessary due to the the high cost of porcine experiment and the unexpected death of one animal. This study design is unlikely to significantly confound the outcome of the study since the same methodology was used.

The animal studies were also limited by the learning curve involved in tissue processing and immunohistochemical staining. Unlike rodent or rabbit eyes, the porcine eye is not familiar to most ophthalmic laboratory scientists. It has a thick and tough scleral coat making gross dissection difficult. Bisection of the posterior eye-cup induced artefactual retinal detachment and shifting of the patch graft. This processing artefact may have been minimised if the entire graft was used for either immuno-histochemistry or electron microscopy, but not both. The thickness of the sclera also posed difficulty during cryosectioning with excessive force required to cut the sclera accompanied by crush artefact in the adjacent neuroretina. In eyes which only had bleb detachment without graft, it was difficult to determine for certain, the site of detachment after fixation. This may have been facilitated by comparing the image from intraoperative video clip with vascular features of the posterior eye cup on gross examination.

Other limitations of the immunological techniques used in this study were (1) the restriction to the use of primary antibodies that were raised in mice and (2) the limited availability of antibodies against porcine immune cells. It was necessary to use the same secondary antibody for restaining RPE markers after human cell marker stain in separate sessions by removing and replacing the cover slip. This was necessary because both human cell (TRA-1-85) and RPE (CRALBP, Bestrophin and RPE65) markers were raised in mice. The same technique was also necessary for concurrently staining for Ki-67 (proliferative cells), porcine CD79 (B cells), porcine CD8 (cytotoxic T cells) or porcine CD4 (T helper cells) antigens. Inflammatory and immunological responses were studied by staining for macrophage and lymphocytes. The primary antibodies for these cells have not been used previously and therefore it was not possible to determine the specificity and sensitivity of these antibodies at their respective dilutions. The lack of lymphocytic infiltrate and the occasional staining of CD4-positive and CD8-positive cells in perivascular and choroidal regions suggest that strong immunological reaction was not present. However, such immunohistochemical techniques were unable to rule out a specific immune response to human cells. Even if immunological response was present in a xenograft model of human cell to porcine recipient transplantation, this may not reflect what will happen in a human to human allogenic setting.

Functional rescue was not an outcome measure in this study. During the course of the experiments, a prototype focal ERG set up was used to record ERG responses to flash and flicker light stimuli. Due to the internal reflections, it was found that corneal ERG recording was unable to distinguish focal white light stimulation on the disc from that on the retina using an intraocular light source. Multifocal ERG set up was not available and it was not known if c-Fos expression is induced by light stimulation in the porcine eye. Further studies are required to confirm anatomical rescue of outer nuclear layer translated to functional rescue.

### **6.5.6 Conclusions**

Using currently available vitreoretinal surgical instruments, it was possible to deliver hESC-RPE as a patch graft into the subretinal space. However, significant donor cell loss occurred during the process of creating the patch from the Transwell® Insert, transfer of the patch to the eye, and delivery of the graft into the subretinal space. Human RPE cells derived from Shef-1 can survive in the porcine subretinal space for up to 6 weeks. However, loss of donor cell coincided with macrophage response at 1-2 weeks. There was minimal lymphocytic response and no evidence of tumour formation. These results suggest that donor cell survival may be enhanced by the use of (1) peri-operative anti-inflammatory agents such as dexamethasone to prevent macrophage activation and migration, and (2) specialised protective delivery device that has been preloaded with the correct size of hESC-RPE patch graft.

### **6.6 Contribution**

Author's contribution to the work presented in this chapter are summarised in **Table 6.6**. During the course of these experiments, the author also collaborated in further studies examining the feasibility of focal electro-retinography using intra-ocular probe to stimulate the retina in an anaesthetised pig as a way to measure functional rescue by hESC-RPE patch graft. In order to analyse immunological response to transplanted hESC-RPE, the author also suggested to the research group the use of flow cytometric methods to allow multiparametric detection of cell surface antigens and intracellular cytokine expression of porcine T cells in response to human antigen stimulus. Thus peripheral blood and vitreous samples were also obtained from all animals for the study of adaptive T cell immune response. The author also initially suggested a novel in vitro assay for testing phagocytic ability of hESC-RPE by using surplus retina harvested during human autologous RPE-choroid patch graft surgery (see **Appendix 1**).

**Table 6.6 Contribution list for the human to porcine xenotransplantation studies**

Contribution category	Contributor (details)
1	<p>Conception and design <b>Author:</b> <u>contributed to the design of the animal experiment, in particular the post-operative care and tissue/blood/vitreous sampling.</u> PJC: wrote the animal study ethics protocol. LDC: approval the research protocol.</p> <p>Data acquisition <b>Author:</b> <u>assisted in all surgical procedures and examined all 21 animals following transplant. Also obtained vitreous samples and enucleated all globes and transported them to the UCL Institute of Ophthalmology.</u> LDC: performed all surgical procedures. JML: dissected the globe and performed cryosection, immunostaining, and electron microscopy. AA: prepared the patch grafts preoperatively and dissected the enucleated globe and obtained photographs of the fundus.</p> <p>Data analysis and interpretation <b>Author:</b> <u>collated, analysed and interpreted the intraoperative, postoperative and histological data.</u> LDC: supervised interpretation of results. PJC: supervised statistical analysis. JML: supervised interpretation of results.</p>
2	<p>Writing <b>Author:</b> <u>wrote the entire chapter.</u></p> <p>Revising <b>Author:</b> <u>revised the entire chapter.</u> LDC: read the chapter and made suggestions. PJC: read the chapter and made suggestions. JML: read the chapter and made suggestions.</p>
3	<p>Statistical analysis <b>Author:</b> <u>performed all statistical analysis.</u></p> <p>Funding PJC and LDC: obtained funding for the London Project to Cure Blindness.</p> <p>Administrative and technical support <b>Author:</b> <u>arranged delivery of operating microscope and specialised vitrectomy surgical equipments, and coordinated availability of vitrectomy technician with surgeon and the vet. Also created all the figure montage from the images obtained from histology and fundus photography.</u> PJC: liased with Northwick Park Institute of Medical Research. KC: liased with Northwick Park Institute of Medical Research in ordering animals and providing anaesthetic support and animal husbandary.</p>

AA; Ahmad Ahmado (PhD student), KC; Karen Cheetham (UCL Business), JML; Jean M Lawrence (senior scientist), LDC; Lyndon Da Cruz (supervisor), PJC; Peter J Coffey (supervisor).

# **Chapter 7**

## **Conclusions**

## 7.1 Original aims

This thesis aimed to (1) examine whether long-term photoreceptor cell function can be rescued by RPE transplantation in atrophic and neovascular macular diseases and (2) to determine the feasibility of subretinal transplantation of RPE derived from hESC in a porcine model. In the following sections, the key findings from **Chapters 4, 5 and 6** are described, the strengths and limitations of the studies are summarised and the future road map for translational research in RPE transplantation is outlined.

## 7.2 Summary of key findings and implications

**Chapter 4** of the thesis demonstrated that it is possible to maintain retinal function by autologous transplantation of RPE-choroid patch graft in patients with atrophic macular disease. However, the choice of patients with advanced disease, the use of diseased autologous RPE and the high operative complication rates may explain the overall poor visual outcomes. Therefore, autologous RPE-choroid graft as a therapeutic approach for these patients cannot be recommended.

In **Chapter 5**, the long-term outcomes of RPE reconstruction, using translocation and autologous patch graft techniques, in neovascular disease were analysed. Although both types of approaches were shown to rescue and maintain high quality foveal function, long-term data suggest translocation was able to achieve superior quality of vision compared to patch graft in this cohort of patients. However, both techniques had significant rates of early post-operative complications and sight threatening late recurrence of CNV. In conjunction with the results presented in **Chapter 4**, these findings suggest that a simpler surgical approach using non-autologous source of RPE need to be developed. This may enable clinical RPE transplantation to be performed on a much larger scale.

Following from the conclusions of **Chapters 4 and 5**, **Chapter 6** examined the feasibility, cell survival and inflammatory reactions of subretinal transplantation of hESC-RPE on an artificial substrate using the porcine eye as a pre-clinical model. The surgical technique described was feasible although significant donor cell loss occurred during transfer and delivery of the graft. Human RPE cells survived in the porcine subretinal space for up to 6 weeks. However, there was substantial donor cell loss accompanied by macrophage infiltration. There was no evidence of tumour formation or significant lymphocytic infiltrate. The implications from this study are: (1) manufacturing processes needs to be optimised to obtain the highest yield and purity of hESC-RPE, (2) a surgical tool that can minimise cell loss during subretinal delivery of

the patch graft will need to be developed and (3) the anti-inflammatory regime will need to be optimised to enhance cell survival and prevent macrophage activity against donor cells.

### **7.3 Appraisal of strengths and limitations**

#### **7.3.1 Strengths of the Thesis**

The main strength of this work was the prospective design of the human clinical trials and the animal experimental studies as described in **Chapters 4 and 6**. This design enabled collection of a wide range of outcome measures and allowed detailed structure-function correlation in the autologous graft trials. The porcine experiment was initially designed as a pilot study of 3 animals. The results from this first study were critical for designing of further long-term and short-term animal experiments. The sequential experiments helped to reduce the number of animal needed to answer the questions of cell survival and immunological reaction.

The main strength of the work described in **Chapter 5** was the inclusion of consecutive patients who have undergone surgery for neovascular AMD and the long duration of regular follow-up. Furthermore, there was microperimetry data in some patients to demonstrate long-term function rescue of photoreceptor cells by paramacular or equatorial RPE.

#### **7.3.2 Limitations of the Thesis**

The main limitation of the trials described in **Chapter 4** was the inclusion of patients with advanced disease. At this late stage of atrophic AMD or AMD, most of the macular photoreceptor cells have already degenerated and thus it was difficult to demonstrate functional rescue by submacular placement of autologous RPE-choroid patch. Other limitations were the evolving technology of fundus imaging and variability of the various psychophysical outcome measures as discussed in **section 4.5.6**.

The main limitation of the the studies in **Chapter 5** was the retrospective design and the non-uniform follow-up duration. Despite being one of the largest series of long-term follow-up study in translocation, the sample size was too small for additional statistical analysis of factors that may predict outcomes.

The animal experimentes described in **Chapter 6** also had several limitations. These were the sequential experimental design, restricted availability of primary antibodies and lack of functional tests to demonstrate photoreceptor cell rescue by

hESC-RPE. There was also a learning curve in the technique of porcine eye processing leading to artefactual retinal detachment and loss of patch graft.

#### **7.4 Future work**

The work presented in this Thesis provided the proofs of principle for RPE transplantation and the evidence of feasibility in the use of hESC-RPE in clinical transplantation. The current protocol of RPE production from hESC is being refined to maximise yield. The tool for delivery of hESC-RPE on a substrate is also currently being developed. A new prototype delivery device has been used in the porcine eye and has demonstrated some promise. Surgical technique has also been modified to reduce the rate of retinal detachment following graft in the porcine model. Finally, combined intra-ocular and peri-operative oral corticosteroid is currently being investigated as an alternative anti-inflammatory regime to reduce donor cell loss.

In summary, this work has shown that autologous RPE can support macular function for prolonged period although the rate of high quality visual function rescue is low. This has been shown to be due to high rates of post-operative complications related to the complexity of harvesting autologous RPE, damage to the RPE during transplant delivery, recurrence of neovascular disease and possibility of transplanting diseased autologous RPE. The use of hESC as a source of RPE may be a feasible alternative to autologous cells. The short-term outcomes in the porcine experiment offer hope that hESC-RPE is likely to become a treatment option for patients with various types of RPE degeneration.



# Bibliography

Abdel-Meguid, A., Lappas, A., Hartmann, K., Auer, F., Schrage, N., Thumann, G., and Kirchhof, B. (2003) One year follow up of macular translocation with 360 degree retinotomy in patients with age related macular degeneration. *Br J Ophthalmol* **87**, 615-621.

Abe, T., Saigo, Y., Hojo, M., Kano, T., Wakusawa, R., Tokita, Y., and Tamai, M. (2005) Protection of photoreceptor cells from phototoxicity by transplanted retinal pigment epithelial cells expressing different neurotrophic factors. *Cell Transplant* **14**, 799-808.

Abe, T., Takeda, Y., Yamada, K., Akaishi, K., Tomita, H., Sato, M., and Tamai, M. (1999) Cytokine gene expression after subretinal transplantation. *Tohoku J Exp Med* **189**, 179-189.

Acland, G. M., Aguirre, G. D., Bennett, J., Aleman, T. S., Cideciyan, A. V., Bennicelli, J., Dejneka, N. S., Pearce-Kelling, S. E., Maguire, A. M., Palczewski, K., Hauswirth, W. W., and Jacobson, S. G. (2005) Long-term restoration of rod and cone vision by single dose rAAV-mediated gene transfer to the retina in a canine model of childhood blindness. *Mol Ther* **12**, 1072-1082.

Acland, G. M., Aguirre, G. D., Ray, J., Zhang, Q., Aleman, T. S., Cideciyan, A. V., Pearce-Kelling, S. E., Anand, V., Zeng, Y., Maguire, A. M., Jacobson, S. G., Hauswirth, W. W., and Bennett, J. (2001) Gene therapy restores vision in a canine model of childhood blindness. *Nat Genet* **28**, 92-95.

Adewumi, O., Aflatoonian, B., Ahrlund-Richter, L., Amit, M., Andrews, P. W., Beighton, G., Bello, P. A., Benvenisty, N., Berry, L. S., Bevan, S., Blum, B., Brooking, J., Chen, K. G., Choo, A. B., Churchill, G. A., Corbel, M., Damjanov, I., Draper, J. S., Dvorak, P., Emanuelsson, K., Fleck, R. A., Ford, A., Gertow, K., Gertsenstein, M., Gokhale, P. J., Hamilton, R. S., Hampl, A., Healy, L. E., Hovatta, O., Hyllner, J., Imreh, M. P., Itskovitz-Eldor, J., Jackson, J., Johnson, J. L., Jones, M., Kee, K., King, B. L., Knowles, B. B., Lako, M., Lebrin, F., Mallon, B. S., Manning, D., Mayshar, Y., McKay, R. D., Michalska, A. E., Mikkola, M., Mileikovsky, M., Minger, S. L., Moore, H. D., Mummery, C. L., Nagy, A., Nakatsuji, N., O'Brien, C. M., Oh, S. K., Olsson, C., Otonkoski, T., Park, K. Y., Passier, R., Patel, H., Patel, M., Pedersen, R., Pera, M. F., Piekarczyk, M. S., Pera, R. A., Reubinoff, B. E., Robins, A. J., Rossant, J., Rugg-Gunn, P., Schulz, T. C., Semb, H., Sherrer, E. S., Siemen, H., Stacey, G. N., Stojkovic, M., Suemori, H., Szatkiewicz, J., Turetsky, T., Tuuri, T., van den, B. S., Vintersten, K., Vuoristo, S., Ward, D., Weaver, T. A., Young, L. A., and Zhang, W. (2007) Characterization of human embryonic stem cell lines by the International Stem Cell Initiative. *Nat Biotechnol* **25**, 803-816.

Aisenbrey, S., Bartz-Schmidt, K. U., Walter, P., Hilgers, R. D., Ayertey, H., Szurman, P., and Thumann, G. (2007) Long-term follow-up of macular translocation with 360 degrees retinotomy for exudative age-related macular degeneration. *Arch Ophthalmol* **125**, 1367-1372.

Aisenbrey, S., Lafaut, B. A., Szurman, P., Grisanti, S., Luke, C., Krott, R., Thumann, G., Fricke, J., Neugebauer, A., Hilgers, R. D., Esser, P., Walter, P., and Bartz-Schmidt, K. U. (2002) Macular translocation with 360 degrees retinotomy for exudative age-related macular degeneration. *Arch Ophthalmol* **120**, 451-459.

Algvere, P. V., Berglin, L., Gouras, P., and Sheng, Y. (1994) Transplantation of fetal retinal pigment epithelium in age-related macular degeneration with subfoveal neovascularization. *Graefes Arch Clin Exp Ophthalmol* **32**, 707-716.

Algvere, P. V., Berglin, L., Gouras, P., Sheng, Y., and Kopp, E. D. (1997) Transplantation of RPE in age-related macular degeneration: observations in disciform lesions and dry RPE atrophy. *Graefes Arch Clin Exp Ophthalmol* **35**, 149-158.

- Algvere, P. V., Gouras, P., and Dørgard, K. E. (1999) Long-term outcome of RPE allografts in non-immunosuppressed patients with AMD. *Eur J Ophthalmol* **9**, 217-230.
- Allikmets, R., Singh, N., Sun, H., Shroyer, N. F., Hutchinson, A., Chidambaram, A., Gerrard, B., Baird, L., Stauffer, D., Peiffer, A., Rattner, A., Smallwood, P., Li, Y., Anderson, K. L., Lewis, R. A., Nathans, J., Leppert, M., Dean, M., and Lupski, J. R. (1997) A photoreceptor cell-specific ATP-binding transporter gene (ABCR) is mutated in recessive Stargardt macular dystrophy. *Nat Genet* **15**, 236-246.
- Angunawela, R. I., Williamson, T. H., Khan, M. A., and Chong, V. (2005) Choroidal translocation with a pedicle following excision of a type 1 choroidal neovascular membrane. *Br J Ophthalmol* **89**, 386.
- Apte, R. S., Scheufler, T. A., and Blomquist, P. H. (2001) Etiology of blindness in an urban community hospital setting. *Ophthalmology* **108**, 693-696.
- Aramant, R. B. and Seiler, M. J. (2002) Retinal transplantation--advantages of intact fetal sheets. *Prog Retin Eye Res* **21**, 57-73.
- Asaria, R. H., Kon, C. H., Bunce, C., Charteris, D. G., Wong, D., Khaw, P. T., and Aylward, G. W. (2001) Adjuvant 5-fluorouracil and heparin prevents proliferative vitreoretinopathy : Results from a randomized, double-blind, controlled clinical trial. *Ophthalmology* **108**, 1179-1183.
- Attebo, K., Mitchell, P., and Smith, W. (1996) Visual acuity and the causes of visual loss in Australia. The Blue Mountains Eye Study. *Ophthalmology* **103**, 357-364.
- Avery, R. L., Fekrat, S., Hawkins, B. S., and Bressler, N. M. (1996) Natural history of subfoveal subretinal hemorrhage in age-related macular degeneration. *Retina* **16**, 183-189.
- Bach, M., Hawlina, M., Holder, G. E., Marmor, M. F., Meigen, T., Vaegan, and Miyake, Y. (2000) Standard for pattern electroretinography. International Society for Clinical Electrophysiology of Vision. *Doc Ophthalmol* **101**, 11-18.
- Baer, C. A., Rickman, C. B., Srivastava, S., Malek, G., Stinnett, S., and Toth, C. A. (2008) Recurrent choroidal neovascularization after macular translocation surgery with 360-degree peripheral retinectomy. *Retina* **28**, 1221-1227.
- Baffi, J., Byrnes, G., Chan, C. C., and Csaky, K. G. (2000) Choroidal neovascularization in the rat induced by adenovirus mediated expression of vascular endothelial growth factor. *Invest Ophthalmol Vis Sci* **41**, 3582-3589.
- Bainbridge, J. W., Smith, A. J., Barker, S. S., Robbie, S., Henderson, R., Balagun, K., Viswanathan, A., Holder, G. E., Stockman, A., Tyler, N., Petersen-Jones, S., Bhattacharya, S. S., Thrasher, A. J., Fitzke, F. W., Carter, B. J., Rubin, G. S., Moore, A. T., and Ali, R. R. (2008) Effect of gene therapy on visual function in Leber's congenital amaurosis. *N Engl J Med* **358**, 2231-2239.
- Bellmann, C., Neveu, M. M., Scholl, H. P., Hogg, C. R., Rath, P. P., Jenkins, S., Bird, A. C., and Holder, G. E. (2004) Localized retinal electrophysiological and fundus autofluorescence imaging abnormalities in maternal inherited diabetes and deafness. *Invest Ophthalmol Vis Sci* **45**, 2355-2360.
- Berglin, L., Gouras, P., Sheng, Y., Lavid, J., Lin, P. K., Cao, H., and Kjeldbye, H. (1997) Tolerance of human fetal retinal pigment epithelium xenografts in monkey retina. *Graefes Arch Clin Exp Ophthalmol* **235**, 103-110.

- Bessho, K., Gomi, F., Harino, S., Sawa, M., Sayanagi, K., Tsujikawa, M., and Tano, Y. (2009) Macular autofluorescence in eyes with cystoid macula edema, detected with 488 nm-excitation but not with 580 nm-excitation. *Graefes Arch Clin Exp Ophthalmol* **247**, 729-734.
- Bharti, K., Nguyen, M. T., Skuntz, S., Bertuzzi, S., and Arnheiter, H. (2006) The other pigment cell: specification and development of the pigmented epithelium of the vertebrate eye. *Pigment Cell Res* **19**, 380-394.
- Bhatt, N. S., Newsome, D. A., Fenech, T., Hessburg, T. P., Diamond, J. G., Miceli, M. V., Kratz, K. E., and Oliver, P. D. (1994) Experimental transplantation of human retinal pigment epithelial cells on collagen substrates. *Am J Ophthalmol* **117**, 214-221.
- Bhutto, I. A., McLeod, D. S., Hasegawa, T., Kim, S. Y., Merges, C., Tong, P., and Luty, G. A. (2006) Pigment epithelium-derived factor (PEDF) and vascular endothelial growth factor (VEGF) in aged human choroid and eyes with age-related macular degeneration. *Exp Eye Res* **82**, 99-110.
- Binder, S., Krebs, I., Hilgers, R. D., Abri, A., Stolba, U., Assadoulina, A., Kellner, L., Stanzel, B. V., Jahn, C., and Feichtinger, H. (2004) Outcome of transplantation of autologous retinal pigment epithelium in age-related macular degeneration: a prospective trial. *Invest Ophthalmol Vis Sci* **45**, 4151-4160.
- Binder, S., Stolba, U., Krebs, I., Kellner, L., Jahn, C., Feichtinger, H., Povelka, M., Frohner, U., Kruger, A., Hilgers, R. D., and Krugluger, W. (2002) Transplantation of autologous retinal pigment epithelium in eyes with foveal neovascularization resulting from age-related macular degeneration: a pilot study. *Am J Ophthalmol* **133**, 215-225.
- Bindewald, A., Roth, F., van Meurs, J., and Holz, F. G. (2004) [Transplantation of retinal pigment epithelium (RPE) following CNV removal in patients with AMD. Techniques, results, outlook]. *Ophthalmologe* **101**, 886-894.
- Blumenkranz, M. S., Bressler, N. M., Bressler, S. B., Donati, G., Fish, G. E., Haynes, L. A., Lewis, H., Miller, J. W., Mones, J. M., Potter, M. J., Pournaras, C., Reaves, A., Rosenfeld, P. J., Schachat, A. P., Schmidt-Erfurth, U., Sickenburg, M., Singerman, L. J., Slakter, J. S., Strong, A., and Vannier, S. (2002) Verteporfin therapy for subfoveal choroidal neovascularization in age-related macular degeneration: three-year results of an open-label extension of 2 randomized clinical trials--TAP Report no. 5. *Arch Ophthalmol* **120**, 1307-1314.
- Bok, D. and Hall, M. O. (1971) The role of the pigment epithelium in the etiology of inherited retinal dystrophy in the rat. *J Cell Biol* **49**, 664-682.
- Boulton, M. E., Marshall, J., and Mellerio, J. (1982) Human retinal pigment epithelial cells in tissue culture: a means of studying inherited retinal diseases. *Birth Defects Orig Artic Ser* **18**, 101-118.
- Bousquet, J., Knani, J., Dhivert, H., Richard, A., Chicoye, A., Ware, J. E., Jr., and Michel, F. B. (1994) Quality of life in asthma. I. Internal consistency and validity of the SF-36 questionnaire. *Am J Respir Crit Care Med* **149**, 371-375.
- Bowes, R. C., Ebright, J. N., Zavodni, Z. J., Yu, L., Wang, T., Daiger, S. P., Wistow, G., Boon, K., and Hauser, M. A. (2006) Defining the human macula transcriptome and candidate retinal disease genes using EyeSAGE. *Invest Ophthalmol Vis Sci* **47**, 2305-2316.
- Braunstein, R. A. and Gass, J. D. (1979) Serous detachments of the retinal pigment epithelium in patients with senile macular disease. *Am J Ophthalmol* **88**, 652-660.

- Bressler, N. M. (2001) Photodynamic therapy of subfoveal choroidal neovascularization in age-related macular degeneration with verteporfin: two-year results of 2 randomized clinical trials--tap report 2. *Arch Ophthalmol* **119**, 198-207.
- Bressler, N. M., Bressler, S. B., Childs, A. L., Haller, J. A., Hawkins, B. S., Lewis, H., MacCumber, M. W., Marsh, M. J., Redford, M., Sternberg, P., Jr., Thomas, M. A., and Williams, G. A. (2004a) Surgery for hemorrhagic choroidal neovascular lesions of age-related macular degeneration: ophthalmic findings: SST report no. 13. *Ophthalmology* **111**, 1993-2006.
- Bressler, S. B., Pieramici, D. J., Koester, J. M., and Bressler, N. M. (2004b) Natural history of minimally classic subfoveal choroidal neovascular lesions in the treatment of age-related macular degeneration with photodynamic therapy (TAP) investigation: outcomes potentially relevant to management--TAP report No. 6. *Arch Ophthalmol* **122**, 325-329.
- Breton, M. E., Schueller, A. W., Lamb, T. D., and Pugh, E. N., Jr. (1994) Analysis of ERG a-wave amplification and kinetics in terms of the G-protein cascade of phototransduction. *Invest Ophthalmol Vis Sci* **35**, 295-309.
- Brittis, M., Lopez, R., Gouras, P., and Kjeldbye, H. (1987) Allotransplantation of cultured retinal epithelium to Bruch's membrane in the rabbit eye. *Transplant Proc* **19**, 1133-1136.
- Brown, B., Adams, A. J., Coletta, N. J., and Haegerstrom-Portnoy, G. (1986) Dark adaptation in age-related maculopathy. *Ophthalmic Physiol Opt* **6**, 81-84.
- Brown, D. M., Kaiser, P. K., Michels, M., Soubrane, G., Heier, J. S., Kim, R. Y., Sy, J. P., and Schneider, S. (2006) Ranibizumab versus verteporfin for neovascular age-related macular degeneration. *N Engl J Med* **355**, 1432-1444.
- Brown, D. M., Michels, M., Kaiser, P. K., Heier, J. S., Sy, J. P., and Ianchulev, T. (2009) Ranibizumab versus verteporfin photodynamic therapy for neovascular age-related macular degeneration: Two-year results of the ANCHOR study. *Ophthalmology* **116**, 57-65.
- Bullimore, M. A. and Bailey, I. L. (1995) Reading and eye movements in age-related maculopathy. *Optom Vis Sci* **72**, 125-138.
- Bush, R. A. and Sieving, P. A. (1994) A proximal retinal component in the primate photopic ERG a-wave. *Invest Ophthalmol Vis Sci* **35**, 635-645.
- Bush, R. A. and Sieving, P. A. (1996) Inner retinal contributions to the primate photopic fast flicker electroretinogram. *J Opt Soc Am A Opt Image Sci Vis* **13**, 557-565.
- Byrne, J. A., Pedersen, D. A., Clepper, L. L., Nelson, M., Sanger, W. G., Gokhale, S., Wolf, D. P., and Mitalipov, S. M. (2007) Producing primate embryonic stem cells by somatic cell nuclear transfer. *Nature* **450**, 497-502.
- Cahill, M. T., Mruthyunjaya, P., Bowes, R. C., and Toth, C. A. (2005a) Recurrence of retinal pigment epithelial changes after macular translocation with 360 degrees peripheral retinectomy for geographic atrophy. *Arch Ophthalmol* **123**, 935-938.
- Cahill, M. T., Stinnett, S. S., Banks, A. D., Freedman, S. F., and Toth, C. A. (2005b) Quality of life after macular translocation with 360 degrees peripheral retinectomy for age-related macular degeneration. *Ophthalmology* **112**, 144-151.
- Cai, J., Jiang, W. G., Grant, M. B., and Boulton, M. (2006) Pigment epithelium-derived factor inhibits angiogenesis via regulated intracellular proteolysis of vascular endothelial growth factor receptor 1. *J Biol Chem* **281**, 3604-3613.

- Campochiaro, P. A. and Hackett, S. F. (1993) Corneal endothelial cell matrix promotes expression of differentiated features of retinal pigmented epithelial cells: implication of laminin and basic fibroblast growth factor as active components. *Exp Eye Res* **57**, 539-547.
- Capeans, C., Pineiro, A., Pardo, M., Sueiro-Lopez, C., Blanco, M. J., Dominguez, F., and Sanchez-Salorio, M. (2003) Amniotic membrane as support for human retinal pigment epithelium (RPE) cell growth. *Acta Ophthalmol Scand* **81**, 271-277.
- Capla, J. M., Ceradini, D. J., Tepper, O. M., Callaghan, M. J., Bhatt, K. A., Galiano, R. D., Levine, J. P., and Gurtner, G. C. (2006) Skin graft vascularization involves precisely regulated regression and replacement of endothelial cells through both angiogenesis and vasculogenesis. *Plast Reconstr Surg* **117**, 836-844.
- Caramoy, A., Liakopoulos, S., Menrath, E., and Kirchhof, B. (2010) Autologous translocation of choroid and retinal pigment epithelium in geographic atrophy: long-term functional and anatomical outcome. *Br J Ophthalmol* **94**, 1040-1044.
- Carr, A. J., Vugler, A., Lawrence, J., Li, C. L., Ahmado, A., Chen, F. K., Semo, M., Gias, C., da Cruz, L., Moore, H. D., Walsh, J., and Coffey, P. J. (2009a) Molecular characterization and functional analysis of phagocytosis by human embryonic stem cell-derived RPE cells using a novel human retinal assay. *Mol Vis* **15**, 283-295.
- Carr, A. J., Vugler, A. A., Hikita, S. T., Lawrence, J. M., Gias, C., Chen, L. L., Buchholz, D. E., Ahmado, A., Semo, M., Smart, M. J., Hasan, S., da Cruz, L., Johnson, L. V., Clegg, D. O., and Coffey, P. J. (2009b) Protective effects of human iPS-derived retinal pigment epithelium cell transplantation in the retinal dystrophic rat. *PLoS ONE* **4**, e8152.
- Castellarin, A. A., Nasir, M., Sugino, I. K., and Zarbin, M. A. (1998) Progressive presumed choriocapillaris atrophy after surgery for age-related macular degeneration. *Retina* **18**, 143-149.
- Castillo, B. V., Jr., Del Cerro, M., White, R. M., Cox, C., Wyatt, J., Nadiga, G., and del Cerro, C. (1997) Efficacy of nonfetal human RPE for photoreceptor rescue: a study in dystrophic RCS rats. *Exp Neurol* **146**, 1-9.
- Castillo, B. V., Jr., Little, C. W., del Cerro, C., and Del Cerro, M. (1995) An improved method of isolating fetal human retinal pigment epithelium. *Curr Eye Res* **14**, 677-683.
- Cereda, M. G., Parolini, B., Bellesini, E., and Pertile, G. (2010) Surgery for CNV and autologous choroidal RPE patch transplantation: exposing the submacular space. *Graefes Arch Clin Exp Ophthalmol* **248**, 37-47.
- Chandler, M. J., Smith, P. J., Samuelson, D. A., and MacKay, E. O. (1999) Photoreceptor density of the domestic pig retina. *Vet Ophthalmol* **2**, 179-184.
- Chen, F. K., Patel, P. J., Webster, A. R., Coffey, P. J., Tufail, A., and da Cruz, L. (2010) NIDEK MP1 IS ABLE TO DETECT SUBTLE DECLINE IN FUNCTION IN INHERITED AND AGE-RELATED ATROPHIC MACULAR DISEASE WITH STABLE VISUAL ACUITY. *Retina*.
- Chen, F. K., Patel, P. J., Xing, W., Bunce, C., Egan, C., Tufail, A. T., Coffey, P. J., Rubin, G. S., and da Cruz, L. (2009) Test-retest variability of microperimetry using the Nidek MP1 in patients with macular disease. *Invest Ophthalmol Vis Sci* **50**, 3464-3472.
- Chen, F. K., Uppal, G. S., Rubin, G. S., Webster, A. R., Coffey, P. J., and da Cruz, L. (2008) Evidence of retinal function using microperimetry following autologous retinal pigment epithelium-choroid graft in macular dystrophy. *Invest Ophthalmol Vis Sci* **49**, 3143-3150.

- Chieh, J. J., Stinnett, S. S., and Toth, C. A. (2008) Central and pericentral retinal sensitivity after macular translocation surgery. *Retina* **28**, 1522-1529.
- Chong, N. H., Keonin, J., Luthert, P. J., Frennesson, C. I., Weingeist, D. M., Wolf, R. L., Mullins, R. F., and Hageman, G. S. (2005) Decreased thickness and integrity of the macular elastic layer of Bruch's membrane correspond to the distribution of lesions associated with age-related macular degeneration. *Am J Pathol* **166**, 241-251.
- Cibulskyte, D., Kaalund, H., Pedersen, M., Horlyck, A., Marcussen, N., Hansen, H. E., Madsen, M., and Mortensen, J. (2005) Chronic cyclosporine nephrotoxicity: a pig model. *Transplant Proc* **37**, 3298-3301.
- Cibulskyte, D., Pedersen, M., Jakobsen, P., Hansen, H. E., and Mortensen, J. (2007a) Pharmacokinetic characterization of a pig model of ciclosporin A nephrotoxicity following intravenous administration. *Pharmacol Res* **56**, 311-317.
- Cibulskyte, D., Samsoe, E. A., Hanefeld, K. D., Ellingsen, A. R., Pedersen, M., Hoerlyck, A., Flyvbjerg, A., Marcussen, N., Hansen, H. E., Madsen, M., and Mortensen, J. (2007b) Renal effects of long-term ciclosporin A treatment in a large animal model. *Nephron Exp Nephrol* **105**, e91-e97.
- Coffey, P. J., Girman, S., Wang, S. M., Hetherington, L., Keegan, D. J., Adamson, P., Greenwood, J., and Lund, R. D. (2002) Long-term preservation of cortically dependent visual function in RCS rats by transplantation. *Nat Neurosci* **5**, 53-56.
- Cong, L., Sun, D., Zhang, Z., Jiao, W., Rizzolo, L. J., and Peng, S. (2008) A novel rabbit model for studying RPE transplantation. *Invest Ophthalmol Vis Sci* **49**, 4115-4125.
- Convento, E. and Barbaro, G. (2007) Technical insights in the interpretation of automatic microperimetry. In: *Perimetry and the Fundus: An Introduction to Microperimetry*, pp. 229-237. Ed E. Midena. Slack Inc.: Thorofare.
- Cook, B., Lewis, G. P., Fisher, S. K., and Adler, R. (1995) Apoptotic photoreceptor degeneration in experimental retinal detachment. *Invest Ophthalmol Vis Sci* **36**, 990-996.
- Crafoord, S., Algvare, P. V., Kopp, E. D., and Seregard, S. (2000) Cyclosporine treatment of RPE allografts in the rabbit subretinal space. *Acta Ophthalmol Scand* **78**, 122-129.
- Crafoord, S., Algvare, P. V., Seregard, S., and Kopp, E. D. (1999) Long-term outcome of RPE allografts to the subretinal space of rabbits. *Acta Ophthalmol Scand* **77**, 247-254.
- Crossland, M. D., Culham, L. E., Kabanarou, S. A., and Rubin, G. S. (2005a) Preferred retinal locus development in patients with macular disease. *Ophthalmology* **112**, 1579-1585.
- Crossland, M. D., Culham, L. E., and Rubin, G. S. (2004a) Fixation stability and reading speed in patients with newly developed macular disease. *Ophthalmic Physiol Opt* **24**, 327-333.
- Crossland, M. D., Culham, L. E., and Rubin, G. S. (2005b) Predicting reading fluency in patients with macular disease. *Optom Vis Sci* **82**, 11-17.
- Crossland, M. D. and Rubin, G. S. (2002) The use of an infrared eyetracker to measure fixation stability. *Optom Vis Sci* **79**, 735-739.
- Crossland, M. D., Sims, M., Galbraith, R. F., and Rubin, G. S. (2004b) Evaluation of a new quantitative technique to assess the number and extent of preferred retinal loci in macular disease. *Vision Res* **44**, 1537-1546.

- Custer, N. V. and Bok, D. (1975) Pigment epithelium-photoreceptor interactions in the normal and dystrophic rat retina. *Exp Eye Res* **21**, 153-166.
- D'Cruz, P. M., Yasumura, D., Weir, J., Matthes, M. T., Abderrahim, H., Lavail, M. M., and Vollrath, D. (2000) Mutation of the receptor tyrosine kinase gene *Mertk* in the retinal dystrophic RCS rat. *Hum Mol Genet* **9**, 645-651.
- da Cruz, L., Chen, F. K., Ahmado, A., Greenwood, J., and Coffey, P. (2007) RPE transplantation and its role in retinal disease. *Prog Retin Eye Res* **26**, 598-635.
- Dastgheib, K., Bressler, S. B., and Green, W. R. (1993) Clinicopathologic correlation of laser lesion expansion after treatment of choroidal neovascularization. *Retina* **13**, 345-352.
- Davis, A. A., Bernstein, P. S., Bok, D., Turner, J., Nachtigal, M., and Hunt, R. C. (1995) A human retinal pigment epithelial cell line that retains epithelial characteristics after prolonged culture. *Invest Ophthalmol Vis Sci* **36**, 955-964.
- Degenring, R. F., Cordes, A., and Schrage, N. F. (2010) Autologous translocation of the retinal pigment epithelium and choroid in the treatment of neovascular age-related macular degeneration. *Acta Ophthalmol*.
- Del Priore, L. V., Hornbeck, R., Kaplan, H. J., Jones, Z., Valentino, T. L., Mosinger-Ogilvie, J., and Swinn, M. (1995) Debridement of the pig retinal pigment epithelium in vivo. *Arch Ophthalmol* **113**, 939-944.
- Del Priore, L. V., Ishida, O., Johnson, E. W., Sheng, Y., Jacoby, D. B., Geng, L., Tezel, T. H., and Kaplan, H. J. (2003a) Triple immune suppression increases short-term survival of porcine fetal retinal pigment epithelium xenografts. *Invest Ophthalmol Vis Sci* **44**, 4044-4053.
- Del Priore, L. V., Kaplan, H. J., Tezel, T. H., Hayashi, N., Berger, A. S., and Green, W. R. (2001) Retinal pigment epithelial cell transplantation after subfoveal membranectomy in age-related macular degeneration: clinicopathologic correlation. *Am J Ophthalmol* **131**, 472-480.
- Del Priore, L. V., Sheng, Y., Johnson, E., Jacoby, D., Edge, A., Suzuki, T., Geng, L., Tezel, T. H., and Kaplan, H. J. (2003b) Identification of transplanted retinal pigment epithelium with a novel chromosomal marker. *Curr Eye Res* **26**, 125-131.
- Del Priore, L. V. and Tezel, T. H. (1998) Reattachment rate of human retinal pigment epithelium to layers of human Bruch's membrane. *Arch Ophthalmol* **116**, 335-341.
- Del Priore, L. V., Tezel, T. H., and Kaplan, H. J. (2004) Survival of allogeneic porcine retinal pigment epithelial sheets after subretinal transplantation. *Invest Ophthalmol Vis Sci* **45**, 985-992.
- Del Priore, L. V., Tezel, T. H., and Kaplan, H. J. (2006) Maculoplasty for age-related macular degeneration: reengineering Bruch's membrane and the human macula. *Prog Retin Eye Res* **25**, 539-562.
- Delori, F. C., Dorey, C. K., Staurenghi, G., Arend, O., Goger, D. G., and Weiter, J. J. (1995) In vivo fluorescence of the ocular fundus exhibits retinal pigment epithelium lipofuscin characteristics. *Invest Ophthalmol Vis Sci* **36**, 718-729.
- Deruaz, A., Goldschmidt, M., Whatham, A. R., Mermoud, C., Lorincz, E. N., Schnider, A., and Safran, A. B. (2006) A technique to train new oculomotor behavior in patients with central macular scotomas during reading related tasks using scanning laser ophthalmoscopy: immediate functional benefits and gains retention. *BMC Ophthalmol* **6**, 35.

- Dimitrov, P. N., Mukesh, B. N., McCarty, C. A., and Taylor, H. R. (2003) Five-year incidence of bilateral cause-specific visual impairment in the Melbourne Visual Impairment Project. *Invest Ophthalmol Vis Sci* **44**, 5075-5081.
- Downes, S. M., Fitzke, F. W., Holder, G. E., Payne, A. M., Bessant, D. A., Bhattacharya, S. S., and Bird, A. C. (1999) Clinical features of codon 172 RDS macular dystrophy: similar phenotype in 12 families. *Arch Ophthalmol* **117**, 1373-1383.
- Draper, J. S. and Andrews, P. W. (2002) Embryonic stem cells: advances toward potential therapeutic use. *Curr Opin Obstet Gynecol* **14**, 309-315.
- Drexler, W., Morgner, U., Ghanta, R. K., Kartner, F. X., Schuman, J. S., and Fujimoto, J. G. (2001) Ultrahigh-resolution ophthalmic optical coherence tomography. *Nat Med* **7**, 502-507.
- Drexler, W., Sattmann, H., Hermann, B., Ko, T. H., Stur, M., Unterhuber, A., Scholda, C., Findl, O., Wirtitsch, M., Fujimoto, J. G., and Fercher, A. F. (2003) Enhanced visualization of macular pathology with the use of ultrahigh-resolution optical coherence tomography. *Arch Ophthalmol* **121**, 695-706.
- Drukker, M., Katz, G., Urbach, A., Schuldiner, M., Markel, G., Itskovitz-Eldor, J., Reubinoff, B., Mandelboim, O., and Benvenisty, N. (2002) Characterization of the expression of MHC proteins in human embryonic stem cells. *Proc Natl Acad Sci U S A* **99**, 9864-9869.
- Dudgeon, S. M., Keating, D., and Parks, S. (2007) Simultaneous structural and functional imaging of the macula using combined optical coherence tomography ophthalmoscope and multifocal electroretinogram. *J Opt Soc Am A Opt Image Sci Vis* **24**, 1394-1401.
- Dunaief, J. L., Kwun, R. C., Bhardwaj, N., Lopez, R., Gouras, P., and Goff, S. P. (1995) Retroviral gene transfer into retinal pigment epithelial cells followed by transplantation into rat retina. *Hum Gene Ther* **6**, 1225-1229.
- Duncan, J. L., Lavail, M. M., Yasumura, D., Matthes, M. T., Yang, H., Trautmann, N., Chappelow, A. V., Feng, W., Earp, H. S., Matsushima, G. K., and Vollrath, D. (2003) An RCS-like retinal dystrophy phenotype in mer knockout mice. *Invest Ophthalmol Vis Sci* **44**, 826-838.
- Dunn, K. C., Aotaki-Keen, A. E., Putkey, F. R., and Hjelmeland, L. M. (1996) ARPE-19, a human retinal pigment epithelial cell line with differentiated properties. *Exp Eye Res* **62**, 155-169.
- Dunn, K. C., Marmorstein, A. D., Bonilha, V. L., Rodriguez-Boulan, E., Giordano, F., and Hjelmeland, L. M. (1998) Use of the ARPE-19 cell line as a model of RPE polarity: basolateral secretion of FGF5. *Invest Ophthalmol Vis Sci* **39**, 2744-2749.
- Duret, F., Issenhuth, M., and Safran, A. B. (1999) Combined use of several preferred retinal loci in patients with macular disorders when reading single words. *Vision Res* **39**, 873-879.
- Durlu, Y. K. and Tamai, M. (1997) Transplantation of retinal pigment epithelium using viable cryopreserved cells. *Cell Transplant* **6**, 149-162.
- Eckardt, C., Eckardt, U., and Conrad, H. G. (1999) Macular rotation with and without counter-rotation of the globe in patients with age-related macular degeneration. *Graefes Arch Clin Exp Ophthalmol* **237**, 313-325.
- Eckardt, C., Eckardt, U., Groos, S., Luciano, L., and Reale, E. (2004) Macular translocation in a patient with adult-onset foveomacular vitelliform dystrophy with light- and electron-microscopic observations on the surgically removed subfoveal tissue. *Graefes Arch Clin Exp Ophthalmol* **242**, 456-467.



- Edwards, A. O., Ritter, R., III, Abel, K. J., Manning, A., Panhuysen, C., and Farrer, L. A. (2005) Complement factor H polymorphism and age-related macular degeneration. *Science* **308**, 421-424.
- el Dirini, A. A., Wang, H. M., Ogden, T. E., and Ryan, S. J. (1992) Retinal pigment epithelium implantation in the rabbit: technique and morphology. *Graefes Arch Clin Exp Ophthalmol* **230**, 292-300.
- Elliott, D. B., Sanderson, K., and Conkey, A. (1990) The reliability of the Pelli-Robson contrast sensitivity chart. *Ophthalmic Physiol Opt* **10**, 21-24.
- Engelsberg, K. and Ghosh, F. (2007) Transplantation of cultured adult porcine full-thickness retina. *Cell Transplant* **16**, 31-39.
- Enzmann, V., Faude, F., Wiedemann, P., and Kohen, L. (2000) The local and systemic secretion of the pro-inflammatory cytokine interleukin-6 after transplantation of retinal pigment epithelium cells in a rabbit model. *Curr Eye Res* **21**, 530-534.
- Enzmann, V., Hollborn, M., Poschinger, K., Wiedemann, P., and Kohen, L. (2001a) Immunosuppression by IL-10-transfected human retinal pigment epithelial cells in vitro. *Curr Eye Res* **23**, 98-105.
- Enzmann, V., Hollborn, M., Wiedemann, P., and Kohen, L. (2001b) Molecular and cellular evidence for T-cell stimulation by allogeneic retinal pigment epithelium cells in vitro. *Graefes Arch Clin Exp Ophthalmol* **239**, 445-451.
- Ergun, E., Maar, N., Radner, W., Barbazetto, I., Schmidt-Erfurth, U., and Stur, M. (2003) Scotoma size and reading speed in patients with subfoveal occult choroidal neovascularization in age-related macular degeneration. *Ophthalmology* **110**, 65-69.
- Faktorovich, E. G., Steinberg, R. H., Yasumura, D., Matthes, M. T., and Lavail, M. M. (1990) Photoreceptor degeneration in inherited retinal dystrophy delayed by basic fibroblast growth factor. *Nature* **347**, 83-86.
- Falkenstein, I. A., Cochran, D. E., Azen, S. P., Dustin, L., Tammewar, A. M., Kozak, I., and Freeman, W. R. (2008) Comparison of visual acuity in macular degeneration patients measured with snellen and early treatment diabetic retinopathy study charts. *Ophthalmology* **115**, 319-323.
- Fang, I. M., Yang, C. H., Yang, C. M., and Chen, M. S. (2009) Overexpression of integrin alpha6 and beta4 enhances adhesion and proliferation of human retinal pigment epithelial cells on layers of porcine Bruch's membrane. *Exp Eye Res* **88**, 12-21.
- Fang, X., Hayashi, A., Morimoto, T., Usui, S., Cekic, O., Fujioka, S., Hayashi, N., Fujikado, T., Ohji, M., and Tano, Y. (2004) Retinal changes after macular translocation with 360-degree retinotomy in monkey eyes. *Am J Ophthalmol* **137**, 1034-1041.
- Farrokh-Siar, L., Rezai, K. A., Semnani, R. T., Patel, S. C., Ernest, J. T., and van Seventer, G. A. (1999) Human fetal retinal pigment epithelium suppresses the activation of CD4(+) and CD8(+) T-cells. *Graefes Arch Clin Exp Ophthalmol* **237**, 934-939.
- Fawzy, N. F., Joeres, S., Llacer, H., Heussen, F. M. A., Kirchhof, B., and Jousseaume, A. M. (2006) Autologous Translocation of the Choroid and RPE in Age Related Macular Degeneration – 1 Year Follow-Up in 25 Patients. *Invest Ophthalmol Vis Sci* **47**, E-Abstract 2191.
- Feigl, B., Lovie-Kitchin, J., and Brown, B. (2005) Objective functional assessment of age-related maculopathy: a special application for the multifocal electroretinogram. *Clin Exp Optom* **88**, 304-312.

- Felbor, U., Schilling, H., and Weber, B. H. (1997) Adult vitelliform macular dystrophy is frequently associated with mutations in the peripherin/RDS gene. *Hum Mutat* **10**, 301-309.
- Ferris, F. L., III, Kassoff, A., Bresnick, G. H., and Bailey, I. (1982) New visual acuity charts for clinical research. *Am J Ophthalmol* **94**, 91-96.
- Fine, E. M. and Rubin, G. S. (1999) Reading with simulated scotomas: attending to the right is better than attending to the left. *Vision Res* **39**, 1039-1048.
- Fisher, S. K., Lewis, G. P., Linberg, K. A., and Verardo, M. R. (2005) Cellular remodeling in mammalian retina: results from studies of experimental retinal detachment. *Prog Retin Eye Res* **24**, 395-431.
- Flood, M. T., Gouras, P., and Kjeldbye, H. (1980) Growth characteristics and ultrastructure of human retinal pigment epithelium in vitro. *Invest Ophthalmol Vis Sci* **19**, 1309-1320.
- Fong, C. Y., Peh, G. S., Gauthaman, K., and Bongso, A. (2009) Separation of SSEA-4 and TRA-1-60 labelled undifferentiated human embryonic stem cells from a heterogeneous cell population using magnetic-activated cell sorting (MACS) and fluorescence-activated cell sorting (FACS). *Stem Cell Rev Rep* **5**, 72-80.
- Francis, P. J., Wang, S., Zhang, Y., Brown, A., Hwang, T., McFarland, T. J., Jeffrey, B. G., Lu, B., Wright, L., Appukuttan, B., Wilson, D. J., Stout, J. T., Neuringer, M., Gamm, D. M., and Lund, R. D. (2009) Subretinal transplantation of forebrain progenitor cells in nonhuman primates: survival and intact retinal function. *Invest Ophthalmol Vis Sci* **50**, 3425-3431.
- Friedman, E., Krupsky, S., Lane, A. M., Oak, S. S., Friedman, E. S., Egan, K., and Gragoudas, E. S. (1995) Ocular blood flow velocity in age-related macular degeneration. *Ophthalmology* **102**, 640-646.
- Fujii, G. Y., De Juan E Jr, Humayun, M. S., Sunness, J. S., Chang, T. S., and Rossi, J. V. (2003) Characteristics of visual loss by scanning laser ophthalmoscope microperimetry in eyes with subfoveal choroidal neovascularization secondary to age-related macular degeneration. *Am J Ophthalmol* **136**, 1067-1078.
- Fujii, G. Y., De Juan E Jr, Pieramici, D. J., Humayun, M. S., Phillips, S., Reynolds, S. M., Melia, M., and Schachat, A. P. (2002a) Inferior limited macular translocation for subfoveal choroidal neovascularization secondary to age-related macular degeneration: 1-year visual outcome and recurrence report. *Am J Ophthalmol* **134**, 69-74.
- Fujii, G. Y., De Juan E Jr, Sunness, J., Humayun, M. S., Pieramici, D. J., and Chang, T. S. (2002b) Patient selection for macular translocation surgery using the scanning laser ophthalmoscope. *Ophthalmology* **109**, 1737-1744.
- Fujikado, T., Asonuma, S., Ohji, M., Kusaka, S., Hayashi, A., Ikuno, Y., Kamei, M., Oda, K., and Tano, Y. (2002) Reading ability after macular translocation surgery with 360-degree retinotomy. *Am J Ophthalmol* **134**, 849-856.
- Fujikado, T., Ohji, M., Kusaka, S., Hayashi, A., Kamei, M., Okada, A. A., Oda, K., and Tano, Y. (2001) Visual function after foveal translocation with 360-degree retinotomy and simultaneous torsional muscle surgery in patients with myopic neovascular maculopathy. *Am J Ophthalmol* **131**, 101-110.
- Gabrielian, K., Oganessian, A., Farrokh-Siar, L., Rezai, K. A., Verp, M. S., Patel, S. C., and Ernest, J. T. (1999a) Growth of human fetal retinal pigment epithelium as microspheres. *Graefes Arch Clin Exp Ophthalmol* **237**, 241-248.

- Gabrielian, K., Oganessian, A., Patel, S. C., Verp, M. S., and Ernest, J. T. (1999b) Cellular response in rabbit eyes after human fetal RPE cell transplantation. *Graefes Arch Clin Exp Ophthalmol* **237**, 326-335.
- Gal, A., Li, Y., Thompson, D. A., Weir, J., Orth, U., Jacobson, S. G., Apfelstedt-Sylla, E., and Vollrath, D. (2000) Mutations in MERTK, the human orthologue of the RCS rat retinal dystrophy gene, cause retinitis pigmentosa. *Nat Genet* **26**, 270-271.
- Gao, H. and Hollyfield, J. G. (1992) Aging of the human retina. Differential loss of neurons and retinal pigment epithelial cells. *Invest Ophthalmol Vis Sci* **33**, 1-17.
- Gekeler, F., Szurman, P., Grisanti, S., Weiler, U., Claus, R., Greiner, T. O., Volker, M., Kohler, K., Zrenner, E., and Bartz-Schmidt, K. U. (2007) Compound subretinal prostheses with extra-ocular parts designed for human trials: successful long-term implantation in pigs. *Graefes Arch Clin Exp Ophthalmol* **245**, 230-241.
- Gelissen, F., Voelker, M., Schwabe, R., Besch, D., Aisenbrey, S., Szurman, P., Grisanti, S., Herzau, V., and Bartz-Schmidt, K. U. (2007) Full macular translocation versus photodynamic therapy with verteporfin in the treatment of neovascular age-related macular degeneration: 1-year results of a prospective, controlled, randomised pilot trial (FMT-PDT). *Graefes Arch Clin Exp Ophthalmol* **245**, 1085-1095.
- Gerke Jr, C. G., Hao, Y., and Wong, F. (1995) Topography of rods and cones in the retina of the domestic pig. *HKMJ* **1**, 302-308.
- Gerner, W., Kaser, T., and Saalmuller, A. (2008) Porcine T lymphocytes and NK cells - An update. *Dev Comp Immunol*.
- Ghosh, F. and Arner, K. (2002) Transplantation of full-thickness retina in the normal porcine eye: surgical and morphologic aspects. *Retina* **22**, 478-486.
- Ghosh, F., Engelsberg, K., English, R. V., and Petters, R. M. (2007) Long-term neuroretinal full-thickness transplants in a large animal model of severe retinitis pigmentosa. *Graefes Arch Clin Exp Ophthalmol* **245**, 835-846.
- Ghosh, F., Wong, F., Johansson, K., Bruun, A., and Petters, R. M. (2004) Transplantation of full-thickness retina in the rhodopsin transgenic pig. *Retina* **24**, 98-109.
- Gibran, S. K., Romano, M. R., and Wong, D. (2009) Perfluorocarbon liquid assisted large retinal epithelium patching in sub-macular hemorrhage secondary to age related macular degeneration. *Graefes Arch Clin Exp Ophthalmol* **247**, 187-191.
- Giordano, G. G., Thomson, R. C., Ishaug, S. L., Mikos, A. G., Cumber, S., Garcia, C. A., and Lahiri-Munir, D. (1997) Retinal pigment epithelium cells cultured on synthetic biodegradable polymers. *J Biomed Mater Res* **34**, 87-93.
- Girman, S. V., Wang, S., and Lund, R. D. (2003) Cortical visual functions can be preserved by subretinal RPE cell grafting in RCS rats. *Vision Res* **43**, 1817-1827.
- Girman, S. V., Wang, S., and Lund, R. D. (2005) Time course of deterioration of rod and cone function in RCS rat and the effects of subretinal cell grafting: a light- and dark-adaptation study. *Vision Res* **45**, 343-354.
- Glybina, I. V. and Frank, R. N. (2006) Localization of multifocal electroretinogram abnormalities to the lesion site: findings in a family with Best disease. *Arch Ophthalmol* **124**, 1593-1600.

- Gong, J., Sagiv, O., Cai, H., Tsang, S. H., and Del Priore, L. V. (2008) Effects of extracellular matrix and neighboring cells on induction of human embryonic stem cells into retinal or retinal pigment epithelial progenitors. *Exp Eye Res* **86**, 957-965.
- Gonvers, M., Hornung, J. P., and de Court (1986) The effect of liquid silicone on the rabbit retina. Histologic and ultrastructural study. *Arch Ophthalmol* **104**, 1057-1062.
- Gouras, P. and Algever, P. (1996) Retinal cell transplantation in the macula: new techniques. *Vision Res* **36**, 4121-4125.
- Gouras, P., Cao, H., Sheng, Y., Tanabe, T., Efremova, Y., and Kjeldbye, H. (1994) Patch culturing and transfer of human fetal retinal epithelium. *Graefes Arch Clin Exp Ophthalmol* **232**, 599-607.
- Gouras, P., Flood, M. T., Eggers, H. M., and Kjeldbye, H. (1983) Transplantation of human retinal epithelium to Bruch's membrane of monkey eye. *Invest Ophthalmol Vis Sci* **24(S)**, 142.
- Gouras, P., Flood, M. T., Kjeldbye, H., Bilek, M. K., and Eggers, H. (1985) Transplantation of cultured human retinal epithelium to Bruch's membrane of the owl monkey's eye. *Curr Eye Res* **4**, 253-265.
- Gouras, P., Lopez, R., Brittis, M., and Kjeldbye, H. (1992) The ultrastructure of transplanted rabbit retinal epithelium. *Graefes Arch Clin Exp Ophthalmol* **230**, 468-475.
- Gouras, P., Lopez, R., Kjeldbye, H., Sullivan, B., and Brittis, M. (1989) Transplantation of retinal epithelium prevents photoreceptor degeneration in the RCS rat. *Prog Clin Biol Res* **314**, 659-671.
- Gragoudas, E. S., Adamis, A. P., Cunningham, E. T., Jr., Feinsod, M., and Guyer, D. R. (2004) Pegaptanib for neovascular age-related macular degeneration. *N Engl J Med* **351**, 2805-2816.
- Graham, D. K., Dawson, T. L., Mullaney, D. L., Snodgrass, H. R., and Earp, H. S. (1994) Cloning and mRNA expression analysis of a novel human protooncogene, c-mer. *Cell Growth Differ* **5**, 647-657.
- Green, W. R. and Enger, C. (1993) Age-related macular degeneration histopathologic studies. The 1992 Lorenz E. Zimmerman Lecture. *Ophthalmology* **100**, 1519-1535.
- Grinnemo, K. H., Kumagai-Braesch, M., Mansson-Broberg, A., Skottman, H., Hao, X., Siddiqui, A., Andersson, A., Stromberg, A. M., Lahesmaa, R., Hovatta, O., Sylven, C., Corbascio, M., and Dellgren, G. (2006) Human embryonic stem cells are immunogenic in allogeneic and xenogeneic settings. *Reprod Biomed Online* **13**, 712-724.
- Grisanti, S., Szurman, P., Jordan, J., Kociok, N., Bartz-Schmidt, K. U., and Heimann, K. (2002) Xenotransplantation of retinal pigment epithelial cells into RCS rats. *Jpn J Ophthalmol* **46**, 36-44.
- Grossniklaus, H. E., Hutchinson, A. K., Capone, A., Jr., Woolfson, J., and Lambert, H. M. (1994) Clinicopathologic features of surgically excised choroidal neovascular membranes. *Ophthalmology* **101**, 1099-1111.
- Gu, S. M., Thompson, D. A., Srikumari, C. R., Lorenz, B., Finckh, U., Nicoletti, A., Murthy, K. R., Rathmann, M., Kumaramanickavel, G., Denton, M. J., and Gal, A. (1997) Mutations in RPE65 cause autosomal recessive childhood-onset severe retinal dystrophy. *Nat Genet* **17**, 194-197.
- Hadlock, T., Singh, S., Vacanti, J. P., and McLaughlin, B. J. (1999) Ocular cell monolayers cultured on biodegradable substrates. *Tissue Eng* **5**, 187-196.

- Hageman, G. S., Anderson, D. H., Johnson, L. V., Hancox, L. S., Taiber, A. J., Hardisty, L. I., Hageman, J. L., Stockman, H. A., Borchardt, J. D., Gehrs, K. M., Smith, R. J., Silvestri, G., Russell, S. R., Klaver, C. C., Barbazetto, I., Chang, S., Yannuzzi, L. A., Barile, G. R., Merriam, J. C., Smith, R. T., Olsh, A. K., Bergeron, J., Zernant, J., Merriam, J. E., Gold, B., Dean, M., and Allikmets, R. (2005) A common haplotype in the complement regulatory gene factor H (HF1/CFH) predisposes individuals to age-related macular degeneration. *Proc Natl Acad Sci U S A* **102**, 7227-7232.
- Haines, J. L., Hauser, M. A., Schmidt, S., Scott, W. K., Olson, L. M., Gallins, P., Spencer, K. L., Kwan, S. Y., Nouredine, M., Gilbert, J. R., Schnetz-Boutaud, N., Agarwal, A., Postel, E. A., and Pericak-Vance, M. A. (2005) Complement factor H variant increases the risk of age-related macular degeneration. *Science* **308**, 419-421.
- Hamasaki, D. I., Machemer, R., and Norton, E. W. (1969) Experimental retinal detachment in the owl monkey. VI. The ERG of the detached and reattached retina. *Albrecht Von Graefes Arch Klin Exp Ophthalmol* **177**, 212-221.
- Hamel, C. (2006) Retinitis pigmentosa. *Orphanet J Rare Dis* **1**, 40.
- Hansen, K. A., Sugino, I. K., Yagi, F., Wang, H., Tsukahara, I., Gullapalli, V., Bennett, J., and Zarbin, M. A. (2003) Adeno-associated virus encoding green fluorescent protein as a label for retinal pigment epithelium. *Invest Ophthalmol Vis Sci* **44**, 772-780.
- Hawkins, B. S., Bressler, N. M., Miskala, P. H., Bressler, S. B., Holekamp, N. M., Marsh, M. J., Redford, M., Schwartz, S. D., Sternberg, P., Jr., Thomas, M. A., and Wilson, D. J. (2004) Surgery for subfoveal choroidal neovascularization in age-related macular degeneration: ophthalmic findings: SST report no. 11. *Ophthalmology* **111**, 1967-1980.
- Hays, R. D., Sherbourne, C. D., and Mazel, R. M. (1993) The RAND 36-Item Health Survey 1.0. *Health Econ* **2**, 217-227.
- He, S., Wang, H. M., Ogden, T. E., and Ryan, S. J. (1993) Transplantation of cultured human retinal pigment epithelium into rabbit subretina. *Graefes Arch Clin Exp Ophthalmol* **231**, 737-742.
- Hendrickson, A. and Hicks, D. (2002) Distribution and density of medium- and short-wavelength selective cones in the domestic pig retina. *Exp Eye Res* **74**, 435-444.
- Heussen, F. M., Fawzy, N. F., Joeres, S., Lux, A., Maaijwee, K., Meurs, J. C., Kirchhof, B., and Jousen, A. M. (2008) Autologous translocation of the choroid and RPE in age-related macular degeneration: 1-year follow-up in 30 patients and recommendations for patient selection. *Eye* **22**, 799-807.
- Heussen, F. M., Joeres, S., Prinz, B., Llacer, H., Fawzy, N., Kirchhof, B., and Jousen, A. M. (2006) Quality of life findings in patients with peripheral autologous translocation of the choroid. *Invest Ophthalmol Vis Sci* **47**, E-Abstract 3488.
- Heynen, H. and van Norren, D. (1985) Origin of the electroretinogram in the intact macaque eye--I. Principal component analysis. *Vision Res* **25**, 697-707.
- Ho, T. C., Del Priore, L. V., and Kaplan, H. J. (1997) Tissue culture of retinal pigment epithelium following isolation with a gelatin matrix technique. *Exp Eye Res* **64**, 133-139.
- Holder, G. E. (2001) Pattern electroretinography (PERG) and an integrated approach to visual pathway diagnosis. *Prog Retin Eye Res* **20**, 531-561.
- Holder, G. E., Brigell, M. G., Hawlina, M., Meigen, T., Vaegan, and Bach, M. (2007) ISCEV standard for clinical pattern electroretinography--2007 update. *Doc Ophthalmol* **114**, 111-116.

- Holladay, J. T. (2004) Visual acuity measurements. *J Cataract Refract Surg* **30**, 287-290.
- Hollborn, M., Enzmann, V., Barth, W., Wiedemann, P., and Kohen, L. (2000) Changes in the mRNA expression of cytokines and chemokines by stimulated RPE cells in vitro. *Curr Eye Res* **20**, 488-495.
- Hollborn, M., Francke, M., Iandiev, I., Buhner, E., Foja, C., Kohen, L., Reichenbach, A., Wiedemann, P., Bringmann, A., and Uhlmann, S. (2008) Early activation of inflammation- and immune response-related genes after experimental detachment of the porcine retina. *Invest Ophthalmol Vis Sci* **49**, 1262-1273.
- Hollborn, M., Kohen, L., Wiedemann, P., and Enzmann, V. (2001) The influence of pro-inflammatory cytokines on human retinal pigment epithelium cell receptors. *Graefes Arch Clin Exp Ophthalmol* **239**, 294-301.
- Holz, F. G., Bindewald-Wittich, A., Fleckenstein, M., Dreyhaupt, J., Scholl, H. P., and Schmitz-Valckenberg, S. (2007) Progression of geographic atrophy and impact of fundus autofluorescence patterns in age-related macular degeneration. *Am J Ophthalmol* **143**, 463-472.
- Hood, D. C., Bach, M., Brigell, M., Keating, D., Kondo, M., Lyons, J. S., and Palmowski-Wolfe, A. M. (2008) ISCEV guidelines for clinical multifocal electroretinography (2007 edition). *Doc Ophthalmol* **116**, 1-11.
- Hood, D. C. and Birch, D. G. (1993a) Human cone receptor activity: the leading edge of the a-wave and models of receptor activity. *Vis Neurosci* **10**, 857-871.
- Hood, D. C. and Birch, D. G. (1993b) Light adaptation of human rod receptors: the leading edge of the human a-wave and models of rod receptor activity. *Vision Res* **33**, 1605-1618.
- Hood, D. C. and Zhang, X. (2000) Multifocal ERG and VEP responses and visual fields: comparing disease-related changes. *Doc Ophthalmol* **100**, 115-137.
- Hoyng, C. B., Heutink, P., Testers, L., Pinckers, A., Deutman, A. F., and Oostra, B. A. (1996) Autosomal dominant central areolar choroidal dystrophy caused by a mutation in codon 142 in the peripherin/RDS gene. *Am J Ophthalmol* **121**, 623-629.
- Hsu, J. K., Thomas, M. A., Ibanez, H., and Green, W. R. (1995) Clinicopathologic studies of an eye after submacular membranectomy for choroidal neovascularization. *Retina* **15**, 43-52.
- Hu, D. N., Del Monte, M. A., Liu, S., and Maumenee, I. H. (1982) Morphology, phagocytosis, and vitamin A metabolism of cultured human retinal pigment epithelium. *Birth Defects Orig Artic Ser* **18**, 67-79.
- Hu, Y., Zhang, T., Wu, J., Li, Y., Lu, X., Qian, F., Yin, Z., and Ma, Z. (2008) Autologous transplantation of RPE with partial-thickness choroid after mechanical debridement of Bruch membrane in the rabbit. *Invest Ophthalmol Vis Sci* **49**, 3185-3192.
- Iandiev, I., Uckermann, O., Pannicke, T., Wurm, A., Tenckhoff, S., Pietsch, U. C., Reichenbach, A., Wiedemann, P., Bringmann, A., and Uhlmann, S. (2006) Glial cell reactivity in a porcine model of retinal detachment. *Invest Ophthalmol Vis Sci* **47**, 2161-2171.
- Idelson, M., Alper, R., Obolensky, A., Ben Shushan, E., Hemo, I., Yachimovich-Cohen, N., Khaner, H., Smith, Y., Wisner, O., Gropp, M., Cohen, M. A., Even-Ram, S., Berman-Zaken, Y., Matzrafi, L., Rechavi, G., Banin, E., and Reubinoff, B. (2009) Directed differentiation of human embryonic stem cells into functional retinal pigment epithelium cells. *Cell Stem Cell* **5**, 396-408.

- Ishibashi, K., Tian, J., and Handa, J. T. (2004) Similarity of mRNA phenotypes of morphologically normal macular and peripheral retinal pigment epithelial cells in older human eyes. *Invest Ophthalmol Vis Sci* **45**, 3291-3301.
- Jackson, T. L., Hillenkamp, J., Williamson, T. H., Clarke, K. W., Almubarak, A. I., and Marshall, J. (2003) An experimental model of rhegmatogenous retinal detachment: surgical results and glial cell response. *Invest Ophthalmol Vis Sci* **44**, 4026-4034.
- Jiang, L. Q. and Hamasaki, D. (1994) Corneal electroretinographic function rescued by normal retinal pigment epithelial grafts in retinal degenerative Royal College of Surgeons rats. *Invest Ophthalmol Vis Sci* **35**, 4300-4309.
- Jiang, L. Q., Jorquera, M., and Streilein, J. W. (1994) Immunologic consequences of intraocular implantation of retinal pigment epithelial allografts. *Exp Eye Res* **58**, 719-728.
- Joeres, S., Llacer, H., Heussen, F. M., Weiss, C., Kirchhof, B., and Jousen, A. M. (2008) Optical coherence tomography on autologous translocation of choroid and retinal pigment epithelium in age-related macular degeneration. *Eye* **22**, 782-789.
- Jousen, A. M., Heussen, F. M., Joeres, S., Llacer, H., Prinz, B., Rohrschneider, K., Maaijwee, K. J., van Meurs, J., and Kirchhof, B. (2006) Autologous translocation of the choroid and retinal pigment epithelium in age-related macular degeneration. *Am J Ophthalmol* **142**, 17-30.
- Jousen, A. M., Joeres, S., Fawzy, N., Heussen, F. M., Llacer, H., van Meurs, J. C., and Kirchhof, B. (2007) Autologous translocation of the choroid and retinal pigment epithelium in patients with geographic atrophy. *Ophthalmology* **114**, 551-560.
- Jurklics, B., Weismann, M., Husing, J., Sutter, E. E., and Bornfeld, N. (2002) Monitoring retinal function in neovascular maculopathy using multifocal electroretinography - early and long-term correlation with clinical findings. *Graefes Arch Clin Exp Ophthalmol* **240**, 244-264.
- Kaiser, P. K. (2006) Verteporfin therapy of subfoveal choroidal neovascularization in age-related macular degeneration: 5-year results of two randomized clinical trials with an open-label extension: TAP report no. 8. *Graefes Arch Clin Exp Ophthalmol* **244**, 1132-1142.
- Kaplan, J., Gerber, S., Larget-Piet, D., Rozet, J. M., Dollfus, H., Dufier, J. L., Odent, S., Postel-Vinay, A., Janin, N., Briard, M. L., and . (1993) A gene for Stargardt's disease (fundus flavimaculatus) maps to the short arm of chromosome 1. *Nat Genet* **5**, 308-311.
- Khurana, R. N., Fujii, G. Y., Walsh, A. C., Humayun, M. S., De Juan E Jr, and Sadda, S. R. (2005) Rapid recurrence of geographic atrophy after full macular translocation for nonexudative age-related macular degeneration. *Ophthalmology* **112**, 1586-1591.
- Kiilgaard, J. F., Andersen, M. V., Wiencke, A. K., Scherfig, E., la Cour, M., Tezel, T. H., and Prause, J. U. (2005) A new animal model of choroidal neovascularization. *Acta Ophthalmol Scand* **83**, 697-704.
- Kiilgaard, J. F., Prause, J. U., Prause, M., Scherfig, E., Nissen, M. H., and la Cour, M. (2007) Subretinal posterior pole injury induces selective proliferation of RPE cells in the periphery in in vivo studies in pigs. *Invest Ophthalmol Vis Sci* **48**, 355-360.
- Kiilgaard, J. F., Wiencke, A. K., Scherfig, E., Prause, J. U., and la Cour, M. (2002) Transplantation of allogenic anterior lens capsule to the subretinal space in pigs. *Acta Ophthalmol Scand* **80**, 76-81.
- Kim, S. Y., Sadda, S., Humayun, M. S., De Juan E Jr, Melia, B. M., and Green, W. R. (2002) Morphometric analysis of the macula in eyes with geographic atrophy due to age-related macular degeneration. *Retina* **22**, 464-470.

- Kirchhof, B., Joeres, S., Fawzy, N., Heussen, F. M., Prinz, B., and Joussem, A. M. (2006) Autologous peripheral RPE choroid patch graft in dry AMD. *Invest Ophthalmol Vis Sci* **47**, E-Abstract 2691.
- Klassen, H., Kiilgaard, J. F., Zahir, T., Ziaieian, B., Kirov, I., Scherfig, E., Warfvinge, K., and Young, M. J. (2007) Progenitor cells from the porcine neural retina express photoreceptor markers after transplantation to the subretinal space of allorecipients. *Stem Cells* **25**, 1222-1230.
- Klassen, H., Warfvinge, K., Schwartz, P. H., Kiilgaard, J. F., Shamie, N., Jiang, C., Samuel, M., Scherfig, E., Prather, R. S., and Young, M. J. (2008) Isolation of progenitor cells from GFP-transgenic pigs and transplantation to the retina of allorecipients. *Cloning Stem Cells* **10**, 391-402.
- Klaver, C. C., Wolfs, R. C., Vingerling, J. R., Hofman, A., and de Jong, P. T. (1998) Age-specific prevalence and causes of blindness and visual impairment in an older population: the Rotterdam Study. *Arch Ophthalmol* **116**, 653-658.
- Klein, R., Wang, Q., Klein, B. E., Moss, S. E., and Meuer, S. M. (1995) The relationship of age-related maculopathy, cataract, and glaucoma to visual acuity. *Invest Ophthalmol Vis Sci* **36**, 182-191.
- Klein, R. J., Zeiss, C., Chew, E. Y., Tsai, J. Y., Sackler, R. S., Haynes, C., Henning, A. K., SanGiovanni, J. P., Mane, S. M., Mayne, S. T., Bracken, M. B., Ferris, F. L., Ott, J., Barnstable, C., and Hoh, J. (2005) Complement factor H polymorphism in age-related macular degeneration. *Science* **308**, 385-389.
- Klimanskaya, I., Hipp, J., Rezai, K. A., West, M., Atala, A., and Lanza, R. (2004) Derivation and comparative assessment of retinal pigment epithelium from human embryonic stem cells using transcriptomics. *Cloning Stem Cells* **6**, 217-245.
- Knapp, A. G. and Schiller, P. H. (1984) The contribution of on-bipolar cells to the electroretinogram of rabbits and monkeys. A study using 2-amino-4-phosphonobutyrate (APB). *Vision Res* **24**, 1841-1846.
- Knudtson, M. D., Klein, R., Klein, B. E., Lee, K. E., Meuer, S. M., and Tomany, S. C. (2004) Location of lesions associated with age-related maculopathy over a 10-year period: the Beaver Dam Eye Study. *Invest Ophthalmol Vis Sci* **45**, 2135-2142.
- Knulst, A. J., Maaijwee, K., van Meurs, J. C., Wieringa, P. A., Breedveld, P., and Schutte, S. (2009) Micro-scale thermal tissue gripper. *Minim Invasive Ther Allied Technol* **18**, 8-14.
- Kociok, N. and Joussem, A. M. (2007) Varied expression of functionally important genes of RPE and choroid in the macula and in the periphery of normal human eyes. *Graefes Arch Clin Exp Ophthalmol* **245**, 101-113.
- Kohen, L., Enzmann, V., Faude, F., and Wiedemann, P. (1997) Mechanisms of graft rejection in the transplantation of retinal pigment epithelial cells. *Ophthalmic Res* **29**, 298-304.
- Kondo, M., Miyake, Y., Horiguchi, M., Suzuki, S., and Tanikawa, A. (1997) Recording multifocal electroretinograms with fundus monitoring. *Invest Ophthalmol Vis Sci* **38**, 1049-1052.
- Krebs, I., Binder, S., Stolba, U., Kellner, L., Glittenberg, C., and Goll, A. (2008) Subretinal surgery and transplantation of autologous pigment epithelial cells in retinal angiomatous proliferation. *Acta Ophthalmol* **86**, 504-509.



- Krishna, Y., Sheridan, C. M., Kent, D. L., Grierson, I., and Williams, R. L. (2007) Polydimethylsiloxane as a substrate for retinal pigment epithelial cell growth. *J Biomed Mater Res A* **80**, 669-678.
- Krumpaszkzy, H. G., Ludtke, R., Mickler, A., Klauss, V., and Selbmann, H. K. (1999) Blindness incidence in Germany. A population-based study from Wurttemberg-Hohenzollern. *Ophthalmologica* **213**, 176-182.
- Kunz, D., Pross, M., Konig, W., Lippert, H., and Manger, T. (1998) Diagnostic relevance of procalcitonin, IL-6 and cellular immune status in the early phase after liver transplantation. *Transplant Proc* **30**, 2398-2399.
- Kyhn M.V., K, Igaard, J. F., Lopez, A. G., Scherfig, E., Prause, J. U., and Cour, M. (2007) The multifocal electroretinogram (mfERG) in the pig. *Acta Ophthalmol Scand* **85**, 438-444.
- Kyhn, M. V., Kiilgaard, J. F., Lopez, A. G., Scherfig, E., Prause, J. U., and la Cour, M. (2008) Functional implications of short-term retinal detachment in porcine eyes: study by multifocal electroretinography. *Acta Ophthalmol* **86**, 18-25.
- Lai, C. C., Gouras, P., Doi, K., Lu, F., Kjeldbye, H., Goff, S. P., Pawliuk, R., Leboulch, P., and Tsang, S. H. (1999) Tracking RPE transplants labeled by retroviral gene transfer with green fluorescent protein. *Invest Ophthalmol Vis Sci* **40**, 2141-2146.
- Lai, C. C., Gouras, P., Doi, K., Tsang, S. H., Goff, S. P., and Ashton, P. (2000) Local immunosuppression prolongs survival of RPE xenografts labeled by retroviral gene transfer. *Invest Ophthalmol Vis Sci* **41**, 3134-3141.
- Lai, J. C., Lapolice, D. J., Stinnett, S. S., Meyer, C. H., Arieu, L. M., Keller, M. A., and Toth, C. A. (2002) Visual outcomes following macular translocation with 360-degree peripheral retinectomy. *Arch Ophthalmol* **120**, 1317-1324.
- Lalwani, G. A., Rosenfeld, P. J., Fung, A. E., Dubovy, S. R., Michels, S., Feuer, W., Davis, J. L., Flynn, H. W., Jr., and Esquiabro, M. (2009) A Variable-dosing Regimen with Intravitreal Ranibizumab for Neovascular Age-related Macular Degeneration: Year 2 of the PrONTO Study. *Am J Ophthalmol*.
- Lane, C., Boulton, M., and Marshall, J. (1989) Transplantation of retinal pigment epithelium using a pars plana approach. *Eye* **3** ( Pt 1), 27-32.
- Lange, C., Feltgen, N., Junker, B., Schulze-Bonsel, K., and Bach, M. (2009) Resolving the clinical acuity categories "hand motion" and "counting fingers" using the Freiburg Visual Acuity Test (FrACT). *Graefes Arch Clin Exp Ophthalmol* **247**, 137-142.
- Lassota, N., Kiilgaard, J. F., la Cour, M., Scherfig, E., and Prause, J. U. (2008) Natural history of choroidal neovascularization after surgical induction in an animal model. *Acta Ophthalmol* **86**, 495-503.
- Lassota, N., Kiilgaard, J. F., Prause, J. U., and la Cour, M. (2006) Correlation between clinical and histological features in a pig model of choroidal neovascularization. *Graefes Arch Clin Exp Ophthalmol* **244**, 394-398.
- Lassota, N., Kiilgaard, J. F., Prause, J. U., Qvortrup, K., Scherfig, E., and la Cour, M. (2007) Surgical induction of choroidal neovascularization in a porcine model. *Graefes Arch Clin Exp Ophthalmol* **245**, 1189-1198.
- Lavail, M. M., Li, L., Turner, J. E., and Yasumura, D. (1992) Retinal pigment epithelial cell transplantation in RCS rats: normal metabolism in rescued photoreceptors. *Exp Eye Res* **55**, 555-562.

- Lawrence, J. M., Sauve, Y., Keegan, D. J., Coffey, P. J., Hetherington, L., Girman, S., Whiteley, S. J., Kwan, A. S., Pheby, T., and Lund, R. D. (2000) Schwann cell grafting into the retina of the dystrophic RCS rat limits functional deterioration. Royal College of Surgeons. *Invest Ophthalmol Vis Sci* **41**, 518-528.
- Lee, C. J., Huie, P., Leng, T., Peterman, M. C., Marmor, M. F., Blumenkranz, M. S., Bent, S. F., and Fishman, H. A. (2002) Microcontact printing on human tissue for retinal cell transplantation. *Arch Ophthalmol* **120**, 1714-1718.
- Legge, G. E., Pelli, D. G., Rubin, G. S., and Schleske, M. M. (1985a) Psychophysics of reading-I. Normal vision. *Vision Res* **25**, 239-252.
- Legge, G. E., Ross, J. A., Isenberg, L. M., and LaMay, J. M. (1992) Psychophysics of reading. Clinical predictors of low-vision reading speed. *Invest Ophthalmol Vis Sci* **33**, 677-687.
- Legge, G. E., Ross, J. A., Luebker, A., and LaMay, J. M. (1989) Psychophysics of reading. VIII. The Minnesota Low-Vision Reading Test. *Optom Vis Sci* **66**, 843-853.
- Legge, G. E., Rubin, G. S., Pelli, D. G., and Schleske, M. M. (1985b) Psychophysics of reading-II. Low vision. *Vision Res* **25**, 253-265.
- Lei, H. and Schuchard, R. A. (1997) Using two preferred retinal loci for different lighting conditions in patients with central scotomas. *Invest Ophthalmol Vis Sci* **38**, 1812-1818.
- Lewis, G. P., Sethi, C. S., Carter, K. M., Charteris, D. G., and Fisher, S. K. (2005) Microglial cell activation following retinal detachment: a comparison between species. *Mol Vis* **11**, 491-500.
- Lewis, H., Straatsma, B. R., Foos, R. Y., and Lightfoot, D. O. (1985) Reticular degeneration of the pigment epithelium. *Ophthalmology* **92**, 1485-1495.
- Li, K. K. and Wong, D. (2007) Avoiding retinal slippage during macular translocation surgery with 360 retinotomy. *Graefes Arch Clin Exp Ophthalmol*.
- Li, L., Baroja, M. L., Majumdar, A., Chadwick, K., Rouleau, A., Gallacher, L., Ferber, I., Lebkowski, J., Martin, T., Madrenas, J., and Bhatia, M. (2004) Human embryonic stem cells possess immune-privileged properties. *Stem Cells* **22**, 448-456.
- Li, L. and Turner, J. E. (1991) Optimal conditions for long-term photoreceptor cell rescue in RCS rats: the necessity for healthy RPE transplants. *Exp Eye Res* **52**, 669-679.
- Li, L. X. and Turner, J. E. (1988a) Inherited retinal dystrophy in the RCS rat: prevention of photoreceptor degeneration by pigment epithelial cell transplantation. *Exp Eye Res* **47**, 911-917.
- Li, L. X. and Turner, J. E. (1988b) Transplantation of retinal pigment epithelial cells to immature and adult rat hosts: short- and long-term survival characteristics. *Exp Eye Res* **47**, 771-785.
- Liang, J., Williams, D. R., and Miller, D. T. (1997) Supernormal vision and high-resolution retinal imaging through adaptive optics. *J Opt Soc Am A Opt Image Sci Vis* **14**, 2884-2892.
- Lin, N., Fan, W., Sheedlo, H. J., Aschenbrenner, J. E., and Turner, J. E. (1996) Photoreceptor repair in response to RPE transplants in RCS rats: outer segment regeneration. *Curr Eye Res* **15**, 1069-1077.
- Little, C. W., Castillo, B., DiLoreto, D. A., Cox, C., Wyatt, J., del Cerro, C., and Del Cerro, M. (1996) Transplantation of human fetal retinal pigment epithelium rescues photoreceptor cells

from degeneration in the Royal College of Surgeons rat retina. *Invest Ophthalmol Vis Sci* **37**, 204-211.

Little, C. W., Cox, C., Wyatt, J., del Cerro, C., and Del Cerro, M. (1998) Correlates of photoreceptor rescue by transplantation of human fetal RPE in the RCS rat. *Exp Neurol* **149**, 151-160.

Lopez, P. F., Grossniklaus, H. E., Lambert, H. M., Aaberg, T. M., Capone, A., Jr., Sternberg, P., Jr., and L'Hernault, N. (1991) Pathologic features of surgically excised subretinal neovascular membranes in age-related macular degeneration. *Am J Ophthalmol* **112**, 647-656.

Lopez, R., Gouras, P., Brittis, M., and Kjeldbye, H. (1987) Transplantation of cultured rabbit retinal epithelium to rabbit retina using a closed-eye method. *Invest Ophthalmol Vis Sci* **28**, 1131-1137.

Lopez, R., Gouras, P., Kjeldbye, H., Sullivan, B., Reppucci, V., Brittis, M., Wapner, F., and Goluboff, E. (1989) Transplanted retinal pigment epithelium modifies the retinal degeneration in the RCS rat. *Invest Ophthalmol Vis Sci* **30**, 586-588.

Lovie-Kitchin, J. E. and Bailey, I. (1981) Task complexity and visual acuity in senile macular degenerati. *Aust J Optom* **64**, 235-242.

Lu, B., Malcuit, C., Wang, S., Girman, S., Francis, P., Lemieux, L., Lanza, R., and Lund, R. (2009) Long-term Safety and Function of RPE from Human Embryonic Stem Cells in Preclinical Models of Macular Degeneration. *Stem Cells*.

Luke, C., Aisenbrey, S., Luke, M., Marzella, G., Bartz-Schmidt, K. U., and Walter, P. (2001) Electrophysiological changes after 360 degrees retinotomy and macular translocation for subfoveal choroidal neovascularisation in age related macular degeneration. *Br J Ophthalmol* **85**, 928-932.

Luke, M., Ziemssen, F., Volker, M., Altpeter, E., Beutel, J., Besch, D., Bartz-Schmidt, K. U., and Gelissen, F. (2009) Full macular translocation (FMT) versus photodynamic therapy (PDT) with verteporfin in the treatment of neovascular age-related macular degeneration: 2-year results of a prospective, controlled, randomised pilot trial (FMT-PDT). *Graefes Arch Clin Exp Ophthalmol* **247**, 745-754.

Lund, R. D., Adamson, P., Sauve, Y., Keegan, D. J., Girman, S. V., Wang, S., Winton, H., Kanuga, N., Kwan, A. S., Beauchene, L., Zerbib, A., Hetherington, L., Couraud, P. O., Coffey, P., and Greenwood, J. (2001a) Subretinal transplantation of genetically modified human cell lines attenuates loss of visual function in dystrophic rats. *Proc Natl Acad Sci U S A* **98**, 9942-9947.

Lund, R. D., Kwan, A. S., Keegan, D. J., Sauve, Y., Coffey, P. J., and Lawrence, J. M. (2001b) Cell transplantation as a treatment for retinal disease. *Prog Retin Eye Res* **20**, 415-449.

Lund, R. D., Wang, S., Klimanskaya, I., Holmes, T., Ramos-Kelsey, R., Lu, B., Girman, S., Bischoff, N., Sauve, Y., and Lanza, R. (2006) Human embryonic stem cell-derived cells rescue visual function in dystrophic RCS rats. *Cloning Stem Cells* **8**, 189-199.

Ma, Z., Han, L., Wang, C., Dou, H., Hu, Y., Feng, X., Xu, Y., Wang, Z., Yin, Z., and Liu, Y. (2009) Autologous transplantation of retinal pigment epithelium-Bruch's membrane complex for hemorrhagic age-related macular degeneration. *Invest Ophthalmol Vis Sci* **50**, 2975-2981.

Maaijwee, K., Heimann, H., Missotten, T., Mulder, P., Jousen, A., and van Meurs, J. (2007a) Retinal pigment epithelium and choroid translocation in patients with exudative age-related macular degeneration: long-term results. *Graefes Arch Clin Exp Ophthalmol* **245**, 1681-1689.

- Maaijwee, K., Joussem, A. M., Kirchhof, B., and van Meurs, J. C. (2008a) Retinal pigment epithelium (RPE)-choroid graft translocation in the treatment of an RPE tear: preliminary results. *Br J Ophthalmol* **92**, 526-529.
- Maaijwee, K., Koolen, T., Rosenbrand, D., Jacobs, E., Kleinheerenbrink, S., Knulst, A., Bos, J., Holland, W. P., Brouwer, A., van Meurs, J. C., and Schutte, S. (2008b) Threshold amplitude and frequency for ocular tissue release from a vibrating instrument: an experimental study. *Invest Ophthalmol Vis Sci* **49**, 1629-1632.
- Maaijwee, K., Missotten, T., Mulder, P., and van Meurs, J. C. (2008c) Influence of Intraoperative Course on Visual Outcome after an RPE-Choroid Translocation. *Invest Ophthalmol Vis Sci* **49**, 758-761.
- Maaijwee, K., Van Den Biesen, P. R., Missotten, T., and van Meurs, J. C. (2008d) Angiographic evidence for revascularization of an rpe-choroid graft in patients with age-related macular degeneration. *Retina* **28**, 498-503.
- Maaijwee, K. J., van Meurs, J. C., Kirchhof, B., Mooij, C. M., Fischer, J. H., Mackiewicz, J., Kobuch, K., and Joussem, A. M. (2007b) Histological evidence for revascularisation of an autologous retinal pigment epithelium--choroid graft in the pig. *Br J Ophthalmol* **91**, 546-550.
- Machemer, R. and Steinhorst, U. H. (1993) Retinal separation, retinotomy, and macular relocation: II. A surgical approach for age-related macular degeneration? *Graefes Arch Clin Exp Ophthalmol* **231**, 635-641.
- Mackiewicz, J., Muhling, B., Hiebl, W., Meinert, H., Maaijwee, K., Kociok, N., Luke, C., Zagorski, Z., Kirchhof, B., and Joussem, A. M. (2007) In vivo retinal tolerance of various heavy silicone oils. *Invest Ophthalmol Vis Sci* **48**, 1873-1883.
- MacLaren, R. E. and Aylward, G. W. (2005) Delayed atrophy of the retinal pigment epithelium after submacular surgery. *Eur J Ophthalmol* **15**, 170-172.
- MacLaren, R. E., Bird, A. C., Sathia, P. J., and Aylward, G. W. (2005) Long-term results of submacular surgery combined with macular translocation of the retinal pigment epithelium in neovascular age-related macular degeneration. *Ophthalmology* **112**, 2081-2087.
- MacLaren, R. E., Uppal, G. S., Balaggan, K. S., Tufail, A., Munro, P. M., Milliken, A. B., Ali, R. R., Rubin, G. S., Aylward, G. W., and da Cruz, L. (2007) Autologous transplantation of the retinal pigment epithelium and choroid in the treatment of neovascular age-related macular degeneration. *Ophthalmology* **114**, 561-570.
- Maguire, A. M., Simonelli, F., Pierce, E. A., Pugh, E. N., Jr., Mingozzi, F., Bennicelli, J., Banfi, S., Marshall, K. A., Testa, F., Surace, E. M., Rossi, S., Lyubarsky, A., Arruda, V. R., Konkle, B., Stone, E., Sun, J., Jacobs, J., Dell'Osso, L., Hertle, R., Ma, J. X., Redmond, T. M., Zhu, X., Hauck, B., Zelenai, O., Shindler, K. S., Maguire, M. G., Wright, J. F., Volpe, N. J., McDonnell, J. W., Auricchio, A., High, K. A., and Bennett, J. (2008) Safety and efficacy of gene transfer for Leber's congenital amaurosis. *N Engl J Med* **358**, 2240-2248.
- Maguire, M. G. (1999) Natural history. In: *Age-related Macular Degeneration*, pp. 17-30. Eds J. W. Berger, S. L. Fine, M. G. Maguire. Mosby: St. Louis.
- Mainster, M. A., Timberlake, G. T., Webb, R. H., and Hughes, G. W. (1982) Scanning laser ophthalmoscopy. Clinical applications. *Ophthalmology* **89**, 852-857.
- Majji, A. B. and De Juan E Jr (2000) Retinal pigment epithelial autotransplantation: morphological changes in retina and choroid. *Graefes Arch Clin Exp Ophthalmol* **238**, 779-791.

- Mangione, C. M., Lee, P. P., Gutierrez, P. R., Spritzer, K., Berry, S., and Hays, R. D. (2001) Development of the 25-item National Eye Institute Visual Function Questionnaire. *Arch Ophthalmol* **119**, 1050-1058.
- Mangione, C. M., Lee, P. P., Pitts, J., Gutierrez, P., Berry, S., and Hays, R. D. (1998) Psychometric properties of the National Eye Institute Visual Function Questionnaire (NEI-VFQ). NEI-VFQ Field Test Investigators. *Arch Ophthalmol* **116**, 1496-1504.
- Marc, R. E., Jones, B. W., Watt, C. B., and Strettoi, E. (2003) Neural remodeling in retinal degeneration. *Prog Retin Eye Res* **22**, 607-655.
- Marmor, M. F., Holder, G. E., Seeliger, M. W., and Yamamoto, S. (2004) Standard for clinical electroretinography (2004 update). *Doc Ophthalmol* **108**, 107-114.
- Marmor, M. F., Hood, D. C., Keating, D., Kondo, M., Seeliger, M. W., and Miyake, Y. (2003) Guidelines for basic multifocal electroretinography (mfERG). *Doc Ophthalmol* **106**, 105-115.
- Marmorstein, A. D., Marmorstein, L. Y., Rayborn, M., Wang, X., Hollyfield, J. G., and Petrukhin, K. (2000) Bestrophin, the product of the Best vitelliform macular dystrophy gene (VMD2), localizes to the basolateral plasma membrane of the retinal pigment epithelium. *Proc Natl Acad Sci U S A* **97**, 12758-12763.
- Marmor, M. F. and Wolfensberger, T. J. (1998) *The retinal pigment epithelium*. Oxford University Press: Oxford/New York.
- Mata, N. L., Radu, R. A., Clemmons, R. C., and Travis, G. H. (2002) Isomerization and oxidation of vitamin a in cone-dominant retinas: a novel pathway for visual-pigment regeneration in daylight. *Neuron* **36**, 69-80.
- Maw, M. A., Kennedy, B., Knight, A., Bridges, R., Roth, K. E., Mani, E. J., Mukkadan, J. K., Nancarrow, D., Crabb, J. W., and Denton, M. J. (1997) Mutation of the gene encoding cellular retinaldehyde-binding protein in autosomal recessive retinitis pigmentosa. *Nat Genet* **17**, 198-200.
- Mayerson, P. L., Hall, M. O., Clark, V., and Abrams, T. (1985) An improved method for isolation and culture of rat retinal pigment epithelial cells. *Invest Ophthalmol Vis Sci* **26**, 1599-1609.
- McBain, V. A., Forrester, J. V., and Lois, N. (2008) Fundus autofluorescence in the diagnosis of cystoid macular oedema. *Br J Ophthalmol* **92**, 946-949.
- McGill, T. J., Lund, R. D., Douglas, R. M., Wang, S., Lu, B., and Prusky, G. T. (2004) Preservation of vision following cell-based therapies in a model of retinal degenerative disease. *Vision Res* **44**, 2559-2566.
- McLeod, D. S., Taomoto, M., Otsuji, T., Green, W. R., Sunness, J. S., and Lutty, G. A. (2002) Quantifying changes in RPE and choroidal vasculature in eyes with age-related macular degeneration. *Invest Ophthalmol Vis Sci* **43**, 1986-1993.
- Meleth, A. D., Mettu, P., Agron, E., Chew, E. Y., Sadda, S. R., Ferris, F. L., and Wong, W. T. (2010) Changes in Retinal Sensitivity in Geographic Atrophy Progression as Measured by Microperimetry. *Invest Ophthalmol Vis Sci*.
- Mendes-Jorge, L., Ramos, D., Luppo, M., Llombart, C., Alexandre-Pires, G., Nacher, V., Melgarejo, V., Correia, M., Navarro, M., Carretero, A., Tafuro, S., Rodriguez-Baeza, A., Esperanca-Pina, J. A., Bosch, F., and Ruberte, J. (2009) Scavenger function of resident autofluorescent perivascular macrophages and their contribution to the maintenance of the blood-retinal barrier. *Invest Ophthalmol Vis Sci* **50**, 5997-6005.

- Michaelides, M., Holder, G. E., Bradshaw, K., Hunt, D. M., and Moore, A. T. (2005) Cone-rod dystrophy, intrafamilial variability, and incomplete penetrance associated with the R172W mutation in the peripherin/RDS gene. *Ophthalmology* **112**, 1592-1598.
- Michaelides, M., Hunt, D. M., and Moore, A. T. (2003) The genetics of inherited macular dystrophies. *J Med Genet* **40**, 641-650.
- Michels, S. and Schmidt-Erfurth, U. (2001) Photodynamic therapy with verteporfin: a new treatment in ophthalmology. *Semin Ophthalmol* **16**, 201-206.
- Midena, E., Radin, P. P., Pilotto, E., Ghirlando, A., Convento, E., and Varano, M. (2004) Fixation pattern and macular sensitivity in eyes with subfoveal choroidal neovascularization secondary to age-related macular degeneration. A microperimetry study. *Semin Ophthalmol* **19**, 55-61.
- Mlambo, G. and Sigola, L. B. (2003) Rifampicin and dexamethasone have similar effects on macrophage phagocytosis of zymosan, but differ in their effects on nitrite and TNF-alpha production. *Int Immunopharmacol* **3**, 513-522.
- Montezuma, S. R., Loewenstein, J., Scholz, C., and Rizzo, J. F., III (2006) Biocompatibility of materials implanted into the subretinal space of Yucatan pigs. *Invest Ophthalmol Vis Sci* **47**, 3514-3522.
- Morgan, J. I., Dubra, A., Wolfe, R., Merigan, W. H., and Williams, D. R. (2009) In vivo autofluorescence imaging of the human and macaque retinal pigment epithelial cell mosaic. *Invest Ophthalmol Vis Sci* **50**, 1350-1359.
- Mori, F., Ishiko, S., Kitaya, N., Takamiya, A., Sato, E., Hikichi, T., and Yoshida, A. (2001) Scotoma and fixation patterns using scanning laser ophthalmoscope microperimetry in patients with macular dystrophy. *Am J Ophthalmol* **132**, 897-902.
- MPS Group (1991) Subfoveal neovascular lesions in age-related macular degeneration. Guidelines for evaluation and treatment in the macular photocoagulation study. Macular Photocoagulation Study Group. *Arch Ophthalmol* **109**, 1242-1257.
- MPS Group (1994a) Laser photocoagulation for juxtafoveal choroidal neovascularization. Five-year results from randomized clinical trials. Macular Photocoagulation Study Group. *Arch Ophthalmol* **112**, 500-509.
- MPS Group (1994b) Persistent and recurrent neovascularization after laser photocoagulation for subfoveal choroidal neovascularization of age-related macular degeneration. Macular Photocoagulation Study Group. *Arch Ophthalmol* **112**, 489-499.
- MPS Group (1994c) Visual outcome after laser photocoagulation for subfoveal choroidal neovascularization secondary to age-related macular degeneration. The influence of initial lesion size and initial visual acuity. Macular Photocoagulation Study Group. *Arch Ophthalmol* **112**, 480-488.
- Mruthyunjaya, P., Stinnett, S. S., and Toth, C. A. (2004) Change in visual function after macular translocation with 360 degrees retinectomy for neovascular age-related macular degeneration. *Ophthalmology* **111**, 1715-1724.
- Mruthyunjaya, P., Stinnett, S. S., and Toth, C. A. (2005) Impact of fluorescein angiographic characteristics of macular lesions on outcomes after macular translocation 360 degree surgery in eyes with age-related macular degeneration. *Retina* **25**, 597-607.
- Mullen, R. J. and Lavail, M. M. (1976) Inherited retinal dystrophy: primary defect in pigment epithelium determined with experimental rat chimeras. *Science* **192**, 799-801.

- Munoz, B., West, S. K., Rubin, G. S., Schein, O. D., Quigley, H. A., Bressler, S. B., and Bandeen-Roche, K. (2000) Causes of blindness and visual impairment in a population of older Americans: The Salisbury Eye Evaluation Study. *Arch Ophthalmol* **118**, 819-825.
- Nasir, M. A., Sugino, I., and Zarbin, M. A. (1997) Decreased choriocapillaris perfusion following surgical excision of choroidal neovascular membranes in age-related macular degeneration. *Br J Ophthalmol* **81**, 481-489.
- Neveu, M. M., Tufail, A., Dowler, J. G., and Holder, G. E. (2006) A comparison of pattern and multifocal electroretinography in the evaluation of age-related macular degeneration and its treatment with photodynamic therapy. *Doc Ophthalmol* **113**, 71-81.
- Nicolini, J., Kiilgaard, J. F., Wiencke, A. K., Heegaard, S., Scherfig, E., Prause, J. U., and la Cour, M. (2000) The anterior lens capsule used as support material in RPE cell-transplantation. *Acta Ophthalmol Scand* **78**, 527-531.
- Nilsson, U. L., Frennesson, C., and Nilsson, S. E. (2003) Patients with AMD and a large absolute central scotoma can be trained successfully to use eccentric viewing, as demonstrated in a scanning laser ophthalmoscope. *Vision Res* **43**, 1777-1787.
- Nowak, J. Z. (2006) Age-related macular degeneration (AMD): pathogenesis and therapy. *Pharmacol Rep* **58**, 353-363.
- Obata, R., Yanagi, Y., and Tamaki, Y. (2006) Postoperative assessment of retinal function using a multifocal electroretinogram after the removal of subfoveal choroidal neovascularization secondary to age-related macular degeneration. *Jpn J Ophthalmol* **50**, 479-482.
- Oganesian, A., Gabrielian, K., Ernest, J. T., and Patel, S. C. (1999) A new model of retinal pigment epithelium transplantation with microspheres. *Arch Ophthalmol* **117**, 1192-1200.
- Ogata, N., Nishizawa, M., Ando, A., and Uyama, M. (1999) Transfection of basic fibroblast growth factor (bFGF) gene or bFGF antisense fene into human retinal pigment epithelial cells. *Graefes Arch Clin Exp Ophthalmol* **237**, 678-684.
- Ohji, M., Fujikado, T., Kusaka, S., Hayashi, A., Hosohata, J., Ikuno, Y., Sawa, M., Kubota, A., Hashida, N., and Tano, Y. (2001) Comparison of three techniques of foveal translocation in patients with subfoveal choroidal neovascularization resulting from age-related macular degeneration. *Am J Ophthalmol* **132**, 888-896.
- Osakada, F., Ikeda, H., Sasai, Y., and Takahashi, M. (2009) Stepwise differentiation of pluripotent stem cells into retinal cells. *Nat Protoc* **4**, 811-824.
- Osusky, R., Jiang, M., Buchi, E. R., Spee, C., Ye, J., and Ryan, S. J. (1995) beta-Galactosidase transgene expression in transplanted rabbit retinal pigment epithelial cells in vivo. *Graefes Arch Clin Exp Ophthalmol* **233**, 220-225.
- Oyagi, T., Fujikado, T., Hosohata, J., Ohji, M., Kamei, M., Bessho, K., and Tano, Y. (2004) Foveal sensitivity and fixation stability before and after macular translocation with 360-degree retinotomy. *Retina* **24**, 548-555.
- Pang, J. J., Chang, B., Kumar, A., Nusinowitz, S., Noorwez, S. M., Li, J., Rani, A., Foster, T. C., Chiodo, V. A., Doyle, T., Li, H., Malhotra, R., Teusner, J. T., McDowell, J. H., Min, S. H., Li, Q., Kaushal, S., and Hauswirth, W. W. (2006) Gene therapy restores vision-dependent behavior as well as retinal structure and function in a mouse model of RPE65 Leber congenital amaurosis. *Mol Ther* **13**, 565-572.
- Patel, P. J., Chen, F. K., Rubin, G. S., and Tufail, A. (2008) Intersession repeatability of visual acuity scores in age-related macular degeneration. *Invest Ophthalmol Vis Sci* **49**, 4347-4352.

- Pelli, D. G., Robson, J. G., and Wilkins, A. J. (1988) The design of a new letter chart for measuring contrast sensitivity. *Clin Vision Sci* **2**, 187-199.
- Pertile, G. and Claes, C. (2002) Macular translocation with 360 degree retinotomy for management of age-related macular degeneration with subfoveal choroidal neovascularization. *Am J Ophthalmol* **134**, 560-565.
- Petersen, J., Ritzau-Tondrow, U., and Hoerauf, H. (2008) [Autologous translocation of large retinal pigment epithelium choroid patches in age-related macular degeneration]. *Klin Monatsbl Augenheilkd* **225**, 286-291.
- Petters, R. M., Alexander, C. A., Wells, K. D., Collins, E. B., Sommer, J. R., Blanton, M. R., Rojas, G., Hao, Y., Flowers, W. L., Banin, E., Cideciyan, A. V., Jacobson, S. G., and Wong, F. (1997) Genetically engineered large animal model for studying cone photoreceptor survival and degeneration in retinitis pigmentosa. *Nat Biotechnol* **15**, 965-970.
- Peyman, G. A., Blinder, K. J., Paris, C. L., Alturki, W., Nelson, N. C., Jr., and Desai, U. (1991) A technique for retinal pigment epithelium transplantation for age-related macular degeneration secondary to extensive subfoveal scarring. *Ophthalmic Surg* **22**, 102-108.
- Peyman, G. A., Fishman, G. A., Sanders, D. R., Apple, D. J., and Vlcek, J. K. (1975) Biopsy of human scleral-chorioretinal tissue. *Invest Ophthalmol* **14**, 707-710.
- Phillips, S. J., Sadda, S. R., Tso, M. O., Humayan, M. S., De Juan E Jr, and Binder, S. (2003) Autologous transplantation of retinal pigment epithelium after mechanical debridement of Bruch's membrane. *Curr Eye Res* **26**, 81-88.
- Pieramici, D. J., Bressler, S. B., Koester, J. M., and Bressler, N. M. (2006) Occult with no classic subfoveal choroidal neovascular lesions in age-related macular degeneration: clinically relevant natural history information in larger lesions with good vision from the Verteporfin in Photodynamic Therapy (VIP) Trial: VIP Report No. 4. *Arch Ophthalmol* **124**, 660-664.
- Pinilla, I., Lund, R. D., Lu, B., and Sauve, Y. (2005) Measuring the cone contribution to the ERG b-wave to assess function and predict anatomical rescue in RCS rats. *Vision Res* **45**, 635-641.
- Piriou-Guzylack, L. and Salmon, H. (2008) Membrane markers of the immune cells in swine: an update. *Vet Res* **39**, 54.
- Poloschek, C. M., Rupp, V., Krastel, H., and Holz, F. G. (2003) Multifocal ERG recording with simultaneous fundus monitoring using a confocal scanning laser ophthalmoscope. *Eye* **17**, 159-166.
- Querques, G., Bocco, M. C., Soubrane, G., and Souied, E. H. (2008) Intravitreal ranibizumab (Lucentis) for choroidal neovascularization associated with vitelliform macular dystrophy. *Acta Ophthalmol* **86**, 694-695.
- Rayner, K., Well, A. D., and Pollatsek, A. (1980) Asymmetry of the effective visual field in reading. *Percept Psychophys* **27**, 537-544.
- Reinhard, J., Messias, A., Dietz, K., MacKeben, M., Lakmann, R., Scholl, H. P., Apfelstedt-Sylla, E., Weber, B. H., Seeliger, M. W., Zrenner, E., and Trauzettel-Klosinski, S. (2007) Quantifying fixation in patients with Stargardt disease. *Vision Res* **47**, 2076-2085.
- Rezai, K. A., Farrokh-Siar, L., Godowski, K., Patel, S. C., and Ernest, J. T. (2000) A model for xenogenic immune response. *Graefes Arch Clin Exp Ophthalmol* **238**, 352-358.



- Rezai, K. A., Semnani, R. T., Farrokh-Siar, L., Hamann, K. J., Patel, S. C., Ernest, J. T., and van Seventer, G. A. (1999) Human fetal retinal pigment epithelial cells induce apoptosis in allogenic T-cells in a Fas ligand and PGE2 independent pathway. *Curr Eye Res* **18**, 430-439.
- Rezai, K. A., Semnani, R. T., Patel, S. C., Ernest, J. T., and van Seventer, G. A. (1997) The immunogenic potential of human fetal retinal pigment epithelium and its relation to transplantation. *Invest Ophthalmol Vis Sci* **38**, 2662-2671.
- Robbins, H. G. and McMurray, N. E. (1988) Psychological and visual factors in low vision rehabilitation of patients with age related macular disease. *J Vis Rehabil* **2**, 11-21.
- Robertson, N. J., Brook, F. A., Gardner, R. L., Cobbold, S. P., Waldmann, H., and Fairchild, P. J. (2007) Embryonic stem cell-derived tissues are immunogenic but their inherent immune privilege promotes the induction of tolerance. *Proc Natl Acad Sci U S A* **104**, 20920-20925.
- Rohrschneider, K., Becker, M., Kruse, F. E., Fendrich, T., and Volcker, H. E. (1995) Stability of fixation: results of fundus-controlled examination using the scanning laser ophthalmoscope. *Ger J Ophthalmol* **4**, 197-202.
- Rohrschneider, K., Springer, C., Bultmann, S., and Volcker, H. E. (2005) Microperimetry--comparison between the micro perimeter 1 and scanning laser ophthalmoscope--fundus perimetry. *Am J Ophthalmol* **139**, 125-134.
- Roorda, A., Zhang, Y., and Duncan, J. L. (2007) High-resolution in vivo imaging of the RPE mosaic in eyes with retinal disease. *Invest Ophthalmol Vis Sci* **48**, 2297-2303.
- Rosa, R. H., Thomas, M. A., and Green, W. R. (1996) Clinicopathologic correlation of submacular membranectomy with retention of good vision in a patient with age-related macular degeneration. *Arch Ophthalmol* **114**, 480-487.
- Rosenfeld, P. J., Brown, D. M., Heier, J. S., Boyer, D. S., Kaiser, P. K., Chung, C. Y., and Kim, R. Y. (2006) Ranibizumab for neovascular age-related macular degeneration. *N Engl J Med* **355**, 1419-1431.
- Rosolen, S. G., Rigaudiere, F., Saint-Macary, G., and Lachapelle, P. (1999) Recording the photopic electroretinogram from conscious adult Yucatan micropigs. *Doc Ophthalmol* **98**, 197-205.
- Rotenstreich, Y., Fishman, G. A., and Anderson, R. J. (2003) Visual acuity loss and clinical observations in a large series of patients with Stargardt disease. *Ophthalmology* **110**, 1151-1158.
- Ruiz, A., Kuehn, M. H., Andorf, J. L., Stone, E., Hageman, G. S., and Bok, D. (2001) Genomic organization and mutation analysis of the gene encoding lecithin retinol acyltransferase in human retinal pigment epithelium. *Invest Ophthalmol Vis Sci* **42**, 31-37.
- Russell, S. R., Hudson, H. L., and Jerdan, J. A. (2007) Anecortave acetate for the treatment of exudative age-related macular degeneration-a review of clinical outcomes. *Surv Ophthalmol* **52 Suppl 1**, S79-S90.
- Rymer, J. and Wildsoet, C. F. (2005) The role of the retinal pigment epithelium in eye growth regulation and myopia: a review. *Vis Neurosci* **22**, 251-261.
- Saigo, Y., Abe, T., Hojo, M., Tomita, H., Sugano, E., and Tamai, M. (2004) Transplantation of transduced retinal pigment epithelium in rats. *Invest Ophthalmol Vis Sci* **45**, 1996-2004.
- Sakamoto, T., Sakamoto, H., Murphy, T. L., Spee, C., Soriano, D., Ishibashi, T., Hinton, D. R., and Ryan, S. J. (1995) Vessel formation by choroidal endothelial cells in vitro is modulated by retinal pigment epithelial cells. *Arch Ophthalmol* **113**, 512-520.

- Sarks, J., Tang, K., Killingsworth, M., Arnold, J., and Sarks, S. (2006) Development of atrophy of the retinal pigment epithelium around disciform scars. *Br J Ophthalmol* **90**, 442-446.
- Sauve, Y., Girman, S. V., Wang, S., Keegan, D. J., and Lund, R. D. (2002) Preservation of visual responsiveness in the superior colliculus of RCS rats after retinal pigment epithelium cell transplantation. *Neuroscience* **114**, 389-401.
- Sauve, Y., Klassen, H., Whiteley, S. J., and Lund, R. D. (1998) Visual field loss in RCS rats and the effect of RPE cell transplantation. *Exp Neurol* **152**, 243-250.
- Sauve, Y., Lu, B., and Lund, R. D. (2004) The relationship between full field electroretinogram and perimetry-like visual thresholds in RCS rats during photoreceptor degeneration and rescue by cell transplants. *Vision Res* **44**, 9-18.
- Sauve, Y., Pinilla, I., and Lund, R. D. (2006) Partial preservation of rod and cone ERG function following subretinal injection of ARPE-19 cells in RCS rats. *Vision Res* **46**, 1459-1472.
- Sawa, M., Gomi, F., Ohji, M., Tsujikawa, M., Fujikado, T., and Tano, Y. (2008) Fundus autofluorescence after full macular translocation surgery for myopic choroidal neovascularization. *Graefes Arch Clin Exp Ophthalmol* **246**, 1087-1095.
- Schanze, T., Sachs, H. G., Wiesenack, C., Brunner, U., and Sailer, H. (2006) Implantation and testing of subretinal film electrodes in domestic pigs. *Exp Eye Res* **82**, 332-340.
- Schmitz-Valckenberg, S., Holz, F. G., Bird, A. C., and Spaide, R. F. (2008) Fundus autofluorescence imaging: review and perspectives. *Retina* **28**, 385-409.
- Scholl, H. P., Bellmann, C., Dandekar, S. S., Bird, A. C., and Fitzke, F. W. (2004) Photopic and scotopic fine matrix mapping of retinal areas of increased fundus autofluorescence in patients with age-related maculopathy. *Invest Ophthalmol Vis Sci* **45**, 574-583.
- Scholl, H. P., Charbel, I. P., Walier, M., Janzer, S., Pollok-Kopp, B., Borncke, F., Fritsche, L. G., Chong, N. V., Fimmers, R., Wienker, T., Holz, F. G., Weber, B. H., and Oppermann, M. (2008) Systemic complement activation in age-related macular degeneration. *PLoS ONE* **3**, e2593.
- Schuchard, R. A. (2005) Preferred retinal loci and macular scotoma characteristics in patients with age-related macular degeneration. *Can J Ophthalmol* **40**, 303-312.
- Schuermans, R. P., Lege, W. A., Lith, G. H., and Oosterhuis, J. A. (1977) The influence of photocoagulation of the retina on the electroretinogram. *Doc Ophthalmol* **42**, 369-373.
- Schwahn, H. N., Gekeler, F., Kohler, K., Kobuch, K., Sachs, H. G., Schulmeyer, F., Jakob, W., Gabel, V. P., and Zrenner, E. (2001) Studies on the feasibility of a subretinal visual prosthesis: data from Yucatan micropig and rabbit. *Graefes Arch Clin Exp Ophthalmol* **239**, 961-967.
- Seaton, A. D., Sheedlo, H. J., and Turner, J. E. (1994) A primary role for RPE transplants in the inhibition and regression of neovascularization in the RCS rat. *Invest Ophthalmol Vis Sci* **35**, 162-169.
- Seaton, A. D. and Turner, J. E. (1992) RPE transplants stabilize retinal vasculature and prevent neovascularization in the RCS rat. *Invest Ophthalmol Vis Sci* **33**, 83-91.
- Semkova, I., Fauser, S., Lappas, A., Smyth, N., Kociok, N., Kirchhof, B., Paulsson, M., Poulaki, V., and Jousen, A. M. (2006) Overexpression of FasL in retinal pigment epithelial cells reduces choroidal neovascularization. *FASEB J* **20**, 1689-1691.

- Sheedlo, H. J., Li, L., Barnstable, C. J., and Turner, J. E. (1993a) Synaptic and photoreceptor components in retinal pigment epithelial cell transplanted retinas of Royal College of Surgeons dystrophic rats. *J Neurosci Res* **36**, 423-431.
- Sheedlo, H. J., Li, L., and Turner, J. E. (1989a) Photoreceptor cell rescue in the RCS rat by RPE transplantation: a therapeutic approach in a model of inherited retinal dystrophy. *Prog Clin Biol Res* **314**, 645-658.
- Sheedlo, H. J., Li, L., and Turner, J. E. (1993b) Effects of RPE age and culture conditions on support of photoreceptor cell survival in transplanted RCS dystrophic rats. *Exp Eye Res* **57**, 753-761.
- Sheedlo, H. J., Li, L. X., and Turner, J. E. (1989b) Functional and structural characteristics of photoreceptor cells rescued in RPE-cell grafted retinas of RCS dystrophic rats. *Exp Eye Res* **48**, 841-854.
- Sheng, Y., Gouras, P., Cao, H., Berglin, L., Kjeldbye, H., Lopez, R., and Rosskothan, H. (1995) Patch transplants of human fetal retinal pigment epithelium in rabbit and monkey retina. *Invest Ophthalmol Vis Sci* **36**, 381-390.
- Shih, Y. F., Ho, T. C., Hsiao, C. K., and Lin, L. L. (2006) Visual outcomes for high myopic patients with or without myopic maculopathy: a 10 year follow up study. *Br J Ophthalmol* **90**, 546-550.
- Shimada, H., Mori, R., Arai, K., Kawamura, A., and Yuzawa, M. (2005) Surgical excision of neovascularization in retinal angiomatous proliferation. *Graefes Arch Clin Exp Ophthalmol* **243**, 519-524.
- Silverman, M. S. and Hughes, S. E. (1990) Photoreceptor rescue in the RCS rat without pigment epithelium transplantation. *Curr Eye Res* **9**, 183-191.
- Song, M. K. and Lui, G. M. (1990) Propagation of fetal human RPE cells: preservation of original culture morphology after serial passage. *J Cell Physiol* **143**, 196-203.
- Springer, C., Bultmann, S., Volcker, H. E., and Rohrschneider, K. (2005) Fundus perimetry with the Micro Perimeter 1 in normal individuals: comparison with conventional threshold perimetry. *Ophthalmology* **112**, 848-854.
- Stanga, P. E., Kychenthal, A., Fitzke, F. W., Halfyard, A. S., Chan, R., Asaria, R. H., Bird, A. C., and Aylward, G. W. (2001a) Functional assessment of the native retinal pigment epithelium after the surgical excision of subfoveal choroidal neovascular membranes type II: preliminary results. *Int Ophthalmol* **23**, 309-316.
- Stanga, P. E., Kychenthal, A., Fitzke, F. W., Halfyard, A. S., Chan, R., Bird, A. C., and Aylward, G. W. (2001b) Retinal pigment epithelium translocation and central visual function in age related macular degeneration: preliminary results. *Int Ophthalmol* **23**, 297-307.
- Stanga, P. E., Kychenthal, A., Fitzke, F. W., Halfyard, A. S., Chan, R., Bird, A. C., and Aylward, G. W. (2002) Retinal pigment epithelium translocation after choroidal neovascular membrane removal in age-related macular degeneration. *Ophthalmology* **109**, 1492-1498.
- Steele, F. R., Chader, G. J., Johnson, L. V., and Tombran-Tink, J. (1993b) Pigment epithelium-derived factor: neurotrophic activity and identification as a member of the serine protease inhibitor gene family. *Proc Natl Acad Sci U S A* **90**, 1526-1530.
- Steele, F. R., Chader, G. J., Johnson, L. V., and Tombran-Tink, J. (1993a) Pigment epithelium-derived factor: neurotrophic activity and identification as a member of the serine protease inhibitor gene family. *Proc Natl Acad Sci U S A* **90**, 1526-1530.

- Steinman, R. M. (1965) Effect of target size, luminance, and color on monocular fixation. *J Opt Soc Am* **55**, 1158-1165.
- Strauss, O. (2005) The retinal pigment epithelium in visual function. *Physiol Rev* **85**, 845-881.
- Streilein, J. W., Ma, N., Wenkel, H., Ng, T. F., and Zamiri, P. (2002) Immunobiology and privilege of neuronal retina and pigment epithelium transplants. *Vision Res* **42**, 487-495.
- Subramanian, A. and Pardhan, S. (2006) The repeatability of MNREAD acuity charts and variability at different test distances. *Optom Vis Sci* **83**, 572-576.
- Subramanian, A. and Pardhan, S. (2009) Repeatability of reading ability indices in subjects with impaired vision. *Invest Ophthalmol Vis Sci* **50**, 3643-3647.
- Sullivan, B., Jovancevic-Misic, J., Hayhoe, M., and Sterns, G. (2008) Use of multiple preferred retinal loci in Stargardt's disease during natural tasks: a case study. *Ophthalmic Physiol Opt* **28**, 168-177.
- Sun, H., Tsunenari, T., Yau, K. W., and Nathans, J. (2002) The vitelliform macular dystrophy protein defines a new family of chloride channels. *Proc Natl Acad Sci U S A* **99**, 4008-4013.
- Sunness, J. S. and Applegate, C. A. (2005) Long-term follow-up of fixation patterns in eyes with central scotomas from geographic atrophy that is associated with age-related macular degeneration. *Am J Ophthalmol* **140**, 1085-1093.
- Sunness, J. S., Applegate, C. A., and Gonzalez-Baron, J. (2000) Improvement of visual acuity over time in patients with bilateral geographic atrophy from age-related macular degeneration. *Retina* **20**, 162-169.
- Sunness, J. S., Applegate, C. A., Haselwood, D., and Rubin, G. S. (1996) Fixation patterns and reading rates in eyes with central scotomas from advanced atrophic age-related macular degeneration and Stargardt disease. *Ophthalmology* **103**, 1458-1466.
- Sunness, J. S., Bressler, N. M., Tian, Y., Alexander, J., and Applegate, C. A. (1999a) Measuring geographic atrophy in advanced age-related macular degeneration. *Invest Ophthalmol Vis Sci* **40**, 1761-1769.
- Sunness, J. S., Gonzalez-Baron, J., Applegate, C. A., Bressler, N. M., Tian, Y., Hawkins, B., Barron, Y., and Bergman, A. (1999b) Enlargement of atrophy and visual acuity loss in the geographic atrophy form of age-related macular degeneration. *Ophthalmology* **106**, 1768-1779.
- Sunness, J. S., Rubin, G. S., Applegate, C. A., Bressler, N. M., Marsh, M. J., Hawkins, B. S., and Haselwood, D. (1997) Visual function abnormalities and prognosis in eyes with age-related geographic atrophy of the macula and good visual acuity. *Ophthalmology* **104**, 1677-1691.
- Sutter, E. E. and Tran, D. (1992) The field topography of ERG components in man--I. The photopic luminance response. *Vision Res* **32**, 433-446.
- Tafoya, M. E., Lambert, H. M., Vu, L., and Ding, M. (2003) Visual outcomes of silicone oil versus gas tamponade for macular hole surgery. *Semin Ophthalmol* **18**, 127-131.
- Takahashi, K., Tanabe, K., Ohnuki, M., Narita, M., Ichisaka, T., Tomoda, K., and Yamanaka, S. (2007) Induction of pluripotent stem cells from adult human fibroblasts by defined factors. *Cell* **131**, 861-872.
- Tanihara, H., Inatani, M., and Honda, Y. (1997) Growth factors and their receptors in the retina and pigment epithelium. *Prog Retin Eye Res* **16**, 271-301.

- Tarita-Nistor, L., Gonzalez, E. G., Markowitz, S. N., and Steinbach, M. J. (2008) Fixation characteristics of patients with macular degeneration recorded with the mp-1 microperimeter. *Retina* **28**, 125-133.
- Terasaki, H., Ishikawa, K., Niwa, Y., Piao, C. H., Niwa, T., Kondo, M., Ito, Y., and Miyake, Y. (2004) Changes in focal macular ERGs after macular translocation surgery with 360 degrees retinotomy. *Invest Ophthalmol Vis Sci* **45**, 567-573.
- Terasaki, H., Ishikawa, K., Suzuki, T., Nakamura, M., Miyake, K., and Miyake, Y. (2003) Morphologic and angiographic assessment of the macula after macular translocation surgery with 360 degrees retinotomy. *Ophthalmology* **110**, 2403-2408.
- Terasawa, Y., Tashiro, H., Uehara, A., Saitoh, T., Ozawa, M., Tokuda, T., and Ohta, J. (2006) The development of a multichannel electrode array for retinal prostheses. *J Artif Organs* **9**, 263-266.
- Tezel, T. H. and Del Priore, L. V. (1997) Reattachment to a substrate prevents apoptosis of human retinal pigment epithelium. *Graefes Arch Clin Exp Ophthalmol* **235**, 41-47.
- Tezel, T. H., Del Priore, L. V., Berger, A. S., and Kaplan, H. J. (2007) Adult retinal pigment epithelial transplantation in exudative age-related macular degeneration. *Am J Ophthalmol* **143**, 584-595.
- Tezel, T. H., Del Priore, L. V., and Kaplan, H. J. (1997) Harvest and storage of adult human retinal pigment epithelial sheets. *Curr Eye Res* **16**, 802-809.
- Tezel, T. H., Del Priore, L. V., and Kaplan, H. J. (2004) Reengineering of aged Bruch's membrane to enhance retinal pigment epithelium repopulation. *Invest Ophthalmol Vis Sci* **45**, 3337-3348.
- Tezel, T. H., Kaplan, H. J., and Del Priore, L. V. (1999) Fate of human retinal pigment epithelial cells seeded onto layers of human Bruch's membrane. *Invest Ophthalmol Vis Sci* **40**, 467-476.
- Theelen, T., Berendschot, T. T., Boon, C. J., Hoyng, C. B., and Klevering, B. J. (2008) Analysis of visual pigment by fundus autofluorescence. *Exp Eye Res* **86**, 296-304.
- Thomas, M. A., Dickinson, J. D., Melberg, N. S., Ibanez, H. E., and Dhaliwal, R. S. (1994) Visual results after surgical removal of subfoveal choroidal neovascular membranes. *Ophthalmology* **101**, 1384-1396.
- Thomas, M. A. and Kaplan, H. J. (1991) Surgical removal of subfoveal neovascularization in the presumed ocular histoplasmosis syndrome. *Am J Ophthalmol* **111**, 1-7.
- Thompson, D. A., Li, Y., McHenry, C. L., Carlson, T. J., Ding, X., Sieving, P. A., Apfelstedt-Sylla, E., and Gal, A. (2001) Mutations in the gene encoding lecithin retinol acyltransferase are associated with early-onset severe retinal dystrophy. *Nat Genet* **28**, 123-124.
- Thomson, R. C., Giordano, G. G., Collier, J. H., Ishaug, S. L., Mikos, A. G., Lahiri-Munir, D., and Garcia, C. A. (1996) Manufacture and characterization of poly(alpha-hydroxy ester) thin films as temporary substrates for retinal pigment epithelium cells. *Biomaterials* **17**, 321-327.
- Thumann, G., Aisenbrey, S., Schaefer, F., and Bartz-Schmidt, K. U. (2006) Instrumentation and technique for delivery of tissue explants to the subretinal space. *Ophthalmologica* **220**, 170-173.
- Thumann, G., Schraermeyer, U., Bartz-Schmidt, K. U., and Heimann, K. (1997) Descemet's membrane as membranous support in RPE/IPE transplantation. *Curr Eye Res* **16**, 1236-1238.

- Thumann, G., Viethen, A., Gaebler, A., Walter, P., Kaempf, S., Johnen, S., and Salz, A. K. (2009) The in vitro and in vivo behaviour of retinal pigment epithelial cells cultured on ultrathin collagen membranes. *Biomaterials* **30**, 287-294.
- Timberlake, G. T., Mainster, M. A., Webb, R. H., Hughes, G. W., and Trempe, C. L. (1982) Retinal localization of scotomata by scanning laser ophthalmoscopy. *Invest Ophthalmol Vis Sci* **22**, 91-97.
- Timberlake, G. T., Peli, E., Essock, E. A., and Augliere, R. A. (1987) Reading with a macular scotoma. II. Retinal locus for scanning text. *Invest Ophthalmol Vis Sci* **28**, 1268-1274.
- Toth, C. A. and Freedman, S. F. (2001) Macular translocation with 360-degree peripheral retinectomy impact of technique and surgical experience on visual outcomes. *Retina* **21**, 293-303.
- Toth, C. A., Lapolice, D. J., Banks, A. D., and Stinnett, S. S. (2004) Improvement in near visual function after macular translocation surgery with 360-degree peripheral retinectomy. *Graefes Arch Clin Exp Ophthalmol* **42**, 541-548.
- Treumer, F., Bunse, A., Klatt, C., and Roeder, J. (2007a) Autologous retinal pigment epithelium-choroid sheet transplantation in age related macular degeneration: morphological and functional results. *Br J Ophthalmol* **91**, 349-353.
- Treumer, F., Klatt, C., and Roeder, J. (2007b) [Autologous RPE-choroid translocation in exudative AMD. A case series of 10 consecutive patients]. *Ophthalmologie* **104**, 795-802.
- Tschernutter, M., Jenkins, S. A., Waseem, N. H., Saihan, Z., Holder, G. E., Bird, A. C., Bhattacharya, S. S., Ali, R. R., and Webster, A. R. (2006) Clinical characterisation of a family with retinal dystrophy caused by mutation in the Mertk gene. *Br J Ophthalmol* **90**, 718-723.
- Tschernutter, M., Schlichtenbrede, F. C., Howe, S., Balaggan, K. S., Munro, P. M., Bainbridge, J. W., Thrasher, A. J., Smith, A. J., and Ali, R. R. (2005) Long-term preservation of retinal function in the RCS rat model of retinitis pigmentosa following lentivirus-mediated gene therapy. *Gene Ther* **12**, 694-701.
- Tso, M. O., Li, W. W., Zhang, C., Lam, T. T., Hao, Y., Petters, R. M., and Wong, F. (1997) A pathologic study of degeneration of the rod and cone populations of the rhodopsin Pro347Leu transgenic pigs. *Trans Am Ophthalmol Soc* **95**, 467-479.
- Turowski, P., Adamson, P., Sathia, J., Zhang, J. J., Moss, S. E., Aylward, G. W., Hayes, M. J., Kanuga, N., and Greenwood, J. (2004) Basement membrane-dependent modification of phenotype and gene expression in human retinal pigment epithelial ARPE-19 cells. *Invest Ophthalmol Vis Sci* **45**, 2786-2794.
- Uppal, G., Milliken, A., Lee, J., Acheson, J., Hykin, P., Tufail, A., and da Cruz, L. (2007) New algorithm for assessing patient suitability for macular translocation surgery. *Clin Experiment Ophthalmol* **35**, 448-457.
- Valtink, M., Engelmann, K., Kruger, R., Schellhorn, M. L., Loliger, C., Puschel, K., and Richard, G. (1999a) [Structure of a cell bank for transplantation of HLA-typed, cryopreserved human adult retinal pigment epithelial cells]. *Ophthalmologie* **96**, 648-652.
- Valtink, M., Engelmann, K., Strauss, O., Kruger, R., Loliger, C., Ventura, A. S., and Richard, G. (1999b) Physiological features of primary cultures and subcultures of human retinal pigment epithelial cells before and after cryopreservation for cell transplantation. *Graefes Arch Clin Exp Ophthalmol* **37**, 1001-1006.

- van Meurs, J. C. (2005) Retinal Pigment Epithelium and Choroid Translocation in Patients with Exudative Age-Related Macular Degeneration. In: *Vitreo-retinal Surgery*, pp. 73-87. Eds B. Kirchhof, D. Wong. Springer: Berlin.
- van Meurs, J. C., ter Averst, E., Hofland, L. J., van Hagen, P. M., Mooy, C. M., Baarsma, G. S., Kuijpers, R. W., Boks, T., and Stalmans, P. (2004) Autologous peripheral retinal pigment epithelium translocation in patients with subfoveal neovascular membranes. *Br J Ophthalmol* **88**, 110-113.
- van Meurs, J. C. and Van Den Biesen, P. R. (2003) Autologous retinal pigment epithelium and choroid translocation in patients with exudative age-related macular degeneration: short-term follow-up. *Am J Ophthalmol* **136**, 688-695.
- van Meurs, J. C., Vijfvinkel, G., Misotten, T., Kirchhof, B., Mulder, P., Heimann, H., Jousen, A. M., and Maaijwee, K. (2006) The Translocation of an Autologous Retinal Pigment Epithelium and Choroid Graft in Patients With Exudative Macular Degeneration: Visual Results. *Invest Ophthalmol Vis Sci* **47**, E-Abstract 2692.
- van Soest, S. S., de Wit, G. M., Essing, A. H., ten Brink, J. B., Kamphuis, W., de Jong, P. T., and Bergen, A. A. (2007) Comparison of human retinal pigment epithelium gene expression in macula and periphery highlights potential topographic differences in Bruch's membrane. *Mol Vis* **13**, 1608-1617.
- Verdugo, M. E., Ailing, J., Lazar, E. S., Del Cerro, M., Ray, J., and Aguirre, G. (2001) Posterior segment approach for subretinal transplantation or injection in the canine model. *Cell Transplant* **10**, 317-327.
- Veske, A., Nilsson, S. E., Narfstrom, K., and Gal, A. (1999) Retinal dystrophy of Swedish briard/briard-beagle dogs is due to a 4-bp deletion in RPE65. *Genomics* **57**, 57-61.
- Vollrath, D., Feng, W., Duncan, J. L., Yasumura, D., D'Cruz, P. M., Chappelow, A., Matthes, M. T., Kay, M. A., and Lavail, M. M. (2001) Correction of the retinal dystrophy phenotype of the RCS rat by viral gene transfer of Mertk. *Proc Natl Acad Sci U S A* **98**, 12584-12589.
- von Ruckmann, A., Fitzke, F. W., and Bird, A. C. (1995) Distribution of fundus autofluorescence with a scanning laser ophthalmoscope. *Br J Ophthalmol* **79**, 407-412.
- Vugler, A., Carr, A. J., Lawrence, J., Chen, L. L., Burrell, K., Wright, A., Lundh, P., Semo, M., Ahmado, A., Gias, C., da Cruz, L., Moore, H., Andrews, P., Walsh, J., and Coffey, P. (2008) Elucidating the phenomenon of HESC-derived RPE: anatomy of cell genesis, expansion and retinal transplantation. *Exp Neurol* **214**, 347-361.
- Wakabayashi, T., Ikuno, Y., Sayanagi, K., Soga, K., Oshima, Y., and Tano, Y. (2008) Fundus autofluorescence related to retinal morphological and functional changes in idiopathic macular holes. *Acta Ophthalmol* **86**, 897-901.
- Wallenten, K. G., Andreasson, S., and Ghosh, F. (2008) Retinal function after vitrectomy. *Retina* **28**, 558-563.
- Wang, F., Xu, P., Wu, J. H., Xia, X., Sun, H. L., Xu, X., and Huang, Q. (2002) [Long-term outcome of gfp gene modified human RPE xenografts into the subretinal space of rabbits]. *Sheng Wu Hua Xue Yu Sheng Wu Wu Li Xue Bao (Shanghai)* **34**, 643-649.
- Wang, H., Leonard, D. S., Castellarin, A. A., Tsukahara, I., Ninomiya, Y., Yagi, F., Cheewatrakoolpong, N., Sugino, I. K., and Zarbin, M. A. (2001) Short-term study of allogeneic retinal pigment epithelium transplants onto debrided Bruch's membrane. *Invest Ophthalmol Vis Sci* **42**, 2990-2999.

- Wang, H., Yagi, F., Cheewatrakoolpong, N., Sugino, I. K., and Zarbin, M. A. (2004) Short-term study of retinal pigment epithelium sheet transplants onto Bruch's membrane. *Exp Eye Res* **78**, 53-65.
- Wang, S., Lu, B., and Lund, R. D. (2005a) Morphological changes in the Royal College of Surgeons rat retina during photoreceptor degeneration and after cell-based therapy. *J Comp Neurol* **491**, 400-417.
- Wang, S., Lu, B., Wood, P., and Lund, R. D. (2005b) Grafting of ARPE-19 and Schwann cells to the subretinal space in RCS rats. *Invest Ophthalmol Vis Sci* **46**, 2552-2560.
- Ware, J. E., Jr. and Sherbourne, C. D. (1992) The MOS 36-item short-form health survey (SF-36). I. Conceptual framework and item selection. *Med Care* **30**, 473-483.
- Warfvinge, K., Kiilgaard, J. F., Klassen, H., Zamiri, P., Scherfig, E., Streilein, W., Prause, J. U., and Young, M. J. (2006) Retinal progenitor cell xenografts to the pig retina: immunological reactions. *Cell Transplant* **15**, 603-612.
- Warfvinge, K., Kiilgaard, J. F., Lavik, E. B., Scherfig, E., Langer, R., Klassen, H. J., and Young, M. J. (2005) Retinal progenitor cell xenografts to the pig retina: morphologic integration and cytochemical differentiation. *Arch Ophthalmol* **123**, 1385-1393.
- Weichel, J., Valtink, M., Engelmann, K., and Richard, G. (2002) Use of an oil-hydraulic microinjection pump for subretinal infusions. *Ophthalmic Surg Lasers* **33**, 340-342.
- Weisz, J. M., Humayun, M. S., De Juan E Jr, Del Cerro, M., Sunness, J. S., Dagnelie, G., Soyulu, M., Rizzo, L., and Nussenblatt, R. B. (1999) Allogeneic fetal retinal pigment epithelial cell transplant in a patient with geographic atrophy. *Retina* **19**, 540-545.
- Wenkel, H., Chen, P. W., Ksander, B. R., and Streilein, J. W. (1999) Immune privilege is extended, then withdrawn, from allogeneic tumor cell grafts placed in the subretinal space. *Invest Ophthalmol Vis Sci* **40**, 3202-3208.
- Wenkel, H. and Streilein, J. W. (1998) Analysis of immune deviation elicited by antigens injected into the subretinal space. *Invest Ophthalmol Vis Sci* **39**, 1823-1834.
- Wenkel, H. and Streilein, J. W. (2000) Evidence that retinal pigment epithelium functions as an immune-privileged tissue. *Invest Ophthalmol Vis Sci* **41**, 3467-3473.
- Whiteley, S. J., Litchfield, T. M., Coffey, P. J., and Lund, R. D. (1996) Improvement of the pupillary light reflex of Royal College of Surgeons rats following RPE cell grafts. *Exp Neurol* **140**, 100-104.
- Wickham, L. J., Chen, F. K., Lewis, G. P., Uppal, G. S., Neveu, M. M., Wright, G. A., Robson, A. G., Webster, A., Grierson, I., Hiscott, P., Coffey, P. J., Holder, G., Fisher, S. K., and da Cruz, L. (2009) Clinicopathological case series of four patients with inherited macular disease. *Invest Ophthalmol Vis Sci*.
- Williams, R. L., Krishna, Y., Dixon, S., Haridas, A., Grierson, I., and Sheridan, C. (2005) Polyurethanes as potential substrates for sub-retinal retinal pigment epithelial cell transplantation. *J Mater Sci Mater Med* **16**, 1087-1092.
- Witmer, A. N., Vrensen, G. F., van Noorden, C. J., and Schlingemann, R. O. (2003) Vascular endothelial growth factors and angiogenesis in eye disease. *Prog Retin Eye Res* **22**, 1-29.
- Wong, D., Stanga, P., Briggs, M., Lenfestey, P., Lancaster, E., Li, K. K., Lim, K. S., and Groenewald, C. (2004) Case selection in macular relocation surgery for age related macular degeneration. *Br J Ophthalmol* **88**, 186-190.



- Wong, T., Chakravarthy, U., Klein, R., Mitchell, P., Zlateva, G., Buggage, R., Fahrbach, K., Probst, C., and Sledge, I. (2008) The natural history and prognosis of neovascular age-related macular degeneration: a systematic review of the literature and meta-analysis. *Ophthalmology* **115**, 116-126.
- Wongpichedchai, S., Weiter, J. J., Weber, P., and Dorey, C. K. (1992) Comparison of external and internal approaches for transplantation of autologous retinal pigment epithelium. *Invest Ophthalmol Vis Sci* **33**, 3341-3352.
- Yamaguchi, K., Yamaguchi, K., Young, R. W., Gaur, V. P., Greven, C. M., Slusher, M. M., and Turner, J. E. (1992) Vitreoretinal surgical technique for transplanting retinal pigment epithelium in rabbit retina. *Jpn J Ophthalmol* **36**, 142-150.
- Yamamoto, S., Du, J., Gouras, P., and Kjeldbye, H. (1993) Retinal pigment epithelial transplants and retinal function in RCS rats. *Invest Ophthalmol Vis Sci* **34**, 3068-3075.
- Yanai, D., Weiland, J. D., Mahadevappa, M., Greenberg, R. J., Fine, I., and Humayun, M. S. (2007) Visual performance using a retinal prosthesis in three subjects with retinitis pigmentosa. *Am J Ophthalmol* **143**, 820-827.
- Yannuzzi, L. A., Nogueira, F. B., Spaide, R. F., Guyer, D. R., Orlock, D. A., Colombero, D., and Freund, K. B. (1998) Idiopathic polypoidal choroidal vasculopathy: a peripheral lesion. *Arch Ophthalmol* **116**, 382-383.
- Ye, J., Li, W., and Ryan, S. J. (1998) Long-term studies on allotransplantation of rabbit retinal pigment epithelial cells double-labelled with 5-bromodeoxyuridine and natural pigment. *Chin Med J (Engl)* **111**, 736-740.
- Yepez, J. B. and Arevalo, J. F. (2003) RPE translocation in ARMD. *Ophthalmology* **110**, 2262.
- Yong, V. K., Morgan, W. H., Cooper, R. L., Shaw, M., Bremner, A. P., Bulsara, M., and Yu, D. Y. (2006) Trends in registered blindness and its causes over 19 years in Western Australia. *Ophthalmic Epidemiol* **13**, 35-42.
- Yoon, M. K., Roorda, A., Zhang, Y., Nakanishi, C., Wong, L. J., Zhang, Q., Gillum, L., Green, A., and Duncan, J. L. (2008) Adaptive Optics Scanning Laser Ophthalmoscopy Images Demonstrate Abnormal Cone Structure in a Family with the Mitochondrial DNA T8993C Mutation. *Invest Ophthalmol Vis Sci*.
- Yrjanheikki, J., Keinanen, R., Pellikka, M., Hokfelt, T., and Koistinaho, J. (1998) Tetracyclines inhibit microglial activation and are neuroprotective in global brain ischemia. *Proc Natl Acad Sci U S A* **95**, 15769-15774.
- Yu, J., Vodyanik, M. A., Smuga-Otto, K., Antosiewicz-Bourget, J., Frane, J. L., Tian, S., Nie, J., Jonsdottir, G. A., Ruotti, V., Stewart, R., Slukvin, I. I., and Thomson, J. A. (2007) Induced pluripotent stem cell lines derived from human somatic cells. *Science* **318**, 1917-1920.
- Zamiri, P., Zhang, Q., and Streilein, J. W. (2004) Vulnerability of allogeneic retinal pigment epithelium to immune T-cell-mediated damage in vivo and in vitro. *Invest Ophthalmol Vis Sci* **45**, 177-184.
- Zarbin, M. A. (2003) Analysis of retinal pigment epithelium integrin expression and adhesion to aged submacular human Bruch's membrane. *Trans Am Ophthalmol Soc* **101**, 499-520.
- Zarepari, S., Branham, K. E., Li, M., Shah, S., Klein, R. J., Ott, J., Hoh, J., Abecasis, G. R., and Swaroop, A. (2005) Strong association of the Y402H variant in complement factor H at 1q32 with susceptibility to age-related macular degeneration. *Am J Hum Genet* **77**, 149-153.

Zetterlund, A., Larsson, P. H., Muller-Suur, C., Palmberg, L., and Larsson, K. (1998) Budesonide but not terbutaline decreases phagocytosis in alveolar macrophages. *Respir Med* **92**, 162-166.

Zhang, X. and Bok, D. (1998) Transplantation of retinal pigment epithelial cells and immune response in the subretinal space. *Invest Ophthalmol Vis Sci* **39**, 1021-1027.

Zhao, B., Ma, A., Cai, J., and Boulton, M. (2006) VEGF-A regulates the expression of VEGF-C in human retinal pigment epithelial cells. *Br J Ophthalmol* **90**, 1052-1059.

## **Appendix 2: RPE Transplantation in IMD Study Documents**

### *A. Study Protocol*

#### **Retinal Pigment Cell Transplantation for the Treatment of Inherited Macular**

**Dystrophies:** Protocol version II – 26th June 2005

Chief Investigator: Mr Lyndon Da Cruz

#### **Background**

Inherited macular dystrophies are a group of disorders that are due to an intrinsic problem with the light-sensitive layer of the eye, known as the retina, specifically with its central portion, known as the macula. Persons affected by such a disorder progressively lose their central vision causing problems with reading, writing, discriminating colours and other visual tasks such as recognising faces. Usually the peripheral vision and thereby the navigational vision remain intact. Presently there are no proven methods to either prevent or alleviate these disorders and central visual loss is usually inexorable.

In some patients it is apparent that the defect in the retina is localised. That is, when imaging (e.g. autofluorescence imaging of the pigment epithelium) and electrophysiology are performed the mid-peripheral and peripheral retina produce normal signals.

Many patients and families with macular dystrophy have a change in a gene that is presently unknown. However, the most common molecular cause of macular dystrophy is mutation in a gene, first discovered in 1997, and called ABCA4. Much work has been done on the changes that occur in this particular gene and a murine model with retinal degeneration due to a mutation in this same gene has been developed. It appears that disease in humans and in mice is due to the slow accumulation of toxic molecules within the retinal pigment epithelial (RPE) layer of the retina. This takes many years to occur and can be monitored with routine retinal imaging. It is likely that other causes of macular dystrophy also cause visual loss by primary damage to this layer of the retina, as RPE dysfunction as monitored by retinal imaging appears similar. The justification of this surgical approach is the possibility of preserving vision, to some degree, by translocating a healthy RPE graft to the macula where it has become damaged. In a situation when no other treatments can be recommended to a patient who, for instance, reports inexorable deterioration of central vision, any such preservation of vision would be of benefit in the patient's management.

Such surgical techniques are now available to successfully transfer grafts of tissue from the periphery of the same eye for transplant to the central vision area and have been applied clinically to those persons with macular disease due to advancing age (age-related macular degeneration). The proposed study wishes to use these techniques, for the first time, to treat younger patients with macular disease due to such an inherent deficiency of a gene.

## **Recruitment**

1. Patients will be identified from the inherited disease clinics at Moorfields Eye Hospital based on their clinical features.
2. Patients will be counselled about the natural history of the disease and the risks and benefits associated with surgery and other treatments. The aims of the trial and associated risks will be explained in full. This will take place at the initial clinic review at the time of diagnosis.
3. Any patient who is interested in taking part in the study will be given a patient information sheet to take home when initially referred from the vitreoretinal clinic. The details in this information sheet will be discussed in full with the patient (and relatives) at a dedicated research session when investigations will also take place. If eligible for surgery, patients will see Mr daCruz and be consented for surgery if they wish to enter the trial.

## **General Methodology**

Prospective, non-randomised, interventional case series, piloting a new surgical technique. Ten patients will be recruited and assessed preoperatively, at 10 days, 6 weeks, 3 months and 6 months post operatively. At each visit they will undergo assessments as detailed below.

## **Investigations**

1. Best corrected visual acuity at each visit (full refraction pre-op and at 6 months)
2. Reading ability with refraction pre-op and at 6 months
3. Slit lamp biomicroscopic examination and cataract grading pre-op and at 6 months
4. Colour fundus photography (pre-op, 6 weeks and 6 months)
5. Fluorescein angiography (pre-op and at 6 months)
6. Optical coherence tomography - Model 3000 (pre-op and at 6 months)
7. Scanning laser ophthalmoscope Microperimetry  
(pre-op, 6 weeks and at 6 months)
8. Autofluorescence imaging (pre-op, 6 weeks and 6 months).
9. Indocyanine-green angiography (at 6 weeks and 6 months).
10. Cataract grading at 3 months and surgery arranged if necessary.
11. Patients may undergo further review after 6 months if the surgery has been successful.
12. Preop quality of life questionnaire and at 12 months.

## **Surgical Technique**

1. Creation of Recipient Site. The patients will undergo a standard three-port pars plana vitrectomy. A small retinotomy will be made temporal to the fovea using a 130° 33 gauge

subretinal cannula (Synergetics 12.01, USA) and a shallow posterior retinal detachment overlying the macula will be created by injecting balanced salt solution (BSS) through the retinotomy and into the sub-retinal space.

2. Harvesting of RPE-Choroid Graft. A second shallow retinal detachment will be induced as described above, in the superior retina. Retinal diathermy will be applied and the retina cut to gain access to the underlying RPE. Vertical scissors will be used to cut a full-thickness RPE-choroid graft. The infusion pressure will be increased again during this time to reduce the risk of choroidal haemorrhage. The patient will be hyperventilated slightly during the procedure to induce choroidal vasoconstriction.

3. Placement of RPE-Choroid Graft. The RPE-choroid graft will be placed (RPE surface up) under the fovea. The retina will then be flattened by subretinal fluid aspiration through the retinotomy. Final adjustments are made during aspiration to ensure the fovea falls onto the centre of the RPE bed. In some cases, where a single retinal flap may give access to both the fovea and RPE harvest site, perfluorocarbon may be used to roll the retina back into position.

4. Closure. To reduce the risk of proliferative vitreoretinopathy (PVR), all RPE cells will be aspirated with a flute prior to air exchange. Laser retinopexy or cryotherapy will be applied to the margins of the RPE-choroid donor site. The vitreous cavity will be drained as much as possible before withdrawing instrumentation and exchanging to silicone oil.

### **Consultation and Informed Consent**

All prospective research participants will be given a Patient Information Sheet describing the study in terms that are understandable by non-medical members of the public. We will use our own press officer to disseminate results of ongoing research to the public objectively through the media and listen to feedback generated from interest groups.

### **Inclusion Criteria**

1. A diagnosis of inherited macular dystrophy
2. Visual acuity of 6/36 or less in the treatable eye
3. Recent visual acuity of 6/12 or better within past 12 months in treatable eye
4. Over 25 years old
5. Fit for surgery and able to consent to surgery
6. Autofluorescent imaging and full-field ERG results suggestive of a localised macular disorder (that is normal mid-peripheral autofluorescence and normal rod and cone Ganzfeld ERGs).

### **Exclusion Criteria**

1. Inability to give informed consent
2. Unfit for general anaesthetic

3. Inability to complete follow-up programme
4. Corneal opacity or other pathology likely to impair vitreoretinal surgery
5. Requirement for warfarin or inability to discontinue aspirin peri-operatively

### **Benefits of Study**

The results of Van Meurs et al (2003) demonstrate that this surgical technique is worth exploring. Although the diseases being treated are different they are conceptually both macular diseases only with a sudden decrease in vision - implying a window period where the retina remains healthy. The unique combination of medical and surgical retina expertise at Moorfields Eye Hospital in London makes this an ideal site to investigate alternative treatment options. If successful, the surgery would improve vision in patients recruited for the trial, increase the understanding of the pathological mechanisms of the diseases, and develop new surgical techniques, applicable to other disorders.

### **References**

- Binder S, Stolba U, Krebs U et al. Transplantation of autologous retinal pigment epithelium in eyes with foveal Neovascularization resulting from age-related macular degeneration: A pilot study. *Am J Ophthalmol* 2002; 133:215-25
- Chylack LT Jr., Wolfe JK, Singer DM et al. The Lens Opacities Classification System III. The Longitudinal Study of Cataract Surgery Group. *Arch Ophthalmol* 1993; 111:831-6
- Eckardt C, Eckardt U and Conrad HG. Macular rotation with and without counter-rotation of the globe in patients with age-related macular degeneration. *Graefes Arch Clin Exp Ophthalmol* 1999; 37:313-25
- Gass JDM. Biomicroscopic and histopathologic considerations regarding the feasibility of surgical excision of subfoveal neovascular membranes. *Am J Ophthalmol* 1994; 118:285-98
- Stanga PE, Kychenthal A, Fitzke FW et al. Retinal pigment epithelium translocation after choroidal neovascular membrane removal in age-related macular degeneration. *Ophthalmology* 2002; 109:1492-8
- Thomas MA, Dickinson JD, Melberg NS, Ibanez HE and Dhaliwal RS. Visual results after surgical removal of subfoveal choroidal neovascular membranes. *Ophthalmology* 1994; 101: 1384-96
- Van Meurs J and Van den Biesen P. Translocation of autologous retinal pigment epithelium and choroid in patients with age-related macular degeneration. *Euretina* 2003; L 57
- Wong D, Lois N. Foveal relocation by redistribution of the neurosensory retina. *Br J Ophthalmol* 2000; 84: 352-7

## B. Participant Information Sheet

Patron: Her Majesty, The Queen

Chairman  
Sir Thomas Boyd-Carpenter  
House Governor and Chief Executive  
I. A. J. Balmer

Version II – 26<sup>th</sup> June 2005

### PATIENT INFORMATION SHEET

#### 1. Study Title

Retinal pigment cell transplantation for the treatment of inherited macular dystrophies.

#### 2. Invitation

You are being invited to take part in this research study. Before you decide, it is important for you to understand why the research is being done and what it will involve. Please take time to read the following information carefully and discuss it with others if you wish. Ask us if there is anything that is not clear or if you would like more information. Take time to decide whether or not you wish to take part.

#### 3. Background and aim of the study

Inherited macular dystrophies are a group of disorders that are due to an intrinsic problem with the light-sensitive layer of the eye, known as the retina, specifically with its central portion, known as the macula. Persons affected by such a disorder progressively lose their central vision causing problems with reading, writing, discriminating colours and other visual tasks such as recognising faces. Usually the peripheral vision and thereby the navigational vision remain intact. Presently there are no proven methods to either prevent or alleviate these disorders and central vision is progressively lost.

In some patients it is apparent that the defect in the retina is localised only to the central retina – the macular region. That is, when special scans of the eye are performed (eg autofluorescence imaging and electrophysiology studies) and peripheral retina give normal signals as compared to an abnormal signal from the central macular region of the retina.

Many patients and families with macular dystrophy have a change in a gene that is presently unknown. However, the most common molecular cause of macular dystrophy is mutation in a gene, first discovered in 1997 called ABCA4. Much work has been done on the changes that occur in this particular gene. Investigations using a mouse model with retinal degeneration due to mutation in this same gene exists. It appears that the disease in mice and



CITY ROAD  
LONDON  
EC1V 2PD

Vitreoretinal Research Office  
Tel: (020) 7566 2039

humans is due to the slow accumulation of toxic molecules within the retinal pigment epithelial (RPE) layer of the retina. This process takes many years to occur and can be monitored with routine retinal imaging studies. Other likely causes of macular dystrophy have also been shown by retinal imaging studies to cause visual loss by primary damage to the RPE layer of the retina.

The central vision in inherited macular dystrophies may remain good for many years until such time that the damage to the RPE layer reaches a critical level and the RPE layer can no longer support the overlying photoreceptor layer of the retina. At this point patients begin to experience a loss of central vision that can deteriorate rapidly over a period of weeks to months. The justification of this surgical approach is that intervention at a stage when the photoreceptors are still functional, by transplanting healthy RPE to the central macular area, provides the best possibility of preserving central vision.

If surgery is delayed for more than 6 months after experiencing significant loss of central vision the ability to salvage photoreceptor function with a healthy graft diminishes progressively. In a situation when no other treatments can be recommended to a patient with severe loss of central vision, any preservation of vision would be a significant benefit in the patient's management.

Surgical techniques are now available to successfully transfer RPE cells to the central visual area from the peripheral retina of the same eye. These techniques have so far only been applied clinically to those persons with macular disease due to advancing age (age-related macular degeneration). Briefly the technique used involves:

1. Removing the defective RPE from beneath the central macular retinal photoreceptor layer and thus creating a recipient site.
2. Harvesting healthy RPE from the peripheral retina of the same eye.
3. Inserting the healthy RPE into the recipient site created beneath the central macular retina.
4. Securing all the retinal layers and the graft in its new position by filling the eye with silicone oil. This oil will be removed at a second minor operation 2 - 3 months after the first operation.

As the donor RPE cell layer is harvested from the same eye that will be the recipient there are no problems associated with rejection (rejection occurs when tissue from another donor is transplanted into a recipient).

The proposed study wishes to use this technique, for the first time, to treat younger patients with macula disease due to an inherent deficiency of a gene. Whilst this surgical technique is relatively new, the individual steps that make up the procedure have been in regular use for many years and are in no way experimental. It is the specific combination of these steps applied to this particular disease that makes this a new treatment.

**4. Why have I been chosen?**

You have been chosen for this study because you are affected with an inherited macular dystrophy and we believe that the onset of your central visual loss is relatively recent. Unfortunately, at the present time there are no proven treatments to improve your vision or prevent further visual loss.

**5. Do I have to take part?**

It is up to you to decide whether or not to take part. If you do decide to take part, you will be given this information sheet to keep and asked to sign a consent form. Even if you do decide to take part, you are still free to withdraw at any time and without giving a reason. A decision to withdraw at any time, or a decision not to take part, will not affect the standard of care you receive in any way.

**6. What will happen to me if I take part?**

The study involves an initial full day of tests, followed by the operation (usually within six weeks) and then follow-up reviews over six months. For the operation you will be required to stay the night after surgery. If transport is difficult for you, you can also come in on the day before the operation. The follow-up schedule is the same as if you had a standard retinal operation, although a few more tests will be done at each visit. The clinic visit is unlikely to last more than four hours. If for whatever reason, the relevant tests cannot be done at your standard visit, you may be asked to make an extra visit, but you would be eligible for travel expenses of up to £20.00 for this. Please note that travel expenses are not applicable for the standard clinic visits, which anyone undergoing an operation on the retina would ordinarily attend. You do not need to see your GP for any additional medications or tests relevant to the study.

Any tests done at Moorfields Eye Hospital will be stored electronically on the hospital computers and will be accessible to anyone who sees you in clinic at subsequent visits, even after the study has been completed. This is standard practice for all patients whether or not they are in a study. If not already done, it will be helpful to file a small blood sample that will allow scientists to attempt to find the gene causing the macular dystrophy. This sample will be housed in the Institute of Ophthalmology and investigated only for this specific purpose.

By agreeing to take part, we would expect you to attend the clinic visits as requested after the operation. This is also for your benefit, in case any unexpected problems arise. It is not possible to have the operation without the tests, although you are reminded that you are free to withdraw at any time. This is not a 'randomized' trial; if you take part in the trial you will have the surgery as described. There is no 'placebo' or dummy procedure.

The flow chart at **APPENDIX 1 (at the end of this patient information sheet)** summarises the hospital visits required for the trial.

**7. What do I have to do?**

After surgery you may need to keep your head tilted in a certain position (for instance on your side or looking at the floor) for up to ten days following your surgery. You would be expected to maintain this posture for 50 minutes in the hour. It is expected however that most posturing will be achievable with you sitting up as if reading a book. We would ask you to refrain from sleeping flat on your back for one week after the operation. You will be given a separate instruction sheet on the posturing required (See **APPENDIX 2 at the end of this patient information sheet**).

At the end of the operation silicone oil will be placed in the eye. This is done because silicone oil has been shown to stabilise the retina and keep it flat and secure. At a later date (approximately three months after your operation) the silicone oil will need to be removed from the eye. This is a short and straightforward procedure and can be performed with a local anaesthetic. While the silicone oil is in your eye it will blur your vision compared to what it was before the operation.

Your eye will feel sore after each operation and to ensure that it settles quickly you will be given a number of drops to take. These include anti-inflammatory drops to help reduce the inflammation caused by having an operation and antibiotic drops to reduce the possibility of getting an infection in the eye. The drops are usually taken regularly for two weeks and then slowly reduced and stopped over a further four weeks. Once again you will be given an instruction sheet explaining how often and for how long to take each drop prescribed.

Generally we would ask you to take it easy for about 2 weeks after surgery. This would mean taking time off work, avoiding lengthy journeys and refraining from hard physical work. After two weeks you should be back to normal and you can return to normal activities.

**8. What is the procedure that is being tested?**

We are testing to see whether vision can be improved in macular dystrophy by surgically moving a patch of pigment cells within the eye. All other parts of the operation, tests and eye drops are standard and are already widely used at Moorfields Eye Hospital.

**9. What are the alternatives for diagnosis or treatment?**

You have been selected for this study because there is currently no other treatment or procedure that is likely to be of benefit in your particular case. You will not miss out on anything if you decide to enter the trial and you would not miss out on any new treatment if it becomes available during or after the trial.



**10. What are the side effects of any treatment received when taking part?**

The main possible side effects are similar for any retinal operation and are as follows:

a) **Cataract:** This is likely to occur in most cases within 1-2 years and a cataract operation will be offered to you at Moorfields if necessary. **If you already have a cataract, surgery for this will be performed within the trial period at the same time as the removal of the oil in a combined procedure. The risk of a sight threatening complication (retinal detachment, infection, haemorrhage) during cataract surgery is 1 - 4 in 1000.** If you have already had cataract surgery then you need not worry, as the cataract cannot return.

b) **Retinal Detachment:** This may occur in 10-20% of cases. Most retinal detachments are treatable (about 90%) but you would require another operation to have it fixed. The retinal detachment operation is similar to the trial operation.

c) **Haemorrhage:** The operation involves blood vessels within the eye and these may bleed (haemorrhage). To reduce the risk of haemorrhage, aspirin should be stopped 1 - 2 weeks before surgery, if possible. Mild haemorrhage usually clears by itself within a few weeks, but if more dense may require another operation. In rare cases the haemorrhage may be so severe as to cause long-term damage to the eye (1 - 2 in 1000).

d) **Infection:** This is relatively rare in retinal surgery and may require you to take intense eye drops (every hour) or possibly even have another operation (less than 1 in a 1000).

e) **Discomfort:** As with any operation on the eye, there is likely to be some redness and discomfort after surgery. For most people, however, pain is minimal and usually does not require additional medication.

**11. What are the possible disadvantages and risks of taking part?**

In agreeing to take part you must appreciate that the main risk is that your vision could be made worse as a result of a complication of the operation. You have to weigh up the possible benefit of a new treatment against the risk. Only you can do this. You should remember, however, that we would not have selected you if we felt in any way that the risks of surgery outweighed any benefits you might get. However this is a new technique and we cannot provide you with statistics on exactly how we expect things to turn out. We are here to advise, but not to make the decision for you (see also paragraph 4 above).

**12. What are the possible benefits of taking part?**

The main benefit is that your vision might improve or that the natural deterioration is slowed or halted. We are not simply testing out a new surgical technique – all parts of this procedure have already been performed in whole or in part in other operations. We hope that the treatment will help you. However, this cannot be guaranteed. The information gained from this study will also help us to treat future patients with macular dystrophy.

**13. What if new information becomes available?**

Sometimes during the course of a research project, new information becomes available about the treatment/drug that is being studied. If this happens, we will tell you about it and discuss with you whether you want to continue in the study. If you decide to withdraw we will make arrangements for your care to continue. If you decide to continue in the study you will be asked to sign an updated consent form. Also, on receiving new information we might consider it to be in your best interests to withdraw you from the study. We will explain the reasons and arrange for your normal care to continue.

**14. What happens when the research study stops?**

The study stops six months after the operation. After that your normal follow-up will continue. You may be asked to take part in further tests at subsequent clinic visits as part of your on-going care but no further data will be collected for this study after the six month period. We expect any benefit to be evident at six months, at which time we will also inform you of the results of the study.

**15. What if something goes wrong?**

If you are harmed by taking part in this research project, there are no special compensation arrangements. If you are harmed due to someone's negligence, then you would have grounds for a legal action, but you may need to pay initial legal costs. Regardless of this, the normal National Health Service complaints mechanism is available to you if you wish to complain, or have any concerns about any aspect of the way you have been approached or treated during the course of this study.

**16. Will my taking part in this study be kept confidential?**

If you consent to take part in the research, any of your medical records may be inspected by doctors at Moorfields for the purpose of analysing the results. They may also be looked at by people from regulatory authorities to check that the study is being carried out correctly. Your GP and any ophthalmologists involved in your care will also be informed. Your name, however, will not be disclosed outside the hospital or GP surgery. Generally, you can expect the same degree of confidentiality as if you would get with any routine NHS procedure, as all data can be collected anonymously.

**17. What will happen to the results of the research study?**

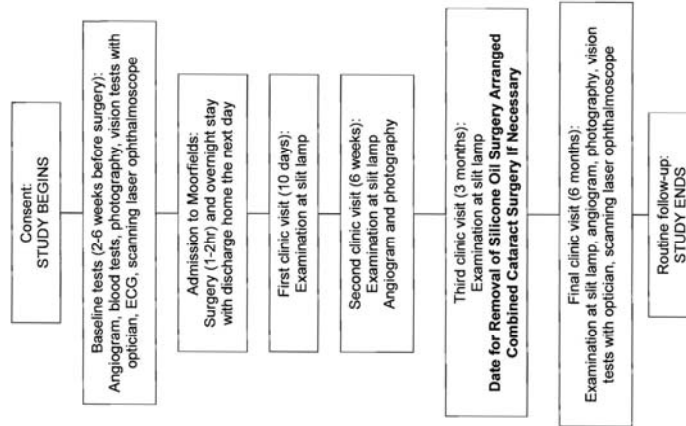
The results of the research will be published in a research journal, probably one that specialises in retinal diseases. It will be available through public libraries or the Internet and Moorfields Eye Hospital will keep copies. You will be able to obtain a copy of the research paper if you wish.

**APPENDIX 1**

**Version II – 26<sup>th</sup> June 2005**

**Title of Project: Retinal Pigment Cell Transplantation for the Treatment of Inherited Macular Dystrophies**

**Schedule of Operation and Clinic Visits:**



**APPENDIX 2**

**18. Who is organising and funding the research?**

The study is being funded by the Special Trustees of Moorfields Eye Hospital. This is a charitable organisation that administers money donated to the hospital for the purpose of funding research into eye diseases. No funding is dependent upon you entering the study and no-one will benefit financially by enrolling you in the study. None of the doctors or nurses that you will see has any financial interest in any treatment that you might or might not get. There is no profit from the study.

**19. Who has reviewed the study?**

The Moorfields Ethics Committee, the NHS Research Ethics Committee and the Moorfields Research and Development Committee will all have reviewed the study and given approval for it to go ahead.

**20. Contacts for Further Information**

Mr Lyndon daCruz is the principal research doctor. He can be contacted as below:

Mr Lyndon daCruz, MBBS FRCOphth FRACO PhD MA  
Consultant Vitreoretinal Surgeon  
Moorfields Eye Hospital  
City Road  
London EC1V 2PD  
Tel: 020 7566 2251

Consumers for Ethics in Research (CERES) also publishes a leaflet entitled 'Medical Research and You'. This leaflet gives more information about medical research in general and looks at some questions you may wish to ask. It does not however have information specific for this study. You may obtain a copy by writing to: CERES, PO Box 1365, London N16 0BW.

**THANK YOU FOR TAKING TIME TO CONSIDER ENTERING THIS STUDY**



## D. Research Ethics Committee Approval

05/Q0504/29

Page 2

36 Item Short Form Survey (SF-36)	(None Specified)
-----------------------------------	------------------

### Management approval

The study should not commence at any NHS site until the local Principal Investigator has obtained final management approval from the R&D Department for the relevant NHS care organisation.

### Notification of other bodies

The Committee Administrator will notify the research sponsor that the study has a favourable ethical opinion.

### Statement of compliance

The Committee is constituted in accordance with the Governance Arrangements for Research Ethics Committees (July 2001) and complies fully with the Standard Operating Procedures for Research Ethics Committees in the UK.

05/Q0504/29	Please quote this number on all correspondence
-------------	--

With the Committee's best wishes for the success of this project,

Yours sincerely

### Chair

Email: [katherine.clark@whittington.nhs.uk](mailto:katherine.clark@whittington.nhs.uk)  
CC Ms Alison Miller, Special Trustees of Moorfields Eye Hospital

Enclosures:

Standard approval conditions  
Site approval form (SF1)

SF1 list of approved sites

## **Appendix 3: RPE Transplantation in Geographic Atrophy Study Documents**

### *A. Study Protocol*

#### **Retinal pigment cell transplantation for the treatment of Dry Age-related Macular Degeneration:** Protocol version IV – 1st April 2007

Chief Investigator: Mr Lyndon Da Cruz

#### **Background**

Dry Age Related Macular Degeneration is a disorder that leads to a progressive loss of the light-sensitive layer of the eye, known as the retina, as well as the supportive layer under it – the retinal pigment epithelium (RPE) – specifically within the central portion, known as the macula. Persons affected by such a disorder progressively lose their central vision causing problems with reading, writing, discriminating colours and other visual tasks such as recognising faces. The peripheral vision and thereby the navigational vision remain intact. Presently there are no proven methods to either prevent or treat this disorder. And central visual loss ensues.

The cause of this degeneration remains unknown. The justification of this surgical approach is the possibility of preserving vision, to some degree, by translocating a healthy RPE graft to the macula where it has become damaged. In a situation when no other treatments can be recommended to a patient who, for instance, reports inexorable deterioration of central vision, any such preservation of vision would be a triumph in the patient's management.

A similar project in this setting has been carried out in Cologne, Germany and has demonstrated that the technique is feasible in this setting, that the grafts survive and that the potential for visual improvement exists.

A concurrent project is the development of homologous RPE graft by ex vivo RPE culture on a substrate in a media that optimise and maintain differentiated state of the RPE. The substrate on which RPE cells are cultured determines the state of differentiation. There are also in vivo and ex vivo evidence that RPE cells dedifferentiate if they are not in contact with the sensory retina. We are, therefore, interested in the potential of co-culturing human retina with RPE cells in inducing further differentiation of the RPE. The combination of using lens capsule and sensory retina samples in RPE culture may optimise differentiation of these RPE cells.

#### **Recruitment**

1. Patients will be identified from the retinal clinics at Moorfields Eye Hospital based on their clinical features.

2. At the time of diagnosis, patients will be counselled about the natural history of the disease and the risks and benefits associated with surgery and other treatments. The aims of the trial and associated risks will be explained in full.
3. Any patient who is interested in taking part in the study will be given a patient information sheet to take home when initially assessed at the vitreoretinal research clinic. The details in this information sheet will be discussed again in full with the patient (and relatives) at a separate research session. Further investigations will also take place to determine if patient is eligible. During these research clinics, there are 3 other consultants present sharing adjacent clinics. These consultants also specialise in retina but they have no affiliation with this study. This provides an opportunity for the patient to discuss the risks of the study with other experts unrelated with the study. If the patient agrees to have surgery (during this or subsequent visit), Mr daCruz will arrange a date for the patient to come in for the operation.

### **General Methodology**

Prospective, non-randomised, interventional case series, piloting a new surgical technique. Ten patients will be recruited and assessed preoperatively, at 10 days, 6 weeks, 3 months, 6 months and 12 months post operatively. At each visit they will undergo assessments as detailed below.

### **Investigations**

1. Best corrected visual acuity at each visit (full refraction pre-op and at 6 months)
2. Reading ability with refraction pre-op and at 6 months
3. Slit lamp biomicroscopic examination and cataract grading pre-op and at 6 months
4. Colour fundus photography (pre-op and 6 months)
5. Fluorescein angiography (pre-op and at 6 months)
6. Optical coherence tomography - Model 3000 (pre-op and at 6 months)
7. Nidek MP1 Fixation and Microperimetry (pre-op and at 6 months)
8. Autofluorescence imaging (pre-op and at 6 months).
9. Indocyanine-green angiography (pre-op and at 6 months).
10. Cataract re-grading at 3 months and surgery arranged if necessary.
11. Patients may be reviewed after 6 months if the surgery has been successful.
12. Quality of life questionnaire (preop and at 12 months).
13. Surplus retinal tissue obtained will be cultured with human RPE cell lines

### **Surgical Technique**

1. Creation of Recipient Site. The patients will undergo a standard three-port pars plana vitrectomy. A small retinotomy will be made temporal to the fovea using a 130° 33 gauge subretinal cannula (Synergetics 12.01, USA) and a shallow posterior retinal detachment

overlying the macula will be created by injecting balanced salt solution (BSS) through the retinotomy and into the sub-retinal space.

2. Harvesting of RPE-Choroid Graft. Retinal diathermy will be applied and the retina cut to gain access to the underlying RPE. Vertical scissors will be used to cut a full-thickness RPE-choroid graft. The infusion pressure will be increased again during this time to reduce the risk of choroidal haemorrhage. The patient will be hyperventilated slightly during the procedure to induce choroidal vasoconstriction. The surplus retina on the donor patch graft is then removed from the eye for RPE – retina co-culture experiment. The retinal tissue will be placed in a culture medium and transported to the Institute of Ophthalmology within 24 hours.

3. Placement of RPE-Choroid Graft. The RPE-choroid graft will be placed (RPE surface up) under the fovea. The retina will then be flattened by subretinal fluid aspiration through the retinotomy. Final adjustments are made during aspiration to ensure the fovea falls onto the centre of the RPE bed. In some cases, where a single retinal flap may give access to both the fovea and RPE harvest site, perfluorocarbon may be used to roll the retina back into position.

4. Closure. To reduce the risk of proliferative vitreoretinopathy (PVR), all RPE cells will be aspirated with a flute prior to air exchange. Laser retinopexy or cryotherapy will be applied to the margins of the RPE-choroid donor site. The vitreous cavity will be drained as much as possible before withdrawing instrumentation and exchanging to silicone oil.

### **Laboratory Technique**

1. Transport and storage of retinal tissue. The retinal tissue will be transported in culture medium without label to the Institute of Ophthalmology. It will be stored in Professor Pete Coffey's laboratory.

2. Human RPE cell culture. Human RPE cells are obtained from commercial ARPE19 providers or derived from commercial human embryonic stem cells.

3. Coculturing with human retina. Retinal sample will be placed over these cell lines in a culture medium with or without substrate (artificial or human lens capsule)

4. Methods of analysis for differentiation. Cells will be studied by confocal microscopy with immunostaining and electron microscopy. RPE transepithelial resistance will also be studied.

5. Destruction of human tissue. After completion of experiment, the tissues will be discarded according to the protocol set up by the Institute of Ophthalmology.

### **Consultation and Informed Consent**

All prospective research participants will be given a Patient Information Sheet describing the study in terms that are understandable by non-medical members of the public. We will use our own press officer to disseminate results of ongoing research to the public objectively through the media and listen to feedback generated from interest groups.

### **Inclusion Criteria**

1. A diagnosis of dry (atrophic) Age Related Macular Degeneration.
2. Visual acuity of 6/24 or less in the treatable eye
3. Evidence of recent loss of reading ability in the past 12 months in the study eye
4. Over 50 years old
5. Fit for surgery and able to consent to surgery
6. Autofluorescent imaging and full-field ERG results suggestive of a localised macular disorder

### **Exclusion Criteria**

1. Inability to give informed consent
2. Unfit for local or general anaesthetic
3. Inability to complete follow-up programme
4. Any other concurrent corneal, retinal or neurological pathology affecting central vision

### **Benefits of Study**

The results of van Meurs et al (2003) demonstrate that this surgical technique is worth exploring. Although the diseases being treated slightly different, they are conceptually both macular diseases due to pigment cell loss. We believe a recent decrease in reading vision - implying a window period where the retina remains healthy - is the key in successful transplantation. The unique combination of medical and surgical retina expertise at Moorfields Eye Hospital in London makes this an ideal site to investigate alternative treatment options. If successful, the surgery would improve vision in patients recruited for the trial, increase the understanding of the pathological mechanisms of the diseases, and develop new surgical techniques, applicable to other disorders.

### **References**

- van Meurs JC, van den Biesen PR Autologous retinal pigment epithelium and choroid translocation in patients with exudative age-related macular degeneration: short-term follow-up. *AJO* 2003; 136:668-695
- Kirchhof B, Joeres S, Fawzy N, Heussen FMA, Prinz B, Joussem AM. Autologous translocation of the choroid and RPE in patients with geographic Atrophy. *ARVO abstracts* 2691, 2006.
- Treumer F, Buse A, Klatt C, Roeder J. Autologous RPE-choroid sheet transplantation in AMD: morphological and functional results. *BJO* 2006; E-pub
- Joussem AM, Heussen FMA, Joeres S, Llacer H, Prinz B, Rohrschneider K, Maaijwee KJM, van Meurs JC, Kirchhof B. Autologous translocation of the choroid and retinal pigment epithelium in age-related macular degeneration. *AJO* 2006; 142:17-30
- MacLaren RE, Uppal GS, Balaggan KS, Tufail A, Munro PMG, Milliken AB, Ali RP, Rubin GS, Aylward GW, Da Cruz L. Autologous transplantation of the retinal pigment epithelium and choroid in the treatment of neovascular age-related macular degeneration
- Eckardt C, Eckardt U and Conrad HG. Macular rotation with and without counter-rotation of the globe in patients with age-related macular degeneration. *Graefes Arch Clin Exp Ophthalmol* 1999; 237:313-25
- Gass JDM. Biomicroscopic and histopathologic considerations regarding the feasibility of surgical excision of subfoveal neovascular membranes. *Am J Ophthalmol* 1994; 118:285-98
- Stanga PE, Kychenthal A, Fitzke FW et al. Retinal pigment epithelium translocation after choroidal neovascular membrane removal in age-related macular degeneration. *Ophthalmology* 2002;109:1492-8
- Thomas MA, Dickinson JD, Melberg NS, Ibanez HE and Dhaliwal RS. Visual results after surgical removal of subfoveal choroidal neovascular membranes. *Ophthalmology* 1994; 101: 1384-96
- Wong D, Lois N. Foveal relocation by redistribution of the neurosensory retina. *Br J Ophthalmol* 2000; 84: 352-7



## B. Participant Information Sheet



**Moorfields Eye Hospital**  
NHS Foundation Trust



Version IV – 1<sup>st</sup> April 2007

City Road  
London  
EC1V 2PD

Vitreoretinal Research Unit

cells from one part of the eye to the other. The vitreous fluid is replaced with a clear silicone oil at the end of surgery. This is removed at a second operation usually combined with cataract surgery. Any improvement in vision should be evident when the silicone oil is removed 2 months after the first operation. We will see you at specific time after that, as part of the normal follow-up for AMD.

### 3. Why have I been chosen?

You have been chosen for this study because we believe that the onset of your symptoms is relatively recent and before the pigment cell disease has had a chance irreversibly to damage the retina. Unfortunately, at the present time there are no proven treatments to improve your vision or prevent further visual loss.

### 4. Do I have to take part?

It is up to you to decide whether or not to take part. If you do decide to take part, you will be given this information sheet to keep and asked to sign a consent form. Even if you do decide to take part, you are still free to withdraw at any time and without giving a reason. A decision to withdraw at any time, or a decision not to take part, will not affect the standard of care you receive in any way.

### 5. What will happen to me if I take part?

The study involves an initial full day of tests, followed by the operation (usually within six weeks) and then follow-up reviews over six months. For the operation you will be required to stay the night after surgery. If transport is difficult for you, you can also come in on the day before the operation. The follow-up schedule is the same as if you had a standard retinal operation, although a few more tests will be done at each visit. The clinic visit is unlikely to last more than four hours. If for whatever reason, the relevant tests cannot be done at your standard visit, you may be asked to make an extra visit, but you would be eligible for travel expenses of up to £20.00 for this. Please note that travel expenses are not applicable for the standard clinic visits, which anyone undergoing an operation on the retina would ordinarily attend. You do not need to see your GP for any additional medications or tests relevant to the study.

Any tests done at Moorfields Eye Hospital will be stored electronically on the hospital computers and will be accessible to anyone who sees you in clinic at subsequent visits, even after the study has been completed. This is standard practice for all patients whether or not they are in a study.

By agreeing to take part, we would expect you to attend the clinic visits as requested after the operation. This is also for your benefit, in case any unexpected problems arise. It is not possible to have the operation without the tests, although you are reminded that you are free to withdraw at any time. This is not a 'randomized' trial; if you take part in the trial you will have the surgery as described. There is no 'placebo' or dummy procedure.

The flow chart at **APPENDIX 1 (at the end of this patient information sheet)** summarises the hospital visits required for the trial.

## PATIENT INFORMATION SHEET

**Title of Project:** Retinal pigment cell transplantation for the treatment of Dry Age-related Macular Degeneration

**Name of Researcher:** Mr Lyndon da Cruz

### 1. Invitation

You are being invited to take part in this research study. Before you decide, it is important for you to understand why the research is being done and what it will involve. Please take time to read the following information carefully and discuss it with others if you wish. Ask us if there is anything that is not clear or if you would like more information. Take time to decide whether or not you wish to take part.

### 2. Background and aim of the study

Age-related macular degeneration (AMD) is a disease of the pigmented cells in the retina, which leads to a loss of central vision. It is now the commonest cause of blind registration in the UK. Sadly there is no treatment available for the dry type of AMD which accounts for 60-90% of advance AMD. This study will test a new surgical treatment to replace the pigmented cells in the retina. Essentially, a small patch of healthy cells from the edge of the retina in the same eye is moved to replace damaged cells in the central retina. We believe this procedure may slow the decline and possibly lead to an improvement in central vision. A similar treatment has been done before at Moorfields Eye Hospital for wet degeneration. A recent study in Europe has also shown visual benefit with a very similar study. This study involves a standard operation (vitrectomy) that involves removal of the vitreous fluid from behind the lens. A small patch of retinal pigment cells is then taken from the peripheral retina and placed under the central retina to replace the lost pigmented cells. There is no foreign tissue – the transplantation is simply moving pigment

**Patron:** Her Majesty The Queen

**Chairman:** Sir Thomas Boyd-Carpenter

**Chief Executive:** Ian Balmer

**threatening complication (retinal detachment, infection, haemorrhage) during cataract surgery is 1 -4 in 1000.** If you have already had cataract surgery then you need not worry, as the cataract cannot return.

- b) **Retinal Detachment:** This may occur in 10-20% of cases. Most retinal detachments are treatable (about 90%) but you would require another operation to have it fixed. The retinal detachment operation is similar to the trial operation.
- c) **Haemorrhage:** The operation involves blood vessels within the eye and these may bleed (haemorrhage). To reduce the risk of haemorrhage, aspirin should be stopped 1 - 2 weeks before surgery, if possible. Mild haemorrhage usually clears by itself within a few weeks, but if more dense may require another operation. In rare cases the haemorrhage may be so severe as to cause long-term damage to the eye (1 - 2 in 1000).
- d) **Infection:** This is relatively rare in retinal surgery and may require you to take intense eye drops (every hour) or possibly even have another operation (less than 1 in a 1000).
- e) **Discomfort:** As with any operation on the eye, there is likely to be some redness and discomfort after surgery. For most people, however, pain is minimal and usually does not require additional medication.
- f) **General anaesthesia:** Modern general anaesthesia is extremely safe even in the elderly population. Temporary breathing problems are most common complication after a general anaesthesia. Nerve injuries and death are very rare (1 in 50,000). Risk of complication from anaesthesia can be reduced by taking the usual medication, following instruction about fasting, not smoking and making sure that the anaesthetist knows about all your medical problems.

**10. What are the possible disadvantages and risks of taking part?**

In agreeing to take part you must appreciate that the main risk is that your vision could be made worse as a result of a complication of the operation. The risk of general anaesthesia, as mentioned above is small but can be serious. You have to weigh up the possible benefits of a new treatment against the risks. Only you can do this. You should remember, however, that we would not have selected you if we felt in any way that the risks of surgery outweighed any benefits you might get. However this is a new technique and we cannot provide you with statistics on exactly how we expect things to turn out. We are here to advise, but not to make the decision for you (see also paragraph 4 above).

**11. What are the possible benefits of taking part?**

The main benefit is that your vision might improve or that the natural deterioration is slowed or halted. We are not simply testing out a new surgical technique – all parts of this procedure have already been performed in whole or in part in other operations. We hope

**6. What do I have to do?**

After surgery you will need to avoid contact of your eyes with tap or other non-sterilised water for at least 2 weeks. Although you are allowed to walk, sit and lie flat in your bed as you would normally do, we would ask you to take it easy for about 2 weeks after surgery. This would mean taking time off work, avoiding lengthy journeys and refraining from hard physical work. After two weeks you should be back to normal and you can return to normal activities.

**At the end of the operation silicone oil will be placed in the eye. This is done because silicone oil has been shown to stabilise the retina and keep it flat and secure. At a later date (approximately 2-3 months after your operation) the silicone oil will need to be removed from the eye. This is a short and straightforward procedure and can be performed with a local anaesthetic. While the silicone oil is in your eye it will blur your vision compared to what it was before the operation.**

**To ensure that the eye settles quickly you will be given a number of drops to take. These include anti-inflammatory drops to help reduce the inflammation caused by having an operation and antibiotic drops to reduce the possibility of getting an infection in the eye. The drops are usually taken regularly for two weeks and then slowly reduced and stopped over a further four weeks. Once again you will be given an instruction sheet explaining how often and for how long to take each drop prescribed.**

**7. What is the procedure that is being tested?**

We are testing to see whether vision can be improved in dry AMD by surgically replacing damaged pigment cells within the eye. All other parts of the operation, tests and eye drops are standard and are already widely used at Moorfields Eye Hospital.

**8. What are the alternatives for diagnosis or treatment?**

You have been selected for this study because there is currently no other treatment or procedure that is likely to be of benefit in your particular case. You will not miss out on anything if you decide to enter the trial and you would not miss out on any new treatment if it becomes available during or after the trial.

**9. What are the side effects of any treatment received when taking part?**

The main possible side effects are similar for any retinal operation done under general anaesthesia and are as follows:

- a) **Cataract:** This is likely to occur in most cases within 1-2 years and a cataract operation will be offered to you at Moorfields if necessary. **If you already have a cataract, surgery for this will be performed within the trial period at the same time as the removal of the silicone oil in a combined procedure. The risk of a sight**

that the treatment will help you. However, this cannot be guaranteed. The information gained from this study will also help us to treat future patients with AMD.

**12. What if new information becomes available?**

Sometimes during the course of a research project, new information becomes available about the treatment/drug that is being studied. If this happens, we will tell you about it and discuss with you whether you want to continue in the study. If you decide to withdraw we will make arrangements for your care to continue. If you decide to continue in the study you will be asked to sign an updated consent form. Also, on receiving new information we might consider it to be in your best interests to withdraw you from the study. We will explain the reasons and arrange for your normal care to continue.

**13. What happens when the research study stops?**

The study stops six months after the operation. After that your normal follow-up will continue. You may be asked to take part in further tests at subsequent clinic visits as part of your on-going care but no further data will be collected for this study after the six month period. We expect any benefit to be evident at six months, at which time we will also inform you of the results of the study.

**14. What if something goes wrong?**

If you are harmed by taking part in this research project, there are no special compensation arrangements. If you are harmed due to someone's negligence, then you would have grounds for a legal action, but you may need to pay initial legal costs. Regardless of this, the normal National Health Service complaints mechanism is available to you if you wish to complain, or have any concerns about any aspect of the way you have been approached or treated during the course of this study.

**15. Will my taking part in this study be kept confidential?**

If you consent to take part in the research, any of your medical records may be inspected by doctors at Moorfields for the purpose of analysing the results. They may also be looked at by people from regulatory authorities to check that the study is being carried out correctly. Your GP and any ophthalmologists involved in your care will also be informed. Your name, however, will not be disclosed outside the hospital or GP surgery. Generally, you can expect the same degree of confidentiality as if you would get with any routine NHS procedure, as all data can be collected anonymously.

**16. Donation of surplus tissue.**

The retinal tissue on the donor patch graft is normally discarded during the operation so that the graft can function after it is transplanted. We would like to keep this surplus retinal tissue for research at the Institute of Ophthalmology, University College of London. By using this tissue in culture with commercially available pigment cells, we can determine if we are able to improve the quality of these cells for future use in transplantation. If you agree to donate this surplus tissue, it will be collected during surgery without extra steps

or risks to the surgery itself. The collected retina sample will be placed in an unlabelled container for transport to the Institute of Ophthalmology. You will not be identified from the retinal sample. The retina sample will be placed in a culture medium with commercially available pigment epithelial cells to see if it affects the growth and maturation of these pigment cells. We will perform tests on these pigment cells to see if they will be good enough for transplantation. We will not be using your tissue for transplantation. Once photographs of these cells and the retina are taken, the content of the culture (cells and your retina) will be discarded immediately. We will not store or keep any tissue or DNA that you have donated after this experiment.

**17. What will happen to the results of the research study?**

The results of the research will be published in a research journal, probably one that specialises in retinal diseases. It will be available through public libraries or the internet and Moorfields Eye Hospital will keep copies. You will be able to obtain a copy of the research paper if you wish.

**18. Who is organising and funding the research?**

The study is being funded by a grant from Stem Cell Ventures. No funding is dependent upon you entering the study and no-one will benefit financially by enrolling you in the study. None of the doctors or nurses that you will see has any financial interest in any treatment that you might or might not get.

**19. Who has reviewed the study?**

The Moorfields Ethics Committee, the NHS Research Ethics Committee and the Moorfields Research and Development Committee will all have reviewed the study and given approval for it to go ahead.

**20. Contacts for Further Information**

Mr Lyndon daCruz is the principal research doctor. He can be contacted as below:

Mr Lyndon daCruz MBBS FRCOphth FRACO PhD MA  
Consultant Vitreoretinal Surgeon  
Moorfields Eye Hospital  
City Road  
London EC1V 2PD  
Tel: 020 7566 2251

Consumers for Ethics in Research (CERES) also publishes a leaflet entitled 'Medical Research and You'. This leaflet gives more information about medical research in general and looks at some questions you may wish to ask. It does not however have information specific for this study. You may obtain a copy by writing to: CERES, PC Box 1365, London N16 0BW.

**21. Contacts for Eye Emergency**

If you have any problems or difficulties please call Mr Lyndon da Cruz on 0207 566 2285. During out of hours, please call 0207 253 3411 and ask to speak to the Specialist Registrar on call for the vitreoretinal service.

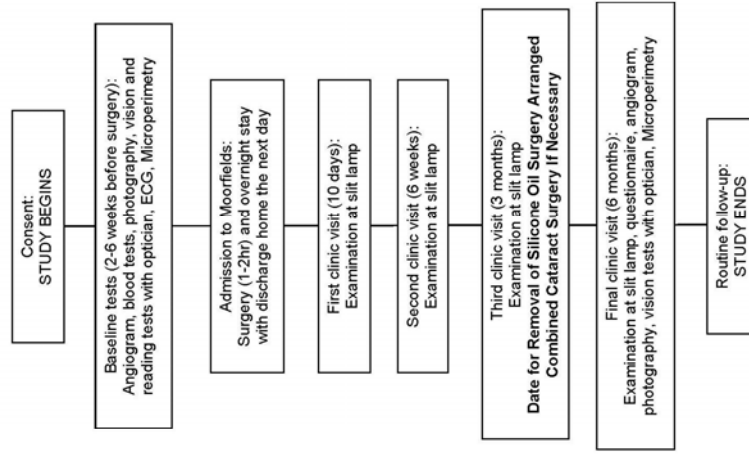
**THANK YOU FOR TAKING TIME TO CONSIDER ENTERING THIS STUDY**

**APPENDIX 1**

**Version IV – 1<sup>st</sup> April 2007**

**Title of Project: Retinal Pigment Cell Transplantation for the Treatment of Dry Age-related Macular Degeneration**

**Schedule of operation and clinic visits:**



*C. Consent form*



**Moorfields Eye Hospital** **NHS**  
NHS Foundation Trust

Version IV – 1<sup>st</sup> April 2007

Study Number:

Patient Identification Number for this trial:

City Road  
London  
EC1V 2PD

Vitreoretinal Research Unit

**CONSENT FORM**

**Title of Project:** Retinal pigment cell transplantation for the treatment of Dry Age-related Macular Degeneration

**Name of Researcher:** Mr Lyndon da Cruz

Please initial box

1. I confirm that I have read and understand the information sheet dated 1<sup>st</sup> April 2007 (version IV) for the above study and have had the opportunity to ask questions.
2. I understand that my participation is voluntary and that I am free to withdraw at any time, without giving any reason, without my medical care or legal rights being affected
3. I understand that sections of any of my medical notes may be looked at by responsible individuals from regulatory authorities where it is relevant to my taking part in research. I give permission for these individuals to have access to my records.
4. I agree to take part in the above study.
5. I understand that my GP will be informed of my participation in this research project and of any findings significant to my general health.
6. I agree to donate the surplus retinal tissue obtained during the surgery for use in the above research project. I understand how the sample will be collected and that giving a sample for this research is voluntary.
7. I agree that the sample I have given can be sent to a laboratory in the UCL Institute of Ophthalmology, as described in the information sheet.

\_\_\_\_\_  
Name of Patient

\_\_\_\_\_  
Date

\_\_\_\_\_  
Signature

\_\_\_\_\_  
Name of Person taking consent  
(if different from researcher)

\_\_\_\_\_  
Date

\_\_\_\_\_  
Signature

\_\_\_\_\_  
Researcher

\_\_\_\_\_  
Date

\_\_\_\_\_  
Signature

Patron: Her Majesty The Queen

Chairman: Sir Thomas Boyd-Carpenter

Chief Executive: Ian Balmer

## *D. Research Ethics Committee Approval*

### **Moorfields & Whittington Research Ethics Committee**

South House, Block A  
Royal Free Hospital  
Pond Street  
London  
NW3 2QG

Tel: 020 7794 0552  
Fax: 020 7794 0714

Mr Lyndon daCruz  
Consultant Ophthalmic Surgeon  
Department of Vitreoretinal surgery  
Moorfields Eye Hospital  
162 City Road  
London, EC1V2PD

23 April 2007

Dear Mr daCruz

**Study title:** Autologous Retinal Pigment Epithelium Transplantation  
for the Treatment Dry Age-related Macular Degeneration;  
a pilot study  
**REC reference:** 06/Q0504/110  
**Amendment number:** 1  
**Amendment date:** 04 April 2007

The above amendment was reviewed at the meeting of the Sub-Committee of the REC held on 23 April 2007.

#### **Ethical opinion**

The members of the Committee present gave a favourable ethical opinion of the amendment on the basis described in the notice of amendment form and supporting documentation.

#### **Approved documents**

The documents reviewed and approved at the meeting were:

Document	Version	Date
Protocol	IV	01 April 2007
Participant Information Sheet	IV	01 April 2007
Participant Consent Form	IV	01 April 2007
Notice of Substantial Amendment (non-CTIMPs)		04 April 2007

**Membership of the Committee**

The members of the Committee who were present at the meeting were Miss Linda Ficker and Mrs Mary Ryan.

**R&D approval**

All investigators and research collaborators in the NHS should notify the R&D office for the relevant NHS care organisation of this amendment and check whether it affects R&D approval of the research.

**Statement of compliance**

The Committee is constituted in accordance with the Governance Arrangements for Research Ethics Committees (July 2001) and complies fully with the Standard Operating Procedures for Research Ethics Committees in the UK.

<b>06/Q0504/110:</b>
----------------------

<b>Please quote this number on all correspondence</b>
---

Yours sincerely

**Ms Kathy Clark**  
**Committee Co-ordinator**

E-mail: [katherine.clark@royalfree.nhs.uk](mailto:katherine.clark@royalfree.nhs.uk)

Copy to: R&D Department Moorfields Eye Hospital NHS Foundation Trust

## **Appendix 4: Long-term Outcomes in Patch Graft Study Documents**

### *A. Study Protocol*

**A case series reporting the 2-year outcomes of successful autologous RPE-choroid transplantation in choroidal neovascularisation (CNV) from age-related macular degeneration:** Protocol version I - 11/04/ 2007

Investigator: Mr Lyndon Da Cruz and Mr Fred K Chen

#### **Introduction**

Age-related macular degeneration (AMD) is a leading cause of blindness in the developed world. Exudative AMD, characterised by leakage of fluid or haemorrhage from choroidal neovascularisation, can lead to acute and permanent central visual loss. Recent advances in intravitreal therapies have shown promise in the treatment of these lesions with over 35% of patients gaining 3 lines or more at 2 years after 24 monthly intravitreal injections.<sup>1</sup> It has been suggested that the mechanism of visual gain is the result of reduction in intra and sub-retinal fluid from the anti-permeability effect of these anti-vascular endothelial growth factor (anti-VEGF) monoclonal antibodies on leaky choroidal neovascular tissue. However, anti-VEGF treatment fails to address the diseased retinal pigment epithelium (RPE) – Bruch's membrane – choriocapillaris complex, the initiating pathology. Furthermore, the complex regulatory pathways in the interaction between VEGF, choroidal neovascular tissue and normal choriocapillaris has raised the concern over the ability of anti-VEGF therapy in inducing complete regression of the neovascular tissue and worse still, the possibility of damage the existing healthy choriocapillaris, which is essential for both RPE and photoreceptor cell function, leading to development of geographic atrophy.

Surgical removal of choroidal neovascular tissue does not lead to improvement of vision due to concomitant removal and damage to the submacular RPE and choriocapillaris.<sup>2</sup> The importance of submacular tissue reconstruction has been reinforced by two surgical techniques developed a decade apart. In the early 1990s, Machemer and Steinhorst relocated the fovea away from the bare neovascular tissue excision site to an area of healthy, but extramacular, RPE by rotating the retina around the optic disc.<sup>3</sup> Ten years later, van Meurs and van den Biesen relocated a patch of RPE choroid graft from the equatorial region to reconstruct the submacular RPE defect after neovascular tissue removal.<sup>4</sup> In both reports, foveal functions were maintained by extramacular RPE.

Although several groups have reported the outcomes of autologous RPE-choroid graft, there is limited information on whether successful visual function after graft is maintained after 1 year.<sup>4-7</sup> We have reported the 6-12 month follow-up results for the first 12 patients who received autologous RPE-choroid graft for treatment of exudative AMD in our institution.<sup>8</sup>



Among these, three patients were able to see 6/24 or better at the end of the study. We have now seen these three patients during routine follow-up visits for over 2 years. Review of case notes of these patients will provide insight into the long-term function of the RPE choroid patch graft and its interaction with foveal photoreceptor cells.

## **Materials and Methods**

The medical notes and imaging investigation results will be obtained for the 12 patients who underwent autologous RPE choroid transplantation under the study number: MACR1002. Patients with 6 months acuity of 6/24 or better will be identified. Some of the patients with poor visual outcome will also be chosen to serve as controls.

Visual acuity, reading acuity and contrast sensitivity measurements in the notes will be recorded. Significant patient history and examination findings will be noted. Any new diagnosis or treatment received during the period will be recorded.

The fundus images performed during and after the study in these three patients will be reviewed and described. The images reviewed will include colour fundus photograph, fundus autofluorescence image, fluorescein angiography, indocyanine green angiography and optical coherence tomography.

## **Benefits of the study**

This 2-year outcome study will provide more information of the long-term survival of peripheral RPE choroid graft and its ability to maintain foveal photoreceptors. We have chosen those with successful visual outcome and compare them with those with poor visual outcome. A comparison of autofluorescence images and angiographies may shed light on the long-term functionality of RPE choroid grafts.

## **References**

1. Brown DM, Kaiser PK, Michels M, Soubrane G, Heier JS, Kim RY, Sy JP, Schneider S. Ranibizumab versus verteporfin for neovascular age-related macular degeneration. *N Engl J Med* 2006;355:1432-1444.
2. Nasir MA, Sugino I, Zarbin MA. Decreased choriocapillaris perfusion following surgical excision of choroidal neovascular membranes in age-related macular degeneration. *Br J Ophthalmol* 1997;81:481-489.
3. Machemer R, Steinhorst UH. Retinal separation, retinotomy, and macular relocation: II. A surgical approach for age-related macular degeneration? *Graefes Arch Clin Exp Ophthalmol* 1993;231:635-641.
4. van Meurs JC, Van Den Biesen PR. Autologous retinal pigment epithelium and choroid translocation in patients with exudative age-related macular degeneration: short-term follow-up. *Am J Ophthalmol* 2003;136:688-695.
5. Jousseaume AM, Heussen FM, Joeres S, Llacer H, Prinz B, Rohrschneider K, Maaijwee KJ, van Meurs J, Kirchhof B. Autologous translocation of the choroid and retinal pigment epithelium in age-related macular degeneration. *Am J Ophthalmol* 2006;142:17-30.
6. Treumer F, Bunse A, Klatt C, Roider J. Autologous RPE-choroid sheet transplantation in AMD. Morphological and functional results. *Br J Ophthalmol* 2006.
7. Jousseaume AM, Joeres S, Fawzy N, Heussen FM, Llacer H, van Meurs JC, Kirchhof B. Autologous translocation of the choroid and retinal pigment epithelium in patients with geographic atrophy. *Ophthalmology* 2007;114:551-560.
8. MacLaren RE, Uppal GS, Balaggan KS, Tufail A, Munro PM, Milliken AB, Ali RR, Rubin GS, Aylward GW, da Cruz L. Autologous transplantation of the retinal pigment epithelium and choroid in the treatment of neovascular age-related macular degeneration. *Ophthalmology* 2007;114:561-570.

B. Hospital Research Governance Approval


MACR1002

**RESEARCH SHORT APPLICATION: PROJECT NO:**

*THIS FORM MUST BE TYPED*

**Full Title:** A retrospective review of case notes looking at the 2-year outcomes of patients with good visual acuity following autologous RPE choroid transplantation in the treatment of choroidal neovascularisation (CNV) secondary to age-related macular degeneration.

**Research Question:** These patients have had autologous RPE choroid patch graft in a pilot study approval by the Moorfields Eye Hospital Research Governance (MACR1002) for treatment of exudative age-related macular degeneration. The aim of the current research is to determine the long-term outcome after successful autologous RPE choroid patch graft.

Have you conducted a literature search on this topic? Is R&D Statistical Support required?	Yes / No Yes/ No
Applicant(s) Name, Title & Contact Number Mr Fred X. Chen (ext 2284)	Supervisor: Mr Lyndon da Cruz Signatures:  Research Co-ordinator: N/A Expected Duration: 2 months
Service/Department_VR/R+D	
Start Date: 09.04.2007	
If Human subjects are involved please indicate whether your study will include: <i>If yes please indicate.</i>	
1) Invasive procedures? 2) Randomised Treatments? 3) New treatments or devices? 4) A questionnaire?	Y/N No Y/N No Y/N No Y/N No (Please attach a copy)
Does your study require: 1) Funding? 2) Space? 3) External collaboration?	
Y/N No Y/N No Y/N No	
For Office Use Only:	
Cost implications for MEH 1) Blood samples? 2) Eye Bank Tissue? 3) Other? Please describe: No	
Y/N No Y/N No No	

Please outline your study design and describe the benefits of the study.

**Design:**  
This is a retrospective descriptive study of patients who have received autologous RPE choroid transplantation under the study number: MACR1002 at Moorfields Eye Hospital during 2004-2005. Case notes and imaging investigations of patients with both good and poor visual function at the end of the pilot study (6 months) will be reviewed and compared. We have chosen to investigate patients with successful visual outcome because in these patients, visual acuity can be used as a marker of RPE function in the area of graft that lies under the fovea. Those with poor visual acuity outcome will serve as controls.

**Benefits:**  
This information will help us to determine if good visual outcome at 6 months is sustained at 2 years after surgery. Any co-morbidity that may contribute to loss of vision between 6 months and 2 years post-operatively will be identified from the case notes. Treatment and outcome of these co-morbidities will be described. This will be the first report of 2 year visual and graft outcome in patients who had successful transplant.

Please attach your protocol to this form (unless previously submitted with associated study).

I agree that this project is scientifically valid and that there are no administrative difficulties with this project

Director of Research:   
Date: 11/06/07

## **Appendix 5: Translocation vs Patch Graft Study Documents**

### *A. Study Protocol*

#### **PROTOCOL: A CASE SERIES REPORTING THE 2 TO 4 YEAR FUNCTIONAL AND STRUCTURAL OUTCOMES OF AUTOLOGOUS RPE CHOROID GRAFT AND MACULAR TRANSLOCATION IN CHOROIDAL NEOVASCULARISATION (CNV) FROM AGE-RELATED MACULAR DEGENERATION.**

**13<sup>TH</sup> NOVEMBER 2007**

**Investigator: Mr Lyndon da Cruz and Mr Fred K Chen**

#### **Introduction**

There have been many reports of the 6 month to 1 year outcomes of macular translocation. More recently, Aisenbrey et al. (2007) reported outcomes in 90 patients who underwent macular translocation at a mean of 3 years. The authors were concerned with the high frequency (60%) of RPE atrophy extending under the fovea during follow up. This group of patients also experienced delayed significant loss of vision. In contrast, there has been no long term data (> 2 years) on autologous RPE choroid graft and occurrence of delayed loss of RPE.

#### **Materials and Methods**

The medical notes and imaging investigation results will be obtained for the 12 patients who underwent autologous RPE choroid graft under the study number: MACR1002 and the first 12 patients who underwent macular translocation under the study number: CHAD1007. Patients who achieved an acuity of 6/24 or better within the first year will be identified and their microperimetry will be closely examined.

Visual acuity, reading acuity and contrast sensitivity measurements in the notes will be recorded. Significant patient history and examination findings will be noted. Any new diagnosis or treatment received during the period will be recorded.

The fundus images performed during and after the study in these patients will be reviewed and described. The images reviewed will include colour fundus photograph, fundus autofluorescence image, fluorescein angiography, indocyanine green angiography and optical coherence tomography.

#### **Benefits of the study**

This 2 to 4 year outcome review will provide more information of the long-term functional and anatomic outcomes of peripheral RPE choroid graft and macular translocation. We have chosen 12 patients from each group for exploratory analysis and comparison between the 2 groups. Due to the small sample sizes, we will restrict our results to case description and descriptive statistics. We are particularly interested in identifying any patients with delayed loss of vision and whether there is any relationship to subfoveal extension of RPE atrophy.

A. Hospital Research Governance Approval

CHRF1009


SAS

**RESEARCH SHORT APPLICATION: PROJECT NO:**

*THIS FORM MUST BE TYPED*

**Full Title:** A retrospective review of case notes looking at the 2 to four year visual and anatomical outcomes following autologous RPE choroid graft and macular translocation in the treatment of choroidal neovascularisation (CNV) secondary to age-related macular degeneration.

**Research Question:** What are the long term (up to 4 years) functional outcomes in the 12 patients who have had autologous RPE choroid patch graft and in the first 12 patients who had macular translocation? Are there any anatomical limitations to the long term outcomes.

<b>Have you conducted a literature search on this topic?</b>	Yes / No
<b>Is R&amp;D Statistical Support required?</b>	Yes/ No
<b>Applicant(s) Name, Title &amp; Contact Number</b> Mr Fred K Chen (ext 2284)	<b>Supervisor:</b> Mr Lyndon da Cruz
<b>Service/Department VR/R+D</b>	<b>Signature:</b> 
<b>Start Date:</b> 09.04.2007	<b>Research Co-ordinator:</b> N/A
	<b>Expected Duration:</b> 2 months

**If Human subjects are involved please indicate whether your study will include:**  
*If yes please indicate:*

1) Invasive procedures?	Y/N	No
2) Randomised treatments?	Y/N	No
3) New treatments or devices?	Y/N	No
4) A questionnaire?	Y/N	No

**Does your study require:**

1) Funding?	Y/N	No
2) Space?	Y/N	No
3) External collaboration?	Y/N	No

**Cost implications for M&H**

1) Blood samples?	Y/N	No
2) Eye Bank Tissue?	Y/N	No
3) Other? Please describe:	No	

**Costings agreed by Finance Department**

For Office Use Only:

**Please outline your study design and describe the benefits of the study**

**Design:**  
This is a retrospective descriptive study of patients who have received autologous RPE choroid graft under the study number: MACR1002 at Moorfields Eye Hospital during 2004-2005 and macular translocation under the study number: CHAD 1007 during 2003-2005. Case notes and imaging investigations of patients with both good and poor visual function at the end of the pilot study (6 months) will be reviewed. We have chosen to investigate patients with successful visual outcome because in these patients, visual acuity can be used as a marker of RPE function in the area of graft that lies under the fovea.

**Benefits:**  
This information will help us to determine if good visual outcome at 6 months is sustained at 2 years and four years after the surgery. Any co-morbidity that may contribute to loss of vision between 6 months and 4 years post-operatively will be identified from the case notes. Treatment and outcome of these co-morbidities will be described. This will be the first report of a 2 or 4 year functional and anatomic outcome in patients who had RPE choroid graft or macular translocation.

**Please attach your protocol to this form (unless previously submitted with associated study)**

*I agree that the project is scientifically valid and that there are no administrative difficulties with this project*

Director of Research  
Date:

  
12/11/07

## **Appendix 6: Long-term Outcomes in Translocation Study Documents**

### *A. Study Protocol*

#### **Two to four year follow-up of macular translocation surgery in neovascular age-related macular degeneration: Protocol version I - 26/11/2008**

Investigator: Mr Fred K Chen

#### **Introduction**

Macular translocation surgery is currently indicated for patients with acute neovascular age-related macular degeneration (AMD) in their second eye and who are not eligible for intravitreal lucentis. The surgical technique involves a vitrectomy, detachment of the retina, 360 degrees of retinotomy, removal of choroidal neovascularisation (CNV) and rotation of the fovea away from the defect in the retinal pigment epithelium (RPE) onto adjacent healthier paramacular RPE and choriocapillaris. Several studies have reported improvement in central visual function following translocation at 1 year.<sup>1-7</sup> We reported the 12 months outcome in the first 27 patients undergoing translocation surgery previously.<sup>8</sup> However, there are relatively few studies which examined whether functional rescue can be sustained by the para-macular RPE for 2 or more years.<sup>9,10</sup> The long-term studies raised concerns regarding sustainability of visual acuity due to the high rates of recurrent geographic atrophy (GA)<sup>9</sup> and CNV<sup>10</sup> at the new subfoveal location. At Moorfields Eye Hospital, a total of 40 patients have now undergone macular translocation surgery. Of these, 30 patients have at least 2 years of follow-up. We wish to examine the clinical notes of these 30 patients to determine if there is late visual function loss and recurrence of GA or CNV.

#### **Purpose**

1. To determine the 2 or more year visual acuity and microperimetry outcomes.
2. To determine the rate of disease recurrence and other late complications.

#### **Materials and Methods**

Patients who underwent macular translocation and had 2 years or more of follow-up will be eligible. We will retrospectively review the medical charts of these patients. Outcome variables include visual acuity, retinal sensitivity, fixation locus and stability, postoperative complications including intraretinal cystic change, recurrent CNV and de novo atrophy, and response of complications to treatment.

## Statistical Analysis

Descriptive analysis will be carried out. Median visual acuity at baseline, 1, 2, 3 and 4 years will be reported. Central and paracentral retinal sensitivity on microperimetry will be calculated. Late postoperative complications will be described. Proportions patients with certain types of complications will be calculated. Change in median visual acuity across different time points will be determined by the non-parametric Friedman test.

## References

1. Toth CA, Freedman SF. Macular translocation with 360-degree peripheral retinectomy impact of technique and surgical experience on visual outcomes. *Retina* 2001;21:293-303.
2. Toth CA, Lapolice DJ, Banks AD, Stinnett SS. Improvement in near visual function after macular translocation surgery with 360-degree peripheral retinectomy. *Graefes Arch Clin Exp Ophthalmol* 2004;242:541-548.
3. Mruthyunjaya P, Stinnett SS, Toth CA. Impact of fluorescein angiographic characteristics of macular lesions on outcomes after macular translocation 360 degree surgery in eyes with age-related macular degeneration. *Retina* 2005;25:597-607.
4. Mruthyunjaya P, Stinnett SS, Toth CA. Change in visual function after macular translocation with 360 degrees retinectomy for neovascular age-related macular degeneration. *Ophthalmology* 2004;111:1715-1724.
5. Lai JC, Lapolice DJ, Stinnett SS, Meyer CH, Arieu LM, Keller MA, Toth CA. Visual outcomes following macular translocation with 360-degree peripheral retinectomy. *Arch Ophthalmol* 2002;120:1317-1324.
6. Aisenbrey S, Lafaut BA, Szurman P, Grisanti S, Luke C, Krott R, Thumann G, Fricke J, Neugebauer A, Hilgers RD, Esser P, Walter P, Bartz-Schmidt KU. Macular translocation with 360 degrees retinotomy for exudative age-related macular degeneration. *Arch Ophthalmol* 2002;120:451-459.
7. Gelisken F, Voelker M, Schwabe R, Besch D, Aisenbrey S, Szurman P, Grisanti S, Herzau V, Bartz-Schmidt KU. Full macular translocation versus photodynamic therapy with verteporfin in the treatment of neovascular age-related macular degeneration: 1-year results of a prospective, controlled, randomised pilot trial (FMT-PDT). *Graefes Arch Clin Exp Ophthalmol* 2007.
8. Uppal G, Milliken A, Lee J, Acheson J, Hykin P, Tufail A, da Cruz L. New algorithm for assessing patient suitability for macular translocation surgery. *Clin Experiment Ophthalmol* 2007;35:448-457.
9. Aisenbrey S, Bartz-Schmidt KU, Walter P, Hilgers RD, Ayertey H, Szurman P, Thumann G. Long-term follow-up of macular translocation with 360 degrees retinotomy for exudative age-related macular degeneration. *Arch Ophthalmol* 2007;125:1367-1372.
10. Baer CA, Rickman CB, Srivastava S, Malek G, Stinnett S, Toth CA. Recurrent choroidal neovascularization after macular translocation surgery with 360-degree peripheral retinectomy. *Retina* 2008.

B. Hospital Research Governance Approval

CHEF 1010

**RESEARCH SHORT APPLICATION: PROJECT NO:**  
THIS FORM MUST BE TYPED

**Full Title:** Two to four year visual outcomes after macular translocation surgery

**Research Question:** Does macular translocation maintain post-operative visual acuity and visual function for 2 or more years?

**Have you conducted a literature search on this topic?** Yes  
**Is R&D Statistical Support required?** No

**Applicant(s) Name, Title & Contact Number**  
Mr Fred K Chen (078 3377 1416)

**Supervisor:** Mr Lyndon Da Cruz

**Signature:**

**Service/Department:** Vitreoretinal Surgery

**Research Co-ordinator:**

**Start Date:** 1<sup>st</sup> December 2008

**Expected Duration:** 8 months

**If Human subjects are involved please indicate whether your study will include:**

*If yes please indicate:*

- 1) Invasive procedures? N
- 2) Randomised treatments? N
- 3) New treatments or devices? N
- 4) A questionnaire? N (Please attach a copy)

**Does your study require:**

- 1) Funding? N
- 2) Space? N
- 3) External collaboration? N

**For Office Use Only:**

**Cost implications for MEH**

- 1) Blood samples? N
- 2) Eye Bank Tissue? N
- 3) Other? Please describe:

**Costings agreed by Finance Department**

**Please outline your study design and describe the benefits of the study**

**Design:** Retrospective case series

**Outcomes:** Visual acuity, microperimetry, OCT features, autofluorescence signal patterns and post operative complications (including recurrent CNV, cystic retinal change and de novo geographic atrophy).

**Sample size:** about 30 patients. — 32 patients (confirmed by Fred)

**Benefits:** This information will be useful in counselling patients about the expected long-term outcome after macular translocation. Long-term structural functional correlation will help to determine if good and poor outcomes can be predicted by structural features.

**Please attach your protocol to this form (unless previously submitted with associated study)**

*I agree that the project is scientifically valid and that there are no administrative difficulties with this project*

**Director of Research**

**Date:**

Research & Ethics September 2004.....

*[Handwritten signature]*

26/11/08

## Appendix 7: ERG outcomes in atrophic macular disease study

Table of the dates of pre- and postoperative electrodiagnostic testing in all patients in the atrophic macular disease study

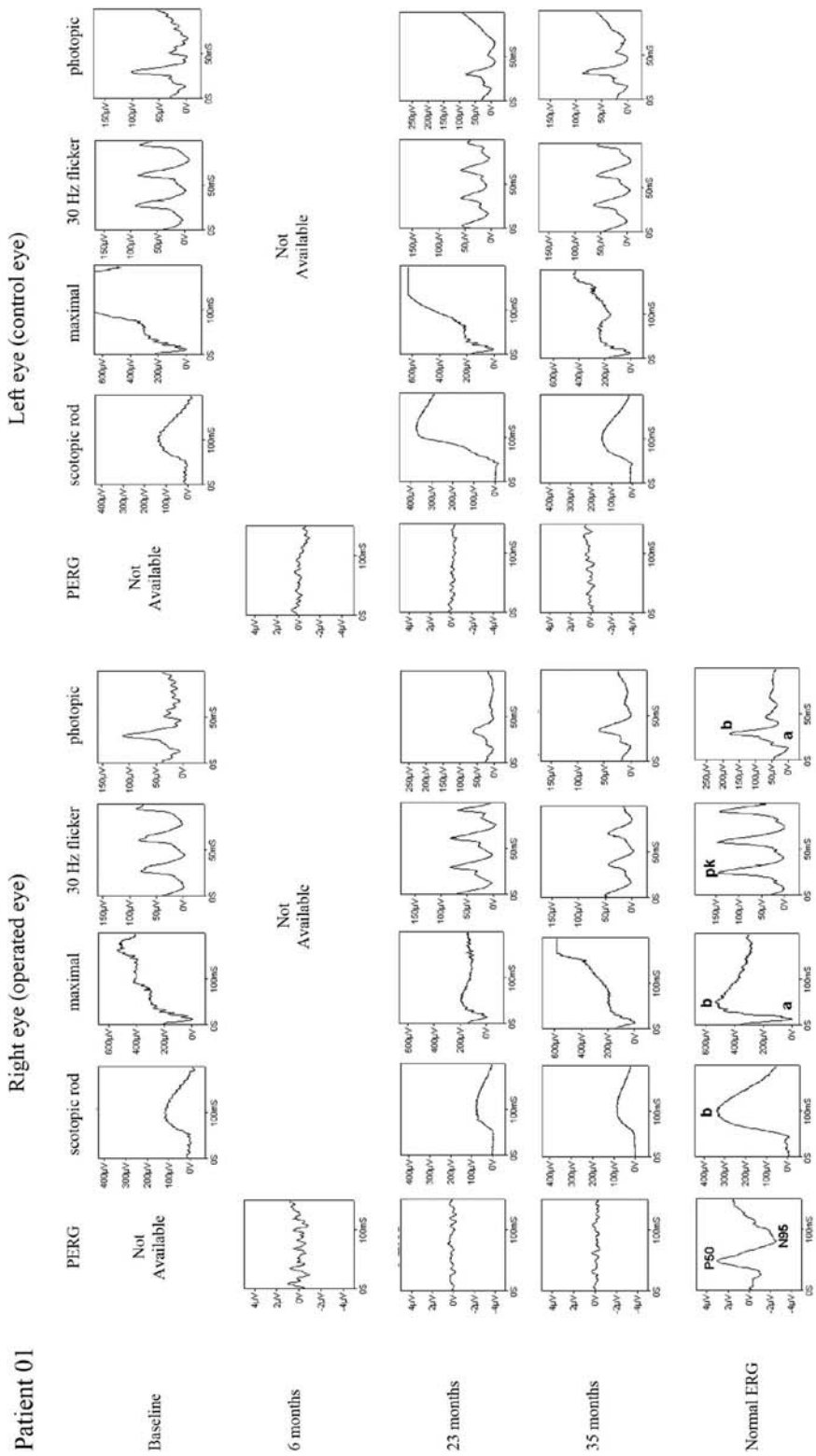
Patient ID (Side)	Previous ERG	Baseline date	Operation date	6 m FU date	12 m FU date	24 m FU date	36 m FU date
1 (RE)	11 Mar 2003 11 Mar 2004	04 Jul 2005†	02 Aug 2005	27 Feb 2006* (~6 m)	14 Feb 2008 (~20 m)	25 Jul 2007 (~23 m)	23 Jul 2008 (~35 m)
2 (LE)	30 Sep 2004	10 May 2006	23 May 2006	12 Dec 2006 (~6 m)	14 Feb 2007 (~8 m)		
3 (LE)	10 Dec 2002 16 Oct 2003	12 Jun 2006*	13 Jun 2006	14 Feb 2007 (~8 m)			
4 (RE)	21 Mar 2002	06 Jul 2006	18 Jul 2006	23 Jan 2007 (~6 m)	19 Dec 2007 (~17 m)		
5 (LE)	09 Oct 2006	08 Jan 2007	09 Jan 2007	15 Aug 2007 (~7 m)			
6 (RE)		01 Jun 2007 19 Jun 2007	19 Jun 2007	13 May 2009 (~10 m)			
7 (RE)		18 May 2007	03 Jul 2007	16 Apr 2008 (~9 m)			
8 (RE)		09 Jul 2007	10 Jul 2007	18 Jan 2008 (~6 m)			
9 (RE)		11 Dec 2007	11 Dec 2007	Not performed			

ERG; electroretinography, FU; follow-up, LE; left eye, PERG; pattern electroretinography, RE; right eye.

\* Full-field ERG not available, † PERG not available



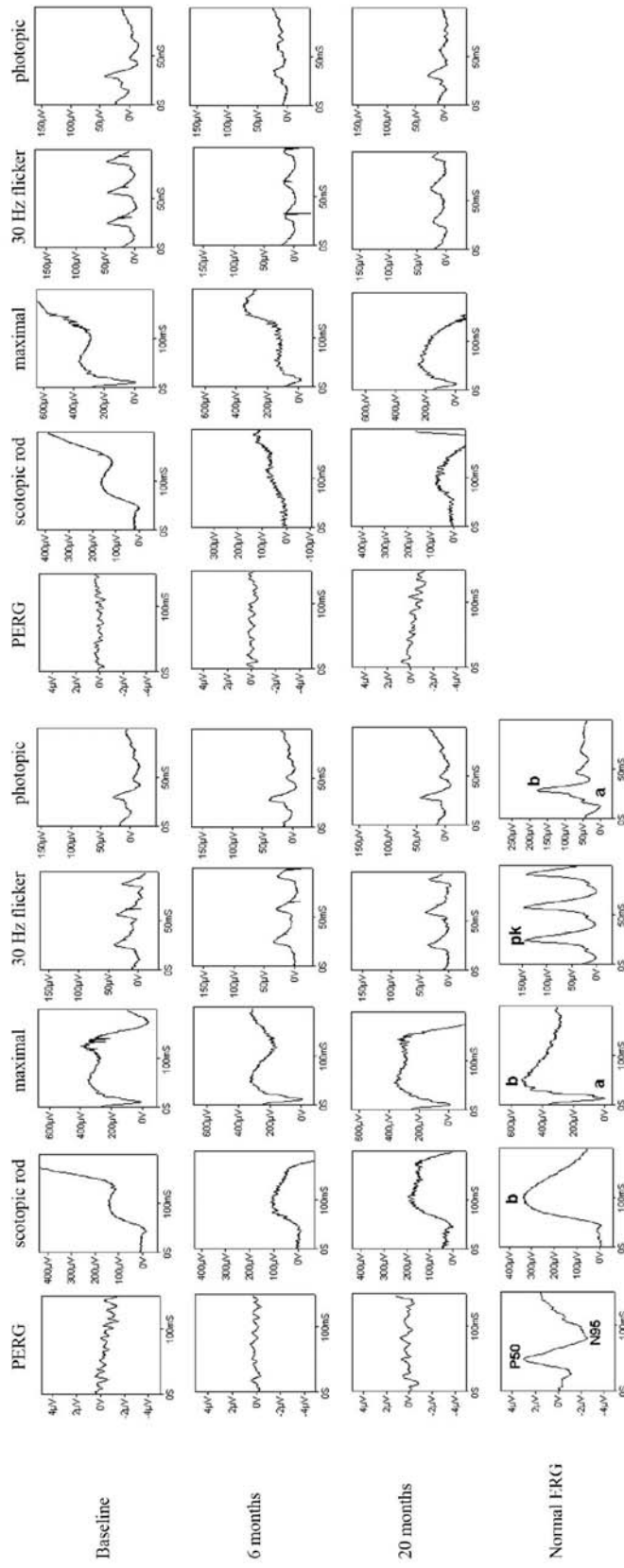
A: pattern and full-field ERG outcomes



Left eye (operated eye)

Right eye (control eye)

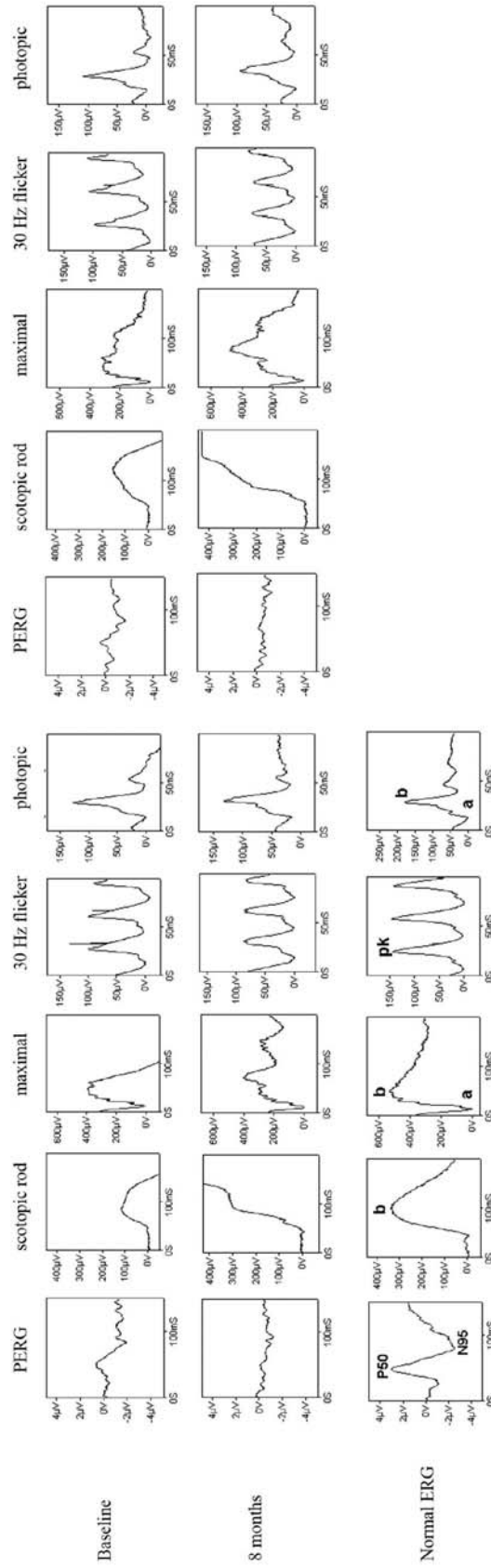
Patient 02



Left eye (operated eye)

Right eye (control eye)

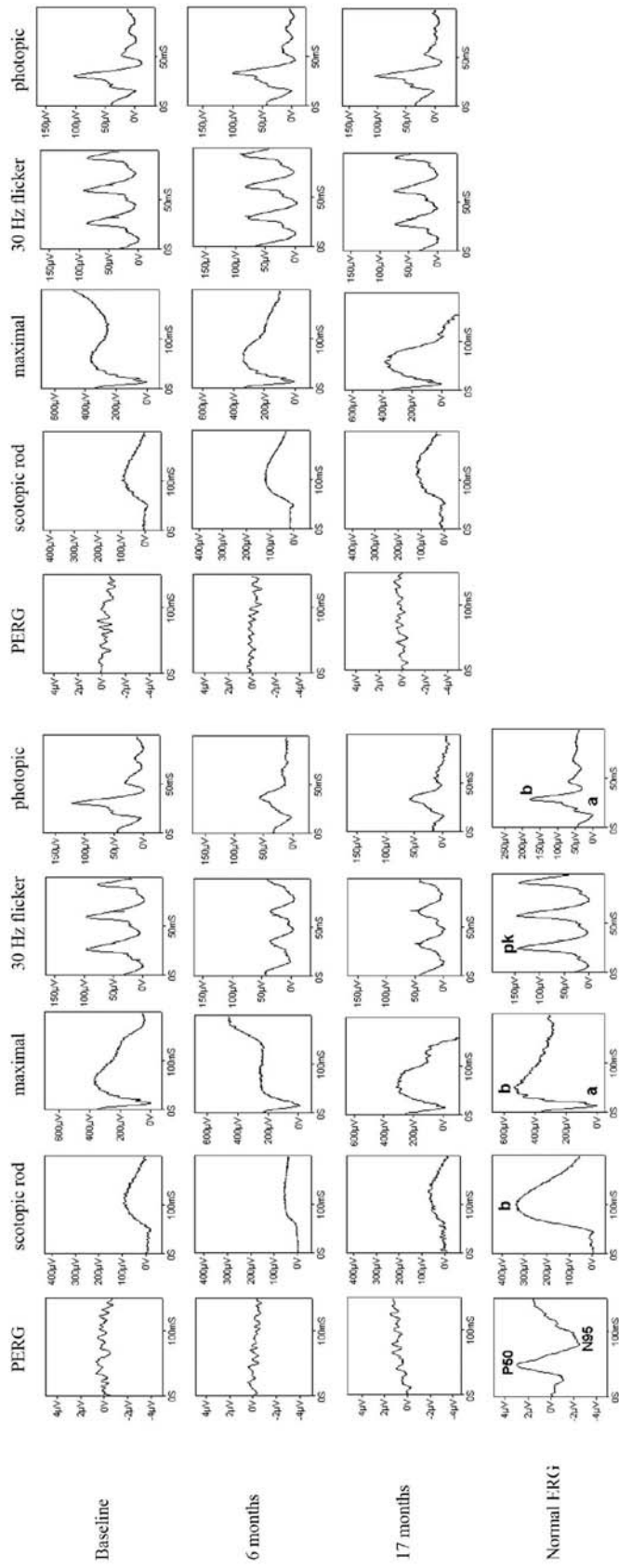
Patient 03



Left eye (control eye)

Right eye (operated eye)

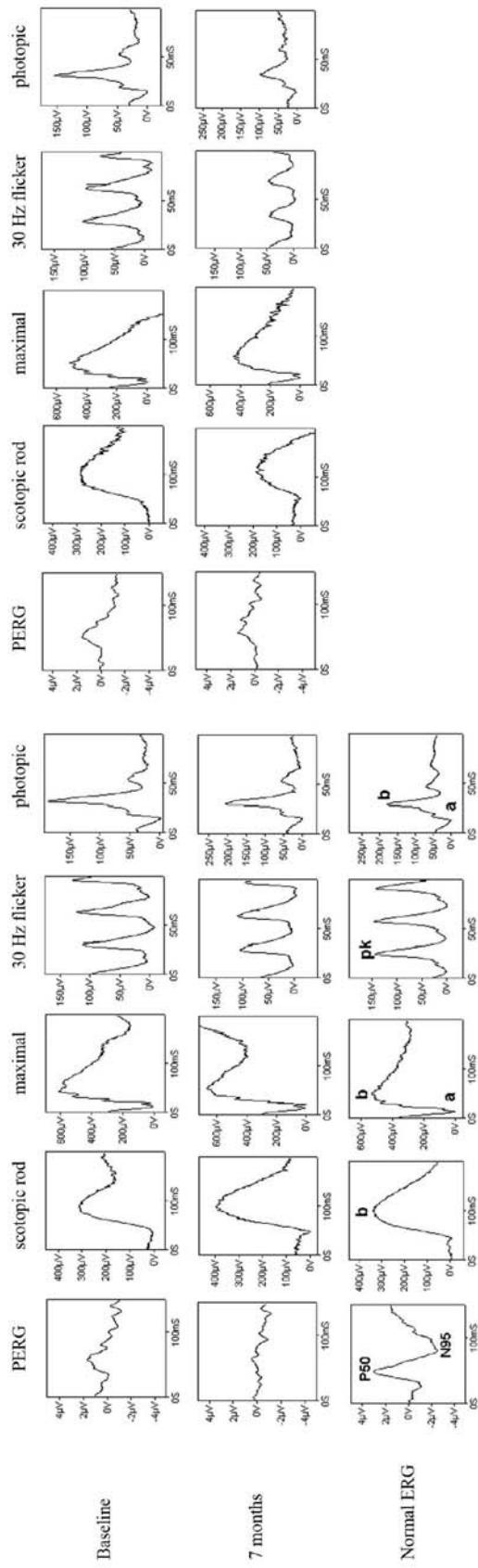
Patient 04



Left eye (operated eye)

Right eye (control eye)

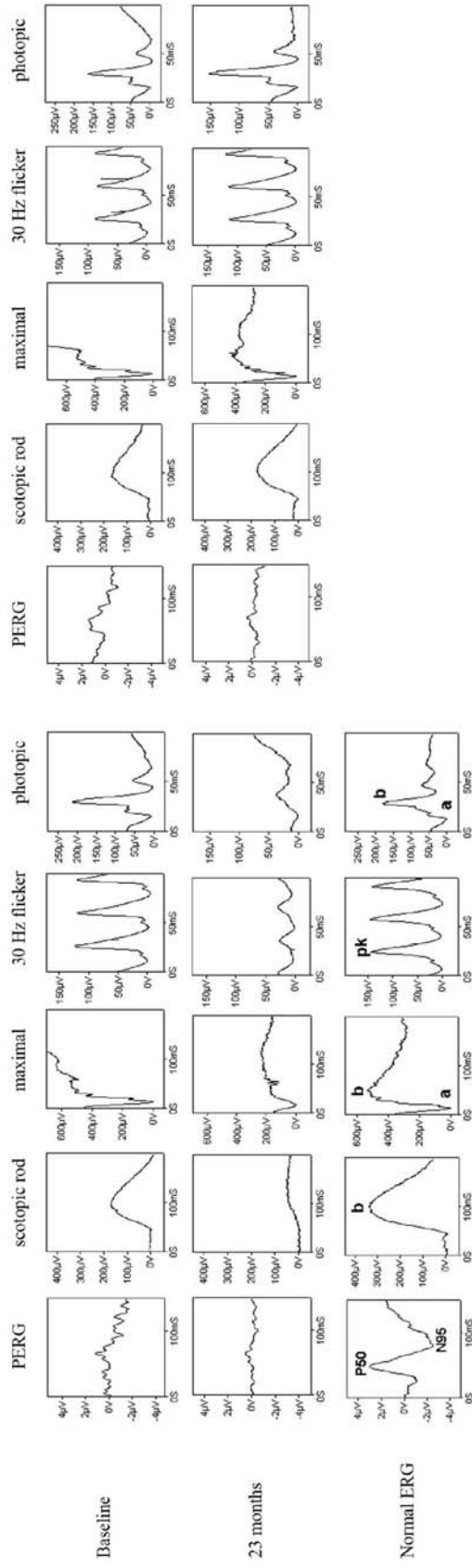
Patient 05



Left eye (control eye)

Right eye (operated eye)

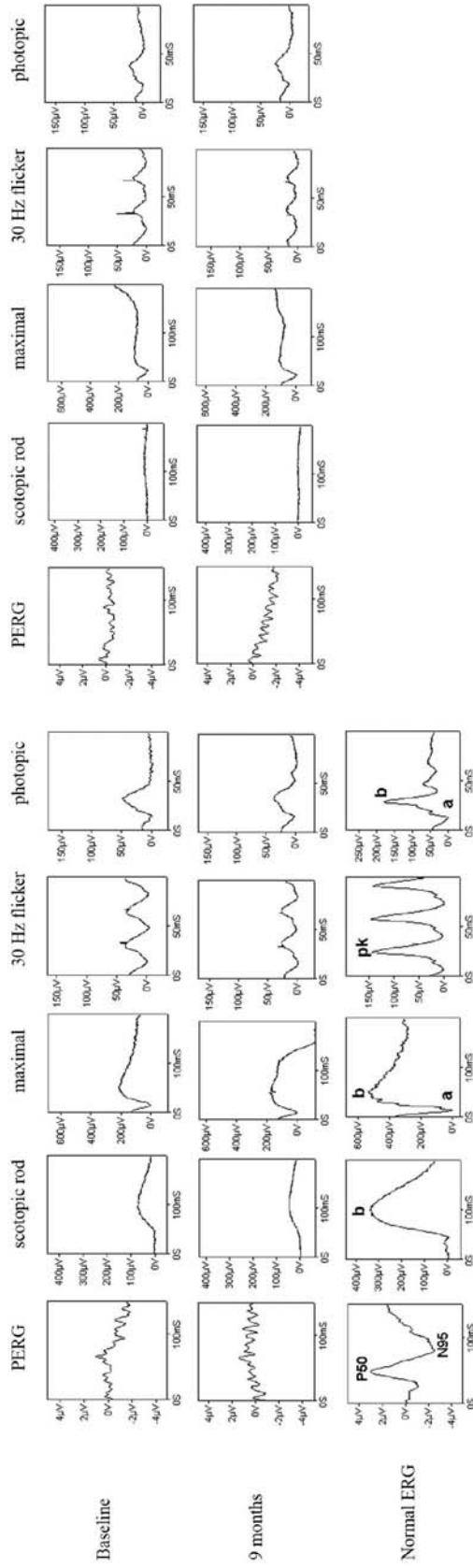
Patient 06



Left eye (control eye)

Right eye (operated eye)

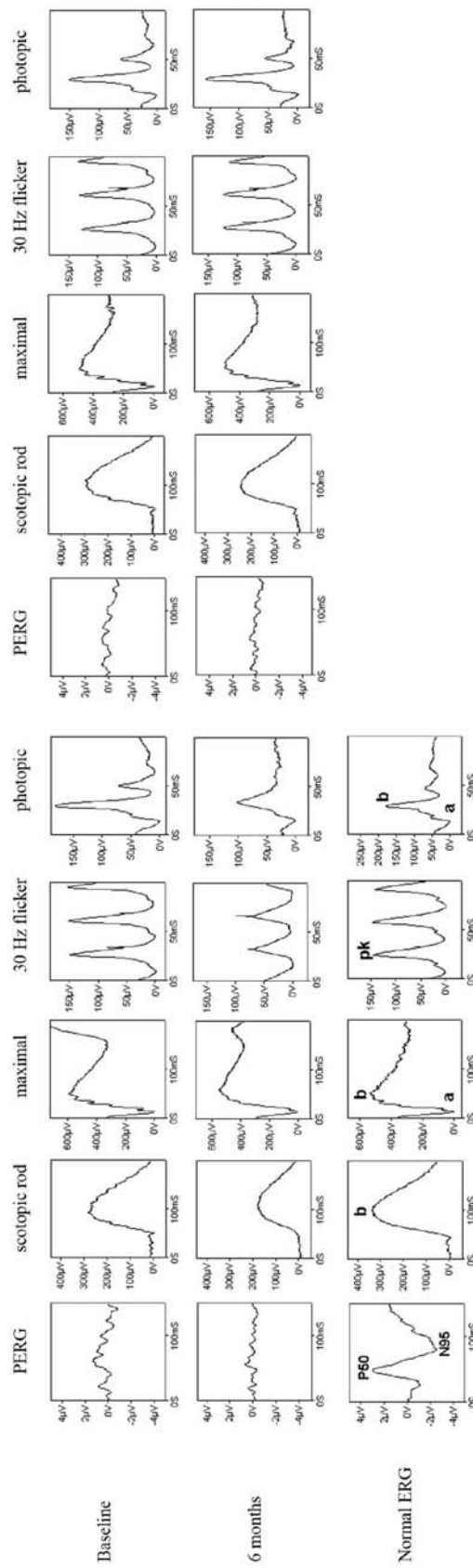
Patient 07



Left eye (control eye)

Right eye (operated eye)

Patient 08






Patient 09

Right eye (operated eye)

Left eye (control eye)

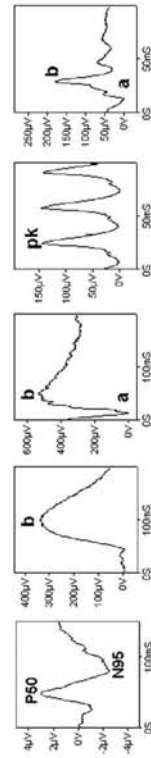


Baseline

6 months

Not Available

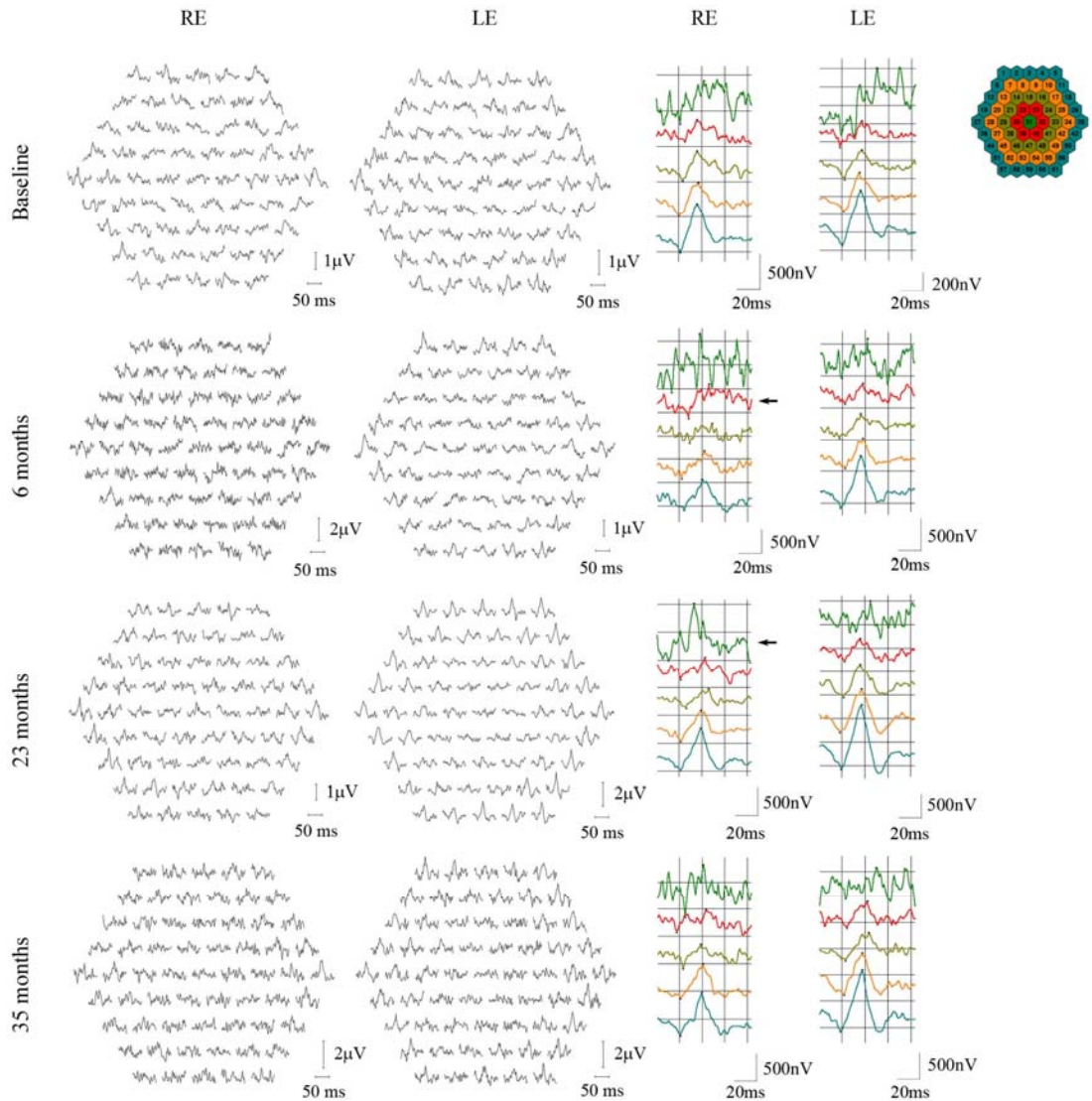
Not Available



Normal ERG

*B: multifocal ERG outcomes*

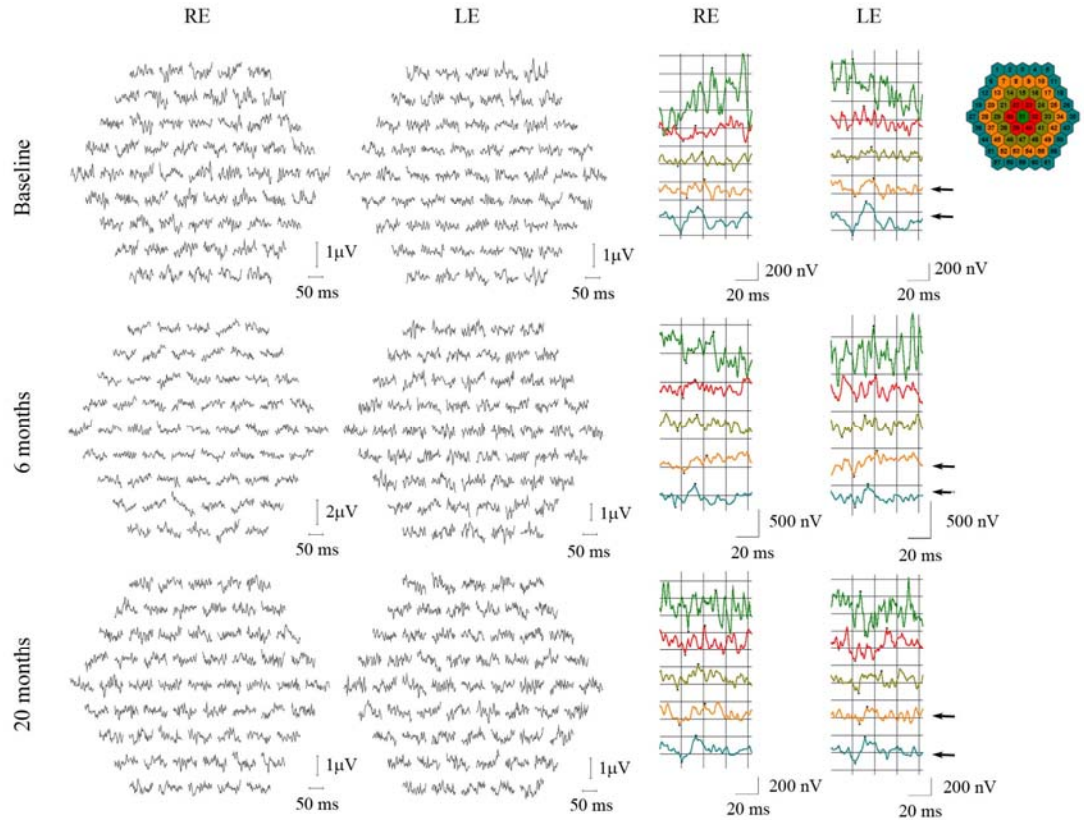
Patient 1



Right eye: Rings 1 and 2 tracing morphology fluctuated between 6 – 35 months. Arrows shows improvement in ring 2 at 6 months and in ring 1 at 23 months. Rings 3 and 4 had mild deterioration. Ring 5 was preserved throughout 35 months.

Left eye: No change in rings 1 to 5 between the 4 test sessions during the 35 months.

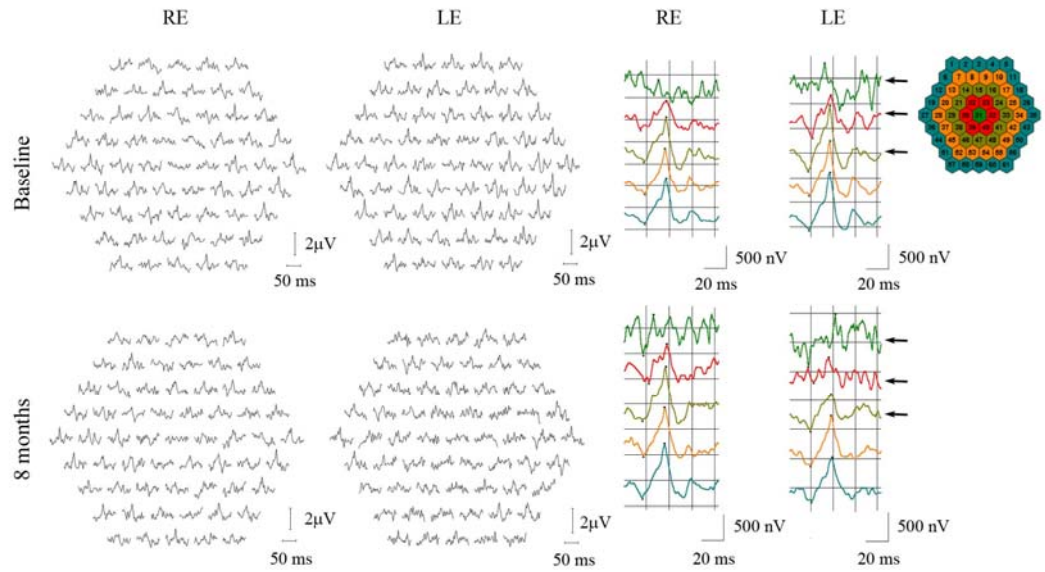
Patient 2



Right eye: No change in rings 1 to 5 between the 3 test sessions during the 20 months.

Left eye: Noisy waveform tracings in rings 1 and 2 during follow-up period. Ring 3 remained unchanged. Rings 4 and 5 (arrows) had deterioration at 6 months which partially recovered by 20 months.

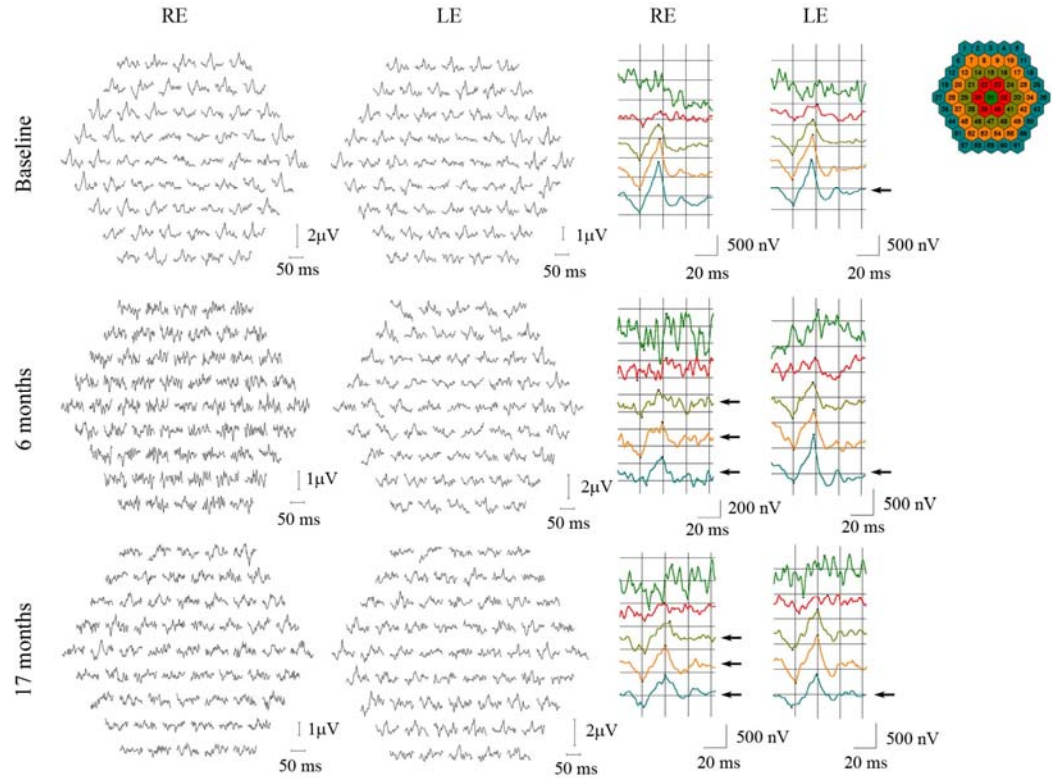
Patient 3



Right eye: No change in rings 1 to 5 between baseline and 8 months.

Left eye: Deterioration was noted in all 6 rings especially in rings 1 to 3 (arrows).

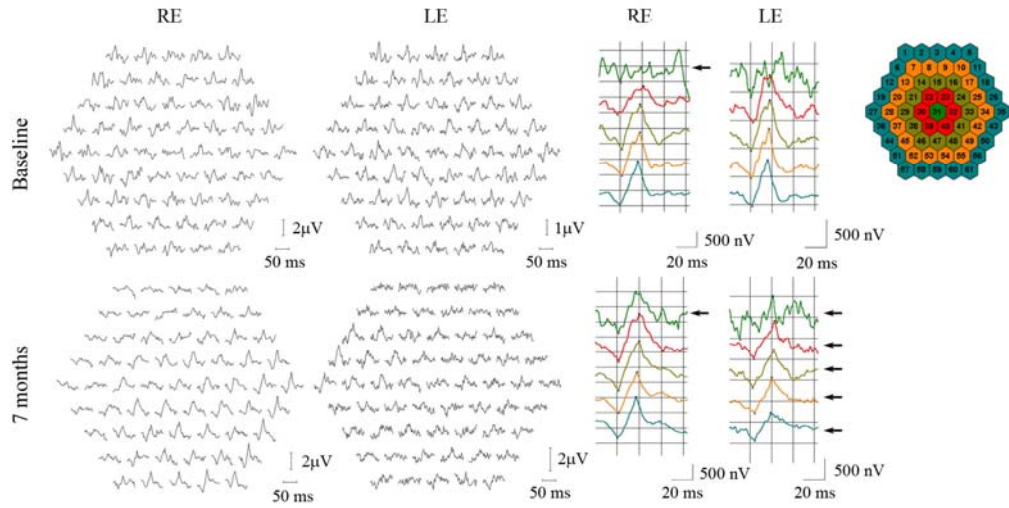
Patient 4



Right eye: Noisy waveform tracings in rings 1 and 2 at all time points. Deterioration in rings 3 to 5 (arrows) at 6 months with partial recovery at 17 months.

Left eye: Some deterioration in ring 5 (arrows) at 17 months.

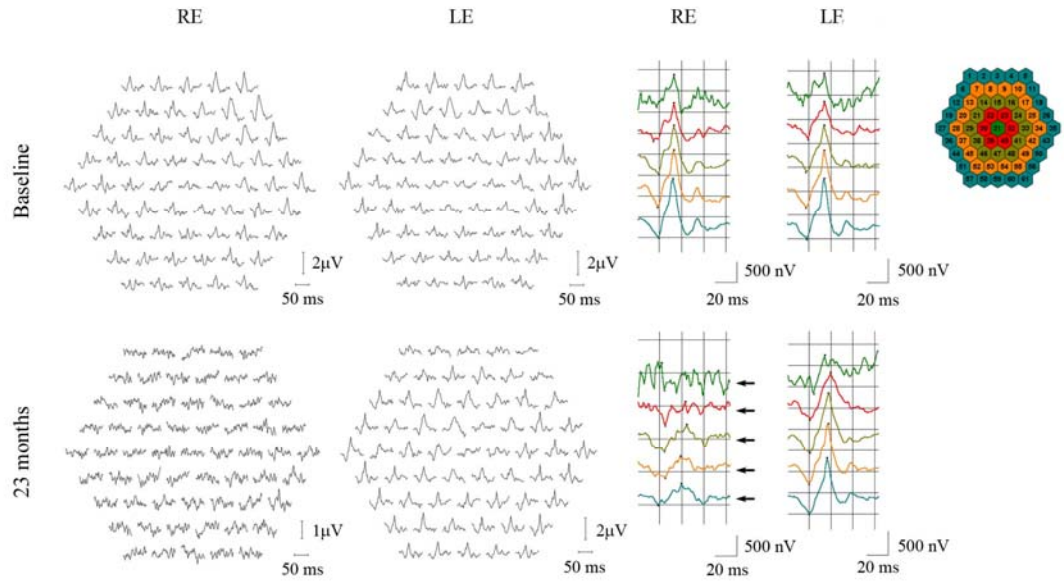
Patient 5



Right eye: Improvement of central ring (arrows) at 7 months

Left eye: Deterioration in all rings (arrows) at 7 months

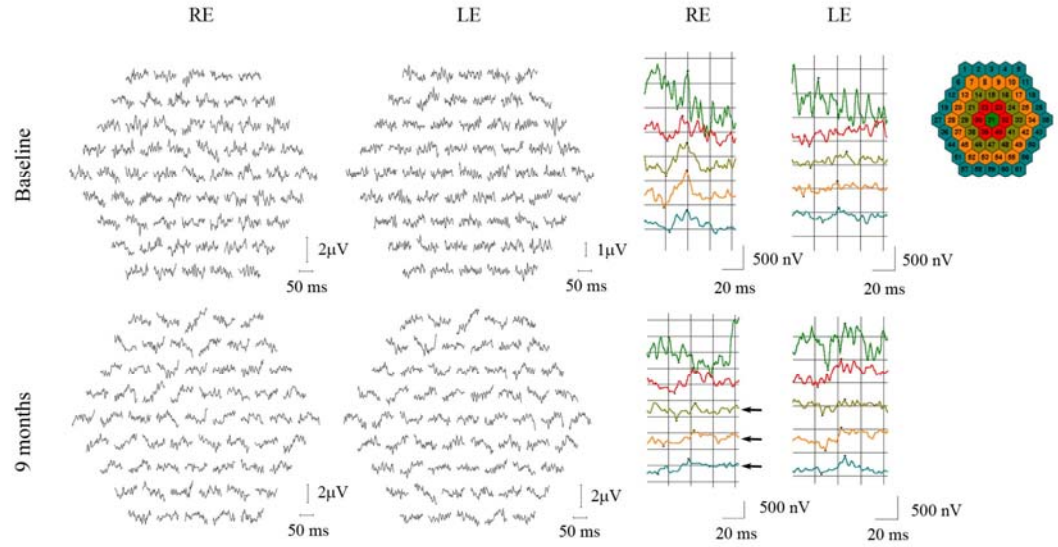
Patient 6



Right eye: Deterioration in all rings (arrows) at 23 months

Left eye: No significant change at 23 months

Patient 7

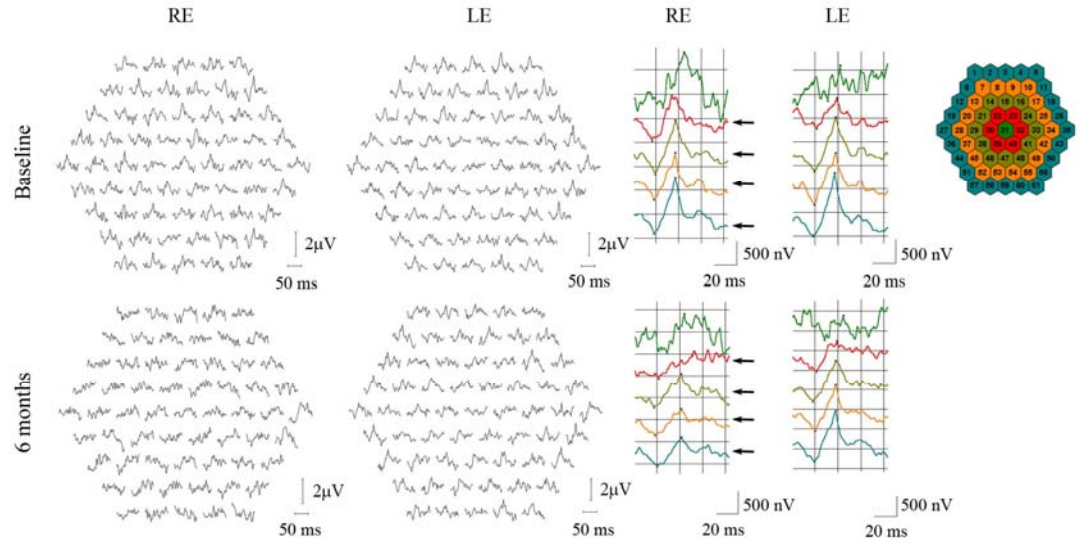


Right eye: Ring 1 had noisy waveforms at baseline and 9 months. Deterioration in rings 3 to 5 (arrows) at 9 months.

Left eye: No change in rings 1 to 5 between baseline and 9 months.



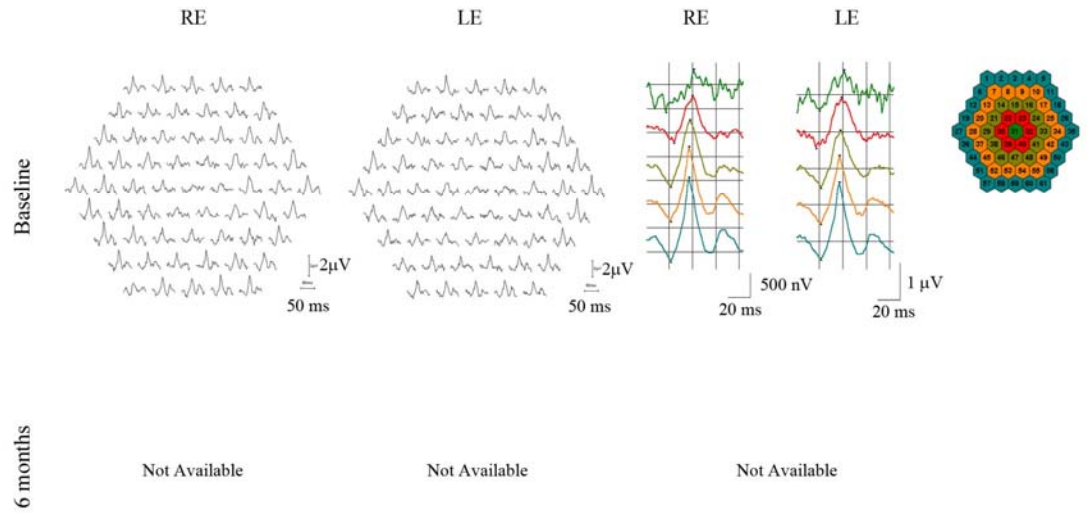
Patient 8



Right eye: Ring 1 response unchanged at 6 months. Marked deterioration of ring 2 (arrows) at 6 months. Some deterioration in rings 3 to 5 (arrows) at 6 months.

Left eye: No change in rings 1 and 2 but preservation of response in rings 3 to 5.

Patient 9



Right eye: Localised area of dysfunction in ring 1.

Left eye: Localised area of dysfunction in ring 1.