


## Accepted Manuscript

A novel mutation in the N-terminal acting-binding domain of Filamin C protein causing a distal myofibrillar myopathy

Chiara Gemelli, Valeria Prada, Chiara Fiorillo, Sabrina Fabbri, Lorenzo Maggi, Alessandro Geroldi, Sara Gibertini, Paola Mandich, Lucia Trevisan, Paola Fossa, Alberto Stefano Tagliafico, Angelo Schenone, Marina Grandis



PII: S0022-510X(19)30019-X  
DOI: <https://doi.org/10.1016/j.jns.2019.01.019>  
Reference: JNS 16167  
To appear in: *Journal of the Neurological Sciences*  
Received date: 26 October 2018  
Revised date: 10 January 2019  
Accepted date: 14 January 2019

Please cite this article as: Chiara Gemelli, Valeria Prada, Chiara Fiorillo, Sabrina Fabbri, Lorenzo Maggi, Alessandro Geroldi, Sara Gibertini, Paola Mandich, Lucia Trevisan, Paola Fossa, Alberto Stefano Tagliafico, Angelo Schenone, Marina Grandis, A novel mutation in the N-terminal acting-binding domain of Filamin C protein causing a distal myofibrillar myopathy. *Jns* (2019), <https://doi.org/10.1016/j.jns.2019.01.019>

This is a PDF file of an unedited manuscript that has been accepted for publication. As a service to our customers we are providing this early version of the manuscript. The manuscript will undergo copyediting, typesetting, and review of the resulting proof before it is published in its final form. Please note that during the production process errors may be discovered which could affect the content, and all legal disclaimers that apply to the journal pertain.

Article title: A novel mutation in the N-terminal acting-binding domain of Filamin C protein causing a distal myofibrillar myopathy.

Key Words:

Filamin C, distal myopathy, myofibrillar myopathy, NGS, hereditary myopathy, *FLNC*.

Corresponding author: Chiara Gemelli

Work address: Clinica Neurlogica, Largo Daneo 3, Genova, 16132, Italy.

E-mail: gemelli.chira@hotmail.it

Telephone number: +39340-3681312

ACCEPTED MANUSCRIPT

## Authors:

Chiara Gemelli MD <sup>a\*</sup>, Valeria Prada PhD <sup>b\*</sup>, Chiara Fiorillo MD PhD <sup>c</sup>, Sabrina Fabbri MD <sup>d</sup>, Lorenzo Maggi MD <sup>e</sup>, Alessandro Geroldi PhD <sup>d</sup>, Sara Gibertini PhD <sup>e</sup>, Paola Mandich MD PhD <sup>f</sup>, Lucia Trevisan <sup>f</sup>, Paola Fossa <sup>g</sup>, Alberto Stefano Tagliafico MD PhD <sup>h</sup>, Angelo Schenone MD <sup>i</sup>, Marina Grandis MD PhD <sup>1</sup>

## Author Affiliation:

a: Department of Neurosciences, Rehabilitation, Ophthalmology, Genetic and Maternal and Infantile Sciences (DINOEMI), University of Genova, Largo Daneo 3, 16132, Genova, Italy. Electronic address: gemelli.chiara@hotmail.it

b: Department of Neurosciences, Rehabilitation, Ophthalmology, Genetic and Maternal and Infantile Sciences (DINOEMI), University of Genova, Largo Daneo 3, 16132, Genova, Italy. Electronic address: Electronic address: valeria.prada@gmail.com

c. Department of Neuroscience, Paediatric Neurology and Neuromuscular Disorders, Istituto Giannina Gaslini, University of Genova, Via Gerolamo Gaslini, 5, 16147 Genova, Italy

d: Department of Neurosciences, Rehabilitation, Ophthalmology, Genetic and Maternal and Infantile Sciences (DINOEMI), University of Genova, Largo Daneo 3, 16132, Genova, Italy.

e: Neuromuscular Diseases and Neuroimmunology Unit, Fondazione IRCCS Istituto Neurologico “Carlo Besta”, Via Celoria 11, 20133 Milano, Italy

f: Department of Neurosciences, Rehabilitation, Ophthalmology, Genetic and Maternal and Infantile Sciences (DINOEMI), University of Genova, Largo Daneo 3, 16132, Genova, Italy; Ospedale Policlinico San Martino IRCCS-Medical Genetic Unit, Largo R. Benzi 10, 16132, Genoa, Italy.

g: Department of Pharmacy, Section of Medicinal Chemistry, School of Medical and Pharmaceutical Sciences, University of Genova, Viale Benedetto XV 3, 16132 Genova, Italy

h: Department of Health Sciences (DISSAL), Radiology Section, University of Genova, Via Pastore, 1-16132, Genova, Italy; Emergency Radiology, Policlinico San Martino, Largo Rosanna Benzi, 10-16132, Genova, Italy.

i: Department of Neurosciences, Rehabilitation, Ophthalmology, Genetic and Maternal and Infantile Sciences (DINOEMI), University of Genova, Largo Daneo 3, 16132, Genova, Italy; Ospedale Policlinico San Martino IRCCS-Neurological Unit, Largo R. Benzi 10, 16132, Genova, Italy.

l: Department of Neurosciences, Rehabilitation, Ophthalmology, Genetic and Maternal and Infantile Sciences (DINOEMI), University of Genova, Largo Daneo 3, 16132, Genova, Italy; Ospedale Policlinico San Martino IRCCS-Neurological Unit, Largo R. Benzi 10, 16132, Genova, Italy. Electronic address: [mgrandis@neurologia.unige.it](mailto:mgrandis@neurologia.unige.it)

\* Both authors contributed equally to this work

**Abstract:**

Variants in Filamin C (*FLNC*) gene may cause either cardiomyopathies or different myopathies. We describe a family affected by a distal myopathy with autosomal dominant inheritance. The onset of the disease was in the third decade with gait impairment due to distal leg weakness. Subsequently, the disease progressed with an involvement of proximal lower limbs and hand muscles. Muscle biopsy, performed in one subject, identified relevant myofibrillar abnormalities.

We performed a target gene panel testing for myofibrillar myopathies by NGS approach which identified a novel mutation in exon 3 of *FLNC* gene (c.A664G:p.M222V), within the N-terminal actin-binding (ABD) domain. This variant has been identified in all affected members of the family, thus supporting its pathogenic role. Differently from previously identified variants, our family showed a predominant leg involvement and myofibrillar aggregates, thus further expanding the spectrum of Filamin C related myopathies.

**Key Words:**

Filamin C, distal myopathy, myofibrillar myopathy, NGS, hereditary myopathy, *FLNC*.

**Abbreviations:**

ABD: actin-binding domain; CMAP: compound muscle action potential; CK: creatine kinase; *FLNC*: Filamin C; EMG: electromyography; MUAP: motor unit action potential; NGS: Next Generation Sequencing.

Title: A novel mutation in the N-terminal actin-binding domain of Filamin C protein causing a distal myofibrillar myopathy.

Dear Editor,

Introduction:

Filamins are 3 actin-crosslinking proteins, including: A, B and C. They share a common structure: a N-terminal ABD consisting of two calponin homology (CH) domains, followed by a semiflexible rod of 24 immunoglobulin-like repeats and a C-terminal dimerization domain [1]. The gene *FLNC* is located in 7q32-q35 chromosome and codifies for Filamin C, the muscle specific isoform expressed in the cardiac and skeletal muscles [2]. Filamin C localizes in the Z-disc, here interacting with different proteins including myotilin [1] and extends in the sarcolemma where it connects to both the transmembrane receptor  $\beta$ 1-integrin [3] and the dystrophin-glycoprotein complex [4]. Through these connections, Filamin C stabilizes the actin filament networks and links it to cell membranes[5]. Mutations in *FLNC* cause progressive myopathies or different cardiomyopathies [6]. Different types of Filamin C related muscle phenotypes have been described according to the mutation domain [5]. Mutations in rod domain tend to cause a proximal myopathy with onset in fourth-to-sixth decade and with typical myofibrillar features with frequent involvement of the cardiac and respiratory muscles [7]. Conversely, mutations in the actin-binding domain (ABD) of *FLNC* are responsible for another phenotype, initially characterized by weakness and wasting of distal muscles, especially intrinsic hand muscles, manifesting in the third decade of life and a later involvement of posterior calf muscles, in this case muscle biopsy usually showings non-specific myopathic abnormalities without myofibrillar derangement [8]. Further, *FLNC* ABD domain can also cause a late onset myopathy characterized by predominant limb-girdle weakness, starting in the fifth decade and later spreading to distal and respiratory muscles, resembling the phenotype of mutations in the rod domain of *FLNC*. [9].

Case Report:

Two brothers come to our attention when they were 51 and 46 years old respectively. Motor milestones had been unremarkable. Both patients reported difficulties in walking, running and frequent nocturnal leg cramps since the third decade of life. Muscle weakness, initially confined to the anterior compartment of the leg,

gradually extended to the proximal muscles of the lower limbs and involved the hands after 10 years. The disease course slowly worsened from walking with single support by the beginning of the fifth decade to the loss of ambulation ten years after. The youngest brother reported also frequent extra-systoles, without any respiratory involvement. In the family history, the mother presented difficulties in walking and a maternal cousin, presented a similar clinical course. In both patients CK levels remained within the normal range and, at the beginning of the disease, nerve conduction studies showed reduced compound muscle action potentials (cMAP) amplitudes in lower limb nerves, with no significant abnormalities at the electromyography (EMG), suggesting a possible axonal motor neuropathy. Later on, when performed at the age of 51, EMG showed myopathic features in the older brother. He underwent a quadriceps femoris muscle biopsy which showed variations in muscle fiber size, with several atrophic fibers, some centralized nuclei and a type 1 fiber predominance. Relevant myofibrillar abnormalities, including impairment of myofibrillar alignment, presence of massive cytoplasmic aggregated and non-rimmed vacuoles were evident on Gomori trichrome and NADH stains (Fig.1, A, B, C). Lobulated or ring fibers were also recognized. Immunofluorescence showed myotilin accumulations within the fibers and a positive desmin reaction in a rim surrounding the vacuoles or the deposits (Fig.1, D-E). A musculoskeletal MRI revealed a complete fatty substitution of lower limb muscles (Fig.1 G).

We performed a target gene panel testing for myofibrillar myopathies by Next Generation Sequencing (NGS) approach, designed with Agilent's HaloPlex technology loaded on Illumina MiSeq sequencer. We identified in the two brothers a novel heterozygous mutation in exon 3 of *FLNC* gene (c.664A>G:p.M222V, NM\_001458), within the N-terminal ABD domain, never reported in any public population database. No other variants were identified in any of the 35 genes analyzed with this panel (supplementary material). Moreover, this variant was confirmed by direct sequencing in an affected cousin and her mother, both living in a different Italian area, while it was excluded in two healthy cousins (Fig. 1, F). The mother of our two patients died before any genetic assessment could be performed. Further, the variant was not found in controls (Exome Sequencing Project, 1000 Genomes Project, or Genome Aggregation Consortium).

The mutation falls in a highly conserved region (Fig.1, H) of a well-established functional domain and multiple lines of computational evidence support a deleterious effect on the gene or gene product (SIFT, Polyphen2, Provean, Mutation Taster and Mutation Assessor). A protein modelling study has also been

performed. In particular, the primary sequence of wild type human Filamin C (Uniprot code Q14315) was downloaded. The three-dimensional structure of the protein human Filamin A, with Protein Data Bank archive code 3HOP, was used as template and mutated on residues T215E and M222V (T223 and M229) using the Mutagenesis wizard implemented in PyMOL (<https://pymol.org>) (Fig.1, I). By *in silico* analysis, the variant M222V does not significantly alter protein properties in that region, since a non-polar residue as methionine is substituted by a smaller, again non polar, residue. However, this model has limitations since human Filamin A, in this region, has a 87% homology with Filamin C and the cristal structure of ABD domain of Filamin C is not available.

#### Discussion:

Myofibrillar myopathies represent a heterogeneous group of inherited muscle disorders sharing common pathologic features, with protein aggregates and myofibrillar disorganization and with a frequent involvement of distal muscles. In the past, the diagnostic approach was a gene by gene analysis, often requiring a long time to reach a molecular diagnosis which was possible in a restricted number of cases. Conversely, the use of NGS is increasing the diagnostic yield of molecular diagnoses and contributes to increase the complexity of genotype/phenotype correlations.

In this paper we describe a different phenotype for a mutation falling in the ABD domain of *FLNC*, thus expanding the clinical spectrum of *FLNC*-related myopathies. Most previously identified mutations in ABD domain cause distal myopathies without myofibrillar features and with thenar and intrinsic hand muscle wasting as clinical presentation [1]. Differently, our family showed a predominant early anterior leg involvement and myofibrillar alterations at muscle biopsy resembling dense granulofilamentous protein aggregates described in other myofibrillar myopathies caused by mutation in the dimerization domain of Filamin C. [10]. Moreover, although the age of onset was similar to other distal forms (third decade), the course of the disease was more severe in our family, leading to the loss of ambulation by 60 years old and a complete lower limb muscle atrophy as demonstrated by a muscle MRI (Fig. 1, G). Since literature highlights a pulmonary and/or cardiac involvement for different mutations in *FLNC* gene [6,7], we performed a cardiac and pulmonary follow-up in our patients which showed only atrial extra-systoles in the



youngest brother without evident structural cardiac abnormalities. Therefore, this mutation is not correlated to a cardiac phenotype.

Despite a robust computational evidence supporting a deleterious effect of this novel Filamin-C variant, the protein modelling did not confirm a significant impairment of the protein, however the study is based on the cristal structure of Filamin-A, which shares a partial homology with Filamin C.

Moreover, the segregation of the variant in all affected members together with its lack from controls (Exome Sequencing Project, 1000 Genomes Project, or Genome Aggregation Consortium), all support a pathogenic role of our mutation.

We can speculate that this mutation could cause a mislocation of the filamin protein with decreased nuclear localization and formation of cytoplasmatic protein aggregates through a gain of function as already described in different ABD mutation of FLNC causing distal myopathies [1]. However, the precise link to myofibrillar abnormalities is unknown and functional studies will be necessary to investigate this hypothesis.

Our data support the use of NGS to reach a molecular diagnosis in neuromuscular diseases and confirm that the phenotype of *FLNC*-related myopathies is more heterogeneous than previously known.

## References:

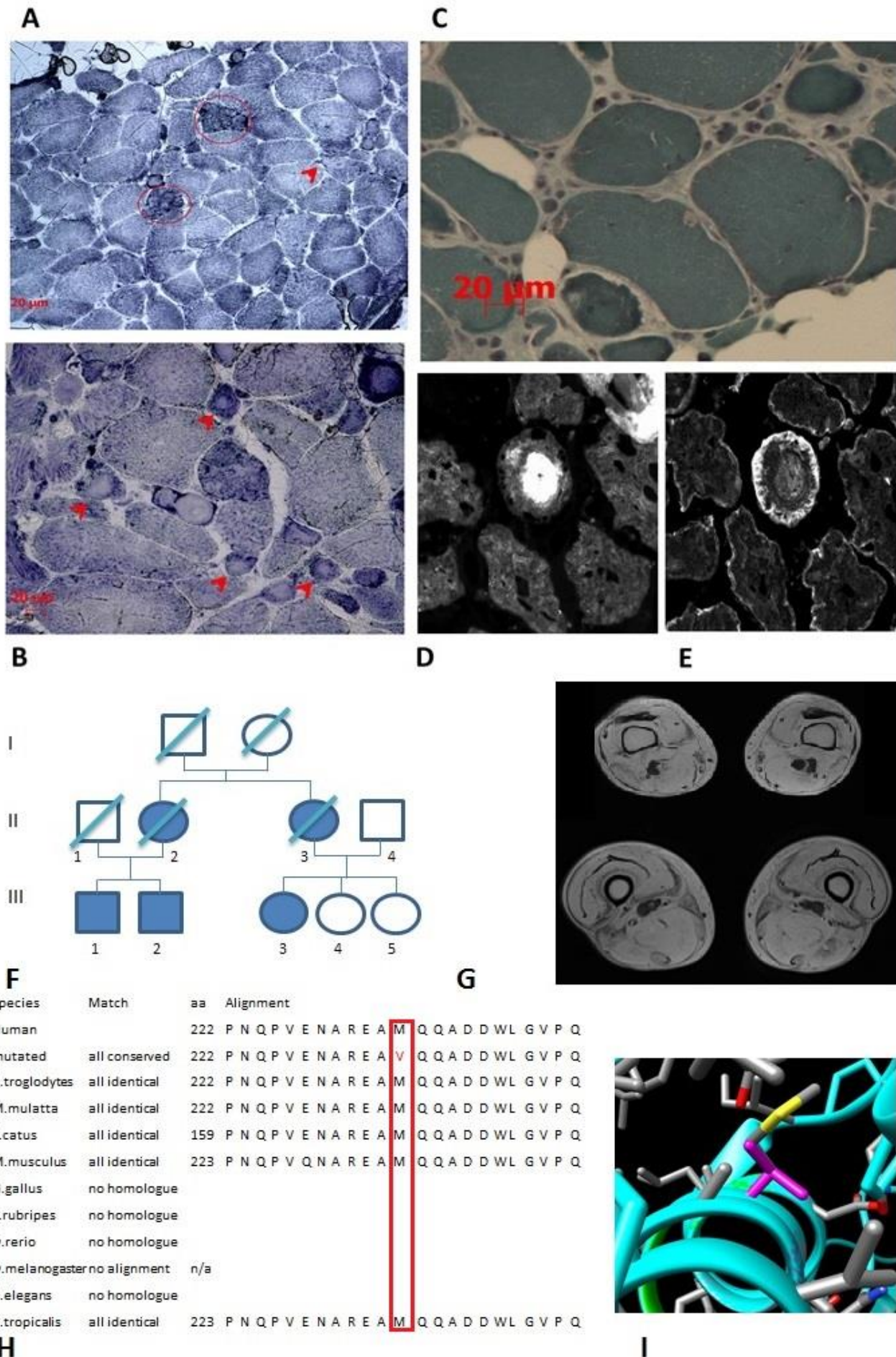
- [1] R.M. Duff, V. Tay, P. Hackman, G. Ravenscroft, C. McLean, P. Kennedy, A. Steinbach, W. Schöffler, P.F.M. Van Der Ven, D.O. Fürst, J. Song, K. Djinović-Carugo, S. Penttilä, O. Raheem, K. Reardon, A. Malandrini, S. Gambelli, M. Villanova, K.J. Nowak, D.R. Williams, J.E. Landers, R.H. Brown, B. Udd, N.G. Laing, Mutations in the N-terminal actin-binding domain of filamin C cause a distal myopathy, *Am. J. Hum. Genet.* (2011). doi:10.1016/j.ajhg.2011.04.021.
- [2] M. Fujita, H. Mitsuhashi, S. Isogai, T. Nakata, A. Kawakami, I. Nonaka, S. Noguchi, Y.K. Hayashi, I. Nishino, A. Kudo, Filamin C plays an essential role in the maintenance of the structural integrity of cardiac and skeletal muscles, revealed by the medaka mutant *zacro*, *Dev. Biol.* (2012). doi:10.1016/j.ydbio.2011.10.008.
- [3] D.T. Loo, S.B. Kanner, a Aruffo, Filamin binds to the cytoplasmic domain of the beta1-integrin. Identification of amino acids responsible for this interaction., *J. Biol. Chem.* (1998). doi:10.1074/jbc.273.36.23304.
- [4] T.G. Thompson, Y.M. Chan, A.A. Hack, M. Brosius, M. Rajala, H.G.W. Lidov, E.M. McNally, S. Watkins, L.M. Kunkel, Filamin 2 (FLN2): A muscle-specific sarcoglycan interacting protein, *J. Cell Biol.* (2000). doi:10.1083/jcb.148.1.115.
- [5] D.O. Fürst, L.G. Goldfarb, R.A. Kley, M. Vorgerd, M. Olivé, P.F.M. Van Der Ven, Filamin C-related myopathies: Pathology and mechanisms, *Acta Neuropathol.* (2013). doi:10.1007/s00401-012-1054-9.
- [6] R.L. Begay, S.L. Graw, G. Sinagra, A. Asimaki, T.J. Rowland, D.B. Slavov, K. Gowan, K.L. Jones, F. Brun, M. Merlo, D. Miani, M. Sweet, K. Devaraj, E.P. Wartchow, M. Gigli, I. Puggia, E.E. Salcedo, D.M. Garrity, A. V. Ambardekar, P. Buttrick, T.B. Reece, M.R. Bristow, J.E. Saffitz, L. Mestroni, M.R.G. Taylor, Filamin C Truncation Mutations Are Associated With Arrhythmogenic Dilated Cardiomyopathy and Changes in the Cell–Cell Adhesion Structures, *JACC Clin. Electrophysiol.* (2018). doi:10.1016/j.jacep.2017.12.003.
- [7] R.A. Kley, Y. Hellenbroich, P.F.M. Van Der Ven, D.O. Fürst, A. Huebner, V. Bruchertseifer, S.A. Peters, C.M. Heyer, J. Kirschner, R. Schröder, D. Fischer, K. Müller, K. Tolksdorf, K. Eger, A. Germing, T. Brodherr, C. Reum, M.C. Walter, H. Lochmüller, U.P. Ketelsen, M. Vorgerd, Clinical and morphological phenotype of the filamin myopathy: A study of 31 German patients, *Brain.* (2007).

doi:10.1093/brain/awm271.

- [8] V. Guergueltcheva, K. Peeters, J. Baets, C. Ceuterick-De Groote, J.J. Martin, A. Suls, E. De Vriendt, V. Mihaylova, T. Chamova, L. Almeida-Souza, E. Ydens, C. Tzekov, G. Hadjidekov, M. Gospodinova, K. Storm, E. Reyniers, S. Bichev, P.F.M. Van Der Ven, D.O. Fürst, V. Mitev, H. Lochmüller, V. Timmerman, I. Tournev, P. De Jonghe, A. Jordanova, Distal myopathy with upper limb predominance caused by filamin C haploinsufficiency, *Neurology*. (2011).  
doi:10.1212/WNL.0b013e31823dc51e.
- [9] F.J.A. van den Bogaart, K.G. Claeys, R.A. Kley, B. Kusters, S. Schrading, E.J. Kamsteeg, N.C. Voermans, Widening the spectrum of filamin-C myopathy: Predominantly proximal myopathy due to the p.A193T mutation in the actin-binding domain of FLNC, *Neuromuscul. Disord.* (2017).  
doi:10.1016/j.nmd.2016.09.017.
- [10] M. Vorgerd, P.F.M. van der Ven, V. Bruchertseifer, T. Löwe, R. a Kley, R. Schröder, H. Lochmüller, M. Himmel, K. Koehler, D.O. Fürst, A. Huebner, A mutation in the dimerization domain of filamin c causes a novel type of autosomal dominant myofibrillar myopathy., *Am. J. Hum. Genet.* (2005).  
doi:10.1086/431959.

Web references:

PyMOL: <https://pymol.org>



## Figure Legends:

Figure 1: A-B: NADH staining (magnification 20 X in A and B, 40x in C) shows lobulated fibres (circled) and areas of devoid activity, sometimes core-like, suggesting a disarrangement of the myofibrillar network. Additionally several large rotund inclusion of granulo-filamentous material are present, resembling ring or targetoid fibres. C: Gomori Trichrome staining (TG, magnification 60x oil) shows rimmed and non-rimmed vacuoles and several scattered atrophic fibres or nuclear clumps. D-E: Immunofluorescence with antibodies against Myotilin 1:500 (ThermoFisher PA5-29059) and Desmin 1:200 (Abcam ab15200) evidenced that the inclusions of the ring fibers are composed by a central cluster rich of myotilin (E) surrounded by a ring of desmin positive material (E). F: Family tree: III, 1 and III, 2 the two brothers. II,3 and III, 3 the affected aunt and affected cousin in which the mutation was confirmed. III, 4 and III, 5 two healthy cousins in which the mutation was excluded. G: musculoskeletal MRI of lower limb muscles showed a complete fatty substitution of lower limb muscles, several decades after the onset. H: Multiple alignments of Filamin C in different orthologous show the high conservation of the residue p. M222 in the second calponin domain. I: The three-dimensional structure of mutant protein implemented in PyMOL (<https://pymol.org> )

Figure 1 is a 2-column fitting image.

Novel mutation in *FLNC* gene (c.A664G:p.M222V), within the N-terminal ABD domain.

A predominant distal leg involvement and severe clinical course in *FLNC* mutation.

Myofibrillar abnormalities and target fibres in distal myopathy due to *FLNC* mutation.

ACCEPTED MANUSCRIPT

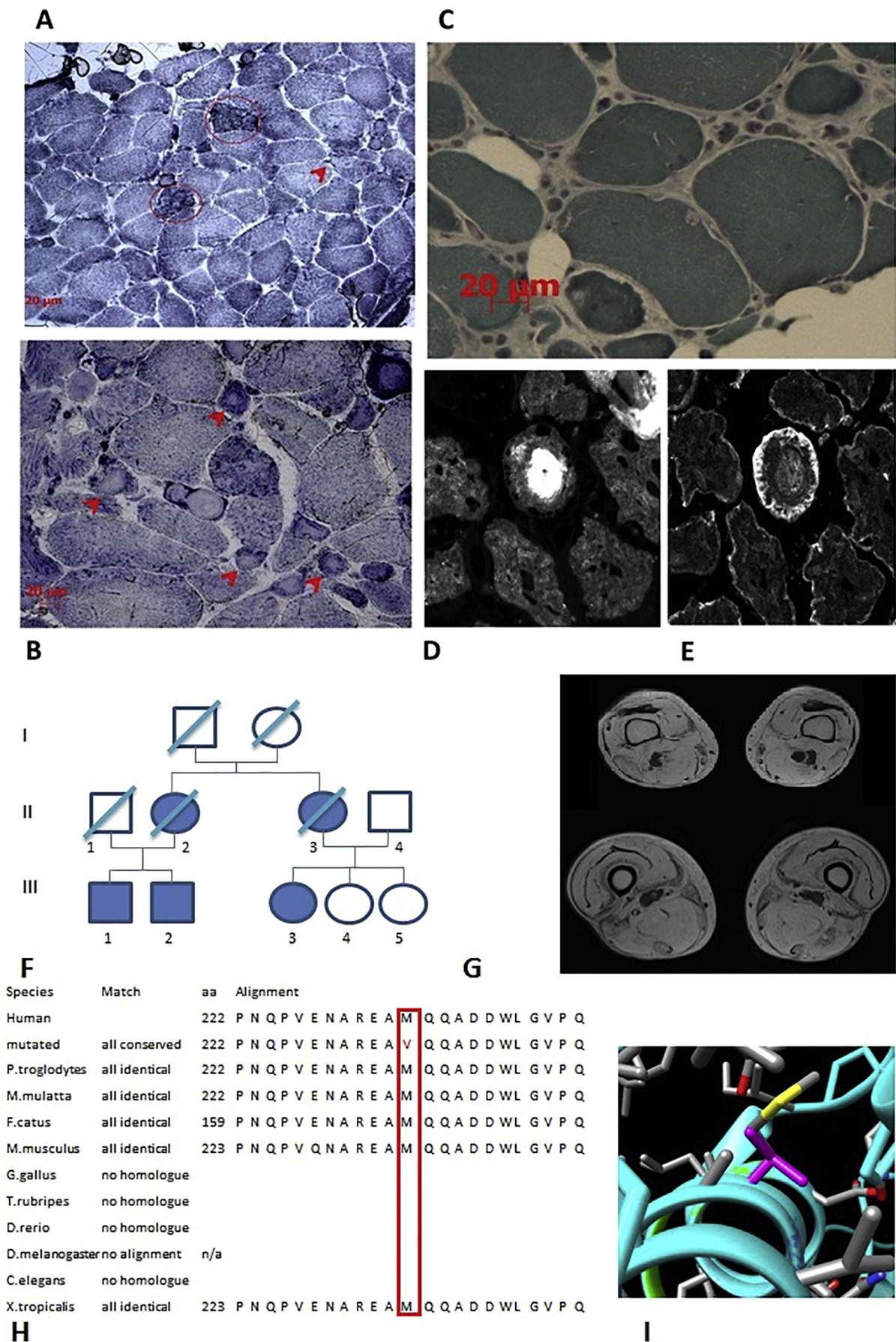


Figure 1