

Double atrial heart sound in a patient with 2:1 atrioventricular block

Alfonso J. Pecoraro, Anton F. Doubell and Philip G. Herbst

Division of Cardiology, Department of Medicine, Faculty of Health Sciences, University of Stellenbosch and Tygerberg Academic Hospital, Tygerberg, South Africa

Address for correspondence:

Alfonso J. Pecoraro
Division of Cardiology
Department of Medicine
University of Stellenbosch and Tygerberg Academic Hospital
PO Box 19063
Tygerberg
7505
South Africa

Email:

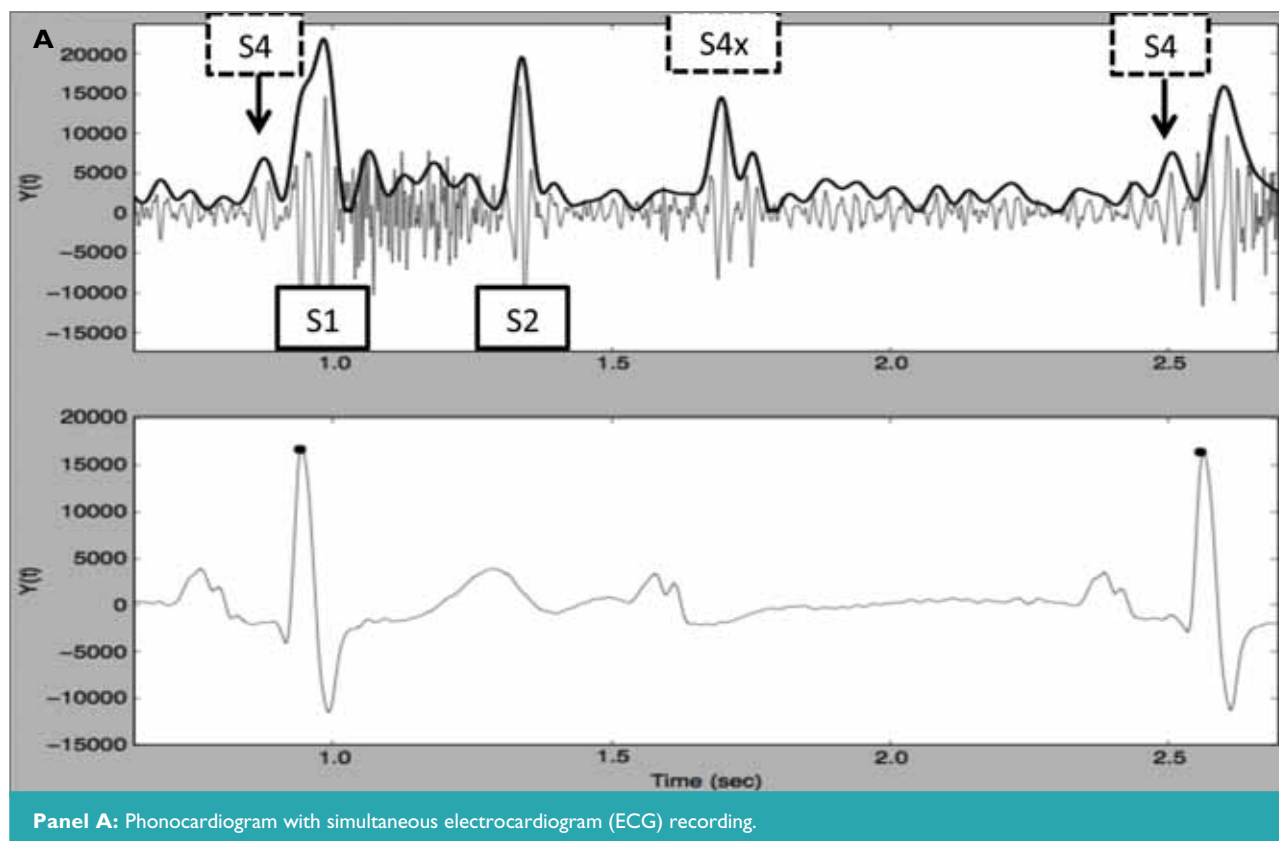
pecoraro@sun.ac.za

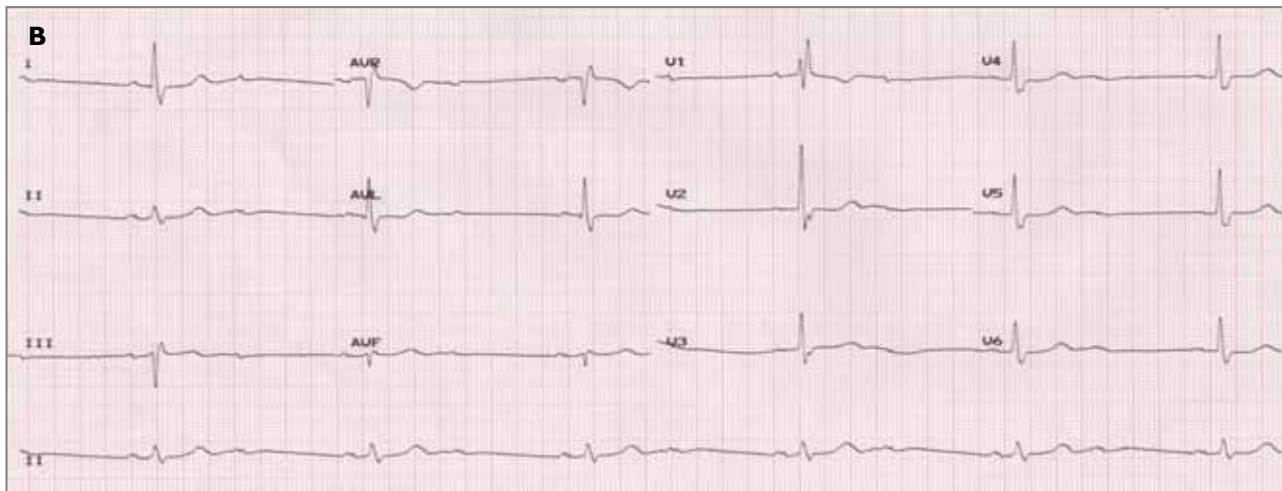
An 83-year-old lady presented to our cardiac unit with presyncope and progressive dyspnoea.

She had a regular bradycardia of 36 beats per minute with a slow-rising central pulse and normal jugular venous pressure without cannon A waves. Auscultation revealed a late-peaking, ejection systolic murmur (ESM) and soft second heart sound in keeping with severe aortic stenosis (AS). Interestingly, 2 added diastolic heart sounds were noted. A phonocardiogram with a simultaneous electrocardiogram (ECG) recording was undertaken using a mobile device. This revealed an early diastolic heart sound following a non-conducted P wave (S4x) in addition to a pre-systolic atrial heart sound (S4) and ESM (Panel A).

An S4 is associated with atrial contraction in the presence of a stiff, non-compliant ventricle (e.g. in severe AS). Electrocardiography confirmed the presence of 2:1 atrioventricular block explaining the additional S4 (Panel B).

New technologies are resurrecting classic teaching and diagnostic aids such as phonocardiography, that can be used to help solve clinical puzzles at the bedside.





Panel B: 12 lead ECG recording.



CLICK TO PLAY HEART SOUND

