

# Comparison of coronary angiography and intracoronary imaging with fractional flow reserve for coronary artery disease evaluation: An anatomical–functional mismatch

 Julien Adjedj,  Nikolay Stoyanov,  Olivier Muller

Department of Cardiology, Lausanne University Hospital (CHUV); Lausanne-Switzerland

## ABSTRACT

Myocardial ischemia is a leading cause of death worldwide, and it corresponds to the imbalance between blood supply and myocardial demand. Epicardial coronary artery disease (CAD) is detected on the basis of coronary angiogram, whereas invasive detection of myocardial ischemia induced by coronary stenosis is commonly based on fractional flow reserve (FFR). The use of FFR for revascularization decision-making demonstrated clinical benefit and cost-effectiveness compared with that of angiographic indices. Discrepancies between anatomical metrics and physiological assessment of CAD are frequent, which lead to change in revascularization decision from angiography compared to functional evaluation of CAD. Despite several clinical studies and guidelines recommending with high level of evidence demonstrating that FFR should be adopted in stable CAD, revascularization decision-making is still based on coronary angiogram in current practice. Because of the unique coronary anatomy, coronary stenosis characteristics, risk factors profile, and microcirculation quality, the unique evaluation based on epicardial coronary stenosis threshold failed to be a landmark of ischemia compared with FFR. Furthermore, coronary angiogram can detect only epicardial vessels, which represent only 10% of the entire coronary vasculature; therefore, microcirculation is not seen and is poorly assessed in clinical practice. Thus, the role of microcirculation is of importance in myocardial ischemia and might impact these discrepancies between angiography and FFR evaluation of CAD. In this review, we aimed to describe the poor correlation between anatomical evaluation compared with physiological evaluation to detect myocardial ischemia induced by coronary stenosis as well as the clinical implications of this visual–functional mismatch. (*Anatol J Cardiol* 2018; 20: 182-9)

**Keywords:** coronary artery disease, coronary angiography, fractional flow reserve, cardiovascular risk factors

## Introduction

Diagnostic coronary angiography was first reported by Sones and Shirey (1) in 1959; it is the most used procedure to assess the severity of coronary artery disease (CAD). In 1974, Gould et al. (2) studied the association between coronary stenosis and functional reduction of maximal coronary flow was studied in animals and observed a relation between coronary stenosis percentage and coronary flow. The maximal flow progressively decreases from 50% to 80% stenosis with a resting flow decrease above 80% stenosis (2). Since general assumption has been made which define a significant coronary stenosis as  $\geq 70\%$  luminal diameter narrowing or  $\geq 50\%$  of a left main, by visual assessment of an epicardial stenosis measured in the “worst view” angiographic projection (3). As such, coronary angiography formed the basis for the revascularization clinical

decision-making of this prevalent disease. It is noteworthy that White et al. (4) performed a study similar to Gould et al. (2) 10 years later in patients undergoing coronary artery bypass graft and did not observe a similar relation between coronary stenosis and flow. Several reasons were given to explain the difference in results between experimentation in animals by Gould et al. (2) and observation in patients by White et al. (4). The animal experimentation was performed with a control setting in healthy animals and surgically controlled diameter stenosis according to the experimental protocol, whereas the patients had risk factors, comorbidities, microvascular impairment, and tissue aging. Coronary stenosis could be diffuse along the coronary artery with vessel remodeling and could interest different territories supplied by variable amount of myocardial mass with heterogenic collaterals network. All these parameters contribute to a unique flow distribution, which affects the balance between myocardial supply and demand of oxygen in stable patients and therefore im-

**Address for correspondence:** Julien Adjedj, PhD, Department of Cardiology, Lausanne University Hospital (CHUV);

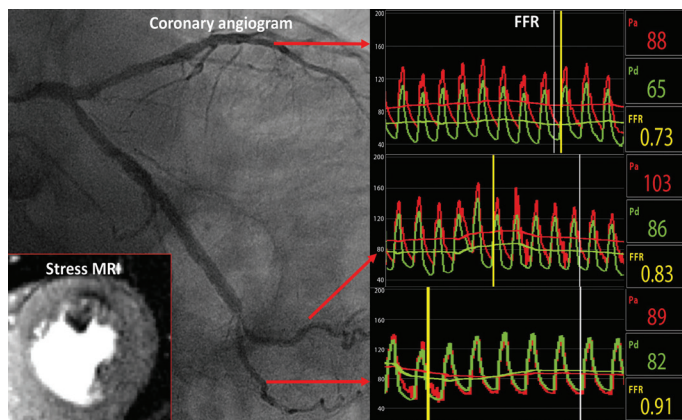
Address Rue du Bugnon 46, 1004, Lausanne-Switzerland

Phone: +4179/5560950 E-mail: julien.adjedj@chuv.ch - julienadjedj@hotmail.com

**Accepted Date:** 01.06.2018

©Copyright 2018 by Turkish Society of Cardiology - Available online at [www.anatoljcardiol.com](http://www.anatoljcardiol.com)  
DOI:10.14744/AnatolJCardiol.2018.42949





**Figure 1.** Example of a 67-year-old patient with positive stress magnetic resonance imaging (MRI) in an anterolateral wall perfusion defect (lower left panel), showing angiographically significant stenosis of circumflex and marginal coronary arteries and nonsignificant left artery descending (LAD) coronary artery (upper left panel). FFR was significant for ischemia in LAD and nonsignificant in the circumflex and marginal coronary arteries in agreement to stress MRI imaging (right panel)

pact differently the coronary flow with similar apparent coronary stenosis assess by angiography (5). Fractional flow reserve (FFR) became the gold standard invasive test to detect myocardial ischemia induced by a coronary stenosis. FFR is recommended (IA) in stable coronary artery stenosis of more than 50% when evidence of ischemia is not available (6). Despite the evidence provided by several randomized trials and multiple observational studies (7-10), the adoption of FFR has been slow in many areas. The mismatch between anatomical and functional evaluation of coronary stenosis has been extensively described and showed frequent redistribution in revascularization indication (Fig. 1) (11). In this general paradox, the percentage of diameter stenosis (DS) does not reliably relate to FFR (12, 13); therefore, revascularization procedures to improve coronary blood flow based on coronary angiogram do not reduce coronary events compared with optimal medical therapy in randomized trials (14). In contrast to these trials, revascularization guided by FFR had significantly fewer follow-up coronary events than percutaneous coronary

intervention (PCI) based on angiographic DS (15, 16). The aim of the current review is to describe the possible reasons and clinical implications of mismatch between anatomical indices and FFR values.

### Fractional flow reserve

FFR has been defined as the ratio of maximal myocardial blood flow in the presence of stenosis to the normal maximal myocardial blood flow (i.e., in the absence of stenosis) (17). It is derived from proximal and distal coronary pressures measured during hyperemic conditions. FFR quantifies the extent to which an epicardial obstruction limits maximal blood flow and predicts the potential benefit of medical therapy and revascularization.

### Calculations

FFR expresses the ratio of maximal myocardial flow in the presence of stenosis ( $Q_s$ ) to the normal hypothetical maximal myocardial flow of the same territory without stenosis ( $Q_n$ ):  $FFR = Q_s / Q_n$ . Based on Ohm's law, the flow can be expressed as the ratio of the driving pressure to the resistance ( $R$ ) of the system, which is the coronary circulation in this case. The driving pressure is the aortic ( $P_a$  for  $Q_n$  and  $P_d$  for  $Q_s$ ) and venous pressure gradient ( $P_v$ ). Accordingly, the formula can be substituted as follows:  $FFR = [(P_d - P_a) / R] / [(P_d - P_a) / R]$ . The measurements are obtained under maximal relaxation of both the macrovascular and microvascular compartments; therefore, the resistance of the system is minimal and cancels in the simplified equation:  $FFR = (P_d - P_v) / (P_a - P_v)$ . In the absence of congestive heart failure, the venous pressure is negligible compared with the aortic or coronary pressure (18). A simpler formula was derived and used in the trials and clinical practice:  $FFR = P_d / P_a$  at maximal hyperemia. Practically, FFR is calculated as the ratio of two mean pressure measurements (17), the distal coronary pressure  $P_d$  divided by the proximal coronary pressure or aortic pressure  $P_a$  under maximal hyperemic condition. The accuracy and physiologic meaning of FFR depend on the induction of maximal hyperemia. Only maximal hyperemia abolishes all mechanisms responsible for the control of resting blood flow to achieve a  $P_d / P_a$  ratio

**Table 1. Studies comparing indices obtained by angiography or intracoronary imaging compared with FFR presented in Figure 4**

Study	Name	Year	Journal	Sensitivity	Specificity	Number of vessels
VE	Danad et al.	2016	Eur Heart J 2017 Apr 1; 38 (13): 991-998	71	66	954
QCA	Toth et al.	2014	Eur Heart J 35 (40): 2831-2838	61	67	4086
QCA <sub>LM</sub>	Toth et al.	2014	Eur Heart J, 35 (40), 2831-2838	35	76	152
IVUS	Nascimento et al.	2014	Catheter Cardiovasc Interv 84: 377-385	66	80	1953
IVUS <sub>LM</sub>	Nascimento et al.	2014	Catheter Cardiovasc Interv 84: 377-385	90	90	110
OCT	Pawlowski et al.	2013	Int J Cardiovasc Imaging 29 (8): 1685-1691	75	90	71
3D QCA	Tu et al.	2014	JACC Cardiovasc Interv 7 (7): 768-777	83	56	77
QFR	Xu et al.	2017	J Am Coll Cardiol 70 (25): 3077-3087	92	93	332

that equals the corresponding flow ratio governed by a linear relationship between perfusion pressure and hyperemic flow (19, 20).

### Practical aspects

During the coronary angiography procedure, intracoronary nitrates are administered prior to the FFR measurements. The guiding catheter measures Pa. Pd is measured by a dedicated intracoronary pressure guidewire placed downstream the coronary stenosis to be investigated. Hyperemic steady state can be induced by drugs such as intravenous (IV) adenosine (at 140 mcg/kg/min), intracoronary (IC) adenosine (100 mcg for the right coronary and 200 mcg for the left coronary) (21). The FFR value is defined as the Pd/Pa value obtained during maximal steady state hyperemia (Fig. 1). FFR has a well-defined cutoff value for the probability of presence or absence of inducible ischemia at 0.80 or below. It is extremely unlikely to observe definitive myocardial ischemia with FFR > 0.80. Therefore, an FFR value of 0.80 is a widely accepted and largely confirmed threshold to guide clinical decision-making (15, 16, 22, 23).

### Clinical outcome data

Several randomized clinical trials and meta-analyses have confirmed the clinical value of FFR-based decision-making. When FFR is >0.80, the clinical outcome of the patient is not improved by revascularization compared with the currently available best of medical care. This has been shown for all kinds of lesions, including left main stenosis, and different patient subsets (7-10, 15, 16, 24-30). In patients with multivessel disease, the application of FFR has led to the concept of functionally complete revascularization (26) as opposed to the prevailing practice of anatomically complete revascularization (31). In contrast, when FFR is ≤0.80, FAME 2 has shown in patients with CAD undergoing elective PCI that outcomes are improved by drug-eluting stent implantation compared with medical therapy only in terms of urgent revascularization and symptoms and seems to improve death and MI at 5 years (16, 22, 32).

Those robust clinical outcome data established that FFR should be used for bidirectional reclassification of angiographically visible stenoses. When applied ad hoc during diagnostic angiography, the use of FFR transforms the invasive procedure in the catheterization laboratory into a “one-stop shop” that allows both morphological and functional evaluation of CAD.

### Visual estimation evaluation

Visual estimation (VE) remains the easiest way to evaluate CAD. It requires prior intracoronary nitrate administration, optimal contrast injection into coronary arteries, and several projections. The eyeballing of coronary stenosis corresponds to DS seen in the “worst view.” This evaluation had large variability, which could not be a reliable and standard evaluation of CAD.

### Visual estimation and fractional flow reserve

VE has been compared with FFR in a meta-analysis, wherein the sensitivity was 71% and the specificity was 66% (33). Simi-

larly, reclassification rate was studied in a French multicentric registry comparing a priori clinical decision based on VE compared with that on FFR in 1028 patients (11). The reclassification rate was 43%. At one-year follow-up, the FFR strategy demonstrated safety in terms of symptoms and clinical outcome. Interestingly, FFR induces high reclassification rate with small variation in overall therapeutics rates: The medical therapy and CABG rates increased of 3% in each group while reduction of PCI rate was only 6%. Moreover, these results were consistent with other studies comparing VE and FFR such as Ripcord study and CVIT DEFER registry (34, 35). Nakamura et al. (35) showed that the independent predictors for mismatch between VE and FFR <0.8 were previous PCI, one-vessel disease, non-left artery descending (LAD) location, nondiffuse lesion, nonstrial lesion, and nontandem lesion. Conversely, mismatch between VE and FFR >0.80 was independently associated with multivessel disease, LAD location, and diffuse lesion (35). FFR-based revascularization strategy is safe at one year in daily clinical practice (36).

### Quantitative coronary angiography

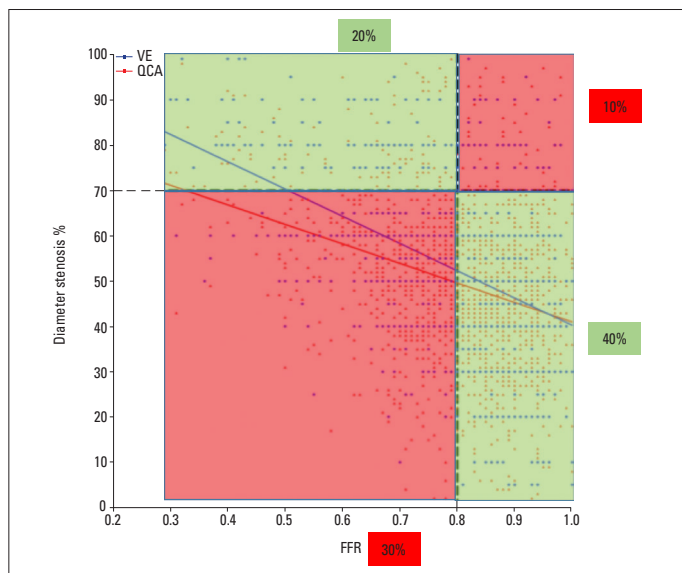
Quantitative coronary angiography (QCA) has been proposed to reduce variability and increase accuracy of CAD evaluation. Similar to VE, it requires nitrate administration and optimal coronary opacification with contrast medium. The severity of the obstructive lesions is derived from the automatically detected contours of the stenosis compared with the reference “healthy part” of the vessel during diastole phase to obtain DS. A metric landmark such as catheter or pixel size is needed to provide absolute values of the minimum lumen diameter, reference diameter, and lesion length (37).

### Quantitative coronary angiography and fractional flow reserve

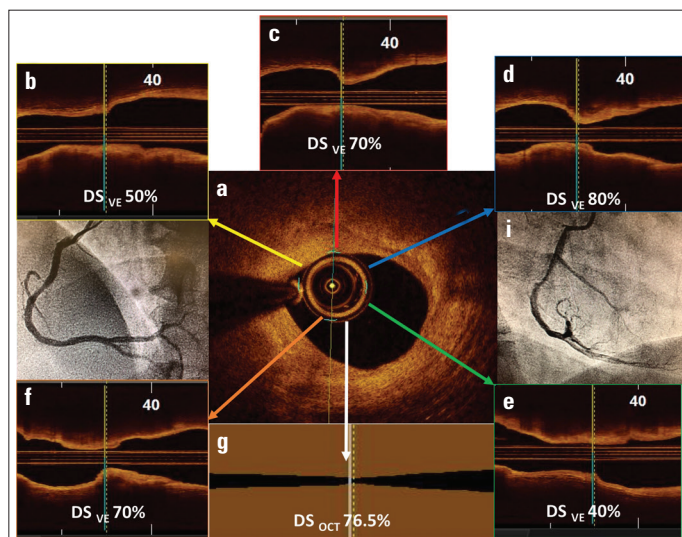
Toth et al. (12) compared 4000 coronary stenoses to FFR in a single center and observed a high rate of discordance between QCA and FFR. Approximately one-third of the population shows discordance between angiogram and FFR with a sensitivity of 61% and a specificity of 67%. Left main (LM) stenoses are especially underestimated by the 50% DS angiographic cutoff compared with FFR with a sensitivity of 35% and a specificity of 76%.

### Discrepancies between visual estimation and QCA

Several studies have compared VE and QCA of CAD to summarize that QCA underestimates mild lesions and VE overestimates tight lesions (13). VE had higher variability than QCA. An international survey on interventional strategy aimed to present coronary angiogram without clinical context and showed extreme variability of VE evaluation between 459 interventional cardiologists (38). However, a sub-study of PROMISE trials comparing VE and QCA evaluation to the clinical outcome in 929 patients observed that one-year unadjusted Kaplan-Meier event rates were highest (5.1%) when QCA and VE agreed for significant CAD, lowest (0.9%) when the 2 agreed for nonsignificant CAD,



**Figure 2.** VE and QCA values compared with FFR. Agreement between green true positive in the left upper panel and true negative in the right lower panel. Discordance between red false-positive in the right upper panel and false-negative in the left lower panel (13)



**Figure 3.** Circumferential OCT imaging of coronary stenosis (a) with a diameter stenosis in an automated lumen profile (g). b, c, d, e, and f showed 2D longitudinal reconstruction with VE of DS according to an independent operator. (h and j) Coronary angiogram showing a moderate mid-right coronary artery stenosis

and intermediate (3.1%) for patients who had significant CAD per VE but not per QCA. This study suggests that cardiologists integrated clinical information into routine VE (39).

### Visual estimation, quantitative coronary angiography, and fractional flow reserve

Similarly to the sub-study of PROMISE trial, a study comparing VE and QCA to FFR in 1104 patients and 1382 stenoses showed a better diagnosis accuracy between VE and FFR than between QCA and FFR (13). Indeed, interrogating the patient, consulting

the medical report, and performing other tests at rest might affect the interventional cardiologists about clinical ischemia relevance and therefore the VE assessment of CAD might be better correlated to invasive ischemic test. Of note, this study showed that compared with FFR, the false-negative rate of VE and QCA were three times higher in mild DS (<70%) than in tight DS (70%). This indicates that the general assumption that adopting FFR will dramatically reduce the number of revascularizations in centers is unsafe since mainly false-negative VE and QCA (DS <70%) have FFR <0.80. These lesions are generally not interrogated with FFR since they appear angiographically non significant. Therefore, based on these studies' results, systematic FFR interrogation of a large range of diameter stenoses from 30% to 90% may lead to a high reclassification rate with a low reduction of revascularization and safety in terms of clinical outcome and symptoms (Fig. 2) (11, 13).

### Intracoronary imaging and three-dimensional quantitative coronary angiography

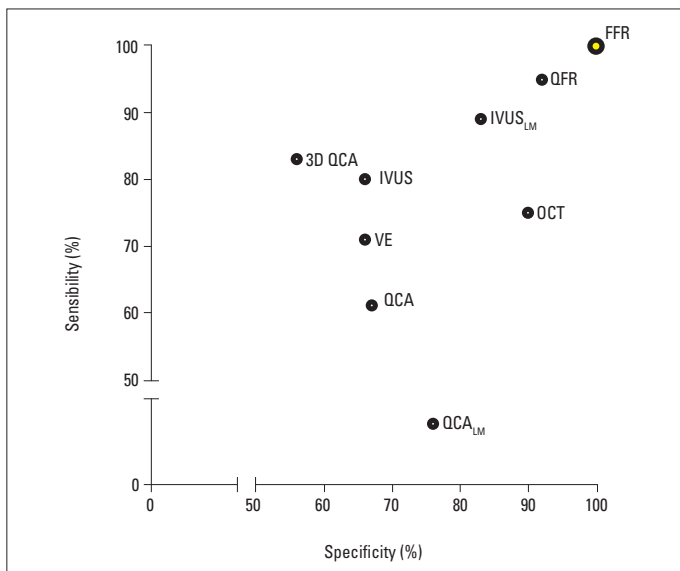
The general limitation of VE and QCA is to find the “worse view” to assess DS for the following reasons. First, coronary arteries can overlap and have vessel foreshortening between different views. Second, coronary stenosis is predominantly eccentric; therefore, the diameter stenosis derived from the “worst view” might overestimate the severity of DS (40). Third, lesion length and vessel remodeling might affect focal lesion evaluation. Thus, the principle to evaluate DS in three dimensions was proposed to assess coronary stenosis based on intracoronary imaging such as intravascular ultrasound (IVUS) and optical coherence tomography (OCT) or three dimensional (3D) QCA to obtain a stenosis area.

### Intracoronary imaging

Because of their higher spatial resolution, imaging of the vascular wall layers and 3D reconstruction IVUS and OCT are superior to angiography in determining lesion severity. DS assessed by VE or QCA can be obtained in a cross-sectional area to determine the minimum lumen area (MLA) associated with the lesion length to obtain 3D evaluation of the studied coronary segment (Fig. 3). To date, no prospective randomized studies have demonstrated improvement in clinical outcomes using intravascular imaging. While these techniques provide important informations such as coronary plaque structure, volume, and stability. Intracoronary imaging devices have significant cost and a lack of clinical evidence to improve patient outcome such as mortality, myocardial infarction, stent thrombosis, or restenosis rates in current practice.

### Intravascular ultrasound and fractional flow reserve

IVUS is an intravascular imaging modality that provides high-resolution cross-sectional measurements of the lumen and vessel areas (41). IVUS quantification of a stenosis has fewer anatomic limitations than angiography. IVUS accurately measures MLA, which is more accurate than luminal DS assessed by QCA.



**Figure 4.** Sensitivity and specificity (%) of studies comparing the diagnostic efficacy of techniques with FFR as gold standard (Table 1)

The main limitation is to ensure coaxial position. Although IVUS is an excellent method to determine plaque volume, its precise role in clinical decision-making has not been defined. Kang et al. (42) found a good correlation between IVUS and FFR for MLA <4.8 mm<sup>2</sup> with a sensitivity of 89% and a specificity of 83% in intermediate LM lesions. A meta-analysis compared MLA assessed with IVUS and FFR values showed for a weighted overall mean MLA cutoff of 2.61 mm<sup>2</sup> in non-LM trials and 5.35 mm<sup>2</sup> in LM trials with a limited accuracy with 20% reclassification. The sensitivity was 79% and the specificity was 65% in non-LM trials, whereas the sensitivity and specificity were 90% in LM trials (43).

#### Optical coherence tomography and fractional flow reserve

OCT is an intravascular imaging based on near-infrared light with better resolution than IVUS, but less power of penetration. OCT imaging needs optimal and prolonged coronary opacification with contrast medium to obtain good imaging quality. Therefore, the main limitations of this technique are the need for extra contrast medium to perform OCT imaging and ostial segment of coronary arteries, particularly LM. OCT MLA and FFR correlations were evaluated in 48 patients and 71 intermediate coronary stenoses. An OCT MLA of 2.05 mm<sup>2</sup> cutoff had a sensitivity of 75% and a specificity of 90% (44).

#### Intravascular ultrasound+optical coherence tomography and fractional flow reserve

A study aimed to evaluate the diagnosis accuracy of IVUS and OCT to predict FFR <0.75 in 186 patients and 203 non-LM stenoses. This study showed a moderate diagnostic performance of both IVUS with a sensitivity of 72% and a specificity of 47% associated with an optimal cutoff value of 2.57 mm<sup>2</sup> and OCT with a sensitivity of 69% and a specificity of 69% associated with an optimal cutoff value of 1.39 mm<sup>2</sup> (45). Comparison of the results

showed better accuracy of OCT than of IVUS to predict significant FFR values. Furthermore, using OCT, a multivariate analysis showed that older age, non-left anterior descending artery, and smaller angiographic reference diameter were independent predictors of false-positive results, whereas younger age and low left ventricular ejection fraction were independent predictors of false-negative results. These results highlight the importance of the impact of myocardial mass and microvascular compartment with CAD to induce myocardial ischemia.

Since OCT, like IVUS, evaluates anatomic dimensions rather than functional significance, its use in assessing coronary stenosis hemodynamic impact will probably be limited. As a result, these imaging modalities remain investigational in terms of improving clinical outcomes associated with the performance of PCI.

#### 3D quantitative coronary angiography and fractional flow reserve

Based on a couple of coronary angiograms with different angles or rotational coronary angiogram, it is possible to obtain 3D reconstruction of vessel lumen called 3D QCA with dedicated software. 3D reconstruction could generate vessel volume and dimensions which are well compared with intracoronary imaging. Tu et al. (46) showed a good correlation between 3D QCA (QAngio XA 3D software, Medis Specials BV, Leiden, The Netherlands) and IVUS ( $r=0.799$ ,  $p<0.001$ ) or OCT ( $r=0.897$ ,  $r<0.001$ ) for the assessment of lumen area, with a trend toward larger lumen area by IVUS ( $6.29\pm 2.77$  mm<sup>2</sup> vs.  $5.08\pm 2.34$  mm<sup>2</sup>) or OCT ( $7.01\pm 3.28$  mm<sup>2</sup> vs.  $5.93\pm 2.66$  mm<sup>2</sup>). 3D QCA diagnosis performance was compared with FFR in 77 vessels and 68 patients with a cutoff value <2.11 mm<sup>2</sup>; the sensitivity was 83% and the specificity was 56% to predict FFR <0.80.

#### Quantitative flow reserve and fractional flow reserve

Quantitative flow reserve (QFR) reconstructs anatomical models using 3D QCA and subsequently applies fluid dynamic equations using the patient-specific hyperemic flow rate derived by 3D QCA. TIMI frame count as a boundary condition was compared with FFR in 308 patients, and 332 vessels showed a good overall sensitivity of 95% and specificity of 92%. Of note, like FFR, QFR cutoff value was <0.80. In this study, for the subgroup with FFR between 0.75 and 0.85, a numerical difference between QFR and FFR could lead to clinical discordance, QFR still had good diagnostic accuracy [86.0% (95% CI: 77.9%-91.9%)] (47). We reported the sensitivity and specificity of previous techniques described compared to FFR as the gold standard in the Table 1 and Figure 4.

#### Limitations and impact of risk factors

Little doubt exists concerning the benefit to widely adopt the use of FFR for revascularization clinical decision-making. FFR demonstrates a continuous link with outcomes when treated

with medical therapy. Therefore, lesions with lower FFR values receive larger absolute benefits from revascularization (48). Thus, FFR links coronary physiology severity to clinical outcome. In subgroups of patients who have microvascular disease, the coronary flow might be reduced due to microvascular impairment with a higher FFR value compared with a subgroup with preserved coronary microcirculation. Thus, clinical outcome should be better predicted by evaluations of both macrocirculation and microcirculation, which is rarely performed in clinical practice. In a study evaluating the diagnosis accuracy of VE and QCA compared with FFR according to the type and number of risk factors, the predictive accuracy of VE and QCA was moderate in patients without risk factors and weakened as risk factors accumulated. Particularly in patients with diabetes, FFR was significantly higher than that in patients without diabetes with comparable stenoses. In this subgroup of patients with diabetes, VE and QCA diagnostic accuracy to predict FFR result was not different compared with a toss coin test (13). Therefore, the more the patients have high cardiovascular risk, the lesser the angiographic indices are reliable, and consequently, the more FFR is needed. Virtual FFR derived from computed tomography or angiography is a promising tool to predict FFR based on the assumption of preserved flow reserve and myocardial mass. In patients with microvascular impairment such as diabetes, a high index of microvascular resistance or post myocardial infarction diagnosis accuracy might be lower; therefore, test results should be taken with cautions (49, 50).

## Conclusion

Coronary angiogram evaluation of coronary stenosis is limited to assess the ischemic impact on the myocardium. Sophisticated technologies based on anatomical description of stenosis than on FFR failed to have reliable measurements. The remaining reason is that many other factors beyond coronary stenosis diameter interplay in this anatomical–functional mismatch, which are not seen on the coronary angiogram and intracoronary imaging. Therefore, the use of FFR should be as extensive as possible to assess the functional significance of a coronary stenosis when a noninvasive test is not available or to confirm the noninvasive test results, if necessary. Future promising techniques virtually evaluate FFR from coronary angiogram, which evolve the classical 2D black and white angiogram to a 3D vessel with a color code corresponding to the FFR value. These techniques could help to generalize the functional evaluation of coronary stenosis in clinical practice.

**Acknowledgements:** The authors would like to thank Dr. Eric Eeckhout and Dr. Christan Roguelov for their contributions to the manuscript.

**Conflict of interest:** None declared.

**Peer-review:** Externally peer-reviewed.

**Authorship contributions:** Concept – J.A., N.S., O.M.; Design – J.A., N.S., O.M.; Supervision – J.A., N.S., O.M.; Fundings – J.A., N.S., O.M.; Materials – J.A., N.S., O.M.; Data collection &/or processing – J.A., N.S., O.M.; Analysis &/or interpretation – J.A., N.S., O.M.; Literature search – J.A., N.S., O.M.; Writing – J.A., N.S., O.M.; Critical review – J.A., N.S., O.M.; Other – J.A., N.S., O.M.

## References

1. Sones FM Jr, Shirey EK. Cine coronary arteriography. *Mod Concepts Cardiovasc Dis* 1962; 31: 735-8.
2. Gould KL, Lipscomb K, Hamilton GW. Physiologic basis for assessing critical coronary stenosis. Instantaneous flow response and regional distribution during coronary hyperemia as measures of coronary flow reserve. *Am J Cardiol* 1974; 33: 87-94.
3. Patel MR, Calhoon JH, Dehmer GJ, Grantham JA, Maddox TM, Maron DJ, et al. ACC/AATS/AHA/ASE/ASNC/SCAI/SCCT/STS 2017 Appropriate Use Criteria for Coronary Revascularization in Patients With Stable Ischemic Heart Disease: A Report of the American College of Cardiology Appropriate Use Criteria Task Force, American Association for Thoracic Surgery, American Heart Association, American Society of Echocardiography, American Society of Nuclear Cardiology, Society for Cardiovascular Angiography and Interventions, Society of Cardiovascular Computed Tomography, and Society of Thoracic Surgeons. *J Am Coll Cardiol* 2017; 69: 2212-41.
4. White CW, Wright CB, Doty DB, Hiratza LF, Eastham CL, Harrison DG, et al. Does visual interpretation of the coronary arteriogram predict the physiologic importance of a coronary stenosis? *New Engl J Med* 1984; 310: 819-24.
5. Gould KL, Johnson NP, Bateman TM, Beanlands RS, Bengel FM, Bober R, et al. Anatomic versus physiologic assessment of coronary artery disease. Role of coronary flow reserve, fractional flow reserve, and positron emission tomography imaging in revascularization decision-making. *J Am Coll Cardiol* 2013; 62: 1639-53.
6. Authors/Task Force members, Windecker S, Kolh P, Alfonso F, Collet JP, Cremer J, et al. 2014 ESC/EACTS Guidelines on myocardial revascularization: The Task Force on Myocardial Revascularization of the European Society of Cardiology (ESC) and the European Association for Cardio-Thoracic Surgery (EACTS) Developed with the special contribution of the European Association of Percutaneous Cardiovascular Interventions (EAPCI). *Eur Heart J* 2014; 35: 2541-619.
7. Muller O, Mangiacapra F, Ntalianis A, Verhamme KM, Trana C, Hamilos M, et al. Long-term follow-up after fractional flow reserve-guided treatment strategy in patients with an isolated proximal left anterior descending coronary artery stenosis. *JACC Cardiovasc Interv* 2011; 4: 1175-82.
8. Sels JW, Tonino PA, Siebert U, Fearon WF, Van't Veer M, De Bruyne B, et al. Fractional flow reserve in unstable angina and non-ST-segment elevation myocardial infarction experience from the FAME (Fractional flow reserve versus Angiography for Multivessel Evaluation) study. *JACC Cardiovasc Interv* 2011; 4: 1183-9.
9. Hamilos M, Muller O, Cuisset T, Ntalianis A, Chlouverakis G, Sarno G, et al. Long-term clinical outcome after fractional flow reserve-guided treatment in patients with angiographically equivocal left main coronary artery stenosis. *Circulation* 2009; 120: 1505-12.

10. Ntalianis A, Sels JW, Davidavicius G, Tanaka N, Muller O, Trana C, et al. Fractional flow reserve for the assessment of nonculprit coronary artery stenoses in patients with acute myocardial infarction. *JACC Cardiovasc Interv* 2010; 3: 1274-81.
11. Van Belle E, Rioufol G, Pouillot C, Cuisset T, Bougrini K, Teiger E, et al. Outcome impact of coronary revascularization strategy reclassification with fractional flow reserve at time of diagnostic angiography: insights from a large French multicenter fractional flow reserve registry. *Circulation* 2014; 129: 173-85.
12. Toth G, Hamilos M, Pyxaras S, Mangiacapra F, Nelis O, De Vroey F, et al. Evolving concepts of angiogram: fractional flow reserve discordances in 4000 coronary stenoses. *Eur Heart J* 2014; 35: 2831-8.
13. Adjedj J, Xaplanteris P, Toth G, Ferrara A, Pellicano M, Ciccarella G, et al. Visual and Quantitative Assessment of Coronary Stenoses at Angiography Versus Fractional Flow Reserve: The Impact of Risk Factors. *Circ Cardiovasc Imaging* 2017; 10: pii: e006243.
14. Boden WE, O'Rourke RA, Teo KK, Hartigan PM, Maron DJ, Kostuk WJ, et al.; COURAGE Trial Research Group. Optimal medical therapy with or without PCI for stable coronary disease. *New Engl J Med* 2007; 356: 1503-16.
15. Tonino PA, De Bruyne B, Pijls NH, Siebert U, Ikeno F, van't Veer M, et al.; FAME Study Investigators. Fractional flow reserve versus angiography for guiding percutaneous coronary intervention. *New Engl J Med* 2009; 360: 213-24.
16. De Bruyne B, Fearon WF, Pijls NH, Barbato E, Tonino P, Piroth Z, et al. Fractional flow reserve-guided PCI for stable coronary artery disease. *New Engl J Med* 2014; 371: 1208-17.
17. Pijls NH, van Son JA, Kirkeeide RL, De Bruyne B, Gould KL. Experimental basis of determining maximum coronary, myocardial, and collateral blood flow by pressure measurements for assessing functional stenosis severity before and after percutaneous transluminal coronary angioplasty. *Circulation* 1993; 87: 1354-67.
18. Toth GG, De Bruyne B, Rusinaru D, Di Gioia G, Bartunek J, Pellicano M, et al. Impact of Right Atrial Pressure on Fractional Flow Reserve Measurements: Comparison of Fractional Flow Reserve and Myocardial Fractional Flow Reserve in 1,600 Coronary Stenoses. *JACC Cardiovasc Interv* 2016; 9: 453-9.
19. De Bruyne B, Baudhuin T, Melin JA, Pijls NH, Sys SU, Bol A, et al. Coronary flow reserve calculated from pressure measurements in humans. Validation with positron emission tomography. *Circulation* 1994; 89: 1013-22.
20. De Bruyne B, Hersbach F, Pijls NH, Bartunek J, Bech JW, Heyndrickx GR, et al. Abnormal epicardial coronary resistance in patients with diffuse atherosclerosis but "Normal" coronary angiography. *Circulation* 2001; 104: 2401-6.
21. Adjedj J, Toth GG, Johnson NP, Pellicano M, Ferrara A, Flore V, et al. Intracoronary Adenosine: Dose-Response Relationship With Hyperemia. *JACC Cardiovasc Interv* 2015; 8: 1422-30.
22. De Bruyne B, Pijls NH, Kalesan B, Barbato E, Tonino PA, Piroth Z, et al. Fractional flow reserve-guided PCI versus medical therapy in stable coronary disease. *New Engl J Med* 2012; 367: 991-1001.
23. Adjedj J, De Bruyne B, Flore V, Di Gioia G, Ferrara A, Pellicano M, et al. Significance of Intermediate Values of Fractional Flow Reserve in Patients With Coronary Artery Disease. *Circulation* 2016; 133: 502-8.
24. Koo BK, Park KW, Kang HJ, Cho YS, Chung WY, Youn TJ, et al. Physiological evaluation of the provisional side-branch intervention strategy for bifurcation lesions using fractional flow reserve. *Eur Heart J* 2008; 29: 726-32.
25. Samady H, McDaniel M, Veledar E, De Bruyne B, Pijls NH, Fearon WF, et al. Baseline fractional flow reserve and stent diameter predict optimal post-stent fractional flow reserve and major adverse cardiac events after bare-metal stent deployment. *JACC Cardiovasc Interv* 2009; 2: 357-63.
26. Nam CW, Mangiacapra F, Entjes R, Chung IS, Sels JW, Tonino PA, et al. Functional SYNTAX score for risk assessment in multivessel coronary artery disease. *J Am Coll Cardiol* 2011; 58: 1211-8.
27. Park SJ, Ahn JM, Pijls NH, De Bruyne B, Shim EB, Kim YT, et al. Validation of functional state of coronary tandem lesions using computational flow dynamics. *Am J Cardiol* 2012; 110: 1578-84.
28. Puymirat E, Peace A, Mangiacapra F, Conte M, Ntarladimas Y, Bartunek J, et al. Long-term clinical outcome after fractional flow reserve-guided percutaneous coronary revascularization in patients with small-vessel disease. *Circ Cardiovasc Interv* 2012; 5: 62-8.
29. Di Serafino L, De Bruyne B, Mangiacapra F, Bartunek J, Agostoni P, Vanderheyden M, et al. Long-term clinical outcome after fractional flow reserve- versus angio-guided percutaneous coronary intervention in patients with intermediate stenosis of coronary artery bypass grafts. *Am Heart J* 2013; 166: 110-8.
30. Toth G, De Bruyne B, Casselman F, De Vroey F, Pyxaras S, Di Serafino L, et al. Fractional flow reserve-guided versus angiography-guided coronary artery bypass graft surgery. *Circulation* 2013; 128: 1405-11.
31. De Bruyne B. Multivessel disease: from reasonably incomplete to functionally complete revascularization. *Circulation* 2012; 125: 2557-9.
32. Xaplanteris P, Fournier S, Pijls NHJ, Fearon WF, Barbato E, Tonino PAL, et al. Five-Year Outcomes with PCI Guided by Fractional Flow Reserve. *N Engl J Med* 2018 May 22. doi: 10.1056/NEJMoa1803538. [Epub ahead of print]
33. Danad I, Szymonifka J, Twisk JW, Norgaard BL, Zarins CK, Knaapen P, et al. Diagnostic performance of cardiac imaging methods to diagnose ischaemia-causing coronary artery disease when directly compared with fractional flow reserve as a reference standard: a meta-analysis. *Eur Heart J* 2017; 38: 991-8.
34. Curzen N, Rana O, Nicholas Z, Golledge P, Zaman A, Oldroyd K, et al. Does routine pressure wire assessment influence management strategy at coronary angiography for diagnosis of chest pain?: the RIPCOR study. *Circ Cardiovasc Interv* 2014; 7: 248-55.
35. Nakamura M, Yamagishi M, Ueno T, Hara K, Ishiwata S, Itoh T, et al. Prevalence of visual-functional mismatch regarding coronary artery stenosis in the CVIT-DEFER registry. *Cardiovasc Interv Ther* 2014; 29: 300-8.
36. Tanaka N, Nakamura M, Akasaka T, Kadota K, Uemura S, Amano T, et al. One-Year Outcome of Fractional Flow Reserve-Based Coronary Intervention in Japanese Daily Practice- CVIT-DEFER Registry. *Circ J* 2017; 81: 1301-6.
37. Serruys PW, Reiber JH, Wijns W, van den Brand M, Kooijman CJ, ten Katen HJ, et al. Assessment of percutaneous transluminal coronary angioplasty by quantitative coronary angiography: diameter versus densitometric area measurements. *Am J Cardiol* 1984; 54: 482-8.
38. Toth GG, Toth B, Johnson NP, De Vroey F, Di Serafino L, Pyxaras S, et al. Revascularization Decisions in Patients With Stable Angina and Intermediate Lesions: Results of the International Survey on Interventional Strategy. *Circ Cardiovasc Interv* 2014; 7: 751-9.
39. Shah R, Yow E, Jones WS, Kohl LP 3rd, Kosinski AS, Hoffmann U, et al. Comparison of visual assessment of coronary stenosis with independent quantitative coronary angiography: Findings from the Prospective Multicenter Imaging Study for Evaluation of Chest Pain (PROMISE) trial. *Am Heart J* 2017; 184: 1-9.

40. Kimura BJ, Russo RJ, Bhargava V, McDaniel MB, Peterson KL, De-Maria AN. Atheroma morphology and distribution in proximal left anterior descending coronary artery: in vivo observations. *J Am Coll Cardiol* 1996; 27: 825-31.
41. Nissen SE, Yock P. Intravascular ultrasound: novel pathophysiological insights and current clinical applications. *Circulation* 2001; 103: 604-16.
42. Kang SJ, Lee JY, Ahn JM, Song HG, Kim WJ, Park DW, et al. Intravascular ultrasound-derived predictors for fractional flow reserve in intermediate left main disease. *JACC Cardiovasc Interv* 2011; 4: 1168-74.
43. Nascimento BR, de Sousa MR, Koo BK, Samady H, Bezerra HG, Ribeiro AL, et al. Diagnostic accuracy of intravascular ultrasound-derived minimal lumen area compared with fractional flow reserve—meta-analysis: pooled accuracy of IVUS luminal area versus FFR. *Catheter Cardiovasc Interv* 2014; 84: 377-85.
44. Pawlowski T, Prati F, Kulawik T, Ficarra E, Bil J, Gil R. Optical coherence tomography criteria for defining functional severity of intermediate lesions: a comparative study with FFR. *Int J Cardiovasc Imaging* 2013; 29: 1685-91.
45. Usui E, Yonetsu T, Kanaji Y, Hoshino M, Yamaguchi M, Hada M, et al. Efficacy of Optical Coherence Tomography-derived Morphometric Assessment in Predicting the Physiological Significance of Coronary Stenosis: Head-to-Head Comparison with Intravascular Ultrasound. *EuroIntervention* 2018; 13: e2210-8.
46. Tu S, Xu L, Ligthart J, Xu B, Witberg K, Sun Z, et al. In vivo comparison of arterial lumen dimensions assessed by co-registered three-dimensional (3D) quantitative coronary angiography, intravascular ultrasound and optical coherence tomography. *Int J Cardiovasc Imaging* 2012; 28: 1315-27.
47. Xu B, Tu S, Qiao S, Qu X, Chen Y, Yang J, et al. Diagnostic Accuracy of Angiography-Based Quantitative Flow Ratio Measurements for Online Assessment of Coronary Stenosis. *J Am Coll Cardiol* 2017; 70: 3077-87.
48. Johnson NP, Tóth GG, Lai D, Zhu H, Açar G, Agostoni P, et al. Prognostic value of fractional flow reserve: linking physiologic severity to clinical outcomes. *J Am Coll Cardiol* 2014; 64: 1641-54.
49. Gaur S, Taylor CA, Jensen JM, Bøtker HE, Christiansen EH, Kaltoft AK, et al. FFR Derived From Coronary CT Angiography in Nonculprit Lesions of Patients With Recent STEMI. *JACC Cardiovasc Imaging* 2017; 10: 424-33.
50. Mejía-Rentería H, van der Hoeven N, van de Hoef TP, Heemelaar J, Ryan N, Lerman A, et al. Targeting the dominant mechanism of coronary microvascular dysfunction with intracoronary physiology tests. *Int J Cardiovasc Imaging* 2017; 33: 1041-59.