

Functional magnetic resonance imaging of the kidneys: where do we stand? The perspective of the European COST Action PARENCHIMA

Anna Caroli¹, Menno Pruijm², Michel Burnier² and Nicholas M. Selby³

¹Medical Imaging Unit, Bioengineering Department, IRCCS Istituto di Ricerche Farmacologiche Mario Negri, Bergamo, Italy, ²Service of Nephrology and Hypertension, Department of Medicine, University Hospital of Lausanne (CHUV), Switzerland and ³Centre for Kidney Research and Innovation, University of Nottingham, Nottingham, UK

Correspondence and offprint requests to: Anna Caroli; E-mail: acaroli@marionegri.it;
Twitter handle: @renalMRI

When Kai-Uwe Eckardt, an internationally renowned nephrologist, was asked at the 2nd International Meeting on Renal MRI in Berlin what he expected from magnetic resonance imaging (MRI) of the kidneys he answered without hesitation, ‘A lot!’ This short answer expresses the unmet need for improved imaging methods that many in the nephrology community sense. But how far away is a wider use of renal MRI in clinical practice?

MRI has come a long way since the 1970s, when the first cross-sectional MRI images of two test tubes were generated [1]. This was closely followed by the development of fast-scan techniques that were an essential step in the adoption of MRI as a clinical diagnostic tool [2], and then the first MRI scans in man [3, 4]. Modern MRI can generate exquisitely detailed anatomical images, but crucially now also encompasses functional MRI. With respect to the kidney, these techniques provide the opportunity to assess total renal volume, the volume of different compartments (i.e. cortex and medulla), function, perfusion, oxygenation, oedema and potentially also the degree of fibrosis or inflammation. Many of these measures can be combined within a single scan session (multiparametric MRI), and do not need the administration of contrast agents, a major advantage in renal patients. As such, MRI has few contra-indications, and estimates suggest that >95% of chronic kidney disease (CKD) patients could potentially undergo renal MRI. **Figure 1** provides a (non-exhaustive) overview of some of the currently available techniques.

To quote Pottumarthi Prasad, functional MRI is motivated by the following: (i) to better understand physiology and pathophysiology; (ii) to provide more comprehensive characterization of pathological lesions; (iii) to provide a more sensitive or earlier index of disease progression; and (iv) to target therapy to the individual (personalized medicine) along with

measurement of response [5]. In terms of kidney diseases, these principles are highly relevant. The prevalence of CKD is considerable and still rising; ultrasound is the only imaging modality used in the majority of patients and provides only limited information. In large CKD cohorts, only ~25% of all CKD patients under the care of nephrologists have undergone a biopsy, and in a similar proportion the cause of CKD is designated as unknown [6, 7]. New imaging methods to identify, characterize and track kidney damage at an early stage are urgently needed; such methods will also have the potential to contribute to the development and successful application of new therapies. To this end, newer renal MRI techniques offer great potential to generate diagnostic, prognostic, predictive, monitoring and safety biomarkers.

However, we have to acknowledge that there are challenges and knowledge gaps that must be addressed before renal MRI methods can be more widely adopted in clinical research and ultimately be transferred to clinical practice. Some of these challenges are technical. Unwanted variation in acquisition, analysis and post-processing approaches need to be reduced, and improvements made in standardizing patient preparation. This is reflected in many MRI techniques being restricted to the research settings in which they were developed. Knowledge gaps include the biological basis of different MRI biomarkers, and how the application of these biomarkers will improve patient care. In addition, the limited availability of MRI scanners and the expense of scanning time eventually need to be offset by a positive health economic impact. All of these factors hinder the set-up of multi-centre trials, limit commercial exploitation and delay translation into clinical practice.

To address these important issues, a multinational group, funded by a European Union COST (European Cooperation in Science and Technology) Action, has recently been formed

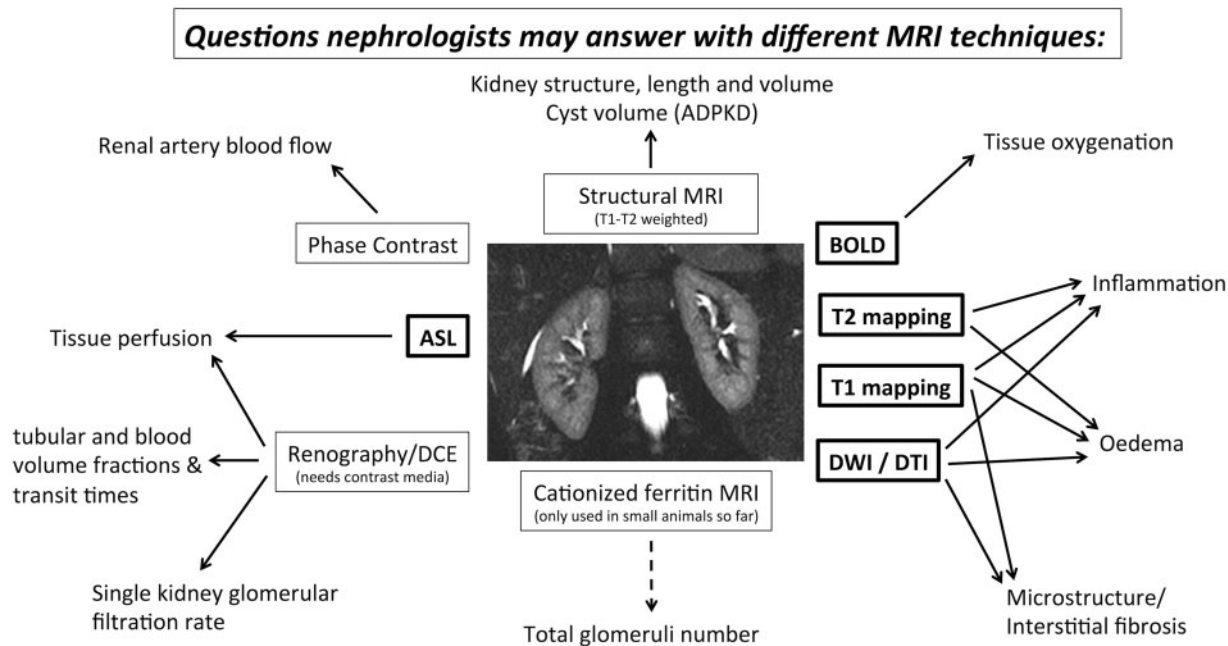


FIGURE 1: Overview of the clinical questions nephrologists may answer, now or in the near future, with functional MRI. The techniques shown in bold are discussed in this supplement. DCE, dynamic contrast enhanced; ADPKD, autosomal dominant polycystic kidney disease; DTI, diffusion tensor imaging.

called ‘PARENCHIMA’: Magnetic Resonance Imaging Biomarkers for Chronic Kidney Disease (www.renalmri.org). PARENCHIMA aims to eliminate the barriers to the broader study, commercial exploitation and clinical use of functional renal MRI biomarkers, initially focusing on CKD but with the potential to generalize to a number of other areas, including renal transplantation and acute kidney injury, cardiorenal syndrome and renovascular disease. This multidisciplinary group brings together a large network of leading nephrologists, radiologists, MRI physicists, medical imaging experts, histopathologists, physiologists and clinical researchers with internationally recognized expertise in the field of renal MRI and CKD and links to a number of other national and international initiatives (e.g. UK renal imaging network, www.kidneyresearchuk.org/research/uk-renal-imaging-network; Biomarker Enterprise to Attack Diabetic Kidney Disease—BEAT-DKD, www.beat-dkd.eu; the National Unified Renal Translational Research Enterprise—NURTURE, www.nurturebiobank.org; German Chronic Kidney Disease—GCKD Study, <https://www.gckd.org>; Chronic Kidney Disease—Epidemiology and Information Network Nephrology—CKD-REIN, ckdrein.inserm.fr).

This special supplement of *Nephrology Dialysis Transplantation*, written collaboratively by international experts from PARENCHIMA, aims to support future activities of PARENCHIMA and other renal MRI research groups. The key clinical questions that renal MRI must address to become more widely used in patients with kidney disease, as well as a series of practical recommendations to accelerate renal MRI clinical research, are presented in a position paper [8]. This is then followed by four in-depth reviews of the most commonly used and promising renal functional MRI techniques: diffusion-weighted MRI (DWI) [9], blood oxygen level dependent

(BOLD) MRI [10], arterial spin labelling (ASL) [11] and T1/T2 mapping of the kidney [12]. Each review paper presents the current status of scientific knowledge in each MRI modality, provides an overview of all studies performed so far in the human kidney (excluding those pertaining to kidney cancer), presents published ranges in healthy and kidney disease populations and discusses current and future clinical application. These papers also highlight current limitations, gaps in knowledge and unmet needs of each individual MRI modality. In combination, these articles provide a comprehensive description of the current status quo, with the aim of aligning and accelerating technical developments, standardization and clinical research. Thus, this supplement should become an essential document for all researchers and clinicians interested in MRI and renal diseases. We firmly believe that the potential of renal MRI biomarkers is immense; collaborative efforts such as PARENCHIMA are needed to move the field forwards and will allow us to prove that MRI really does have ‘a lot’ to offer.

ACKNOWLEDGEMENTS

We would like to dedicate the supplement to Professor Jarle Rørvik, a professor in Radiology in the University of Bergen with a passion for renal MRI, a dear colleague and active supporter of the PARENCHIMA project, who suddenly passed away before seeing the project come to fruition. This article is based upon work from COST Action Magnetic Resonance Imaging Biomarkers for Chronic Kidney Disease (PARENCHIMA), funded by COST (European Cooperation in Science and Technology; www.cost.eu). For additional information, please visit PARENCHIMA project website: www.renalmri.org

FUNDING

M.P. is supported by a grant from the Swiss National Science Foundation (FN 320030-169191).

CONFLICT OF INTEREST STATEMENT

None declared.

REFERENCES

1. Lauterbur PC. Image formation by induced local interactions: examples employing nuclear magnetic resonance. *Nature* 1973; 242: 190–191
2. Mansfield P, Grannell PK. 'Diffraction' and microscopy in solids and liquids by NMR. *Phys Rev B Condens Matter* 1975; 12: 3618–3634
3. Mansfield P, Maudsley AA. Medical imaging by NMR. *Br J Radiol* 1977; 50: 188–194
4. Damadian R, Goldsmith M, Minkoff L. NMR in cancer: XVI. FONAR image of the live human body. *Physiol Chem Phys* 1977; 9: 97–100
5. Prasad PV. Functional MRI of the kidney: tools for translational studies of pathophysiology of renal disease. *Am J Physiol Ren Physiol* 2006; 290: F958–F974
6. Titze S, Schmid M, Köttgen A *et al.* Disease burden and risk profile in referred patients with moderate chronic kidney disease: composition of the German Chronic Kidney Disease (GCKD) cohort. *Nephrol Dial Transplant* 2015; 30: 441–451
7. Stengel B, Metzger M, Combe C *et al.* Risk profile, quality of life and care of patients with moderate and advanced CKD: The French CKD-REIN Cohort Study. *Nephrol Dial Transplant* 2018. doi: 10.1093/ndt/gfy058
8. Selby NM, Blankestijn PJ, Boor P *et al.* Magnetic resonance imaging biomarkers for chronic kidney disease: a position paper from the European Cooperation in Science and Technology Action PARENCHIMA. *Nephrol Dial Transplant* 2018; 33 (Suppl 2): ii4–ii14
9. Caroli A, Schneider M, Friedli I *et al.* Diffusion-weighted magnetic resonance imaging to assess diffuse renal pathology: a systematic review and statement paper. *Nephrol Dial Transplant* 2018; 33 (Suppl 2): ii29–ii40
10. Pruijm M, Mendichovszky IA, Liss P *et al.* Renal blood oxygenation level-dependent magnetic resonance imaging to measure renal tissue oxygenation: a statement paper and systematic review. *Nephrol Dial Transplant* 2018; 33 (Suppl 2): ii22–ii28
11. Odudu A, Nery F, Hartevelde AA *et al.* Arterial spin labelling MRI to measure renal perfusion: a systematic review and statement paper. *Nephrol Dial Transplant* 2018; 33 (Suppl 2): ii15–ii21
12. Wolf M, de Boer A, Sharma K *et al.* Magnetic resonance imaging T₁- and T₂-mapping to assess renal structure and function: a systematic review and statement paper. *Nephrol Dial Transplant* 2018; 33 (Suppl 2): ii41–ii50

Received: 14.5.2018; Editorial decision: 15.5.2018