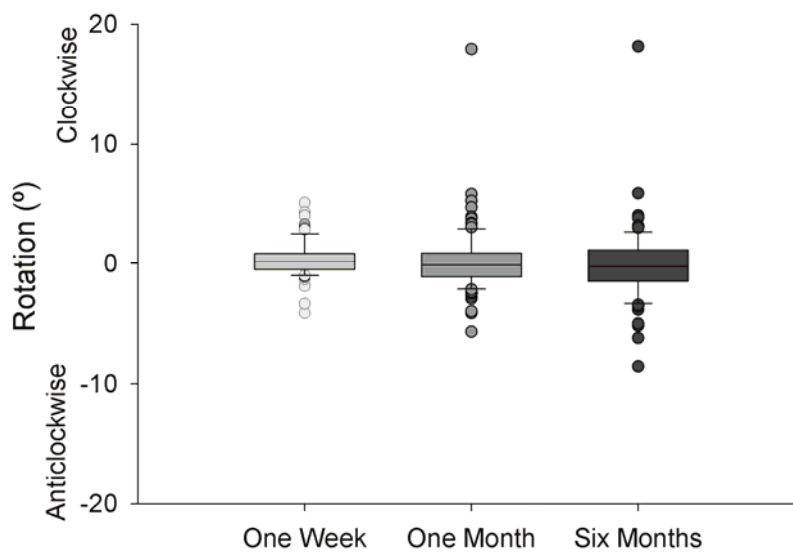
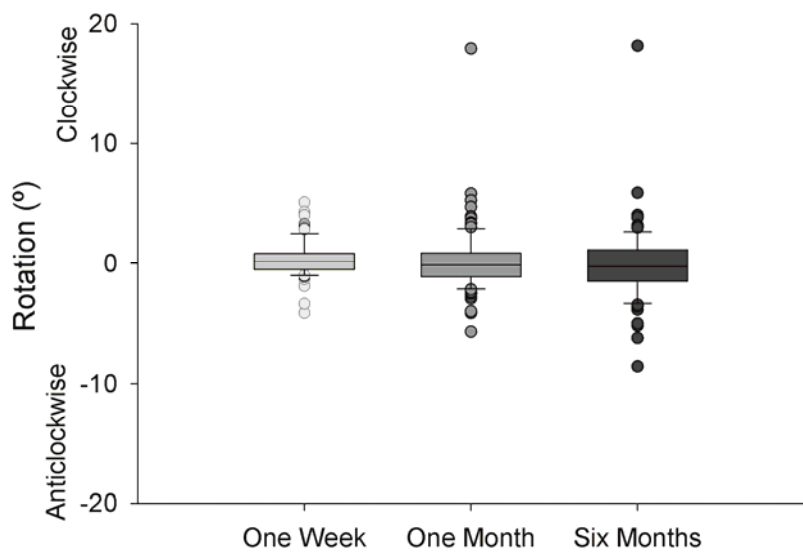
Title: Rotational and Centration Stability of the Aspheric Akreos AO Intraocular Lens

Running Head: Stability of Akreos AO Intraocular Lens Platform

Authors: Phillip J. Buckhurst, BSc
James S. Wolffsohn, PhD

Shehzad A. Naroo, PhD

Leon N. Davies, PhD

Affiliation (all authors): Aston University, School of Life and Health Sciences, Ophthalmic Research Group, Birmingham, B4 7ET, UK

Presentation: Association for Research in Vision and Ophthalmology meeting, Fort Lauderdale, May 2009

None of the authors has a financial or proprietary interest in any of the products, methods or materials mentioned. The study was funded by Bausch and Lomb.

Corresponding Author:

Prof James S. Wolffsohn

Aston University, School of Life and Health Sciences, Ophthalmic Research Group

Aston University, Birmingham, B4 7ET, UK

Email: j.s.w.wolffsohn@aston.ac.uk

Abstract

PURPOSE: To assess the stability of the Akreos AO intraocular lens (IOL) platform, with a simulated toric design, using objective image analysis.

SETTING: Six hospital eye clinics across Europe.

METHODS: IOLs with orientation marks were imaged in 107 patients aged 69.9 ± 7.7 years implanted monocularly with Akreos AO aspheric IOLs at 1-2 days, 7-14 days, 30-60 days and 120-180 days after implantation. The axis of rotation and IOL centration were objectively assessed using image analysis.

RESULTS: The image quality was sufficient for IOL rotation analysis in 91% of eyes. The average rotation between the first day after implantation and 120-180 days was $1.93 \pm 2.33^\circ$, with 96% of IOLs rotating $<5^\circ$ and 99% rotating $<10^\circ$. There was no significant rotation between visits and there was no clear bias in the direction of the rotation. In 71% of eyes, the dilation and image quality was sufficient for image analysis of centration. The average change in centration between the first day after implantation and 120-180 days was 0.21 ± 0.11 mm, with 100% of IOLs decentring <0.5 mm. There was no significant decentration between visits and there was no clear bias in the direction of the decentration.

CONCLUSIONS: Objective analysis of digital retroillumination images taken at different post-op periods shows the Akreos AO platform to be stable in the eye. Therefore, it is suitable for the application of a toric surface to correct corneal astigmatism.

The prevalence of corneal astigmatism, greater than 1.50 DC, is estimated to be 22%.¹

Uncorrected astigmatism reduces visual acuity and increases spectacle dependence; this can reduce quality of life² and increase overall economic costs.³ Correcting astigmatism at the time of surgery removes the problem of meridional magnification caused by spectacle astigmatic correction, which distorts shape and affects spatial perception.⁴

Corneal astigmatism following cataract surgery can be corrected either with corneal or limbal relaxing incisions^{5,6} or with a toric intraocular lens (IOL). Correction of astigmatism on the cornea relies on a predictable corneal healing response, which can be capricious especially with high levels of astigmatism.⁷ Toric IOLs promise a more stable correction of astigmatism for cataract patients as long as the lens is correctly positioned and does not rotate. There is a sinusoidal relationship between the amount of axis misalignment and the residual cylinder power; therefore, small misalignments cause disproportionately larger losses of cylindrical effect.⁸ If a cylindrical correction rotates 30° off-axis after surgery, there will be no correction of the astigmatic power, although the resultant cylinder will have shifted to a new axis.⁹

The first described posterior chamber toric IOL was the Nidek Toric NT-98B.¹⁰ This was a 13.5 mm long three-piece lens with loop haptics. However, over one-fifth of these lenses rotated by more than 30°. ¹⁰ Since the introduction of the NT-98B, there has been much advancement in toric IOL technology. The first commercially available posterior chamber toric IOL was the STAAR 4203TF, which had silicone plate haptics. Several studies have shown a relatively high incidence of postoperative axis rotation of this IOL (Table 1). A longer 11.2 mm version of the STAAR 4203TF IOL was later introduced (AA4203TL) giving more stable results compared with its shorter predecessor.¹⁵

The Alcon AcrySof SN60T (models 3,4 and 5) achieved FDA approval in 2005 and is the current first-choice toric IOL.²⁸ The FDA trial on 244 subjects found 81.9% of lenses rotated less than 5° and 97.1% less than 10°. The rate of extraction or reposition of this lens is between 0.8% (FDA trial

<http://www.accessdata.fda.gov/scripts/cdrh/cfdocs/cftopic/pma/pma.cfm?num=p930014s015> accessed on the 10/08/09) and 1.1%.²⁹ There are several other non-FDA approved Toric IOLs currently available in Europe with a variety of different haptic designs.^{25,30} Toric IOLs have shown to be effective in correcting irregular as well as regular astigmatism.³¹ Previous published studies have seldom assessed positional stability as well as rotational stability.³²

The purpose of this study is to determine the rotational stability and centration of the Akreos AO aspheric IOL platform over a 6-month period following implantation to determine if it would be a suitable and effective medium for correcting astigmatism through the application of a toric optical surface.

Method

One hundred and seven patients were implanted monocularly with the fifth generation Akreos AO aspheric IOL (Bausch and Lomb, Rochester, New York) with orientation marks in one eye at six hospital sites across Europe. Inclusion criteria included age-related cataract amenable to treatment with standard phacoemulsification and IOL implantation, and pupils which could be dilated to at least 5mm. Subjects were aged 69.9 ± 7.7 years (range 51 to 87 years) and 63% were female.

The acrylic, hydrophilic lens has a 6 mm optic with a 360° posterior square edge barrier attached to 11 mm closed loop haptics. . The optic has aspheric surfaces aiming to induce no IOL aberrations. Preoperatively conjunctival markings were imprinted on the IOL to form a reference point for the IOL alignment. A 5.5 mm continuous curvilinear capsulotomy was used through which phacoemulsification was performed. Once the capsular bag was filled with a viscoelastic substance, the lens was inserted using an *Akreos* single use insertion device through a 2.8 mm incision and the viscoelastic device aspirated from in front and behind the lens.

Patients were dilated using phenylephrine 2.5% and tropicamide 1.0% at 4 post operative appointments. These appointments were conducted 1-2, 7-14, 30-60 and 120-180 days after IOL implantation. The intraocular lens was imaged at 10x magnification in retroillumination using a CSO SL-990 digital slit-lamp biomicroscope (Costruzione Strumenti Oftalmici, Florence, Italy). Informed consent was obtained from all participants prior to lens implantation and the study was approved by ethical committees at each of the sites.

The axis of rotation of the IOL was determined from the digitally captured image by drawing a line to join the IOL orientation marks. This was normalised for any rotation of the eye in front of the slit-lamp between visits by comparing the axis of a line joining two consistent conjunctival vessels or iris features on opposite sides of the pupil margin. The reference markers needed to be visible on the images captured at every follow-up visit and allowed rotation to be assessed at each visit in 97 of the 107 eyes. The centre of two ovals overlaid to circumscribe the IOL optic edge and the limbus, respectively, were compared to determine the IOL centration. Pupil dilation was only sufficient for centration to be quantified in 76 of the 107 eyes. This technique has previously been evaluated and showed excellent repeatability.³²

Statistical Analysis

To assess rotation, the toric mark orientation, compensated for head rotation, at each visit was subtracted from the value obtained 1-2 days after surgery. Repeated measure analysis of variance was used to assess orientational stability between visits. The IOL centration with respect to the limbus at each visit was subtracted from 1-2 days after surgery to assess decentration. Repeated measure analysis of variance was used to assess locational stability between visits.

Results

The average and range of rotation at each visit compared to 1-2 days after surgery is displayed in figure 1. All lenses rotated $<5^\circ$ between 7-14 days and 1-2 days (absolute rotation $1.03 \pm 1.08^\circ$). By 30-60 days after implantation 3% of eyes had rotated between 5° and 10° (absolute rotation $1.53 \pm 2.16^\circ$) and this remained stable up to 120-180 days (absolute rotation $1.93 \pm 2.33^\circ$). One lens (1%), in an eye that was clearly inflamed, rotated more than 10° by 30-60 days but subsequently remained stable. There appeared to be no strong bias in the direction of the rotation, with 60% rotating clockwise. There was no significant rotation between day 1-2 and day 120-180 ($F = 0.96$, $p = 0.412$).

Decentration on implantation was generally superior (0.18 ± 0.17 mm) nasal (0.19 ± 0.15 mm). Total absolute decentration values were 0.31 ± 0.13 mm at 1-2 days, 0.30 ± 0.13 mm at 7-14 days, 0.30 ± 0.14 mm at 30-60 days and 0.28 ± 0.12 mm at 120-180 days. There were no significant changes in IOL centration with time ($F = 1.61$, $p = 0.09$), with subsequent decentration appearing random in direction (Figure 2). All lenses remained within 0.5 mm of their 1-2 day position at all visits average 0.21 ± 0.11 mm.

Discussion

The literature seems to support four main mechanisms resulting in IOL rotation after implantation: The first is caused by the initial friction between the IOL haptics within the capsular bag relating to IOL and capsule size and residual viscoelastic; the second is due to instability of the anterior chamber related to post-operative intraocular pressure changes and ocular trauma; the third is influenced by the lens design and level of fibrosis; the final cause is compression of the IOL haptics from capsular bag shrinkage.

Movement of IOL haptics within the capsular bag tends to occur during the early postoperative period before fusion between the capsular bag and IOL haptics.³³ Maximising friction between haptic and capsular bag can reduce this early rotation. Several mechanisms can be employed to increase the friction. A larger lens diameter ensures more contact with the capsular bag and, therefore, more friction; however, if too large, distortion of the capsular bag and zonules occurs.³⁴ Unfortunately, it is difficult to establish the size of the capsular bag in the clinic pre-operatively and a reliable link between accessible ocular measurements and capsular bag size are yet to be confirmed.³⁵ Haptic materials need to be considered as these also affect the amount of friction: PMMA gives the most adhesive force between bag and haptic, followed by foldable Acrylic with silicone the least.³⁶ Care needs to be taken to remove completely the ophthalmic viscoelastic device (OVD), which coats the IOL, decreasing friction and thus allowing easy manipulation.³⁷ OVDs vary in viscosity and the type of OVD used may influence the amount of rotation.¹⁵

Intraocular pressure can fluctuate in the early period after cataract surgery causing increased fluid flow within the anterior chamber. In uneventful cataract surgery, IOP can drop to below 5

mmHg in 6.3% of patients³⁸. Hypotony causes destabilisation of the anterior chamber reducing its integrity and, therefore, resulting in a higher risk of rotation.³⁹ Post-operative ocular trauma can also cause IOL rotation. If the force on the eye is sufficient to cause significant wound leakage then large degrees of IOL rotation can occur.³⁹

Positioning holes, present on many plate haptics, can increase stability. Capsular fibrosis and proliferative lens cortical material migrate through the positioning holes creating an effective anchor. The larger the positioning holes, the more material migrates through them, strengthening the fixation of the IOL with capsule therefore increasing long-term stability and could help resist the effect of traumatic forces. This fibrosis typically takes 2 weeks after implantation to establish.⁴⁰ If a toric lens is misaligned it is easier to reposition the IOL before this fibrosis occurs.²⁹

Capsular shrinkage compresses on the IOL haptics and, depending on the design, can cause rotation. Plate haptic lenses have no preference in their direction of rotation and show good stability with capsular compression.¹⁶ Open loop haptic IOL's however can rotate with capsular compression. If sufficient friction between the haptics and capsule occurs, then the lens optic rotates clockwise (presuming the haptics are directed anticlockwise) under compression. If insufficient friction is present, however, then the haptics slip causing an anticlockwise rotation;⁴¹ this pattern of rotation has been demonstrated *in vivo*.^{34,42}

The rotational stability and centration of the Akreos AO platform as assessed by an established sensitive and repeatable objective technique was as good, or better than, previously studies

toric IOLs (Table 1). The 11 mm length of the IOL and acrylic material should maximise early friction with the lens capsule. The 4 large positioning holes should be anchored by fibrosis migration. These features of the first closed loop haptic design to be examined for rotational stability, show it to be resilient to potential rotation caused by compression of the capsular bag. The lens was shown to provide excellent rotational stability with only 4% of lenses rotating more than 5 degrees (with no systematic direction of rotation) and 1% more than 10 degrees. This would result in the effectivity of the toric power being reduced by just $6.7 \pm 8.0\%$ over the 6 months⁸. The effect of IOL decentration and tilt has previously been examined on spherical and aspherical IOLs using Scheimpflug imaging and bespoke systems utilising Purkinje images.⁴³ Lens tilt can induce coma aberrations, but the effect of decentration is difficult to predict; it is dependent on the shape factor of the IOL.⁴⁴ Despite the reference for centration differing between studies between the pupil and corneal center or visual axis, centration results from this study compare well with modern studies on aspheric IOLs where no higher order aberrations were induced by increased decentration.⁴⁵

Although the IOL did not have a toric optic, it is not expected that the change in thickness profile when this is added would have a significant effect on rotational stability or centration. Consequently, the Akreos AO should provide an excellent rotationally and centration stable platform with which to correct corneal astigmatism through the application of a toric optical surface.

References

- [1] Ferrer-Blasco T, Montes-Mico R, Peixoto-de-Matos S C, Gonzalez-Meijome J M, Cervino A. Prevalence of corneal astigmatism before cataract surgery. *J Cataract Refract Surg* 2009; 35: 70-75.
- [2] Pesudovs K, Garamendi E, Elliott D B. A quality of life comparison of people wearing spectacles or contact lenses or having undergone refractive surgery. *J Refract Surg*. 2006; 22: 19-27.
- [3] Laurendeau C, Lafuma A, Berdeaux G. Modelling lifetime cost consequences of toric compared with standard IOLs in cataract surgery of astigmatic patients in four European countries. *J Med Econ* 2009; 12: 230-237.
- [4] Guyton D L. Prescribing cylinders: the problem of distortion. *Surv Ophthalmol* 1977; 22: 177-188.
- [5] Sun XY, Vicary D, Montgomery P, Griffiths M. Toric intraocular lenses for correcting astigmatism in 130 eyes. *Ophthalmology* 2000; 107: 1776-1781.
- [6] Mendicute J, Irigoyen C, Ruiz M, Illarramendi I, Ferrer-Blasco T, Montes-Mico R. Toric intraocular lens versus opposite clear corneal incisions to correct astigmatism in eyes having cataract surgery. *J Cataract Refract Surg* 2009; 35: 451-458.
- [7] Tehrani M, Dick HB, Incisional Keratotomy to Toric Intraocular Lenses: An Overview of the Correction of Astigmatism in Cataract and Refractive Surgery. *Int Ophthalmol Clin* 2003; 43: 43-52
- [8] Ma JJ, Tseng SS. Simple method for accurate alignment in toric phakic and aphakic intraocular lens implantation. *J Cataract Refract Surg* 2008; 34: 1631-1636.

- [9] Novis C. Astigmatism and toric intraocular lenses. *Curr Opin Ophthalmol* 2000; 11: 47-50.
- [10] Shimizu K, Misawa A, Suzuki Y. Toric intraocular lenses: correcting astigmatism while controlling axis shift. *J Cataract Refract Surg* 1994; 20: 523-526.
- [11] Grabow H B. Toric intraocular lens report. *Annals of Ophthalmology-Glaucoma* 1997; 29: 161-163.
- [12] Ruhswurm I, Scholz U, Zehetmayer M, Hanselmayer G, Vass C, Skorpik C. Astigmatism correction with a foldable toric intraocular lens in cataract patients. *J Cataract Refract Surg* 2000; 26: 1022-1027.
- [13] Leyland M, Zinicola E, Bloom P, Lee N. Prospective evaluation of a plate haptic toric intraocular lens. *Eye (Lond)* 2001; 15: 202-205.
- [14] Till J S, Yoder P R, Wilcox T K, Spielman J L. Toric intraocular lens implantation: 100 consecutive cases. *J Cataract Refract Surg* 2002; 28: 295-301.
- [15] Chang D F. Early rotational stability of the longer Staar toric intraocular lens: fifty consecutive cases. *J Cataract Refract Surg* 2003; 29: 935-940.
- [16] Jampaulo M, Olson M D, Miller K M. Long-term Staar toric intraocular lens rotational stability. *Am J Ophthalmol* 2008; 146: 550-553.
- [17] Chang D F. Comparative rotational stability of single-piece open-loop acrylic and plate-haptic silicone toric intraocular lenses. *J Cataract Refract Surg* 2008; 34: 1842-1847.
- [18] Weinand F, Jung A, Stein A, Pfutzner A, Becker R, Pavlovic S. Rotational stability of a single-piece hydrophobic acrylic intraocular lens: new method for high-precision rotation control. *J Cataract Refract Surg* 2007; 33: 800-803.

- [19] Bauer N J, de Vries N E, Webers C A, Hendrikse F, Nuijts R M. Astigmatism management in cataract surgery with the AcrySof toric intraocular lens. *J Cataract Refract Surg* 2008; 34: 1483-1488.
- [20] Olaru G, Gavris M, Horge I, Marian N, Popa D, Levai L, Ghindea C, Bran L. [Toric intraocular lens implantation in cataract patients--6 months results]. *Oftalmologia* 2008; 52: 100-104.
- [21] Mendicute J, Irigoyen C, Aramberri J, Ondarra A, Montes-Mico R. Foldable toric intraocular lens for astigmatism correction in cataract patients. *Journal of Cataract and Refractive Surgery* 2008; 34: 601-607.
- [22] Zuberbuhler B, Signer T, Gale R, Haefliger E. Rotational stability of the AcrySof SA60TT toric intraocular lenses: a cohort study. *BMC Ophthalmol* 2008; 8: 8.
- [23] Dardzhikova A, Shah CR, Gimbel HV. Early experience with the AcrySof toric IOL for the correction of astigmatism in cataract surgery. *Can J Ophthalmol*, 2009; 44: 269-273.
- [24] Ruiz-Mesa R, Carrasco-Sanchez D, Diaz-Alvarez SB, Ruiz-Mateos MA, Ferrer-Blasco T, Montes-Mico R. Refractive lens exchange with foldable toric intraocular lens. *Am J Ophthalmol* 2009; 147: 990-996.
- [25] De Silva DJ, Ramkissoon YD, Bloom PA. Evaluation of a toric intraocular lens with a Z-haptic. *J Cataract Refract Surg* 2006; 32: 1492-8.
- [26] Dick HB, Krummenauer F, Trober L. [Compensation of corneal astigmatism with toric intraocular lens: results of a multicentre study]. *Klin Monatsbl Augenheilkd* 2006; 223: 593-608.

- [27] Gerten G, Michels A, Olmes A. [Toric intraocular lenses. Clinical results and rotational stability]. *Ophthalmologe* 2001; 98: 715-20.
- [28] Pick Z S, Leaming D V, Elder M J. The fourth New Zealand cataract and refractive surgery survey: 2007. *Clin Experiment Ophthalmol* 2008; 36: 604-619.
- [29] Chang D F. Repositioning technique and rate for toric intraocular lenses. *J Cataract Refract Surg* 2009; 35: 1315-1316.
- [30] Borkenstein A F, Reuland A, Limberger I J, Rabsilber T M, Auffarth G U. Transscleral fixation of a toric intraocular lens to correct aphakic keratoplasty with high astigmatism. *J Cataract Refract Surg* 2009; 35: 934-8.
- [31] Navas A, Suarez R. One-year follow-up of toric intraocular lens implantation in forme fruste keratoconus. *J Cataract Refract Surg* 2009; 35: 2024-2027.
- [32] Wolffsohn JS, Buckhurst PJ. Objective Analysis of Toric Intraocular Lens Rotation and Centration *J Cataract Refract Surg* 2010; *In press*.
- [33] Patel C K, Ormonde S, Rosen P H, Bron A J. Postoperative intraocular lens rotation: a randomized comparison of plate and loop haptic implants. *Ophthalmology* 1999; 106: 2190-5; discussion 2196.
- [34] Lim S J, Kang S J, Kim H B, Apple D J. Ideal size of an intraocular lens for capsular bag fixation. *J Cataract Refract Surg* 1998; 24: 397-402.
- [35] Khng C, Osher R H. Evaluation of the relationship between corneal diameter and lens diameter. *Journal of Cataract and Refractive Surgery* 2008; 34: 475-479.

- [36] Oshika T, Nagata T, Ishii Y. Adhesion of lens capsule to intraocular lenses of polymethylmethacrylate, silicone, and acrylic foldable materials: an experimental study. *Br J Ophthalmol* 1998; 82: 549-53.
- [37] Myers TD, Olson RJ. Comparison of the effects of Viscoelastic agents on clinical properties of the Unfolder lens injection system. *J Cataract Refract Surg* 1999; 25:953-958.
- [38] Shingleton B J, Rosenberg R B, Teixeira R, O'Donoghue M W. Evaluation of intraocular pressure in the immediate postoperative period after phacoemulsification. *J Cataract Refract Surg* 2007; 33: 1953-7.
- [39] Pereira F A, Milverton E J, Coroneo M T. Miyake-Apple study of the rotational stability of the Acrysof toric intraocular lens after experimental eye trauma. *Eye* 2009; [Epub ahead of print]
- [40] Mamalis N, Omar O, Veiga J, Tanner D, Pirayesh A, Fernquist D S. Comparison of two plate-haptic intraocular lenses in a rabbit model. *J Cataract Refract Surg* 1996; 22: Suppl 2, 1291-5.
- [41] Parssinen O, Raty J, Vainikainen J, Timonen J, Lyyra A L. Compression forces of haptics of freely rotating posterior chamber intraocular lenses. *J Cataract Refract Surg* 1998; 24: 415-425.
- [42] Werblin T P. Do three-piece PMMA IOLs rotate after implantation in the capsular bag? *J Refract Surg* 1995; 11: 468-471.
- [43] De Castro A, Rosales P, Marcos S. Tilt and decentration of intraocular lenses in vivo from Purkinje and Scheimpflug imaging. Validation study. *J Cataract Refract Surg* 2007; 33: 418-429.

- [44] Atchison DA. Refractive errors induced by displacement of intraocular lenses within the pseudophakic eye. *Optom Vis Sci* 1989; 66: 146-152.
- [45] Baumeister Bühren J, Kohnen T. Tilt and decentration of spherical and aspheric intraocular lenses: effect on higher-order aberrations. *J Cataract Refract Surg* 2009; 35: 1006-1012.

FIGURE LEGENDS

Figure 1: Box and whisker plot of rotation of the IOL at each of the visits compared to day 1-2 post-implantation. Box indicates standard deviation around mean line and bars denote 95% confidence intervals. n=97.

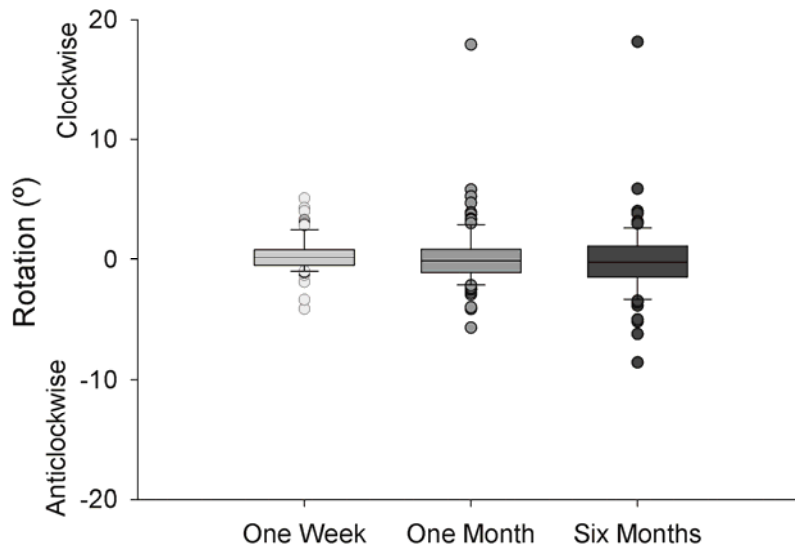


Figure 2: Vector graph showing the change in IOL centration over the course of the 6 months after implantation. Vector length indicates the magnitude of the centration shift and the vector orientation, the direction of the centration shift n=76.

