

University of Nebraska - Lincoln

DigitalCommons@University of Nebraska - Lincoln

Papers in Veterinary and Biomedical Science

Veterinary and Biomedical Sciences,
Department of

6-1-1993

Immunocompromise in Gnotobiotic Pigs Induced by Verotoxin-Producing *Escherichia coli* (O111:NM)

Jane Christopher-Hennings
South Dakota State University

JoAnn A. Willgohs
South Dakota State University, Brookings, South Dakota

David H. Francis
South Dakota State University, david.francis@sdstate.edu

Usha A. K. Raman
South Dakota State University

Rodney A. Moxley
University of Nebraska - Lincoln, rmoxley1@unl.edu

See next page for additional authors

Follow this and additional works at: <https://digitalcommons.unl.edu/vetscipapers>

 Part of the [Veterinary Medicine Commons](#)

Christopher-Hennings, Jane; Willgohs, JoAnn A.; Francis, David H.; Raman, Usha A. K.; Moxley, Rodney A.; and Hurley, David J., "Immunocompromise in Gnotobiotic Pigs Induced by Verotoxin-Producing *Escherichia coli* (O111:NM)" (1993). *Papers in Veterinary and Biomedical Science*. 19.
<https://digitalcommons.unl.edu/vetscipapers/19>

This Article is brought to you for free and open access by the Veterinary and Biomedical Sciences, Department of at DigitalCommons@University of Nebraska - Lincoln. It has been accepted for inclusion in Papers in Veterinary and Biomedical Science by an authorized administrator of DigitalCommons@University of Nebraska - Lincoln.

Authors

Jane Christopher-Hennings, JoAnn A. Willgohs, David H. Francis, Usha A. K. Raman, Rodney A. Moxley, and David J. Hurley

Immunocompromise in Gnotobiotic Pigs Induced by Verotoxin-Producing *Escherichia coli* (O111:NM)†

JANE CHRISTOPHER-HENNINGS,¹ JOANN A. WILLGOHS,¹ DAVID H. FRANCIS,^{1*}
USHA A. K. RAMAN,² RODNEY A. MOXLEY,³ AND DAVID J. HURLEY^{1,2}

Departments of Veterinary Science¹ and Biology/Microbiology,² South Dakota State University, Brookings, South Dakota 57007, and Department of Veterinary Science, University of Nebraska, Lincoln, Nebraska 68583³

Received 8 October 1992/Accepted 22 March 1993

A verotoxin-producing *Escherichia coli* serotype O111:NM strain (strain 10049; verotoxin 1 positive) persistently infected experimentally inoculated gnotobiotic pigs, causing attaching-effacing intestinal lesions and chronic diarrhea. Experiments were performed to determine whether persistent infection might be associated with immunocompromise of the host by this organism. Pigs inoculated with this strain had a significant reduction in peripheral blood lymphocytes and lower antibody titers to sheep erythrocytes compared with control pigs. Compared with pigs given a verotoxin-negative pathogenic strain of the same serotype (O111:NM, strain 2430), pigs inoculated with the verotoxin-positive strain had lower peripheral lymphocyte counts and proliferative responses to concanavalin A, phytohemagglutinin, and pokeweed mitogens. The results of this study suggest that strain 10049 has an immunocompromising effect on gnotobiotic pigs.

Certain strains of *Escherichia coli* frequently referred to as enterohemorrhagic *E. coli* (EHEC) (22) produce verotoxin 1 (VT1) and/or verotoxin 2 (VT2) (Shiga-like toxin I and/or II) and attach to and efface the microvilli from intestinal epithelium. These organisms have been incriminated as a cause of hemorrhagic or nonhemorrhagic colitis in humans and other animals (9, 17, 18). In humans, they may also cause hemolytic uremic syndrome (8) and thrombotic thrombocytopenic purpura (26). Verotoxins are believed to be virulence factors in these syndromes, but their role in disease remains unclear. When applied to HeLa or Vero cells, the toxins are cytolytic (21, 27), and VT1 administered parenterally to experimental animals caused necrosis of the endothelial and muscular layers of blood vessels (7a, 31). However, in one experimental model, the toxins did not appear essential for the generation of diarrhea in these animals (39).

Gnotobiotic pigs are very susceptible to experimental infection by EHEC and have been used by several investigators as a model for studying the pathogenesis of disease caused by these organisms (9, 12, 38, 40, 41). When gnotobiotic pigs are inoculated with verotoxigenic *E. coli* (VTEC), they develop nonbloody diarrhea and, with certain strains, neurologic disease also occurs (10). A description of the pathogenesis of acute illness has been the focus of the previously reported experimental challenge studies. In those studies, animals were observed for 5 days or less after inoculation. In contrast, we maintained gnotobiotic pigs for 3 to 4 weeks following inoculation with a serotype O111:NM VTEC strain, and these animals remained diarrheic throughout. Examination of diarrheic pigs revealed histologic evidence of chronic typhlocolitis and persistent infection of intestinal epithelium by the challenge organism.

Chronic infection caused by *E. coli* serotype O111:NM has also been previously reported (1, 7, 19, 33, 34). Persistent diarrhea is a recognized clinical expression of entero-

pathogenic *E. coli* (EPEC) infection in humans (23). Clinical cases involving EHEC organisms in which patients had diarrhea that persisted up to 2 weeks (19) and was of a duration similar to that of the EPEC cases have been reported (7, 33). However, the potential for various EPEC and EHEC strains to cause diarrhea for this length of time has not been investigated in the gnotobiotic pig model. We have identified an EHEC strain which has the capacity to cause chronic infection in gnotobiotic pigs and is of a serotype (O111:NM) associated with persistent diarrhea. The purpose of our study was to determine whether the chronic infection and colitis observed in gnotobiotic pigs inoculated with VTEC (O111:NM) might be associated with an immunocompromised condition.

MATERIALS AND METHODS

Animals. Gnotobiotic pigs were obtained by closed hysterotomy and maintained in rigid tub isolators similar to those previously described (25).

Bacterial strains. Three *E. coli* strains, 10049, 2430, and G58-1, were used to inoculate gnotobiotic pigs. Strain 10049 (serotype O111:NM) was isolated from a calf with diarrhea. It did not produce pilus antigen K88, K99, or 987P or heat-labile or heat-stable enterotoxins. It was noninvasive in the Sereny test and was probe positive for the EHEC plasmid (as determined by the pCVD 419 probe) (24) and VT1, but not VT2. This information was provided by Bradford A. Kay (Center for Vaccine Development, University of Maryland, Baltimore, Md.). A high level of VT1 is produced by this organism as measured in the HeLa cell assay described by Alison D. O'Brien (Uniformed Services University of the Health Sciences, Bethesda, Md.). This strain was also negative for adherence to HEP-2 cells as reported by Carol Maddox (University of Missouri, Columbia, Mo.) and to Int-407 cells.

E. coli 2430 (serotype O111:NM), a human, non-verotoxin-producing isolate was provided by Nancy Stockbrine (Centers for Disease Control, Atlanta, Ga.). It was probe negative for VT1, VT2, and the EHEC plasmid but was

* Corresponding author.

† Journal series no. 2666 and 10013 of the Agricultural Experiment Station, South Dakota State University, and the Agricultural Research Division, University of Nebraska at Lincoln, respectively.

probe positive for the EPEC adherence factor, as reported by Carol Maddox.

Strain G58-1 (serotype O101:K28:NM) (9), a nonpathogenic porcine isolate, was provided by Werner K. Maas (New York University, New York, N.Y.). It did not adhere to HEp-2 cells and was negative by gene probe for VT1, VT2, and the EHEC plasmid. All of the bacterial strains were maintained frozen on porous beads (Protect; Pro-Lab, Inc., Round Rock, Tex.) at -70°C , until use.

Bacterial inoculation. Bacterial strains were cultured on 5% sheep blood (heart infusion) agar (Difco, Detroit, Mich.) for 18 to 24 h, transferred to tryptic soy broth (Difco), and cultivated overnight at 37°C (to approximately 10^9 CFU/ml). At 24 h of age, pigs were given orally 3 ml of the culture suspension or 3 ml of uninoculated broth. Multiple litters of pigs were used in most experiments, and pigs within litters were divided between principal and control groups.

Blood collection. Once weekly, 10 ml of peripheral blood from the anterior vena cava was collected in heparinized tubes for lymphocyte counts and mitogenesis assays. Serum for the analysis of anti-sheep erythrocyte (SRBC) titers was collected when pigs were 4 weeks of age.

Clinical evaluation and postmortem examination. Pigs were evaluated three times daily for anorexia, diarrhea, or lethargy. Pigs were euthanized at 3 to 4 weeks of age. Necropsy examination included evaluation for gross lesions and collection of tissue samples from the stomach, duodenum, jejunum, ileum, cecum, spiral colon (two locations), rectum, liver, lung, spleen, and thymus for histologic evaluation. Tissue samples for histologic examination were fixed in 10% neutral buffered formalin, processed by routine methods, paraffin embedded, sectioned into 6- μm pieces, and stained with hematoxylin and eosin. Fecal samples were collected from the colon for bacteriologic culture to confirm challenge inoculation and to test for bacterial contamination. Bacterial isolates were evaluated by a cytotoxicity assay for the presence or absence of verotoxin (11).

Total lymphocyte counts. Total peripheral leukocyte counts were determined with an automated cell counter (model MHR; Coulter Electronics, Inc., Hialeah, Fla.), and differential counts were determined microscopically on Wright-stained blood smears (Hema-Quik; Biochemical Sciences, Inc. Bridgeport, N.J.). The total lymphocyte count was calculated by multiplying the percentage of lymphocytes by the total leukocyte count.

Immunization protocol. To determine their ability to mount an immune response, the pigs were injected with 1 ml of a 10% solution of SRBCs in sterile phosphate-buffered saline (PBS; pH 7.4). The injection was given subcutaneously at 3 days postinoculation and again 2 weeks later.

Anti-SRBC titers. Serum was analyzed for antibodies to SRBCs via a complement-mediated hemolysis test (29). SRBCs were suspended in citrate buffer, washed twice, and then resuspended to 1% (vol/vol) in PBS. Porcine serum was heat inactivated for 30 min at 56°C and serially diluted in twofold increments after heat inactivation. Fifty microliters of a 1:10 dilution of lyophilized guinea pig complement (GIBCO, Grand Island, N.Y.) was added to the serially diluted porcine serum along with 0.1 ml of the 1% SRBC solution. Two controls per serum sample, one with serum plus SRBCs but no complement and one with complement plus SRBCs but no serum, were included. All mixtures were incubated at 37°C for 1 h, and the titer was determined visually as the last serum dilution in which complete SRBC lysis occurred.

Mitogen assays. Peripheral blood was collected in heparin

from each pig, diluted 1:5 in Ca^{2+} - Mg^{2+} -free PBS, layered onto Histopaque 1077 (Sigma Chemical Co., St. Louis, Mo.), and centrifuged at $650 \times g$ for 25 min. Mononuclear cells were collected from the buffer-Histopaque interface, washed three times in PBS containing a 1:100 dilution of preservative-free heparin, and suspended at 3×10^6 cells per ml in RPMI-1640 medium (Sigma) with 10% fetal bovine serum. Concanavalin A, phytohemagglutinin, pokeweed mitogen, and lipopolysaccharide were diluted in RPMI-1640 medium for final concentrations of 1, 1, 5, and 16 $\mu\text{g}/\text{ml}$, respectively. The cell suspension was then mixed with an equal volume of each mitogen and plated in triplicate on a 96-well microtiter plate (Corning, Corning, N.Y.). Lymphocytes were incubated at 37°C with concanavalin A, phytohemagglutinin, and pokeweed mitogen for 48 h or with lipopolysaccharide for 72 h. Tritiated thymidine (ICN, Irvine, Calif.) at 0.2 μCi per well was added to each well 4 h prior to the end of incubation. Incorporation of [^3H]thymidine was determined in a scintillation counter (Beckman, Arlington Heights, Ill.) after cells were harvested on filter paper (Brandel, Gaithersburg, Md.). Each filter disk was placed in 3 ml of scintillation fluid (Cyto-Scint; ICN) in 7-ml vials. Specific incorporation, reported for our study, was determined by the average counts per minute (cpm) for the sample (equal volume of each mitogen mixed with equal volume of lymphocytes) minus the average counts per minute for the control sample (equal volumes of RPMI-1640 medium mixed with equal volumes of lymphocytes).

Statistical analysis. A maximum-likelihood analysis of variance test (35) was used as a nonparametric statistical measure when infected and control samples were compared. Statistical significance is reported throughout the text and in the figures at the $P \leq 0.05$ level of confidence. All values reported in the text and figures are means \pm the standard errors of the means (SEM).

RESULTS

Clinical signs and postmortem examination. Surviving pigs inoculated with strain 10049 had persistent diarrhea and anorexia associated with chronic typhlocolitis. Twenty-three (85%) of 27 strain 10049-inoculated pigs had diarrhea which persisted until the pigs were euthanized at 3 to 4 weeks postinoculation. The other four pigs died 5 days after inoculation, before the onset of diarrhea. Of the strain 2430-inoculated pigs, seven (78%) of nine developed transient diarrhea, and three were anorexic for only a couple of days. Five (38%) of 13 of the uninoculated control pigs developed transient diarrhea, but none exhibited depression or anorexia.

Histopathologic examination of the large intestines of nine pigs inoculated with strain 10049 revealed attaching-effacing bacterial colonization of the luminal and crypt epithelial surfaces in seven (78%), loss of crypt epithelium and fibrosis in the mucosa or submucosa in six (67%), and neutrophilic inflammation of the mucosal surfaces, chronic inflammation of the laminae propriae and submucosae, and loss of lymphoglandular complexes in seven (78%). Histologic examination of the lymphoid tissues revealed atrophy of the periarterial lymphatic sheaths of the spleens in six (67%) of nine pigs. Two pigs lacking attaching-effacing lesions also did not demonstrate chronic colitis or lymphoid depletion of the lymphoglandular complexes and periarterial lymphatic sheaths. No histopathologic lesions were seen in pigs inoculated with strain 2430 ($n = 11$) or G58-1 ($n = 16$) or in the uninoculated controls ($n = 8$). Thymic tissues of pigs in all

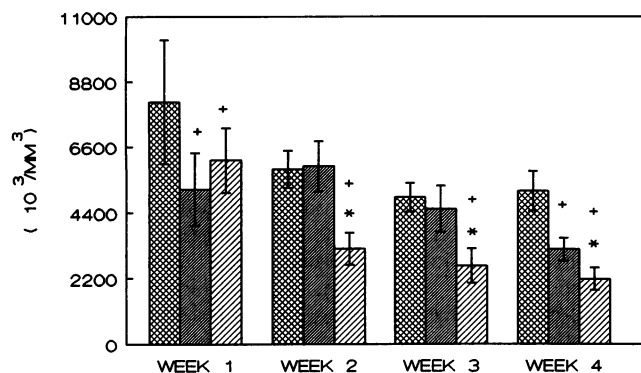


FIG. 1. The absolute lymphocyte counts for uninoculated pigs and pigs inoculated with *E. coli* 2430 or 10049. The number of pigs tested were 13, 6, and 20 (week 1); 13, 6, and 15 (week 2); 11, 4, and 14 (week 3); and 3, 4, and 5 (week 4) for uninoculated controls (□), strain 2430-inoculated pigs (▨), and strain 10049-inoculated pigs (■), respectively. Significant different ($P \leq 0.05$) from results for uninoculated controls and for strain 2430-inoculated pigs are indicated by + and *, respectively.

treatment groups appeared normal by microscopic examination.

Loosely adherent bacteria were seen in the large intestines of pigs inoculated with strain G58-1, 2430, or 10049 and occasionally in those of the uninoculated controls. Results of bacterial culture and serotyping analysis confirmed the presence of serotype O111:NM in pigs inoculated with strain 10049 or 2430 and serotype O101:NM in pigs inoculated with strain G58-1. Verotoxin analysis indicated that isolates from pigs inoculated with strain 10049 produced verotoxin in large amounts (titer, >640), whereas bacteria from pigs in the other treatment groups did not produce verotoxin. Low numbers of *Bacillus* sp. contaminants were cultured for all treatment groups. However, the majority of *Bacillus* spp. have little or no pathogenic potential and are rarely associated with disease in humans or lower animals (37).

Total lymphocyte count. Changes in the distribution of leukocytes have been associated with reduced immune competence (2, 15). Therefore, peripheral blood was examined for the total leukocyte count and the percentage of lymphocytes. Pigs inoculated with strain 10049 had a significantly decreased absolute mean lymphocyte count compared with that of uninoculated controls for weeks 1 to 4 postinoculation and that of strain 2430-inoculated pigs for weeks 2 to 4 postinoculation (Fig. 1). The mean lymphocyte count for pigs inoculated with strain 10049 at 4 weeks of age only was significantly lower than that for pigs inoculated with strain G58-1 ($P < 0.001$) (data not shown).

Anti-SRBC titers. The antibody response to a complex antigen was determined in each treatment group via an anti-SRBC titer. The geometric mean anti-SRBC titer for pigs inoculated with strain 10049 was significantly lower than that for G58-1-inoculated pigs or uninoculated controls. A trend for a lower geometric mean titer was also observed in pigs inoculated with strain 10049 compared with those given strain 2430 ($P = 0.07$) (Fig. 2). No significant differences were noted in antibody titers between uninoculated controls and pigs given strain 2430 ($P = 0.12$). Uninoculated controls and strain 2430- and 10049-inoculated pigs all had titers significantly lower than those of pigs inoculated with G58-1 (Fig. 2).

Mitogen assays. Reduced functional activity of lympho-

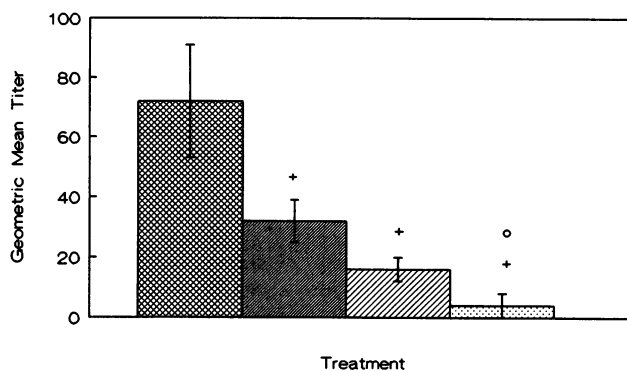


FIG. 2. Antibody titers to SRBCs for uninoculated pigs ($n = 3$) (□) and pigs inoculated with strain G58-1 ($n = 15$) (▨), 10049 ($n = 13$) (■) or 2430 ($n = 7$) (▨) at 4 weeks postinoculation. Significant differences ($P \leq 0.05$) from results for strain G58-1-inoculated pigs and for uninoculated controls are indicated by + and o, respectively.

cytes was indicated by the results of mitogen assays, which indicated that lymphocytes from pigs inoculated with VTEC did not have the same potential to undergo clonal expansion as did those from control pigs or from pigs inoculated with verotoxin-negative *E. coli* (Fig. 3). Concanavalin A, phytohemagglutinin, and pokeweed mitogens induced lymphocyte proliferation in pigs inoculated with strain 10049 that was significantly lower than the proliferation in pigs given strain 2430 or uninoculated pigs throughout the 4 weeks assayed. The mitogenic response to lipopolysaccharide for all treatment groups was too low for comparisons to be made. The capacity of B cells to undergo a proliferative response to lipopolysaccharide may not be well developed in 1- to 4-week-old gnotobiotic pigs. Therefore, it is difficult to make any definite comparisons of B-cell proliferation in response to lipopolysaccharide between these groups.

DISCUSSION

In this report, we provide evidence suggesting that persistent infection by *E. coli* serotype O111:NM (strain 10049) in gnotobiotic pigs may be due, at least in part, to the ability of the organism to compromise the immunoresponsive capacity of its host. Evidence for immunocompromise was found both in histologic changes in lymphoid tissues and in immune function. These changes included severe depletion of periarterial lymphatic sheaths in the spleen, loss of lymphoglandular complexes in the submucosa of the large intestine, low numbers of lymphocytes in peripheral blood, lowered proliferative responses to T-cell mitogens, and decreased antibody production.

Decreased numbers of peripheral lymphocytes may be accounted for by their migration to lymphoid tissue (5) or possibly even lymphatic or vascular leakage as seen in chronic enteric disease (20). Since atrophy of lymphoid tissue was observed on histologic examination, we could also suggest that destruction or decreased production of lymphocytes had occurred. Several studies have indicated that Shiga toxin (which is essentially identical to VT1) (16) in cultured human vascular endothelium (28), purified VT1 injected into rabbits (31) and partially purified VT1 injected into gnotobiotic pigs (7a) can cause vascular damage. Cytolysis of endothelial and other accessory cells would result in a release of cytokines, which in turn could alter lymphocyte

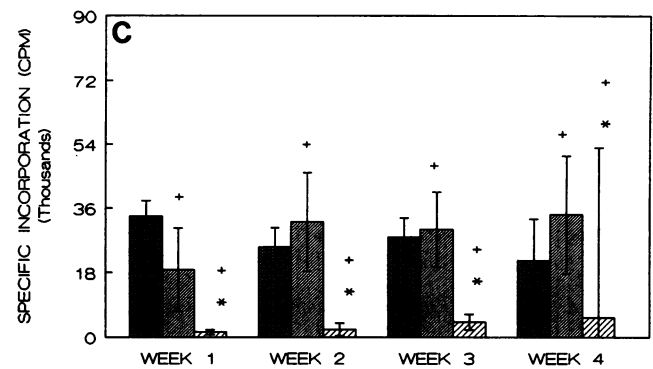
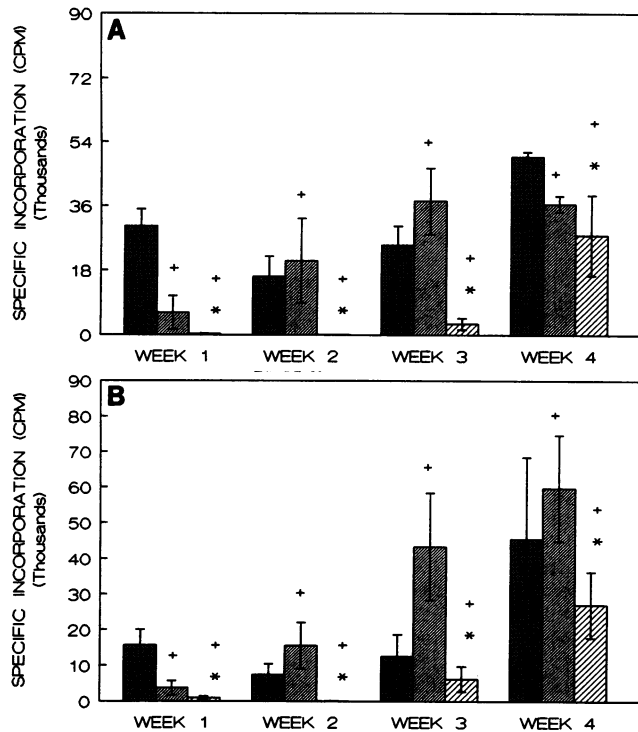


FIG. 3. Lymphocyte response to concanavalin A (A), phytohemagglutinin (B), and pokeweed mitogen (C). The number of pigs tested were 13, 6, and 20 (week 1); 13, 6, and 15 (week 2); 11, 4, and 13 (week 3); and 3, 4, and 5 (week 4) for uninoculated pigs (■) and pigs inoculated with strain 2430 (▨) or 10049 (▧), respectively. Significant differences ($P \leq 0.05$) from results for uninoculated controls and for pigs inoculated with strain 2430 are indicated by + and *, respectively.

number and behavior and account for both the lowered lymphocyte count and mitogenic responses seen in our study (6).

We also observed a significantly lower complement-fixing antibody response to SRBCs in pigs inoculated with VTEC than in controls. Since T-cell function was compromised in pigs inoculated with VTEC, as indicated by low mitogenic responses, the interaction of T-cell cytokines (e.g., interleukin 4, 5, or 6) with B cells may also have been affected and may have caused a decreased antibody response (32). Pigs used as bacterial colonization controls (inoculated with strain G58-1) exhibited an increased capacity to produce anti-SRBC antibody compared with that of uninoculated controls. The interaction between the immune system and the G58-1 organism during the 4 weeks of the experiment appears to have promoted the development of the humoral response in these gnotobiotic pigs. This is consistent with our observations (unpublished observations) that gnotobiotic pigs compared with their conventionally raised counterparts have slower immunological development and are less responsive (13).

The mechanism(s) by which strain 10049 compromises the immune system is not entirely clear. It is tempting to speculate that verotoxin is a contributing factor since the O111:NM verotoxin-negative strain 2430 did not persistently infect gnotobiotic pigs and had a much-less-pronounced suppressive effect (and, in fact, sometimes had a stimulatory effect) on immune function than did the verotoxin-positive strain 10049. Recently, the mechanism by which several organisms cause chronic or persistent infections has been attributed to the action of the cytotoxins which they produce and which are defined as superantigens (14). Some, such as the staphylococcal enterotoxins, have been shown to suppress antibody production in vitro (35) and humoral and cellular immune responses in vivo (30). Several in vitro criteria are required to classify a cytotoxin as a superantigen

(3), and studies are in progress to so characterize VT1 (15a). However, since strain 10049 differs from strain 2430 in more than just the production of verotoxin (strain 10049 is an EHEC while strain 2430 is an EPEC), additional or other virulence factors may be responsible for the observed immunocompromise.

An O157:H7, VT1-positive strain (strain 933D) (36) infects gnotobiotic pigs (10) but does not cause persistent diarrhea or chronic disease in gnotobiotic pigs (26a). This suggests that some factor in addition to or other than verotoxin may contribute to chronic infection. For example, even though both the EHEC serotypes O157:H7 and O111:NM attach to and efface the microvilli of intestinal epithelia in gnotobiotic pigs, the O111:NM serotype causes more severe intestinal lesions and is more invasive and necrotizing than the O157:H7 serotype (26b, 38). Tissue destruction and invasiveness by the O111:NM organism might allow greater access of the verotoxin to lymphatic vessels and the systemic circulation, thereby affecting immune cells. This greater virulence and invasive capacity may contribute to the organism's ability to persistently infect its host. In addition, chronic inflammation seen with strain 10049 could cause the release of products such as tumor necrosis factor, while endotoxin levels may also contribute to the immunosuppression. Therefore, definitive incrimination of verotoxin as a contributor to an immunocompromised condition in the gnotobiotic pig model will require the creation of and challenge with a verotoxin-negative derivative of strain 10049.

ACKNOWLEDGMENTS

This research was supported by USDA CSRS North Central Regional Project no. 62, the USDA Animal Health Formula Fund Section AH-159, USDA NC-IPM grant no. 90-34103-5063, and South Dakota State University Agricultural Experimental Station project no. H-300.

We thank our statistician, Paul Evenson, at South Dakota State University for time and contribution to the manuscript.

REFERENCES

1. Belnap, W. D., and J. J. O'Donnell. 1955. Epidemic gastroenteritis due to *Escherichia coli* O111. *J. Pediatr.* 47:178-193.
2. Brandon, R., M. Gatel, H. Naif, R. Daniel, and M. Lavin. 1989. Observations on blood leucocytes and lymphocyte subsets in

- sheep infected with bovine leukaemia virus: a progressive study. *Vet. Immunol. Immunopathol.* **23**:15–27.
3. Callahan, J. E., A. Herman, J. Kappler, and P. Marrack. 1990. Stimulation of B10.BR T cells with superantigenic staphylococcal toxins. *J. Immunol.* **144**:2473–2479.
 4. Clausen, C. R., and D. L. Christie. 1982. Chronic diarrhea in infants caused by adherent enteropathogenic *Escherichia coli*. *J. Pediatr.* **100**:358–361.
 5. Coleman, R. M., M. F. Lombard, R. E. Sicard, and N. J. Rencricca. 1984. Cells and tissues of the immune system, p. 64. In E. D. Jaffe (ed.), *Fundamental immunology*. Wm. C. Brown, Dubuque, Iowa.
 6. Dinarello, C. A. 1989. Interleukin-1 and its biologically related cytokines. *Adv. Immunol.* **44**:153–205.
 7. Drucker, M. M., A. Polliack, R. Yeivin, and T. G. Sack. 1970. Immunofluorescent demonstration of enteropathogenic *Escherichia coli* in tissues of infants dying with enteritis. *Pediatrics* **46**:855.
 - 7a. Dykstra, S. A., R. A. Moxley, B. H. Janke, E. A. Nelson, and D. H. Francis. *Vet. Pathol.*, in press.
 8. Fong, J. S. C., J. P. de Chadarevian, and B. S. Kaplan. 1982. Hemolytic-uremic syndrome. *Pediatr. Clin. North Am.* **29**:835–856.
 9. Francis, D. H., J. E. Collins, and J. R. Duimstra. 1986. Infection of gnotobiotic pigs with an *Escherichia coli* O157:H7 strain associated with an outbreak of hemorrhagic colitis. *Infect. Immun.* **51**:953–956.
 10. Francis, D. H., R. A. Moxley, and C. Y. Andraos. 1989. Edema disease-like brain lesions in gnotobiotic piglets infected with *Escherichia coli* serotype O157:H7. *Infect. Immun.* **57**:1339–1342.
 11. Gentry, M. K., and J. M. Dalrymple. 1980. Quantitative microtiter cytotoxicity assay for Shigella toxin. *J. Clin. Microbiol.* **12**:361–366.
 12. Hall, G., N. Chanter, and A. Bland. 1988. Comparison in gnotobiotic pigs of lesions caused by verotoxigenic and non-verotoxigenic *Escherichia coli*. *Vet. Pathol.* **25**:205–210.
 13. Hammerberg, C., G. G. Schurig, and D. Ochs. 1989. Immuno-deficiency in young pigs. *Am. J. Vet. Res.* **50**:868–874.
 14. Hoffman, M. 1990. “Superantigens” may shed light on immune puzzle. *Science* **248**:685–686.
 15. Hoxie, J., J. Rackowski, B. Haggarty, and G. Gaulton. 1987. T4 endocytosis and phosphorylation induced by phorbol esters but not by mitogen or HIV infection. *J. Immunol.* **140**:786–795.
 - 15a. Hurley, D. J. Unpublished data.
 16. Jackson, M. P., J. W. Newland, R. K. Holmes, and A. D. O’Brien. 1987. Nucleotide sequence analysis of the structural gene for Shiga-like toxin I by bacteriophage 933J from *Escherichia coli*. *Microb. Pathog.* **2**:147–153.
 17. Janke, B. H., D. H. Francis, J. E. Collins, M. C. Libal, D. H. Zeman, D. D. Johnson, and R. D. Neiger. 1990. Attaching and effacing *Escherichia coli* infection as a cause of diarrhea in young calves. *J. Am. Vet. Med. Assoc.* **196**:897–901.
 18. Karmali, M. A., M. Petric, P. Lim, P. C. Fleming, G. S. Arbus, and H. Lior. 1985. The association between idiopathic hemolytic uremic syndrome and infection by verotoxin-producing *Escherichia coli*. *J. Infect. Dis.* **151**:775–782.
 19. Kelly, J. K., C. H. Pai, I. H. Jadusin, M. L. MacInnis, E. A. Shaffer, and N. B. Hersfield. 1987. The histopathology of rectosigmoid biopsies from adults with bloody diarrhea due to verotoxin-producing *Escherichia coli*. *Am. J. Clin. Pathol.* **88**:78–82.
 20. Kirk, R. W., and S. I. Bistner. 1981. Hematology: interpretation of laboratory findings, p. 672. In R. W. Kirk and S. I. Bistner (ed.), *Handbook of veterinary procedures and emergency treatment*. W. B. Saunders Co., Philadelphia.
 21. Konowalchuk, J., J. I. Speirs, and S. Stavric. 1977. Vero response to a cytotoxin of *Escherichia coli*. *Infect. Immun.* **18**:775–779.
 22. Levine, M. M. 1987. *Escherichia coli* that cause diarrhea: enterotoxigenic, enteropathogenic, enteroinvasive, enterohemorrhagic and enteroadherent. *J. Infect. Dis.* **155**:377–389.
 23. Levine, M. M., and R. Edelman. 1984. Enteropathogenic *Escherichia coli* of classic serotypes associated with diarrhea: epidemiology and pathogenesis. *Epidemiol. Rev.* **6**:31–51.
 24. Levine, M. M., J. Xu, J. B. Kaper, H. Lior, V. Prado, B. Tall, J. Nataro, H. Karch, and K. Wachsmuth. 1987. A DNA probe to identify enterohemorrhagic *Escherichia coli* of O157:H7 and other serotypes that cause hemorrhagic colitis and hemolytic uremic syndrome. *J. Infect. Dis.* **156**:175–182.
 25. Miniats, O. P., and D. Jol. 1978. Gnotobiotic pigs—derivation and rearing. *Can. J. Comp. Med.* **42**:428–437.
 26. Morrison, D. M., D. L. J. Tyrell, and L. P. Jewell. 1985. Colonic biopsy in verotoxin-induced hemorrhagic colitis and thrombotic thrombocytopenic purpura (TTP). *Am. J. Clin. Pathol.* **86**:108–112.
 - 26a. Moxley, R. A., and D. H. Francis. Unpublished observations.
 - 26b. Moxley, R. A., D. H. Francis, H. Karch, and E. D. Erickson. 1987. International Symposium and Workshop on Verocytotoxin (Shiga-like Toxin) Producing *E. coli* (VTEC) Infection, 12 to 15 July 1987, Toronto, Canada, abstr. AMV-3.
 27. O’Brien, A. D., G. D. LaVeck, M. R. Thompson, and S. B. Formal. 1982. Production of Shigella dysenteriae type I-like cytotoxin by *Escherichia coli*. *J. Infect. Dis.* **146**:763–769.
 28. Obrig, T. G., P. J. Del Cecchio, J. E. Brown, T. P. Morgan, B. M. Rowland, T. K. Judge, and S. W. Rothman. 1988. Direct cytotoxic action of Shiga toxin on human vascular endothelial cells. *Infect. Immun.* **56**:2373–2378.
 29. Palmer, D. F. 1989. Complement fixation test, p. 35–47. In N. R. Rose and H. Friedman (ed.), *Manual of clinical immunology*, 2nd ed. American Society for Microbiology, Washington, D.C.
 30. Pinto, M., M. Torten, and S. C. Brinbaum. 1978. Suppression of the in vivo humoral and cellular immune response by staphylococcal enterotoxin. *Transplantation* **25**:320–323.
 31. Richardson, S. E., T. A. Rotman, V. Jay, C. R. Smith, L. E. Becker, M. Petric, N. F. Olivieri, and M. A. Karmali. 1992. Experimental verocytotoxemia in rabbits. *Infect. Immun.* **60**:4154–4167.
 32. Rook, G. 1989. Cell-mediated immune responses, p. 9.9. In I. M. Roitt, J. Brostoff, and D. K. Male (ed.), *Immunology*. Gower Medical Publishers, Inc., London.
 33. Rothbaum, R., A. J. McAdams, R. Gianella, and J. C. Partrin. 1982. A clinicopathologic study of enterocyte-adherent *Escherichia coli*: a cause of protracted diarrhea in infants. *Gastroenterology* **83**:441–454.
 34. SAS Institute Inc. 1988. SAS-STAT user’s guide release 6.03 ed., p. 1028. SAS Institute Inc., Cary, N.C.
 35. Smith, B. J., and H. M. Johnson. 1975. The effects of staphylococcal enterotoxin on the primary in vitro immune response. *J. Immunol.* **115**:575–578.
 36. Stockbrine, N. A., L. R. Marques, J. W. Newland, H. W. Smith, R. K. Holmes, and A. D. O’Brien. 1986. Two toxin-converting phages from *Escherichia coli* O157:H7 strain 933 encode antigenically distinct toxins with similar biologic activities. *Infect. Immun.* **53**:135–140.
 37. Turnbull, P. C. B., and J. M. Kramer. 1991. *Bacillus*, p. 296–303. In A. Balows, W. J. Hausler, Jr., K. L. Herrmann, H. D. Isenberg, and H. J. Shadomy (ed.), *Manual of clinical microbiology*, 5th ed. American Society for Microbiology, Washington, D.C.
 38. Tzipori, S., R. Gibson, and J. Montanaro. 1989. Nature and distribution of mucosal lesions associated with enteropathogenic and enterohemorrhagic *Escherichia coli* in piglets and the role of plasmid-mediated factors. *Infect. Immun.* **57**:1142–1150.
 39. Tzipori, S., H. Karch, K. I. Wachsmuth, R. M. Robins-Brown, A. D. O’Brien, H. Lior, M. L. Cohen, J. Smithers, and M. M. Levine. 1987. Role of a 60-megadalton plasmid and Shiga-like toxins in the pathogenesis of infection caused by enterohemorrhagic *Escherichia coli* O157:H7 in gnotobiotic piglets. *Infect. Immun.* **55**:3117–3125.
 40. Tzipori, S., K. I. Wachsmuth, C. Chapman, R. Birner, J. Brittingham, C. Jackson, and J. Hogg. 1986. The pathogenesis of hemorrhagic colitis caused by *Escherichia coli* O157:H7 in gnotobiotic piglets. *J. Infect. Dis.* **154**:712–716.
 41. Tzipori, S., K. I. Wachsmuth, J. Smithers, and C. Jackson. 1988. Studies in gnotobiotic pigs on non-O157:H7 *Escherichia coli* serotypes isolated from patients with hemorrhagic colitis. *Gastroenterology* **94**:590–597.