

University of Nebraska - Lincoln

DigitalCommons@University of Nebraska - Lincoln

Faculty Publications from the Harold W. Manter
Laboratory of Parasitology

Parasitology, Harold W. Manter Laboratory of

7-1971

On the Ecology and Distribution of *Echinococcus* spp. (Cestoda: Taeniidae), and Characteristics of Their Development in the Intermediate Host. II. Comparative Studies on the Development of Larval *E. multilocularis* Leuckart, 1863, in the Intermediate Host

Masashi Ohbayashi
Hokkaido University

Robert L. Rausch
Arctic Health Research Center, rausch@u.washington.edu

Francis H. Fay
Arctic Health Research Center

Follow this and additional works at: <https://digitalcommons.unl.edu/parasitologyfacpubs>



Part of the [Parasitology Commons](#)

Ohbayashi, Masashi; Rausch, Robert L.; and Fay, Francis H., "On the Ecology and Distribution of *Echinococcus* spp. (Cestoda: Taeniidae), and Characteristics of Their Development in the Intermediate Host. II. Comparative Studies on the Development of Larval *E. multilocularis* Leuckart, 1863, in the Intermediate Host" (1971). *Faculty Publications from the Harold W. Manter Laboratory of Parasitology*. 534.

<https://digitalcommons.unl.edu/parasitologyfacpubs/534>

This Article is brought to you for free and open access by the Parasitology, Harold W. Manter Laboratory of at DigitalCommons@University of Nebraska - Lincoln. It has been accepted for inclusion in Faculty Publications from the Harold W. Manter Laboratory of Parasitology by an authorized administrator of DigitalCommons@University of Nebraska - Lincoln.

This article is a U.S. government work, and is not subject to copyright in the United States.

Jap. J. vet. Res., **19**, *Suppl. No. 3* (1971)

**ON THE ECOLOGY AND DISTRIBUTION OF
ECHINOCOCCUS SPP. (CESTODA: TAENIIDAE), AND
CHARACTERISTICS OF THEIR DEVELOPMENT
IN THE INTERMEDIATE HOST**

**II. COMPARATIVE STUDIES ON THE DEVELOPMENT OF
LARVAL *E. MULTILOCULARIS* LEUCKART, 1863,
IN THE INTERMEDIATE HOST**

Masashi OHBAYASHI*, Robert L. RAUSCH
and Francis H. FAY

*Zoonotic Disease Section, Arctic Health Research Center,
U. S. Department of Health, Education and Welfare,
College, Alaska, U. S. A.*

(Received for publication, December 25, 1970)

SUMMARY

This paper reports the results of a comparative study of the development of the larval *Echinococcus multilocularis* LEUCKART, 1863, and associated tissue reaction in naturally and experimentally infected mammals representing 31 species. The histogenesis of the larval cestode was traced in detail in arvicoline rodents of several species, and interspecific differences were defined.

In arvicoline rodents, the developing larva exhibited host-specific characteristics within about a month after infection was established. The tissue reaction in *Microtus oeconomus* was characterized by the production of a large quantity of detritus around the larva, and by the formation of a thick epithelioid zone. In one subspecies, *M. oeconomus innuitus*, development of the larva was retarded, and the detrital mass was often calcified; in another, *M. oeconomus operarius*, the detritus rarely became calcified and the larva proliferated more rapidly. In *M. pennsylvanicus*, the tissue reaction was minimal, and little detritus was present. The characteristics of the tissue reaction in *M. montebelli* placed it in an intermediate position between the aforementioned species. In *Clethrionomys rutilus*, a thin epithelioid zone and an outer zone of loose collagenous fibers composed the adventitial layer; exogenous budding was retarded in this vole. A minimal tissue reaction occurred in *Lagurus curtatus*. In *Lenmus* spp., larger cysts were characteristic, but areas of small-cystic proliferation were always present. Similar differences in species or subspecies of *Citellus* and *Dicrostonyx* were described.

Lesions of alveolar hydatid disease in man also were studied. The invasive growth of the larval cestode in the human liver involves a process comparable to

* Exchange investigator, U. S. Department of State Exchange Visitor Program, G-V-18, with subvention by the Japanese Government. Present address: Department of Parasitology, Faculty of Veterinary Medicine, Hokkaido University, Sapporo, Japan.

small-cystic proliferation in the natural intermediate hosts. Although the later stages of development of the larval cestode are inhibited in man, exogenous proliferation of vesicles continues for the life of the host. The lesion in man was compared with a morphologically similar formation produced by anomalous development of the larval *E. granulosus* in the bovine liver. The latter is distinguished by the absence of areas of small-cystic proliferation. Non-echinococcal lesions found in the tissues studied, some of which resembled foci caused by the larval *E. multilocularis*, were briefly discussed.

INTRODUCTION

Mammals of many species, especially rodents, are known to serve as the intermediate host of *Echinococcus multilocularis* LEUCKART, 1863. SMYTH and SMYTH (1964) listed the hosts of the larva of this cestode, and in part one of the present series, RAUSCH (1967) reviewed records of naturally infected intermediate hosts. Also with relation to the intermediate host, YAMASHITA et al. (1958, 1963) and OHBAYASHI (1960) recognized that well defined developmental characteristics of the larval cestode and the tissue reaction evoked could be correlated with its occurrence in different species or strains of rodents. WEBSTER and CAMERON (1961) described similar findings. In the present paper, we report results of further studies, on the histogenesis and comparative histopathology of the larval *E. multilocularis* in naturally and experimentally infected animals.

MATERIALS AND METHODS

We studied tissues from 473 animals, listed in table 1. These formed three categories: a) animals naturally infected by the larval *E. multilocularis*, 98 cases; b) those infected experimentally, 333 cases; and c) others, 145 cases. The last group, not considered in table 1, included cases diagnosed macroscopically as *E. multilocularis* infection, but found histologically to have lesions of other types, as well as some cases of *E. multilocularis* infection lacking complete data. In addition, tissues from 42 animals exposed experimentally to *E. multilocularis* infection were studied histologically with negative results.

Most of the specimens were selected from a large series assembled from 1955 through 1969 by the staff of the Zoonotic Disease Section, Arctic Health Research Center; also studied were tissues from animals infected experimentally by one of us (OHBAYASHI) at Hokkaido University.

Three strains of *E. multilocularis* were used to establish infections in experimental animals: one from St. Lawrence Island, in the Bering Sea; one from southern Germany; and one from North Dakota, in the north-central United States. For exposure to infection, a single gravid segment was introduced by a pipette into the stomach of anesthetized animals; the horse and goats were

Ecology and Distribution of Echinococcus spp. II.

3

TABLE 1 *Number of cases studied: Mammals infected naturally or experimentally by the larval Echinococcus multilocularis*

SPECIES	Naturally	INFECTED		TOTAL CASES
		Positive	Negative	
RODENTIA				
Cricetidae				
Arvicolinae				
1. <i>Microtus oeconomus</i>	75	126	15	216
2. <i>M. pennsylvanicus</i>	3	29	—	32
3. <i>M. montebelli</i>	—	21	—	21
4. <i>M. abbreviatus</i>	—	1	—	1
5. <i>M. californicus</i>	—	1	—	1
6. <i>Clethrionomys rutilus</i>	2	81	7	90
7. <i>Ondatra zibethica</i>	—	11	2	13
8-11. <i>Dicrostonyx groenlandicus</i>	—	11	2	13
12. <i>Lemmus sibiricus</i>	1	5	1	7
13. <i>L. lemmus</i>	—	2	—	2
14. <i>Lagurus curtatus</i>	—	4	—	4
Murinae				
15. <i>Mus musculus</i>	—	2	—	2
Cricetinae				
16. <i>Peromyscus maniculatus</i>	1	2	10	13
17. <i>P. truei</i>	—	1	—	1
18. <i>Sigmodon hispidus</i>	—	18	—	18
19. <i>Mesocricetus auratus</i>	—	1	—	1
Sciuridae				
20. <i>Citellus parryi</i>	—	—	4	4
21. <i>C. columbianus</i>	—	3	—	3
22. <i>C. tridecemlineatus</i>	—	5	—	5
23. <i>C. franklini</i>	—	1	—	1
24. <i>Tamiasciurus hudsonicus</i>	—	1	—	1
25. <i>Glaucomys sabrinus</i>	—	1	—	1
— <i>Marmota caligata</i> *	—	—	1	1
LAGOMORPHA				
Leporidae				
26. <i>Oryctolagus cuniculus</i>	—	1	—	1
INSECTIVORA				

SPECIES	INFECTED			TOTAL CASES
	Naturally	Experimentally		
		Positive	Negative	
Soricidae				
27. <i>Sorex jacksoni</i>	4	—	—	4
PERISSODACTYLA				
Equidae				
28. <i>Equus caballus</i>	—	1	—	1
ARTIODACTYLA				
Bovidae				
29. <i>Capra hircus</i>	—	1	—	1
PRIMATES				
Cercopithecidae				
30. <i>Macaca mulatta</i>	—	3	—	3
Hominidae				
31. <i>Homo sapiens</i>	12	—	—	12
Total	98	333	42	473

* Found to be negative following exposure to infection experimentally; this species is not considered in the text.

fed directly. Unless otherwise stated, the experimental animals were laboratory-reared. These animals, before and after exposure, were maintained in quarters approximately 3 miles from the area where infected definitive hosts were kept, which precluded the possibility of accidental infection. A few animals, as noted below, became infected when housed with dogs harboring the adult cestodes.

Tissues were prepared by the paraffin-embedding method and stained routinely with hematoxylin-eosin. Other stains (Azan, PAS, VAN GIESON, WEIGERT) were also used. Serial sections were made of tissues containing lesions of very small size.

For the scientific names of North American rodents, we have mainly followed HALL and KELSON (1959). Recent cytogenetic studies by LIAPUNOVA (1969) have shown that the name *Citellus parryi* (RICHARDSON) is applicable to the holarctic species of ground squirrel formerly designated *C. undulatus* (PALLAS). Findings by LIAPUNOVA and MIROKHANOV (1969) and by FEDYK (1970) demonstrate that the Eurasian *Microtus gregalis* (PALLAS) is specifically distinct from the North American representative of the subgenus *Stenocranius* KASHCHENKO, to which the name *M. miurus* OSGOOD is applicable.

RESULTS

1. Northern vole, *Microtus oeconomus* PALLAS*Naturally infected animals*

Tissues were examined from 132 northern voles (124 from St. Lawrence Island and 8 from the Alaskan mainland) in which infection by *E. multilocularis* had been diagnosed macroscopically or in which lesions possibly attributable to this larval cestode were present.

a. Findings in voles from St. Lawrence Island

Infection by the larval cestode was confirmed histologically in 74 voles, *M. oeconomus innuitus* MERRIAM, from the island (including one animal from nearby Punuk Island). Non-echinococcal lesions (50 cases) are discussed below, in connection with the differential diagnosis of multilocular echinococcosis.

The echinococcal cases were segregated into 4 groups classed in accordance with developmental phase of the larva. Our material included specimens collected in all months of the year excepting January and February (table 2).

TABLE 2 *Seasonal incidence of developmental groups of larval E. multilocularis in natural infections in M. oeconomus innuitus on St. Lawrence Island (Cases examined histologically)*

DEVELOPMENTAL GROUPS	MAR	APR	MAY	JUNE	JULY	AUG	SEPT	OCT	NOV	DEC	TOTAL CASES
I	—	—	1	4	2	2	2	—	1	—	12
II	—	2	—	3	4	1	2	1	2	3	18
III	1	1	6	4	2	—	4	—	1	—	19
IV	—	—	8	3	8	1	1	—	—	4*	25
Total	1	3	15	14	16	4	9	1	4	7	74

* Animals captured on the island, 3 in May and 1 in September, and maintained in the laboratory.

Group I (Early or suppressed development: 12 cases)

The larvae assigned to this group were characteristically embedded in a mass of cellular detritus. The length of time over which the respective developmental stages persist is unknown for the naturally infected animals.

Macroscopic findings After fixation in 10% formalin solution, the foci appeared as discrete, yellowish-gray, slightly convex nodules at the hepatic surface. Only rarely were they deeper within the hepatic tissue. The lesions were spherical to subspherical, 1 to 1.5 mm (rarely less than 1 mm) in diameter. Cystic structure was not macroscopically evident.

Microscopic findings The lesions were characterized histologically by the severe tissue reaction of the host and by the suppressed development of the larval cestode. In a lesion estimated to be not more than 2 weeks old, proliferation of cysts was beginning, and no cuticle had been produced. Exogenous cysts were few to numerous in this group. The thickness of the cuticle ranged usually from 0.002 to 0.005 mm.

The larvae were embedded in a mass of necrotic detritus of degenerated eosinophils and hepatic cells (pl. I, fig. 1). Remains of these elements progressively disappeared, producing a gradually calcifying homogeneous mass which was in turn surrounded by a thick adventitial layer, consisting of an inner zone of epithelioid cells (the epithelioid zone) and an outer zone of granulation tissue (the fibrous zone) (pl. I, fig. 2). The epithelioid zone, demonstrable at a very early stage of development of the focus, consisted of large cells arranged radially and usually syncytially, and numerous giant cells, usually of the LANGHANS type, were present. In the youngest larvae observed, eosinophils had emigrated and accumulated within this zone. In foci situated superficially, the epithelioid zone was found frequently to be interrupted adjacent to the hepatic capsule. The fibrous zone was composed of immature connective tissue at earlier stages of development. Around the periphery of the outer zone was a more or less dense accumulation of rounded histiocytes such as lymphoid cells and plasma cells.

Group II (Invasive or spreading stage: 18 cases)

The larvae had begun to overcome the barrier of host tissue and expand into the surrounding area by means of exogenous proliferation. In the later stages, large cysts contained beginning brood capsules.

Macroscopic findings The lesions measured 1 to 9 mm (usually 4 to 5 mm) in diameter and were of irregular shape; the cysts present were usually less than 1 mm in diameter.

Microscopic findings With the beginning of invasion of the host's tissue, the actively proliferating cysts penetrated the surrounding detritus, often through openings in calcified areas. The thicker layers of cuticle occasionally ruptured, allowing the newly formed cysts to emerge with only a thin covering made up of the inner cuticular lamina. The space between the detritus and the surrounding adventitial layer was often invaded initially by the proliferating cysts (pl. I, fig. 3). Invasion of the hepatic parenchyma evoked a tissue reaction similar to that observed at the earlier stages of development. With continued exogenous proliferation, in some of the larger cysts formation of brood capsules began. Sometimes, as in 3 voles collected in December, vigorous proliferation of small cysts was taking place, but no large cysts were being formed. The cuticle of

the larvae, 0.001 to 0.002 mm thick, was thinnest where the cysts were budding. As size of the cysts increased, the thickness of the epithelioid zone decreased, as did numbers of giant cells. The fibrous zone became thinner but increasingly dense.

Group III (Stage of maturity: 19 cases)

This group of larvae was characterized by the production of protoscolices (pl. I, fig. 4).

Macroscopic findings The smaller foci were as little as 4 mm in diameter, with the majority about 10 mm and more. In some cases, hepatic lobes had been replaced almost entirely by larval tissue. Many large cysts were present. The central cavity of the latter was frequently of large size, with its volume decreasing with increasing thickness of the germinal layer. Both hepatic and pulmonary lesions were present in 3 animals.

Microscopic findings Small-cystic proliferation was observed also in foci when the tissue reaction of the host was severe. However, when such proliferation occurred within already established intercystic connective tissue, which was poorly reactive, necrosis and calcification of the connective tissue were the result. In some cases, a thin zone of calcified adventitial tissue surrounded the cysts. In the more advanced stages, the epithelioid zone disappeared and the large cysts were enclosed only by a thin fibrous layer. The intercystic connective tissue and the adventitial layer were usually not so well developed, but thick, trabecula-like strands were sometimes observed. The cuticle was about 0.005 mm in thickness in larvae more advanced in development. At early stages, both immature and fully developed protoscolices were present, but the latter were comparatively few. Calcareous corpuscles were numerous.

Group IV (Terminal stage: 25 cases)

The numbers of mature protoscolices and calcareous corpuscles had increased, but regressive changes were more in evidence. Both regressive changes and secondary spread of the larvae were characteristic of infections in this group.

Macroscopic findings From one to all of the hepatic lobes were largely replaced by the larval tissue, and were often much enlarged. The unaffected lobes exhibited compensatory hypertrophy. When greatly enlarged, the liver occupied more than half of the abdominal cavity. On the hepatic surface, the lesions usually appeared irregular or nodular. Transected lesions had a rather medullary appearance, lent by the grayish-white, opaque germinal tissue filling the cavities of the cysts. The tissue of both the larval cestode and the host exhibited regressive changes, such as calcification, hemorrhage, and sequestration. Adhesion between hepatic lobes, or between the liver and the diaphragm, were

rarely observed.

Generalized metastasis was observed in nearly all animals. Metastases were found at the splenic hilus, on the gastro-splenic omentum, in the cardiac and pyloric areas of the lesser omentum, in the hepatic portal area, at the anterior and posterior poles of the kidneys, in the dorsal portion of both mesenteries, in the broad ligament of the uterus, and in the pelvic cavity around the uterus and the rectum. In older infections, many nodules or masses, from 1-2 mm to as much as 30 mm in diameter, filled spaces among the abdominal viscera. Free masses were occasionally present in the body cavity. Metastasis to the abdominal wall was noted once.

Microscopic findings The development of the primary focus was well advanced, and regressive changes were much in evidence. The thickness of the cuticle varied from about 0.005, which was usual, to 0.010 mm or more. Small-cystic proliferation was continuing in some areas. Regressive changes included desquamation of the cyst-wall and sometimes an edematous condition and necrobiosis of the germinal layer. Protoscolices became necrobiotic or necrotic, and focal calcification was observed in degenerating tissues of the parasite. The adventitial layer exhibited focal necrosis, often with calcification. The proliferation of small cysts was often accompanied by necrosis and calcification of the connective tissue stroma. Changes observed in protoscolices included metamorphosis leading to formation of daughter-cysts.

The metastatic nodules were characterized by small-cystic proliferation. Interstitial tissue was less abundant in such nodules, and regressive changes, such as necrosis and calcification, were frequently noted. Protoscolices were produced in the metastatic tissue, but they were few compared with the numbers present in the primary tissue; they also more often exhibited regressive changes. Invasion of the renal parenchyma by the larval cestodes was very rare, but the splenic tissue was rather commonly involved. Nearly all of the free nodules in the abdominal cavity were undergoing regressive changes. In one case, spread of the larval cestode by extension from one hepatic lobe to an adjacent lobe was noted. In another, the parasitic tissue extended into a layer of fibrinofibrous reactive tissue on the hepatic surface.

b. Findings in voles from mainland Alaska

Minute hepatic lesions were observed in 8 voles from the mainland. Of these, infection by *E. multilocularis* was confirmed only in a specimen of *M. oeconomus operarius* NELSON, from Hooper Bay. The infected animal, a female, was one of 3 voles trapped on 20-22 February 1957.

The focus was elongate, 1.2×0.6 mm, and included a central mass of uncalci-

fied detritus, containing remnants of eosinophils, surrounded by an adventitial layer about 0.1 mm thick. The larval cestode, embedded in the detritus, consisted of 3 or 4 cysts about 0.100 mm in diameter. The cuticle was very thin and the germinal layer was inactive. Excepting the surface adjacent to the hepatic capsule, the detritus was surrounded by an epithelioid zone largely made up of giant cells. The fibrous zone was poorly developed, with a peripheral accumulation of histiocytes.

Experimentally infected animals

a. Findings in *M. oeconomus inuitus*

Four laboratory-reared voles infected experimentally by the St. Lawrence Island strain of *E. multilocularis* were studied. The original stock of these voles had been captured on the island.

30-day infection (1 case) Five hepatic foci, 1 to 2 mm in diameter, were present, surrounded by a zone of severe tissue reaction in the detritus of which the multilocular larvae were embedded. The cuticle measured up to 0.005 mm thick. The epithelioid zone was interrupted or incomplete in some areas. The fibrous zone, about 0.200 mm thick, included a dense accumulation of histiocytes.

70-day infection (1 case) Three hepatic foci, 2.5 to 4 mm in diameter, were present, surrounded by a thick adventitial layer. The epithelioid zone was well developed, but was interrupted adjacent to the hepatic capsule. The larvae exhibited multilocular vesiculation within a partially calcified mass of detritus. The cuticle was about 0.005 mm thick. In one focus only, the adjacent hepatic tissue had been invaded by exogenous buds.

125-day infection (1 case) A focus 5×4×3 mm protruded from the margin of a hepatic lobe. Multilocular proliferation was taking place in an area surrounded by a fibrous adventitial layer. The cuticle was 0.005 mm thick, and the germinal layer was inactive. Detritus was present. The epithelioid zone was lacking.

130-day infection (1 case) Vigorous proliferation of the larval cestodes had caused hepatomegaly. Proliferation of connective tissue was marked, with calcification and focal necrosis. Complex multilocular proliferation had taken place, and the cuticle varied in thickness. Some large cysts, about 1 mm in diameter, contained a few mature protoscolices.

b. Findings in *M. oeconomus operarius*

The animals were all laboratory-reared, from stock captured near Homer, on the Kenai Peninsula. Adult cestodes, from which infective embryophores were obtained, were reared in experimentally infected dogs; the culture was

derived from cestodes collected from naturally infected arctic foxes, *Alopex lagopus* L., from St. Lawrence Island. Of the 115 voles studied, 104 were infected.

24-hour infection (2 cases) No foci were macroscopically visible. Microscopically, many irregularly shaped foci, about 0.100 mm in diameter, were found, each composed of activated sinusoidal endothelial cells and eosinophils, with subspherical, solid larva, 0.015 to 0.017 mm in diameter. Slight degenerative changes in hepatic cells were noted around each focus.

48-hour infection (1 case) The foci, occasionally visible macroscopically, were irregular in shape, 0.200 to 0.250 mm in size, each composed of a mass of degenerating eosinophils and necrobiotic hepatic cells. Peripherally, activated sinusoidal endothelial cells and eosinophils were observed. No larvae could be identified in sections.

72-hour infection (2 cases) The foci were visible macroscopically. Sections disclosed areas of acute focal necrosis 0.350 to 0.500 mm in diameter, within which necrobiotic hepatic cells remained. Intra- and perifocal accumulations of eosinophils and histiocytes were present, as well as central, small masses of degenerating cells. No larvae were found.

4-day infection (3 cases) The diameter of the foci had increased to 0.5 to 0.6 mm. A mass of degenerating eosinophils and hepatic cells made up the greater part of each focus, in which cystic larvae, about 0.050 mm in diameter, were situated centrally. Some larvae appeared multilocular; others were polymorphic. A thin layer of detritus lay in contact with the larva. Intact eosinophils and histiocytes had accumulated around each focus, and some epithelioid cells were present. A definite zone of necrotic hepatic tissue surrounded the detritus in some foci.

6-day infection (1 case) The foci were spherical to subspherical, 0.5 to 0.7 mm in diameter, and were made up of an extensive area of detritus and an incompletely formed adventitial layer. The centrally situated larvae had begun to bud; in some cases, minute cysts about 0.025 mm in diameter were present in the detritus. Incompletely formed epithelioid zones were usually visible, and giant cells were frequently observed. The epithelioid zone usually was in contact with hepatic cells. In some foci, slight fibrosis and accumulation of histiocytes were observed.

7- and 8-day infections (6 cases) The foci were 0.5 to 1.5 mm in diameter, with incomplete epithelioid and fibrous zones. In one focus, calcification of detritus adjacent to the larva was observed. Dense accumulations of histiocytes

were present peripherally. Exogenous proliferation of the larvae had produced small cysts, up to 0.030 mm in diameter, scattered in the detritus.

10- and 11-day infections (3 cases) The foci ranged from 0.7 to 1.2 mm in diameter. The multilocular larvae were embedded in noncalcified detritus about 0.300 mm in diameter. The well developed epithelioid zone was about 0.100 mm thick. The outer zone of the adventitial layer, about 0.100 mm thick, showed a marked accumulation of eosinophils and histiocytes. Little evidence of fibrosis was noted.

12- to 14-day infections (6 cases) The foci measured 0.5 to 2 mm in diameter, the larger irregular in shape. In some, recently formed detritus had been added to that already existing. The epithelioid zone was well developed (pl. II, fig. 5). In some foci, the larva had produced numerous, minute buds, up to 0.050 mm in diameter. Fibrosis of the outer zone was sometimes evident. Cuticle was present in many cysts of 14-day infections.

15- to 17-day infections (4 cases) Some foci showed a decrease in the volume of the detritus, an effect related to the activity of the epithelioid cells and the proliferation of the larvae. The cuticle was usually found.

19- to 21-day infections (4 cases) Cysts lacking cuticle were rare. Some cysts extended into the epithelioid zone. Epithelioid cells were no longer present around a large cyst, more than 0.400 mm in diameter.

23- to 25-day infections (4 cases) The cuticle, always recognizable, was usually 0.001 to 0.002 mm thick, but rarely more than 0.003 mm. Partial calcification of the detritus was noted in a few foci (pl. II, fig. 6).

27- to 29-day infections (5 cases) The foci were 0.6 to 1.7 mm in diameter. In the larger, exogenous buds were greater in size, but small-cystic proliferation was in progress; in the large cysts the epithelioid zone, which persisted in small, suppressed foci, was less well defined. Calcification of detritus was rarely observed. In the 29-day specimen, a few aggregations of germinal cells were found in one large cyst.

30- to 32-day infections (12 cases) The foci ranged from 1 to 5 mm in diameter, were generally irregular in shape, and the larger contained cysts 1 to 2 mm in diameter. The fibrous zone, about 0.100 mm thick, was surrounded by a dense accumulation of histiocytes. Around some of the larger cysts, epithelioid cells had decreased in number or had disappeared. An epithelioid zone, however, was appearing in areas where new buds were forming. In two cases, a few calcareous corpuscles were present; one focus contained a few protoscolices.

33- to 37-day infections (5 cases) Larger cysts measured from 3 to more than 5 mm in diameter. The epithelioid zone and the perifocal, histiocytic accumulation were rarely present. Most of the cysts contained immature protoscolices. The cuticle was as much as 0.005 mm in thickness. Vigorous production of small cysts, embedding in well developed connective tissue, was characteristic; in some foci, the connective tissue contained areas of necrosis and calcification. Many foci included masses of detritus, parts of which were calcified.

39- and 40-day infections (5 cases) The proportion of larger cysts had increased; protoscolices were relatively few and immature. Static fibrosis was evident in some areas, but active reaction with accumulating leukocytes was noted in other loci.

46- to 51-day infections (3 cases) In the majority of foci, the fibrous zone was thin; if present at all, the epithelioid zone was made up of cells having a reduced amount of cytoplasm and arranged in a syncytial pattern. Early-stage brood capsules were abundant; immature protoscolices and their *Anlagen* were present in larger cysts. The thickness of the germinal layer had increased, and calcareous corpuscles were abundant. The cuticle was usually 0.002 to 0.003 mm thick.

60-day infection (20 cases) Infections were massive in all, and marked hepatomegaly was typical. The large cysts measured from 10 to as much as 17 mm in diameter. In 19 cases, protoscolices were developing; in 14, completely developed protoscolices were found. The thickness of the germinal layer was 0.200 to 0.300 mm. The cuticle was thin, usually 0.001 to 0.002 mm, rarely 0.003 to 0.005 mm. Granulomatous and histiocytic reaction was not marked, except where small-cystic proliferation was taking place. Calcified detritus was noted in 3 cases. The fibrous zone surrounding large cysts was thin, sometimes less than 0.020 mm. The epithelioid zone was scarcely discernible, except for those areas where new cysts were proliferating. In 7 cases, regressive changes in the larval tissue were noted. Where adhesions existed between hepatic lobes, a fibrino-fibrous layer was present, and the proliferating cysts frequently had extended from one lobe to the other.

73- to 78-day infections (4 cases) The foci were about 10 to 20 mm, with cysts 5 to 7 mm, in diameter. Immature and mature protoscolices were present; the germinal layer was not markedly thickened. Areas of continuing exogenous budding were noted in all cases.

90- and 94-day infections (2 cases) Mature protoscolices were abundant. Regressive changes were evident in the larval tissue. The cuticle was about 0.005 mm thick (thinner in newly formed buds). The thickness of the germinal

layer had increased to 0.250 to 0.600 mm.

119- and 122-day infections (4 cases) Mature protoscolices filled the cavities of the cysts. In a 122-day case, the hepatic lesions exhibited central regressive changes, through which the tissues of larva and host had become partially calcified. A pulmonary focus was present in this animal.

168-day infection (1 case) The enlarged liver contained much larval tissue. Numerous protoscolices were present. Local small-cystic proliferation, with extension into necrotic and calcifying tissue, was observed. In some cysts, protoscolices had metamorphosed to daughter-cysts. A mass 12 mm in diameter, composed of typical, proliferating small cysts, was found free in the abdominal cavity.

7-month infection (2 cases) In both, the liver was much enlarged, and many masses of larvae were found in the abdomen. The cavities of the hepatic cysts were filled by germinal tissue containing numerous mature protoscolices and abundant calcareous corpuscles. The cuticle was thin, about 0.002 mm. Many cysts exhibited regressive changes. The intercystic connective tissue was poorly formed. The metastatic masses in the abdomen contained fully developed protoscolices. A pulmonary focus was found in one case.

8-month infection (1 case) The microscopic findings in the liver were similar to those in the two preceding cases, but regressive changes were not apparent.

9-month infection (2 cases) In these only the liver was affected. It measured 70×45×25 mm in one animal. All cysts except the largest were filled by germinal tissue containing abundant calcareous corpuscles and mature protoscolices. The cuticle was 0.005 to 0.030 mm thick. The adventitial layer was thin and fibrous. Regressive changes observed in the larvae included collapse, necrobiosis, necrosis, and calcification. Some protoscolices showed changes indicating metamorphosis to daughter-cysts.

11-month infection (1 case) When transected, the surface of the enlarged liver had the typical medullary appearance. Many metastatic masses, up to 20 mm in diameter, were found among the abdominal viscera and in the left lung. These aggregations were made up of large, rounded cysts filled by germinal tissue. Calcification was rarely observed. One mass free in the body cavity exhibited generalized regressive changes, with calcification.

13-month infection (1 case) Larval tissue was present in the liver and lungs. Microscopic findings were similar to those of the preceding case.

c. Findings in *M. oeconomicus operarius* × *M. oeconomicus innuitus*

Sixteen laboratory-produced intergrades between the two subspecies of *M.*

oeconomus were exposed experimentally to the St. Lawrence Island strain. Four did not become infected.

25-hour infection (2 cases) Microscopically, minute foci, 0.050 to 0.100 mm in diameter, were found, each consisting of activated sinusoidal endothelial cells and, occasionally, eosinophils and hepatic cells. Each focus contained a non-cystic larva about 0.015 mm in diameter.

48-hour infection (3 cases) No lesions were evident macroscopically. The foci were similar to those in the 25-hour cases. The larvae were subspherical and non-cystic, 0.017 to 0.025 mm in diameter.

70-hour infection (2 cases) Minute hepatic lesions were visible macroscopically. These were subspherical, 0.150 to 0.200 mm in diameter, composed of a central mass of eosinophils surrounded by a zone of histiocytes, and some were surrounded by a zone of necrobiosed hepatic cells. The larvae, 0.020 to 0.030 mm in diameter, were unilocular.

118-hour infection (2 cases) The foci, 0.5 to 1 mm in diameter, consisted of a central necrotic area and an outer necrobiotic zone. Both contained hepatic cells, eosinophils, and in the outer zone, histiocytes. Early-stage formation of the epithelioid zone was noted around the area of degenerating cells. Some larvae, up to 0.040 mm in diameter, were unilocular; others were multilocular.

142-hour infection (1 case) The single focus studied was subspherical, about 0.750 mm in diameter. The larva was multilocular, embedded in detritus. The developing epithelioid zone was 0.050 to 0.060 mm thick. No fibrosis was observed, but a thin, perifocal layer of eosinophils and histiocytes was present.

8-month infection (1 case) The liver was massively involved, and metastatic nodules filled the abdominal and pelvic cavities. The cysts were filled by germinal tissue containing numerous, fully developed protoscolices and calcareous corpuscles. The larval tissue exhibited regressive changes; calcification was noted in the larvae and in the reactive tissue of the host. Abscess-like areas were found in the hepatic and pelvic masses, the area in the liver a necrotic mass of larvae showing sequestration.

d. Infection of *M. oeconomus* by the North Dakota strain of *E. multilocularis*

Two laboratory-reared specimens of *M. oeconomus operarius* were infected experimentally with embryophores from a red fox, *Vulpes vulpes* L., which had received larvae from a naturally infected *Peromyscus* from North Dakota. In addition, four female voles received embryophores from an experimentally infected arctic fox (born at the University of Alaska Fur Experimental Farm, Petersburg, Alaska, and kindly provided by Dr. James LEEKLEY).

30-day infection (4 cases) Minute hepatic foci, 0.350 to 0.650 mm in diameter, present in all, contained vesicles 0.120 to 0.300 mm in diameter, with a few exogenous buds. The cuticle was 0.001 to 0.002 mm thick, and the very thin germinal layer was inactive. Detritus was observed only in larger foci. The epithelioid zone, containing some giant cells, was incompletely formed. The fibrous zone, 0.040 to 0.080 mm thick, exhibited peripheral accumulations of histiocytes. Scattered eosinophils were found in some foci.

2-month infection (1 case) Foci 2.5 to 5 mm in diameter were found singly in all hepatic lobes but the right papillary process and the caudate lobe. The larger foci contained cysts 2 to 2.5 mm in diameter. The larvae exhibited large-cystic multivesiculation; the fibrous zone was thin and loose, and the epithelioid zone was lacking. The cuticle was about 0.002 mm thick. Small, mound-like structures representing early-stage brood capsules were observed in large cysts.

18-month infection (1 case) Large cysts were found in the hepatic foci. The cuticle was up to 0.020 mm in thickness. Brood capsules and protoscolices were well established. The adventitial layer was thin and fibrous.

2. Common vole, *Microtus pennsylvanicus* (ORD)

Naturally infected animals

Two naturally infected voles, *M. p. drummondii* (AUDUBON and BACHMAN) were collected on 6 August 1965 (see HNATIUK, 1966) and 13 July 1966 near Saskatoon, Saskatchewan, by Dr. Joseph M. HNATIUK, who kindly made material available.

In sections of the liver from the first vole, the larval cestodes were surrounded by a fibrous zone 0.150 mm thick. Perifocal cellular reaction was essentially lacking. Mature protoscolices and calcareous corpuscles were abundant. The cuticle was 0.002 to 0.005 mm thick.

Microscopic findings in the second vole were similar. However, the fibrous zone (about 0.050 mm) and the germinal layer were thinner.

A third animal was collected in Stutsman County, North Dakota, by Mr. Stephen H. RICHARDS. The much enlarged liver was almost totally involved, with cysts up to 6 mm in diameter visible on the surface. Sections showed aggregations of cysts of various size, with a few immature protoscolices in some of the larger. The cuticle was 0.001 to 0.002 mm thick, and the adventitial layer was thin and fibrous. New buds had evoked an active cellular reaction.

Experimentally infected animals

a. Findings in *M. p. pennsylvanicus* (ORD)

The stock of voles was obtained through the courtesy of the National Insti-

tutes of Health, Bethesda, Maryland. The animals originated in the eastern United States. We studied 26 animals infected with embryophores of *E. multilocularis* of St. Lawrence Island origin. Since the histogenesis of the larval cestode in this species of vole has been described (RAUSCH, 1954), only representative cases are considered here.

20-hour infection (1 case) The liver contained minute foci, 0.050 to 0.140 mm in diameter, within which were intact hepatic cells; the sinusoidal endothelial cells had proliferated and were accompanied by a few neutrophils. The larvae were subspherical and non-cystic, about 0.010 mm in diameter; the oncospherical membrane was clearly visible.

26-hour infection (1 case) The foci were similar in size to the aforementioned, but almost all exhibited focal necrobiosis or necrosis of hepatic cells. The larvae, subspherical and non-cystic, were about 0.015 mm in diameter. Neutrophils had increased in number and were associated with the regressive processes.

48-hour infection (1 case) The well defined foci were 0.150 to 0.200 mm in diameter. The larvae, about 0.020 mm in diameter, were unilocular. The hepatic cells immediately surrounding the larvae had disappeared, and the area had been densely infiltrated by histiocytes. Perifocal activation of the sinusoidal endothelium also was evident.

79-hour infection (1 case) The leukocytes had become few or had disappeared. Some foci were nodular as the result of the dense accumulation of sinusoidal cells and lack of hepatic cells. The larvae were unilocular, 0.030 to 0.040 mm in diameter, and their shape varied from subspherical to elongate, or rarely, irregular.

96-hour infection (1 case) The foci, up to 0.250 mm in diameter, varied in type. Some were nodular, containing dense accumulations of histiocytes; other were made up mainly of necrotic hepatic cells. In the former, the larvae exhibited multilocular vesiculation, and around them, a mass of degenerating eosinophils had accumulated. Epithelioid cells were found in a few foci. In the latter type, the sinusoidal endothelial cells, or histiocytes, were slightly activated, and the larvae were usually unilocular.

6- and 7-day infections (3 cases) As at 96 hours, the foci were of both proliferative and necrotic types, 0.250 to 0.300 mm in diameter, rarely as much as 0.500 mm; they were well defined and spherical. In some, the epithelioid zone was well established; eosinophils were degenerating or not recognizable. Many of the foci were surrounded by a thin fibrous zone.

8-day infection (1 case) The foci, 0.200 to 0.350 mm in diameter, were composed of granulomatous tissue and epithelioid cells; little detritus was visible. The larvae were multilocular, and a few to several scattered cysts, up to 0.025 mm in diameter, were present in the majority of foci.

9-day infection (1 case) The size of the foci had not increased. A thin fibrous zone with a scanty histiocytic accumulation and a thick epithelioid zone were clearly distinguishable. The latter, 0.025 to 0.100 mm thick, was composed of syncytial cells. No detritus was observed. In the aggregations of cysts, one or two were sometimes large, about 0.200 mm in diameter. The cysts were apposed, without intercystic substance.

10- and 12-day infections (2 cases) The spherical foci measured up to 0.400 mm in diameter. The fibrous and epithelioid zones were about 0.025 and 0.050 mm in thickness, respectively. Some of the larger cysts exhibited a very thin and discontinuous layer of granular substance, the developing cuticle.

14-day infection (2 cases) The usually spherical foci measured 0.4 to 1 mm in diameter; in some, more than 100 cysts were visible in a single section, and some aggregations contained no intercystic substance (pl. II, fig. 7). Individual cysts ranged in size from 0.010 to 0.300 mm, with most from 0.050 to 0.100 mm. In the large cysts, initial formation of cuticle was evident, but it was incomplete. The fibrous zone was somewhat indefinite because of intercystic invasion by collagenous fibers. Perifocal accumulations of histiocytes were closely associated with GLISSON'S capsule. Epithelioid cells were not observed.

21-day infection (1 case) The markedly enlarged foci contained cysts 1 to 3 mm in diameter. The adventitial layer was poorly developed, and the epithelioid zone had disappeared. A very thin cuticle, less than 0.001 mm, was found on many larger cysts.

27- and 29-day infections (2 cases) In the majority of spherical foci, inter-cystic connective tissue was little or lacking; the perifocal fibrous zone was very thin, and the cellular reaction was scanty. The foci contained aggregations of cysts of various sizes, some as much as 3 to 5 mm in diameter; other foci were still granulomatous, with numerous minute cysts. The cuticle was about 0.001 mm thick. A few mound-like aggregations of germinal cells could be observed in cysts of the 29-day case.

34-day infection (1 case) The foci were mostly spherical. Large cysts contained scattered brood capsules at an early developmental stage. Calcareous corpuscles were rarely observed. The cuticle was 0.001 to 0.002 mm thick.

44- and 45-day infections (2 cases) The foci contained large cysts, 3 to 4 mm

in diameter, and spherical areas of active multilocular proliferation. Large cysts contained a greater number of brood capsules with immature protoscolices, but the germinal layer was thin and calcareous corpuscles were few.

59- and 68-day infections (2 cases) The hepatic parenchyma was largely replaced by cysts. The foci appeared confluent. In most cysts, the protoscolices were immature, although some were filled with germinal tissue containing numerous mature protoscolices and abundant calcareous corpuscles. The cuticle was 0.002 to 0.003 mm thick.

3½- and 5-month infections (3 cases) Aggregations of rounded cysts, 0.3 to 2.5 mm in diameter, were characteristic. Almost all were filled by germinal tissue with mature protoscolices and calcareous corpuscles. Immature protoscolices were rare. The perifocal fibrous zone was very thin, about 0.010 mm; very little fibrous tissue was visible intercystically. A few cysts were surrounded by a thin epithelioid zone.

7-month infection (1 case) The brood capsules were more numerous and densely aggregated. The germinal tissue among the brood capsules was reduced in quantity. Intercystic fibrous tissue was thicker than in the 5-month case.

b. Findings in *M. p. alcorni* BAKER

The animals were trapped in the vicinity of Anchorage, in a region from which *E. multilocularis* has never been recorded. Four were exposed to infection by the St. Lawrence Island strain and examined 5 months later. Only one was found to be infected.

The right median lobe of the liver had been replaced by the larval tissue; large cysts were 3 to 7 mm in diameter. Microscopically, many solitary or confluent rounded areas, 1 to 5 mm in diameter, were found, these encapsulated by a fibrous zone, 0.015 to 0.250 mm in thickness, each containing one or more cysts. The germinal layer, to 0.500 mm thick, contained abundant mature protoscolices. In areas where the larva was invading peripheral tissue, histiocytic accumulation and epithelioid proliferation were noted. The cuticle was usually about 0.002 mm thick, and rarely as much as 0.007 mm.

c. Infection of *M. pennsylvanicus* by the European strain of *E. multilocularis*

Infective embryophores used were provided by Prof. Hans VOGEL. Two voles, *M. p. pennsylvanicus*, were examined in the present study.

The first, with an 85-day infection, had received embryophores derived from a human case at Nehren, Germany. The hepatic tissue of this vole was largely replaced by cysts 0.500 to 0.700 mm in diameter, each filled by brood capsules containing mature protoscolices. The germinal layer was well developed. The

cuticle was less than 0.005 mm. In some cysts, regressive changes were evident.

The second animal, with a 4-month infection, received embryophores derived from a red fox from the Swabian Alps, Germany. The liver was largely replaced by larval tissue, and metastatic masses were noted in the abdominal organs and lungs. The larval tissue in the liver contained numerous mature protoscolices and calcareous corpuscles. The adventitial layer was thin and fibrous. The cuticle was usually 0.002 to 0.010 mm in thickness. Many loci of degenerated larval tissue with calcification were observed.

3. Japanese meadow vole, *Microtus montebelli montebelli* (MILNE-EDWARDS)

Twenty-one 2-month-old voles were obtained from stock of the Institute for Infectious Diseases, University of Tokyo, and were exposed to infection by the St. Lawrence Island strain. The foci were limited to the liver. Some of these findings have been considered elsewhere (OHBAYASHI, 1960).

24-hour infection (2 cases) Minute foci, 0.100 to 0.170 mm in diameter, were found, each with a central cellular mass and an outer zone of degenerated hepatic cells. The former was made up of activated sinusoidal endothelial cells and regressive neutrophils and eosinophils. The spherical larvae, 0.013 to 0.020 mm in diameter, possessed an oncospherical membrane; some exhibited central vacuolation.

3-day infection (1 case) One focus, 0.130 mm in diameter, was found. The sinusoidal endothelial cells had increased in number around a dense mass of regressive histiocytes and eosinophils. Degenerated hepatic cells were not seen. The larva was unilocular.

5-day infection (1 case) Minute foci, 0.200 to 0.300 mm in diameter, contained unilocular larvae about 0.050 mm in diameter, embedded in detritus of eosinophils. The epithelioid zone was well developed and contained giant cells. Histiocytes had accumulated in the outermost area.

10- and 12-day infections (2 cases) The foci were 0.5 to 1 mm in diameter. Multilocular larvae were embedded in a central mass of detritus, 0.300 to 0.900 mm in diameter (pl. II, fig. 8). Each section of the focus contained up to 80 buds, from 0.020 to 0.100 mm in size. The epithelioid zone included giant cells. The outermost zone consisted of fibroblasts among densely accumulated histiocytes. In the 12-day case, the adventitial layer was being invaded by exogenous buds.

20-day infection (1 case) The foci, 0.7 to 1.2 mm in diameter, contained large cysts up to 0.200 mm in diameter. The central mass of detritus and the epithelioid zone were well developed. The fibrous zone included an accumulation of histiocytes and eosinophils.

26- to 33-day infections (6 cases) The foci were 2 to 5 mm in diameter and frequently confluent. The cuticle was 0.001 to 0.002 mm thick. Exogenous buds,

from 0.015 to 0.200 mm (usually 0.040 to 0.050 mm) in diameter, were arising, numbering more than 100 in each section of the focus. Large cysts, 1 to 4 mm in diameter, were present, surrounded by a thin (about 0.050 mm) adventitial layer. Reduction in size of the mass of detritus had occurred. Aggregations of minute cysts were embedded in granulation tissue.

44-day infection (1 case) The liver was enlarged. Large cysts were 1 to 2 mm (rarely 6 to 7 mm) in diameter. Initial formation of brood capsules and protoscolices was evident. Aggregations of minute cysts were observed. The cuticle was usually less than 0.005 mm, but sometimes as much as 0.010 mm.

53-day infection (1 case) The liver was greatly enlarged and had been almost entirely replaced by larval tissue containing numerous large cysts up to 6 mm in diameter and limited areas of small-cystic proliferation. Some cysts were surrounded by a zone of giant cells. The cuticle was about 0.005 mm (rarely 0.010 mm) thick. The germinal layer was frequently thickened. Brood capsules and protoscolices were at various developmental stages; large cysts contained mature protoscolices.

56-day infection (1 case) Findings were similar to those in the preceding stage, but the adventitial layer was thinner and the protoscolices more numerous. Mature protoscolices were present in large and small cysts.

60-day infection (1 case) Large cysts were 3 to 4.5 mm in diameter. The thickness of the cuticle and that of the germinal layer were 0.005 to 0.015 mm and more than 0.200 mm, respectively. Some cysts showed regressive changes.

77-day infection (1 case) Most cysts were more than 1 mm in diameter. The fibrous zone was thin but dense, and the zone of giant cells was 0.010 to 0.015 mm thick. The cuticle was 0.010 to 0.015 mm thick. The germinal layer, up to 0.300 mm thick, filled the cavities of smaller cysts, and it contained numerous calcareous corpuscles and brood capsules with mature protoscolices. Some cysts showed desquamative changes.

103-day infection (1 case) Findings were similar to those of the 77-day case. Some cysts exhibited degenerative changes, and occasionally, necrosis and calcification of the intercystic tissue had occurred.

140- and 202-day infections (2 cases) The large cysts, 3 to 4 mm in diameter, were surrounded only by a thin fibrous zone. The thickness of the germinal layer attained 0.500 to 0.800 mm in large cysts. The intercystic tissue and the cysts occasionally showed regressive changes.

4. Insular vole, *Microtus abbreviatus fisheri* MERRIAM

One wild-trapped male vole, examined 12 days after experimental exposure

to the St. Lawrence Island strain, was found to be infected. A few minute foci were visible. Sections of one disclosed a spherical mass 0.450 mm in diameter, composed of slightly degenerated eosinophils in which were scattered small numbers of siderocytes. No larval tissue was observed. A fibrous layer was present, however, and a few capillaries were invading the mass of cells. The focus appeared to be in an initial stage of organization. Attempts to infect other *M. abbreviatus* have been unsuccessful.

M. abbreviatus, restricted in distribution to the St. Matthew Islands, appears to be a divergent form of *M. gregalis* PALLAS (= *M. miurus* OSGOOD) (see FEDYK, 1970, and RAUSCH and RAUSCH, 1968). Numerous attempts to infect experimentally specimens of *M. miurus* from the Alaskan mainland have also been unsuccessful.

5. California vole, *Microtus californicus* (PALLAS)

A wild-trapped individual was examined 44 days after exposure to infection by the St. Lawrence Island strain. The larvae present exhibited marked small-cystic proliferation; large cysts, up to 2.5 mm in diameter, were surrounded by a discontinuous epithelioid zone, and a very thin fibrous zone. Small cysts were embedded in granulomatous tissue, which had accumulations of histiocytes and exhibited some regressive changes; some were surrounded by giant cells. The cuticle was about 0.003 mm thick. Larger cysts contained a few early-stage brood capsules.

6. Northern red-backed vole, *Clethrionomys rutilus* PALLAS

Naturally infected animals

Two naturally infected animals, *C. rutilus albiventer* HALL and GILMORE, collected on Sevuokuk Mountain, near Gambell, St. Lawrence Island, in summer, 1953 and on 26 July 1957, were studied.

In the first animal, echinococcal foci were present in the caudate, both median, and the left lateral lobes of the liver. No metastases were found. The fully developed larval cestodes consisted of aggregations of rounded cysts 0.7 to 1 mm (rarely as much as 2 to 4 mm) in diameter. Germinal tissue filled all but the largest cysts, and brood capsules containing mature protoscolices were abundant. Calcareous corpuscles were numerous. The cuticle was usually 0.005 to 0.010 (rarely as much as 0.020) mm thick.

In the second case, a male, all hepatic lobes except the right lateral lobe and the papillary processes contained larval cestodes. Metastatic foci, up to 30 mm in diameter, were found on the abdominal wall, mesentery, omentum, and at the splenic hilus. Microscopically, aggregations of rounded cysts containing

numerous mature protoscolices were found; some cysts were as much as about 2 mm in diameter, but most were 0.200 to 0.500 mm. Trabecula-like connective tissue divided the cysts into groups, although the fibrous zones were usually thin. The cuticle was about 0.010 mm thick. Widespread regressive areas contained collapsed and calcified cysts. The subcutaneous cysts resembled the others of metastatic origin, and contained abundant immature protoscolices.

Experimentally infected animals

All voles were laboratory-reared, from stock (*C. rutilus dawsoni* MERRIAM) captured near Anchorage.

a. Infection of *C. rutilus* by the St. Lawrence Island strain

Of the 77 voles studied, 4 did not contain larvae.

24-hour infection (1 case) In foci of about 0.150 mm in diameter, activated endothelial cells were evident, and small numbers of eosinophils and neutrophils were present. A few hepatic cells exhibited regressive changes. The spherical larvae were noncystic, about 0.015 mm in diameter.

79-hour infection (1 case) The foci were 0.150 to 0.200 mm in diameter. The unilocular larvae were about 0.035 mm in diameter, and surrounded by a very thin (0.010 to 0.025 mm) sinusoidal network, from which hepatic cells had disappeared and in which a few degenerating histiocytes were scattered. In the outer necrobiotic area, a slight increase was noted in numbers of activated sinusoidal endothelial cells.

12-day infection (3 cases) Rounded foci were mostly less than 1 mm in diameter, rarely as much as 2 mm. Little exogenous proliferation had occurred. Smaller foci usually contained single cysts 0.500 to 0.700 mm in diameter. All cysts except buds had a very thin cuticle. The epithelioid zone, up to 0.010 mm thick, was syncytial in structure; the external zone was composed of loose, annular collagenous fibers (pl. III, fig. 9). Peripherally, histiocytic infiltration was minimal or lacking. In one large focus, the cyst was surrounded by many small, exogenous vesicles; no detritus was observed, but there was a marked perifocal accumulation of histiocytes.

16-day infection (2 cases) All hepatic lobes were massively involved. In each focus were several large cysts, 1 to 1.7 mm, and numerous minute cysts, 0.030 to 0.050 mm, in diameter, all with a cuticle 0.001 to 0.003 mm thick. The epithelioid zone was little developed or lacking. A very thin fibrous zone surrounded large cysts. In some areas, minute cysts were embedded in necrotic hepatic tissue or had proliferated in immature granulomatous tissue containing numerous epithelioid cells. The hepatic parenchyma was severely degenerated.

20- to 22-day infections (5 cases) Findings were similar to those of 16-day infections, but multilocular proliferation was further advanced. In moderate or light infections, an epithelioid zone was usually evident, and a fibrous zone, about 0.100 mm thick, was loosely formed.

26- to 29-day infections (7 cases) The size of foci differed according to the number of large cysts (usually 2 to 4 mm in diameter) present. A loose, annular fibrous zone and an epithelioid zone with basophilic syncytial cells were characteristic (pl. III, fig. 10). Numerous minute cysts, each surrounded by an epithelioid zone, were embedded in granulomatous tissue containing a marked accumulation of histiocytes. In heavily infected animals in which the hepatic tissue exhibited degenerative changes, the formation of granulation tissue and the adventitial layer had been disrupted to some degree. Early-stage brood capsules and protoscolices were present in only a few animals.

31- and 32-day infections (2 cases) Findings were similar to those of the preceding stage. A few protoscolices were found in the 31-day case. The cuticle was up to 0.005 mm thick.

38- and 40-day infections (3 cases) The foci measured 10 to 20 mm, and contained cysts up to 5 to 6 mm in diameter. Extensive areas, the central portions of which were degenerated, contained numerous minute cysts. Large cysts existed peripherally or protruded from granulomatous areas. The cuticle was 0.001 to 0.003 mm thick. Dense peripheral accumulations of histiocytes were present. No detritus was noted. Small numbers of immature protoscolices were present in 2 cases.

45- and 46-day infections (3 cases) Findings were similar to those in the 38-40-day infections, although the amount of granulomatous tissue was more limited. All cases had early-stage brood capsules, some with single, immature protoscolices.

51- and 52-day infections (2 cases) The embryophores used in the 51-day case were of St. George Island origin. Infections were very severe. The large cysts were about 2 mm in diameter. The epithelioid zone was little developed or lacking. The cuticle was 0.001 to 0.002 mm thick. A few early-stage brood capsules were found. The hepatic parenchyma exhibited focal necrosis.

55- to 63-day infections (4 cases) Protoscolices were observed more frequently, but most were still immature. In some foci, however, the germinal layer was still inactive. The cuticle was up to 0.005 mm thick. In some areas of calcified granulomatous tissue, small-cystic proliferation was observed.

71- and 77-day infections (2 cases) Fully developed protoscolices and

calcareous corpuscles were abundant. No epithelioid zone was observed, and the fibrous zone around larger cysts was thin or barely discernible. Small, proliferating cysts were embedded in granulomatous tissue. In some cysts, the germinal layer filled the central cavity. The cuticle was up to 0.010 mm thick. The germinal layer in some cysts was necrobiotic or necrotic.

87- to 91-day infections (8 cases) Numbers of mature protoscolices varied from cyst to cyst. In the most advanced case, almost all cysts were filled by germinal tissue. In all but a few foci, aggregations of minute cysts were embedded in regressive granulomatous tissue.

97- to 100-day infections (4 cases) The findings were similar to those in the 87-91-day infections. In general, intercystic granulomatous tissue had decreased in quantity. The fibrous zone around large cysts was often barely distinguishable. The cuticle was usually 0.005 to 0.010 mm thick.

4-month infection (2 cases) The larval cestodes were fully developed. In one vole, numerous small metastatic foci, ranging up to 4 mm in diameter, were present in all lobes of the lungs.

5- to 5½-month infections (3 cases) Two cases had pulmonary and abdominal metastases, respectively. At 5½ months, the larval tissue exhibited regressive changes.

6- to 7-month infections (4 cases) All had pulmonary and abdominal metastases containing abundant mature protoscolices. Calcification of the larval tissue was observed infrequently. Small-cystic proliferation was evident.

8- to 10-month infections (8 cases) The liver in each was much enlarged, often making up more than half the total weight. Almost all cases had thoracic and abdominal metastases. The germinal layer (usually more than 0.700 mm in thickness and with numerous mature protoscolices and calcareous corpuscles) filled the cavities of all but the largest cysts. Areas of regressive connective tissue were present in nearly all foci. The cuticle was usually up to 0.020 mm thick, rarely to 0.030 mm. Some cysts exhibited regressive changes; limited calcification was noted in both connective tissue and in tissue of the larvae.

11- to 12½-month infections (4 cases) Findings in general were similar to those in the preceding 8 cases. Regressive changes in the larvae were frequently observed, with calcification in one case.

15-month infection (2 cases) Active proliferation of metastatic larval masses was marked. Both primary and metastatic foci were similar histologically. Most cysts were filled by germinal tissue containing numerous mature protoscolices and calcareous corpuscles. The cuticle was up to 0.040 mm thick. Limited

necrosis and calcification were noted in the larval tissue.

20- to 21-month infections (3 cases) These voles had heavy infections when they died at an age of about 2 years. Two had malignant tumors (melanoma and hemangiopericytoma, respectively), which might have been the cause of death. The tumors probably were related to the advanced age of the voles, rather than to any carcinogenic effect of the larval cestode. The larval tissue, both hepatic and metastatic, frequently showed calcification, along with widespread regressive changes such as collapse of cysts and necrosis. The cuticle in some areas had attained a thickness of as much as 0.080 mm.

b. Infection of *C. rutilus* by the European strain

30-day infection (1 case) The embryophores were derived from the human case. Active multilocular development of the larval cestodes was evident; cysts were up to 4 mm in diameter, and multilocular vesiculation had occurred in a restricted area. The epithelioid zone was thin or, in some foci, lacking. Germinal cells had increased focally in larger cysts.

The following 3 animals were infected by embryophores of the isolate from the red fox.

3-month infection (1 case) Active exogenous budding was in progress, but the cellular reaction was limited. The cuticle was about 0.005 mm thick. The relatively thin germinal layer contained many mature and immature protoscolices. The adventitial layer was thick and fibrous.

5½-month infection (1 case) All hepatic lobes except the left papillary process had been replaced by larval tissue. All pulmonary lobes contained metastatic foci. Fully developed larvae were present, and exogenous budding was actively continuing. The cuticle was about 0.005 mm thick. The adventitial layer was thin and fibrous.

7½-month infection (1 case) In the larvae, more advanced in development, the cuticle was of greater thickness (0.005 to 0.010 mm). Exogenous buds were very rare, and marked regressive changes had occurred in the larval tissue.

c. Infection of *C. rutilus* by the North Dakota strain

Seven voles were exposed, but 3 did not become infected.

26-day infection (1 case) In the one hepatic focus, 7 mm in diameter, the largest cyst measured 4 mm. The loose, annular fibrous zone was as much as 0.100 mm in thickness, but thinner around larger cysts. The epithelioid zone was present only in areas around exogenous buds.

31-day infection (2 cases) The foci were less than 10 mm, with cysts up to

3 mm, in diameter. A very thin epithelioid zone was occasionally noted. The cuticle was 0.002 to 0.003 mm thick, and the germinal layer was inactive.

81-day infection (1 case) The one focus occupied an entire hepatic lobe, and the largest cysts were 5 to 6 mm in diameter. The fibrous zone was thin or, around some cysts, lacking. The cuticle was about 0.002 mm thick. The germinal layer was thin, but many brood capsules had formed, and they contained both mature and immature protoscolices. Calcareous corpuscles were numerous.

7. Muskrat, *Ondatra zibethica* (LINNAEUS)

The animals were segregated into 3 series: 1) routine oral infection; 2) suprainfection; and 3) uncontrolled infection (animals maintained in a room with infected dogs). The St. Lawrence Island strain was involved.

1) *22-day infection (1 case)* The foci, containing a few cysts, were about 1 mm in diameter. The cuticle was less than 0.004 mm in thickness. The adventitial layer was about 0.050 mm thick, with perifocal histiocytic accumulation and an epithelioid zone. Fibrosis was minimal. A detrital mass of eosinophils was present.

45-day infection (1 case) The larvae had formed numerous small cysts, among which were large cysts, usually about 4 mm but rarely as much as 8 mm in diameter. The walls of large cysts were wavy and folded. Brood capsules were forming. Calcareous corpuscles were very rare. The adventitial layer was about 0.080 mm thick, with a well developed epithelioid zone containing no giant cells.

2) Six animals were exposed twice and examined 90 and 11 days, respectively, after the first and second exposures. Known small numbers of embryophores were given at the first exposure, and infection was confirmed by laparotomy before the second exposure. Five animals exhibited lesions of both infections, and one animal only those of 90-day duration. The foci of the first infection were usually 10 mm to occasionally more than 20 mm in diameter, with large cysts commonly 6 to 8 mm, but sometimes as much as 12 mm, in diameter. The foci of the second infection were less than 1 mm in size.

90-day infection The adventitial layer was thin, 0.010 to 0.020 mm. The epithelioid zone was partially formed. The cuticle was 0.002 to 0.005 mm, rarely as much as 0.020 mm, thick. The relatively thin germinal layer included a small number of mature or immature protoscolices. Calcareous corpuscles were few. Eosinophils had accumulated around some cysts. The cuticle of some cysts had separated into 2 layers, the outer one regressive and embedded in the adventitial layer, but the inner one intact.

11-day infection Foci were about 0.200 mm in diameter. Most larvae were unilocular; some had a few buds. All were embedded in a central mass of eosinophils. Cuticle was not seen. The epithelioid zone was about 0.020 mm thick; histiocytes had accumulated in the very thin fibrous zone.

3) Five male muskrats were maintained near infected dogs. Three animals became infected. The exact duration of infection is unknown.

Early infection (1 case) The hepatic foci, about 1 mm in diameter, contained larvae composed of small numbers of cysts, the latter with undulating walls and embedded in a mass of regressive eosinophils. Both epithelioid and fibrous zones were thick, the former containing giant cells. Perifocal eosinophilic and histiocytic accumulations were present.

Advanced infection (2 cases) The foci were 15 to 30 mm in diameter; large cysts were up to 10 mm in size. Intercystic tissue was reduced in amount. The germinal layer and cuticle were thin, the latter 0.001 to 0.005 mm. Numerous mature protoscolices were present. The fibrous and epithelioid zones were 0.010 to 0.080 mm and 0.010 to 0.015 mm thick, respectively. Regressive changes were frequently noted in the larvae.

8. Varying lemming, *Dicrostonyx groenlandicus rubricatus* (RICHARDSON)

We studied 2 specimens of varying lemming, Point Barrow stock, infected experimentally with the St. Lawrence Island strain (see RAUSCH and SCHILLER, 1956).

20-day infection (1 case) Numerous, rounded hepatic foci, 0.5 to 0.7 mm in diameter, were composed of a thick layer (0.100 to 0.150 mm) of connective tissue surrounding dead larvae 0.200 to 0.450 mm in diameter. The cysts were usually spherical and unilocular, although some had divided into two or three chambers. The cyst-walls were extensively calcified. Light accumulations of histiocytes were present perifocally.

4-month infection (1 case) Many small hepatic foci, about 1.5 mm in diameter, consisted of calcified masses surrounded by fibrous zones; no parasites could be found. The one large focus, 5 mm, contained aggregated cysts 0.7 to 1.7 mm in diameter. The adventitial layer was 0.050 to 0.500 mm thick; necrotic and calcified tissue adjoined. The cyst-wall was very thin; the germinal layer was barely discernible. The cuticle, 0.001 to 0.003 mm thick, was partially calcified.

9. Varying lemming, *Dicrostonyx groenlandicus stevensoni* NELSON

The stock was obtained on Umnak Island. Four animals were studied. One had been exposed to embryophores obtained from an arctic fox from Wales, on the Seward Peninsula; the other infections involved the St. Lawrence Island

strain.

3-month infection (1 case: isolate from Wales) The much enlarged liver contained larvae composed of numerous minute cysts and many large ones up to about 10 mm in diameter. The fibrous zone was thin, less than 0.050 mm, and in some hardly discernible. The germinal layer contained numerous calcareous corpuscles and immature protoscolices. The cuticle was about 0.005 mm thick. The minute cysts in regressive fibrous areas were 0.020 to 0.250 mm in diameter; their cuticles were very thin, and their germinal layers were inactive.

100-day infection (1 case) The largest cyst was 20 mm in diameter. Aggregations of small cysts were embedded in fibrous tissue. In the large cysts, the germinal layer was thin, but contained mature and immature protoscolices. Calcareous corpuscles were numerous. The cuticle was up to 0.020 mm thick.

4-month infection (1 case) The entire animal weighed 65.9 g, and its liver, 28.7 g. Large cysts, more than 10 mm in diameter, contained abundant mature protoscolices and many calcareous corpuscles. The fibrous zone was about 0.150 mm thick. The central portions of the foci exhibited regressive changes without calcification.

9½-month infection (1 case) The animal weighed 104.4 g. The liver, 80.2 g, was massively involved, with large cysts about 20 mm in diameter; their germinal layers were very thick and contained abundant mature protoscolices and calcareous corpuscles. The cuticle measured as much as 0.040 mm. The comparatively thin adventitial layer was fibrous. Abdominal and pulmonary metastases were present, and the splenic parenchyma also was invaded by the larval tissue.

10. Varying lemming, *Dicrostonyx groenlandicus richardsoni* MERRIAM

Four animals, the stock of which was obtained at Churchill, Manitoba (Hudson Bay), Canada, and made available by Dr. T. W. M. CAMERON, were exposed to embryophores of St. Lawrence Island origin. Two did not become infected.

14-day infection (1 case) Minute nodular foci, less than 1 mm in diameter, were found in the liver. In sections, each rounded focus was about 0.200 mm in diameter, and made up of immature granulation tissue with slight, histiocytic infiltration. Centrally, minute, irregular masses of detritus were present. The foci were considered to have become organized.

90-day infection (1 case) A single hepatic focus, 2.5 mm in diameter, was found, composed of granulation tissue with peripheral histiocytic accumulation. Extensive central necrosis was noted. Cysts, of which the largest was 0.300 mm in diameter, were scattered within the focus. Almost all larger cysts were

surrounded by a calcified layer. The cuticle and the inactive germinal layer were extremely thin.

11. Varying lemming, *Dicrostonyx groenlandicus nelsoni* MERRIAM

Three animals, the stock of which was obtained at Nome (Seward Peninsula) through the courtesy of Mr. J. J. BURNS, were exposed to the St. Lawrence Island strain.

90-day infection (3 cases) Well developed larvae, with abundant mature protoscolices and calcareous corpuscles, were found in the liver. The large cysts were 3 to 6 mm in diameter. In cysts from one animal, the germinal layer was very thick, and the cuticle measured about 0.005 mm. The adventitial layer was thin and fibrous. No regressive changes were noted. In the other 2 animals, areas with small-cystic proliferation were found; in these cysts, the germinal layer was thinner.

12. Brown lemming, *Lemmus sibiricus* KERR

Naturally infected animals

One naturally infected lemming, *L. sibiricus nigripes* (TRUE), was obtained on St. George Island (Pribilof Islands). It contained a multilocular hepatic focus 13×8×6 mm, in which the largest cyst was 4 mm in diameter. Surrounding the focus was a broad zone of regressive connective tissue, with a dense accumulation of histiocytes; within the lesion were numerous minute cysts, usually 0.020 to 0.050 mm in diameter. Multiple foci of calcification were present. The larger cysts were surrounded by a fibrous layer 0.100 to 0.400 mm thick. Detritus present was partially calcified. The cuticle was up to 0.020 mm thick. The germinal layer was thin, and mature protoscolices were locally abundant.

Experimentally infected animals

Five specimens (original stock from Point Barrow) infected by the St. Lawrence Island strain were studied. (Lesions were not found in a lemming which died 4 days after receiving embryophores of North Dakota origin.)

38-day infection (1 case) The hepatic foci contained large cysts, up to 7 mm in diameter. The fibrous zone was 0.100 to 0.200 mm thick, with or without histiocytic accumulations. The cuticle was 0.003 to 0.005 mm in thickness. In these large cysts, immature brood capsules were scattered in small numbers, but the germinal layer was thin.

78-day infection (1 case) The irregularly shaped foci contained large, spherical cysts 2 to 3 mm in diameter. Small cysts were less than 1 mm in diameter. The fibrous zone was 0.020 to 0.100 mm thick, with focal accumulations

of histiocytes and lymphocytes. The cuticle measured 0.010 mm or more. The germinal layer, up to 0.300 mm thick, contained abundant mature protoscolices. Protoscolices were present also in small cysts.

128-day infection (1 case) The single hepatic focus, 12×9×8 mm, was made up of several large cysts 6 to 7 mm in diameter. Findings were similar to those of the 78-day infection. The fibrous zone was 0.050 to 0.100 mm thick. Mature protoscolices were abundant; the germinal layer measured about 0.200 mm.

137-day infection (1 case) The liver contained large cysts up to 5 mm in diameter; small cysts were rare. The fibrous zone was about 0.100 mm, with accumulations of histiocytes and lymphocytes. Calcified areas were noted. The cuticle and germinal layer were about 0.010 and 0.300 mm thick, respectively. Mature protoscolices were numerous.

7-month infection (1 case) The hepatic lesion contained many large cysts about 5 mm in diameter. Small cysts were very rare. The fibrous zone was less than 0.100 mm, and cellular accumulations were slight. The cuticle was 0.010 to 0.015 mm thick, and the germinal layer, 0.500 mm. Calcareous corpuscles were numerous, and brood capsules contained mature protoscolices.

13. Scandinavian lemming, *Lemmus lemmus* LINNAEUS

Two animals were studied, of stock obtained from Norway and made available to us by Dr. E. C. VIERECK.

86-day infection (1 case: St. Lawrence Island strain) A hepatic focus 17×12×10 mm contained 6 large cysts, 5 to 10 mm in diameter, with many small cysts 0.150 to 0.400 mm in diameter. The focus was surrounded by a zone composed of dense, annular collagenous fibers, 0.025 to 0.150 mm thick, around which were aggregations of histiocytes and lymphocytes. The germinal layer, 0.250 to 0.400 mm thick, had produced mature protoscolices. The cuticle was about 0.005 mm thick.

34-day infection (1 case: North Dakota strain) The liver contained a focus with large cysts up to 6 mm in diameter. The fibrous zone was up to 0.200 mm thick. The epithelioid zone, up to 0.025 mm, contained scattered eosinophils. The cuticle was about 0.003 mm thick, and the germinal layer was inactive.

14. Sagebrush vole, *Lagurus curtatus* (COPE)

The animals, trapped in Washington, were provided by Dr. M. L. JOHNSON. Four infected by the St. Lawrence Island strain were studied; all were heavily infected.

14- and 15-day infections (3 cases) The massively involved liver had a spongy appearance. The foci, 0.200 to 0.500 mm in diameter, contained larvae

which had undergone marked small-cystic proliferation (pl. III, fig. 11). Most cysts measured 0.020 to 0.040 mm, but some were as large as 0.200 mm. The inner portion of the thin fibrous zone contained regressive eosinophils. The hepatic parenchyma exhibited multiple necrotic foci. In the 15-day infection, the cuticle could be distinguished. No cellular reaction was observed around some of the buds invading the surrounding hepatic parenchyma. The hepatic reaction included fibrinous perihepatitis, and the cysts had passed from one to the other of two adherent lobes.

3-month infection (1 case) More advanced and vigorous small-cystic proliferation was evident; cysts larger than 2 mm were very rare. Within the liver were multiple, degenerated areas in which small cysts were embedded. Little tissue reaction was observed. A few immature protoscolices were noted in larger cysts. The cuticle was up to 0.003 mm thick. A fibrinous inflammatory layer on the hepatic surface also had been invaded by the proliferating larvae. Calcification was rarely noted in the necrotic intercystic tissue. In many areas, degenerative changes were observed in the cysts.

15. House mouse, *Mus musculus* LINNAEUS

We studied two wild house mice, captured in Anchorage, and exposed to infection by the St. Lawrence Island strain.

19-day infection Two foci 0.7 and 0.9 mm in diameter were found in the left lateral lobe of the liver; in each, the centrally situated larva, with a few exogenous buds, was embedded in a detrital mass. The cuticle was very thin. The epithelioid zone contained a few giant cells. The fibrous zone was 0.100 to 0.200 mm in thickness, with a diffuse infiltration of histiocytes.

51-day infection A single focus, about 1 mm in diameter, was present in the caudate lobe of the liver. A multilocular larva consisting of a few cysts was embedded in granulomatous tissue; intense infiltration of lymphocytes and histiocytes had taken place peripherally. No epithelioid zone was noted. The cuticle was less than 0.002 mm thick. Some necrosis had occurred in tissue near the larva.

16. Deer mouse, *Peromyscus maniculatus* (WAGNER)

Naturally infected animal

A female *P. maniculatus bairdii* (HOY and KENNICOTT) was collected on 23 August 1965 in Wells County, North Dakota, by Mr. S. H. RICHARDS. In the liver, one subspherical focus, 7 mm in diameter, was found to contain several large cysts, 3 to 5 mm in diameter, and surrounded by a thin fibrous zone, 0.015 to 0.045 mm thick, without histiocytic accumulation. The germinal layer, 0.150

to 0.300 mm thick, contained mature portoscolices and calcareous corpuscles. The cuticle was 0.010 to 0.015 mm thick. In one area, numerous minute cysts, 0.015 to 0.050 mm in diameter, formed an aggregation in poorly developed fibrous tissue.

Experimentally infected animals

RAUSCH and SCHILLER (1956) obtained negative results in attempts to infect 6 specimens of *P. maniculatus artemisiae* (RHOADS), using the St. Lawrence Island strain. Of one series of 5 specimens of *P. maniculatus bairdii* exposed later to this strain, one became infected.

31-day infection A few minute, nodular foci were present in the liver, all well defined and surrounded by a thick (about 0.170 mm) adventitial layer. The fibrous zone was immature, with abundant histiocytes; the epithelioid zone was composed of syncytial cells. A zone of eosinophils and histiocytes surrounded each cyst. The larvae had few exogenous buds, and the cuticle was not evident.

One specimen of *P. maniculatus bairdii* infected by the North Dakota strain was also studied.

113-day infection Large cysts, up to 8 mm in diameter, were present in the liver. The adventitial layer was thin, 0.040 to 0.050 mm, but fibrous; histiocytic accumulation was rarely seen. The epithelioid zone was very thin. Masses of detritus were occasionally found adhered to the cuticle, which was about 0.003 mm thick. Small numbers of early-stage brood capsules were present, but the germinal layer was thin and calcareous corpuscles were not seen.

17. Piñon mouse, *Peromyscus truei* SHUFELDT

44-day infection (1 case) The animal had been infected experimentally by the St. Lawrence Island strain (RAUSCH and SCHILLER, 1956). In the hepatic parenchyma, well developed cysts up to 2.5 mm in diameter were enclosed by a thin fibrous zone, in which perifocal accumulation of histiocytes was rare. The cuticle was about 0.003 mm thick. The germinal layer was slightly thickened. A small number of brood capsules in an early developmental stage was noted, and some immature protoscolices were found. No small cysts were found in sections.

18. Cotton rat, *Sigmodon hispidus* SAY and ORD

Eighteen animals, the stock of which was obtained from the Institute of Infectious Diseases, University of Tokyo, were infected by the St. Lawrence Island strain. Some aspects of this work were reported previously by OHBAYASHI (1960).

24-hour infection (1 case) Minute foci, 0.130 to 0.170 mm in diameter, consisted of sinusoidal endothelial cells and a few degenerated hepatic cells. The larva, spherical and 0.013 to 0.020 mm in diameter, was situated centrally and possessed an oncospherical membrane.

3-day infection (1 case) The foci, about 0.200 mm in diameter, consisted of a central mass of histiocytes and necrosed hepatic cells, and an outer zone of activated sinusoidal endothelial cells. The former contained the larva. About a third of the larvae, 0.020 to 0.040 mm in diameter, showed unilocular vesiculation.

5-day infection (1 case) The foci, 0.200 to 0.350 mm in diameter, could be seen macroscopically. The central area containing the larva was composed of epithelioid cells; the outer zone was made up of degenerated hepatic cells and rounded sinusoidal endothelial cells. The larvae had a small number of exogenous buds. The oncospherical membrane was no longer present.

10-day infection (1 case) The foci, 0.400 to 0.850 mm in diameter, contained larvae composed of many cysts (10 to 40 in each section), 0.010 to 0.170 mm in diameter (pl. IV, fig. 14). The cysts were closely grouped, with degenerated cells interposed. Numbers of exogenous buds had invaded surrounding tissue beyond the adventitial layer, which was up to 0.090 mm thick.

14-day infection (1 case) The foci, 0.8 to 0.9 mm in diameter, included abundant cysts from about 0.020 to 0.400 mm in diameter. Pericystic cellular and fibrous reactions were very slight. The surrounding hepatic cells exhibited slight degenerative changes, with accumulation of eosinophils.

18-day infection (1 case) The foci were 1 to 2.5 mm in diameter; the number of cysts had increased, with about 100 in each section. The poorly developed adventitial layer was about 0.010 mm thick (pl. IV, fig. 15). At 18 days, cuticle was beginning to appear on some of the cysts.

20-day infection (1 case) The foci were spherical, 2 to 5 mm in diameter. The adventitial layer, 0.020 to 0.045 mm thick, was well established. The focus contained aggregations of numerous cysts, the smallest about 0.010 mm and the large ones to 4 mm in diameter. The cuticle was up to 0.005 mm thick. In large cysts, the germinal layer, 0.005 to 0.010 mm thick, contained calcareous corpuscles and brood capsules in an early developmental stage.

30- and 36-day infections (2 cases) The spherical foci, 4 to 9 mm in diameter, contained large cysts up to 6 mm. The hepatic parenchyma remained in limited amounts among the foci. The adventitial layer was about 0.100 mm thick; the epithelioid zone was present. Intercystic connective tissue was frequently degenerated. The cuticle was up to 0.007 mm thick. The germinal layer contained a small number of calcareous corpuscles. Many brood capsules, with immature

protoscolices, had formed. Regressive changes were observed in large cysts.

In most animals infected 48 days and longer, metastatic foci were found on the gastro-splenic omentum and the greater omentum. The weight of the liver sometimes was as much as $\frac{2}{3}$ of the total body-weight; the organ was almost wholly replaced by larval tissue, only islet-like portions of hepatic tissue remaining. In infections of more than 2 months' duration, the cavities of regressive large cysts occasionally contained membranous and trabecular structures, and daughter-cysts.

48-day infection (1 case) The fibrous zone was very thin, 0.020 to 0.030 mm, and the thickness of the epithelioid zone was reduced. The germinal layer, up to 0.090 mm thick, contained immature protoscolices and abundant calcareous corpuscles. Daughter-cysts were present on the collapsed cyst-walls. Small foci showing early-stage formation of brood capsules were found on the greater omentum.

62- and 64-day infections (2 cases) Among the large cysts were aggregations of numerous minute cysts 0.020 to 0.100 mm in diameter. The epithelioid zone was occasionally absent. Abundant mature protoscolices were observed. The cuticle was about 0.010 mm thick. Large cysts had undergone regressive changes, accompanied by formation of daughter-cysts. Metastatic foci on the greater omentum contained protoscolices.

70-day infection (3 cases) The cysts, usually about 0.500 mm, sometimes exceeded 10 mm in diameter. The adventitial layer was 0.020 to 0.040 mm thick. The cuticle occasionally attained 0.010 mm in thickness. The germinal layer contained abundant calcareous corpuscles and mature protoscolices. Regressive changes in large cysts were marked. The daughter-cysts were 0.5 to 1 mm in diameter and contained immature protoscolices.

76-day infection (1 case) Findings were similar to those of the preceding stage. Small cysts were filled by germinal tissue.

83-day infection (1 case) Mature protoscolices were abundant. Small cysts were filled by germinal tissue. Calcareous corpuscles measured in diameter up to 0.040 mm. The epithelioid zone was usually lacking. Many daughter-cysts, about 0.5 mm in diameter, containing mature protoscolices, were found free or attached to degenerated larval tissue.

92-day infection (1 case) Most cysts were 0.5 to 0.8 mm in diameter, and the cuticle was about 0.010 mm thick. Numerous brood capsules with mature protoscolices were embedded in germinal tissue. The adventitial layer, lacking an epithelioid zone, was thin. Regressive changes and formation of daughter-

cysts were noted in the larval tissue. Metastatic cysts contained a thick germinal layer with mature protoscolices.

19. Golden hamster, *Mesocricetus auratus* WATERHOUSE

Of 14 hamsters exposed to the St. Lawrence Island strain, only one was found to be infected after 26 days (RAUSCH and SCHILLER, 1956). Eight nodular foci, about 0.5 mm in diameter, were found in the liver of this animal. In the centers of the foci were clearly delineated necrotic areas, each about 0.200 mm in diameter, and surrounded by degenerating eosinophils. Centrally in each focus was situated a cyst about 0.050 mm in diameter, with a thin cuticle; a few minute buds were present. The epithelioid zone, 0.100 to 0.125 mm thick, contained no giant cells. The fibrous zone contained histiocytes and eosinophils, and a dense perifocal accumulation of lymphocytes was present.

20. Arctic ground squirrel, *Citellus parryi ablusus* OSGOOD

Four animals trapped on the Alaskan mainland were exposed to the St. Lawrence Island strain. In each of these (one 14-day and three 4-day infections), small foci composed of reticulo-endothelial cells were present, but no signs of developing larvae could be found.

21. Columbian ground squirrel, *Citellus columbianus* (ORD)

Three animals became heavily infected by the St. Lawrence Island strain when maintained in a room with dogs harboring the adult tapeworms. All of the animals exhibited similar lesions. The livers were much enlarged, and active abdominal metastases were found. In one case, the hepatic focus showed cavernformation. The fully developed larvae frequently showed regressive changes, and intrafocal connective tissue also exhibited necrosis and calcification. The cuticle was 0.005 to 0.040 mm thick. The adventitial layer was fibrous. Areas of small-cystic proliferation were present.

22. Thirteen-lined ground squirrel, *Citellus tridecemlineatus* (MITCHILL)

Nine squirrels trapped near Jamestown, North Dakota, by Mr. S. H. RICHARDS were exposed to infection by the St. Lawrence Island strain. Only four were found to be infected. Another (trapped in Oklahoma by Dr. C. E. HOPLA) became infected as the result of housing near dogs harboring the tapeworms.

51-day infection (1 case) The liver contained 3 foci 5 to 7 mm in diameter, consisting of widespread, immature granulation tissue, with abundant histiocytes and eosinophils; collagenous fibers were arranged in a loose, irregular network. In the foci were multilocular larvae composed of minute cysts (pl. III, fig. 12). A few cysts were enlarged, up to 0.300 mm in diameter, and had very thin cuticle. Masses of detritus surrounded the cysts.

70-day infection (3 cases) Two females had similar lesions, consisting of rounded hepatic foci, up to 2.5 mm in diameter. The foci were composed of a surrounding adventitial layer, 0.150 to 0.300 mm thick, and a central cavity, within which the cysts were present singly or clustered (pl. IV, fig. 13). The usually regressive larvae had produced few exogenous buds. No protoscolices were found. The cuticle was very thin. Limited areas of small-cystic proliferation had occurred where there was newly formed granulation tissue with abundant eosinophils and histiocytes.

In the liver of the male were scattered, rounded foci, 1 to 7.5 mm in diameter. The adventitial layer was approximately 0.200 mm thick. The larvae had undergone multilocular vesiculation within the cavity of the lesion; most appeared as a cluster of collapsed cysts with cellular infiltration and fluid. The epithelioid zone was rarely visible, and protoscolices were absent.

Long-term infection (1 case) The infection was of unknown duration in the squirrel maintained near infected dogs. The liver was much enlarged; the left lateral lobe contained a large focus, 60 mm in diameter, made up of fibrous tissue, in which were numerous rounded cavities less than 5 mm in diameter, and within which were the multilocular larvae. Almost all larvae were regressive and embedded in detritus. The fibrous tissue had undergone extensive degeneration. The cuticle was usually 0.005 to 0.010 mm thick, and split and fragmented in necrosed areas. Protoscolices were seen only in marginal areas, where a few large cysts contained small numbers of them, both mature and immature. Calcareous corpuscles were few. Neutrophils and giant cells were attached to the cyst-walls.

23. FRANKLIN'S ground squirrel, *Citellus franklini* (SABINE)

Ten squirrels, trapped near Jamestown, N. D., received embryophores of the St. Lawrence Island strain. One became infected.

69-day infection (1 case) The single unilocular cyst was about 3 mm in diameter. The cyst-wall was desquamated from a thin, fibrous adventitial layer, around which was little cellular reaction. The cuticle and germinal layer were very thin, and no brood capsules were observed.

24. Red squirrel, *Tamiasciurus hudsonicus* (ERXLEBEN)

Three animals trapped near Anchorage were exposed to infection by the St. Lawrence Island strain. One of these had many hepatic foci, up to 3 mm in diameter.

14-day infection (1 case) The cysts were embedded in a wide zone of degenerating hepatic cells, but were immediately surrounded by great numbers of histiocytes. No fibrosis had occurred. Some larvae had produced numerous

exogenous buds. In some, also, cuticle was present. Many foci contained no recognizable larvae.

25. Northern flying squirrel, *Glaucomys sabrinus yukonensis* (OSGOOD)

An adult animal was examined 14 days after infection by the St. Lawrence Island strain (RAUSCH and SCHILLER, 1956). The liver contained many rounded foci, 0.300 to 0.600 mm in diameter, in which unilocular cysts, 0.060 to 0.500 mm in diameter, with a very thin cuticle, were situated centrally. A few cysts in the initial stage of exogenous budding were irregular in shape. The adventitial layer, 0.050 to 0.150 mm thick, was composed of successive zones of eosinophils, epithelioid cells (middle), and fibroblasts (outermost). That of eosinophils, some of which were degenerating, was relatively thick. The fibrous zone contained numerous histiocytes.

26. Domestic rabbit, *Oryctolagus cuniculus* LINNAEUS

Three animals were examined at intervals of 1, 1½, and 5 months after exposure to the St. Lawrence Island strain; only the second was found to be infected (RAUSCH and SCHILLER, 1956).

1½-month infection (1 case) The liver contained many spherical to ellipsoid, nodular foci, 0.5 to 1 mm in diameter, which consisted of a fibrous zone, 0.100 to 0.200 mm thick, an epithelioid zone about 0.100 mm thick, and central detritus. In most foci, the detritus contained dead larvae, the deformed cuticle of which was vaguely discernible. In living larvae, the cuticle was 0.001 to 0.002 mm thick; multilocular vesiculation was rarely noted.

27. Tundra shrew, *Sorex jacksoni* MERRIAM

Five shrews collected on St. Lawrence Island exhibited hepatic lesions which were macroscopically similar to those caused by *E. multilocularis*. The diagnosis was confirmed in four of the animals.

Case 1 A male collected on 10 July 1955 had a large, subspherical focus 13 mm in diameter. The larval mass had a complex, spongy composition, a result of active multilocular vesiculation. The cuticle was 0.001 to 0.002 mm thick. The fibrous zone was 0.040 to 0.080 mm thick. Small numbers of immature protoscolices were observed; calcareous corpuscles were rarely found. A few cysts had collapsed.

Case 2 A female collected on 23 July 1955, had foci 3 to 5 mm in diameter in the right lateral and caudate lobes. The larvae were in a state of active small-cystic proliferation. The fibrous zone was 0.050 to 0.200 mm thick. Giant cells were present. The cuticle was up to 0.002 mm thick. The germinal layer was relatively thick, and a few early-stage brood capsules were noted; calcareous

corpuscles were scarce.

Case 3 A female collected on 20 July 1959, exhibited foci in all hepatic lobes. The larger cysts were 2 to 3 mm in diameter. The adventitial layer was well developed, and included giant cells and a dense accumulation of histiocytes. The cuticle was 0.003 to 0.010 mm thick. A few immature brood capsules were found. Regressive changes in the larval tissue were frequently observed. In some areas, the thick outer layer of cuticle had become detached from the inner lamina; exogenous buds covered by the inner cuticular lamina were seen.

Case 4 A female collected on 30 October 1959, was found to have a spherical focus, 6 mm in diameter, in the right lateral lobe. The larvae were of the large-cystic type. The germinal layer and cuticle were about 0.250 and 0.003 to 0.005 mm thick, respectively. Large numbers of well developed protoscolices and numerous calcareous corpuscles were present. The fibrous zone was about 0.050 mm thick; the epithelioid zone was absent.

28. Horse, *Equus caballus* LINNAEUS

In a horse killed 56 days after exposure to the St. Lawrence Island strain, many nodular foci, around 5 mm in diameter, were found in the liver, the perirenal fat, the lungs, and elsewhere. Almost all were nodules caused by strongyles. In the liver, however, a few echinococcal foci, 1 to 4 mm in diameter, were found. Each consisted of an outer fibrous layer, 0.100 to 0.200 mm thick, and a central detritus of eosinophils. Perifocal histiocytic infiltration was marked. Regressive larvae, rarely with any evidence of budding, were present centrally in the lesions. The cuticle was up to 0.010 mm thick; the very thin germinal layer contained few nuclei.

29. Goat, *Capra hircus* LINNAEUS

Three domestic goats, exposed to the St. Lawrence Island strain, were studied. Two were negative for lesions.

15-day infection (1 case) Many opaque foci, about 1 mm in diameter, were found in the liver; each consisted of a central necrotic area, about 0.500 mm in diameter, a thin epithelioid zone, and a dense accumulation of lymphocytes. The necrotic areas contained degenerated hepatic cells and eosinophils, but no trace of larval cestodes.

30. Rhesus monkey, *Macaca mulatta* ZIMMERMANN

Attempts to infect 4 animals experimentally by the St. Lawrence Island strain were successful in three cases. Some information concerning the first two was provided by RAUSCH and SCHILLER (1956). Lesions were confined to the liver in all.

29-day infection (1 case) The single focus, near 0.300 mm in diameter, a recently formed granulomatous nodule, consisted of a mass of well developed, immature granulation tissue; histiocytes were very numerous. The very thin fibrous zone was surrounded by an accumulation of lymphocytes. The focus contained at the center a small, irregularly shaped cyst about 0.100 mm in diameter, without cuticle, and surrounded by a small quantity of degenerating eosinophils.

80-day infection (1 case) Numerous foci, 2 to 5 mm in diameter, were present. The fibrous zone, up to 0.500 mm thick, had been infiltrated by many histiocytes and small numbers of lymphocytes. The centrally situated multilocular cysts, immediately surrounded by epithelioid zones containing giant cells and degenerating eosinophils, had cuticle 0.001 to 0.002 mm thick; the germinal layer was thin and inactive. Some necrotic eosinophils were present among the cysts.

15-month infection (1 case) The single focus was very large, measuring 40×35 mm on the hepatic surface (pl. V, fig. 17). A central necrotic cavity, 16×12 mm, was filled by thick, greyish pus. When the lesion was transected, the cysts were seen to be arranged radially from the central cavity (pl. V, fig. 18). Individual cysts measured 1 to 5 mm in diameter. The larva exhibited small-cystic proliferation. The germinal layer was very thin and inactive, and no brood capsules or protoscolices were present. The cuticle was usually about 0.020 mm thick, but sometimes as much as 0.030 mm. Some cysts showed degenerative changes. They were surrounded by both newly forming and degenerating cellular elements, mainly histiocytes, but with some lymphocytes and eosinophils. Regressing cysts with colloidal contents were present within areas of degenerating connective tissue, in which were scattered foci of calcification. The central cavity of the lesion was surrounded by granulation tissue containing histiocytes, lymphocytes, eosinophils, and abundant macrophages. In this immature connective tissue, regressive cysts were being surrounded by giant cells.

31. Man

Tissues were studied from 12 cases of alveolar hydatid disease: one from Rebus Island (off the northwestern coast of Hokkaido); one from southern Germany; and 10 from Alaska (all Eskimo patients). The material had been obtained at surgery (6 patients), at necropsy (5 patients), and at both for one patient, who died three years after a hemihepatectomy had been performed. Findings in 8 of the Alaskan cases have been described in part by WEST et al. (1963).

Relatively little is known about the early developmental stages of the larval

E. multilocularis in the human host, since cases seen at surgery or at necropsy usually involve chronic infections of long duration. The initial infection may occur during childhood or youth, and from 10 to 20 years may elapse before clinical signs of disease become apparent. In man, the primary locus of infection seems invariably to be in the liver.

Macroscopically, the hepatic lesion usually appears as one or more whitish, rounded masses of firm to solid consistency, slightly elevated above the surrounding tissue of the surface of the liver. The lesion when transected is seen to consist of a central cavity surrounded by dense, pale tissue which lacks a clearly defined border with respect to the adjacent hepatic tissue. The cavity usually contains a turbid, yellowish to brown fluid in which are particles or fragments of necrotic tissue. Calcification of necrotic tissue produces the characteristic "Kalkspritzer" often seen in Röntgenograms (FRIEDRICH, 1938). In the earliest-stage lesion we studied, a 35×18 mm focus from the dorsal surface of the liver of a 12-year-old Eskimo boy, formation of a central necrotic cavity had already begun.

The hepatic lesion in man is produced by a process comparable to small-cystic proliferation in rodents. But in man, the infection runs a chronic course, as a result of the host's strong reaction to it. In spite of the latter, the larval cestode evidently continues exogenous budding throughout the life of the host, with the result that a great amount of the hepatic tissue is gradually invaded and destroyed.

In general, the following description typifies the hepatic infections seen microscopically in man: There is evidence of a vigorous proliferation of fibrous tissue peripherally, but of regressive changes (necrosis and cavity-formation) centrally, indicating the strong reaction of the host in suppressing the development of the larval cestode. Cysts of various sizes are scattered, or closely aggregated, in the matrix of connective tissue. Individual cysts are often so minute that they are difficult to identify in sections stained in hematoxylin-eosin, although they are readily distinguished when stained by the PAS-method. The cuticle is thick. The germinal layer is very thin, with few brood capsules. Only rarely in the liver, and then usually focally, are brood capsules, protoscolices, and calcareous corpuscles present.

In sections studied, the perifocal cellular reaction varied in degree. Accumulations of histiocytes and lymphocytes were characteristic, with the former predominating. Newly formed cysts were surrounded by epithelioid cells. In the extensive necrotic areas, the cellular elements were only faintly discernible. The cysts frequently exhibited regressive changes and sometimes had been invaded by eosinophils. The cuticle was usually 0.015 to 0.020 mm thick, but showed

malformations such as splitting, thickening with homogeneous structure, and basophilic staining.

Metastasis is not uncommon. The secondary foci usually occur in the brain and lungs. Such foci were found in three (two with metastases in the brain; one, in the lungs) of the 12 cases. The tissue reaction to secondary foci in the brain appears to be weaker than it is to such foci in the other organs; protozoal forms were present in one of the two lesions in the brain, in the material we studied. In one patient, also, a 74-year-old Eskimo, the right kidney had been invaded directly from the liver, at the point where the two organs are contiguous.

DIFFERENTIAL DIAGNOSES

The minute lesions of early-stage larvae of *E. multilocularis* often cannot be differentiated macroscopically from those attributable to several other infectious agents. For example, such lesions in 8 ground squirrels, *Citellus parryi lyratus*, were diagnosed histologically as follows: cystic dilatation of biliary canals, 3 cases; superficial focal fibrosis, 3 cases; adenoma originating in the biliary canal, 1 case; focal necrosis, 1 case. Even in an advanced stage of development, the larval *E. multilocularis* may be confused with lesions of another type, since the filling of the cysts by germinal tissue imparts an appearance much the same as those of some mycotic or neoplastic lesions. Other lesions which we distinguished in our material were the following.

Larva migrans In 21 of 124 voles, *M. oeconomus innuitus*, naturally infected by *E. multilocularis*, minute foci caused by a larval nematode were also found in the liver and other organs. Some foci were spherical and nodular, while others were depressed and irregular in shape. The lesions were minute granulomata which sometimes could be distinguished only with difficulty from those caused by early-stage larvae of *E. multilocularis*. It has been confirmed experimentally (FAY, unpublished) that these were attributable to a larval ascarid, *Toxascaris leonina* (VON LINSTOW, 1902). Further observations on the histopathology of such larvae in voles will be reported separately.

Hepatozoon infection *Hepatozoon* sp. was present in sections of liver from 13 of the 124 voles from St. Lawrence Island. The lesions somewhat resembled those produced by early-stage larvae of *E. multilocularis*. Findings concerning this organism will be reported elsewhere (OHBAYASHI, in press).

Cysticercosis Cysticerci of *Taenia* spp. were found in the liver of 4 voles, all naturally infected: *M. oeconomus innuitus*, 1; *M. o. operarius* 2; and *M. pennsylvanicus drummondii*, 1. These larvae, readily identifiable in sections, usually produce rounded, white nodules.

Capillariasis Lesions caused by *Capillaria* sp. [cf. *C. hepatica* (BANCROFT, 1893)] were observed in the liver of 4 animals: *M. p. drummondi*, 1; *Lemmus sibiricus harroldi* SWARTH, 2 (see RAUSCH, 1961); and *Citellus franklini*, 1. The presence of this nematode could easily be determined microscopically.

Mycosis Five cases of mucormycosis were diagnosed in animals which had been exposed experimentally to *E. multilocularis* (1 vole became infected): 4 in *M. oeconomus*, and one in a hybrid *Dicrostonyx*. Macroscopically, the lesions resembled the fully developed larvae of *E. multilocularis*. The foci varied in size, and exhibited characteristics of a well defined abscess-like granuloma. A detailed description will be published separately (OHBAYASHI, in press).

Neoplasia Hepatic tumors of various types (e.g., hemangioma, hepatoma, adenoma) were found in animals which had been exposed experimentally to infection by *E. multilocularis*. A multicystic tumor diagnosed as a cystadenoma was found in the kidney of a deer mouse, *Peromyscus maniculatus*. The tumors could be easily distinguished microscopically from lesions caused by the larval cestode.

Echinococcus granulosus infection Anomalous development of the larval *E. granulosus* (BATSCH, 1786) is not unusual in man and other animals. The anomalous larvae are sometimes similar morphologically to that of *E. multilocularis*. The larval *E. granulosus* in its natural hosts (e.g., reindeer) typically consists of a spherical, fluid-filled cyst with a laminated outer wall, or cuticle, and an inner wall, or germinal layer, from which the brood capsules arise. The cyst is enclosed by a dense adventitial layer. The cuticle is anucleate and takes an acidophilic stain; its thickness is usually more than 0.100 mm and may be as much as 1.0 mm. The very thin layer of germinal tissue is composed of cells arranged syncytially in almost a monolayer, with the nuclei scattered irregularly. The brood capsules protrude into the cyst-cavity, and when fully developed, are readily detachable from the germinal tissue. In preserved cysts which have not been injected with formalin to ensure rapid fixation (RAUSCH, 1967), detached brood capsules are usually found free in the cyst-fluid. Calcareous corpuscles are rarely present in the larval *E. granulosus*.

The morphological characteristics of the larval *E. granulosus* vary widely with species of ungulate host. A multicystic form (see VOGEL, 1957, p. 448), often confused with the larval *E. multilocularis*, occurs occasionally in cattle, sometimes in sheep, and rarely in swine (WETZEL, 1967). This form, most commonly observed in the liver, consists of an isolated mass of cysts enclosed by a stroma of connective tissue. The cysts are discrete, do not progressively invade the surrounding hepatic tissue, nor do they metastasize. Protoscolices

are rarely, if ever, produced. OSTERTAG noted as long ago as 1891 that the multicystic larva of *E. granulosus* differs from the alveolar larva of man (now known to be *E. multilocularis*) in that it does not undergo ulcerative processes, the size of individual cysts is greater, and the connective tissue matrix is less well developed. POSSELT (1936) and other have brought to our attention that the multicystic form of larva occurs in cattle outside the geographic range of *E. multilocularis*.

Macroscopically, the multicystic larva of *E. granulosus* appears as a mass of aggregated vesicles somewhat elevated above the level of the surrounding hepatic tissue, whereas the larval *E. multilocularis* in the human liver forms large, comparatively smooth nodules of solid consistency. The latter lesions may closely resemble some types of hepatic neoplasia, with which they sometimes have been confused.

Larval cestodes of the alveolar type have been reported in man in regions where *E. multilocularis* is not known to occur, but where infection of man by the larval *E. granulosus* is common (DEW, 1931; DÉVÉ, 1932; DÉVÉ et al., 1936; MEADE and BARNETT, 1941). We studied sections of tissue from a human case diagnosed in New Zealand as alveolar hydatid disease. In these, the connective tissue was not so well developed as in lesions caused by the larval *E. multilocularis*, nor did it show marked regressive changes. The cysts were larger than those produced in man by *E. multilocularis*; the cuticle was often folded, and in most cysts the germinal layer exhibited regressive changes. No brood capsules or protoscolices were found. We consider this infection to have been caused by the larval *E. granulosus*, in which development was anomalous; the larva seemed comparable to the multicystic form from cattle.

We studied as well three specimens of multicystic larvae from the liver of cattle, one from North America (Indianapolis, Indiana) and two from Japan. In the case from North America, the transected lesions showed many discrete cysts, usually 0.5 to 2.5 mm in diameter, embedded in a matrix of connective tissue. The thin cuticle had desquamated from the adventitial capsule. Microscopically, the intercystic connective tissue was found to contain small numbers of histiocytes. The cyst-wall was very thin, folded, and frequently fragmented. The cuticle was 0.001 to 0.002 mm thick, and a germinal layer could not be discerned. Some cysts contained degenerated mononuclear and polymorphonuclear cells, and turbid fluid. In one case from Japan, one focus contained more than 200 cavities, 1 to 10 mm in diameter, each surrounded by well developed adventitial tissue in which histiocytes had accumulated, and each usually contained an agglomeration of collapsed, degenerating cysts (pl. IV, fig. 16). The laminated cuticle was 0.004 to 0.100 mm thick. The germinal layer was hardly discernible.

A thick epithelioid zone with giant cells and showing regressive changes was present intercystically.

Although larger cysts are characteristically produced by the larval *E. multilocularis* in mammals of some species (e. g., *Lemmus*), areas of small-cystic proliferation seem always to be present. We determined that small-cystic proliferation is an intrinsic process in the development of this larva, even in terminal stages when the focus is composed largely of brood capsules filled by mature protoscolices. Consequently, the presence of areas of small-cystic proliferation constitutes the best character for distinguishing the larval *E. multilocularis* from anomalous larvae of *E. granulosus*.

DISCUSSION

The histogenesis of the larval *E. multilocularis* in experimentally infected animals has been studied by several investigators (RAUSCH, 1954; VOGEL, 1955a, 1955b; RAUSCH and SCHILLER, 1956; MANKAU, 1956a, 1956b, 1957; SADUN et al., 1957; YAMASHITA et al., 1958, 1960, 1963; OHBAYASHI, 1960; LUKASHENKO, 1960, 1964, 1966; WEBSTER and CAMERON, 1961). The earlier studies were concerned mainly with the development of the larval cestode in single species of host, including several standard strains of laboratory mice. In the present work, we have emphasized differences between hosts in pattern of development of the larval cestode, particularly in arvicoline rodents, several of which are important as natural intermediate hosts.

The tissue reactions evoked by the larval cestode can be categorized as progressive, involving the formation of granulation tissue in the process of encapsulation and organization of the lesion, and regressive in the response to chemical and mechanical effects of the parasite. With establishment of the embryo in the hepatic parenchyma, the tissue reaction begins with activation of the sinusoidal endothelium. The endothelial cells increase in numbers and become polygonal. Leukocytes (mainly eosinophils; rarely neutrophils) infiltrate the area, and within one to two days following infection, a nodule composed of these cellular elements is formed. At the same time, focal necrobiosis or necrosis of the hepatic tissue occurs.

The degenerating hepatic cells and eosinophils form a mass of detritus in which the larva is embedded. The quantity of detritus formed and the extent to which it becomes calcified vary with species of host. After the larva becomes vesicular, production of exogenous buds begins. The number of buds produced is inversely proportional to the volume of the detrital mass and to the extent of its calcification. The detritus is surrounded by an epithelioid zone characterized by radially arranged syncytial cells having large, rounded nuclei and

abundant protoplasm and by formation of giant cells usually of the LANGHANS type. We consider the epithelioid zone to have a resorptive function in respect to the detritus, particularly during the earlier stages of infection. The epithelioid cells also degenerate and contribute further to formation of detritus. Fibrosis begins within 7 to 10 days following infection, and an outer fibrous zone showing an annular arrangement of collagenous fibers is produced. The cellular reaction further involves histiocytes, identified as plasma cells and lymphoid cells, which infiltrate the periphery of the fibrous zone and tend to accumulate on GLISSON'S capsule. Lymphocytic infiltration was observed only in advanced stages of infection, in lesions closely associated with GLISSON'S capsule. In foci situated at the margin of the hepatic lobe and protruding above the hepatic surface, development of the larval cestode is somewhat retarded. In such lesions, the epithelioid zone was discontinuous and the adventitial zone was very thin on the outer surface.

Pressure atrophy of the hepatic cell-cords is evident in comparatively early-stage infections. The hepatic parenchyma is later largely replaced by the vigorously proliferating tissue of the parasite, although islet-like areas of hepatic tissue showing atrophic changes usually remain, scattered among the cysts within the lesion. Chronic dilatation of the sinusoids is also a frequent finding. The rate of development of protoscolices, depending mainly upon formation of large cysts, and the time of appearance and abundance of calcareous corpuscles differ with species of host. The number of such corpuscles is usually proportional to the thickness of the germinal layer, although some intraspecific variation is seen. Calcareous corpuscles are usually abundant by the time infective protoscolices are present. We consider the presence of abundant calcareous corpuscles to be indicative of a favorable parasite-host relationship.

Interspecific differences among arvicoline rodents Findings in *Microtus* spp. are of unusual interest because of the range of species-related differences observed in the development of the larva and in the associated tissue reactions. In these voles, as well as in mammals of other groups, distinctive characteristics of the lesions are most strongly defined at a comparatively early stage, prior to the onset of formation of brood capsules, but they persist for the duration of the lesion.

In *M. oeconomus*, the rate of enlargement of the lesion is suppressed by the persistent, large detrital mass characteristically produced in this species. Characteristic for this species also is a thick adventitial layer composed of an inner epithelioid zone and an outer fibrous zone. The focus is initially subspherical and assumes a more irregular shape with the proliferation of buds which extend through the adventitial layer into the surrounding hepatic tissue. The proli-

feration of vesicles is most strongly suppressed in *M. oeconomus innuitus*, in which the lesion contains only a few cysts having a relatively thick cuticle. The cuticle of such cysts sometimes ruptures, and buds covered only by its thin inner layer extend gradually into the hepatic tissue. The detrital mass frequently becomes calcified in *M. oeconomus innuitus*, but rarely does so in *M. o. operarius*.

Little detritus is produced in lesions in *M. pennsylvanicus*, and the epithelioid zone is usually poorly developed. The focus is spherical and is surrounded by a thin fibrous zone within which numerous small cysts of similar size accumulate. The intercystic spaces are at first filled by a small quantity of granulation tissue which disappears as the cysts enlarge.

The lesion produced in *M. montebelli* has characteristics which are intermediate between those in *M. oeconomus* and *M. pennsylvanicus*. A large amount of non-calcified detritus with aggregations of minute cysts is present in early-stage lesions, but the amount of detritus decreases with continuing proliferation of cysts.

In *Clethrionomys rutilus*, exogenous buds are few or absent for about 12 days following infection; the tissue reaction is of low grade, and the lesion is surrounded by a thin adventitial layer consisting of a thin zone of cuboidal epithelioid cells and a very loose fibrous tissue. Thereafter, minute exogenous buds proliferate at a rapid rate, and some increase rapidly in size. The hepatic parenchyma exhibits marked regressive changes; heavy infections invariably show necrosis of hepatic tissue. Little perifocal infiltration by leukocytes is seen in lesions in *C. rutilus*.

Infections in the sagebrush vole, *Lagurus curtatus*, are characterized by vigorous small-cystic proliferation with little tissue reaction. The pattern of development of the lesion in these voles closely resembles that in *C. rutilus*, but formation of protoscolices by the larval cestode is delayed in comparison with that observed in the other arvicoline species. This slow rate of production of protoscolices is evidently related to poor development of large cysts. Infection in *L. curtatus* produces marked degenerative changes in the liver and in some cases leads to the death of the host.

Variation in degree of susceptibility and in the characteristics of the lesion was observed also in subspecies of the varying lemming, *Dicrostonyx groenlandicus*, although comparatively few animals were studied. Both *D. groenlandicus rubricatus*, from northern Alaska, and *D. g. richardsoni*, from northern Manitoba (Canada), are highly resistant to infection. *D. g. nelsoni*, from the Seward Peninsula (western Alaska), is quite susceptible, while *D. g. stevensoni*, from Umnak Island (Aleutian Islands), shows an intermediate degree of susceptibility. Cytogenetic findings (RAUSCH and RAUSCH, unpublished) indicate that some of

the varying lemmings now regarded as subspecies may be specifically distinct.

Localization of the larva in arvicoline rodents The distribution of foci in the hepatic lobes of arvicoline rodents was, in a general way, related to the size of the lobes. Larvae occurred most frequently in the left lateral lobe, which is the largest, and least often in the papillary lobes, which are the smallest. However, the relationship of frequency of occurrence to weight of the respective lobes is apparently imperfect, at least in *Microtus oeconomus*: in 847 natural infections from nine large samples of voles from St. Lawrence Island, the frequency of occurrence of larvae per hepatic lobe differed significantly ($p=.999$) by the Chi-square test from the "expected" frequency, based on weights of lobes from 15 non-infected voles (table 3).

TABLE 3 Comparison of observed and expected frequency of occurrence of *E. multilocularis* larvae per hepatic lobe in northern voles, *M. oeconomus*

HEPATIC LOBE	FREQUENCY (PER CENT)				APPROXIMATE PROBABILITY (p) OF DIFFERENCE
	Observed*		Expected*		
	Range	Mean	Range	Mean	
Right median	17.1-21.8	19.4	13.5-20.9	17.9	.94
Left median	11.8-17.4	15.2	7.8-14.4	11.5	.999
Right lateral	13.6-20.8	17.4	14.2-22.8	18.5	.78
Left lateral	19.5-31.0	26.1	33.1-42.2	36.6	.999
Caudate	10.0-16.2	12.4	4.4-12.2	8.8	.999
Right papillary	2.3- 6.9	4.6	1.5- 5.4	4.1	.78
Left papillary	1.9- 6.2	4.7	1.0- 4.2	3.1	.999

* Observed frequency based on 2243 occurrences in 847 infected voles; expected frequency based on weights of hepatic lobes in 15 non-infected voles.

No relationship between size of lobe and localization of larvae was evident in muskrats which had received from 1 to 5 embryophores.

Metastases in arvicoline rodents The usual distribution of metastatic foci in naturally infected voles was described above. Such foci are found on serous surfaces, such as the mesentery, lesser omentum, broad ligaments of the uterus, and others. Metastases are relatively rare in thoracic organs (lungs) or elsewhere in the body. Hematogenous metastasis involving metamorphosed protoscolices or other tissue elements is a possibility in these rodents. In man, hematogenous metastasis seems usually to involve invasion of the inferior vena cava (POSSELT, 1931, p. 532).

Metastases in arvicoline rodents appear usually to be a result of intra-

abdominal dissemination of tissue elements, including protoscolices or daughter-cysts, or of direct invasion from a lesion in a contiguous organ. In long-standing infections, protoscolices metamorphosing to daughter-cysts are sometimes observed in large cysts that are undergoing regression. As noted above, when such cysts are superficially situated, the thin adventitial layer and the hepatic capsule together form a covering which is frequently less than 0.050 mm in total thickness. Such cysts may rupture spontaneously, releasing tissue elements that become localized and produce new foci. In some cases, minute protrusions from the large cyst through the thin covering layer were observed; in others, the fibrinous inflammatory layer on the hepatic surface was invaded by proliferating cysts. Nodules of metastatic origin usually become localized, but some remain unattached. Such free nodules, which continue development, seem to occur most commonly in *Clethrionomys rutilus*.

In *M. oeconomus*, heavy infections sometimes caused adhesions between hepatic lobes, most frequently between the right lateral and the caudate lobes. When present in one lobe, the parasite often invaded the adjacent lobe in such cases. The cause for the frequency of adhesions in this area can be explained by the anatomical relationships, since the right kidney presses against the caudate lobe, and the lobes on the right are less movable than are those on the left. Such invasion of one hepatic lobe from another was noted also in a specimen of *Lagurus curtatus*.

Some characteristics of infection in other species No systematic chronological study of the histogenesis of the larval cestode was made in animals other than those discussed above. Other animals exposed experimentally to infection exhibited a wide range in degree of susceptibility and in characteristics of the tissue reactions.

Species of ground squirrels of the genus *Citellus* exhibited variation in degree of susceptibility comparable to that observed in subspecies of *Dicrostonyx*. *Citellus parryi*, from the Alaskan mainland, could not be infected experimentally, nor have we found naturally infected specimens of *C. parryi lyratus* on St. Lawrence Island, where rates of infection in susceptible rodents of other species are comparatively high. *C. columbianus*, from the state of Washington, was highly susceptible; infected animals tolerated massive proliferation of the larval cestode. Specimens of *C. tridecemlineatus* became infected, but the larvae had undergone severe regressive changes, and their development was inhibited. *C. franklini* appears also to be relatively resistant; of 10 animals exposed, infection was established in only one, in which the larval cestode was little developed.

The wide range in degree of susceptibility in different standard strains of laboratory mice, *Mus musculus*, has been demonstrated by YAMASHITA et al.

(1958, 1963). Comparable findings have been reported by LUBINSKY and DESSER (1963) and by LUBINSKY (1964), who implanted larval tissue subcutaneously in mice. In wild mice infected by us, development of the larvae was inhibited to a degree similar to that observed in some strains of laboratory mice. However, greater susceptibility might be expected in wild mice from other geographic populations.

Certain mammals of other species were found to be unsuitable as intermediate hosts for *E. multilocularis*. In some, no signs of larvae could be found; in others, organized lesions containing dead larvae were present in the liver. Death of the larvae sometimes does not occur until after their development has progressed to the stage of early multilocular vesiculation, as in horse, domestic rabbit, and hamster.

In man and in rhesus monkey, the infection takes a protracted course, with almost complete inhibition of the later developmental processes in the larval cestode. The hepatic lesion in these animals is a result of small-cystic proliferation similar to that occurring in normally developing larvae in arvicoline rodents. Calcareous corpuscles and protoscolices are usually absent. These primates seem to provide the least favorable conditions under which the larval cestode is able to persist and proliferate.

Biological strains of E. multilocularis In establishing experimental infections, we used mainly the strain of *E. multilocularis* from St. Lawrence Island, and secondarily those originating in central Europe and in North Dakota. The European strain may differ from that of St. Lawrence Island in degree of pathogenicity and in localization of foci. Using the European strain experimentally, VOGEL and SCHUMACHER (1957) noted the occurrence of lesions involving the central nervous system in *Microtus agrestis* LINNAEUS, but we found no such foci in *M. pennsylvanicus* and *C. rutilus* infected with this strain. However, in both of the latter, intraabdominal metastases were unusually numerous, and the lungs were often involved to an extent not observed in rodents infected by embryophores of the St. Lawrence Island strain. Compared with that of St. Lawrence Island, the strain from North Dakota may be less pathogenic; also, the larvae developed more slowly in arvicoline rodents of some species.

ACKNOWLEDGEMENTS

Prof. H. VOGEL, Institut für Schiffs- und Tropenkrankheiten, Hamburg, provided embryophores of the European strain of *E. multilocularis* as well as tissues and other materials. Tissues from a patient with alveolar hydatid disease were made available by Dr. S. HORIE, Horie Hospital, Kabuka Town (Rebun Island). Dr. T. W. M. CAMERON, Ste. Anne de Bellevue, Quebec, lent us sections of tissues from the case of multicystic hydatid disease from New Zealand, and also provided the stock of varying lemmings from Manitoba. Embryophores of the North Dakota strain of *E. multilocularis* and other materials were provided by Mr. S. H. RICHARDS, North Dakota Game and Fish Department, Jamestown, who also sent us live-trapped animals. Stocks of rodents for establishing laboratory colonies or wild-trapped animals were provided by Mr. J. J. BURNS, Alaska Department of Fish and Game, Fairbanks; by Dr. E. C. VIERECK, University of Alaska, College; by Dr. M. L. JOHNSON, University of Puget Sound, Tacoma; and by Dr. C. E. HOPLA, University of Oklahoma, Norman. Tissues from naturally infected rodents were sent by Dr. J. M. HNATIUK, Department of Biology, University of Saskatchewan, Saskatoon, and by Mr. R. L. DELONG, Smithsonian Institution, Washington, D. C. At the Alaska Native Medical Center, Anchorage, Dr. J. T. WEST and Dr. J. F. WILSON made available tissues obtained at surgery and at autopsy, and assisted in other ways. Prof. Y. FUJIMOTO, Faculty of Veterinary Medicine, Hokkaido University, Sapporo, diagnosed tumors in experimental animals. The Naval Arctic Research Laboratory, under the direction of Dr. M. C. BREWER at Point Barrow, supported field work in northern Alaska and assisted in obtaining animals and other materials. For these contributions, we express our sincere gratitude.

REFERENCES

- 1) DÉVÉ, F. (1932): L'échinococcose alvéolaire. *Prensa méd. argent.*, **19**, 966-976
- 2) DÉVÉ, F., PIAGGIO-BLANCO, R. & GARCÍA-CAPURRO, F. (1936): Echinococcose hépatique maligne micro-polykystique infiltrante. Forme intermédiaire entre l'échinococcose hydatique et l'échinococcose alvéolaire. *Archos urug. Med. Cirug.*, **8**, 3-28
- 3) DEW, H. R. (1931): Echinococcus alveolaris, with report of an Australian case. *Aust. N. Z. J. Surg.*, **1**, 115-141
- 4) FEDYK, S. (1970): Chromosomes of *Microtus (Stenocranius) gregalis major* (OGNEV, 1923) and phylogenetic connections between sub-arctic representatives of the genus *Microtus* SCHRANK, 1798. *Acta theriol.*, **15**, 143-152
- 5) FRIEDRICH, H. (1938): Die Diagnose des Echinococcus alveolaris (infiltrierend wachsender Echinokokkus); keine extrem seltene, sondern fast immer verkannte Erkrankung. *Medsche Klin.*, **34**, 1220-1222
- 6) HALL, E. R. & KELSON, K. R. (1959): The mammals of North America, 1 ed., New York: Ronald Press
- 7) HNATIUK, J. M. (1966): First occurrence of *Echinococcus multilocularis* LEUCKART, 1863 in *Microtus pennsylvanicus* in Saskatchewan. *Can. J. Zool.*, **44**, 493
- 8) LIAPUNOVA, E. A. (1969): „Opisanie khromosomnogo nabora i podtverzhdenie

- vidovoi samostoiatel'nosti *Citellus parryi* (Marmotinae, Sciuridae, Rodentia)“ Mleko-pitaiushchie (Evoliutsiia, Kariologiya, Sistematika, Faunistika), Ed. N. N. VORONTSOV, 53-54, Novosibirsk: Inst. Tsitol. i Genetiki, Sibir. Otdel. Akad. Nauk SSSR (in Russian)
- 9) LIAPUNOVA, E. A. & MIROKHANOV, Iu. M. (1969): „Opisanie khromosomnykh naborov nekotorykh vidov polevok (podrody *Stenocranius*, *Lasiopodomys*, *Blanfordimys*, *Microtus* s. str.)“ *Ibid.*, 134-138 (in Russian)
 - 10) LUBINSKY, G. (1964): Growth of the vegetatively propagated strain of larval *Echinococcus multilocularis* in some strains of Jackson mice and in their hybrids. *Can. J. Zool.*, **42**, 1099-1103
 - 11) LUBINSKY, G. & DESSER, S. (1963): Growth of the vegetatively propagated strain of larval *Echinococcus multilocularis* in C57L/J, B6AF₁, and A/J mice. *Ibid.* **41**, 1213-1216.
 - 12) LUKASHENKO, N. P. (1960): Laboratornaia model' al'veoliarnogo ekhinokokkoza. *Medskaya Parazit.*, **29**, 154-157 (in Russian with English summary)
 - 13) LUKASHENKO, N. P. (1964): K izucheniiu patogeneza eksperimental'nogo al'veokokkoza (al'veoliarnogo ekhinokokkoza). II. Gistogenez vyvodkovykh kapsul i zarodyshevykh skoleksov *Alveococcus multilocularis* (LEUCKART, 1863). *Ibid.*, **33**, 587-590 (in Russian with English summary)
 - 14) LUKASHENKO, N. P. (1966): Sravnitel'noe izuchenie genezisa puzyr'kov *Alveococcus multilocularis* (LEUCKART, 1863), ABULADZE, 1959 u nekotorykh mlekopitaiushchikh v aspekte vzaimootnoshenii khoziain-parazit. *Ibid.*, **35**, 474-481 (in Russian with English summary)
 - 15) MANKAU, S. K. (1956a): Studies on the helminth, *Echinococcus alveolaris* (KLEMM, 1883), from St. Lawrence Island, Alaska. II. Development of brood capsules and scolices in alveolar cysts, in white mice. *Trans. Am. microscop. Soc.*, **75**, 401-406
 - 16) MANKAU, S. K. (1956b): Studies on *Echinococcus alveolaris* (KLEMM, 1883), from St. Lawrence Island, Alaska. III. The histopathology caused by the infection of *E. alveolaris* in white mice. *Am. J. trop. Med. Hyg.*, **5**, 872-880
 - 17) MANKAU, S. K. (1957): Studies on *Echinococcus alveolaris* (KLEMM, 1883), from St. Lawrence Island, Alaska. I. Histogenesis of the alveolar cyst in white mice. *J. Parasit.*, **43**, 153-159
 - 18) MEADE, J. A. & BARNETT, L. (1941): Echinococcosis alveolaris (alveolar hydatid disease), associated with ordinary hydatid cysts of the liver. *Aust. N. Z. J. Surg.*, **10**, 317-327
 - 19) OHBAYASHI, M. (1960): Studies on echinococcosis. X. Histological observations on experimental cases of multilocular echinococcosis. *Jap. J. vet. Res.*, **8**, 134-160
 - 20) OSTERTAG, R. (1891): Ueber den Echinococcus multilocularis bei Rindern und Schweinen. *Dt. Z. Tiermed. vergl. Path.*, **17**, 172-195
 - 21) POSSELT, A. (1931): Allgemeine Pathologie und pathologische Anatomie der Alveolarechinokokken-Geschwulst in der Leber des Menschen. *Ergebn. allg. Path. path. Anat.*, **24**, 447-553
 - 22) POSSELT, A. (1936): Über die Natur des Echinococcus alveolaris und seine Bezieh-

- ung zum *Echinococcus hidatidosus*. *Rep. 3. int. Congr. comp. Path., Sect. hum. Med.*, **1**, 27-55
- 23) RAUSCH, R. L. (1954): Studies on the helminth fauna of Alaska. XX. The histogenesis of the alveolar larva of *Echinococcus* species. *J. infect. Dis.*, **94**, 178-186
- 24) RAUSCH, R. L. (1961): Notes on the occurrence of *Capillaria hepatica* (BANCROFT, 1893). *Proc. helminth. Soc. Wash.*, **28**, 17-18
- 25) RAUSCH, R. L. (1967): On the ecology and distribution of *Echinococcus* spp. (Cestoda: Taeniidae), and characteristics of their development in the intermediate host. *Annls Parasit. hum. comp.*, **42**, 19-63
- 26) RAUSCH, R. L. & RAUSCH, V. R. (1968): On the biology and systematic position of *Microtus abbreviatus* MILLER, a vole endemic to the St. Matthew Islands, Bering Sea. *Z. Säugetierk.*, **33**, 65-99
- 27) RAUSCH, R. L. & SCHILLER, E. L. (1956): Studies on the helminth fauna of Alaska. XXV. The ecology and public health significance of *Echinococcus sibiricensis* RAUSCH & SCHILLER, 1954, on St. Lawrence Island. *Parasitology*, **46**, 395-419
- 28) SADUN, E. H., NORMAN, L., ALLAIN, D. S. & KING, N. M. (1957): Observations on the susceptibilities of cotton rats to *Echinococcus multilocularis* (LEUCKART, 1863). *J. infect. Dis.*, **100**, 273-277
- 29) SMYTH, J. D. & SMYTH, M. M. (1964): Natural and experimental hosts of *Echinococcus granulosus* and *E. multilocularis*, with comments on the genetics of speciation in the genus *Echinococcus*. *Parasitology*, **54**, 493-514
- 30) VOGEL, H. (1955a): Über den Entwicklungszyklus und die Artzugehörigkeit des europäischen Alveolarechinococcus. *Dt. med. Wschr.*, **80**, 931-932
- 31) VOGEL, H. (1955b): Beobachtungen über einen alveolären *Echinococcus* bei süddeutschen Wildtieren. *Revta ibér. Parasit.*, Tomo extraord., 443-449
- 32) VOGEL, H. (1957): Über den *Echinococcus multilocularis* Süddeutschlands. I. Das Bandwurmstadium von Stämmen menschlicher und tierischer Herkunft. *Z. Tropenmed. Parasit.*, **8**, 404-454
- 33) VOGEL, H. & SCHUMACHER, H. H. (1957): Beobachtungen über alveoläre Echinokokken des Zentralnervensystems bei Versuchstieren. *Ibid.*, **8**, 278-287
- 34) WEBSTER G. A. & CAMERON, T. W. M. (1961): Observations on experimental infections with *Echinococcus* in rodents. *Can. J. Zool.*, **39**, 877-891
- 35) WEST, J. T., HILLMAN, F. J. & RAUSCH, R. L. (1963): Alveolar hydatid disease of the liver: rationale and technics of surgical treatment. *Ann. Surg.*, **157**, 548-559
- 36) WETZEL, R. (1967): „Parasitäre Erkrankungen der Leber und der Gallengänge“ Handbuch der speziellen pathologischen Anatomie der Haustiere, Hrsg. DOBBERSTEIN, J., PALLASKE, G. & STÜNZI, H., 3 Aufl., **6**, 209-299, Berlin & Hamburg: Verlag Paul Parey
- 37) YAMASHITA, J., OHBAYASHI, M., KITAMURA, Y., SUZUKI, K. & OKUGI, M. (1958): Studies on echinococcosis. VIII. Experimental echinococcosis multilocularis in various rodents; especially on the difference of susceptibility among uniform strains of the mouse. *Jap. J. vet. Res.*, **6**, 135-155

Ecology and Distribution of Echinococcus spp. II.

53

- 38) YAMASHITA, J., OHBAYASHI, M. & SAKAMOTO, T. (1960): Studies on echinococcosis. XI. Observations on secondary echinococcosis. *Ibid.*, **8**, 315-322
- 39) YAMASHITA, J., OHBAYASHI, M., SAKAMOTO, T., ORIHARA, M., SUZUKI, K. & OKUGI, M. (1963): Studies on echinococcosis. XIV. Further observations on the difference of susceptibility to *Echinococcus multilocularis* among uniform strains of the mouse. *Ibid.*, **11**, 50-54

EXPLANATION OF PLATES

PLATE I

- Fig. 1 Early-stage lesion (Group I) in the liver of a naturally infected vole, *Microtus oeconomus innuitus* × 135
- Fig. 2 Hepatic lesion (Group I) in naturally infected *M. oeconomus innuitus*. Rounded focus contains calcified detritus in which cysts are embedded × 62
- Fig. 3 Hepatic lesion (Group II) in naturally infected *M. oeconomus innuitus*. Space between the detritus and the adventitial layer being invaded by proliferating cysts × 52
- Fig. 4 Hepatic lesion (Group III) in naturally infected *M. oeconomus innuitus*. Mature protoscolices and calcified detritus × 66

OHBAYASHI, M. et al.

PLATE I

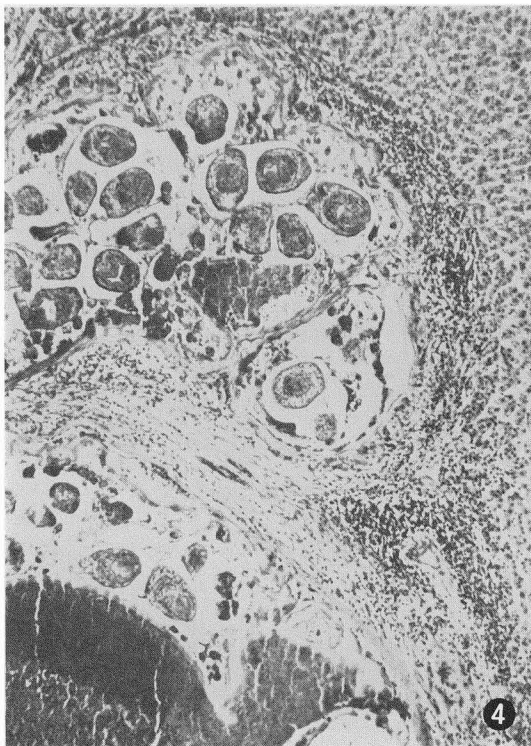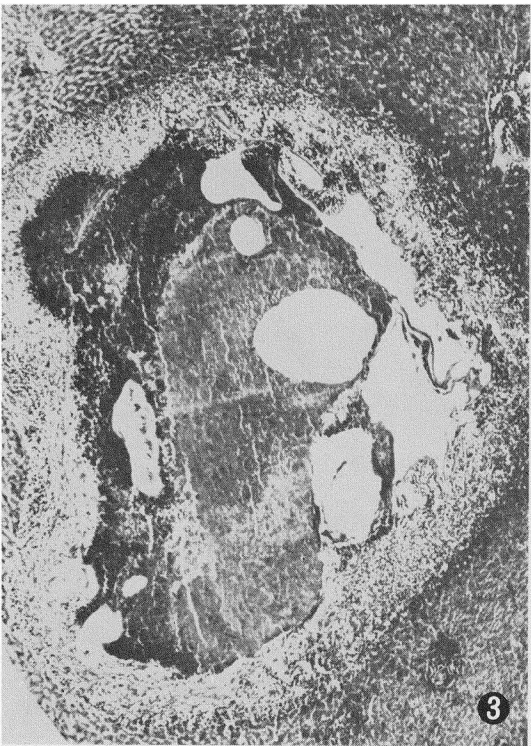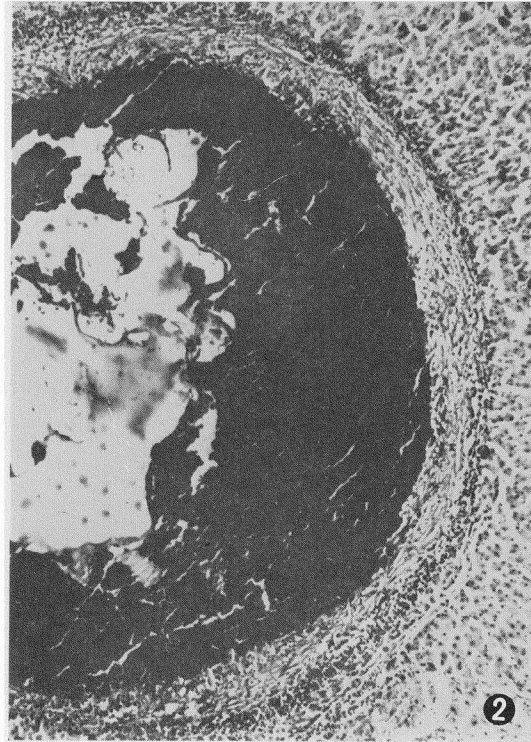
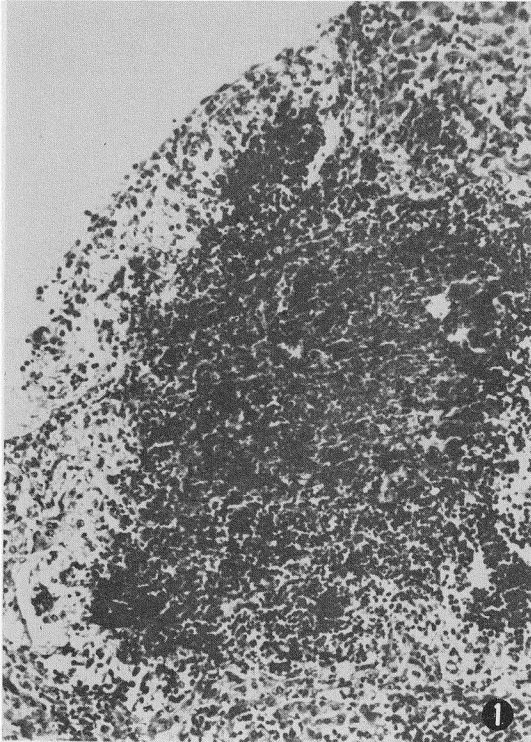


PLATE II

- Fig. 5 Hepatic lesion in *Microtus oeconomus operarius* 12 days after experimental infection by St. Lawrence Island (SLI) strain of *E. multilocularis*. Cysts embedded in non-calcified detritus, with well developed epithelioid zone and fibrous zone infiltrated by histiocytes × 120
- Fig. 6 Hepatic lesion in *M. o. operarius* 23 days after infection by the SLI strain. Central detritus and thick adventitial layer × 60
- Fig. 7 Hepatic lesion in *M. p. pennsylvanicus* 14 days after experimental infection by the SLI strain. Aggregation of cysts in typical, rounded focus; no detritus present × 130
- Fig. 8 Hepatic lesion in *M. m. montebelli* 10 days after experimental infection by the SLI strain. Large mass of non-calcified detritus in which cysts are actively proliferating × 120

OHBAYASHI, M. et al.

PLATE II

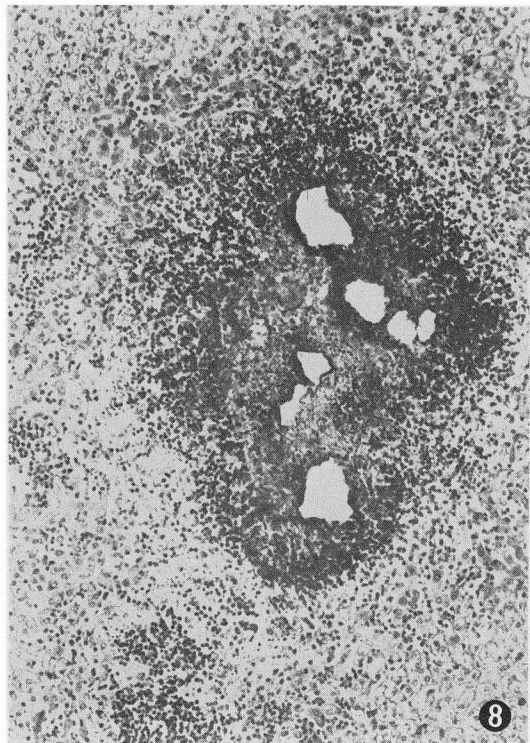
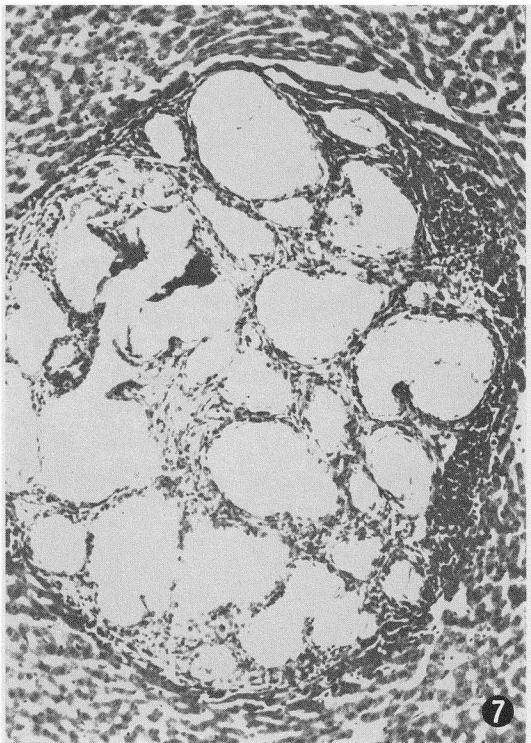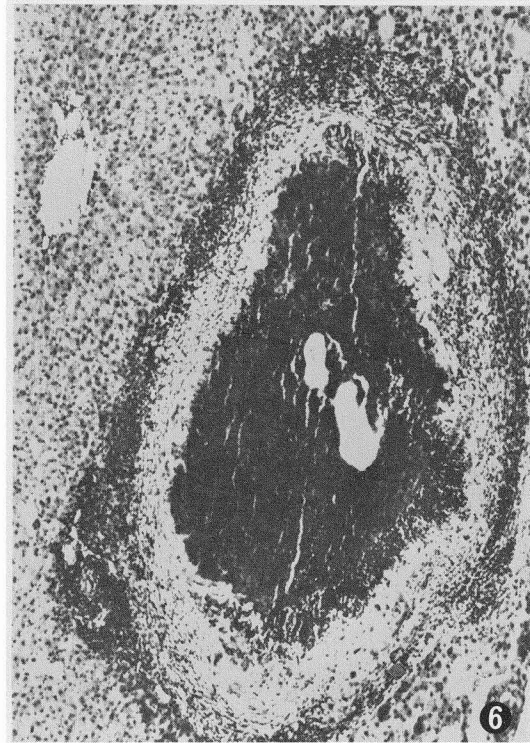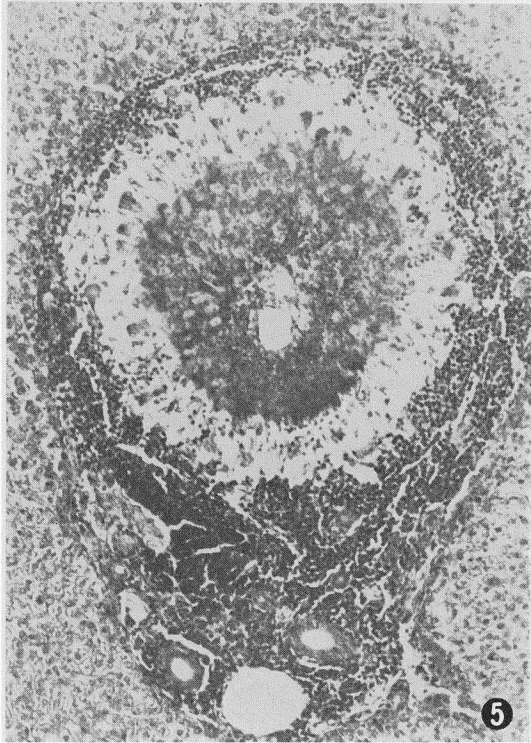


PLATE III

- Fig. 9 Hepatic lesion in *Clethrionomys rutilus dawsoni* 12 days after experimental infection by the SLI strain. Almost unilocular cyst surrounded by epithelioid zone and external zone of loosely arranged fibers $\times 145$
- Fig. 10 Hepatic lesion in *C. r. dawsoni* 26 days after experimental infection by the SLI strain. Active exogenous budding $\times 50$
- Fig. 11 Hepatic lesion in *Lagurus curtatus* 15 days after experimental infection by the SLI strain. Vigorous proliferation of cysts with scanty tissue reaction $\times 125$
- Fig. 12 Hepatic lesion in *Citellus tridecemlineatus* 51 days after experimental infection by the SLI strain. Vigorous proliferation of connective tissue with numerous, scattered cysts $\times 50$

OHBAYASHI, M. et al.

PLATE III

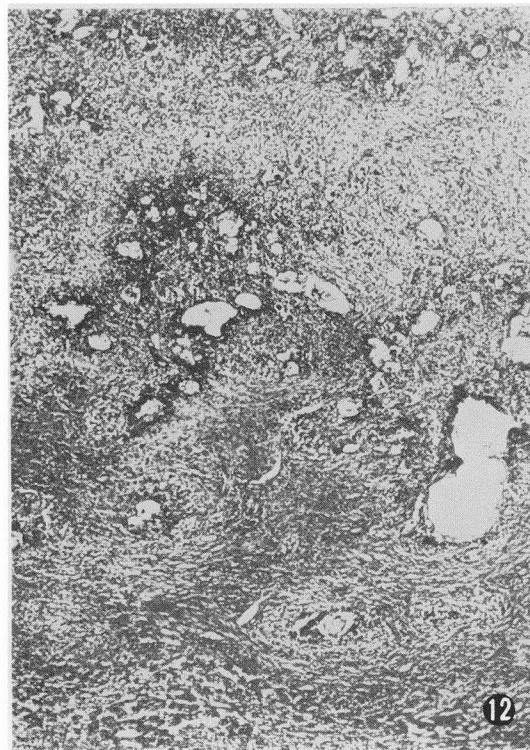
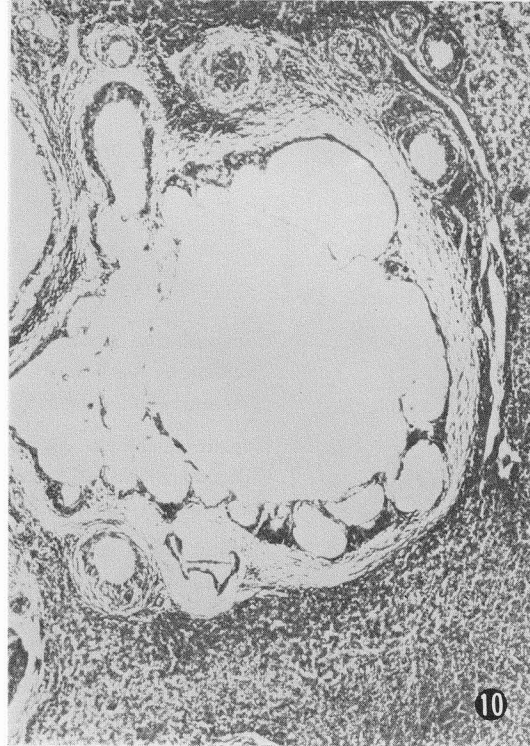
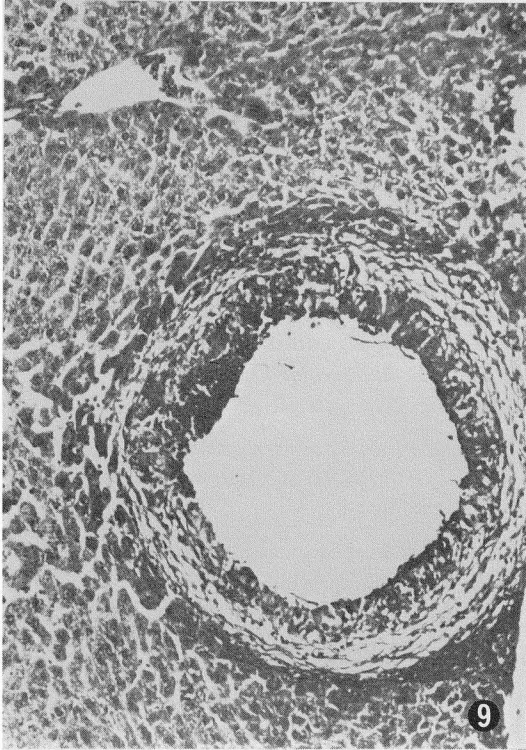


PLATE IV

- Fig. 13 Hepatic lesion in *Citellus tridecemlineatus* 70 days after experimental infection by the North Dakota strain of *E. multilocularis*. Regressive cysts surrounded by a thick adventitial layer × 58
- Fig. 14 Hepatic lesion in *Sigmodon hispidus* 10 days after experimental infection by the SLI strain. Active proliferation of cysts without formation of detritus × 115
- Fig. 15 Hepatic lesion in *S. hispidus* 18 days after experimental infection by the SLI strain. Active multilocular vesiculation with scanty tissue reaction × 54
- Fig. 16 Multicystic larva of *E. granulosus* in bovine liver (animal imported to Japan from New Zealand). Much-folded cuticle with thick layer of connective tissue × 48

OHBAYASHI, M. et al.

PLATE IV

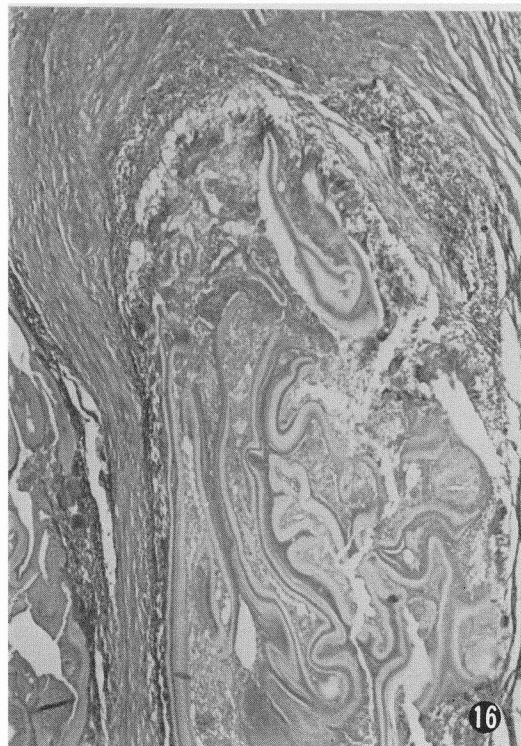
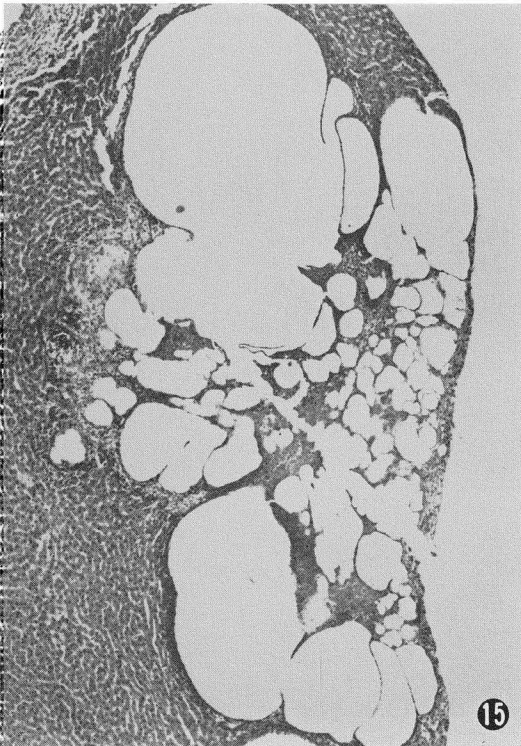
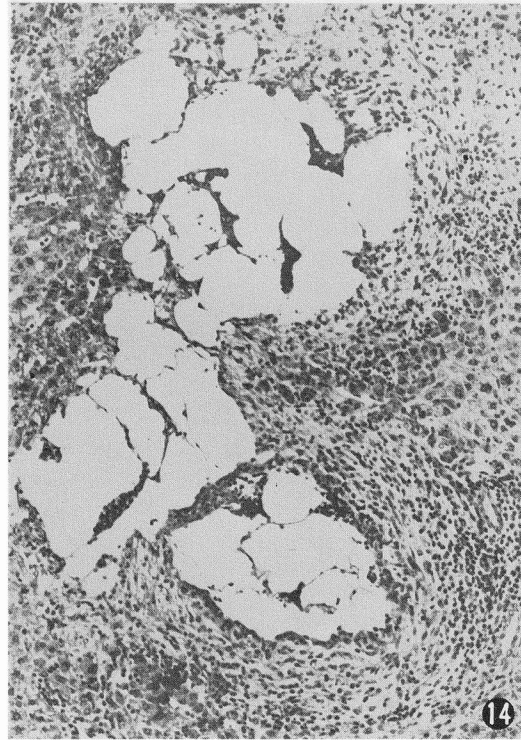
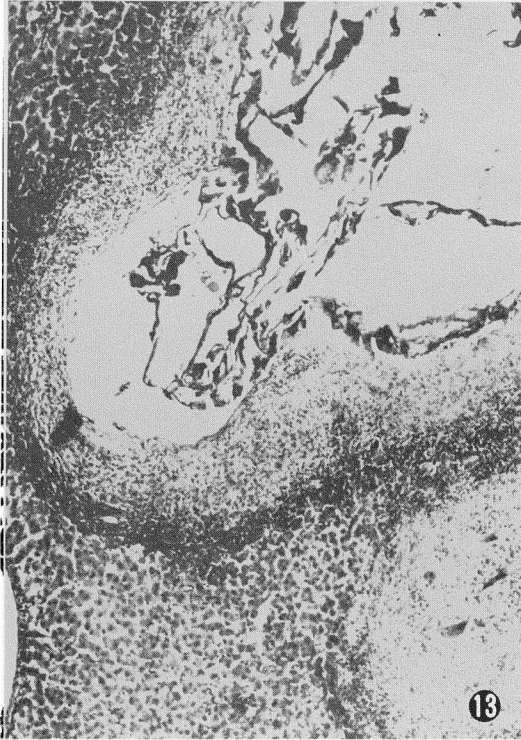

PLATE V

Fig. 17 Liver of rhesus monkey 15 months after experimental infection by the SLI strain of *E. multilocularis*. At the hepatic surface, the maximum diameter of the lesion was 40 mm.

Fig. 18 Liver of rhesus monkey 15 months after experimental infection by the SLI strain. The transected lesion, 34 mm in greatest diameter, shows central necrotic cavity and radial arrangement of cysts.

OHBAYASHI, M. et al.

PLATE V

