

Maxillary expansion in an animal model with light, continuous force

Achint Utreja^a; Carol Bain^b; Brett Turek^c; Robert Holland^c; Rawan AlRasheed^d; Parand Sorkhdini^d; W. Eugene Roberts^e

ABSTRACT

Objectives: Maxillary constriction is routinely addressed with rapid maxillary expansion (RME). However, the heavy forces delivered by most RME appliances to expand the palate may lead to deleterious effects on the teeth and supporting tissues. The objective of this study was to explore a more physiologic maxillary expansion with light continuous force.

Materials and Methods: Twenty 6-week-old Sprague-Dawley rats were equally divided into experimental (EXPT) and control (CTRL) groups. A custom-fabricated archwire expansion appliance made from 0.014-inch copper-nickel-titanium wire was activated 5 mm and bonded to the maxillary molar segments of animals in the EXPT group for 21 days. The force applied to each maxillary segment was 5 cN. Microfocus x-ray computed tomography and histological analyses were used to compare the tooth movement and bone morphology in the midpalatal suture and buccal aspect of the alveolar process between the EXPT and CTRL groups. Descriptive statistics (mean \pm standard error of the mean) and nonparametric statistical tests were used to compare the outcomes across groups.

Results: Compared to the CTRL group, there was a statistically significant increase in buccal tooth movement and expansion of the midpalatal suture in the EXPT group. There was no difference in the bone morphologic parameters between groups. The mineral apposition rate was increased on the buccal surface of the alveolar process in the EXPT group.

Conclusions: Application of light, continuous force resulted in maxillary osseous expansion due to bilateral sutural apposition and buccal drift of the alveolar processes. This animal experiment provides a more physiologic basis for maxillary expansion. (*Angle Orthod.* 2018;88:306–313.)

KEY WORDS: Maxillary expansion; Orthodontic tooth movement

INTRODUCTION

The clinical signs of a transverse arch deficiency include posterior crossbite and/or dental crowding.¹ Orthodontic correction of maxillary constriction can be challenging as facial growth in the transverse dimension decreases during late childhood.² Expansion of the maxilla is usually achieved with rapid palatal expansion (RPE),³ but semirapid⁴ and slow (such as the Minne expander)⁵ expansion protocols have also been reported. Unfortunately, concerns about moving the roots of teeth through the buccal plate of bone and periodontal deterioration are common to all of the methods. Additionally, the force exerted by RPE appliances may often be as high as 15–50 N, producing deleterious side effects on the temporomandibular joint as well as the midpalatal suture and contributing to root resorption.^{6,7}

An alternative to the heavy force delivered by RPE appliances is the application of light, continuous buccal force to achieve maxillary expansion. Clinical outcomes indicate that this effect is physiologically

^a Assistant Professor, Department of Orthodontics and Oral Facial Genetics, Indiana University School of Dentistry, Indianapolis, Ind.

^b Research Tissue Processing Specialist, Indiana University Simon Cancer Center, Indianapolis, Ind.

^c Dental Student, Indiana University School of Dentistry, Indianapolis, Ind.

^d Graduate Student, Indiana University School of Dentistry, Indianapolis, Ind.

^e Professor Emeritus, Department of Orthodontics and Oral Facial Genetics, Indiana University School of Dentistry, Indianapolis, Ind.

Corresponding author: Dr Achint Utreja, Department of Orthodontics and Oral Facial Genetics, Indiana University School of Dentistry, 1121 West Michigan Street, Indianapolis, IN 46202

(e-mail: autreja@iupui.edu)

Accepted: December 2017. Submitted: July 2017.

Published Online: January 24, 2018

© 2018 by The EH Angle Education and Research Foundation, Inc.

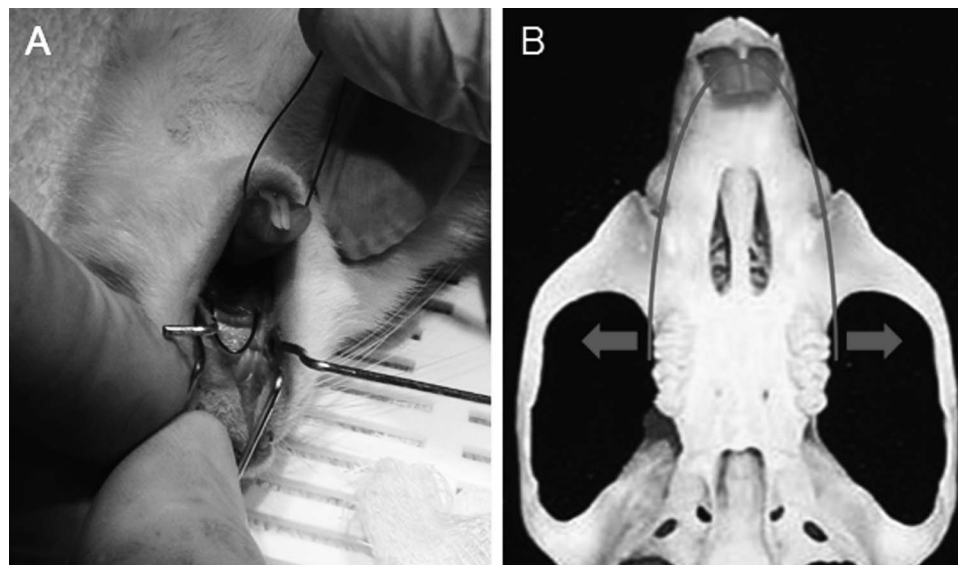


Figure 1. (A) Intraoral view of the activated archwire bonded on the maxillary molars in a rat. (B) Illustration showing the 0.014-inch copper-nickel-titanium (CuNiTi) wires in the resting state. The wire exerted force in the transverse dimension when it was activated by bonding on the occlusal surface of the maxillary first molars.

possible,^{8,9} but the underlying biological mechanisms are unknown. Periodontally healthy teeth can be moved extensively within the alveolar process; however, molar tooth movement in the buccal direction is thought¹⁰ to be limited by the thickness of the buccal plate of bone. Weinstein et al.¹¹ and Proffit¹² studied soft tissue pressure relative to the equilibrium theory of tooth position and concluded that cheek pressure as low as 1–2 g (1–2 cN) can cause tooth movement. Similar to conventional maxillary expansion with heavy force, a sutural response has been reported¹³ with light expansion force, but the adaptation of the buccal alveolar bone to such light, continuous force is unclear. In contrast to the severe buccal tipping and extrusion of molars exposed to RPE,^{14,15} an ideal outcome with light force would be remodeling of the buccal bone.

In light of previous observations and reports, the aim of this study was to assess the effects of light-force buccal expansion on the bone surfaces of the midpalatal suture, molar periodontal ligament (PDL) and buccal subperiosteal alveolar bone surface in an animal model. The hypothesis was that slow expansion of the maxillary arch with a light-force archwire results in physiologic expansion of the maxilla and remodeling of the buccal alveolar bone.

MATERIALS AND METHODS

Experimental Design and Appliance Placement

Twenty 6-week-old male Sprague-Dawley rats were randomly divided into two groups: experimental (EXPT) undergoing archwire expansion for 3 weeks and control (CTRL) not subjected to expansive force.

All experimental procedures were approved by the Institutional Animal Care and Use Committee.

An impression of the rodent maxilla was made with a polyvinyl siloxane (PVS) impression material and poured into orthodontic stone. The archwire expansion appliance was then fabricated on the stone model using a 0.014-inch copper-nickel-titanium (CuNiTi) archwire (Ormco Corp, Orange, Calif). A Memory-Maker[®] pulsed electric device (Forestadent Bernhard Förster GmbH, Pforzheim, Germany) was used to bend a pre-measured length of the NiTi wire to conform to the maxillary arch of the rat. The activated (expanded) archwire was adjusted to deliver 5 cN of force bilaterally within a range of 5 mm when bonded to the occlusal surfaces of the maxillary molars in the EXPT group (Figure 1A,B). Composite resin bite blocks were bonded to the terminal ends of the wire to maintain even bilateral posterior contacts.

All animals were maintained on a standard rodent diet. Fluorescent bone labels, calcein, alizarin, and tetracycline (Sigma-Aldrich, St Louis, Mo) were injected intraperitoneally 7, 4, and 2 days prior to euthanasia.

Microfocus X-Ray Computed Tomography Scan and Analysis

All animals were euthanatized after 3 weeks using CO₂ inhalation. The maxillae were dissected, fixed in 10% neutral buffered formalin, and then stored in 70% ethanol. Fixed maxillae were scanned using the Skyscan[®] 1172 microfocus x-ray computed tomography (micro-CT) scanner (Bruker microCT, Kontich,

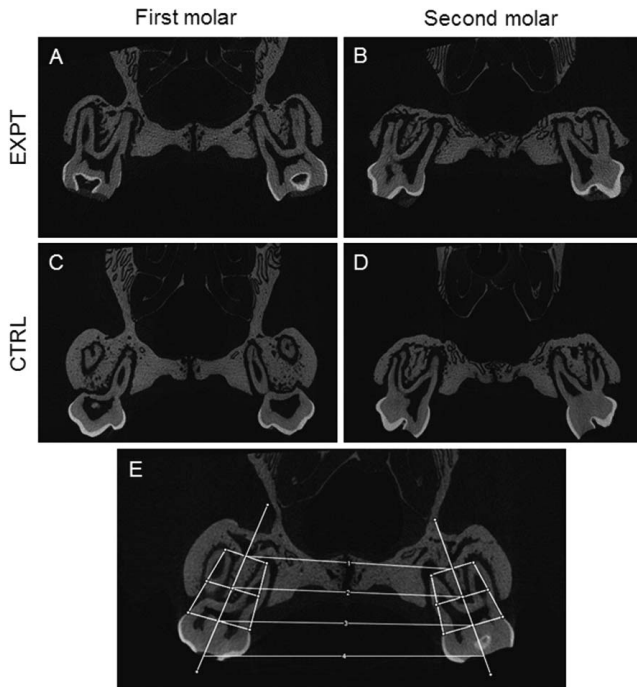


Figure 2. Micro-computed tomography (CT) scans from the experimental (EXPT; A, B) and control (CTRL; C, D) groups at the maxillary first (A, C) and second (B, D) molars. (E) Transverse measurements were performed at the root apex (1), midroot (2), cemento-enamel junction (CEJ) (3), and occlusal surface (4).

Belgium) at a resolution of 6.57 $\mu\text{m}/\text{pixel}$. The NRecon software (v1.6.9.1) was used to reconstruct three-dimensional scans from raw images, and these were then imported to the Ctan software (v1.13.5.1) for analyses.

Micro-CT scans were used to quantify changes in the transverse dimension, midpalatal suture, and buccal alveolar bone. Transverse distances between the first, second, and third maxillary molars were measured at the root apex, midroot, cemento-enamel junction (CEJ), and occlusal surface of each tooth (Figure 2E). The midpalatal suture was outlined in coronal sections, and the sutural area was measured. Regions of interest (ROIs) that were defined and used to quantify micro-CT parameters in the buccal alveolar bone bilaterally included 60 serial sagittal sections on each side.

Histological Imaging and Staining

Following micro-CT scanning, all tissue samples were processed and embedded in methyl methacrylate (Sigma-Aldrich). A rotary microtome (Leica Biosystems, Buffalo Grove, Ill) was used to obtain 4- μm -thick sections in the coronal plane. Images were taken at 10 \times and 40 \times magnification using a Nikon Eclipse Ni-U Microscope[®] with a color camera (Nikon Instruments, Melville, NY).

Table 1. Intermolar Width Measurements (in μm) at the Maxillary First and Second Molars in the Experimental (EXPT) and Control (CTRL) Groups. EXPT Group (Posttreatment) Measurements at the Root Apex, Midroot, Cementoenamel Junction (CEJ), and Occlusal Surface Were Significantly Increased Compared to the CTRL Group^a

	EXPT, μm	CTRL, μm	P Value
First molar			
Root apex (1)	5737 \pm 42.24	5434 \pm 54.03	**
Midroot (2)	6414 \pm 43.20	5953 \pm 33.23	**
CEJ (3)	7105 \pm 52.21	6496 \pm 24.44	**
Occlusal surface (4)	7868 \pm 91.95	7085 \pm 35.10	**
Second molar			
Root apex (1)	5684 \pm 106.1	5298 \pm 62.81	*
Midroot (2)	6195 \pm 106.2	5787 \pm 57.51	*
CEJ (3)	6715 \pm 114	6248 \pm 51.4	*
Occlusal surface (4)	7371 \pm 119.2	6875 \pm 53.38	*

^a Values are mean \pm SEM.

* $P < .05$; ** $P < .01$.

Tartrate-resistant acid phosphatase (TRAP) staining was performed to visualize osteoclasts, and von Kossa stain with MacNeal's tetrachrome counterstain was used to visualize new bone formation. The ROI included the alveolar bone adjacent to the buccal roots of the left and right maxillary molars. The separation between the fluorescent bone labels was measured, and bone parameters were quantified using the Bioquant Osteo software (Bioquant Image Analysis Corporation, Nashville, Tenn). Six animals from each group and a minimum of four histological sections/animal were used for quantification.

Statistical Analysis

The SPSS Statistics 24 software (IBM Corporation, Armonk, NY) was used to analyze the data. Descriptive statistics and the Kruskal-Wallis and Mann-Whitney U nonparametric statistical tests were used to compare the outcomes across groups. All statistical tests were two-sided (two tail), and the significance level was set at $P < .05$.

RESULTS

Compared to the CTRL group, micro-CT scans through the first molar areas of EXPT animals showed areas of PDL compression and sutural tension consistent with dental and orthopedic expansion of the maxilla. Bone surface analysis at the PDL interface was consistent with buccal tooth movement of the molars (Figure 2). At the first molar, the posttreatment intermolar width was significantly increased ($P < .01$) in the EXPT group compared to the CTRL group at the root apex, midroot, CEJ, and occlusal surface (Table 1). A similar trend was seen at the second molar, with the EXPT group displaying significantly greater ($P < .05$) measurements than the CTRL group (Table 1).

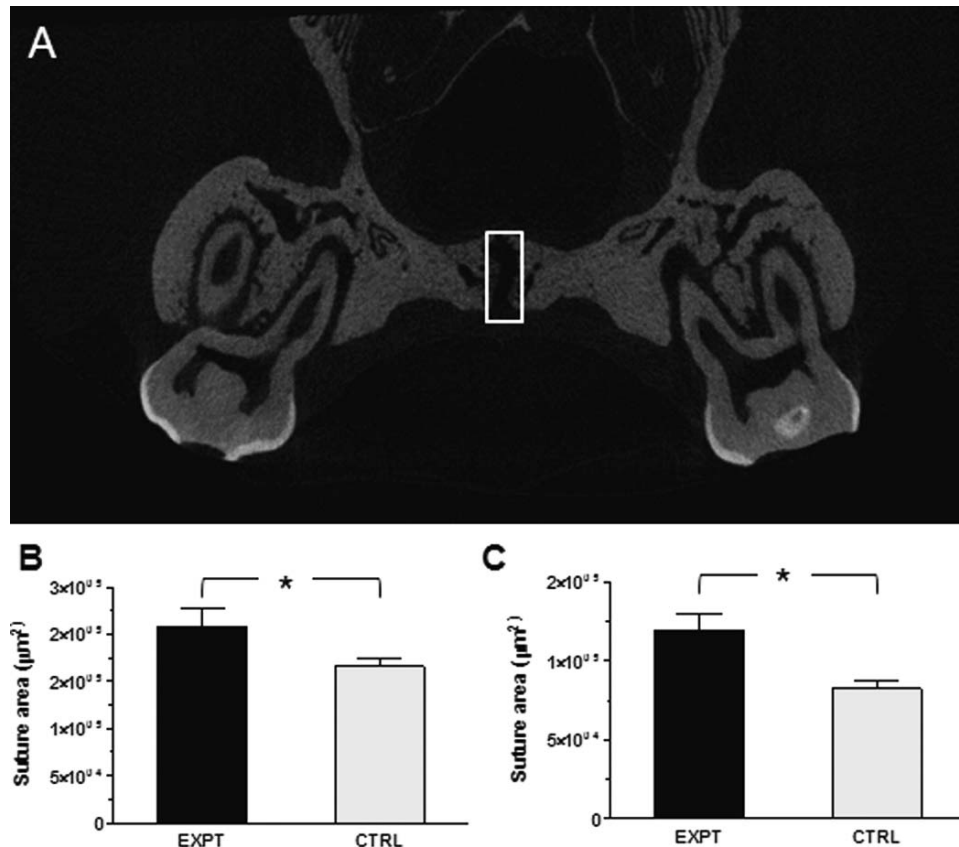


Figure 3. (A) The midpalatal suture area at the maxillary first (M1) and second (M2) molars was outlined in micro-computed tomography (CT) scans and compared between experimental (EXPT) and control (CTRL) groups. The suture area in the EPXT group was significantly increased ($P < .05$) at M1 (B) and M2 (C).

In coronal sections from micro-CT scans, the midpalatal suture area was significantly increased in the EXPT group compared to the CTRL group at both the first and second molars ($P < .05$) (Figure 3B,C), indicating sutural expansion. Analysis of the ROI in the left and right buccal bone (Figure 4A,B) indicated no change in bone parameters such as percent bone volume (BV/TV), bone surface/volume ratio (BS/BV), bone surface density (BS/TV), trabecular thickness (Tb.Th), trabecular number (Tb.N), and trabecular spacing (Tb.Sp) between EXPT and CTRL groups (Figure 4C–H).

Composite fluorescent histological images of the maxilla showed a distinct separation between fluorescent bone labels in the EXPT group compared to the CTRL group (Figure 5A,B). The separation between the fluorescent labels was quantified at the left and right buccal bone (Figure 6A,C,D,F) and in the suture (Figure 6B,E). At the 5-day interval, both interlabel width and the mineral apposition rate were significantly higher in the EXPT group compared to the CTRL group in the buccal (Figure 6G,H) and suture (Figure 6I,J) regions ($P < .05$). A trend for increase in both variables

was also noted at the 3-day interval in the EXPT group (Figure 5K,L).

Comparison of von Kossa staining for mineralized tissues showed separation of the midpalatal suture and regions of bone remodeling adjacent to the suture in the EXPT group but not in the CTRL group (Figure 7A,C). TRAP staining demonstrated increased osteoclastic activity in areas of remodeling beneath the cortical plate of the suture (Figure 7B,D). Histological analysis of the left and right buccal regions also showed increased osteoclastic activity along the resorbing surfaces in the EXPT group (Figure 7E,G).

DISCUSSION

Orthodontists have traditionally addressed transverse dimension discrepancies between the maxillary and mandibular arches by rapid maxillary expansion. Advocates of early orthopedic treatment list various health benefits in growing children, including decreased need for subsequent treatment later in life.¹⁶ However, increasing evidence suggests that loss of buccal alveolar bone seen in patients undergoing the procedure is not an ideal dentoalveolar outcome.^{15,17}

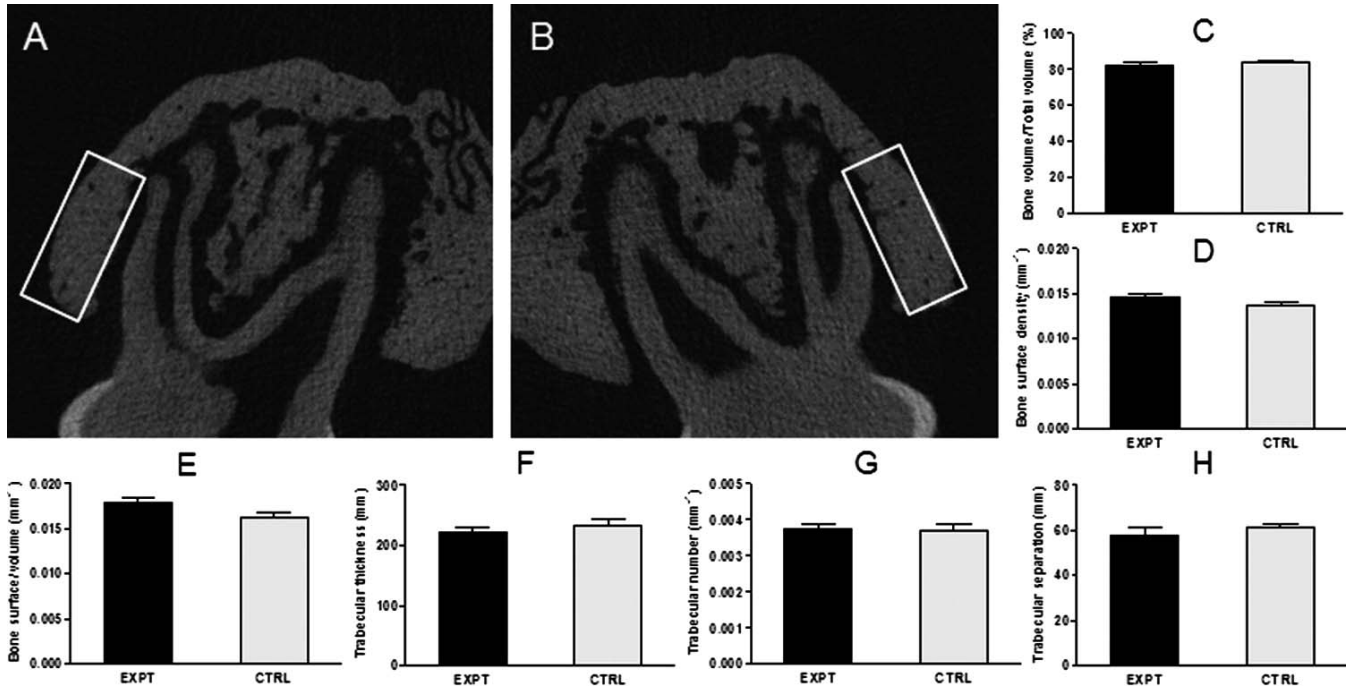


Figure 4. The left (A) and right (B) buccal bone was outlined in micro-computed tomography (CT) scans and compared between the experimental (EXPT) and control (CTRL) groups. Bone parameters including (C) percent bone volume (BV/TV), (D) bone surface density (BS/TV), (E) bone surface/volume (BS/BV), (F) trabecular thickness (Tb.Th), (G) trabecular number (Tb.N), and (H) trabecular separation were not different among the groups.

Slow maxillary expansion with light forces delivered either by archwires or appliances^{18,19} is an alternative and, based on the results of this animal study, results in maintenance of buccal alveolar bone.

Transverse tooth movement in the EXPT and CTRL groups in this study was compared by measuring

intermolar widths at four regions (root apex, midroot, CEJ, and occlusal surface) along the long axis of the molars. The results showed a significant increase in intermolar width at each region, suggesting that varying magnitudes of maxillary expansion occurred from the occlusal surface to the root apex of the

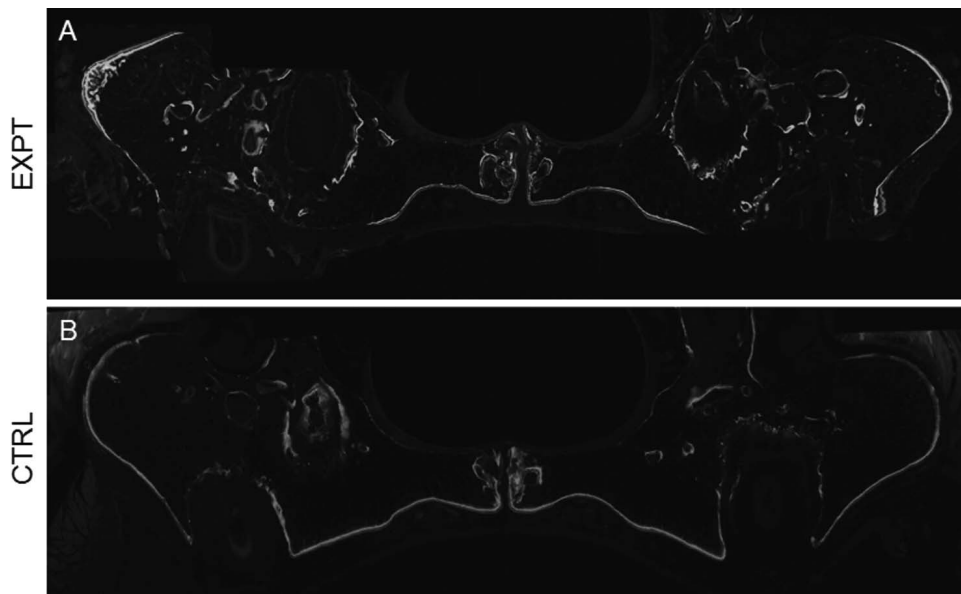


Figure 5. Fluorescent bone labels calcein, alizarin, and tetracycline were injected 7, 4, and 2 days prior to euthanasia. Distinct separation between the labels was seen in the (A) experimental (EXPT) group compared to the (B) control (CTRL) group.

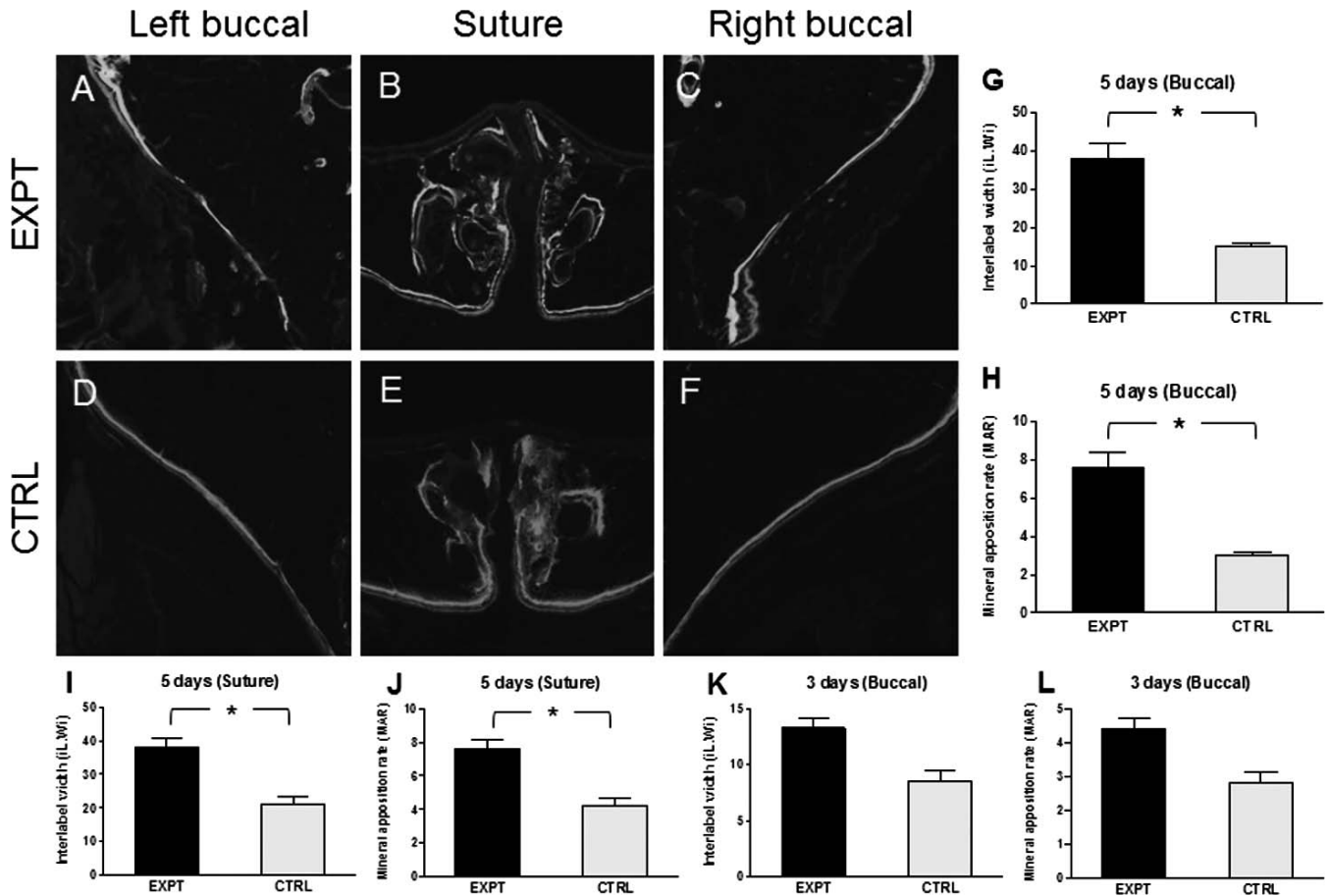


Figure 6. Comparison of the fluorescent bone labels between the experimental (EXPT) and control (CTRL) groups in the left buccal (A, D), suture (B, E), and right buccal (C, F) regions showed significantly increased interlabel width (G, I, K) and mineral apposition rate (H, J, L) at 5- and 3-day intervals in the EXPT group compared to the CTRL group ($P < .05$).

molars. This effect was observed at both the first and second molars, even though the archwire was bonded to the occlusal surfaces of the maxillary first molars. Danz et al.²⁰ utilized beta-titanium springs with two levels of force to expand maxillary molars and reported root translation in the animal groups. Although the results are not directly comparable to those of the current study because of differences in the appliance, force levels, and analysis methods, the trends are similar.

The midpalatal suture area was significantly increased in the EXPT group undergoing archwire expansion, suggesting that the light, continuous force was sufficient to separate the maxillary processes. Histological examination of the suture showed collagen fibers under tension, similar to the results reported in mice.²¹ This trend was observed at both first and second maxillary molars, suggesting that the effect of archwire expansion was not restricted to the point of attachment (first molar). The maxillary molars were expanded as segments, but as expected, the effect

was greatest on the first molars because they were nearest to the active segment of wire.

Quantification of the bone parameters in the buccal bone region showed no differences between the EXPT and CTRL groups in this study. This suggests that tooth movement in the transverse direction did not lead to bone loss and is not expected to produce bone dehiscence. These findings differ from the results of Kraus et al.,²² who reported changes in buccal bone thickness following expansion with light to moderate forces in dogs. A direct comparison between the studies is not possible as a result of differences in the animal model, force levels, and measurement methods. The measurements in the current study included the bone surrounding the buccal roots of the rat maxillary first molar and are a reliable indicator of changes in buccal bone parameters following light, continuous expansive force.

Incorporation of fluorescent bone labels during bone modeling and remodeling provides a reliable estimate of bone apposition in expanding sutures.²³ In this study, increased intensity of fluorescent labeling in the EXPT

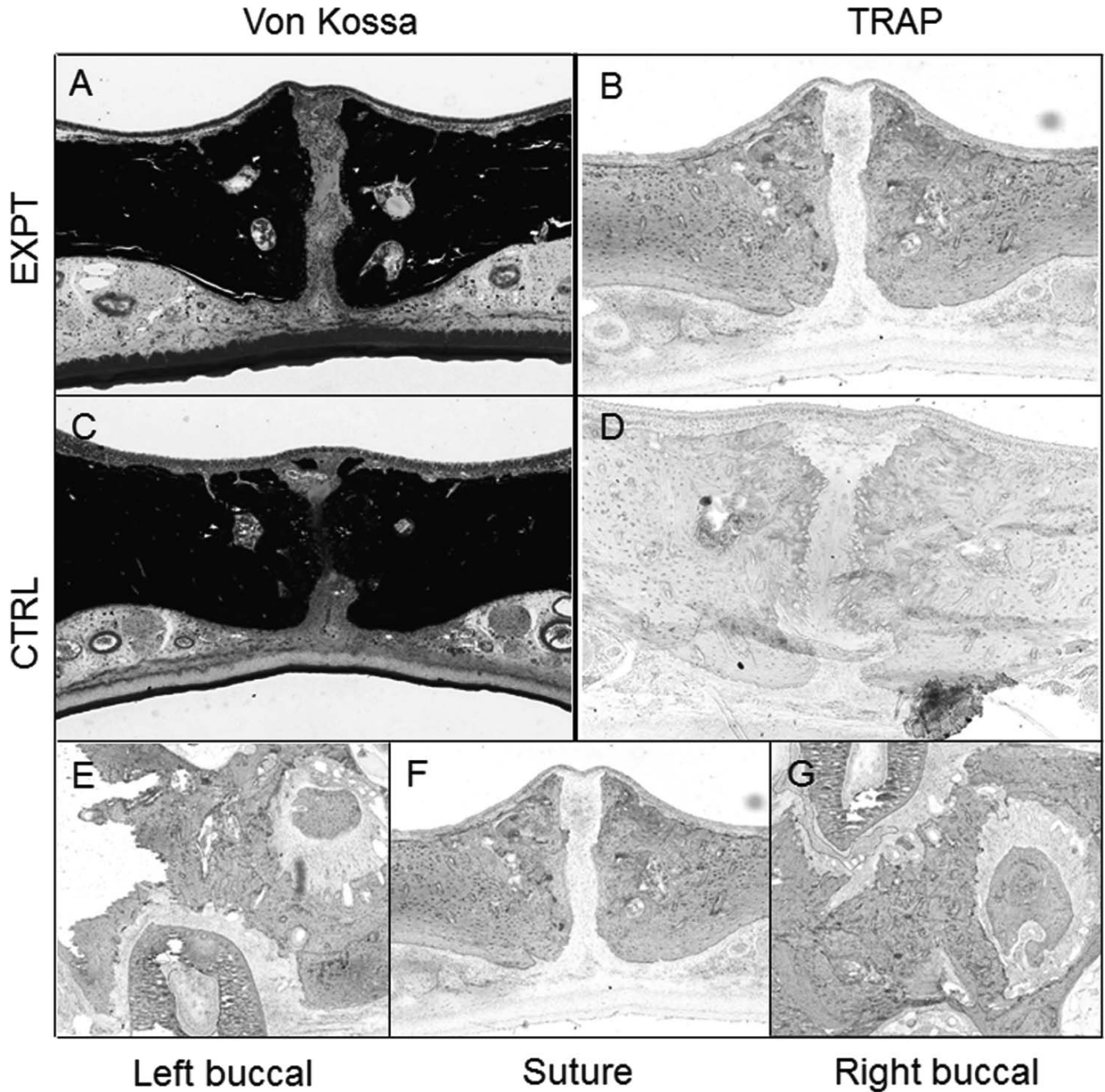


Figure 7. von Kossa and MacNeal's tetrachrome counterstain for mineralized tissue demonstrated separation of the suture in the experimental (EXPT) group (A) compared to the control (CTRL) group (C). Tartrate-resistant acid phosphatase (TRAP) staining showed increased osteoclastic activity in the EXPT (B) group compared to the CTRL group (D). Osteoclast activity seen as TRAP-positive areas in the left buccal (E), suture (F), and right buccal (G) regions of the EXPT group.

group and greater separation between fluorescent labels injected 5 days apart indicated enhanced bone deposition consistent with bone modeling and remodeling in the midpalatal suture as well as the buccal bone. The mineral apposition rate that evaluates changes in cortical bone was also increased, indicating significant overall modeling and remodeling changes. Additionally, increased osteoclastic bone resorption

was seen near the midpalatal suture and at the PDL interface. These resorptive effects were consistent with catabolic modeling of the PDL interface in the direction of tooth movement and remodeling of the new bone formed by anabolic modeling at the suture interface.²⁴ Collectively these findings indicate that light, continuous force produces bone modeling and remodeling patterns associated with new bone formation along the

labial plate of bone.²⁵ The current research supports the interactive bone modeling and remodeling response to applied loads first advocated by Frost.²⁴

Overall, the results from this animal study indicate that maxillary expansion with light, continuous force is a viable alternative to RME with heavy, interrupted forces because the molars maintained healthy periodontal support as the alveolar process was expanded. Clinical studies are indicated to test this approach for palatal expansion to determine its stability and long-term periodontal effects.

CONCLUSIONS

- Archwire expansion with a light, continuous force in an animal model resulted in sutural expansion and buccal tooth movement of the maxillary molars.
- Light, continuous force resulted in patterns of osteoclastic bone resorption and osteoblastic bone deposition consistent with the bone modeling and remodeling reactions expected for physiologic maxillary expansion.

ACKNOWLEDGMENTS

The authors acknowledge the assistance provided by Dr Na Kang and thank Gene Ruffing from Ormco Corporation for providing the orthodontic archwires. This work was supported by the American Association of Orthodontists Foundation.

REFERENCES

1. Betts NJ, Vanarsdall RL, Barber HD, Higgins-Barber K, Fonseca RJ. Diagnosis and treatment of transverse maxillary deficiency. *Int J Adult Orthod Orthognath Surg*. 1995;10:75–96.
2. Edwards CB, Marshall SD, Qian F, Southard KA, Franciscus RG, Southard TE. Longitudinal study of facial skeletal growth completion in 3 dimensions. *Am J Orthod Dentofacial Orthop*. 2007;132:762–768.
3. Cross DL, McDonald JP. Effect of rapid maxillary expansion on skeletal, dental, and nasal structures: a postero-anterior cephalometric study. *Eur J Orthod*. 2000;22:519–528.
4. Iseri H, Ozsoy S. Semirapid maxillary expansion—a study of long-term transverse effects in older adolescents and adults. *Angle Orthod*. 2004;74:71–78.
5. Akkaya S, Lorenzon S, Ucem TT. Comparison of dental arch and arch perimeter changes between bonded rapid and slow maxillary expansion procedures. *Eur J Orthod*. 1998;20:255–261.
6. Langford SR, Sims MR. Root surface resorption, repair, and periodontal attachment following rapid maxillary expansion in man. *Am J Orthod*. 1982;81:108–115.
7. Linder-Aronson S, Lindgren J. The skeletal and dental effects of rapid maxillary expansion. *Br J Orthod*. 1979;6:25–29.
8. Basciftci FA, Akin M, Ileri Z, Bayram S. Long-term stability of dentoalveolar, skeletal, and soft tissue changes after non-extraction treatment with a self-ligating system. *Korean J Orthod*. 2014;44:119–127.
9. Fleming PS, Lee RT, McDonald T, Pandis N, Johal A. The timing of significant arch dimensional changes with fixed orthodontic appliances: data from a multicenter randomised controlled trial. *J Dent*. 2014;42:1–6.
10. Saffar JL, Lasfargues JJ, Cherruau M. Alveolar bone and the alveolar process: the socket that is never stable. *Periodontol 2000*. 1997;13:76–90.
11. Weinstein S, Haack DC, Morris LY, Snyder BB, Attaway HE. On an equilibrium theory of tooth position. *Angle Orthod*. 1963;33:1–26.
12. Proffit WR. Equilibrium theory revisited: factors influencing position of the teeth. *Angle Orthod*. 1978;48:175–186.
13. Darendeliler MA, Strahm C, Joho JP. Light maxillary expansion forces with the magnetic expansion device. A preliminary investigation. *Eur J Orthod*. 1994;16:479–490.
14. Baysal A, Uysal T, Veli I, Ozer T, Karadede I, Hekimoglu S. Evaluation of alveolar bone loss following rapid maxillary expansion using cone-beam computed tomography. *Korean J Orthod*. 2013;43:83–95.
15. Woller JL, Kim KB, Behrents RG, Buschang PH. An assessment of the maxilla after rapid maxillary expansion using cone beam computed tomography in growing children. *Dental Press J Orthod*. 2014;19:26–35.
16. McNamara JA Jr, Lione R, Franchi L, et al. The role of rapid maxillary expansion in the promotion of oral and general health. *Prog Orthod*. 2015;16:33.
17. Podesser B, Williams S, Crismani AG, Bantleon HP. Evaluation of the effects of rapid maxillary expansion in growing children using computer tomography scanning: a pilot study. *Eur J Orthod*. 2007;29:37–44.
18. Martina R, Cioffi I, Farella M, et al. Transverse changes determined by rapid and slow maxillary expansion—a low-dose CT-based randomized controlled trial. *Orthod Craniofac Res*. 2012;15:159–168.
19. Vajaria R, BeGole E, Kusnoto B, Galang MT, Obrez A. Evaluation of incisor position and dental transverse dimensional changes using the Damon system. *Angle Orthod*. 2011;81:647–652.
20. Danz JC, Dalstra M, Bosshardt DD, Katsaros C, Stavropoulos A. A rat model for orthodontic translational expansive tooth movement. *Orthod Craniofac Res*. 2013;16:223–233.
21. Hou B, Fukai N, Olsen BR. Mechanical force-induced midpalatal suture remodeling in mice. *Bone*. 2007;40:1483–1493.
22. Kraus CD, Campbell PM, Spears R, Taylor RW, Buschang PH. Bony adaptation after expansion with light-to-moderate continuous forces. *Am J Orthod Dentofacial Orthop*. 2014;145:655–666.
23. Liu SS, Kyung HM, Buschang PH. Continuous forces are more effective than intermittent forces in expanding sutures. *Eur J Orthod*. 2010;32:371–380.
24. Roberts WE, Roberts JA, Epker BN, Burr DB, Hartsfield JK Jr. Remodeling of mineralized tissues, Part I: the Frost legacy. *Semin Orthod*. 2006;12:216–237.
25. Roberts WE. Bone physiology, metabolism and biomechanics in orthodontic practice. In: Graber LW, Vanarsdall RLJ, Vig KWL, eds. *Orthodontics: Current Principles and Techniques*. St Louis, Mo: Elsevier Mosby; 2012:287–343.