

ORIGINAL ARTICLE

Salvage Surgery After Radiotherapy for Laryngeal Cancer

From Endoscopic Resections to Open-Neck Partial and Total Laryngectomies

Cesare Piazza, MD; Giorgio Peretti, MD; Augusto Cattaneo, MD; Francesco Garrubba, MD; Luca Oscar Redaelli De Zinis, MD; Piero Nicolai, MD

Objective: To evaluate our experience in management of radiotherapy failure using endoscopic resection (ER) with carbon dioxide laser, open-neck partial laryngectomy (ONPL), and total laryngectomy.

Design: Retrospective medical record review.

Setting: Referral university hospital.

Patients: Seventy-one patients with laryngeal cancer previously treated with radiotherapy (69 patients) and chemoradiotherapy (2 patients) underwent salvage surgery.

Interventions: The treatment policy encompassed ER for glottic rT1a, rT1b with limited anterior commissure involvement, and rT2 with normal cord mobility carcinoma. All ONPLs were performed for rT1 and rT2 tumors with suboptimal endoscopic exposure, rT2 tumors with impaired cord mobility or transcommissural extension, and rT3 tumors for limited paraglottic space invasion or involvement of the inner portion of the thyroid cartilage. Total laryngectomy was planned in patients who were not suitable for partial laryngectomy owing to poor general condition, for rT3 carcinoma with

massive involvement of the paraglottic space, and for rT4a tumors.

Main Outcome Measures: Clinical, radiologic, surgical, and pathologic data. Survival curves were calculated using the Kaplan-Meier method. Comparisons between different variables were performed using the log-rank test.

Results: Salvage surgery consisted of ER in 22 patients, ONPL in 15, and total laryngectomy in 34. The pT category after salvage surgery was pT1 in 12 patients, pT2 in 20, pT3 in 20, and pT4a in 19. Five-year disease-specific and disease-free survival and laryngeal preservation for the entire series were 72%, 61%, and 40%, respectively.

Conclusions: Survival rates for the entire series were not different from those previously reported using a more aggressive surgical approach without attempts at organ preservation. The laryngeal preservation rate justifies conservative treatment in the presence of limited recurrent lesions.

Arch Otolaryngol Head Neck Surg. 2007;133(10):1037-1043

RADIODTHERAPY AND, MORE recently, organ preservation protocols using concomitant chemoradiotherapy are becoming the most common first-line treatments for many patients with laryngeal cancer. Although 5-year local control rates for radiotherapy in T1 and T2 laryngeal carcinoma range from 67% to 93% and progressively decline with increasing T category, recurrence rates of 21% to 37% for T1 and T2 glottic lesions and 30% to 45% for T1 and T2 supraglottic lesions are frequently reported even in large series.¹⁻³ In many centers, total laryngectomy (TL) is still considered the safest and easiest salvage option after radiotherapy failure even though it sacrifices the voice, requires a

permanent stoma, and is frequently associated with serious perioperative complications. Such a treatment strategy is only in part justified by the frequently observed progression of initially staged T1



CME available online at www.archoto.com

and T2 tumors toward more extensive lesions, by an understandable tendency to more aggressively treat recurrences, and by objective difficulties in correctly restaging the tumor in patients who have previously undergone irradiation.

A variety of studies^{4,21} addressing the results of different conservative options after radiotherapy failure for selected pa-

Author Affiliations:
Department of
Otorhinolaryngology, University
of Brescia, Brescia, Italy.

Table 1. Preradiotherapy, Clinical, and Pathologic T Categories of the Laryngeal Tumors in the 71 Patients in the Present Series

T Category ^a	Patients, No. (%)		
	Preradiotherapy Staging	Recurrence Staging	
		Clinical	Pathologic
T1a	28 (40)	10 (14)	10 (14)
T1b	5 (7)	7 (10)	2 (3)
T2	15 (21)	29 (41)	20 (28)
T3	15 (21)	18 (25)	20 (28)
T4a	8 (11)	7 (10)	19 (27)

^aAccording to the most recent edition of the American Joint Committee on Cancer TNM staging system.³¹

tients with a disease control at least comparable with that obtained with TL have been published: they encompass endoscopic resection (ER) with carbon dioxide laser^{4,22-28} and different types of open-neck partial laryngectomy (ONPL). Comparisons between different selection criteria, oncologic and functional outcomes, and complication rates for each surgical approach are possible, as detailed in the recent review by Motamed et al.²⁹ However, biases deriving from nonhomogeneous recruitment modalities, differences in radiation and surgical techniques, and various follow-up modalities are unavoidable when comparing series from different institutions.

To our knowledge, this is the second study, after that recently published by Holsinger et al³⁰ from the M. D. Anderson Cancer Center, that comprehensively addresses all available salvage surgical options (ER, ONPL, and TL with or without flaps) applied at the same institution and based on a homogeneous, retrospective series of unselected patients. This allows direct comparisons in terms of indications, oncologic outcomes, and complication rates among the different surgical approaches.

METHODS

Between January 17, 1995, and March 23, 2004, 71 patients (male to female ratio, 68:3; mean age, 63.4 years; age range, 45-86 years) with laryngeal squamous cell carcinoma previously treated with radiotherapy (69 patients) and chemoradiotherapy (2 patients) were treated at the Department of Otorhinolaryngology, University of Brescia, by 1 of the 5 senior surgeons, or under their direct supervision, sharing a common therapeutic strategy. Salvage surgery was indicated for persistence (tumor in the same or adjacent sites of the primary lesion detected <6 months after the completion of nonsurgical treatment) in 11 patients, recurrence (tumor diagnosed 6-60 months after the end of treatment) in 50 patients, or second laryngeal tumor (neoplasm arising > 60 months after management of the first tumor) in 10 patients.

Medical record review was performed to obtain clinical, radiologic, surgical, and pathologic data. Preradiotherapy staging was retrospectively reassessed according to the 2002 American Joint Committee on Cancer TNM staging system (**Table 1**). All the patients received radiotherapy using cobalt 60, with a mean dose of 68 Gy (to convert to rad, multiply by 100) (range, 64-72 Gy), delivered daily as 2 Gy for 5 days per week. Pa-

tients with T1 lesions received narrow-field radiation to the primary site, and patients with higher T categories also received radiotherapy to nodal groups II to IV. Concomitant chemoradiotherapy was administered to 2 patients affected by a T3 transglottic tumor and consisted of fluorouracil, 1000 mg/m² per day, and cisplatin, 20 mg/m² per day, both given as continuous intravenous infusions for 4 days beginning on the first and fourth weeks of radiotherapy. The mean disease-free interval between the end of nonsurgical organ preservation treatment and the diagnosis of recurrence, persistence, or a second laryngeal tumor for the entire series was 19 months (range, 3-113 months).

All the patients were preoperatively examined by means of fiberoptic laryngoscopy, videolaryngostroboscopy, and computed tomography or magnetic resonance imaging to assess the superficial and deep extension of the lesion in the visceral compartments and to exclude or quantify involvement of the laryngeal framework. Ultrasonography of the neck with or without fine-needle aspiration cytologic examination was performed in selected patients with clinically evident neck metastases or tumors with a high risk of occult nodal disease. Moreover, all the patients underwent microlaryngoscopic examination using 0° and angled rigid endoscopes (Karl Storz, Tuttlingen, Germany) to improve clinical and radiologic staging of the lesion. Accordingly, we obtained preoperative staging of these patients as reported in Table 1. After accurate restaging of the recurrent lesion and comprehensive evaluation of the patient's general condition, every case was thoroughly discussed in a collegial form during preoperative counseling to clearly explain the different therapeutic options (if available) along with their advantages and disadvantages to the patient.

The treatment policy encompassed ER for glottic rT1a tumors, rT1b tumors with limited anterior commissure involvement, and rT2 tumors with normal cord mobility. An essential prerequisite for this approach was adequate laryngeal exposure as determined during the initial microlaryngoscopic examination. The ER was performed using a carbon dioxide laser (Sharplan 1055 S) coupled with a micromanipulator (AcuSpot 712) (Sharplan, Tel Aviv, Israel) with superpulse emission in continuous mode (2.5-5.0 W, 270-μm spot size). The procedures were categorized according to the European Laryngological Society classification.³² No patient in this group received either a tracheotomy or a feeding tube. Oral feeding always began the day after surgery.

The ONPLs were performed for rT1 and rT2 lesions with suboptimal endoscopic exposure, rT2 lesions with impaired cord mobility or transcommissural extension, and rT3 lesions for limited paraglottic space invasion or involvement of the inner portion of the thyroid cartilage. Paraglottic space invasion and erosion of the inner portion of the thyroid cartilage were preoperatively evaluated by means of radiologic imaging. In particular, minimal paraglottic space involvement was defined as that observed in patients with rT2 glottic tumors with normal or reduced vocal cord mobility in which the fat tissue lateral to the vocal muscle was partially encroached on by the neoplasm but not completely replaced by the tumor. Moreover, candidacy for conservation laryngeal surgery was evaluated preoperatively in all patients by using pulmonary function tests and cardiologic examination to assess the adequacy of patients' general condition. The types of ONPL performed included horizontal supraglottic laryngectomy and supracricoid partial laryngectomy (SCPL) with cricothyroidopexy, with cricothyroidopexy, and with tracheocricothyroidopexy. All patients underwent intraoperative tracheotomy at the fourth to sixth tracheal ring, with an inferiorly based tracheal flap and a feeding tube. When patients could breathe through the natural airway, the tracheotomy tube was plugged and definitively removed after 48 hours of effortless breathing. Swallowing rehabilitation usually began 10 to 12 days af-

ter surgery, beginning with soft foods. Voice rehabilitation began 2 to 3 days after surgery to avoid ankylosis of the cricoarytenoid joint.

Total laryngectomy as first-line salvage treatment was planned in patients who were not suitable for ONPLs owing to poor overall health status and locoregional conditions (massive laryngeal edema, suggestion of chondronecrosis, and diffuse fibrosis of the neck), for rT3 tumors with massive involvement of the paraglottic space (tumors with complete fixation of the vocal cord or with radiologic evidence of complete neoplastic obliteration of the fat-filled space located lateral to the vocal muscle), and for rT4a cancers. Primary flaps were used either as an external covering of a regular neopharyngeal suture or as a patch in case of insufficient pharyngeal tissue, whereas secondary flaps were applied to close pharyngocutaneous fistulas that were not responsive to standard conservative treatment. A nasogastric feeding tube was always positioned during surgery and was usually removed 12 days after surgery in the absence of overt clinical signs of fistula or a negative barium swallow test result. Pathologic staging after salvage surgery in patients included in groups A, B, and C is reported in Table 1.

All patients treated by ER (group A) had a clinically normal neck according to results of palpation, ultrasonography, and computed tomography and therefore did not undergo neck dissection. In contrast, 8 of 15 patients (53%) treated by ONPLs (group B) and all patients undergoing TL (group C) were concomitantly treated with unilateral or bilateral neck dissection.

All patients received postoperative prophylactic antibiotic drug therapy for at least 8 days, even when scheduled for ER, to reduce the possibility of postoperative chondritis and chondronecrosis. In the case of ONPLs, antibiotic agents were given for the duration of swallowing rehabilitation to prevent aspiration pneumonia, whereas in patients undergoing TL, antibiotic drug therapy was usually discontinued after feeding tube removal in the absence of clinically evident salivary fistulas. The most frequently used antibiotics were ampicillin sodium plus sulbactam sodium (1.5 g intravenously 3 times daily), associated with ciprofloxacin (200 mg intravenously twice daily) and metronidazole phosphate (500 mg intravenously 3 times daily) only in the case of pulmonary or locoregional complications.

Follow-up visits included fiberoptic examination every 2 months, computed tomography of the larynx every 12 months, and, when indicated, ultrasonography of the neck every 6 months. The last follow-up was in March 2006 (mean follow-up, 46 months; range, 6-121 months), and 5-year overall, disease-specific, and disease-free survival and laryngeal preservation rates were calculated using the Kaplan-Meier method for the entire series and for each group of patients. Comparisons of different variables using the log-rank test were performed. Statistical analysis was performed using a commercially available computer software package (SPSS; SPSS Inc, Chicago, Illinois).

RESULTS

Group A was composed of 22 patients (31%) treated with ER, including 9 transmuscular (type III) cordectomies (for glottic rT1a tumors), 4 total (type IV) cordectomies (for glottic rT2 tumors with impaired cord mobility), and 9 extended (type V) cordectomies (further subgrouped into 5 type Va cordectomies [ie, extended to the anterior commissure and contralateral vocal cord for rT1b tumors involving both vocal cords] and 4 type Vc cordectomies [ie, extended to the bottom and roof of the ventricle, including the false vocal fold for glottic-supraglottic rT2 tumors with normal cord mobility and without radiologic evidence of paraglottic space inva-

Table 2. Preradiotherapy, Clinical, and Pathologic T Categories of the 22 Patients in Group A

T Category ^a	Patients, No.		
	Preradiotherapy Staging	Recurrence Staging	
		Clinical	Pathologic
T1a	16	9	9
T1b	2	5	2
T2	2	8	11
T3	2	0	0
T4a	0	0	0

^a According to the most recent edition of the American Joint Committee on Cancer TNM staging system.³¹

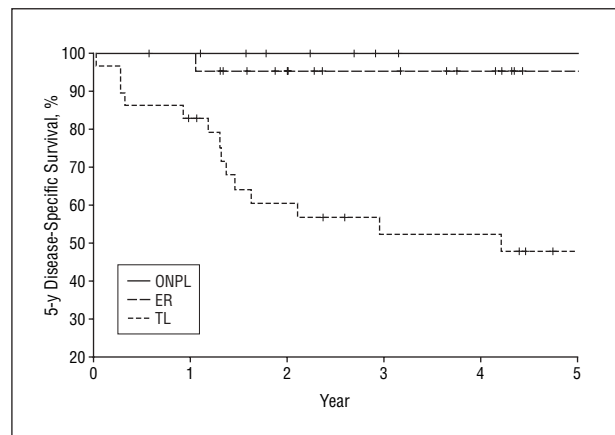


Figure 1. Five-year disease-specific survival for group A (endoscopic resection [ER]), group B (open-neck partial laryngectomy [ONPL]), and group C (total laryngectomy [TL]) according to the Kaplan-Meier method.

sion)). The preradiotherapy, clinical (before salvage surgery), and pathologic (after salvage surgery) T categories are reported in Table 2. Hospitalization ranged from 3 to 9 days (mean, 4 days). Early complications (within 1 month of surgery) were not encountered. Three patients (14%) experienced late thyroid cartilage chondritis (1 patient) or chondronecrosis (2 patients), which were all successfully treated with hyperbaric oxygen therapy. At the last follow-up visit, 14 patients were alive and well (despite TL in 1 patient initially staged as having rT1b carcinoma and further ERs in 3 patients, 1 initially staged as rT1a and 2 as rT2), 1 patient treated for an rT1a tumor was alive with disease at the stomal site after another recurrence requiring TL, 1 patient with an rT2 lesion died of laryngeal cancer despite TL for a subsequent recurrence, and 6 patients died of other causes (myocardial infarction in 2, stroke in 2, hepatocarcinoma after TL for further recurrence in a previously rT2 lesion in 1, and renal failure in 1). Of the 7 patients with recurrence after salvage laser surgery, 1 had anterior commissure involvement (rT1b) when first seen after radiotherapy, and 4 had rT2 lesions (2 with anterior commissure extension). Kaplan-Meier curves for group A showed 5-year disease-specific survival, disease-free survival, and laryngeal preservation of 95%, 63%, and 75%, respectively (Figures 1, 2, and 3).

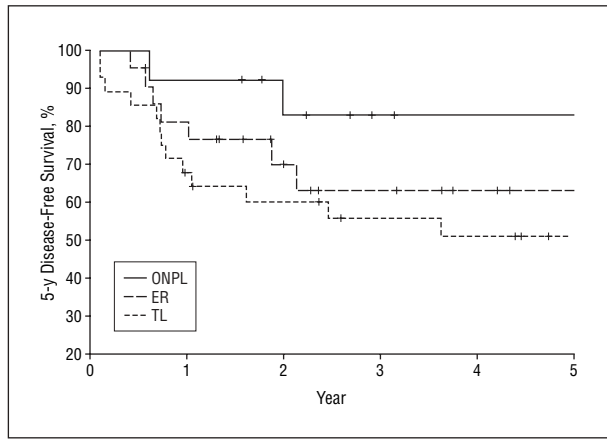


Figure 2. Five-year disease-free survival for group A (endoscopic resection [ER]), group B (open-neck partial laryngectomy [ONPL]), and group C (total laryngectomy [TL]) according to the Kaplan-Meier method.

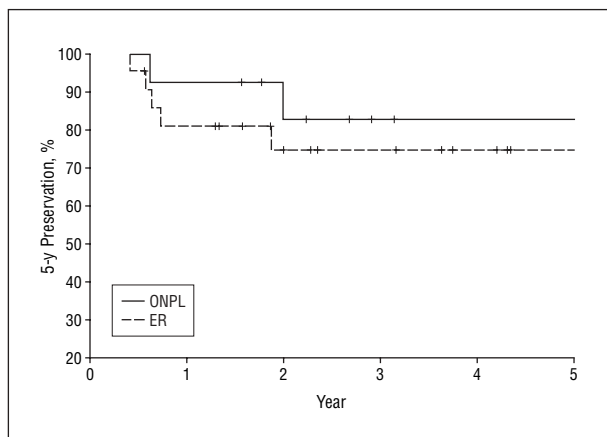


Figure 3. Five-year laryngeal preservation rates for group A (endoscopic resection [ER]) and group B (open-neck partial laryngectomy [ONPL]) according to the Kaplan-Meier method.

Group B consisted of 15 patients (21%) treated by ONPLs distributed as follows: horizontal supraglottic laryngectomy (1 patient with an rT2 supraglottic tumor) and SCPL with cricothyroidopiglottopexy (9 patients: 1 with a glottic rT1a tumor, 1 with a glottic rT1b tumor, and 7 with a glottic rT2 tumor with impaired cord mobility), cricothyroidopexy (4 patients with glottic-supraglottic rT2 lesions), and tracheocricothyroidopiglottopexy (1 patient with a glottic-subglottic rT2 tumor). The preradiotherapy, clinical, and pathologic T categories are reported in **Table 3**. Hospitalization ranged from 16 to 50 days (mean, 30 days). Decannulation was achieved in all patients, with intervals from surgery ranging from 10 to 120 days (mean, 41 days). Removal of the feeding tube was also accomplished in all patients, with an interval of 14 to 120 days (mean, 38 days). Early complications were observed in 6 patients (40%) and consisted of 1 pharyngocutaneous fistula with massive bleeding requiring TL and internal jugular vein ligation, 2 cases of aspiration pneumonia at the beginning of swallowing rehabilitation (in 1 case requiring percutaneous endoscopic gastrostomy, removed 50 days later), 2 partial dehiscences of the pexy (healed after hyperbaric oxygen therapy), and 1 limited dehiscence of the cervical wound

Table 3. Preradiotherapy, Clinical, and Pathologic T Categories of the 15 Patients in Group B

T Category ^a	Patients, No.		
	Preradiotherapy Staging	Recurrence Staging	
		Clinical	Pathologic
T1a	7	1	1
T1b	0	1	0
T2	7	13	6
T3	1	0	8
T4a	0	0	0

^a According to the most recent edition of the American Joint Committee on Cancer TNM staging system.³¹

Table 4. Preradiotherapy, Clinical, and Pathologic T Categories of the 34 Patients in Group C

T Category ^a	Patients, No.		
	Preradiotherapy Staging	Recurrence Staging	
		Clinical	Pathologic
T1a	5	0	0
T1b	3	1	0
T2	6	8	3
T3	12	18	12
T4a	8	7	19

^a According to the most recent edition of the American Joint Committee on Cancer TNM staging system.³¹

(healed by second intention). Late complications (in particular, aspiration pneumonia) were not encountered. At the last follow-up visit, 13 patients were alive and well (despite 2 TLs, in 1 patient for perioperative complications and in another for a second recurrence on the residual larynx in an rT3 tumor), 1 was alive with regional disease after TL and neck dissection in an initially staged rT2 lesion, and 1 had died of a stroke. Kaplan-Meier curves for this group showed 5-year disease-specific survival, disease-free survival, and laryngeal preservation of 100%, 83%, and 83%, respectively (Figures 1, 2, and 3).

Group C included 34 patients (48%) treated with TL (1 with a glottic rT1b tumor with intraoperative evidence of thyroid cartilage invasion, 8 with rT2 lesions with impaired vocal cord mobility or supraglottic and glottic extension, 18 with glottic rT3 tumors with vocal cord fixation, and 7 with rT4a lesions with thyroid or cricoid cartilage invasion or hypopharyngeal involvement). In 6 patients (18%), we coupled TL with a primary (2 patients) or secondary (4 patients) pedicled (myocutaneous or myofascial major pectoralis) or free (radial forearm) flap. The preradiotherapy, clinical, and pathologic T categories are reported in **Table 4**. Hospitalization ranged from 15 to 45 days (mean, 25 days). Removal of the feeding tube was accomplished between 12 and 50 days (mean, 22 days). Early complications were observed in 13 patients (38%) and were mainly represented by pharyngocutaneous fistula (12 patients). This

was conservatively managed in 7 patients by compressive bandages twice daily, whereas 1 patient required local revision with primary sutures and 4 needed secondary myofascial or myocutaneous pedicled pectoralis major flaps. In 2 patients receiving primary reconstruction with radial forearm free flaps at the end of salvage surgery, no fistulization was observed. One case of postoperative chylous leak was also encountered and conservatively managed by compressive bandages on the left supraclavicular region. No late complication was diagnosed in this group of patients. At the last follow-up visit, 14 patients were alive and well, 14 had died of locoregional recurrence or distant metastasis, and 6 had died of other causes (2 lung tumors, 1 hepatocarcinoma, 2 acute myocardial infarctions, and 1 stroke). Kaplan-Meier curves for this group showed 5-year disease-specific and disease-free survival of 48% and 51%, respectively (Figures 1 and 2). One of 8 patients (13%) treated with neck dissection in group B was N+ (pN1). Eight of 34 patients (24%) who underwent this procedure in group C were N+ (2 were pN1, 4 were pN2b, 1 was pN2c, and 1 was pN3).

The complication rate for the entire series was 31%, with 5-year overall survival, disease-specific survival, disease-free survival, and laryngeal preservation of 54%, 72%, 61%, and 40%, respectively. Comparison of 5-year disease-specific survival in groups A, B, and C showed a significant difference ($P < .001$). A similar result was observed when comparing 5-year disease-specific survival on the basis of the preradiotherapy, clinical (before salvage surgery), and pathologic T categories ($P = .03$, $P < .001$, and $P < .001$, respectively). In contrast, no significant difference was observed when comparing 5-year disease-free survival in groups A, B, and C ($P = .20$). There were no significant differences in the laryngeal preservation rates of groups A and B ($P = .5$).

COMMENT

Before treating laryngeal cancer recurrent after radiotherapy failure, a variety of factors should be evaluated to choose the most appropriate treatment. The first and essential element is the preradiotherapy staging of the lesion, which must be accurately compared with that of the recurrent lesion. In fact, 6.5% to 30.0% of recurrences of early laryngeal cancers tend to be localized,³³ and although tumor margins may vary after radiotherapy and their identification during endoscopic and open-neck surgery can be difficult even for the experienced surgeon, a definite role for conservative approaches has already been demonstrated.^{29,30} The choice between ER using carbon dioxide laser and ONPLs should be based on the extension and characteristics of the tumor, overall health status, and the possibility to obtain complete laryngeal exposure for endoscopic purposes. However, a highly variable spectrum of indications for ER related to tumor extent have been reported.^{4,22-28} The present selection criteria are strict and rather limited compared with those of other investigators,^{23,24,28} who included rT3 and rT4 lesions with extensive involvement of the anterior commissure in their endoscopic series. Although involvement of the anterior commissure does not

represent a contraindication for ER of previously untreated glottic tumors,³⁴ extreme caution should be used, in our experience,²⁷ for rescue ER of such lesions after radiotherapy failure in view of the normal appearance, even under endoscopic magnification, of the anterior commissure mucosa (marginally involved in 3 of the 7 recurrences in this series), which can hide the persistence of deep nests of tumor invading visceral compartments or focally involving the laryngeal framework.^{35,36} In the case of macroscopic involvement of the anterior commissure by recurrent tumors, we prefer to perform SCPLs, which present wider safe margins of resection and avoid the risk of thyroid cartilage chondronecrosis, one of the most feared complications of vertical partial laryngectomies after radiotherapy failure.^{20,37}

The most appealing features of ER are the possibility to make a tumor-tailored excision without any reconstructive limitations in terms of tension of the pexy or symmetry, to precisely stage the lesion with a microscope, possibly switching to an ONPL whenever the tumor is beyond the presumed preoperative limits. Shorter hospitalizations, lower complication rates, better functional outcomes in terms of voice and swallowing, and a more favorable cost-effectiveness ratio are other advantages of this treatment modality, as demonstrated by other series.^{4,22-28} Five-year disease-free survival and laryngeal preservation rates obtained with ER in rT1 and rT2 carcinoma are certainly lower than those observed in primary ER.³⁴ Nonetheless, the 5-year disease-specific survival of 95% emphasizes the importance of strict follow-up with regular fiberoptic examinations and periodic imaging, allowing early detection and treatment of further recurrences without a negative impact on survival.^{26,27} Moreover, the difference between the laryngeal preservation rates in groups A and B (75% and 83%, respectively) was not statistically significant.

In this experience, ONPLs mainly included all variants of SCPL. Horizontal supraglottic laryngectomy was used in only 1 patient according to the general opinion that the procedure has limited value as salvage surgery after radiotherapy.^{5,19,29} Most of the recurrences extending to the supraglottis were treated using SCPL with cricothyroidopexy. The SCPLs allow a wide tumor resection while preserving aerodigestive continuity and a lung-powered voice. Moreover, the possibility of obtaining complete clearance of the entire paraglottic space ipsilateral to a sacrificed arytenoid and, in the case of SCPL with cricothyroidopexy, of the entire preepiglottic space expands the indications of this technique to include glottic T2 tumors with impaired vocal cord mobility, T3 tumors with limited paraglottic space invasion, and supraglottic T3 tumors with pre-epiglottic involvement. Although some rT3 lesions were included in group B, SCPLs showed 5-year disease-free and disease-specific survival comparable with or even superior to those reported in most postirradiation vertical partial laryngectomies series.^{5,6,8,10,11,13,14,17,19} This was achieved with an increase in perioperative morbidity that was not different from that observed after salvage TL.

The potentially higher morbidity rate for SCPLs, already mentioned by several researchers,^{12,18} was encountered even in the present series, but it did not statisti-

cally significantly affect the overall laryngeal preservation rate. However, patient selection before SCPLs, in relation to the precise tumor extension and adherence to a lengthy rehabilitation trial, likely remains the most difficult and subjective argument and must be resolved on a case-by-case basis. Beyond pulmonary and cardiologic functions, subtle elements such as dexterity, compliance, self-motivation, and support from the surrounding social environment must be adequately assessed to properly choose the candidates for such a procedure.¹²

More than half of the patients in this series could initially retain their larynx after undergoing ER or ONPL. This percentage decreased to 40% in the subsequent 5 years, mainly for further local recurrences or, less frequently, for surgery-related complications. This is of paramount importance when considering that all these patients would have obtained similar local control of disease (reported to be 60% to 80% for rT1-rT2 tumors after salvage TL and <50% for advanced T category tumors)^{1,7,38} with comparable perioperative morbidity but without any organ preservation in the case of TL alone.

In the present series, as in others,³³ approximately half of the patients had locally advanced disease at the time of detection. In addition, medical comorbidities and socioeconomic constraints in many cases prevented the application of larynx-preserving procedures. The 5-year disease-specific and disease-free survival rates of TL in this cohort likely reflect the negative prognostic effect of the most locally advanced tumors that were not deemed candidates for conservation procedures. Even the complication rates were not negligible, although they are similar to those reported previously,^{33,39,40} and were mainly related to pharyngocutaneous fistulas. An extensive and prophylactic use of pedicled or free flaps in these patients seems to help in preventing or reducing the incidence and severity of fistulas.⁴⁰ The only 2 patients in whom we chose to adopt such a policy for poor tissue condition (edematous and pale hypopharyngeal mucosa requiring removal of part of the piriform sinuses) regained a normal oral diet without developing fistulas. In contrast, most flaps harvested by us for purely laryngeal cancer recurrent after radiotherapy were for secondary closure of fistulas clinically progressing despite conservative methods.

In conclusion, these proposed selection criteria strictly stratify instances of laryngeal radiotherapy failure into different groups amenable to various types of conservative surgery or TL on the basis of well-known tumor- and patient-related variables. This treatment policy allowed us to spare the larynx initially in more than half of the individuals who were candidates for salvage surgery. This percentage progressively reduced in the following 5 years to 40%, still maintaining survival rates comparable with those commonly reported for more aggressive approaches, without any attempt at organ preservation.

Submitted for Publication: August 22, 2006; final revision received June 1, 2007; accepted June 4, 2007.

Correspondence: Cesare Piazza, MD, Department of Otorhinolaryngology, University of Brescia, Piazza Spedali Civili 1, 25123 Brescia, Italy (ceceplaza@libero.it).

Author Contributions: Drs Piazza and Peretti had full access to all the data in the study and take responsibility for the integrity of the data and the accuracy of the data analysis. *Study concept and design:* Piazza, Peretti, and Nicolai. *Acquisition of data:* Piazza, Peretti, Cattaneo, and Garrubba. *Analysis and interpretation of data:* Piazza, Peretti, and De Zinis. *Drafting of the manuscript:* Piazza, Cattaneo, and Garrubba. *Critical revision of the manuscript for important intellectual content:* Piazza, Peretti, De Zinis, and Nicolai. *Statistical analysis:* De Zinis. *Administrative, technical, and material support:* Piazza, Peretti, Cattaneo, and Garrubba. *Study supervision:* Piazza, Peretti, and Nicolai.

Financial Disclosure: None reported.

Previous Presentation: This study was presented at the Annual Meeting and Research Workshop on the Biology, Prevention, and Treatment of Head and Neck Cancer; August 20, 2006; Chicago, Illinois.

REFERENCES

- Schwaab G, Mamelle G, Lartigau E, Parise O, Wibault P, Lubinski B. Surgical salvage treatment of T1/T2 glottic carcinoma after failure of radiotherapy. *Am J Surg.* 1994;168(5):474-475.
- Greisen O, Carl J, Pedersen MA. Consecutive series of patients with laryngeal carcinoma treated by primary irradiation. *Acta Oncol.* 1997;36(3):279-282.
- Barthel SW, Esclamado RM. Primary radiation therapy for early glottic cancer. *Otolaryngol Head Neck Surg.* 2001;124(1):35-39.
- Sewnaik A, Meeuwis CA, van der Kwast TH, Kerrebijn JDF. Partial laryngectomy for recurrent glottic carcinoma after radiotherapy. *Head Neck.* 2005;27(2):101-107.
- Shaw HJ. A view of partial laryngectomy in the treatment of laryngeal cancer. *J Laryngol Otol.* 1987;101(2):143-154.
- Rothfield RE, Johnson JT, Myers EN, Wagner RL. The role of hemilaryngectomy in the management of T1 vocal cord cancer. *Arch Otolaryngol Head Neck Surg.* 1989;115(6):677-680.
- Shah JP, Loree TR, Kowalski LP. Conservation surgery for radiation-failure carcinoma of the glottic larynx. *Head Neck.* 1990;12(4):326-331.
- Lavey RS, Calcatera TC. Partial laryngectomy for glottic cancer after high-dose radiotherapy. *Am J Surg.* 1991;162(4):341-344.
- Nichols RD, Mickelson SA. Partial laryngectomy after irradiation failure. *Ann Otol Rhinol Laryngol.* 1991;100(3):176-180.
- DelGaudio JM, Fleming DJ, Esclamado RM, Carroll WR, Bradford CR. Hemilaryngectomy for glottic carcinoma after radiation therapy failure. *Arch Otolaryngol Head Neck Surg.* 1994;120(9):959-963.
- Kooper DP, van den Broek P, Manni JJ, Tiwari RM, Snow GB. Partial vertical laryngectomy for recurrent glottic carcinoma. *Clin Otolaryngol Allied Sci.* 1995;20(2):167-170.
- Laccourreye O, Weinstein G, Naudo P, Cauchois R, Laccourreye H, Brasnu D. Supracricoid partial laryngectomy after failed laryngeal radiation therapy. *Laryngoscope.* 1996;106(4):495-498.
- Lydiatt WM, Shah JP, Lydiatt KM. Conservation surgery for recurrent carcinoma of the glottic larynx. *Am J Surg.* 1996;172(6):662-664.
- Nibu K, Kamata S, Kawabata K, Nakamizo M, Nigauri T, Hoki K. Partial laryngectomy in the treatment of radiation-failure of early glottic carcinoma. *Head Neck.* 1997;19(2):116-120.
- Rodriguez-Cuevas S, Labastida S, Gonzalez D, Briseno N, Cortes H. Partial laryngectomy as salvage surgery for radiation failures in T1-T2 laryngeal cancer. *Head Neck.* 1998;20(7):630-633.
- Watters GW, Patel SG, Rhys-Evans PH. Partial laryngectomy for recurrent laryngeal carcinoma. *Clin Otolaryngol Allied Sci.* 2000;25(2):146-152.
- Mooney WW, Cole I, Albsoul N, Pearson SA. Salvage vertical partial laryngectomy for radiation failure in early glottic carcinoma. *ANZ J Surg.* 2002;72(10):746-749.
- Spriano G, Pellini R, Romano G, Muscatello L, Roselli R. Supracricoid partial laryngectomy as salvage surgery after radiation failure. *Head Neck.* 2002;24(8):759-765.
- Yiotakis J, Stavroulaki P, Nikolopoulos T, et al. Partial laryngectomy after irradiation failure. *Otolaryngol Head Neck Surg.* 2003;128(2):200-209.

20. Makeieff M, Venegoni D, Mercante G, Crampette L, Guerrier B. Supracricoid partial laryngectomies after failure of radiation therapy. *Laryngoscope*. 2005;115(2):353-357.
21. Sewnaik A, Hakkesteegt MM, Meeuwis CA, de Gier HHW, Kerrebijn JDF. Supracricoid partial laryngectomy with cricothyroidoepiglottomy for recurrent laryngeal cancer. *Ann Otol Rhinol Laryngol*. 2006;115(6):419-424.
22. Casiano RR, Cooper JD, Lundy DS, Chandler JR. Laser cordectomy for T1 glottic carcinoma: a 10-year experience and videostroboscopic findings. *Otolaryngol Head Neck Surg*. 1991;104(6):831-837.
23. Kerrebijn JD, de Boer MF, Knegt PP. CO₂-laser treatment of recurrent glottic carcinoma. *Clin Otolaryngol Allied Sci*. 1992;17(5):430-432.
24. Outzen KE, Illum P. CO₂-laser therapy for carcinoma of the larynx. *J Laryngol Otol*. 1995;109(2):111-113.
25. Quer M, Leon X, Orus C, Venegas P, Lopez M, Burgues J. Endoscopic laser surgery in the treatment of radiation failure of early laryngeal carcinoma. *Head Neck*. 2000;22(5):520-523.
26. de Gier HHW, Knegt PPM, de Boer MF, Meeuwis CA, van der Velden L-A, Kerrebijn JDF. CO₂-laser treatment of recurrent glottic carcinoma. *Head Neck*. 2001;23(3):177-180.
27. Puxeddu R, Piazza C, Mensi MC, Ledda GP, Argiolas F, Peretti G. Carbon dioxide laser salvage surgery after radiotherapy failure in T1 and T2 glottic carcinoma. *Otolaryngol Head Neck Surg*. 2004;130(1):84-88.
28. Steiner W, Vogt P, Ambrosch P, Kron M. Transoral carbon dioxide laser micro-surgery for recurrent glottic carcinoma after radiotherapy. *Head Neck*. 2004;26(6):477-484.
29. Motamed M, Laccourreye O, Bradley PJ. Salvage conservation laryngeal surgery after irradiation failure for early laryngeal cancer. *Laryngoscope*. 2006;116(3):451-455.
30. Holsinger FC, Funk E, Roberts DB, Diaz EM Jr. Conservation laryngeal surgery versus total laryngectomy for radiation failure in laryngeal cancer. *Head Neck*. 2006;28(9):779-784.
31. Greene FL, Page DL, Fleming ID, eds, et al. *AJCC Cancer Staging Handbook: TNM Classification of Malignant Tumors*. 6th ed. New York, NY: Springer; 2002.
32. Remacle M, Eckel HE, Antonelli AR, et al. Endoscopic cordectomy: a proposal for a classification by the Working Committee, European Laryngological Society. *Eur Arch Otorhinolaryngol*. 2000;257(4):227-231.
33. Viani L, Stell PM, Dalby JE. Recurrence after radiotherapy for glottic carcinoma. *Cancer*. 1991;67(3):577-584.
34. Peretti G, Piazza C, Bolzoni A, et al. Analysis of recurrences in 322 Tis-T1-T2 glottic carcinomas treated by carbon dioxide laser. *Ann Otol Rhinol Laryngol*. 2004;113(11):853-858.
35. Kirchner JA. Pathways and pitfalls in partial laryngectomy. *Ann Otol Rhinol Laryngol*. 1984;93(4, pt 1):301-305.
36. Kirchner JA. What have whole organ sections contributed to the treatment of laryngeal cancer? *Ann Otol Rhinol Laryngol*. 1989;98(9):661-667.
37. Laccourreye O, Weinstein G, Brasnu D, Trotoux J, Laccourreye H. Vertical partial laryngectomy: a critical analysis of local recurrence. *Ann Otol Rhinol Laryngol*. 1991;100(1):68-71.
38. Howell-Burke D, Peters LJ, Goepfert H, Oswald MJ. T2 glottic cancer: recurrence, salvage, and survival after definitive radiotherapy. *Arch Otolaryngol Head Neck Surg*. 1990;116(7):830-835.
39. Schwartz SR, Yueh B, Maynard C, Daley J, Henderson W. Predictors of wound complications after laryngectomy: a study of over 2000 patients. *Otolaryngol Head Neck Surg*. 2004;131(1):61-68.
40. Ganly I, Patel S, Matsuo J, et al. Postoperative complications of salvage total laryngectomy. *Cancer*. 2005;103(10):2073-2081.