

Acquired thrombotic thrombocytopenic purpura in a child: rituximab to prevent relapse. A pediatric report and literature review.

Thrombotic thrombocytopenic purpura (TTP) is a life-threatening thrombotic microangiopathy (TMA), characterized by peripheral thrombocytopenia, microangiopathic hemolytic anemia (MAHA) and severe deficiency of a disintegrin and metalloproteinase with thrombospondin type 1 motif, member 13 (ADAMTS13), required for the cleavage of von Willebrand factor (vWF). The absence of ADAMTS13 leads to an inappropriate cleavage of ultra large multimers of vWF (ULvWF) that causes platelet aggregates and microvascular thrombosis mostly in the brain, kidney and heart. TTP may be congenital or familial due to a mutation in the ADAMTS13 gene leading to an enzyme deficiency, or it may be acquired due to an inhibitor of ADAMTS13 activity. Diagnosis of TTP was originally formulated on the basis of a clinical pentad, including thrombocytopenia, MAHA, neurological signs, renal dysfunction, and fever. However, 35% of patients do not present neurological or renal abnormalities, thus, according to the current guidelines, the presence of thrombocytopenia and non-autoimmune MAHA anemia are sufficient for a diagnosis of TTP. Acquired TTP is a rare disorder with an incidence, in UK adult patients, of six cases per million per year.¹ In infants, TTP is a very uncommon disease, and congenital TTP is more prevalent than the acquired form. In children, the differential diagnosis with hemolytic uremic syndrome (HUS) is mandatory. HUS is more frequent and has a clinical presentation similar to that of TTP, but it is profoundly distinct with regard to both pathophysiology and management. ADAMTS13 activity is typically normal in children with HUS, while a severe ADAMTS13 deficiency defines children with TTP. Thus, the evaluation of ADAMTS13 activity and the search for inhibitor antibodies are crucial for a differential diagnosis.² The standard treatment of acquired TTP consists mainly of daily therapeutic plasma exchange (PEX). PEX removes the inhibitors and the ULvWF multimers that cause platelet aggregates, and also replenishes ADAMTS13. It is necessary for PEX to be performed on a daily basis until

the platelet count has stably recovered. The emerging consideration of TTP as an autoimmune disorder has led to a large use of immunosuppressive treatment with steroids during PEX. This approach has impacted on the historically fatal prognosis of TTP in the current 90% survival rates. Approximately 10-20% of TTP patients are refractory to PEX and require an additional immunosuppressive treatment. Rituximab, a humanized monoclonal antibody directed against the B-cell antigen CD20, inhibits autoantibody formation and is now routinely recommended in the acute phase of TTP for adult patients with a suboptimal response to primary therapy.¹ Up to 40% of adult patients who are responsive to first-line treatment will relapse. Rituximab is effective in relapsed TTP resulting in a response rate greater than 90%.¹ The prevention of relapse represents a major goal. Rituximab, used as a preemptive therapy, reduces the incidence of relapse in adult patients in clinical remission with persistent severe ADAMTS13 deficiency, or when ADAMTS13 becomes <10% during follow up.³

We herein report the case of an 11-year-old girl with acquired TTP who was treated with rituximab to prevent clinical relapse. The child was admitted to our Hematology Center with a fever (38°C) and petechiae. The physical and neurological examination was normal. Blood testing showed anemia (Hemoglobin [Hb] 8.8 g/dL) with an increase of hemolysis indices: reticulocytosis was $119 \times 10^9/L$ (normal range: 22-139), lactate dehydrogenase (LDH) 4715 UI/L (normal range: 120-300), total bilirubin 2.62 mg/dL (normal range: 0.35-1), and a low haptoglobin level without schistocytes; she also showed a normal white blood cell count ($7 \times 10^9/L$) and severe thrombocytopenia (platelet count $9 \times 10^9/L$), without renal involvement. Blood coagulation tests were normal. The direct antiglobulin test was negative. Hepatitis screening for the hepatitis B virus (HBV), hepatitis C virus (HCV), and human immunodeficiency virus (HIV) proved negative. Her family medical history was silent for related diseases. A bone marrow aspirate showed adequate granulopoiesis, erythropoiesis and megakaryocytes with normal morphology. An autoimmune work-up - antinuclear antibodies (ANA), double stranded DNA (dsDNA), extractable nuclear antigens (ENA), Complement 3 (C3)

Table 1. Summary of published reports on the use of rituximab in pediatric thrombotic thrombocytopenic purpura.

Reference	N° patients	Rituximab Usage	Follow up (months)	Relapses
Curtillet <i>et al.</i> 2006 ⁷	1	Refractory	3	-
Binder <i>et al.</i> 2010 ⁸	1	Refractory	12	-
McDonald <i>et al.</i> 2010 ⁹	6	Refractory	38, 35, 24, 16, 12, 9	- , 1, 1, -, -, -
Harambat <i>et al.</i> 2011 ¹⁰	1	Refractory	18	-
Narayanan <i>et al.</i> 2012 ¹¹	1	Refractory	12	-
Albaramki <i>et al.</i> 2009 ¹²	2	Refractory, Relapse	12,17	-
Wieland <i>et al.</i> 2015 ¹⁴	7	Refractory, Relapse	144, 72, 48, 36, 24, 12, lost to follow up	- , 2, -, -, 3, 3, 1
Sankararaman <i>et al.</i> 2014 ¹³	1	Relapse	29	-
Joly <i>et al.</i> 2016 ⁵	7	Refractory/Relapse	6-16 (years)	NA
	7	Preemptive	6-16 (years)	NA
Jayabose <i>et al.</i> 2011 ¹⁵	1	Preemptive	46	-
Present report 2017	1	Preemptive	6	-

NA: not available.

and Complement 4 (C4) - was carried out and resulted negative. The child was treated with intravenous human immunoglobulins (0.4 g/kg/day) for three days and prednisone (1 mg/kg/die) on the suspicion of an autoimmune bicytopenia. Because of a clinical deterioration and no response to intravenous human immunoglobulin therapy, a peripheral blood smear was reevaluated and showed schistocytes (60/1000 cells per microscope field). ADAMTS13 activity was immediately tested and PEX promptly started (replacement with fresh frozen plasma 30 ml/kg), in association with continuous plasma infusion (10 ml/kg) and dexamethasone (12 mg/day). The ADAMTS13 activity was less than 3% and the presence of inhibitor antibodies confirmed the diagnosis of acquired TTP.¹ The patient underwent five daily PEX with a rise in the platelet count ($>150 \times 10^9/L$); PEX was then performed every other day for one week, and the final PEX one week later. The child was discharged, and oral steroid therapy was tapered and stopped over the course of four months. One month after the last PEX, ADAMTS13 activity was normal (100%). ADAMTS13 activity was monitored every six months; 27 months later, ADAMTS13 activity fell to 3% with the reappearance of inhibitor antibodies. Taking into account that the occurrence of severe ADAMTS13 deficiency during remission may predict the risk of relapse,⁴ we decided to treat the patient with preemptive rituximab at a dose of 375 mg/m²/week for four weeks, preceded by the infusion of antihistamines, steroids (dexamethasone 4 mg) and antipyretics. ADAMTS13 activity after the first, second and fourth infusion was 9%, 70% and 95%, respectively. The treatment was well tolerated without infective complications. Currently, after one year of follow up, the girl is in clinical remission with normal ADAMTS13 activity without inhibitor antibodies; ADAMTS13 activity is monitored every six months (Figure 1).

Herein, we report the case of a pediatric patient with acquired TTP who was successfully treated with rituximab to prevent hematological relapse. Acquired TTP in childhood (age <18 years) is a very rare disease, often misdiagnosed; the epidemiology of childhood TTP, as well as the best first-line treatment and the role of preemptive strategies are not known. Retrospective studies from registries have shown that the rate of annual incidence is approximately 3% in adults, and that it is more frequent in females and adolescents (age >10 years).^{2,5} The idiopathic form is more common. Acquired TTP in children appears to be the same disorder that occurs in adults, requiring a similar management and long-term follow up, as well as an awareness of the possibility of relapse.⁶ Indeed, a high relapse rate is observed after first-line treatment, and relapses are more frequent in acquired TTP.² Few reports in the literature indicate that rituximab has gained favor as an adjunctive agent to treat refractory or relapsing TTP in children.^{5,7-11} During relapse, children undergo PEX and thereafter receive standard dose rituximab.^{5,12-14} Encouraging results have been observed, with complete remission rates ranging between 82% and 100%, and the depletion of B cells induced by rituximab leads to long-term remissions (median 7.7 years, range: 2-12.7).¹⁴ Treatment is well tolerated, with no severe side effects. In our experience, severe ADAMTS13 deficiency with the presence of inhibitor antibodies confirmed the diagnosis of acquired TTP in an adolescent girl. A prompt and complete response was achieved following treatment with PEX and steroids, with a normalization of ADAMTS13 activity. Careful monitoring allowed us to identify an increased risk of TTP recurrence due to a reduction in

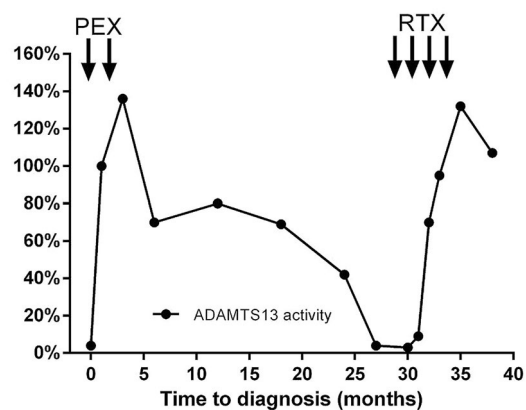


Figure 1. Level of ADAMTS 13 activity due to treatment. PEX: plasma exchange; RTX: rituximab.

activity (<3% in two consecutive controls) and the reappearance of the inhibitor antibody. In fact, during the remission phase, the persistence of an undetectable ADAMTS13 activity (<5%) and the presence of inhibitor antibodies is considered a predisposing factor to clinical relapse.¹ In this setting, the use of preemptive rituximab has demonstrated to be an effective treatment to prevent hematological recurrence in adult patients.³ In children, rituximab as preemptive therapy has been used in eight cases alone.^{5,15} In our patient, taking into account the increased risk of mortality or psychomotor and psychosocial sequelae due to TTP relapse, we utilized preemptive rituximab 27 month after diagnosis. The treatment was well tolerated and was followed by a rapid normalization of ADAMTS13 activity and inhibitor disappearance. ADAMTS13 monitoring was continued every six months showing persistent normal ADAMTS13 levels after one year of follow up. The long-term effects of rituximab in children are unknown. A recent study based on The International Classification of Diseases has shown a significantly increased risk of infectious complications associated with rituximab treatment in children with immunological and onco-hematological diseases, but these were related to the underlying condition. The case herein has clearly shown that the regular monitoring of both ADAMTS13 activity and inhibitor levels is of the utmost importance in order to identify children at risk for relapse. Rituximab is an effective preemptive therapy which assists in the avoidance of consequences and sequelae on the growth and social life of the child. Acquired TTP is a rare disorder in childhood, hence, it is important to collect all observed data in order to have more information about which is the best treatment and outcome.

Sabrina Mariani,¹ Silvia M. Trisolini,¹ Saveria Capria,¹ Maria L. Moleti,¹ Marta Chisini,² Giancarlo Ferrazza,³ Mahnaz Shafii Bafii,³ Maria A. Limongiello,¹ Eleonora Miulli,¹ Flora Peyvandi,² Robin Foà¹ and Anna M. Testi¹

¹Hematology, Department of Cellular Biotechnologies and Hematology, Policlinico Umberto 1, Sapienza University, Rome; ²Angelo Bianchi Bonomi Hemophilia and Thrombosis Center, Fondazione IRCCS Ca' Granda Ospedale Maggiore Policlinico and Fondazione Luigi Villa, Milan and ³Immunohematology and Transfusion Medicine Unit, Sapienza University, Rome, Italy

Correspondence: mariani@bce.uniroma1.it
doi:10.3324/haematol.2017.185363

Information on authorship, contributions, and financial & other disclosures was provided by the authors and is available with the online version of this article at www.haematologica.org.

References

1. Scully M, Hunt BJ, Benjamin S, et al. Guidelines on the diagnosis and management of thrombotic thrombocytopenic purpura and other thrombotic microangiopathies. *Br J Haematol.* 2012;158(3):323-335.
2. Reese JA, Muthurajah DS, Kremer Hovinga JA, et al. Children and adults with thrombotic thrombocytopenic purpura associated with severe, acquired Adamts13 deficiency: comparison of incidence, demographic and clinical features. *Pediatr Blood Cancer* 2013;60(10):1676-1682.
3. Hie M, Gay J, Galicier L, et al. Preemptive rituximab infusions after remission efficiently prevent relapses in acquired thrombotic thrombocytopenic purpura. *Blood.* 2014;124(2):204-210.
4. Page EE, Kremer Hovinga JA, Terrell DR, et al. Clinical importance of ADAMTS13 activity during remission in patients with acquired thrombotic thrombocytopenic purpura. *Blood.* 2016;128(17):2175-2178.
5. Joly BS, Stepanian A, Leblanc T, et al. French Reference Center for Thrombotic Microangiopathies. Child-onset and adolescent-onset acquired thrombotic thrombocytopenic purpura with severe ADAMTS13 deficiency: a cohort study of the French national registry for thrombotic microangiopathy. *Lancet Haematol.* 2016;3(11):537-546.
6. Bouw MC, Dors N, van Ommen H, et al. Thrombotic thrombocytopenic purpura in childhood. *Pediatr Blood Cancer.* 2009;53(4):537-542.
7. Curtillet C, Poullin P, Doré E, et al. Pediatric case report of an acquired autoimmune thrombotic thrombocytopenic purpura. *Arch Pediatr.* 2006;13(12):1521-1524.
8. Binder WD, Traum AZ, Makar RS, et al. Case 37-2010: A 16-year-old girl with confusion, anemia, and thrombocytopenia. *N Engl J Med.* 2010;363(24):2352-2361.
9. McDonald V, Liesner R, Grainger J, et al. Acquired, noncongenital thrombotic thrombocytopenic purpura in children and adolescents: clinical management and the use of ADAMTS 13 assays. *Blood Coagul Fibrinolysis.* 2010;21(3):245-250.
10. Harambat J, Lamireau D, Delmas Y, et al. Successful treatment with rituximab for acute refractory thrombotic thrombocytopenic purpura related to acquired ADAMTS13 deficiency: a pediatric report and literature review. *Pediatr Crit Care Med.* 2011;12(2):90-93.
11. Narayanan P, Jayaraman A, Rustagi RS, et al. Rituximab in a child with autoimmune thrombotic thrombocytopenic purpura refractory to plasma exchange. *Int J Hematol.* 2012;96(1):122-124.
12. Albaramki JH, Teo J, Alexander SI. Rituximab therapy in two children with autoimmune thrombotic thrombocytopenic purpura. *Pediatr Nephrol.* 2009;24(9):1749-1752.
13. Sankararaman S, Jeroudi M, Ibrahim H. Successful treatment of relapsing autoimmune thrombotic thrombocytopenic purpura with rituximab. *Pediatr Int.* 2014;56(6):914-918.
14. Wieland I, Kentouche K, Jentzsch M, et al. Long-term remission of recurrent thrombotic thrombocytopenic purpura (TTP) after Rituximab in children and young adults. *Pediatr Blood Cancer.* 2015;62(5):823-829.
15. Jayabose S, Dunbar J, Nowicki TS, et al. Rituximab therapy to prevent relapse in chronic relapsing thrombotic thrombocytopenic purpura (TTP) in a child. *Pediatr Hematol Oncol.* 2011;28(2):167-172.