

Immediate post-extraction screw-retained partial and full-arch rehabilitation. A 3-year follow-up retrospective clinical study

Roberto Villa, MD, DDS,<sup>1</sup> Gabriele Villa, DDS<sup>1</sup>, Massimo Del Fabbro, MSc, PhD<sup>2,3</sup>

<sup>1</sup> Private Practice, Biella, Italy

<sup>2</sup> Associate Professor, Department of Biomedical, Surgical and Dental Sciences, Università degli Studi di Milano, Milan, Italy.

<sup>3</sup> IRCCS Galeazzi Orthopaedic Institute, Milan, Italy.

Corresponding author:

Dr. Roberto Villa

Clinica Odontoiatrica Villa

Piazza del Duomo 9, 13900 Biella, ITALY

Email: r.villa@clinicavilla.com

## **ABSTRACT**

Aim of this study was to document the performance of a novel technique (OnlyOne®), involving immediate restoration of postextraction implants supporting partial or full-arch restoration. A retrospective analysis of patients with at least 3 years follow-up was performed. Implants were tilted mesio-distally and vestibulo-palatally according to the available bone. Prosthetically-guided definitive abutments were connected at surgery and never disconnected. Anorganic bovine bone grafting was done to preserve the buccal bone and the ridge contour. Patients received a screw-retained provisional prosthesis within 24 hours of surgery and a final screw-retained prosthesis within one year. Prostheses emerged from natural soft tissue. Clinical and radiographic evaluation was routinely performed. Seventy patients received 153 implants in fresh extraction sockets. The mean follow-up was  $38.0 \pm 3.0$  months (range 36-51 months). One implant failed at 3-year follow-up. Implant survival was 99.3%. The marginal bone level change averaged  $-0.68 \pm 1.2$  mm at the last radiographic control. Immediate placement and restoration of implants designed for high primary stability, with definitive abutment placed at surgery and final screw-retained prosthesis with no artificial gingiva is a viable procedure with excellent medium-term outcomes.

**Key words:** post-extraction sockets; immediate implants; immediate loading; immediate restoration; Multi-Unit abutment

## **INTRODUCTION**

Several treatment options have been adopted in order to overcome bone resorption after tooth loss or extraction, and enable implant treatment. One of the most popular approaches is to placing the implants at an axis angulated with respect to the occlusal plane, taking advantage of the residual cortical bone.<sup>1</sup> This protocol combined a reduced morbidity with a high implant survival and success rates in the mid-long term, as well as a limited peri-implant bone level change.<sup>2</sup> Most clinicians also loaded the tilted implants immediately, thereby reducing the treatment time, without compromising the clinical and radiographic outcomes.<sup>3,4</sup> This technique, however, is often associated with a poor esthetics of the soft tissues as an artificial gingiva is mostly present in complete rehabilitations involving tilted implants. For implants inserted in fresh post-extraction sockets, immediate restoration means the preservation of a functional stimulus on the alveolar bone, possibly reducing the marginal bone loss after implant placement.<sup>5-7</sup>

A further concept involves immediate positioning of a definitive abutment, to avoid multiple abutment removal and subsequent reconnection, which may have deleterious effects on the marginal peri-implant tissues.<sup>8</sup> Though it is still controversial,<sup>9</sup> some clinical studies demonstrated that avoiding abutment disconnection is associated with lower peri-implant crestal bone remodeling.<sup>10,11</sup> Furthermore, this concept appears to have beneficial effects on the soft tissue interface around implants. In particular, the epithelial attachment tends to stabilize, avoiding the excessive recession observed with multiple abutment dis-/reconnection, which may in turn drive reduction of the marginal bone level.<sup>8,12</sup>

The aim of this retrospective clinical study was to document the mid-term performance of a novel technique consisting of implants inserted in fresh post-extraction sockets and restored immediately with definitive abutments connected at surgery and not disconnected thereafter, supporting rehabilitations emerging from natural soft tissue.

## **MATERIALS AND METHODS**

This report follows the STROBE guidelines for observational studies.<sup>13</sup> All patients were treated according to the principles contained in the Helsinki Declaration of 1980 for biomedical research involving human subjects, as revised in 2000.<sup>14</sup> The present study is a retrospective analysis of implants placed in post-extraction sites with variable tilting and immediately rehabilitated by using definitive abutments with the aim of preserving the soft

tissue and the bone architecture. The analysis was based on a review of clinical charts from a single private center. All data were extracted by the treating clinician from the clinic's standard documentation and de-identified prior to statistical analysis.

Patients were selected for implant surgery according to standard inclusion criteria: at least 18 years old; physically and psychologically able to undergo conventional surgical and restorative procedures (American Society of Anaesthesiologist (ASA) class I or II). Pre-surgical radiological assessment of the edentulous region included periapical radiographs, panoramic radiographs and computerized tomography.

All patients treated between April 2010 and December 2011 with variable-thread tapered implants (NobelActive, Nobel Biocare AB) placed in fresh post-extraction sites with a variable angulation with respect to the occlusal plane, according to the local anatomy of the residual bone were eligible for the analysis. Restorations could be supported by such immediate implants in combination with implants placed in healed sites, but the present analysis involved only the former. Additional inclusion criteria were: implants were coupled to 17° or 30° tilted or straight (0°) Multi-unit Abutments (Nobel Biocare AB) and provisionalized immediately; opposing dentition had to be present; availability of readable peri-apical radiographs taken at implant insertion and at the longest follow-up, at least three years post-surgery. Patients who received additional implants in healed sites in the same jaw were included but these additional implants were not part of the analysis.

Exclusion criteria for the surgical procedure were: presence of uncontrolled systemic conditions such as diabetes mellitus or bone metabolic disease; patients smoking habit with 20 or more cigarettes/day; head or neck radiotherapy in the 12 months prior to surgery; presence of heavy parafunctions (e.g. bruxism, clenching); past or current therapy with intravenous bisphosphonates. Furthermore, patients with incomplete demographic (age, gender, smoking status or systemic conditions) or clinical (implant outcomes, implant size and location) data reporting were not included.

### **Surgical procedures**

Each patient received detailed explanation regarding the treatment and signed a consent form before the surgical procedure. One hour prior to surgery, patients took two tablets of amoxicillin plus clavulanic acid (875+125 mg each tablet, Augmentin, Glaxo-SmithKleine). Then, patients rinsed with 0.12% chlorhexidine digluconate mouthwash (Curasept, Curaden Healthcare). Local anesthesia was induced using 2% mepivacaine

(Carboplyina, Dentsply). Implant site preparation was performed by following the manufacturer's recommendations. Immediately after atraumatic tooth extraction with the aid of a periosteal elevator (Nobel Biocare AB), granulation tissue and remnants of soft tissue in the socket were removed, alveolar bone curettage was performed and sockets were washed with an antibiotic solution (rifampin sodium or metronidazole).<sup>15</sup> Then, implants were placed in post-extraction sites with tilting at different angulations (vestibulo-palatally/lingually, mesio-distally or distomesially) to maximize the engagement of the native bone beyond the alveolus. The angulation and position of the implants was planned in advance using a specialized software for digital treatment planning (NobelClinician, Nobel Biocare AB). This software for 3D reconstruction helped for a precise evaluation of the local bone anatomy and a careful planning of implant insertion. However, it was never used to prepare surgical guides. A flap or flapless protocol was used. Flaps were only raised at the palatal/lingual aspect to better engage the palatal/lingual bone and to avoid any damage to blood vessels in the mandible. Use of buccal flap was intentionally avoided to prevent soft tissue recession. Implants were inserted with the platform as deep as 3-5 mm below the crest level in order to have the platform of the angulated abutment on the average 2 mm below the soft tissue margin, with the aim of favoring a natural emergence profile of the crown and to prevent any exposure of the buccal aspect of the abutment after soft tissue healing. Implants were always inserted by free hand without using a surgical stent. Insertion torque was measured with a torque wrench. Then, upon achievement of sufficient implant primary stability (insertion torque  $\geq 35$  Ncm), definitive abutments were connected and oriented to have the screw access hole towards the occlusal aspect of the prosthesis. If the minimum insertion torque of 35 Ncm could not be achieved, no immediate loading was performed. In all cases, the peri-implant gap within the extraction sockets was filled with anorganic bovine bone (Bio-Oss®, Geistlich Pharma) to minimize buccal bone resorption. The post-extraction sockets where implants were not placed were filled with Bio-Oss as well, to preserve the ridge contour.

When dealing with full-arch rehabilitation, five or six implants were placed in the maxilla and four implants in the mandible. Finally, soft tissue was sutured and impression was taken with Impregum Penta (3M ESPE).

Within 24 hours of implant placement a screw-retained, provisional prosthesis emerging from natural tissues and reinforced with a metal casting was mounted. Then, within one year, to allow for a proper soft tissue healing and stabilization, the final Zirconia full arch or partial prosthesis without artificial gingiva made in a dental lab was

screwed on the same abutments that had been placed during the initial surgery. All patients were requested to return for annual controls.

### **Outcome measures**

The primary outcomes of this study were: a) implant survival, defined as the proportion of implants present in the jaw, supporting a prosthetic restoration; b) prosthesis survival, defined as the proportion of functional prosthetic restorations, in the absence of biological or mechanical complications; c) marginal bone level at the last follow-up. Marginal bone levels were evaluated on the basis of the periapical radiographs taken in accordance with the routine of the clinic using a paralleling technique with standard Rinn holders at the time of implant placement, and at each follow-up post-surgery, with the implant platform and threads clearly visible. An independent radiologist in Gothenburg, Sweden, made the bone-height measurements. The distance between the implant platform and the most apical level of the marginal bone was measured. The first bone-to-implant contact evaluated by radiograph taken at final prosthesis delivery was defined as the baseline. In fact, the radiograph taken at surgery was considered unreliable due to the overfilling of the implant-bone gap with anorganic bovine bone. Secondary outcomes were: a) implant stability, clinically evaluated by means of two metallic instruments, applying opposing forces to the implant-abutment structure; an implant was judged as unstable if a clearly visible movement could be observed; b) absence or presence of plaque on the surface of the abutment/restoration complex, by naked eye or by running a periodontal probe; c) peri-implant soft tissue inflammation. The treating clinician assessed all clinical parameters.

### **Statistical analysis**

The analysis was carried out using SPSS Statistics for Windows (Version 19.0, SPSS Inc.). An independent statistician performed the descriptive statistical analysis. Data were synthesized using the mean value and standard deviation (SD) for quantitative variables, and absolute or relative frequencies for qualitative variables. Independent samples Kruskal-Wallis and Mann-Whitney U tests were performed to test whether the angulation and the diameter of the abutment, respectively, had an impact on marginal bone level. An independent statistician performed the univariate analysis for risk indicators associated with bone level at last follow-up using the following variables: age, number of implants/patient, gender, diameter, length, abutment height, abutment angulation, follow-up, position maxilla/mandible, position anterior/posterior, opposite dentition, flap/flapless, in

occlusion/out of occlusion, type of rehabilitation. The Spearman Test was used for quantitative variables, and the Wilcoxon rank sum test for qualitative variables. The significance level was set at  $p=0.05$ .

## **RESULTS**

The study included 70 patients (46 females, 24 males). Mean age was  $60.6\pm 12.6$  (standard deviation) years (range 34 to 89 years). A total of 153 implants were placed in fresh post-extraction sites by a single surgeon. The reason for extraction was: destructive caries, periodontal lesion, endodontic lesion, combined endo-periodontal lesion and root fracture. One-hundred forty-one implants were placed in the maxilla (33 incisors, 33 canines, 49 premolars and 26 molars) and 12 in the mandible (2 incisors, 1 premolar, 9 molars). Patients were rehabilitated by means of 42 partial prostheses (75 immediate implants) and 27 full prostheses (78 immediate implants).

The opposing dentition was an implant-supported prosthesis in 38 cases (24.8%) and natural teeth in 115 cases (75.2%). Implant diameter was 4.3 or 5 mm, and length ranged between 8.5 and 18 mm. Ninety-seven implants (63.4%) were placed using a palatal/lingual flap procedure and 56 (36.6%) using a flapless procedure. All implants achieved an insertion torque of  $>35$  Ncm, and were immediately restored with a screw-retained provisional prosthesis. The majority of the provisional restorations (54.9%) were designed to avoid any occlusal contact on the opposing dentition.

All multi-unit abutments had a regular platform diameter. Twenty-nine abutments had no angulation, 55 had an angulation of  $17^\circ$  and 69 of  $30^\circ$ . The final restoration was screw-retained in all cases.

The mean follow-up was  $38.0\pm 3.0$  months, with a range of 36-51 months. One implant was reported as a failure at the last follow-up (36 months). The patient, a 56-year old woman, received three study implants in the maxilla in positions 4, 6 and 11. Additional implants inserted in healed sites supported the prosthesis. All implants were loaded within 24 hours after placement. After three years, the study implant in position 11 (size 4.3x13 mm, abutment length 2.5 mm, angulation  $0^\circ$ ) failed, without compromising prosthetic function. This implant displayed a lower than average marginal bone level at 3 years ( $-6.7$  mm and  $-2.4$  mm at the mesial and distal aspect, respectively). Soft tissues around the implant also showed signs of mucositis, suggesting that late infection may have caused implant loss. The overall implant survival rate after 36 months was 99.3%. As no drop-out occurred and only one implant failed after three years, no calculation of a Cumulative Survival Rate (e.g. actuarial life table according to Altman) was performed.

Readable intraoral radiographs taken at the last follow-up were available for 142 implants. In a few cases, only the mesial or distal bone level was readable. The mean marginal bone level was  $-0.68 \pm 1.21$  mm. Neither mesial ( $p = 0.93$ ) nor distal ( $p = 0.43$ ) aspects were impacted by implant angulation. Also, mean marginal bone level was not significantly influenced by the implant diameter ( $p = 0.11$ ).

In the univariate analysis none of the investigated variables were found to associate with marginal bone level ( $p > 0.05$  in all cases).

All implants/restorations showed absence of detectable plaque, indicating a good oral hygiene level maintenance by the patients. Peri-implant mucosa was judged healthy (not inflamed) in 152 cases (99.3%), there was only one case of mucositis around the failed implant, as mentioned above. No prosthetic failure occurred throughout the observation period, leading to a 100% prosthetic survival rate. Two clinical cases illustrating the technique are presented in Figures 1 to 14.

## **DISCUSSION**

This retrospective study evaluated the clinical and radiographic outcomes of dental implants placed in post-extraction sites for immediate screw-retained partial and full-arch rehabilitations. The present approach, developed and named “OnlyOne®” by the authors, was focused on bone preservation and avoidance of artificial gingiva. Several aspects of the technique aimed at the best possible use of the limited available bone. The tilting of the implants at insertion, where necessary, allowed avoidance of augmentation procedures, which are generally demanding for both clinicians and patients, and are often associated with increased surgical risks and higher financial cost. Prior studies with variable-thread tapered implants showed excellent results in protocols adopting the tilted implant concept in order to exploiting the available residual bone, similar to the present study.<sup>16,17</sup> In the present study, bone grafting was performed only for the purpose of the socket preservation. With tilted implants, angulated abutments must be used to allow for a better loading force distribution and connection of a prosthetic restoration. The use of such abutments allows the surgeon a wide flexibility in placing implants, which is particularly useful in patients with limited amount of remaining bone after tooth extraction. In this kind of situation, choosing the regions that may provide optimal primary stability can be of critical importance. As a consequence, different possibilities are made available for the restorative dentist. Implants were inserted into fresh extraction sockets, in order to exploit residual alveolar bone. The features of the study implant allowed to achieve a high



implant primary stability with relative ease in either a flap or flapless approach without removing the existing bone. When using a flap approach, only palatal or lingual flap was elevated. Avoidance of buccal flap was aimed at preservation of the buccal gingival blood supply, and at engagement of the palatal/lingual aspect of the alveolar bone, which is usually of better quality in comparison to the buccal one.<sup>18</sup> Positioning implants in fresh extraction sockets along the lingual/palatal wall may play a key role in reducing the vertical bone resorption at the buccal aspect of the implants.<sup>19</sup> In full-arch reconstructions, after multiple extractions, implants were never placed in narrow sockets (e.g. upper lateral incisor or lower incisors sites), to avoid the risk of dehiscence, rather frequent at these sites after extraction. A careful digital treatment planning allowed to maximize the available bone without disconnecting the abutment placed during initial surgery and never moved again, in order to prevent excessive bone loss. Furthermore, the internal conical connection of the study implant with a built-in platform shift, allowed for deep implant placement (up to 3-5 mm subcrestal) and angulated abutment connection in order to have the abutment platform 2 mm below the gingival margin. Hence, the prosthesis could emerge from the natural soft tissue, improving the aesthetics. Poor esthetics is a frequent concern of other popular treatment concepts using tilted implants, like the all-on-four”, in which an artificial gingiva (a pink base acrylic/ceramic material) is used to simulate soft tissues around crowns.<sup>3</sup> An internal connection made the technique described in this paper feasible because it would have been very difficult to connect the abutment to an external hexagonal connection of an implant placed very deeply in a post-extraction socket without having any mismatch of the implant-abutment connection. The results achieved with this technique were excellent, as only one implant was lost after three years of function, and the marginal bone level was  $-0.68 \pm 1.2$  mm at 3 years, reflecting an optimal alveolar bone preservation.

The present results are in line with recent retrospective<sup>20</sup> and prospective clinical studies<sup>21</sup> about definitive multi-unit abutments connected to implants immediately placed in multiple fresh extraction sockets.

Clinical procedures have been shown to affect soft tissue health around dental implants. The elevation of a full mucoperiosteal flap may lead to a marked bone loss and, therefore, influences the soft tissue behavior.<sup>22</sup> In addition, the stability of the soft tissues may be influenced by the prosthetic treatment approach. In animal studies, it was found that repeated abutment disconnection and reconnection is associated with disruption of the mucosal seal and an increase of the size, as well as a more apical positioning, of the transmucosal barrier.<sup>8,23</sup> Hence,

as histologically confirmed, abutments should not be replaced once they have been connected.<sup>24</sup> For this reason, placement of the definitive abutment on the day of surgery has been previously proposed. In a prospective clinical study, the group where the definitive abutment was placed at surgery showed significantly less bone loss compared to a control group using provisional abutments, up to 3-year follow-up.<sup>10</sup> Another multicenter randomized controlled trial confirmed this finding.<sup>11</sup>

When connecting the definitive abutment immediately after surgery, the healing of the soft tissue takes place at the definitive restoration instead of at the healing abutment. Therefore, the emergence profile heals immediately toward an optimal shape. Furthermore, the immediate placement of the definitive restoration abutment allows formation of a long junctional epithelium between the restoration abutment and the soft tissue representing a proper seal and should not be separated again.<sup>24-27</sup> Such seal between the oral environment and the alveolar bone surrounding the implant is an important factor contributing to the long-term success of implant-supported restorations.<sup>26,28</sup> The choice of implant type used in this study was based on the fact that these implants had been designed to achieve high primary stability and excellent esthetics including in difficult situations such as fresh post-extraction sockets.

A recent randomized study on 210 patients compared immediate implants, immediate-delayed implants (inserted 6 weeks postextraction) and delayed implants (inserted 4 months postextraction).<sup>29</sup> In that study the same implant as the present study was used, though only single implants were considered, no angulated abutments were used, and no definitive abutment was placed at surgery. In that study, no statistically significant differences in implant failure rates, complication rates and bone level changes were found among the three groups one year after loading, confirming the validity of the immediate implant approach.<sup>29</sup> Furthermore, better aesthetic results were observed in the immediate and immediate-delayed procedure, respect to the delayed one.

## **CONCLUSIONS**

The results of this study indicate that positioning post-extraction implants so as to take maximum advantage of the remaining bone, using implants designed for achieving a high primary stability and connecting them immediately to the definitive abutment is a technique that offers a safe, effective and well-accepted solution for immediate rehabilitation with screw-retained partial and full-arch prostheses.

## **ACKNOWLEDGEMENTS**

Study supported in part by a grant of Nobel Biocare (grant no. 2014-1321). The authors also thank Nobel Biocare for providing support with data analysis.

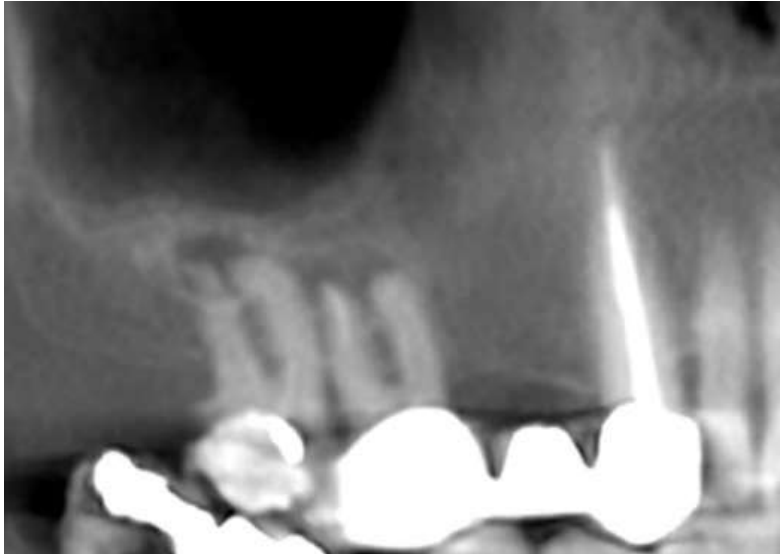
## REFERENCES

1. Krekmanov L, Kahn M, Rangert B, Lindström H. Tilting of posterior mandibular and maxillary implants for improved prosthesis support. *Int J Oral Maxillofac Implants* 2000;15:405-414.
2. Del Fabbro M, Bellini CM, Romeo D, Francetti L. Tilted implants for the rehabilitation of edentulous jaws: A systematic review. *Clin Impl Dent Rel Res* 2012;14:612-621.
3. Malò P, Rangert B, Nobre M. "All-on-four" immediate function concept with Brånemark System® Implants for completely edentulous mandibles: a retrospective clinical study. *Clin Implant Dent Relat Res* 2003; 5:2-9.
4. Del Fabbro M, Ceresoli V. The fate of marginal bone around axial vs. tilted implants: A systematic review. *Eur J Oral Implantol* 2014; 7(Suppl. 2):S171-S189.
5. Testori T, Zuffetti F, Capelli M, Galli F, Weinstein RL, Del Fabbro M. Immediate versus Conventional Loading of Post-Extraction Implants in the Edentulous Jaws. *Clin Impl Dent Rel Res* 2014;16:926-935.
6. Chen ST, Wilson TG Jr, Hämmerle CH. Immediate or early placement of implants following tooth extraction: review of biologic basis, clinical procedures, and outcomes. *Int J Oral Maxillofac Implants* 2004;19 (Suppl):12-25.
7. Chen ST, Buser D. Clinical and esthetic outcomes of implants placed in postextraction sites. *Int J Oral Maxillofac Implants* 2009;24 (Suppl):186-217.
8. Abrahamsson I, Berglundh T, Lindhe J. The mucosal barrier following abutment dis/reconnection, An experimental study in dogs. *J Clin Periodontol* 1997;24:568-572.
9. Rompen E. The impact of the type and configuration of abutments and their (repeated) removal on the attachment level and marginal bone. *Eur J Oral Implantol* 2012;5(Suppl):S83-S90.
10. Canullo L, Bignozzi I, Cocchetto R, et al: Immediate positioning of a definitive abutment versus repeated abutment replacements in post-extractive implants: 3-year follow-up of a randomised multicentre clinical trial. *Eur J Oral Implantol* 2010;3:285-296
11. Grandi T, Guazzi P, Samarani R, Maghaireh Hassan, Grandi G. One abutment-one time versus a provisional abutment in immediately loaded post-extractive single implants: A 1-year follow-up of a multicentre randomised controlled trial. *Eur J Oral Implantol* 2014; 7:141-149.

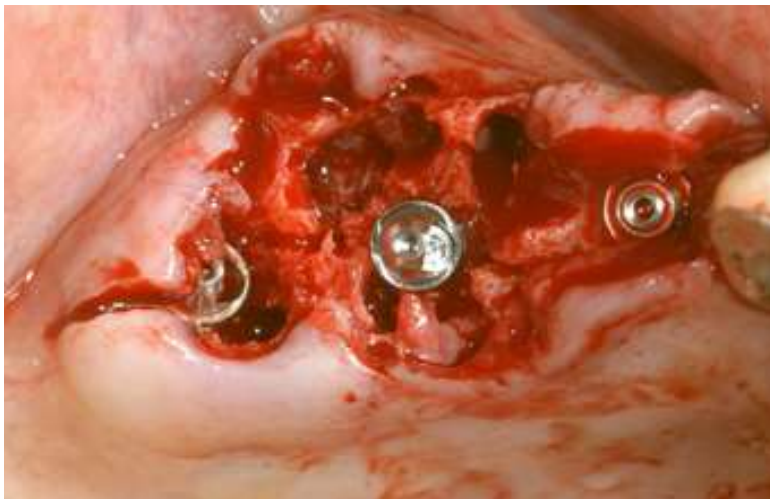12. Iglhaut G, Schwarz F, Winter RR, Mihatovic I, Stimmelmayer M, Schliephake H. Epithelial attachment and downgrowth on dental implant abutments-A comprehensive review. *J Esthet Restorative Dent* 2014;26:324-331.
13. von Elm E, Altman DG, Egger M, et al; STROBE Initiative. The Strengthening the Reporting of Observational Studies in Epidemiology (STROBE) statement: guidelines for reporting observational studies. *J Clin Epidemiol*. 2008;61:344-349.
14. World Medical Association Declaration of Helsinki: ethical principles for medical research involving human subjects. *JAMA* 2000;284:3043-3045.
15. Villa R, Rangert B. Immediate and early function of implants placed in extraction sockets of maxillary infected teeth: A pilot study. *J Prosthet Dent* 2007;97:S96-S108.
16. Babbush CA, Kutsko GT, Brokloff J. The all-on-four immediate function treatment concept with NobelActive implants: a retrospective study. *J Oral Implantol* 2011;37:431-445.
17. Galindo DF, Butura CC. Immediately loaded mandibular fixed implant prostheses using the all-on-four protocol: a report of 183 consecutively treated patients with 1 year of function in definitive prostheses. *Int J Oral Maxillofac Implants* 2012;27:628-633.
18. Kim DG, Elias KL, Jeong YH, Kwon HJ, Clements M, Brantley WA, Lee DJ, Han JS. Differences between buccal and lingual bone quality and quantity of peri-implant regions. *J Mech Behav Biomed Mater* 2016;60:48-55.
19. Covani U, Cornelini R, Calvo JL, Tonelli P, Barone A. Bone remodeling around implants placed in fresh extraction sockets. *Int J Periodontics Restorative Dent* 2010;30:601-607.
20. Aires I, Berger J. Planning implant placement on 3D stereolithographic models applied with immediate loading of implant-supported hybrid prostheses after multiple extractions: A case series. *Int J Oral Maxillofac Implants* 2016;31:172-178.
21. Pera P, Menini M, Bevilacqua M, Pesce P, Pera F, Signori A, Tealdo T. Factors affecting the outcome in the immediate loading rehabilitation of the maxilla: a 6-year prospective study. *Int J Periodontics Restorative Dent*. 2014;34:657-665.
22. Araujo MG, Lindhe J: Ridge alterations following tooth extraction with and without flap elevation: an experimental study in the dog. *Clin Oral Implants Res* 2009;20:545-549.

23. Rodriguez X, Vela X, Mendez V, et al: The effect of abutment dis/reconnections on peri-implant bone resorption: a radiologic study of platform-switched and non-platform-switched implants placed in animals. *Clin Oral Implants Res* 2013;24:305-311.
24. Becker K, Mihatovic I, Golubovic V, et al: Impact of abutment material and dis-/re-connection on soft and hard tissue changes at implants with platform-switching. *J Clin Periodontol* 2012;39:774-780.
25. Zucchelli G, Mazzotti C, Mounssif I, et al: A novel surgical-prosthetic approach for soft tissue dehiscence coverage around single implant. *Clin Oral Implants Res* 2013;24:957-962.
26. Cochran DL, Mau LP, Higginbottom FL, et al: Soft and hard tissue histologic dimensions around dental implants in the canine restored with smaller-diameter abutments: a paradigm shift in peri-implant biology. *Int J Oral Max Implants* 2013;28:494-502.
27. Welander M, Abrahamsson I, Berglundh T: The mucosal barrier at implant abutments of different materials. *Clin Oral Implants Res* 2008;19:635-641.
28. Cutrim ES, Peruzzo DC, Benatti B: Evaluation of soft tissues around single tooth implants in the anterior maxilla restored with cemented and screw-retained crowns. *J Oral Implantol* 2012;38:700-705.
29. Esposito M, Zucchelli G, Cannizzaro G, et al. Immediate, immediate-delayed (6 weeks) and delayed (4 months) post-extractive single implants: 1-year post-loading data from a randomised controlled trial. *Eur J Implantol* 2017;10:11-26.

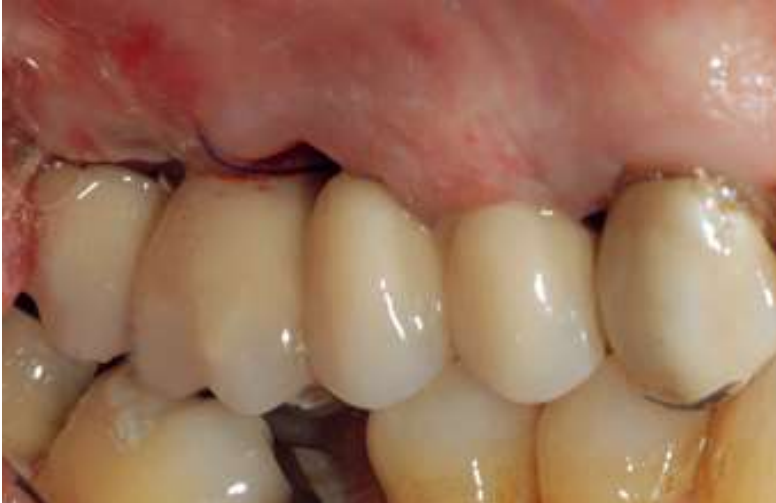**Figure 1.** First clinical case. Sixty-one years old nonsmoker male presenting with pain and mobility in the upper right posterior region. Image from CT scan showing hopeless first and second upper right molar with very limited amount of residual bone.



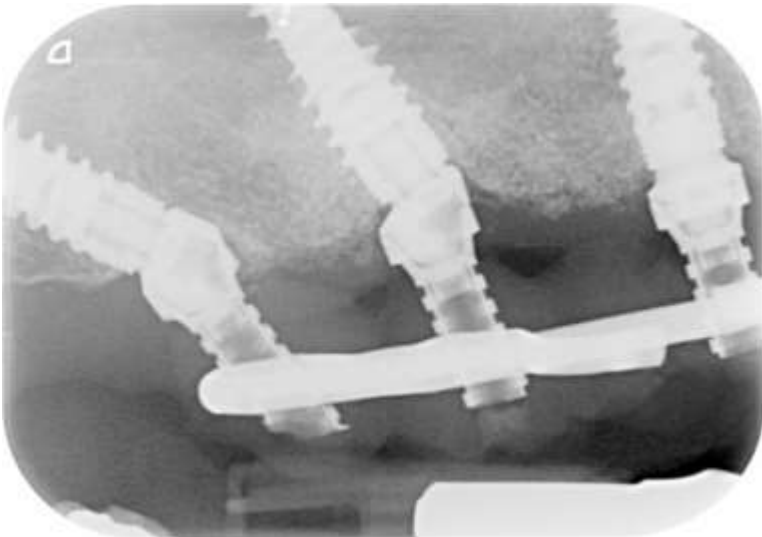
**Figure 2.** Case 1. After flapless extraction, an implant was placed in the healed site in position 5 with a straight axis. The implant in position 3 was placed with a palatal-buccal tilt and the implant emerging in position 2 was inserted about 45 degrees tilted with respect to the occlusal plane, with the apex pointing distally. Then, multi unit abutments were positioned and oriented to have the screw access hole in the occlusal position of the prosthesis. MUA on 2 and 3 were angulated by 30 degrees.



**Figure 3.** Case 1. The provisional screw-retained prosthesis, reinforced with a metal casting kept out of centric occlusion, was connected 24 hours after surgery.

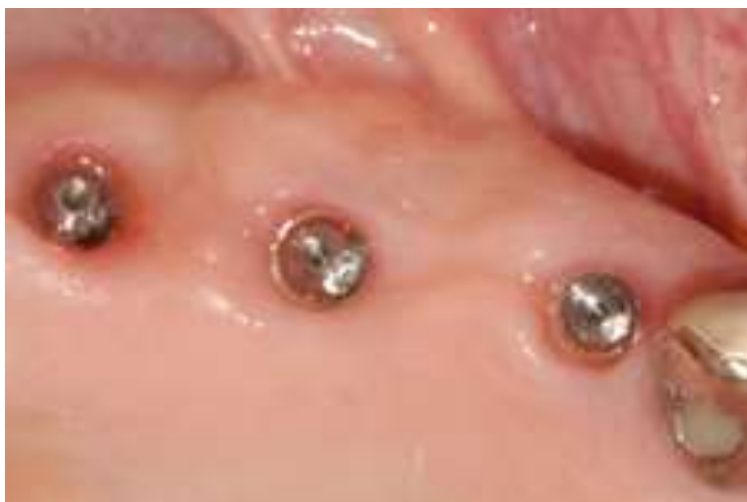

**Figure 4.** Case 1. Periapical radiograph of the implants supporting the provisional restoration, taken prior to the placement of the final prosthesis. Peri-implant bone condition appears good.

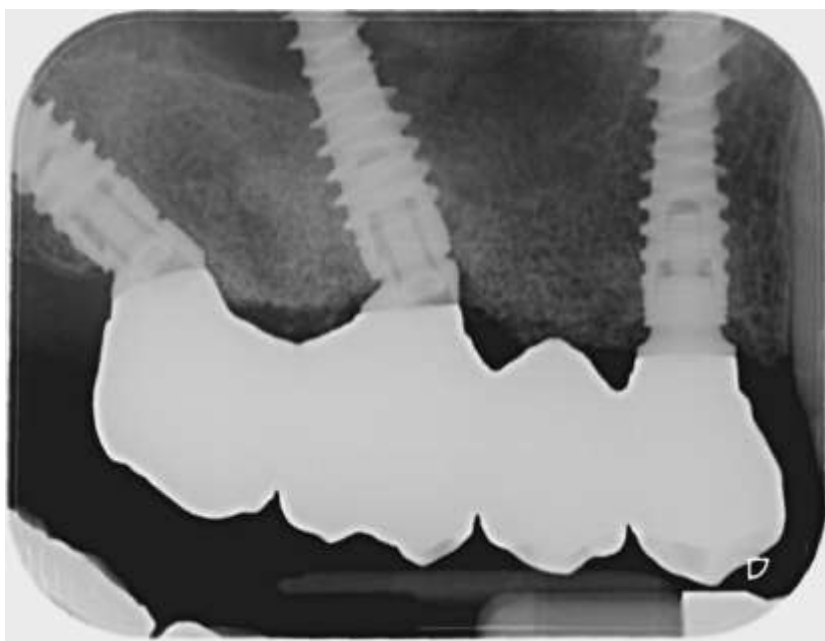



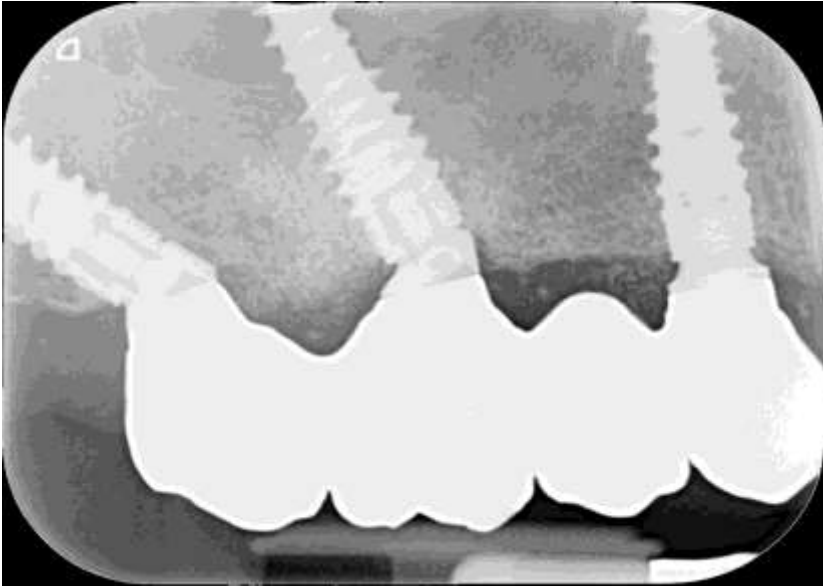
**Figure 5.** Case 1. Soft tissue healing at one year follow-up. The excellent condition of soft tissues may be appreciated.



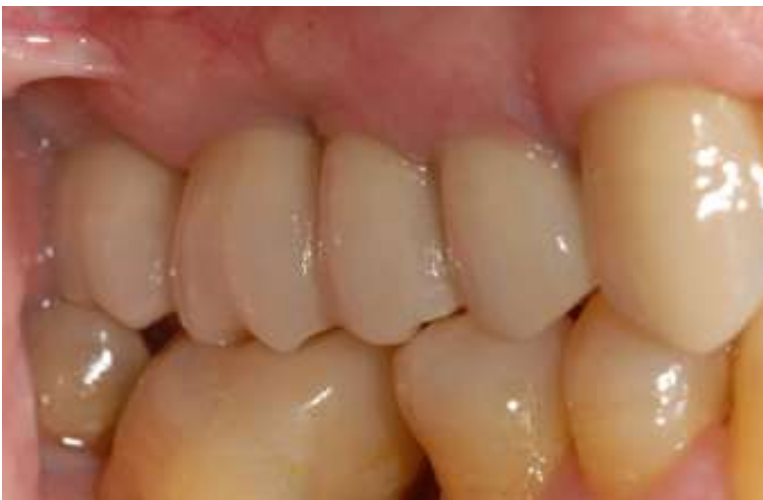**Figure 6.** Case 1. Periapical radiograph taken at two years after implant placement, with the final restoration.



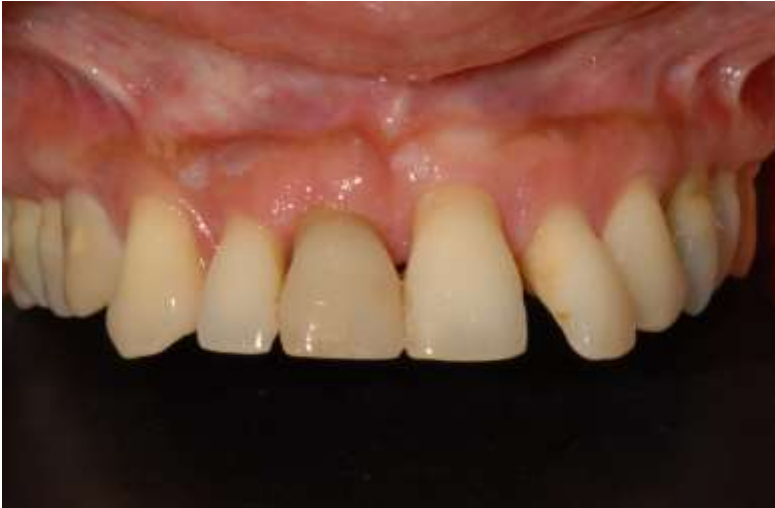**Figure 7.** Case 1. Periapical radiograph taken at the three-year follow-up. All implants were stable and a fair preservation of the marginal bone levels was observed.



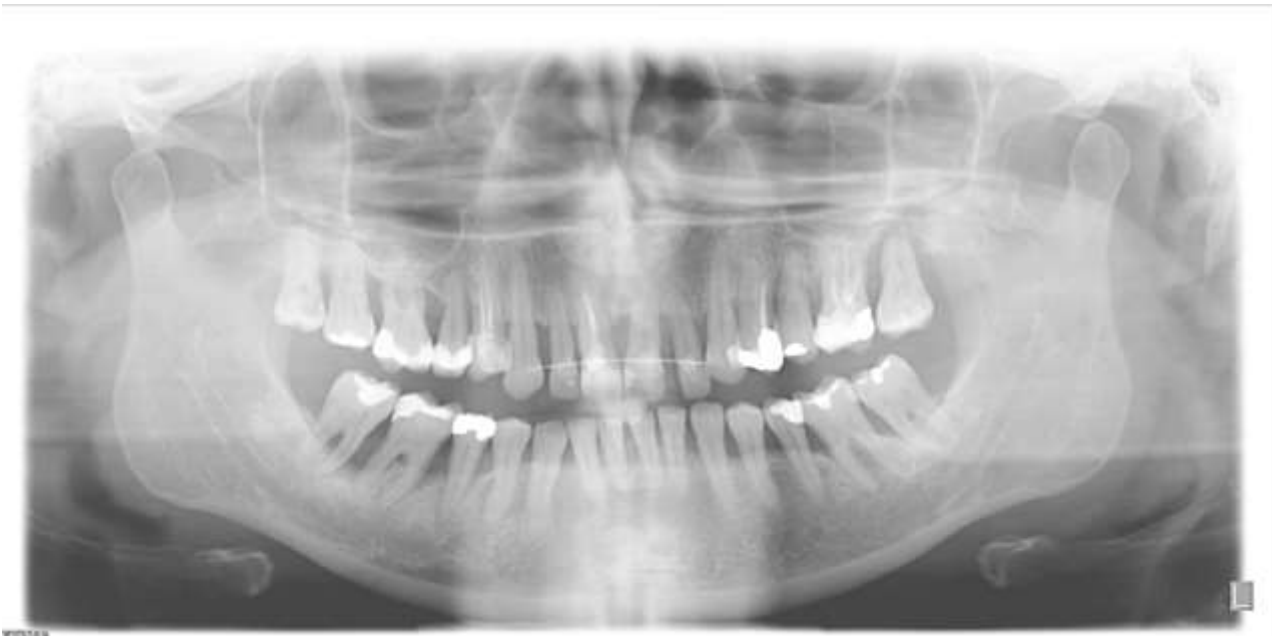**Figure 8.** Case 1. Final screw-retained zirconia prosthesis 3 years after implant placement. The previous canine tooth crown has been replaced by a zirconia one. The peri-implant tissues appear healthy and a negligible amount of plaque was observed, indicating a good oral hygiene level maintenance. The patient was highly satisfied with mastication function, aesthetics and phonetics.



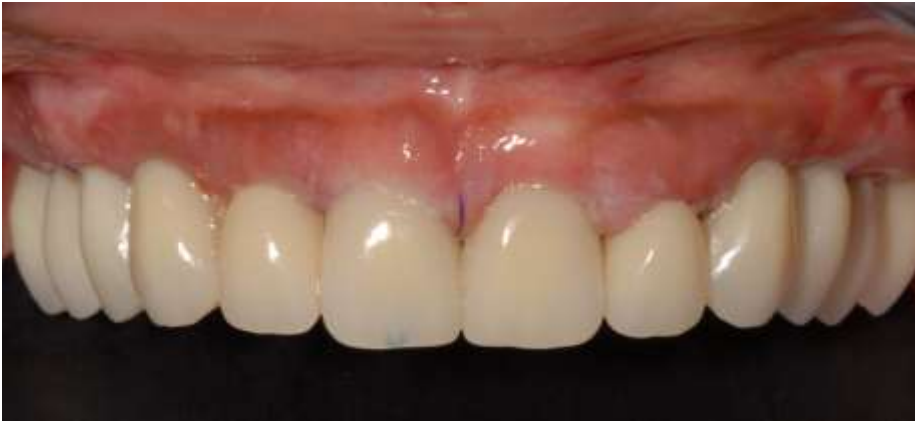**Figure 9.** Second clinical case. A 40-year old nonsmoker female with advanced generalized periodontal disease, unsuccessfully treated for years by her periodontist, complained of tooth mobility and poor aesthetics. Frontal view.



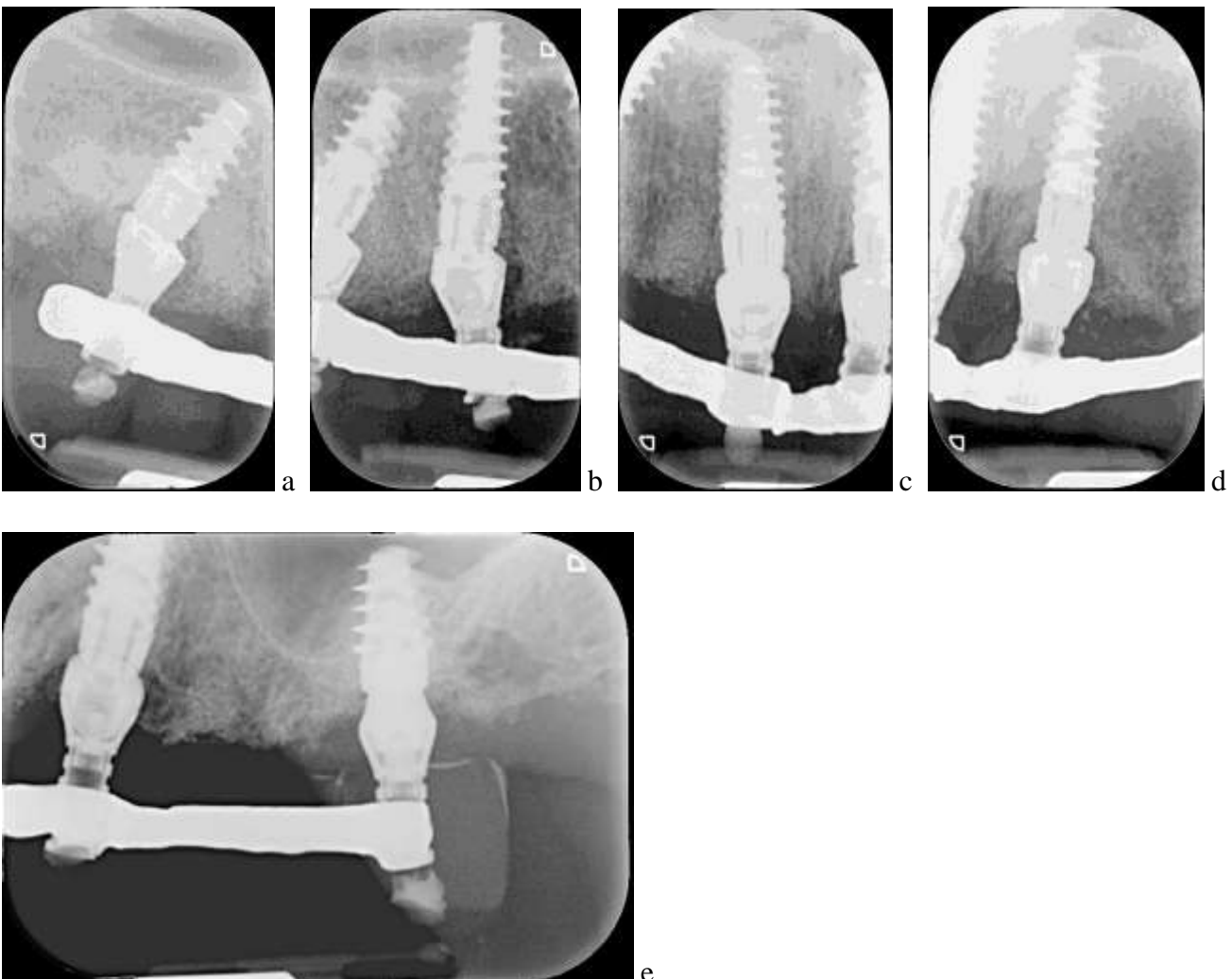
**Figure 10.** Case 2. Pre-surgical panoramic radiograph showing the status of generalized advanced periodontal disease, that required extraction of all maxillary teeth.



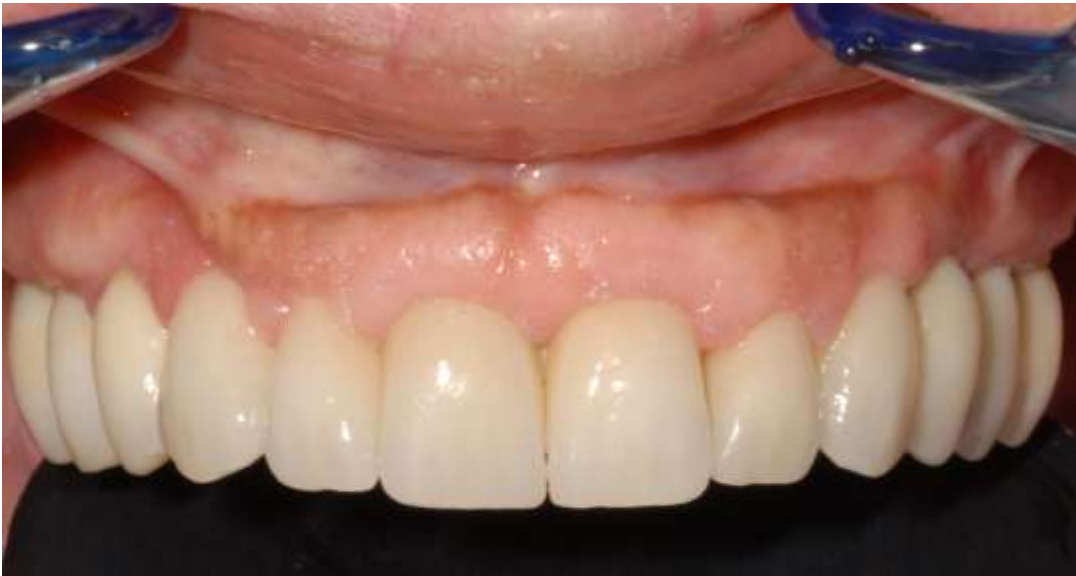**Figure 11.** Case 2. Provisional full-arch screw-retained prosthesis reinforced with a metal casting was delivered 24 hours after the placement of six implants.



**Figure 12.** Case 2. Periapical radiograph of the implants supporting the provisional restoration one year after implant placement. Implants were placed in position 3 (a), 5 (b), 8 (c), 9 (d), 11 and 14 (e).



**Figure 13.** Case 2. Final screw-retained zirconia prosthesis three years after implant placement. Soft tissue appeared healthy and the emergence profile of zirconia crowns looked natural. The patient was highly satisfied with the final result.



**Figure 14.** Case 2. Periapical radiograph of the implants in position 3 (a), 5 (b), 8 and 9 (c), 11 and 14 (d), supporting the final restoration at three-year follow-up. Bone levels around implants were good.

