

# Short-Term Clinical Results of a Calcium Magnesium Carbonate-Blasted Dental Implant

Riccardo Sirello<sup>1</sup>, Donato Frattini<sup>2</sup>, Lorenzo Banci<sup>3</sup>, Andrea Baracchino<sup>4</sup>, Elena Canciani<sup>5</sup>, Claudia Dellavia<sup>6</sup>

1-DDS, Università degli Studi di Milano, laboratorio sezioni sottili, dip. di Scienze Biomediche Chirurgiche e Odontoiatriche, Italy. 2-MD, Unità Operativa di chirurgia Maxillo Facciale, ASST Ovest Milanese, Legnano, Italy. 3-Research and Development Department, Permedica S.p.A., via Como 38, 23807 Merate, Italy. 4-DDS, Private practice, Livorno, Italy. 5-Post Doc, PhD, MSc, Università degli Studi di Milano, Milano, Italy, Dipartimento di Scienze Biomediche, Chirurgiche ed Odontoiatriche. 6-Associate Professor, PhD, DDS, Università degli Studi di Milano, Milano, Italy, Dipartimento di Scienze Biomediche, Chirurgiche ed Odontoiatriche.

Correspondence to:  
Dr. Riccardo Sirello, Via Carlo Lorenzini 17, 57124 Livorno, Italy.  
Phone: +39 338 8143709  
Contact Us: [www.ijohmr.com](http://www.ijohmr.com)

## ABSTRACT

**Introduction:** There are several dental implant surfaces available in oral implantology nowadays. Rough-surfaced implants, such as grit blasted implants, have a well proven clinical efficacy, but few clinical results regarding calcium magnesium carbonate-blasted implants have been reported in the literature. The study aims at reporting the survival rate and the marginal bone loss (MBL), after the first year of function of a moderately roughened calcium magnesium carbonate-blasted implant, in partially edentulous patients.

**Materials and Methods:** We retrospectively analyzed the clinical records and radiographic data of a series of patients treated for a single or multi-tooth restoration in a single center with the ProSystem<sup>®</sup> Advance implants by Permedica, in order to assess implant survival and any change of peri-implant bone level at the 12-month follow-up. **Results:** A total of 352 ProSystem<sup>®</sup> Advance implants were implanted in 121 patients. After the healing period, 345 implants were found to be stable (98.0%). Seven implants (2.0%) failed to osseointegrate during the healing period in 7 patients. The implant survival rate after implant-abutment connection was 100% at the 12-month follow-up. The total average MBL was 0.88 mm from fixture insertion to 12-month follow-up.

**Conclusion:** The calcium magnesium carbonate-blasted implants showed survival and MBL results comparable to other clinically well-proven grit blasted implants.

**KEYWORDS:** Dental Implants, Calcium Magnesium Carbonate-Blasting, Implant Survival, Marginal Bone Loss.

## INTRODUCTION

To date, in oral implantology, there is still no clinical evidence regarding which dental implant works best. There are several implant surfaces available on the market for oral implantology. Implant surfaces differ for chemical composition, topography, roughness and manufacturing processes.

The conventional roughening methods commonly used to modify the machined implant surface are titanium plasma spraying, acid etching, grit blasting, titanium oxide anodizing and, more recently, pulsed laser treatment.<sup>1</sup>

Rough implant surfaces, such as grit blasted surfaces, have shown improved osseointegration and primary anchorage compared to machined/turned surfaces, in both *in vitro* and *in vivo* tests.<sup>2-6</sup> However, the available literature does not confirm the superior clinical performance of roughened surfaces, in terms of osseointegration (found *in vitro* and *in vivo* testing), when compared to the smooth machined surfaces.<sup>7-9</sup>

One of the most common grit blasted surfaces with the longest and most comprehensive clinical follow-up published for roughened dental implant surfaces is the titanium dioxide-blasted surface by Astra Tech.<sup>10,11</sup> Titanium dioxide blasting gives a moderate roughness of 1-2  $\mu\text{m}$  on titanium surfaces, which seems to be the most

favorable range of roughness for osseointegration.<sup>12,13</sup> Other blasting media are available for grit blasting, such as alumina or calcium magnesium carbonate particles, which give a similar range of roughness and microtopography as that of the titanium surface.

To our knowledge, no study available in literature reports on the clinical results of calcium magnesium carbonate-blasted dental implants.

This study aims at reporting the survival rate and marginal bone loss after the first year of function of a moderately roughened calcium magnesium carbonate-blasted implant in partially edentulous patients.

## MATERIAL AND METHODS

This retrospective study documents a series of patients who were treated with a grit-blasted implant in a single center from 2014 to 2015. The inclusion criterion was partially edentulous patients who received one or more dental implants, subsequently loaded by a complete fixed definitive dental prosthesis. All the patients in this study received the same dental implants (ProSystem<sup>®</sup> Advance by Permedica, (Figure 1) for single or multi-tooth restorations.

ProSystem<sup>®</sup> Advance implants by Permedica (Permedica Manufacturing S.p.A., Merate, Italy), are intended for use

How to cite this article:

Sirello R, Frattini D, Banci L, Baracchino A, Canciani E, Dellavia C. Short-Term Clinical Results of a Calcium Magnesium Carbonate-Blasted Dental Implant. *Int J Oral Health Med Res* 2018;4(6):1-6.



Figure 1. ProSystem® Advance implants by Permedica

in odonto-stomatological surgical interventions for single/multi-tooth reconstructions or entire dental arches, together with single crowns or prosthetic components. ProSystem® Advance implants are made of a pure grade 4 titanium (ISO 5832/2). The implant's titanium surface is micro-structured by grit-blasting it with a calcium magnesium carbonate [CaMg(CO<sub>3</sub>)<sub>2</sub>] based media. Calcium magnesium carbonate particles have a granulometry distribution that ranges from 200 µm to 400 µm (60-80%) and below 200 µm (20-40%). The average surface roughness (Sa) is 0.8 µm ± 0.03, thus obtaining a moderately irregular surface micro-topography (Figure 2 A and B). In order to prevent




Figure 2 A-B. ProSystem® Advance surface topography by Permedica. The Implant surface is machined and then grit blasted with CaMg(CO<sub>3</sub>)<sub>2</sub> micro particles (size below 400 µm). A: 200 µm magnification. B: 10 µm magnification.

surface contamination, the residual blasting particles embedded in the implant's surface after grit-blasting are completely removed with a validated decontamination process, which consists of a weak acid solution bath, followed by ultrasonic vibration cleaning and a final cold plasma decontamination. The implant's neck surface in proximity of the bone crest is machined and polished (not micro-sandblasted) for a length ranging from 0.2 to 0.5 mm, depending on size. The implant's neck portion, just below the polished portion, has micro-threads with the same micro-sandblasted surface of the implant. The micro threads on the fixture's apex prevent stress concentration around the alveolar ridge crest, for the purpose of reducing marginal bone loss.

The implants come in a conical and/or cylindrical geometrical shape, with both external and internal hexagon connections. The sizes available range from 3.0 mm to 6.2 mm in diameter and from 8.5 mm to 15 mm in length. The implant's external threading has a trapezoidal or triangular profile, with a double principle respectively for the conical and cylindrical version. Two to four machined anti-rotational micro-stops at the apex of the implant increase the self-tapping effect.

The surgical technique used for fixture installation followed the outline described in the manual for the

ProSystem Advance Implant System. Both one-stage and two-stage procedures were included. One-stage installation procedure requires the immediate placement of the implant plus abutment with non-submerged healing, whereas the two-stage installation protocol requires the implants to be fully submerged beforehand and for the abutments to be placed with a second surgical procedure after 3 (mandible) or 6 (maxilla) months of healing. All the maximal insertion torque values were recorded using the manufacturer's recommended drilling units. The insertion torque values applied were between a minimum of 15 Ncm and a maximum of 70 Ncm, in function of bone density and hardness.

The bone quality was classified at placement time according to Lekholm et Zarb classification.<sup>14</sup> The patient's oral hygiene was classified as either good, sufficient or poor.

The healing time between implant placement and loading ranges from 3 to 6 months, depending on the bone quality found during the first stage surgery. Clinical and radiographic examinations were usually performed at 6 and 12 months after fixture insertion. Clinical records and radiographic data were reviewed to assess implant survival and the change of peri-implant bone level.

Implant survival was met when: the implant was found to be still stable, in place and osseointegrated at healing time and at the 12-month follow-up. The change of peri-implant bone level between the fixture insertion during the first surgery and the 12-month evaluation was also recorded. The marginal bone loss (MBL), defined as the distance between the reference point on the fixture and the peri-implant bone level, on both mesial and distal

sides of the implants, was evaluated at the 12-month follow-up. The crestal bone level at fixture insertion served as a point of reference when reporting the MBL. Therefore, we considered as MBL the bone remodeling that may occur early after implant installation together with the bone resorption that may be detected around implants after loading. The MBL was recorded as follows: 0 mm as no MBL, 1.5 mm as MBL up to 1.5 mm and 2.5 mm as MBL up to 2.5 mm.

## RESULTS

Between 2014 and 2015, a series of 352 dental implants were implanted in 121 patients. 180 implants were placed in the maxilla and 172 implants in the mandible. The average age of the patients in this study was 45 years old (range 27 to 70 years). Sixty-six were women and 55 were men.

Oral hygiene was classified as good in 45 patients (13%), sufficient in 229 (65%) and poor in 78 patients (22%). Fifteen implants (4%) were implanted in a class I quality bone, 166 (47%) implants in a class II quality bone, 119 (34%) implants in a class III quality bone and 52 implants (15%) in a class IV quality bone.

A conically shaped geometry with internal or external hexagonal connection was used respectively in 137 implants (39%) and in 2 implants (0.5%), while a cylindrically shaped geometry with internal or external hexagonal connection was used respectively in 150 implants (43%) and 63 implants (18%). The size (diameter and length) of implants used are summarized in Table 1 and Figure 3 A and B.

Diameter	∅ 3.8 mm	∅ 4.0 mm	∅ 4.7 mm	∅ 5.2 mm
N. of implants	135 (38%)	80 (23%)	100 (28%)	37 (10%)
Length	8.5 mm	10 mm	12 mm	15 mm
N. of implants	26 (7%)	183(52%)	139 (40%)	4 (1%)

Table 1. Diameter and length distribution of the ProSystem® Advance fixtures implanted

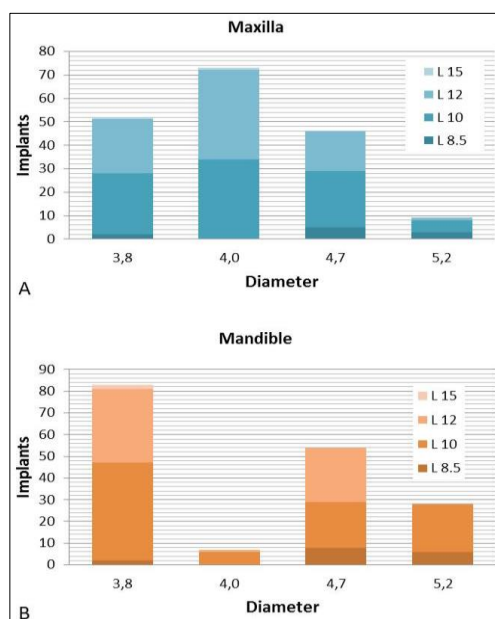


Figure 3A-B. Diameter and length distribution of the ProSystem® Advance fixtures implanted in the maxilla (A) and in the mandible (B)

A two-steps surgical technique was used for the placement of 277 implants (79%), the immediate placement procedure was performed for 66 implants (19%), while a post-extraction procedure was used for 9 implants (2%). During the second step procedure, at healing time, a torque test with 20 Ncm reverse screwing was performed on 148 implants (42%) with good results (stable and osseointegrated) in 144 (97%).

During the second surgery after healing time, 345 implants were found stable (98.0%). Seven implants (2.0%) failed to osseointegrate during the healing phase and resulted non-stable in 7 patients (Table 2). At the 6 and 12-month follow-ups, all 345 stable implants at healing time survived with no further failures. Excluding the failed cases occurred during healing time, the implant survival after abutment connection was 100% at the 12-month follow-up.

An MBL ranging between 0 mm and 1.5 mm was visible at the 12 month-follow-up in 189 implants (56%) and an MBL ranging between 1.5 mm to 2.5 mm was visible in 7 implants (2%). No MBL was visible in the remaining 144 implants (42%). The total average MBL was 0.88 mm from fixture insertion to 12-month follow-up.

## DISCUSSION

The osseointegration property of titanium dental implants is related to their composition and surface roughness. Rough-surfaced implants favor both bone anchoring and biomechanical stability. It is well recognized that titanium rough surfaces allow a favorable biological response in terms of osseointegration.<sup>2</sup>

Implant surface roughness and topography influence the MBL, but the literature does not give any clinical evidence that demonstrates a specific surface superiority in terms of MBL and osseointegration.<sup>7,9</sup>

The roughness and the micro-topography of the titanium surface obtained by grit-blasting allow an optimal osseointegration in comparison to surface topographies obtained by other different treatments. These results were confirmed by clinical studies, in vivo tests and histological analysis.<sup>3</sup> Most commonly used blasting media contain hard ceramic particles such as alumina (Al<sub>2</sub>O<sub>3</sub>), titanium dioxide (TiO<sub>2</sub>) or calcium phosphate.

Grit blasting with TiO<sub>2</sub> particles is a valid roughening method for titanium dental implant surfaces, as is shown by the excellent, clinically proven, TiOblast™ surface of the Astra Tech implant system, which is historically one of the most used grit blasted implant used in oral implantology. Titanium dioxide particles, with an average size of 25 μm, produce a moderately roughened surface of 1.10 μm (Sa).<sup>1,10,12</sup> Nowadays, there is a vast consensus on the clinical advantages of moderately roughened surfaced implants with a micro-topographic profile obtained through grit blasting.<sup>1</sup> The TiOblast™ surface has a significant increased bone-to-implant contact and mechanical anchorage, compared to machined surfaces, that are well-documented human in

Case	Sex	Age	Failed implants	Pos.	Type	Ø	H	Bone*	Oral Hygiene	Torque Test 20 Ncm
1	M	42	1	44	KI	4.7	12	D2	G	Not done
2	M	63	1	21	CI	3.8	10	D3	S	Failed
3	F	70	1	21	KI	4.0	12	D3	S	Passed
4	F	43	1	12	KI	4.0	12	D2	S	Not done
5	F	42	1	16	KI	4.7	10	D4	S	Failed
6	F	35	1	14	KI	5.2	10	D3	S	Not done
7	F	42	1	14	CE	3.8	12	D4	S	Not done

Table 2. Details of failed implants. KI, conical - internal connection. CI, cylindrical - internal connection. CE, cylindrical - external connection. G, good. S, sufficient.  
\*Bone quality classified according to Lekholm et Zarb.<sup>14</sup>

Vivo<sup>4</sup> and animal histology studies.<sup>5,6,15</sup> One of the biggest concerns about roughened surfaces is the increased risk of developing early peri-implantitis compared to the lower risk in relatively smooth surfaces, such as with machined/turned surfaces, even though there is limited evidence to support this assessment.<sup>7</sup> A moderate roughness (i.e., surface roughness of 1-2 µm, Sa) has been seen to minimize the risk of peri-implantitis.<sup>13</sup>

Alumina is frequently used as a blasting material and produces a moderately roughened surface depending on the granulometry of the alumina particles.<sup>7,16-18</sup> A concern regarding the grit blasting roughening method is the residual particles that can remain embedded in the grit blasted implant surface.<sup>19</sup> Residual particles can theoretically impair or delay the direct contact with the bone at the bone-implant interface level, leading to a reduced bone-to-implant contact area and, therefore, to a reduced osseointegration of the implant. Residual aluminum oxide particles can embed themselves in the titanium surface and the residue can remain even after ultrasonic cleaning, acid passivation and sterilization. Alumina residue proves hard to remove from titanium surfaces and it is insoluble in acid solutions. However, there is a lack of evidence that aluminum oxide residual particles could affect the osseointegration of titanium dental implants.<sup>19</sup>

The Permedica implant surface is grit blasted with a natural calcium magnesium carbonate-based blast media in order to obtain an average roughness (Sa) of 0.8 µm. Residual magnesium calcium carbonate particles embedded in titanium surfaces are easily removable with a weak acid bath, as magnesium calcium carbonate is soluble in a citric acid solution. The high purity of the chemical composition of the calcium magnesium carbonate-blasted titanium surfaces is confirmed by in vitro analysis, the elevated biocompatibility and the affinity of the surface to create a direct contact with the bone are proven by in vitro testing with osteoblast (20). Enhanced bone-to-implant contact is obtained by cold plasma decontamination used by Permedica to treat the implant surface.<sup>21-23</sup>

Grit-blasted roughened implants, of which the TiO<sub>2</sub>-blasted Astra Tech implants is one of the most representative, have extensive clinical documentation, reporting excellent results in long-term follow-ups. The TiOblast surface by Astra Tech implants has among the longest and most comprehensive prospective follow-up

published for moderately roughened dental implant surface, with survival rates ranging from 89.7% to 96.9% over 10 years.<sup>10-12</sup> A meta-analysis including 10 prospective studies on the Astra Tech implant reported an average survival rate of 98% after 5 years of function.<sup>24</sup> Rasmusson et al.<sup>10</sup> reported that 6 failures occurred within the first year in a study of 199 TiO<sub>2</sub>-blasted implants (Astra Tech), with a cumulative survival of 96.9% at the 12-month follow-up, which remained constant over the following 10 years of follow-ups.

Other studies reported higher survival rates for the Astra Tech implants, at the 5 year-follow-up, compared to traditional machined implants, but without any significant differences in terms of survival rates and change of marginal bone levels.<sup>25-27</sup> Astra Tech implants have excellent survival rates in the first year of loading, which in literature are reported to be 100%<sup>25-29</sup> or lower at 96.4%.<sup>27,30-32</sup>

Excellent early survival results are reported in literature also for alumina-blasted implants (Southern Implants). Several studies with alumina-blasted implants showed 100% of survival rate at the 2-year follow-up (16-18). However, literature is lacking long-term studies with this type of implant roughened surface. Esposito et al. (7), through a meta-analysis on high-quality RCTs, did not support evidence of the superiority of a specific surface characteristic between different brands of dental implants in terms of clinical results and survival rates.

The Permedica ProSystem® Advance implants failure rate (2.0%) at healing time is comparable to the implant failure rate reported in the literature. No other implants failed after healing time, thus showing a survival rate of 98.0% at the 12-month follow-up. In our series, 7 fixtures failed before loading in 7 patients, of whom 5 did not have good bone quality (D3-4).

Most implant failures occur within the first year of loading.<sup>33</sup> Many studies have considered the 12-month follow-up to be a critical point because the Kaplan-Meier survival curve almost reaches a plateau one-year after implant placement. In a large retrospective clinical study, more than 57% of the TiO<sub>2</sub> grit-blasted Astra Tech implants failed before implant loading, leading to a cumulative survival rate of 96.2% at the 5-year follow-up.<sup>34</sup> For these reasons, we expect to have a very low decrease in the cumulative survival rate of our ProSystem® Advance implant series for the mid-term follow-ups.

Approximately fifty percent of the implants in the present study was associated with an MBL of up to 1.5 mm within the first year of function. The average total MBL around the ProSystem® Advance implants was 0.88 mm from fixture insertion at the 12-month follow-up, and this result is comparable to normal values of MBL found in literature. Historically, approximately 1.0 mm to 1.5 mm of bone loss has occurred immediately following second-stage surgery and implant loading.

A review literature study through a meta-analysis estimated an average MBL of 0.75 mm at the 5 year follow-up with Brånemark implants.<sup>24</sup> In most of the studies included in the review, the major part of the MBL occurred during the first year after prosthetic loading, after which the marginal bone levels stabilized.<sup>27</sup> An average MBL of 1 mm within the first year and further annual loss not exceeding 0.2 mm, which in turn corresponds to 1.8 mm over 5 years are normal and accepted values of a successful implant.<sup>24</sup>

A long-term follow-up study on a large series of turned Brånemark implants showed an MBL of  $\geq 3$  mm at the 12-month follow-up in 5.6% of 3462 implants.<sup>35</sup> The average peri-implant bone levels below the abutment junction were 1.1 mm at prosthesis placement and 1.6 mm at the 12-month of follow-up. Hereafter, bone levels decrease very slowly during the following years, from 2.1 mm in the second year to 2.3 up to 10 years.<sup>35</sup>

The average bone level changes after 5 years evaluated in an RCT around TiO<sub>2</sub>-blasted implants (Astra Tech) in the upper and lower jaws were respectively 1.74 mm and 1.06 mm, lower but not statistically different than the average bone level change with the Brånemark implants respectively of 1.98 mm and 1.38 mm.<sup>27</sup> Astrand *et al.*<sup>27</sup> reported an average total MBL between fixture insertion and 12-month examination with Astra Tech implants of 1.74 mm and 1.26 mm respectively in the upper and the lower jaws. Similar results with Astra Tech implants are reported by Ravald *et al.*<sup>11</sup>, with an average total MBL between fixture insertion and 12-month examination of 2 mm and 1 mm respectively in the upper and the lower jaws. Van Steenberghe *et al.*<sup>26</sup> reported an average bone level of 1.48 mm below the shoulder of the fixture for the Astra Tech implant at implant loading time.

With the Astra Tech implants, most studies reported an average MBL ranging from 0.1 mm to 0.5 mm, considered from the prosthetic component connection (baseline) at the 12-month examination.<sup>25-27,29,31,32</sup> However, the major postoperative changes of the marginal bone level are found between fixture insertion and the baseline.

A review literature study through a meta-analysis estimated a pooled average MBL from the baseline of 0.24 mm at the 5-year follow-up with Astra Tech implants, with a significant difference compared with Brånemark implants with a pooled average MBL of 0.75 mm.<sup>24</sup>

This study shows how MBL results obtained with Permedica implants are also comparable with the results obtained from benchmark implants such as Astra Tech.

Marginal bone levels decrease in a similar manner with grit blasted implants, with a stabilized MBL after 1 year of loading.<sup>36</sup>

Rough implant neck surface with micro threads could have an effect in reducing the MBL compared to polished neck surfaces or rough neck surfaces without micro thread.<sup>36,37</sup>

## CONCLUSION

Considering the outcomes mentioned above, calcium magnesium carbonate-blasted ProSystem® Advance Implant by Permedica can be reliable and successful dental implants for edentulous patients, with performances comparable to those of others grit blasted implants. Further studies and longer follow-ups are needed to confirm these conclusions.

## REFERENCES

1. Le Guehennec L, Soueidan A, Layrolle P, Amouriq Y. Surface treatments of titanium dental implants for rapid osseointegration. *Dent Mater* 2007;23:844-54.
2. Lincks J, Boyan BD, Blanchard CR, Lohmann CH, Liu Y, Cochran DL, *et al.* Response of MG63 osteoblast-like cells to titanium and titanium alloy is dependent on surface roughness and composition. *Biomaterials* 1998;19:2219-32.
3. Herrero-Climent M, Lazaro P, Vicente Rios J, Lluch S, Marques M, Guillem-Marti J, *et al.* Influence of acid-etching after grit-blasted on osseointegration of titanium dental implants: in vitro and in vivo studies. *J Mater Sci Mater Med* 2013;24:2047-55.
4. Ivanoff CJ, Hallgren C, Widmark G, Sennerby L, Wennerberg A. Histologic evaluation of the bone integration of TiO<sub>2</sub> blasted and turned titanium microimplants in humans. *Clin Oral Implants Res* 2001;12:128-34.
5. Gotfredsen K, Wennerberg A, Johansson C, Skovgaard LT, Hjorting-Hansen E. Anchorage of TiO<sub>2</sub>-blasted, HA-coated, and machined implants: an experimental study with rabbits. *J Biomed Mater Res* 1995;29:1223-31.
6. Wennerberg A, Albrektsson T, Johansson C, Andersson B. Experimental study of turned and grit-blasted screw-shaped implants with special emphasis on effects of blasting material and surface topography. *Biomaterials* 1996;17:15-22.
7. Esposito M, Ardebili Y, Worthington HV. Interventions for replacing missing teeth: different types of dental implants. *Cochrane Database Syst Rev* 2014:CD003815.
8. Abrahamsson I, Berglundh T. Effects of different implant surfaces and designs on marginal bone-level alterations: a review. *Clin Oral Implants Res* 2009;20 Suppl 4:207-15.
9. Jokstad A, Braegger U, Brunski JB, Carr AB, Naert I, Wennerberg A. Quality of dental implants. *Int Dent J* 2003;53:409-43.
10. Rasmusson L, Roos J, Bystedt H. A 10-year follow-up study of titanium dioxide-blasted implants. *Clin Implant Dent Relat Res* 2005;7:36-42.

11. Ravald N, Dahlgren S, Teiwik A, Grondahl K. Long-term evaluation of Astra Tech and Branemark implants in patients treated with full-arch bridges. Results after 12-15 years. *Clin Oral Implants Res* 2013;24:1144-51.
12. Al-Nawas B, Kammerer PW, Morbach T, Ladwein C, Wegener J, Wagner W. Ten-year retrospective follow-up study of the TiOblast dental implant. *Clin Implant Dent Relat Res* 2012;14:127-34.
13. Albrektsson T, Wennerberg A. The impact of oral implants - past and future, 1966-2042. *J Can Dent Assoc* 2005;71:327.
14. Strietzel FP, Nowak M, Kuchler I, Friedmann A. Peri-implant alveolar bone loss with respect to bone quality after use of the osteotome technique: results of a retrospective study. *Clin Oral Implants Res* 2002;13:508-13.
15. Ericsson I, Johansson CB, Bystedt H, Norton MR. A histomorphometric evaluation of bone-to-implant contact on machine-prepared and roughened titanium dental implants. A pilot study in the dog. *Clin Oral Implants Res* 1994;5:202-6.
16. Hall JA, Payne AG, Purton DG, Torr B. A randomized controlled clinical trial of conventional and immediately loaded tapered implants with screw-retained crowns. *Int J Prosthodont* 2006;19:17-9.
17. Tawse-Smith A, Payne AG, Kumara R, Thomson WM. Early loading of unsplinted implants supporting mandibular overdentures using a one-stage operative procedure with two different implant systems: a 2-year report. *Clin Implant Dent Relat Res* 2002;4:33-42.
18. Nikellis I, Levi A, Nicolopoulos C. Immediate loading of 190 endosseous dental implants: a prospective observational study of 40 patient treatments with up to 2-year data. *Int J Oral Maxillofac Implants* 2004;19:116-23.
19. Piattelli A, Degidi M, Paolantonio M, Mangano C, Scarano A. Residual aluminum oxide on the surface of titanium implants has no effect on osseointegration. *Biomaterials* 2003;24:4081-9.
20. Gorrieri O, Fini M, Kyriakidou K, Zizzi A, Mattioli-Belmonte M, Castaldo P, et al. In vitro evaluation of bio-functional performances of Ghimas titanium implants. *Int J Artif Organs* 2006;29:1012-20.
21. Aronsson BO, Lausmaa J, Kasemo B. Glow discharge plasma treatment for surface cleaning and modification of metallic biomaterials. *J Biomed Mater Res* 1997;35:49-73.
22. Shibata Y, Hosaka M, Kawai H, Miyazaki T. Glow discharge plasma treatment of titanium plates enhances adhesion of osteoblast-like cells to the plates through the integrin-mediated mechanism. *Int J Oral Maxillofac Implants* 2002;17:771-7.
23. Swart KM, Keller JC, Wightman JP, Draughn RA, Stanford CM, Michaels CM. Short-term plasma-cleaning treatments enhance in vitro osteoblast attachment to titanium. *J Oral Implantol* 1992;18:130-7.
24. Laurell L, Lundgren D. Marginal bone level changes at dental implants after 5 years in function: a meta-analysis. *Clin Implant Dent Relat Res* 2011;13:19-28.
25. Gotfredsen K, Karlsson U. A prospective 5-year study of fixed partial prostheses supported by implants with machined and TiO<sub>2</sub>-blasted surface. *J Prosthodont* 2001;10:2-7.
26. van Steenberghe D, De Mars G, Quirynen M, Jacobs R, Naert I. A prospective split-mouth comparative study of two screw-shaped self-tapping pure titanium implant systems. *Clin Oral Implants Res* 2000;11:202-9.
27. Astrand P, Engquist B, Dahlgren S, Grondahl K, Engquist E, Feldmann H. Astra Tech and Branemark system implants: a 5-year prospective study of marginal bone reactions. *Clin Oral Implants Res* 2004;15:413-20.
28. Kim JS, Sohn JY, Park JC, Jung UW, Kim CS, Lee JH, et al. Cumulative survival rate of Astra Tech implants: a retrospective analysis. *J Periodontal Implant Sci* 2011;41:86-91.
29. Veltri M, Ferrari M, Balleri P. Stability values of titanium dioxide-blasted dental implants in edentulous maxillas: a 3-year pilot study. *J Oral Rehabil* 2010;37:63-8.
30. Astrand P, Engquist B, Dahlgren S, Engquist E, Feldmann H, Grondahl K. Astra Tech and Branemark System implants: a prospective 5-year comparative study. Results after one year. *Clin Implant Dent Relat Res* 1999;1:17-26.
31. Kemppainen P, Eskola S, Ylipaavalniemi P. A comparative prospective clinical study of two single-tooth implants: a preliminary report of 102 implants. *J Prosthet Dent* 1997;77:382-7.
32. Norton MR. A short-term clinical evaluation of immediately restored maxillary TiOblast single-tooth implants. *Int J Oral Maxillofac Implants* 2004;19:274-81.
33. Del Fabbro M, Testori T, Francetti L, Taschieri S, Weinstein R. Systematic review of survival rates for immediately loaded dental implants. *Int J Periodontics Restorative Dent* 2006;26:249-63.
34. Garcia-Bellosta S, Bravo M, Subira C, Echeverria JJ. Retrospective study of the long-term survival of 980 implants placed in a periodontal practice. *Int J Oral Maxillofac Implants* 2010;25:613-9.
35. Pikner SS, Grondahl K, Jemt T, Friberg B. Marginal bone loss at implants: a retrospective, long-term follow-up of turned Branemark System implants. *Clin Implant Dent Relat Res* 2009;11:11-23.
36. Lee DW, Choi YS, Park KH, Kim CS, Moon IS. Effect of microthread on the maintenance of marginal bone level: a 3-year prospective study. *Clin Oral Implants Res* 2007;18:465-70.
37. Aloy-Prosper A, Maestre-Ferrin L, Penarrocha-Oltra D, Penarrocha-Diago M. Marginal bone loss in relation to the implant neck surface: an update. *Med Oral Patol Oral Cir Bucal* 2011;16:e365-8.

Source of Support: Nil  
Conflict of Interest: Nil