

# Accepted Manuscript

Anatomical Characteristics Of Intrapetrous Carotid Artery: A 3d Segmentation Study On Head Ct-Scan

Daniele Gibelli, MD, PhD, Michaela Cellina, MD, Stefano Gibelli, MD, Elena Belloni, MD, Antonio Giancarlo Oliva, MD, Giovanni Termine, MD, Claudia Dolci, MD, Chiarella Sforza, MD

PII: S1878-8750(18)32171-5

DOI: [10.1016/j.wneu.2018.09.125](https://doi.org/10.1016/j.wneu.2018.09.125)

Reference: WNEU 10330

To appear in: *World Neurosurgery*


Received Date: 19 June 2018

Revised Date: 15 September 2018

Accepted Date: 17 September 2018

Please cite this article as: Gibelli D, Cellina M, Gibelli S, Belloni E, Oliva AG, Termine G, Dolci C, Sforza C, Anatomical Characteristics Of Intrapetrous Carotid Artery: A 3d Segmentation Study On Head Ct-Scan, *World Neurosurgery* (2018), doi: <https://doi.org/10.1016/j.wneu.2018.09.125>.

This is a PDF file of an unedited manuscript that has been accepted for publication. As a service to our customers we are providing this early version of the manuscript. The manuscript will undergo copyediting, typesetting, and review of the resulting proof before it is published in its final form. Please note that during the production process errors may be discovered which could affect the content, and all legal disclaimers that apply to the journal pertain.



## **ANATOMICAL CHARACTERISTICS OF INTRAPETROUS CAROTID ARTERY: A 3D SEGMENTATION STUDY ON HEAD CT-SCAN**

Daniele Gibelli<sup>1</sup>, MD, PhD, Michaela Cellina<sup>2</sup>, MD, Stefano Gibelli<sup>3</sup>, MD, Elena Belloni<sup>4</sup>, MD, Antonio Giancarlo Oliva<sup>2</sup>, MD, Giovanni Termine<sup>3</sup>, MD, Claudia Dolci<sup>1</sup>, MD, Chiarella Sforza<sup>1</sup>, MD

- 1) Dipartimento di Scienze Biomediche per la Salute  
Università degli Studi di Milano, Italy
- 2) Reparto di Radiologia  
Ospedale Fatebenefratelli  
ASST Fatebenefratelli Sacco, Milano, Italy
- 3) Reparto di Otorinolaringoiatria  
Ospedale Fatebenefratelli  
ASST Fatebenefratelli Sacco, Milano, Italy
- 4) Department of Radiology  
Civil Hospital, Vigevano, Italy

Corresponding author: Dr Daniele Gibelli, MD, PhD  
Dipartimento di Scienze Biomediche per la Salute  
Università degli Studi di Milano  
Via Mangiagalli 31, 20133, Milano, Italy  
tel. +39-02-50315399  
ORCID ID: 0000-0002-9591-1047

**Running title:** 3D analysis of intrapetrous carotid artery

### **Funding and conflict of interest**

None.

**Abstract**

The intrapetrous portion of internal carotid artery (IPCA) is one of the most unexplored anatomical regions, and its three-dimensional reconstruction in living subjects is still missing. The present study aims at describing IPCA on 3D models extracted from head CT-scans.

The intrapetrous carotid artery was manually segmented on head CT-scans of 100 healthy patients free from vascular and neurological pathologies (50 males and 50 females aged between 18 and 91 years). Angles of the posterior and anterior genu, diameter and length of the horizontal portion, and volume of the entire canal were calculated through VAM® software. Statistically significant differences according to sex and side were assessed through two-way ANOVA test ( $p < 0.05$ ). Correlation of each measurement with age was calculated as well.

On average the angles of the posterior and anterior genu were  $120.1 \pm 10.4^\circ$  and  $118.0 \pm 10.0^\circ$  in males,  $119.5 \pm 9.2^\circ$  and  $117.6 \pm 10.3^\circ$  in females, respectively, without statistically significant differences according to sex or side ( $p > 0.05$ ). Average length and diameter of the horizontal part were respectively  $25.5 \pm 2.9$  mm and  $5.8 \pm 0.8$  mm in males,  $24.0 \pm 2.3$  mm and  $5.3 \pm 0.8$  mm in females. The volume of IPCA was  $0.941 \pm 0.215$  cm<sup>3</sup> in males, and  $0.752 \pm 0.159$  cm<sup>3</sup> in females. Length and diameter of horizontal portion, and volume of IPCA showed statistically significant differences according to sex ( $p < 0.05$ ). No correlation with age was found.

This study first provided data concerning not only linear and angular measurements, but also volumes of IPCA, useful in planning surgical interventions of the cranial base.

**Keywords:** anatomical variants, intrapetrous carotid artery (IPCA), radiology, CT-scan, 3D segmentation

## Introduction

The internal carotid artery (ICA) is the main vascular structures supplying blood for the intracranial circulation, and is usually divided into an extracranial and an intracranial portion, being the latter one further classified into a petrous, cavernous and cerebral portion<sup>1,2</sup>. The petrous portion of ICA is usually divided into five parts, defined from caudal to cranial posterior vertical, posterior genu, horizontal, anterior genu and anterior vertical<sup>1</sup>. The petrous portion of ICA represents the most obscure and the least detailed, as it is not easily accessible to anatomical dissection<sup>3,4</sup>, although it is of crucial importance in clinics and surgery. In fact, the intrapetrous carotid artery (IPCA) may be invaded by tumors originating in the jugular foramen area such as schwannoma and chemodectoma, as well as chordoma, meningioma, neuroma, cholesteatoma and cholesterol granuloma<sup>5,6</sup>. Isolated ICA dissections in the intrapetrous portion are reported by literature, although rarely<sup>7</sup>, sometimes as complications of mycotic infections of the middle ear<sup>8</sup>. In all these cases the analysis of anatomical characteristics of IPCA is crucial for surgical procedures<sup>5</sup>. In addition, knowledge of IPCA position and relationships with surrounding anatomical structures is important for treating pathologies of the skull base, and minimizing the risk of vascular complications<sup>9</sup>.

Finally, surgical exposure of the horizontal segment of IPCA is important for bypass procedures including cervical-to-petrous and the petrous-to-supraclinoid ICA bypass<sup>10</sup>, preliminary to the removal of tumors invading the petrous portion of ICA.

Therefore, the exact metrical and morphological knowledge of IPCA may prevent its involuntary damage and is basilar for a good surgical exposure of structures of interest<sup>5</sup>. Very few studies have analysed size and shape of intrapetrous carotid artery so far: angles or knees of ICA are widely described by literature<sup>1,2</sup>, but very few articles have provided a quantification of different artery portions in the intracranial path<sup>11</sup>, mainly through anatomic dissections<sup>4,10</sup>. Other authors assessed the same parameters on CT-scans, usually providing general metrical indications potentially useful in surgery<sup>12,13</sup>.

In addition, even fewer authors have analysed the possible relation of IPCA size with sex and age: an example is represented by the study by Takegoshi and Kikuchi who measured metrical characteristics of the horizontal part of the IPCA on CT-scans and verified statistically significant differences between males and females. In addition, according to their results, length seems to significantly decrease in males according to age<sup>6</sup>.

In the last years, the diffusion of 3D segmentation on CT-scan has allowed the researchers to obtain three-dimensional models of anatomical structures, with the chance of improving metrical assessment through the addition of novel measurements, such as volumes<sup>14</sup>. However, to the best of our knowledge, IPCA has not been adequately assessed through these innovative approaches. In fact, only one study has segmented 3D models of IPCA from CT-scans, focusing on the anatomic relationships and distance from surrounding structures. The same study analysed the length of the horizontal segment as well<sup>10</sup>. However, the previously cited study was limited to 29 patients, did not assess possibly statistically significant differences according to side or sex and did not consider angles and volume of IPCA, which has not yet been analysed by existing literature.

This study aims at performing a three-dimensional study of the intrapetrous canal of the ICA on CT-scans through the segmentation of their 3D models. The results may improve the scanty information available in literature about this unexplored and sensitive region of the internal carotid artery.

## **Materials and methods**

The study took into consideration 100 Caucasoid patients (50 males and 50 females), aged between 18 and 91 years (mean age:  $46.3 \pm 17.9$  years and  $51.5 \pm 21.4$  years for males and females, respectively) who had previously undergone a head CT-scan in a hospital of Northern Italy for reasons not related with the study. Clinical requests were most frequently related to screening for possible cranial fractures in trauma (57.3%), suspected sinusitis or nasal and paranasal symptoms (20.0%) or neurological symptoms (12.7%), without sex distinction. All CT-scans were performed through Somatom Definition Flash (Siemens, Forchheim, Germany); parameters of acquisition: kV:120, mAs: 320, collimation: 40 x 0.6 mm, tube rotation: 1 sec; reconstruction thickness: 3 mm; reconstruction filters: H21s smooth for soft tissues and H60 sharp for bone tissue.

All CT-scans were anonymized to meet the local and international ethical rules (Helsinki Declaration).

The intrapetrous canal harbouring the ICA was manually segmented through ITK-SNAP free software<sup>14</sup> (Fig. 1). The entire petrous path of the internal carotid artery was

segmented, including the posterior vertical portion from the carotic foramen, the posterior genu, the horizontal part, the anterior genu and the anterior vertical portion (Fig. 2).

The 3D model of the intrapetrous carotid artery was exported in .stl file and further elaborated through VAM® software (Vectra Analysis Module, version 2.8.3, Canfield Scientific®, Inc.). Angles of the posterior and anterior genu were measured as the angles between the axes of the posterior vertical and the horizontal portion, and the horizontal and the anterior vertical portion respectively. The diameter of the horizontal portion was measured at the midpoint, whereas the maximum length was taken at the middle third of its height (Fig. 3). The same software automatically calculated the volume of the intrapetrous canal. Prevalence of bone wall dehiscence in the horizontal part was calculated on the entire sample.

The entire procedure from segmentation to volume calculation was repeated in five cases by the same and another operator, for a total of ten 3D models of IPCA: possible intra- and inter-observer errors were assessed through calculation of absolute and relative technical errors of measurement (TEM and rTEM) for all the measurements<sup>14</sup>.

Normal distribution and homoscedasticity of all the measurements were tested through Jarque-Bera test and Bartlett's test, respectively ( $p < 0.05$ ). Both the tests were performed through Matlab® software.

Statistically significant differences for five measurements (angle of the posterior and anterior genu, length and diameter of the horizontal portion, volume) according to sex and side were assessed through two-way ANOVA test (factors: sex, side, two levels for each; the sex x side interaction was calculated as well). A p value of 0.05 or less was considered as significant. In addition, correlation of each measurement with age was calculated as well.

## Results

Intra- and inter-observer rTEMs for linear and angular measurements ranged between 1.0% and 1.7%, and between 1.4% and 3.2%, respectively, 7.0% and 6.6% for volume (Table 1).

All the measurements were normally distributed and homoscedastic ( $p > 0.05$ ).

Overall results are shown in Table 2. Posterior genu angle ranged between 95.0° and 142.5° in males, between 93.8° and 139.6° in females; on the other side, the anterior genu was between 90.4° and 138.2° in males, and between 89.3° and 142.2° in females. Both the angles did not show any statistically significant difference according to side or sex ( $p>0.05$ ). The sex x side interaction was negligible as well.

Horizontal portion length ranged between 19.3 mm and 33.5 mm in males, and between 17.2 mm and 29.3 mm in females, being on average 1.1 times longer in males than in females. The diameter was between 3.2 mm and 8.1 mm in males, and between 3.3 mm and 7.4 mm in females, with a male/female ratio of 1.1. The volume of IPCA ranged between 0.450 cm<sup>3</sup> and 1.594 cm<sup>3</sup> in males, and between 0.337 cm<sup>3</sup> and 1.067 cm<sup>3</sup> in females, with a male/female ratio of 1.25. The bone wall of the horizontal part was dehiscent in 29% of the population, and in detail in 15 males (bilaterally) and 14 females (12 bilaterally, two on the right side).

Length and diameter of horizontal portion, and volume of IPCA showed statistically significant differences according to sex ( $p<0.05$ ), but not to side, with negligible interaction ( $p>0.05$ ).

Correlation with age was low for all the measurements, ranging between -0.34 and 0.22 (Table 3).

## Discussion

### *Comparison with literature*

The intrapetrous portion of the internal carotid artery has gained a growing interest in surgery, not only because it may be involved in different pathologies<sup>5-8</sup>, but also because it may be accidentally damaged during surgical procedures of the skull base<sup>9</sup>; in addition, it is often the target of pioneering bypass procedures used to handle vascular lesions and preliminary to the removal neoplasms infiltrating the petrous portion of the temporal bone<sup>10</sup>. Several authors have widely described the strict relationships with surrounding structures including the cochlea, the internal auditory canal and the bony labyrinth<sup>10,15,16</sup>, whereas very few studies have considered the metrical assessment of IPCA so far<sup>6</sup>. Most of literature have focused on the localization of IPCA according to reference points such as the foramen ovale, rotundum and spinosum<sup>10,17,18</sup>.

Less information is available on the size of intrapetrous canal and is mainly limited to length and diameter of the horizontal portion, assessed on cadavers and CT-scans. The length of the horizontal part of IPCA is reported between 14.5 mm and 25.1 mm in cadavers<sup>10,16,19</sup>, and between 20.7 mm and 30.4 mm on CT-scans<sup>6,20</sup>. These discordances may be justified by the different measurement protocols in the two cases, and in different assessment of anatomical limits of the horizontal part of IPCA<sup>21</sup>. On the other side, literature on cadavers and CT-scans agrees on diameters, that range between 4.0 and 8.0 mm<sup>6,10,19</sup>.

Very few indications are given by literature concerning sex and age differences of IPCA size: Takegoshi and Kikuchi first verified that the horizontal portion of IPCA is significantly longer in males than in females, and decreases with age but only in men<sup>6</sup>.

Even less data are available for what concerns the angles of posterior and anterior genu: a recent study first found that both the angles were positively correlated to each other, and negatively correlated with the length of the horizontal portion of IPCA. On average, the posterior and anterior genu ranged between 31° and 110°, and between 68° and 124°, respectively<sup>22</sup>.

In the last decades, the introduction of 3D segmentation methods has allowed the researchers to obtain three-dimensional models of different anatomical structures from CT-scan or NMR images<sup>23,24</sup>, thus simplifying conventional procedures so far limited to the application of silicone gel to dry skulls and its extraction after removal of the canal floor<sup>25</sup>. In addition, 3D models of IPCA enable a wider range of metrical measurement than previously assessed on cadavers and CT-scans, including not only linear distances and angles, but also volumes.

The present data partially confirm the existing literature. In fact, length and diameter of the horizontal portion are similar to those reported on cadavers and CT-scans<sup>6,10,16,19,20</sup>; on the other hand, angles of the posterior and anterior genu are higher than the intervals reported by Vijaywargiya et al.<sup>22</sup>. However, the previous study was performed on embalmed cadavers, and the encountered discordances may be due to the elastic deformation of ICA during the measurement procedures.

Another discordance encountered between the present data and previous reports by literature concerns the possible correlation of some measurements with age: in fact, Takegoshi et al. found that the horizontal part of the internal carotid artery was on average 0.8 mm wider in subjects over 60 years than in subjects aged 19 years or less,



but only in males<sup>6</sup>. This result was not confirmed by the present study: however, the statistically significant difference between the two age groups may be justified by the inclusion of children and adolescents (in fact, the age range of the sample by Takegoshi et al. was between 5 and 86 years). In addition, subjects over 60 years showed a shorter length of the horizontal portion than in the 20-39-year and 40-59-year groups, again only in male population<sup>6</sup>. This result was explained by the observation that arteries usually increase their diameter with age<sup>26,27</sup>. However, a correlation between diameter and age was not found in the present population: this discordance may be due to ethnic and geographical differences between the present Northern-Italian (including Caucasoid subjects) and the Japanese group, which is worth being analysed in depth. On the contrary, the present study suggests that IPCA size seems to be independent from age, possibly because of the restraint function of the bone walls of the intrapetrous canal. However, more studies are needed to verify the real interaction between age and IPCA measurements, as well as possible influencing factors. Bone dehiscence of the horizontal part was found in 29% of subjects: this result is of particular importance, as very few indications are available in literature concerning the prevalence of this anatomical variant. An example is given by Spiessberger et al. who studied IPCA in cadavers and found bone dehiscence in two bodies out of four<sup>28</sup>.

#### *Practical applications and clinical cases*

At our knowledge, the present study first assessed volume of IPCA in a CT-scans population through 3D segmentation techniques. Results showed that volume is sexually dimorphic, being about 25% higher in males than in females. In addition, the volumetric intervals of IPCA are first described, which may be useful in surgical context; in detail, our results suggest once more that the surgical planning of the petrous portion of temporal bone or the cranial base should vary according to sex, as all the measurements show differences between males and females, but for the angles of posterior and anterior genu. Moreover, the present study highlights that there is no difference according to side, for any measurement: this conclusion confirms data from existing literature reporting a high symmetry of ICA and generally of circle of Willis<sup>29,30</sup>. Asymmetry of internal carotid artery are usually caused by high-grade cervical stenosis<sup>31</sup>, or anatomical alterations of the anterior portion of the circle of Willis, including the unilateral absence or hypoplasia of anterior cerebral artery at A1 segment, which is usually linked to an ipsilateral decrease in

ICA size<sup>32</sup>. In addition, volume of IPCA is symmetrical as well, without distinction between the right and the left side.

The aim of the present anatomical study is to investigate morphological and metrical characteristics of the IPCA focusing on general characteristics of sexual dimorphism and symmetry. Although this structure can be easily analysed within the patient for planning of surgical interventions, the present results provide standard metrical indications concerning the normal size of IPCA, which may be useful for assessing possible asymmetry or anomalous morphology due to pathological conditions. An example is shown in Fig. 4 and concerns a patient affected by Kawasaki syndrome with an asymmetry of IPCA whose diameter is more than one third higher on the left side than the right side.

In addition, anatomical data concerning morphology of IPCA are of special importance in planning surgical interventions of cerebral high-flow bypass, using saphenous vein or radial artery grafts. This type of procedure is usually preliminary to the treatment of aneurysms, and is performed also before the removal skull base tumors infiltrating ICA, to facilitate the maximum safe resection of neoplasms preserving distal blood flow<sup>28</sup>. An example is shown in Fig. 5, reporting a case of infiltration of the left IPCA by metastases of a liver primitive neoplasm. In this case, data concerning general shape of IPCA and volume are therefore useful for planning of surgical procedures, which will be further improved by specific parameters found in the patient.

Another relevant information regards the distribution of bone wall dehiscence in the horizontal portion: because of this anatomical variant IPCA is exposed into the middle cranial fossa, and is covered only by dura mater and connective tissue<sup>33</sup>. The dehiscence of the bony canal in the horizontal part of IPCA can facilitate bypass procedures, lowering the surgical morbidity<sup>28</sup>; however, the prevalence of this variant is still unknown, and has been explored so far only on small samples of cadavers<sup>28</sup>. The present study report that this favourable variant for surgical procedures is common in general population, and provides an additional help for the anatomical description of IPCA.

### *Conclusions*

In conclusion, the present study first describes the results of metrical assessment of 3D segmented models of IPCA: results may contribute to light up this sensitive and still incompletely known anatomical structure.

**Conflict of interest**

None.

**References**

- 1) Standering S. Gray's Anatomy: the anatomical basis of clinical practice. 39<sup>th</sup> ed. London: Churchill Livingstone; 2005
- 2) Moore KL, Dally AF. Clinically oriented anatomy. 5<sup>th</sup> ed. Baltimore, MD: Lippincott Williams & Wilkins, 2006
- 3) Liu JK, Fukushima T, Sameshima T, Al-Mefty O, Couldwell WT. Increasing exposure of the petrous internal carotid artery for re-vascularization using the transzygomatic extended middle fossa approach: a cadaveric morphometric study. *Neurosurgery* 2006;59(4 Suppl. 2):ONS309-18
- 4) Osawa S, Rhoton AL Jr, Tanriover N, Shimizu S, Fujii K. Microsurgical anatomy and surgical exposure of the petrous segment of the internal carotid artery. *Neurosurgery* 2008;63(4 Suppl. 2):210-38
- 5) Scerrati A, Ercan S, Wu P, Zhang J, Ammirati M. Intrapetrous internal carotid artery: evaluation of exposure, mobilization and surgical manoeuvres feasibility from a retrosigmoid approach in a cadaveric model. *World Neurosurg* 2016;91:443-50
- 6) Takegoshi H, Kikuchi S. An anatomic study of the horizontal petrous internal carotid artery: sex and age differences. *Auris Nasus Larynx* 2007;34(3):297-301
- 7) Huang YC, Chen CM, Lai SL, Lee TH, Chen ST, Chin SC, Chen YC. Spontaneous intrapetrous internal carotid artery dissection: a case report and literature review. *J Neurol Sci* 2007;253:90-3
- 8) Crossland GJ, De R, Higgins JN, Axon PR. Two stage management of petrositis with associated mycotic aneurysm of the intrapetrous carotid artery. *J Laryngol Otol* 2005;119(6):479-82

- 9) Colasanti R, Tailor AR, Lamki T, Zhang J, Ammirati M. Maximising the petroclival region exposure via a suboccipital retrosigmoid approach: where is the intrapetrous internal carotid artery. *Neurosurgery* 2015(11 Suppl. 2):329-36
- 10) Zhen G, Fang-Lu C, Pei-dong D. The anatomic relationship around the horizontal segment of petrous internal carotid artery: a study based on reconstructed computed tomography angiography. *Surg Radiol Anat* 2012;34(8):695-700
- 11) Vijaywargiva M, Deopujari R, Athavale SA. Anatomical study of petrous and cavernous parts of internal carotid artery. *Anat Cell Biol* 2017;50:163-70
- 12) Villavicencio AT, Levegue JC, Bulsara KR, Friedman AH, Gray L. Three-dimensional computed tomographic cranial base measurements for improvement of surgical approaches to the petrous carotid artery and apex regions. *Neurosurg* 2001;49(2):342-52
- 13) Yushkevich PA, Piven J, Hazlett HC, Smith RG, Ho S, Gee JC, Gerig G. User-guided 3D active contour segmentation of anatomical structures: significantly improved efficiency and reliability. *Neuroimage* 2006;31:1116-28
- 14) Adao Perini T, Lameira de Oliveira G, dos Santos Ornellas J, Palha de Oliveira F. Technical error of measurement in anthropometry. *Rev Bras Med Esporte* 2005;11(1):86-90
- 15) Dew LA, Shelton C, Harnsberger HR, Thompson Jr BG. Surgical exposure of the petrous internal carotid artery: practical application for skull base surgery. *Laryngoscope* 1997;107:967-76
- 16) Paullus WS, Pait TG, Rhoton Jr AL. Microsurgical exposure of the petrous portion of the carotid artery. *J Neurosurg* 1977;47:713-26
- 17) Mason E, Gurrola J II, Reyes C, Brown JJ, Figueroa R, Solares A. Analysis of the petrous portion of the internal carotid artery: landmarks for an endoscopic endonasal approach. *Laryngoscope* 2014;124:1988-994
- 18) Jiang Y, Chen Y, Yao J, Tian Y, Su L, Li Y. Anatomic assessment of petrous internal carotid artery, facial nerve, and cochlea through the anterior transpetrosal approach. *J Craniofac Surg* 2015;26(7):2180-3
- 19) Leonetti JP, Smith PG, Linthicum FH. The petrous carotid artery: anatomic relationships in skull base surgery. *Otolaryngol Head Neck Surg* 1990;102:3-12
- 20) Villavicencio AT, Leveque JC, Bulsara KR, Friedman AH, Gray L. Three-dimensional computed tomographic cranial base measurements for improvement of surgical

- approaches to the petrous carotid artery and apex regions. *Neurosurgery* 2001;49:342-52
- 21) Bouthillier A, van Loveren HR, Keller JT. Segments of the internal carotid artery: a new classification. *Neurosurgery* 1996;38:425-32
- 22) Vijaywargiya M, Deopujari R, Athavale SA. Anatomical study of petrous and cavernous parts of internal carotid artery. *Anat Cell Biol* 2017;50(3):163-70
- 23) Hassan K, Dort JC, Sutherland GR, Chan S. Evaluation of software tools for segmentation of temporal bone anatomy. *Stud Health Technol Inform* 2016;220:130-3
- 24) Gibelli D, Cellina M, Gibelli S, Oliva AG, Codari M, Termine G, Sforza C. Volumetric assessment of sphenoid sinuses through segmentation on CT scan. *Surg Radiol Anat* 2018;40(2):193-8
- 25) Vidya CS, Shamasundar NM. Study of the morphometry of carotid canal in skulls of South Indian origin. *J Clin Diagn Res* 2015;9(2):AC16-AC18
- 26) Samijo SK, Willigers JM, Barkhuysen R, Kitslaar PJ, Reneman RS, Brands PJ, Hoeks AP. Wall shear stress in the human common carotid artery as function of age and gender. *Cardiovasc Res* 1998;39:515– 22
- 27) Hansen F, Mangell P, Sonesson B, Lanne T. Diameter and compliance in the human common carotid artery: variations with age and sex. *Ultrasound Med Biol* 1995;21:1–9
- 28) Spiessberger A, Baumann F, Kothbauer KF, Aref M, Marbacher S, Fandino J, Nevzati E. Bony dehiscence of the horizontal petrous internal carotid artery canal: an anatomic study with surgical implications. *World Neurosurg* 2018;114:e1174-9
- 29) Mujagic S, Kozic D, Huseinagic H, Smajlovic D. Symmetry, asymmetry and hypoplasia of the intracranial internal carotid artery on magnetic resonance angiography. *Acta Med Acad* 2016;45(1):1-9
- 30) Stojanovic N, Stefanovic I, Kostic A, Radisavejevic M, Stojanov D, Petrovic S. Analysis of the symmetric configuration of the circle of Willis in a series of autopsied corpses. *Vojnosanit Pregl* 2015;72(4):356-60
- 31) Naggara O, Touzè E, Seiller N, Gobin-Metteil MP, Mas JL, Meder JF, Oppenheim C. Asymmetry of intracranial internal carotid artery on 3D TOF MR angiography: a sign of unilateral extracranial stenosis. *Eur Radiol* 2008;18(5):1038-42

- 32) Kane AG, Dillon WP, Barkovich AJ, Norman D, Dowd CF, Kane TT. Reduced caliper of the internal carotid artery: anormal finding with ipsilateral absence or hypoplasia of the A1 segment. *AJNR Am J Neuroradiol* 1996;17(7):1295-301
- 33) Hearst MJ, Kadar A, Keller JT, Choo DI, Pensak ML, Samy RN. Petrous carotid canal dehiscence: an anatomic and radiographic study. *Otol Neurotol* 2008;29:1001-4

### Legends to figures

**Fig. 1:** example of 3D segmentation of IPCA canals through ITK-SNAP software: visualization in the three axes and reconstruction of the segmented model

**Fig. 2:** 3D model of right IPCA; a) posterior vertical portion; b) posterior genu; c) horizontal portion; d) anterior genu; e) anterior vertical portion

**Fig. 3:** linear and angular measurements assessed on 3D models of IPCA:  $\alpha$ ) posterior genu angle;  $\beta$ ) anterior genu angle; a) diameter of the horizontal portion at the midpoint; b) length of the horizontal portion

**Fig. 4:** 30 years old female patient affected by Kawasaki syndrome, showing the asymmetry of the horizontal part of IPCA

**Fig. 5:** 80 years old male patient affected by primitive liver cancer and a large metastatic area infiltrating the left IPCA (indicated by the black arrow)

	Intra-observer error		Inter-observer error	
	TEM	rTEM	TEM	rTEM
<b>Posterior genu angle</b>	2.1°	1.7%	3.4°	2.8%
<b>Horizontal portion length</b>	0.3 mm	1.2%	0.5 mm	2.1%
<b>Horizontal portion diameter</b>	0.1 mm	1.0%	0.1 mm	1.4%
<b>Anterior genu angle</b>	1.9°	1.6%	3.8°	3.2%
<b>Volume</b>	0.049 cm <sup>3</sup>	7.0%	0.034 cm <sup>3</sup>	6.6%

Table 1: technical error measurement (TEM) and relative technical error of measurement (rTEM) of intra- and inter-observer error for all the measurements

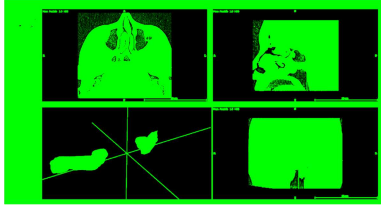
		Males		Females		Total		Two-way ANOVA test					
		Right	Left	Right	Left	Males	Females	Sex		Side		Interaction	
								F	P	F	P	F	P
<b>Posterior genu angle (°)</b>	<b>Mean</b>	119.5	120.8	120.4	118.6	120.1	119.5	0.17	0.6806	0.04	0.8417	1.26	0.263
	<b>SD</b>	9.1	11.6	9.3	9.1	10.4	9.2						
<b>HP length (mm)*</b>	<b>Mean</b>	25.3	25.7	24.0	24.0	25.5	24.0	15.42	<0.01	0.17	0.6806	0.2	0.6552
	<b>SD</b>	2.7	3.2	2.2	2.5	2.9	2.3						
<b>HP diameter (mm)*</b>	<b>Mean</b>	5.8	5.9	5.3	5.3	5.8	5.3	21.52	<0.01	0.49	0.4848	0.1	0.7522
	<b>SD</b>	0.7	0.9	0.8	0.9	0.8	0.8						
<b>Anterior genu angle (°)</b>	<b>Mean</b>	116.7	119.3	118.0	117.3	118.0	117.6	0.06	0.8068	0.39	0.533	1.28	0.2593
	<b>SD</b>	10.8	9.0	9.0	11.5	10.0	10.3						
<b>Volume (cm<sup>3</sup>)*</b>	<b>Mean</b>	0.935	0.946	0.750	0.754	0.941	0.752	49.07	<0.01	0	1	0	1
	<b>SD</b>	0.192	0.237	0.154	0.166	0.215	0.159						

Table 2: descriptive statistics and results of two-way ANOVA test for all the measurements: HP: horizontal portion; \*: statistically significant differences according to sex (p<0.05)




	Males		Females	
	Right	Left	Right	Left
<b>Posterior genu angle (°)</b>	0.10	0.00	-0.07	0.14
<b>HP length (mm)</b>	-0.01	0.10	-0.24	-0.34
<b>HP diameter (mm)</b>	0.01	-0.06	0.05	0.22
<b>Anterior genu angle (°)</b>	-0.01	-0.10	-0.19	-0.14
<b>Volume (cm<sup>3</sup>)</b>	0.12	0.17	-0.02	0.16


Table 3: correlation index for all the measurements divided according to side and sex



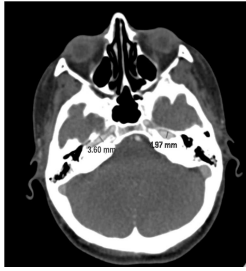
ACCEPTED MANUSCRIPT




ACCEPTED MANUSCRIPT



ACCEPTED MANUSCRIPT



ACCEPTED MANUSCRIPT



ACCEPTED MANUSCRIPT

- The present study aims at describing IPCA on 3D models extracted from 100 CT-scans
- The volume of IPCA was  $0.941 \pm 0.215 \text{ cm}^3$  in males, and  $0.752 \pm 0.159 \text{ cm}^3$  in females
- Length and diameter of horizontal portion, and volume were sexually dimorphic
- This study first provided data concerning distances, angles and volumes of IPCA

ICA: internal carotid artery

IPCA: intrapetrous carotid artery

TEM: technical error of measurement

rTEM: relative technical error of measurement

ACCEPTED MANUSCRIPT