

Nephrol Dial Transplant (2008) 23: 3010–3016

doi: 10.1093/ndt/gfn209

Advance Access publication 19 April 2008



## Original Article

# Renal transplantation in adults with Henoch-Schönlein purpura: long-term outcome

Gabriella Moroni<sup>1</sup>, Beniamina Gallelli<sup>1</sup>, Alessandro Diana<sup>1</sup>, Alessia Carminati<sup>1</sup>, Giovanni Banfi<sup>1</sup>, Francesca Poli<sup>2</sup>, Giuseppe Montagnino<sup>1</sup>, Antonio Tarantino<sup>3</sup> and Piergiorgio Messa<sup>1</sup>

<sup>1</sup>Divisione di Nefrologia and Dialisi, <sup>2</sup>Centro Trasfusionale e di Immunologia dei Trapianti, Fondazione Ospedale Maggiore Policlinico, Mangiagalli, Regina Elena and <sup>3</sup>Private nephrologist, U.O. Nefrologia, Ospedale Maggiore Policlinico, Mangiagalli e Regina Elena, Fondazione IRCCS, Milano, Italy

### Abstract

**Background.** Little information is available about the long-term outcome of renal transplantation in adults with Henoch-Schönlein purpura (HSP).

**Methods.** We compared the outcomes of 17 patients with HSP who received 19 renal transplants with those of 38 controls matched for time of transplantation, age, gender and source of donor. The mean post-transplant follow-up was 109 ± 99 months for HSP patients and 110 ± 78 months for controls.

**Results.** The actuarial 15-year patient survival was 80% in HSP patients and 82% in controls, and the death-censored graft survival was 64% in HSP patients and in controls. The risks of acute rejection, chronic graft dysfunction, arterial hypertension and infection were not different between the two groups. In eight grafts (42%) recurrence of HSP nephritis was found (0.05/patient/year). In spite of therapy, one patient died and four eventually restarted dialysis respectively 10, 32, 35 and 143 months after renal transplant. Seventy-one percent of grafts transplanted in patients with necrotizing/crescentic glomerulonephritis of the native kidney had HSP recurrence in comparison to 12% of recurrences in patients with mesangial nephritis ( $P = 0.05$ )

**Conclusions.** Long-term patient and allograft survival of HSP patients was good. However, 42% of HSP patients, particularly those with necrotizing/crescentic glomerulonephritis of the native kidneys, developed a recurrence of HSP nephritis that eventually caused the loss of the graft function in half of them.

**Keywords:** Henoch-Schönlein purpura nephritis; IgA glomerulonephritis; renal transplant

### Introduction

Henoch-Schönlein purpura (HSP) is a small-vessel vasculitis that affects the kidney in about 20–28% of children and 49–83% of adults [1]. In a large Italian multicentre study, renal survival rates at 10 years were 90% in children and 76% in adults [1]. However, the data concerning the outcome of adults with HSP submitted to renal transplant are very scanty [2,3], probably due to the low frequency of the disease. Only a few case reports [4–6] have underlined the systemic and/or the graft recurrence of the original disease with consequent loss of graft function. Three papers have reported the outcome of a cohort of HSP renal transplant patients [7–9]. Almost all the patients were children. About half of the patients lost graft function in the long term, mostly due to chronic rejection. The risk of recurrence varied between 21% and 88%. The impact of recurrence was varied, with some patients developing graft failure while others maintaining stable graft function.

The short- and long-term outcome, the frequency and the renal factors for clinical recurrences of HSP nephritis after renal transplantation in adults remain largely unknown.

The aims of this single-centre retrospective analysis were (1) to compare the long-term patient and renal allograft survival of HSP patients with those of well-matched controls, (2) to compare the long-term complications in these two groups and (3) to assess the rate and the consequences of recurrence in renal transplant recipients with HSP.

### Subjects and methods

#### Patients

We considered for this study HSP patients who had received a kidney transplantation at Ospedale Maggiore of Milan between March 1979 and January 2006. The diagnosis of HSP was based on clinical criteria (purpuric papules involving the extensor surfaces of the lower extremities and buttocks symmetrically, arthralgia and periarticular oedema of the knees, ankles, elbows and wrists, abdominal pain

Correspondence and offprint requests to: Gabriella Moroni, Divisione di Nefrologia e Dialisi-Padiglione Croff, Ospedale Maggiore IRCCS, Via della Commenda 15-20122 Milano, Italy. Tel: +39-2-55-03-45-52; Fax: +39-2-55-03-45-50; E-mail: gmoroni@policlinico.mi.it

with vomiting and diarrhoea, microscopic or macroscopic haematuria, proteinuria and deterioration of renal function) as well as renal biopsy (segmental or diffuse granular deposition of IgA in the mesangium and/or along the glomerular capillary walls; IgA should be prevalent on the other Ig classes).

Renal allograft recipients transplanted before and after patients with HSP, matched for age ( $\pm 5$  years), gender and source of the donor (deceased or living) were considered as controls. None of the 38 controls showed any clinical sign or symptom of HSP. One patient had polycystic kidney disease, 10 had congenital urinary tract abnormalities, 8 a clinical diagnosis of chronic glomerulonephritis, 10 biopsy-proven glomerulonephritis (focal/segmental glomerulosclerosis 4 patients, membranous glomerulonephritis 2 patients, IgM nephropathy 1 patient, membranoproliferative glomerulonephritis 1 patient), 1 renal AA amyloidosis, 1 Alport's syndrome, 1 Fabry's disease, 3 chronic pyelonephritis and 3 nephroangiosclerosis.

All HSP patients and controls were Caucasian.

### Definitions

Acute rejection was diagnosed on the basis of a double-checked increase of 20% or more in plasma creatinine over the baseline not explained by other causes. In patients who underwent graft biopsy the severity of rejection and the classification of chronic histological lesions were scored retrospectively according to the recently revised Banff classification [10]. Unspecific sclerosing lesions were defined by the presence of interstitial fibrosis with tubular atrophy and glomerular and arteriolar sclerosis, without evidence of any specific etiology. Chronic rejection was defined by the presence of chronic allograft arteriopathy and/or chronic transplant glomerulopathy.

All renal biopsies were evaluated by light microscopy and immunofluorescence. *Histologic recurrence* of HSP nephritis in the graft was defined by the presence of IgA in the mesangium and/or along the glomerular capillary walls.

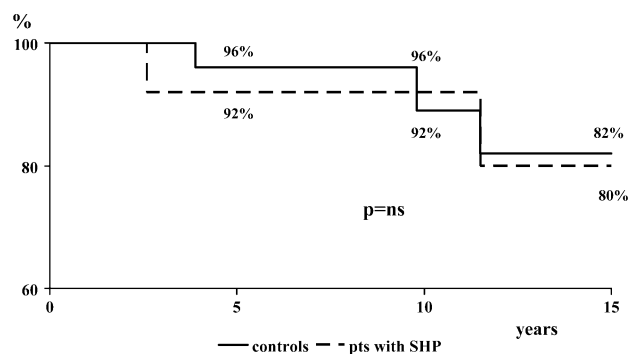
### Immunosuppression

Eight grafts (42%) in the HSP group and 22 (58%) in the control group received a triple therapy (cyclosporine or tacrolimus plus azathioprine or mycophenolate mofetil, plus steroids). Six HSP patients (31%) and eight (21%) controls received cyclosporine plus steroids. Two HSP patients and six controls received steroids plus azathioprine (10% versus 16%). Two HSP patients (10%) and one control (3%) received sirolimus plus cyclosporine and steroids. One patient in each group was treated with cyclosporine only.

Acute cellular rejections were treated with intravenous methylprednisolone pulse (MP) therapy, and acute vascular rejections with anti-thymocyte globulins.

### Statistical analysis

The statistical package S-Plus was used to analyse sample data. Means  $\pm$  SDs were used for descriptive analysis. The *t*-test and the non-parametric Wilcoxon test were used to investigate differences between the two groups of patients.



**Fig. 1.** Kaplan-Meier estimates of patient survival in renal-transplanted patients with Henoch-Schönlein purpura (solid line) and in controls (dashed line).

Cross-tabulated data were analysed by the chi-square test, or by the Fisher test when the expected cell count was  $< 5$ . Survival curves were drawn using the Kaplan-Meier estimate and compared using the log-rank test.

### Results

Of the 1790 renal transplants performed in our Renal Unit between March 1979 and January 2006, 19 (1%) were performed on 17 patients (15 adults, 2 adolescents aged 12 and 14 years, respectively) with HSP (2 patients had 2 transplants). Fifteen (88%) had been submitted to renal biopsy before transplantation; of them, five had necrotizing/crescentic glomerulonephritis involving 25% to  $> 50\%$  of glomeruli. In the other two patients the diagnosis of HSP was based on clinical and biological features. Diagnosis of HSP and that of nephritis were made in mean  $155 \pm 89$  months and  $147 \pm 83$  months, respectively, before transplantation. HSP patients had been on dialysis for  $44 \pm 33$  months before transplantation. At the time of transplantation all HSP patients showed clinical quiescence of the disease for at least 12 months.

The demographic characteristics of HSP patients, the number of HLA mismatches and the levels of panel-reactive antibodies (PRA) revealed no differences from those of the controls. (Table 1).

### Patient and graft survival

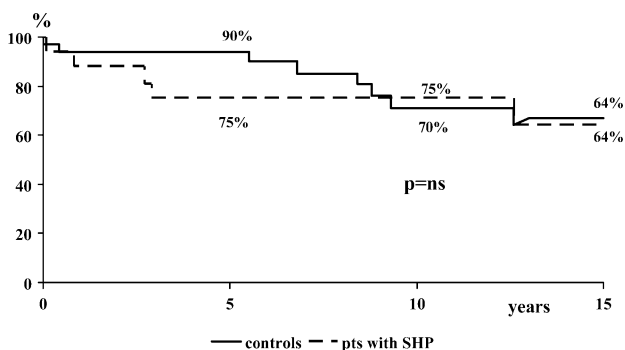
The mean follow-up after renal transplantation was  $109 \pm 99$  months for patients with HSP and  $110 \pm 79$  months for controls. The actuarial 10- and 15-year patient survival rates were 92% and 80% in HSP patients and 96% and 82%, respectively, in controls ( $P = ns$ ) (Figure 1). Two HSP patients died, one in a car accident and the other for desiccation of aortic aneurysm (last serum creatinine 1.3 and 1.6 mg/dl). In the control group, three patients died, two from cardiac infarct and one because of an accident at work (last serum creatinine 1.2, 1.7 and 1.8 mg/dl).

In HSP patients, six grafts were lost (31%), due to acute vascular rejection in one patient, renal recurrence of HSP in four patients and chronic rejection in the other patient. Nine graft failures occurred in the control group (23%).

**Table 1.** Demographic and laboratory characteristics of Henoch–Schonlein purpura and control recipients at renal transplantation

	HSP (19 grafts)	Controls (38 grafts)	P
Age (years) at transplant (mean ± SD)	29 ± 12	31 ± 14	ns
Sex (male/female)	13/6	26/12	ns
Living/deceased donors	7/12	14/24	ns
Length of dialysis (months) (mean ± SD)	45 ± 34	32 ± 25	ns
CAPD/HD	1/17	8/29	ns
HCV positive/negative	5/14	8/30	ns
Follow-up post transplant (mean ± SD)	109 ± 99	110 ± 79	ns
HLA mismatches (number)	3 ± 1.41	2.75 ± 1.54	ns
Panel reactive antibodies (No. of positive)	2	3	ns
Nadir serum creatinine (mg/dl) (mean ± SD)	1.3 ± 0.4	1.8 ± 2.1	ns

CAPD = continuous ambulatory peritoneal dialysis; HD = haemodialysis.

**Fig. 2.** Kaplan–Meier estimates of renal survival probability censored for death in renal-transplanted patients with Henoch–Schonlein purpura (solid line) and in controls (dashed line).**Table 2.** Main complications after kidney transplantation

	HSP patients	Control patients	P
Delayed graft function ≥3 days	0	2	ns
Acute rejections	10	13	ns
Vascular rejections	1	2	
Cellular rejections	2	1	
Clinical acute rejections	7	10	
Chronic rejection	2	4	ns
Unspecific sclerosing lesions	1	6	ns
Arterial hypertension	16 (84%)	33 (86%)	ns
No. of patients with infections	10 (52%)	17 (45%)	ns

There was one case of primary non-functioning kidney, one patient had acute renal artery thrombosis, and the other seven patients lost the graft in mean  $89 \pm 54$  months after transplantation: three due to chronic rejection and four due to aspecific sclerosing lesions. The actuarial 10- and 15-year graft survival rates censored by death were 75% and 64% in HSP patients and 70% and 64%, respectively, in the control group ( $P = ns$ ) (Figure 2).

#### Posttransplant complications (Table 2)

There were no significant differences between HSP patients and controls in the number of delayed graft functions, acute and chronic rejections, unspecific chronic lesions or severe infections.

Considering HSP grafts still functioning at the end of the follow-up (13 out of 19), the mean levels of serum creatinine and daily proteinuria were  $1.6 \pm 0.7$  mg/dl and  $0.3 \pm 0.2$  g/24 h, respectively.

#### Outcome of Henoch-Schonlein purpura during renal transplantation (Table 3)

In 12 of the 19 grafts, 16 biopsies were performed during the follow-up for clinical reasons, such as primary non-function or impairment of graft function and/or proteinuria and/or haematuria. Seven biopsies performed in four grafts did not show IgA immune deposits at immunofluorescence. In the remaining eight grafts (42%) transplanted in seven patients a renal recurrence of HSP was documented in a mean  $30 \pm 41$  months after transplantation; the relapse rate was 0.05/patient/year. In their native kidneys, four patients who received six grafts had necrotizing/crescentic glomerulonephritis, one patient had mesangial proliferation, in another patient only immunofluorescence was available and in the last patient a biopsy of the native kidney was not performed.

The first renal manifestation of the recurrence was microscopic haematuria in seven and macroscopic haematuria in the other graft.

In five patients, proteinuria and a worsening of graft function developed during the following months (patients 1, 2, 3, 6, 7). In three of them (patients 1, 2, 3) the clinical recurrence of the disease occurred within the first year after transplant. The biopsy of their native kidneys showed crescentic glomerulonephritis in 25–50% of the glomeruli. After transplantation their immunosuppressive regimen was steroids, cyclosporine and azathioprine in patient 1; steroids, cyclosporine and sirolimus in patient 2 and steroids and cyclosporine in patient 3. Graft biopsies showed mesangial proliferation with a variable extent of extracapillary and necrotizing glomerular lesions in all of them. At immunofluorescence, IgA was present in the mesangium and along the capillary walls, while fibrin was observed in necrotic areas. The recurrence was treated with a course of 3 MP pulses in patients 1 and 2 and with cyclophosphamide 1 mg/kg/day for 4 months in patient 3. In spite of the therapy, nephrotic syndrome developed and graft function progressively declined, and all three patients restarted haemodialysis 10, 32 and 35 months,

**Table 3.** Patients with recurrence of Henoch-Schönlein purpura

Pts	Sex	Age (years)	Time of recurrence (months)	Donor	At recurrence				Outcome after therapy				At last observation			
					S.creat (mg/dl)	U.prot (g/24 h)	Ery HPF	Therapy	S.creat (mg/dl)	U.prot (g/24 h)	Ery HPF	Follow-up after Tx (months)	S.creat. (mg/dl)	U.prot (g/24 h)	Ery HPF	Follow-up after Tx (months)
1	M	27	4	Living	1.9–2.8	3.9	3+	MP: 3	3.3	2.6	3+	10	7.0 HD	3		
2 1° Tx	M	27	4	Deceased	1.5–1.9	2	3+	MP: 3	1.9	6.0	3+	35	7.6 HD	8.1		
2 2° Tx	M	8	8	Deceased	1.4–1.6	0.20	2+	None	1.4	0.12	2+	14	1.4	0.15		
3	M	29	9	Living	1.6–1.9	4.9	3+	Cycloph 50 mg/day 4 months	2.9	6.3	3+	32	6.0 HD	4.2		
4	F	14	36	Deceased	1.7–1.7	0	3+	None	2	0.3	3+	221	3.2	0.5		
5	M	33	37	Living	1.5–1.5	0.27	MH	None	1.5	0.12	1+	118	1.5	0.23		
6	M	35	127	Deceased	2–3.1	3	2+	MP: 3 Cycloph 150 mg/day 2 months	2.8	3.0	2+	143	5.0 HD	2.4		
7 1° Rec	F	51	17	Deceased	1.5–5.2	4.2	MH	MP: 5	1.9	0.4	1+	84 before 2° recurrence	1.6	0.4		
7 2° Rec	F	51	101	Deceased	1.6–2.4	3.24	MH	MP 3	1.7	1.2	1+	143	1.8 died	0.9		

Pts: patients; S.creat: serum creatinine; U.prot: proteinuria; Ery: erythrocyte; HPF: high power field; MH macroscopic haematuria; MP: methylprednisolone pulses; Cycloph: cyclophosphamide; d: day; Tx: transplant; HD haemodialysis 1° Tx: first renal transplant; 2° Tx: second renal transplant; 1° Rec: first recurrence; 2° Rec: second recurrence. Patient 2 received two renal transplants; patient 7 had two episodes of HSP renal and extrarenal recurrence.

respectively, after transplantation. Patients 2 and 3 received a second deceased graft. Patient 3 lost the second graft due to irreversible vascular rejection 1 month after transplant. Patient 2 developed microscopic haematuria 8 months after the second transplant. The graft biopsy documented the presence of mild mesangial proliferation and IgA immunodeposits. Immunosuppressive therapy (steroid, cyclosporine, mycophenolic acid) was not modified. At last observation, 6 months later, isolated microscopic haematuria persisted with normal graft function.

In patient 6 the recurrence of HSP nephritis developed 10 years after transplant. In this case, the original diagnosis of HSP was based on clinical grounds and no renal biopsy of the native kidney was performed. The immunosuppressive therapy consisted of steroids and cyclosporine. Six years after transplantation a graft biopsy revealed initial signs of chronic rejection but without deposits of IgA at immunofluorescence. Mycophenolic acid was added to the immunosuppressive therapy. Four years later microscopic haematuria and proteinuria developed followed by a worsening of graft function. A second graft biopsy showed extracapillary proliferation and necrosis in 20% of glomeruli, focal and segmental glomerular sclerosis, interstitial fibrosis and arteriolar hyalinosis with mesangial and parietal IgA immunodeposits. In spite of a course of 3 MP pulses followed by cyclophosphamide 2 mg/kg/day for 2 months in substitution of cyclosporine and mycophenolic acid, graft function progressively worsened and the patient eventually restarted dialysis 14 months later.

Seventeen months after renal transplant, patient 7 developed fever, arthralgias, purpuric lesions on the legs and abdomen with macroscopic haematuria, nephrotic syndrome and renal failure. At graft biopsy, necrotizing/crescentic glomerulonephritis in 40% of glomeruli and IgA immunodeposits were present. Treatment with 5 MP pulses within 2 weeks, while continuing cyclosporine, rapidly reversed the extrarenal manifestations. Renal function returned to the basal value within 2 months; proteinuria slowly disappeared and microscopic haematuria persisted. Seven years later a new renal and extrarenal HSP flare occurred that completely reversed after a new course of 3 MP pulses. At repeated graft biopsy, 30% of glomeruli were sclerotic, while fresh crescents with necrosis were present in many other glomeruli. The patient eventually died 12 years after transplantation due to desiccation of aortic aneurysm with serum creatinine of 1.8 mg/dl and proteinuria of 0.9 g/day.

The last two patients (patients 4 and 5) in whom the graft HSP recurrence was documented 3 years after transplant, when microscopic (patient 4) and macroscopic (patient 5) haematuria developed, did not receive additional therapies. The biopsies of their native kidneys showed crescentic glomerulonephritis in patient 4 and mesangial proliferation in patient 5. Graft biopsies in both patients showed a mild increase in mesangial cells in a minority of the glomeruli, and IgA immunodeposits in mesangium. Haematuria disappeared a few months later in both patients. Thirteen years after transplantation, slow but progressive impairment of graft function occurred in patient 4. Considering that the patient was not compliant to therapy, the deterioration of graft function may be attributed to chronic rejection, although a role of the HSP recurrence cannot be excluded. Patient 5

continued to have satisfactory graft function 10 years after transplantation.

There were no significant differences between the 8 grafts in whom the recurrence occurred and the other 11 for any clinical or biochemical or therapeutical features (Table 4); in particular the time from diagnosis to dialysis in the native kidney was not different between the two groups. Five out of seven grafts (71%) of patients in whom the biopsy of the native kidneys showed necrotizing/crescentic glomerulonephritis had graft HSP recurrence, while only one out of nine patients (12%) with pure mesangial nephritis of the native kidney developed a graft recurrence ( $P = 0.05$ ) (Table 4).

At last observation, five out of the eight recurrent grafts lost their function, due to recurrence of HPS nephritis in four and due to sudden vascular rejection in one; one other patient had severe impairment of graft function and the last patient died.

## Discussion

In this study, we have reported our single-centre experience with 17 HSP adults who received 19 renal transplants followed for a mean of 9 years, a fairly long follow-up never reported until now. The majority were adults and were treated with calcineurin inhibitors after transplantation. We used as controls those patients who were transplanted before and after those with HSP and matched for the variables that could influence the outcome of renal transplant. No data are available about the survival of HPS children or adults submitted to renal transplant. In this series, the actuarial 15-year patient survival rate in HSP patients was 80% and 82% in the control group.

Hasengawa [7] reported a graft survival rate of 50% at 10 years in 15 HSP children submitted to 17 renal transplantations, but no comparison with a control group was made. In our series, the actuarial 15-year graft survival rate censored by death was 64% in HSP patients and in controls. Our data underline that patients affected by HSP can obtain a good graft survival even in the long term. In patients with HSP the number of acute and chronic rejections and the risk of developing infections were comparable to those of controls. No data are available about these complications in the published studies.

The risk of HSP recurrence after renal transplantation is still unclear in adults and few data are available in children.

In 15 children who received 17 renal transplants, submitted to serial allograft biopsies, Hasegawa [7] found histological recurrence of HSP in nine grafts (53%). In five patients only, did proteinuria and haematuria develop during the follow-up and two lost the graft due to recurrence. Meulders [9] described the outcome of 14 renal transplants in 10 HSP patients (7 children and 3 adults) followed for a mean period of 66 months. Histological recurrence was documented in three patients (21%) associated with development of proteinuria, haematuria and irreversible deterioration of renal function in two (14%). In addition, five other patients lost the kidney due to chronic rejection. Habib [8] documented a histological recurrence of HSP in eight of nine HSP-transplanted children; proteinuria, haematuria and

**Table 4.** Demographic, clinical and laboratory characteristics of patients with Henoch-Schonlein purpura who relapsed and those who did not

	Grafts with recurrent renal HSP: 8	Non-recurrent grafts: 11	<i>P</i>
Age at tx (years) (mean ± SD)	31.2 ± 10.4	30.1 ± 14.6	ns
Sex (male/female)	6/2	6/5	ns
Months between diagnosis of HSP and ESRD (months) (mean ± SD)	145.1 ± 102	140 ± 92	ns
Duration of dialysis (months) (mean ± SD)	37 ± 19	50 ± 40	ns
Type of dialysis (HD/CAPD)	7/1	11/0	ns
Crescentic GN of the native kidney	71%	12%	0.05
Follow-up post-tx (months) (mean ± SD)	90 ± 77	123 ± 114	ns
Deceased/living donors	5/3	7/4	ns
HCV positivity (yes/no)	1/7	4/7	ns
Calcineurin inhibitors therapy			
No. of grafts	8	9	ns
Basal serum creat. (mg/dl) (mean ± SD)	1.6 ± 0.3	1.2 ± 0.25	0.013
Arterial hypertension	7/0	9/3	ns
Acute rejection	3	7	ns
Chronic rejection	1	1	ns
Unspecific sclerosing lesions	1	0	ns
No. of patients with infections	3	7	ns
Final serum creat. (mg/dl) (mean ± SD)	1.8 ± 0.9	14 ± 0.5	ns
Final proteinuria (g/24 h) (mean ± SD)	0.4 ± 0.2	0.3 ± 0.3	ns
No. of deaths	1	1	ns
No. of lost kidneys	4	2	ns

HSP = Henoch-Schonlein purpura, tx = transplant, ESRD = end-stage renal disease, CAPD = continuous ambulatory peritoneal dialysis, HD = haemodialysis, GN = glomerulonephritis, creat. = creatinine.

progressive deterioration of graft function developed during the follow-up in only one patient. In contrast, Cameron [11] found no histological recurrence in 7 out of the 10 HSP-transplanted children.

In adults with IgA nephropathy too, allograft recurrences of mesangial IgA deposits have been occasionally noted even though there have been no clinical manifestations of glomerulonephritis or with only minimal haematuria [12,13]. Since IgA nephropathy and HSP probably share [14] similar immune pathogenetic mechanisms it is not surprising to observe also in HSP patients histological recurrences in allografts without clinical signs. The prognostic significance of these forms of histological recurrences, not complicated by the development of clinical manifestations, is not clarified. However, they do not seem to unfavourably impact on the graft survival.

In our study we performed graft biopsies only for clinical purposes. However, in four grafts, on which seven renal biopsies were performed, no IgA immunodeposits were found, while in another eight grafts histological recurrences of HSP were documented. Three patients recurred with microscopic or macroscopic haematuria, and all had mild histological lesions. These clinical manifestations were transient in two while haematuria persisted in the last patient. At the last observation, 14 months and 7 years after transplant, respectively, two patients had good renal function, while the third patient, 18 years after transplant, had impaired graft function, although without urinary abnormalities. In this last case, even in the absence of histological documentation, the renal dysfunction was unlikely to have been due to the progression of nephritis. In the other five patients, the clinical manifestations as well as the histological lesions were more severe. In spite of the reinforcement of

immunosuppression, all but one lost the graft. Altogether we found a histological recurrence of 42% in HSP patients, but the rate of recurrence rose to 64% if only those patients who received a post-transplant biopsy were evaluated. A comparable rate of recurrence was observed in our series of 106 transplanted patients with IgA nephritis followed for a mean period of 70 months: 35% of all patients and 65%, if only patients submitted to graft biopsy were considered. [15]. In contrast, the median time for histological recurrence was longer in our IgA patients (52 months) than in HSP patients (30 months), and the percentage of graft failure due to recurrence was lower in IgA (11%) than in HSP (50%) patients. These data underline that, as for the course of these diseases in the native kidney, the recurrence of HSP pertains a worse graft prognosis than that of IgA nephritis.

As recently shown in the native kidney of patients with HSP [1] the worsening of graft function was heralded in our five patients by the progressive increase of proteinuria. In contrast to what has been reported by others [9,16] we did not observe either a shorter duration of the original disease or a higher incidence of grafts from living donors in patients who relapsed than in those who did not. Instead, a significantly higher rate of recurrences of HSP nephritis was observed in our patients with crescentic glomerulonephritis of the native kidney. Although this observation is based on a small series, it is possible to speculate that in these patients crescentic nephritis represents a more aggressive form of the original disease that recurs in the graft in spite of immunosuppression.

Few data are available concerning the treatment of the recurrence of HSP in the graft [7,9,17,18], and in the majority of those cases the therapy was unsuccessful [7,9]. The use of

the new immunosuppressive agents and the reinforcement of therapy with i.v. MP pulse and/or oral cyclophosphamide did not prevent the recurrence and/or the progression of graft dysfunction in the majority of our recurrent patients.

In conclusion, our study, although retrospective and based on a small sample size, suggests that transplanted patients with HSP may have good patient and graft survival, not only in the short term but also up to 15 years. Therefore, patients with HSP may be considered as suitable candidates for kidney transplantation. However, the risk of recurrence is high, and in spite of an aggressive therapy, the recurrence can cause graft loss in the majority of patients. Patients with crescentic glomerulonephritis of the native kidneys, who seem to be at higher risk of recurrence, should be closely monitored, particularly during the first years after transplant.

*Acknowledgement.* The study was supported by the grant 'Project in glomerulonephritis' in memory of Pippo Neglia.

*Conflict of interest statement.* None declared.

## References

- Coppo R, Andrulli S, Amore S *et al.* Predictors of outcome in Henoch–Schonlein nephritis in children and adults. *Am J Kidney Dis* 2006; 47: 993–1003
- Soler MJ, Mir M, Rodriguez E *et al.* Recurrence of IgA Nephropathy and Henoch–Schonlein Purpura after kidney transplantation, risk factors and graft survivals. *Transplant Proc* 2005; 37: 3705–3709
- Briganti EM, Russ GR, McNeil JJ *et al.* Risk of renal allograft loss from recurrent glomerulonephritis. *N Engl J Med* 2002; 347: 103–109
- Bar-On H, Rosenmann E. Schonlein–Henoch syndrome in adults. *Israel J Med Sci* 1972; 8: 1702–1715
- Nast CC, Ward KJ, Koyle MA *et al.* Recurrent Henoch–Schonlein purpura after renal transplantation. *Am J Kidney Dis* 1987; 9: 39–43
- Crown AL, Woolfson RG, Griffiths MH *et al.* Recurrent systemic Henoch Schonlein purpura in an adult following renal transplantation. *Nephrol Dial Transplant* 1994; 9: 423–425
- Hasegawa A, Kawamura T, Ito H, *et al.* Fate of renal grafts with recurrent Henoch–Schonlein Purpura nephritis in children. *Transplant Proc* 1989; 21: 2130–2133
- Habib R, Antignac C, Hinglais N *et al.* Glomerular lesions in the transplanted kidney in children. *Am J Kidney Dis* 1987; 3: 198–207
- Meulders Q, Pirson Y, Cosyns JP *et al.* Course of Henoch–Schonlein nephritis after renal transplantation. *Transplantation* 1994; 58: 1179–1186
- Solez K, Colvin RB, Racusen LC *et al.* Banff 05 Meeting Report: differential diagnosis of chronic allograft injury and elimination of chronic allograft nephropathy (CAN). *Am J Transplant* 2007; 7: 518–526
- Cameron JS. Glomerulonephritis in renal transplants. *Transplantation* 1982; 34: 237–245
- Morzyccka M, Croker BP, Seigler HF *et al.* Evaluation of recurrent glomerulonephritis in kidney allografts. *Am J Med* 1982; 59: 177–190
- Mathew TH, Mathews DC, Hobbs JB *et al.* Glomerular lesions after renal transplantation. *Am J Med* 1975; 59: 177–190
- Rai A, Nast C, Adler S. Henoch–Schonlein Purpura Nephritis. *J Am Soc Nephrol* 1999; 10: 2637–2644
- Ponticelli C, Traversi L, Feliciani A *et al.* Kidney transplantation in patients with IgA mesangial glomerulonephritis. *Kidney Int* 2001; 60: 1948–1954
- Chadban SJ. Glomerulonephritis recurrence in the renal graft. *J Am Soc Nephrol* 2001; 12: 394–402
- Nyberg G, Akesson P, Gunela N *et al.* Systemic vasculitis in kidney transplant population. *Transplantation* 1997; 63: 1273–1277
- Lee J, Clayton F, Shihab F *et al.* Successful treatment of recurrent Henoch–Schonlein Purpura in a renal allograft with plasmapheresis. *Am J Transplant* 2007; 8: 228–231

*Received for publication:* 15.12.07

*Accepted in revised form:* 20.3.08