

C. Maspero\*, G. Galbiati\*\*, L. Giannini\*\*,  
G. Guenza\*\*, L. Esposito\*, G. Farronato\*

Department of Orthodontics, Fondazione IRCCS Cà Granda –  
Ospedale Maggiore Policlinico, University of Milan, Milan, Italy  
\*MD, DDS \*\*DDS

email: [giampietro.farronato@unimi.it](mailto:giampietro.farronato@unimi.it)

DOI: 10.23804/ejpd.2018.19.01.12

## Titanium TSME appliance for patients allergic to nickel

### ABSTRACT

**Aim** The aim of this article is to describe the use of a titanium TSME appliance for patients with allergy to resin and nickel. We aim to highlight the optimal way to avoid problems such as stomatitis and peri-labial dermatitis, which generally appear in patients who use traditional orthodontic appliances made in acrylic resin and steel.

**Materials and methods** The construction of a titanium appliance is described and a case treated with it is reported.

**Results** The titanium TSME presented in this paper has excellent biocompatibility due to its ability to form superficial oxides, which prevent oxidation and thus corrosion.

**Conclusion** The non-allergic properties of titanium allow to propose it as an alternative in patients with a long-term history of allergic reactions to nickel.

**Keywords** Allergy; Biocompatibility; Hypersensitivity; Patch test; Rapid palatal expander; TSME.

### Introduction

During the last few years an increased incidence of allergic reactions to nickel and resin (polymethylmethacrylate) in patients undergoing orthodontic treatment has been evidenced [Baker et al., 2008; Budinger et al., 2000]. Oral appliances come in direct contact with the oral tissues and therefore require good adaptation to the biological environment [Baker et al., 1998; Budinger and

Herti, 2000; Farronato et al., 2013; Wataha, 2000].

Steel usually contains nickel and it is used for the construction of the majority of orthodontic appliances. Nowadays biocompatibility of orthodontic materials represents a clinical problem and is linked to an increased use of piercings, which may cause a generalised sensitivity to nickel [Kerosuo and Kanerval, 1997]. The metal alloys mainly used for the construction of orthodontic appliances are stainless steel 18/8, which contains 18% chromium, and 8% nickel and NiTi elastic alloys contain 50% of nickel. Nickel and chromium can cause contact hypersensitivity and this may manifest as itching, eczema, vesicles, urticaria and desquamation. In more severe cases, the patient may present respiratory conditions such as asthma, and gastroenterological problems. Nickel is generally present in many metallic ornaments such as jewelry, kitchen utensils, cosmetic products, washing powders, hair colors and dietary products. [Kerosuo and Kanerval, 1997; Farronato et al., 2002]. Although nickel is the most common cause of contact allergy, nickel-containing orthodontic appliances seldom cause adverse reactions that result in discontinuation of treatment. Exposure to nickel-containing orthodontic appliances may cause intra- or extra-oral allergic reactions. Nickel is frequently associated with allergic contact dermatitis, which is a Type IV delayed hypersensitivity immune response. The diagnosis of specific allergies is confirmed by means of skin patch test, which involves application of patches containing the allergens to which hypersensitivity is suspected to be related. The reaction is considered positive when redness of the skin or itching vesicles are present.

The Rapid Palatal Expander is one of the most commonly used nickel-containing orthodontic appliance: it can be anchored to deciduous or permanent molars and is often used to increase the palatal transverse dimension or to intercept maxillary incisor crowding in the mixed dentition. The expander anchored on deciduous teeth is effective in improving dental arch constriction and crowding in patients treated for lateral crossbite [Mutinelli and Cozzani, 2015]. Also, in the absence of posterior crossbite, the RPE provides an "anticipation of transverse growth" and could be indicated to expand the anterior portion of the maxillary arch perimeter to solve upper incisor crowding [Rosa et al., 2016].

Oral rashes due to nickel allergy are rare. A common presentation of intraoral contact dermatitis is the presence of lichenoid plaques of the buccal mucosa, but sometimes papular erythema on the face and neck can also be observed. Also some important reaction such as laryngeal edema are described in literature. The incidence of metal allergies has been found to be 1% in men and 10% in women. A major risk factor for hypersensitivity is ear piercing or piercings in other body areas as once the hypersensitivity has established, all the oral mucosal surfaces may be involved [Kerosuo and Kanerval, 1997]. Such problems led to the research of

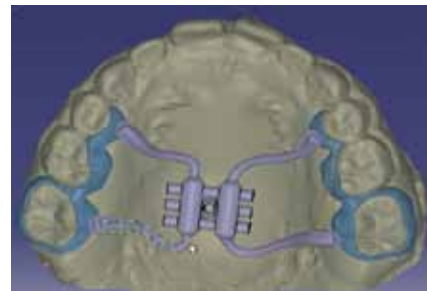
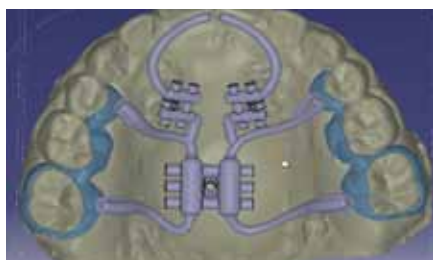
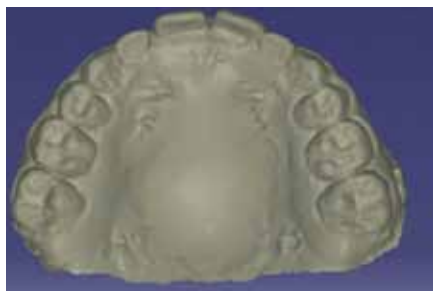

FIG. 1-3 TSME appliance.

alternative materials for orthodontic appliances.

The aim of this article is to describe the titanium TSME appliance for patients allergic to nickel and to highlight the resolution of conditions such as stomatitis and perioral dermatitis that can develop with the use of the traditional orthodontic TSME steel appliance [Farronato et al., 2011; Farronato et al., 2007; Maspero et al., 2012].

## Materials and methods

### Appliance design

The TSME is a fixed device specifically designed for patients with constricted dental arches, and maxillary transverse and anteroposterior deficiency. The appliance is versatile and it may also be worn in association with extra-oral devices.

### Construction of the rapid palatal expander

The titanium TSME consists of two titanium bands crowns cemented to the right and left first maxillary molars, a Hyrax-type transverse expansion screw, two 0.045-inch titanium wires extending to the palatal surfaces of the central incisors and two 8 mm Hyrax-type screws attached to these wires between the molar bands and the incisors. The device is realised with a titanium screw. The Rematitan casting system and the laser welding technology (Dentaurum Desktop) to couple the titanium screw with the titanium arms are used. The laser welding technology is crucial to obtain a monometallic structure that can avoid galvanic side effects and guarantee mechanical properties.

The critical area is the connecting point between the titanium arms and the titanium screws. Currently there are no commercially available titanium bands and it has therefore been necessary to anchor the palatal expander to the teeth with the aid of titanium band crowns.

Construction phases of the palatal expander:

- silicon impressions;
- construction and duplication of study models with the same refractory material used for the titanium castings. On this model the structure is waxed;
- band crowns are adapted to the molars.
- the splice bars are modelled on the screw using different thicknesses of wax, and the smallest splice bars are modelled for the canine area;
- placement of the screw protected by wax before the laser welding phase;
- after this last phase the casting is prepared by channelling all the waxes to blend them with the main flow channel;
- the model with the wax is placed into the casting box and finally the metal is cast;
- the casted elements are then smoothed, glassed and polished;
- finally the titanium arms and the expansion screws are welded to the structure;
- the TSME is ready to be cemented in the oral cavity with a photo-activated composite.

The activation of the appliance must be carried out twice daily until the desired expansion has been obtained, thus restoring the correct nasal respiratory function (Fig. 1–3).

### Appliance application

Once the appliance is finished, it is placed according to the following procedure:

- separators should be positioned three days before the appliance is fitted;
- the expander is tested in the mouth to try the proper fit;
- the appliance is cementated in place;
- the correct positioning and inclination of the palatal arms should be controlled.
- the appliance is worn for 6 to 12 months.

In the first phase, the transverse screw is activated one quarter turn twice per day until the desired expansion has been obtained [Farronato et al., 2011b].

In the second phase the sagittal screw is activated one quarter turn every 7 days for 6–8 months. [Farronato et al., 2011a; Farronato et al., 2011b].

The structure of the titanium TSME proved highly resistant, especially during periods of maximum

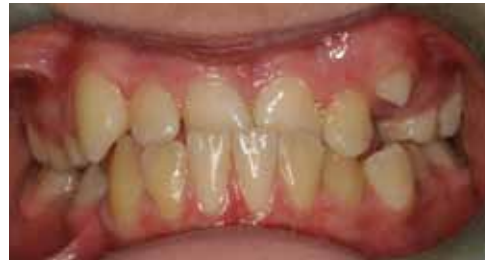

FIG. 5, 6 Extraoral and intraoral photos at the beginning of the treatment.

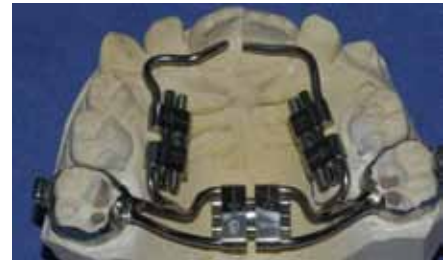

FIG. 7 The titanium TSME appliance.

mechanical stress such as on activation. No fractures occurred during the fusion.

### Case report

The patient A.S. came to the Orthodontic Department at the age of 11. Intraoral examination showed a dental Class III, 3 mm overbite and -3 mm overjet, anterior crossbite and palate hypoplasia (Fig. 5, 6). Conventional treatment of this kind of malocclusion is performed with bonded RME and facial mask, which produce in the deciduous or early mixed dentition a significant expansion of the maxillary arch and mesialisation of the posterior teeth with reduction of the arch depth [Lione et al., 2015].

The medical history revealed nickel hypersensitivity, so to avoid allergic reactions a nickel-free TSME appliance was used (Fig. 7). After taking dental impressions, the orthodontic appliance was fabricated. The patient and the parents were instructed about the activation protocol both on the transversal and sagittal dimension until the desired expansion was obtained. The appliance was then left in place for further six months. At the end of the 12-month treatment, the patient showed a dental Class I and correct transversal and sagittal relationships between the basal bone (Fig. 8).

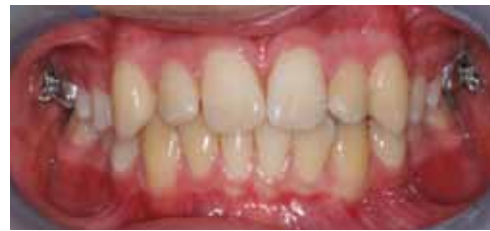

FIG. 8 Intraoral photo at the end of treatment.

technologies available such as the Rematitan (Dentaurum), which allows fabrication of appliances that are mechanically valid and fully biocompatible. The non-allergic properties of titanium make this material a valid alternative in individuals with a history of allergic reactions to metals and resins.

## Discussion and conclusion

The corrosion phenomenon occurring within the oral cavity is the basis of allergies as it determines the release of ions, which act as allergens capable of activating cellular mediated allergic reactions responsible for the clinical manifestations of nickel allergy [Noble et al., 2008].

The biocompatibility of materials is directly correlated to the corrosion phenomenon. Titanium allows to construct appliances with a good mechanical resistance, lightweight and totally non-allergic. The titanium appliance used for this study obtained excellent results due to its ability to produce a superficial layer of oxide, that is the passive layer, which prevents corrosion.

Nowadays the difficulty of fabrication of titanium appliances has been resolved due to new laboratory

## References

- › Baker S, Brooks SC, Walker DM. The release of residual monomeric methyl methacrylate from acrylic appliance in the human mouth: an assay for monomer in saliva. *J Dent Res* 1998;67:129-139.
- › Budinger T, Herti M. Immunologic mechanisms in hypersensitive reactions to metal ions: an overview. *Allergy* 2000;55:108-15.
- › Lione R, Buongiorno M, Laganà G, Cozza P, Franchi L. Early treatment of Class III malocclusion with RME and facial mask: evaluation of dentoalveolar effects on digital dental casts. *Eur J Paediatr Dent* 2015 Sep;16(3):217-20.
- › Farronato G, Alicino C, Tirafilli C, Santoro F. Titanium appliances for allergic patients. *J Clin Orthod* 2002;12:676-679.
- › Farronato G, Cordasco G, Farronato D, Esposito L, Briguglio E. The transverse sagittal maxillary expander. *J Clin Orthod* 2007;41:387-391.
- › Farronato G, Maspero C, Esposito L, Briguglio E, Farronato D, Giannini L. Rapid maxillary expansion in growing patients. Hyrax versus transverse sagittal maxillary expander: a cephalometric investigation. *Eur J Orthod* 2011a;33:185-189.
- › Farronato G, Giannini L, Galbiati G, Maspero C. Sagittal and vertical effects of rapid maxillary expansion in Class I, II, and III occlusions. *Angle Orthod* 2011b Mar;81(2):298-303.
- › Farronato G, Giannini L, Galbiati G, Cannalire P, Martinelli G, Tubertini I, Maspero C. Oral tissues and orthodontic treatment: common side effects. *Min Stomat* 2013 Nov-Dec;62(11-12):431-46.
- › Kerosuo I, Kanerva L. Systemic contact dermatitis caused by nickel in a stainless steel orthodontic appliance. *Contact Dermatitis* 1997;36:112-123.
- › Maspero C, Galbiati G, Perillo L, Favero L, Giannini L. Orthopedic treatment efficiency in skeletal Class III malocclusions in young patients: RME-face mask versus TSME. *Eur J Paediatr Dent* 2012 Sep;13(3):225-30.
- › Mutinelli S, Cozzani M. Rapid maxillary expansion in early-mixed dentition: effectiveness of increasing arch dimension with anchorage on deciduous teeth. *Eur J Paediatr Dent* 2015 Jun;16(2):115-22.
- › Noble J, Ahing SI, Karaikos NE, Wiltshire WA. Nickel allergy and orthodontics, a review and report of two cases. *Br Dent J* 2008; 22; 204(6):297-300.
- › Rosa M, Lucchi P, Manti G, Caprioglio A. Rapid Palatal Expansion in the absence of posterior cross-bite to intercept maxillary incisor crowding in the mixed dentition: a CBCT evaluation of spontaneous changes of untouched permanent molars. *Eur J Paediatr Dent* 2016 Dec;17(4):286-294.
- › Wataha JC. Biocompatibility of dental casting alloys: a review. *J Prosthet Dent* 2000;83:223-34.